

Alterations of FHIT and P53 genes in keratocystic odontogenic tumor, dentigerous and radicular cyst

Malčić, Ana; Jukić, Silvana; Anić, Ivica; Pavelić, Božidar; Kapitanović, Sanja; Krušlin, Božo; Pavelić, Krešimir

Source / Izvornik: **Journal of Oral Pathology & Medicine, 2008, 37, 294 - 301**

Journal article, Accepted version

Rad u časopisu, Završna verzija rukopisa prihvaćena za objavljivanje (postprint)

<https://doi.org/10.1111/j.1600-0714.2007.00622.x>

Permanent link / Trajna poveznica: <https://urn.nsk.hr/urn:nbn:hr:105:443461>

Rights / Prava: [In copyright](#)/[Zaštićeno autorskim pravom.](#)

Download date / Datum preuzimanja: **2025-02-07**



Repository / Repozitorij:

[Dr Med - University of Zagreb School of Medicine
Digital Repository](#)





Središnja medicinska knjižnica

Malčić A., Jukić S., Anić I., Pavelić B., Kapitanović S., Krušlin B., Pavelić K. (2008) *Alterations of FHIT and P53 genes in keratocystic odontogenic tumor, dentigerous and radicular cyst.* Journal of Oral Pathology & Medicine, 37 (5). pp. 294-301. ISSN 0904-2512

<http://www.wiley.com/bw/journal.asp?ref=0904-2512>

<http://www.interscience.wiley.com/jpages/0904-2512>

<http://www3.interscience.wiley.com/journal/119406841/abstract>

<http://medlib.mef.hr/740>

University of Zagreb Medical School Repository

<http://medlib.mef.hr/>

ALTERATIONS OF FHIT AND p53 GENES IN KERATOCYSTIC ODONTOGENIC TUMOR, DENTIGEROUS AND RADICULAR CYST

Running title: FHIT and p53 in KOT, DC and RC

Key words: FHIT, keratocystic odontogenic tumor, odontogenic cyst, p53

**Malčić Ana¹, Jukić Silvana¹, Anić Ivica¹, Pavelić Božidar¹, Kapitanović Sanja²,
Krušlin Božo³, Pavelić Krešimir²**

¹ Department of Endodontics and Restorative Dentistry, School of Dental Medicine,
University of Zagreb, Gundulićeva 5, 10000 Zagreb, Croatia

² Division of Molecular Medicine, Rudjer Boskovic Institute, Bijenička cesta 54, 10000
Zagreb, Croatia

³ Department of Pathology, School of Medicine, University of Zagreb, Šalata 3, 10000
Zagreb, Croatia

Corresponding author:

Ana Malčić DDS

Department of Endodontics and Restorative Dentistry

School of Dental Medicine, University of Zagreb

Gundulićeva 5

10 000 Zagreb

Croatia

Tel. +385 1 4802 126

Fax: +385 1 4802 159

e-mail: amalcic@inet.hr

ABSTRACT

Background: The purpose of this study was to determine fragile histidine triad (FHIT) and p53 protein expression, and to analyze FHIT and p53 gene status in keratocystic odontogenic tumor (KOT), dentigerous (DC) and radicular cysts (RC).

Methods: The methods used were immunohistochemistry and molecular genetic methods including loss of heterozygosity (LOH) and gene sequencing.

Results: FHIT protein expression was different among groups. Aberrant expression was the highest in KOT, then RC and DC. p53 protein expression was different among groups. Loss of heterozygosity (LOH) in paraffin embedded specimens was detected in 22.6% and 12.9% for FHIT and p53, respectively. Mutation of p53 gene at codon 237 was observed in only two specimens (1 KOT, 1 DC).

Of the six frozen specimens, three exhibited FHIT gene LOH (2 RC, 1 KOT). KOT showed loss of exons 6-7 at FHIT locus and mutation at codon 237 at p53 locus, but this could be a chance result.

Conclusion: Aberrations of FHIT and p53 genes/proteins could be considered markers responsible for the development of odontogenic lesions.

INTRODUCTION

Fragile histidine triad (FHIT) is a tumor-suppressor gene isolated and identified by collaborating researchers in the USA and Japan in 1996 and it was shown to span the most common human fragile chromosomal site FRA 3B at 3p14.2.^{1,2} Besides 3p14.2, there are 3 other major regions at 3p shown to be involved in allelic losses in human malignancies: 3p25, 3p21.3 and 3p12.^{3,4} The region 3p14.2 contains FRA3B,^{1,5} familial kidney cancer-associated translocation breakpoint t(3;8)(p14.2;q24),⁶ and papilloma virus integration sites.⁷ Studies on FHIT gene demonstrated that its expression is altered in many human epithelial cancer cell lines including lung, bladder, breast, cervical carcinomas, and that it is frequently a target of homozygous deletions at 3p14.2.^{2, 8, 9} Role of the FHIT gene has been studied in primary cancers of the oral cavity, tongue, oral squamous cell carcinoma and head and neck squamous cell carcinoma.¹⁰⁻¹² FHIT functions as a tumor suppressor *in vivo* and *in vitro* and its over expression induces apoptosis.¹⁰

FHIT gene encodes a 147 amino acid protein showing 69% similarity in a core region of 109 amino acids to diadenosine 5',5''P¹, P⁴-tetraphosphate (Ap₄A) hydrolase from the fission yeast *Schizosaccharomyces pombe*, a member of histidine triad protein family.¹ Aberration of FHIT gene is estimated on the level of DNA loss of heterozygosity analysis (LOH), altered mRNA FHIT transcripts and absence or reduction of the FHIT protein.¹³⁻¹⁵

Fragile histidine triad mRNA alterations are also detected in normal tissues and the abnormality can be due to abnormal splicing and processing of the transcripts, since the gene is located in a region prone to stress-induced damage and some of the genetic changes observed, might be a reflection of an intrinsic instability due to cancer cell growth.^{16,17}

The p53 gene is one of the most common tumor-suppressor genes located on the short arm of chromosome 17. It spans a region of 20 kb and is made of 11 exons which encode nuclear

phosphoprotein having molecular weight of 53 kDa.¹⁸ The disturbed function of p53 results in uncontrolled proliferation of the cell. The mutations of p53 are present in more than 50% of malignant tumors and are commonly related to early and frequent death, decreased differentiation of cells and early recurrence.¹⁹⁻²¹ In normal tissue p53 protein has a short half-life and cannot be detected using immunohistochemical techniques, whereas the p53 gene mutation produces increased stability and over expression of p53 protein.²²

Keratocystic odontogenic tumor (formerly odontogenic keratocyst) and odontogenic cysts are derived from the remnants of odontogenic epithelial cells. It has been postulated that there is a regulated balance between cell proliferation, differentiation and death in the development of the jaw cysts resulting in the specific histopathology in the lining epithelium.²³ This suggests that different factors may be involved in the development of these lesions, and numerous papers have dealt with the expression of tumor-suppressor genes and oncogenes in KOT, DC and RC.²³⁻³¹ The higher incidence of p53 aberration in former OKC than in DC and RC was reported.^{23,24,27} According to the available literature no studies on FHIT in KOT and odontogenic cysts were performed.

The purpose of this study was to determine differential expression of FHIT as an apoptosis related factor and p53 as a marker for, both cellular proliferation and apoptosis.

Immunohistochemical and molecular methods were used to clarify details of the epithelial lining cells' proliferation and death, particularly with respect to aggressive clinical behavior of former OKCs, in the context of new WHO classification according to which the former OKCs have been classified as benign neoplasm- KOT.²⁸

MATERIALS AND METHODS

Tissue specimens

Ninety two paraffin embedded specimens of odontogenic lesions were obtained from Department of Pathology, School of Medicine, University of Zagreb, Croatia, Institut für pathologie, Universität Hamburg, Germany and Abteilung für Chirurgie Klinik für Zahn-, Mund-, Kieferheilkunde, Universität Würzburg, Germany. Of the 92 specimens, 38 were KOT, 13 dentigerous cysts (DC) and 41 radicular cysts (RC). The paraffin embedded specimens were collected and evaluated in concordance with all ethical and legal requirements.

Six specimens of odontogenic cysts and blood samples were obtained from Department of Oral Surgery, Clinical Hospital Dubrava, Zagreb, Croatia. The specimens of odontogenic cysts were obtained during routine surgery and were snap frozen in liquid nitrogen shortly after surgical removal and stored at -80°C. A part of each tissue sample was embedded in paraffin. Sections of each paraffin block were stained with hematoxylin and eosin to confirm the tissue analyzed. Of the 6 samples 1 was KOT, 1 DC and 4 RC. Full blood samples in acid citrate dextrose tubes were obtained from the patients after the surgery by trained personnel. The patients signed informed consent for participating in the research before the surgery.

Immunohistochemical examination of FHIT and p53 proteins

Four µm sections of 92 paraffin embedded samples were cut and mounted on slides for immunohistochemical analysis of FHIT protein (48 male and 44 female, age ranged from 14 to 69, mean age 40.9; 38 KOT, 13 DC, 41 RC). They were further deparaffinized and rehydrated through xylene and graded alcohols, and incubated in 3% H₂O₂ in methanol for 10 minutes to block endogenous peroxidase activity. Antigen retrieval was then performed by heating slides in microwave oven immersed in citrate buffer (750 W, pH 6, 15 minutes). Nonspecific antibody binding was blocked with pig serum diluted by PBS (1:20, 20 minutes). Anti-FHIT rabbit polyclonal primary antibody (Zymed Laboratoires Inc., San Francisco, USA)

was diluted by PBS (1:80). Sections were incubated for 12 hours at 4°C with antibody in PBS containing 5% rabbit serum. The sections were processed for detection of the positive immunohistochemical reaction using Universal LSAB+ kit (DAKO Corp., USA) (Biotinylated link and Streptavidin-HRP) and Liquid DAB (DAKO Corp., USA). For the negative control, the primary antibody was replaced with normal rabbit serum. Tumor tissue with the wild-type of FHIT gene (breast carcinoma) was used as positive control.

Immunohistochemical evaluation of p53 protein was performed on 64 samples (32 KOT, 13 DC, 19 RC) as described previously.²⁷ The samples of KOT and RC for p53 protein expression analysis were chosen according to the results of their, negative or weakly positive, reactivity to FHIT. Certain samples were not analyzed for p53, regardless of their positive or weakly positive reaction to FHIT, because the paraffin embedded sample was initially too small and we could not obtain good sections for p53 analysis. Total number of DC samples was only 13, so all DC samples were analyzed for p53 reactivity regardless of their FHIT reactivity.

The intensity of staining was evaluated for the epithelial cells of the cyst lining as negative, weak positive or strong-positive staining, for FHIT and p53 protein. The criteria were as follows: no staining detected in epithelial cells was classified as negative reaction, staining detected in <25% epithelial cells was classified as weak positive reaction and if more than 25% epithelial cells showed staining the reaction was classified as strong-positive reaction. The percentage of FHIT-stained cytoplasm or p53-stained nuclei was calculated manually from a minimum of 1000 nuclei i.e. cells at a magnification of 400x. The staining was regarded as positive regardless of the staining intensity. Cells within the cyst wall (fibrocytes and lymphocytes in the case of RC) served as the internal negative control. The specimens were histologically evaluated by a trained pathologist.

Isolation of DNA and RNA and reverse transcription

After deparaffinisation,³² genomic DNA from microdissected epithelial cyst lining was extracted from the tissue collected in 500 µl microcentrifuge with digestion buffer (0.9% Tween20, 0.9% Trion X-100, 5 nM EDTA, 2mM DTT, 10 mM TrisHCl, pH 7.5) and Proteinase K (20µg/ml; Roche Diagnostics, Mannheim, Germany). Nucleic acids were quantified by reading UV absorbance at 260 nm. The extracts were stored at -20° until assayed. Control normal DNA of the patients was extracted from corresponding normal tissue surrounding the lesion.

Genomic DNA from micro dissected epithelial lining of frozen samples was extracted as described, but without deparaffinisation.³⁰ Control normal DNA from the whole blood samples was isolated using a standard phenol-extraction procedure.³³

Total RNA from snap frozen tissue specimens was extracted using RNAzolTMB reagent (Biogenesis, Poole, UK) according to manufacturer's protocol. Recovered RNA was assayed by a 260/280 nm ratio. The reaction volume of 20 µl for reverse transcription contained 5 µg denatured RNA (10 min, 70 °C), 2 µl 10 x reverse transcriptase buffer (500 Mm Tris HCl, pH 8.3, 300 mM KCl, 80 mM MgCl₂, 100 mM dithiothreitol; New England BioLabs Inc.), 2µl 10 mM each dNTPs (Roche), 25 U Moloney Murine Leukemia Virus reverse transcriptase (New England BioLabs Inc., Frankfurt am Main, Germany) and 0.4 mM oligo (dT)₁₈ (New England BioLabs Inc.). The reaction was performed at 42°C for 1 hour. The reaction was inactivated at 70°C for 15 min and at 94°C for 3 min. The cDNA was used as a template in the following PCR reactions.

PCR amplification, FHIT and p53 gene expression analysis

The FHIT gene expression analysis was performed by nested RT-PCR method as described previously.³⁴ Half of microliter of cDNA was used for PCR amplifications with primers 5U2

and 3D2 from FHIT exons 1 and 10, respectively. Two microliters of first PCR products were used for nested PCR amplifications with primers 5U1 and 3D1 from FHIT exons 3 and 10, respectively. The PCR products were resolved by agarose gel electrophoresis (1.5% agarose stained with 0.5 µg/ml ethidium bromide). The sequencing of aberrant PCR products was performed as described previously.³⁵

The p53 gene expression analysis was performed as described by Li et al.²⁹ Forty cycles were performed (94°C, 55 °C, 72°C, 1 min each) to amplify exons 5-9 of p53 gene in a 100 µl reaction mixture. The sufficient PCR target products for the exons 5-9 were obtained only with DNA templates obtained from some paraffin sections and all fresh frozen samples. The PCR products were resolved by agarose gel electrophoresis. p53 gene mutations analysis was performed by SSCP analysis of all p53 gene exons. Mutations were detected by direct sequencing of the relevant genomic DNA fragments with aberrant profile in SSCP analysis using CircumVent™ Thermal Cycle dideoxy DNA sequencing kit (New England Biolabs) according to the manufacturer's instructions. Mutations were additionally confirmed using fluorescence-based dideoxy sequencing on Applied Biosystems Model 373A automated sequencer (ABI Foster City, Ca, USA).

Loss of heterozygosity analysis (LOH)

Thirty one paraffin embedded samples (11 KOT, 10 DC, 10 RC) were chosen for LOH analysis of FHIT and p53 loci according to their aberrant immunohistochemical reaction for either FHIT, p53 or both. All six frozen samples (1 KOT, 1 DC, 4 RC) were analyzed for FHIT and p53 LOH. Five µm sections of paraffin embedded samples were cut for microdissection and DNA extraction from the epithelial lining of the cyst samples. Constitutional DNA was obtained from the blood samples corresponding to the frozen cyst specimens.

To analyze LOH at the FHIT gene, D3S1300 dinucleotide repeat and D3S4103 trinucleotide repeat were used as described previously³⁴.

LOH at the p53 gene locus was analyzed by VNTR analysis and highly informative exogenic (CA)_n repeat as it was previously described.³⁶

LOH was recognized as visible change in alleles in terms of allele ratio in cyst epithelial lining compared with matching normal tissue.

Statistical analysis

The data of FHIT and p53 protein expression, and LOH analysis for FHIT and p53 gene in KOT, DC and RC, were compared with modified Fisher's exact test as described in SAS Procedures Guide.³⁷ The proportion of FHIT and p53 aberrant expression was compared to the number of epithelial cell layers using Chi-square test. The SAS System for Windows, Release 8.02, TS Level 02M0 (SAS Institute Inc., Cary, NC, USA) was used.

RESULTS

FHIT and p53 protein expression in paraffin embedded samples

To investigate the reactivity of FHIT protein, we examined 38 KOT, 13 DC and 41 RC samples embedded in paraffin. Reactivity to FHIT was for KOT: (-) 28, (+) 9, (++) 1; for DC: (-) 4, (+) 2, (++) 7; for RC: (-) 20, (+) 12, (++) 9. The intensity of aberrant (negative) immunohistochemical reaction for FHIT protein was different between the three groups ($p=0.00078$), and it was the highest in KOT, then RC and DC. Although the reaction for FHIT was negative in the majority of specimens, in the cases where the reaction was positive it was observed in the cytoplasm of the epithelial lining (Fig 1). In KOT, staining was observed mostly in suprabasal cells and in DC and RC in basal to superficial epithelial cells.

The intensity of p53 immunostaining was weak, and it was the highest in KOT, but statistical analysis showed no difference in intensity between KOT, DC and RC ($p=0.9344$). The staining in KOT was mostly observed in suprabasal cells, and in DC and RC in basal to superficial epithelial cells of the nuclei of epithelial cells (Figure 2). The results of immunohistochemical expression of FHIT and p53 proteins are shown in Table 1.

The aberrant expression of FHIT and p53 proteins was compared to the number of epithelial cell layers. All 92 samples in the case of FHIT and 64 in the case of p53 were divided in two groups with the cyst specimens with ≤ 5 layers and >5 layers. The samples showing weakly positive (+) and strong positive (++) reaction were pooled. Using chi-square test ($p<0.05$) it was determined that the specimens with more than 5 epithelial cell layers gave aberrant (negative) reaction to FHIT in significantly more cases ($\chi^2=4.19$). In the case of p53 protein, specimens with >5 epithelial cell layers gave positive (+ and ++) reaction in significantly more cases ($\chi^2=8.43$).

Loss of heterozygosity analysis (LOH)

Thirty one paraffin embedded samples were chosen for LOH analysis of FHIT and p53 loci according to their aberrant immunohistochemical reaction for either FHIT, p53 or both (11 KOT, 10 DC and 10 RC). 75% of the samples were informative for both markers of FHIT locus and 49 % of were informative for p53 locus. Mutation of FHIT other than LOH, was not observed in neither of the specimens, while the mutation at codon 237 of p53 was observed in 2 samples (1 KOT and 1 DC). Normal tissues did not show loss of heterozygosity at the gene loci examined. Loss of heterozygosity of FHIT gene was detected in 22.6% of the samples examined (45% in KOT, 10% in RC, and 10% in DC). Loss of heterozygosity of p53 gene was detected in 12.9% of the samples (27.3% in KOT, 10% in DC and 0% in RC). Protein expression of the two genes was correlated with the results of DNA analysis, and it was

noticed that the p53 gene mutation was found in 2 of 11 examined cases of KOT which exhibited normal p53 protein expression. p53 mutation was not found in RC although it would be expected differently based on immunohistochemical analysis which showed strong positive immunohistochemical reaction to p53 in 26% of RC. The results of LOH and other mutation analysis of FHIT and p53 genes in paraffin embedded samples are shown in Table 2.

FHIT and p53 gene analysis in frozen samples

The frozen samples were analyzed for FHIT and p53 LOH and other mutations. The results of DNA analysis at FHIT and p53 loci in frozen odontogenic cyst samples are shown in Table 3 and Figure 3 and 4. Since there were only six frozen specimens no consistent conclusions can be drawn from the obtained data.

DISCUSSION

Odontogenic tumors and allied lesions have been extensively studied in the past decade and new findings lead to new and improved classification of the lesions.^{28,38} Recent findings concerning the events taking place at the molecular level, together with the clinical behavior of the lesions, gave the better insight into the nature of the lesions. The most recent WHO classification of head and neck tumors referred to the former OKC as keratocystic odontogenic tumor (KOT), a benign odontogenic tumour arising from odontogenic epithelium with mature fibrous stroma without odontogenic ectomesenchyme.²⁸

Radicular cysts are epithelial lesions which arise from the epithelial residues (rest of Malassez) in the periodontal ligament as a consequence of inflammation which follows the death of a dental pulp. The dentigerous cyst is the second most-frequent cystic lesion of the jaws which usually encloses the crown of an unerupted tooth.²⁸

A new classification gives enlarged terminology and diagnostic framework, but there are still many uncertainties concerning molecular and cellular mechanisms underlying the development and behavior of tumors arising from epithelium of the odontogenic apparatus and allied lesions, which gives the inspiration for further research into the lesions.^{23,26,39,40}

Altered expression of oncoproteins and tumor-suppressor proteins in odontogenic cysts, and the mutations of genes regulating the cell cycle have been reported for different odontogenic cysts.^{23,25-27,29} Furthermore, functional genomic analyses of malignancies related to jaws, support the hypotheses that they can arise from odontogenic cysts, apart from arising de novo or secondary to a tumor.⁴¹⁻⁴³ Furthermore, there are reports on transformation of former OKC into squamous cell carcinoma and DC into ameloblastoma.^{44,45}

In our study we demonstrated variable expression of FHIT tumor suppressor protein in paraffin embedded samples of odontogenic lesions. Negative immunohistochemical reaction was the highest in KOT (74%) than in RC (49%) and DC (31%). Pavelic³⁴ reported that FHIT gene is disrupted in head and neck squamous cell carcinomas (HNSCC) and lung cancer, and suggested a strong correlation between the loss of FHIT protein function and increased tumor cell proliferation and low rate of apoptosis. Former OKCs recur at greater frequency and their epithelial lining has greater proliferative potential than that of other types of odontogenic cysts.^{26,27,29} Our results, showing the highest negative reaction to FHIT in KOT, suggest that the disruption of FHIT may induce cell proliferation.

Loss of heterozygosity of FHIT gene was detected in 45% of informative cases of KOT, 10% of DC, and 10% of RC. In frozen specimens, FHIT gene LOH was observed in three, out of six, specimens (2 RC, 1 KOT). Loss of exons 6-7 of the FHIT gene was found in KOT specimen. Loss of FHIT protein function and higher incidence of FHIT mutation in benign neoplasm KOT, may be important in its development and/or progression.

Given that defective FHIT genes were found in DC and RC, the inactivation of FHIT gene is likely to be an early event in the pathogenesis of odontogenic cysts. Our data suggest strong difference in the FHIT aberration between KOT and DC and RC. Less aggressive DC and RC have much less incidence of FHIT loss in comparison to KOT. It was reported that the FHIT gene could be aberrant in non-neoplastic or premalignant tissues, although the changes increased with progression of lesions from normal tissue and dysplasia to carcinoma in situ and cancer.^{9, 10, 17, 33} Tanimoto¹⁰ examined abnormalities of FHIT genes in HNSCC and preamalignant lesions: leukoplakias and erythroplakias, and found abnormal FHIT transcripts in HNSCC samples and in two of seven premalignant lesions. One patient with premalignant lesion with abnormal FHIT transcript developed oral SCC during a 3-year follow up period. Tokuchi¹⁷ found significant difference in the frequency of abnormal FHIT transcripts between lung cancer and paired normal lung, while the difference in the frequency of abnormal transcripts was not significant between lung cancer and normal control lung. Therefore, the authors suggested that the presence of abnormal FHIT transcripts is not cancer specific in the case of lung cancer, and the abnormality may be due to abnormal splicing and processing of the transcripts since the gene is located in a region prone to stress-induced damage.¹⁷

Furthermore, some studies reported that some mutagenic compounds such as benzo(α)pyrene diol-epoxide, which is a major constituent of tobacco smoke, induce molecular alterations of FHIT and p53 gene in human lung cancer.³⁴ Both p53 and FHIT tumor suppressor gene mutations have been frequently found in other types of carcinomas.^{2, 11, 15, 35, 46} According to the available literature FHIT gene has not been studied in odontogenic cysts and KOT. The frequency of positive immunohistochemical reaction for p53 protein in paraffin embedded specimens of KOT, DC and RC was 29%, 15% and 26%, respectively, and there was no difference between the three groups ($p=0.9344$). The intensity of p53 immunostaining

was weak, and in KOT it was mostly observed in suprabasal cells, and in DC and RC in basal to superficial epithelial cells which is in concordance with previous reports.^{23,27,29} Loss of heterozygosity of p53 gene was detected in 27.3% of informative cases of KOT and 10% of DC, while it was not observed in RC. The mutation of p53 gene at codon 237 was observed in 2 paraffin embedded specimens (1 KOT and 1 DC). In snap frozen specimens, p53 mutation at codon 237 was found in KOT.

Our results as well as those of other authors show that p53 mutations are more frequently present in KOT i.e. former OKC, compared with other types of cysts.^{21, 23,27,29} However, we did not find any mutation in RC. These results support the assumption that the inactivation of p53 may confer odontogenic lesions with local growth and aggressive properties attributed to KOT. Agaram²⁴ also reported that a significant number of former OKC show clonal LOH of p53, along with LOH of some other common tumor-suppressor genes. Furthermore, the inactivation of p53 could even be one event in the multi-step genetic process leading to the malignant transformation of KOT and DC reported in the literature.^{41,44,45}

Immunohistochemical analysis showed that the samples with more than 5 epithelial cell layers gave positive reaction to p53 in significantly more cases ($p < 0.05$) which confers the lesions with increased cell division and local growth. This is in concordance with Regezi⁴⁷ report where the mitotic index in OKC was similar to that in ameloblastoma.

In conclusion, our results support the hypothesis that FHIT gene alteration is involved in development of KOT and odontogenic cysts, and that aberrant FHIT and p53 genes could be markers of local invasiveness or even neoplastic nature. Aberrant FHIT gene may be early event in odontogenic cyst development.

ACKNOWLEDGEMENTS

This work is a part of the projects No. 0065999, 0098093 and 065-0650445-0434 supported by the Ministry of Science, Education and Sports of the Republic of Croatia.

REFERENCES

1. Ohta M, Inoue H, Cotticelli MG, et al. The FHIT gene, spanning the chromosome 3p14.2 fragile site and renal carcinoma-associated t(3;8) breakpoint, is abnormal in digestive tract cancers. *Cell* 1996 ;84: 587-97.
2. Sozzi G, Veronese ML, Negrini M, et al. The FHIT gene at 3p14.2 is abnormal in lung cancer. *Cell* 1996; 85 :17-26.
3. Naylor SL, Johnson BE, Minna JD, Sakaguchi AY. Loss of heterozygosity of chromosome 3p markers in small-cell lung cancer. *Nature* 1987; 329: 451-4.
4. Hibi K, Takahashi T, Yamakawa K, et al. Three distinct regions involved in 3p deletions in human lung cancer. *Oncogene* 1992; 7: 445-9.
5. Glover TW, Coyle-Morris JF, Li FP, et al. Translocation t(3;8)(p14.2;q24.1) in renal cell carcinoma affects expression of the common fragile site at 3p14 (FRA3B) in lymphocytes. *Cancer Genet Cytogenet* 1988; 31 :69-73.
6. Glover TW, Stein CK. Chromosome breakage and recombination at fragile sites. *Am J Hum Genet* 1988; 43: 265-73.
7. Rassool FV, McKeithan TW, Neilly ME, van Melle E, Espinosa R 3rd, Le Beau MM. Preferential integration of marker DNA into the chromosomal fragile site at 3p14.2: an approach to cloning fragile sites. *Proc Natl Acad Sci USA* 1991; 88: 6657-61.
8. Negrini M, Monaco C, Vorechovsky I, et al. The FHIT gene at 3p14.2 is abnormal in breast carcinomas. *Cancer Res* 1996; 56: 3173-79.
9. Druck T, Hadaczek P, Fu TB, et al. Structure and expression of the human FHIT gene in normal and tumor cells. *Cancer Res* 1997; 57: 504-12.
10. Tanimoto K, Hayashi S, Tsuchiya E, et al. Abnormalities of the FHIT gene in human oral carcinogenesis. *Br J Cancer* 2000; 82: 838-43.

11. Lee JI, Soria JC, Hassan K, et al. Loss of Fhit expression is a predictor of poor outcome in tongue cancer. *Cancer Res* 2001; 61: 837-41.
12. Rosin MP, Lam WL, Poh C, et al. 3p14 and 9p21 loss is a simple tool for predicting second oral malignancy at previously treated oral cancer sites. *Cancer Res* 2002; 62: 6447-50.
13. Sozzi G, Pastorino U, Moiraghi L, et al. Loss of FHIT function in lung cancer and preinvasive bronchial lesions. *Cancer Res* 1998; 58: 5032-37.
14. Campiglio M, Pekarsky Y, Manard S, Tagliabue E, Pilotti S, Croce CM. FHIT loss of function in human primary breast cancer correlates with advanced stage of the disease. *Cancer Res* 1999; 59: 3866-69.
15. Connolly DC, Greenspan DL, Wu R, et al. Loss of fhit expression in invasive cervical carcinomas and intraepithelial lesions associated with invasive disease. *Clin Cancer Res* 2000; 6: 3505-10.
16. Matthews CP, Shera K, Kiviat N, McDougall JK. Expression of truncated FHIT transcripts in cervical cancers and in normal human cells. *Oncogene* 2001; 20: 4665-75.
17. Tokuchi Y, Kobayashi Y, Hayashi S, et al. Abnormal FHIT transcripts found in both lung cancer and normal lung tissue. *Genes Chromosomes Cancer* 1999; 24: 105-11.
18. Isobe M, Emanuel BS, Givol D, Oren M, Croce CM. Localization of gene for human p53 tumor antigen to band 17q13. *Nature* 1986; 320: 84-5.
19. Hollstein M, Rice K, Greenblatt MS, et al. Database of p53 gene somatic mutations in human tumors and cell lines. *Nucleic Acids Res* 1994; 22: 3551-55.
20. Pavelić K. Molecular-genetic base of cancer. In: Samija M editor. *Oncology*. Zagreb: Medicinska naklada, 2000. p.19-25.

21. Ogden GR, Chisholm DM, Kiddie RA, Lane DP. P53 protein in odontogenic cysts: increased expression in some odontogenic keratocysts. *J Clin Pathol* 1992; 45: 1007-10.
22. Warnakulasuriya KA, Johnson NW. Association of overexpression of p53 oncoprotein with the state of cell proliferation in oral carcinoma. *J Oral Pathol Med* 1994; 23: 246-50.
23. Kichi E, Enokiya Y, Muramatsu T, et al. Cell proliferation, apoptosis and apoptosis-related factors in odontogenic keratocysts and in dentigerous cysts. *J Oral Pathol Med* 2005; 43: 280-6.
24. Agaram NP, Collins BM, Barnes L, et al. Molecular analysis to demonstrate that Odontogenic keratocysts are neoplastic. *Arch Pathol Lab Med* 2004; 128: 313-17.
25. Ohki K, Kumamoto H, Ichinohasama R, Sato T, Takahashi N, Ooya K. PTC gene mutations and expression of SHH, PTC, SMO, and GLI-1 in odontogenic keratocysts. *Int J Oral Maxillofac Surg* 2004; 33: 584-92.
26. Stoll C, Stollenwerk C, Riediger D, Mittermayer C, Alfer J. Cytokeratin expression patterns for distinction of odontogenic keratocysts from dentigerous and radicular cysts. *J Oral Pathol Med* 2005; 34: 558-64.
27. Piattelli A, Fioroni M, Santinelli A, Rubini C. p53 Protein Expression in Odontogenic Cysts. *J Endod* 2001; 27: 459-61.
28. Barnes L, Everson JW, Reichart P, Sidransky D (Eds.): World Health Organization Classification of Tumors. Pathology and Genetics of Head and Neck Tumors. IARC Press: Lyon 2005.
29. Li TJ, Browne RM, Prime SS, Paterson IC, Matthews JB. p53 expression in odontogenic keratocyst epithelium. *J Oral Pathol Med* 1996; 25: 249-55.

30. Levanat S, Kappler R, Hemmerlein B, et al. Analysis of the PTCH1 signaling pathway in ovarian dermoids. *Int J Mol Med* 2004; 14: 793-99.
31. Tosios KI, Kakarantza-Angelopoulou E, Kapranos N. Immunohistochemical study of bcl-2 protein, Ki-67 antigen and p53 protein in epithelium of glandular odontogenic cysts and dentigerous cysts. *J Oral Pathol Med* 1999; 29:139-44.
32. Gall K, Pavelic J, Jadro-Santel D, Poljak M, Pavelic K. DNA amplification by polimerase chain reaction from brain tissues embedded in paraffin. *Int J Exp Path* 1993; 74: 333-7.
33. Ciulla TA, Sklar RM, Hauser SL. A simple method of DNA purification from peripheral blood. *Anal Biochem* 1988;174: 485-8.
34. Pavelic K, Krizanac S, Cacev T, et al. Aberration of FHIT gene is associated with increased tumor proliferation and decreased apoptosis-clinical evidence in lung and head and neck carcinomas. *Mol Med* 2001; 7: 442-53.
35. Virgilio L, Shuster M, Gollin SM, et al. FHIT gene alteration in head and neck squamous cell carcinomas, *Proc Natl Acad Sci USA* 1996; 93: 9770-75.
36. Berggren P, Steineck G, Adolfsson J, et al. P53 mutations in urinary bladder cancer, *Br J Cancer* 2001; 84: 1505-11.
37. SAS Institute INC. SAS Procedures Guide, Release 6.03 Edition. Cary, NC: SAS Institute Inc., 1988. p. 222.
38. Philipsen HP, Reichart PA. Classification of odontogenic tumours. A historical review. *J Oral Pathol Med* 2006; 35: 525-9.
39. Kumamoto H, Ooya K. Immunohistochemical detection of insulin-like growth factors, platelet-derived growth factor, and their receptors in ameloblastic tumors. *J Oral Pathol Med* 2007; 36: 198-206.

40. Gomez RS, De Marco L. Possible molecular approach to the treatment of odontogenic keratocyst. *Oral Surg Oral Med Oral Pathol Oral Radiol Endod* 2005; 99: 527-28.
41. Cavalcanti MG, Veltrini VC, Ruprecht A, Vincent SD, Robinson RA. Squamous-cell carcinoma arising from an odontogenic cyst-the importance of computed tomography in the diagnosis of malignancy. *Oral Surg Oral Med Oral Pathol Oral Radiol Endod* 2005; 100: 365-8.
42. Carinci F, Palmieri A, Delaiti G, et al. Expression profiling of ameloblastic carcinoma. *J Craniofac Surg* 2004; 15: 264-69.
43. Chaisuparat R, Coletti D, Kolokythas A, Ord RA, Nikitakis NG. Primary intraosseous odontogenic carcinoma arising in an odontogenic cyst or de novo: a clinicopathologic study of six new cases. *Oral Surg Oral Med Oral Pathol Oral Radiol Endod* 2006; 101: 194-200.
44. Makowski GJ, McGuff S, Van Sickels JE. Squamous cell carcinoma in a maxillary odontogenic keratocyst. *J Oral Maxillofac Surg* 2001; 59: 76-80.
45. Greer RO Jr. The oral cavity. In: Silverberg SG editor. *Principles and practice of surgical pathology* Vol 1, 2nd ed. New York: Churchill Livingstone, 1990. p. 835-894.
46. Powell Jr DJ, Russell JP, Li G, Kuo BA, Fidanza V, Huebner K et al. Altered gene expression in immunogenic poorly differentiated thyroid carcinomas from RET/PTC3^{p53-/-} mice. *Oncogene* 2001; 20 :3235-46.
47. Regezi JA. Odontogenic cysts, odontogenic tumors, fibrous, and giant cell lesions of the jaws. *Mod Pathol*, 2002; 15: 331-41.

Table 1

Cyst type	FHIT N=92			Cyst type	p53 N=64		
	-	+	++		-	+	++
KOT (38cases)	28 (74%)	9 (24%)	1 (2%)	KOT (32 cases)	16 (50%)	7 (22%)	9 (29%)
DC (13cases)	4 (31%)	2 (15%)	7 (54%)	DC (13 cases)	8 (62%)	3 (23%)	2 (15%)
RC (41cases)	20 (49%)	12 (29%)	9 (22%)	RC (19cases)	9 (48%)	5 (26%)	5 (26%)

- negative reaction (0% of the cells showing reactivity); + positive reaction (<25% of the cells showing reactivity); ++ positive reaction (>25% of the cells showing reactivity); KOT- keratocystic odontogenic tumor; DC- dentigerous cyst; RC- radicular cyst

Table 2

N=31	FHIT LOH	p53 LOH	OTHER MUTATIONS
KOT (11cases)	(5 cases) 45%	(3 cases) 27.3%	(1 case) p53 at codon 237
DC (10 cases)	(1 case) 10%	(1 case)10%	(1 case) p53 at codon 237
RC (10 cases)	(1 case) 10%	(0 cases) 0%	-

LOH- loss of heterozygosity; KOT- odontogenic keratocyst; DC- dentigerous cyst; RC- radicular cyst;

Table 3

N=6	FHIT LOH	P53 LOH	OTHER MUTATIONS
KOT (1 case)	YES	-	P53 at codon 237 FHIT: loss of exons 6-7
DC (1 case)	-	-	-
RC (4 cases)	2 cases	-	-

LOH- loss of heterozigosity; YES- LOH found in odontogenic cyst sample; KOT- odontogenic keratocyst; DC- dentigerous cyst; RC- radicular cyst;

Figure 1

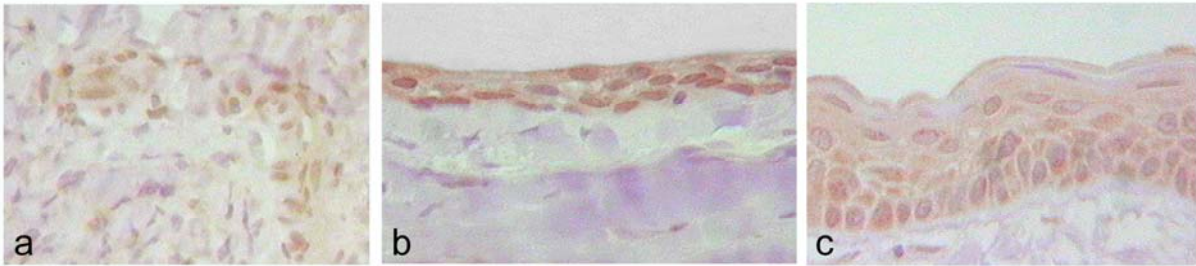


Figure 2

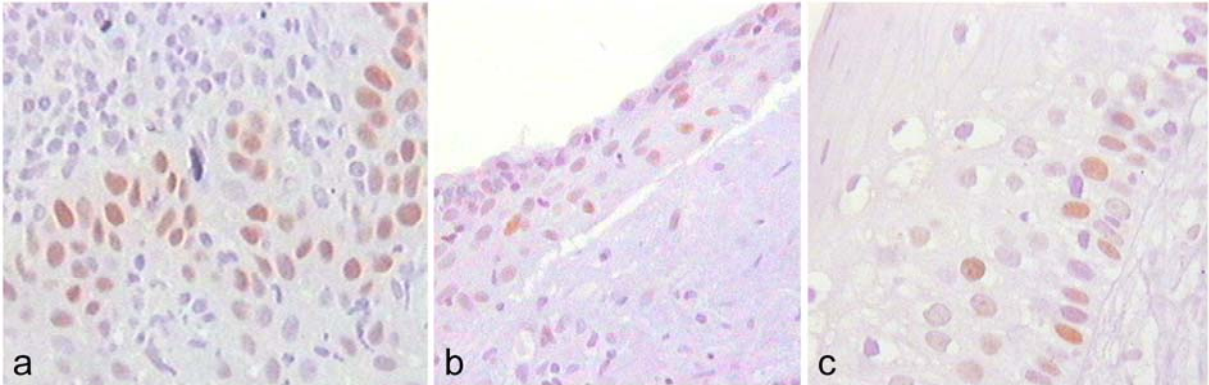


Figure 3

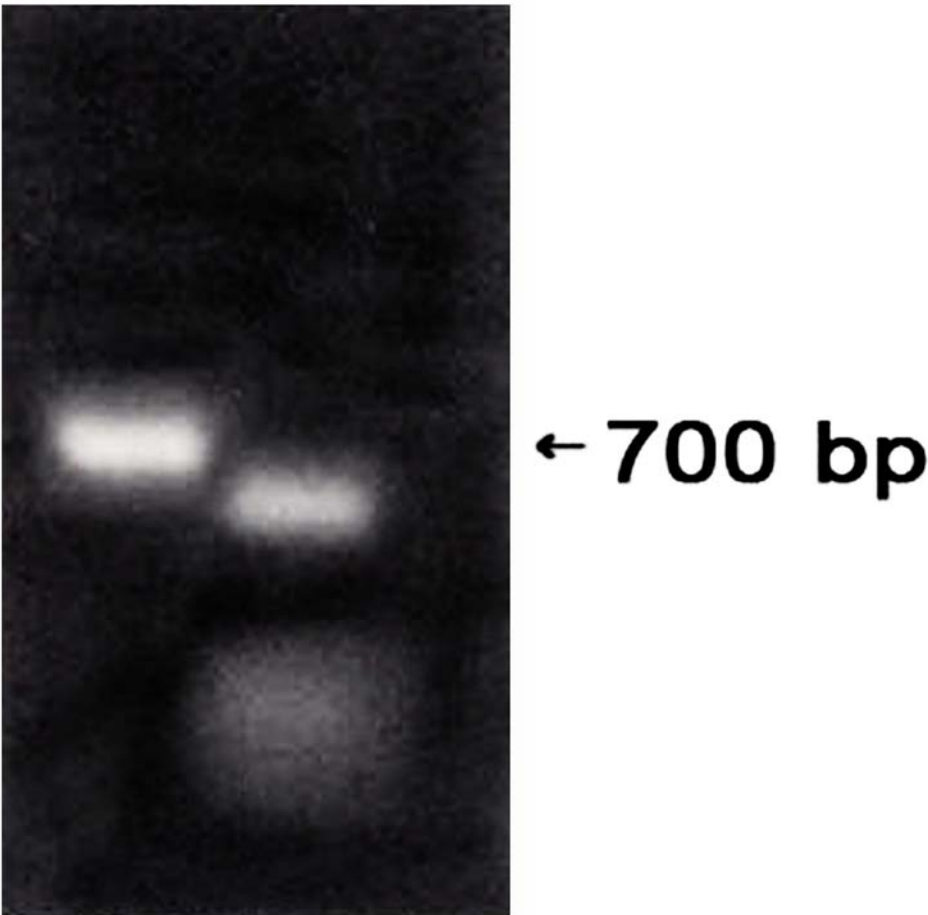


Figure 4

