

Vertebroplasty--high viscosity cement versus low viscosity cement

Rapan, Saša; Jovanović, Savo; Gulan, Gordan; Boschi, Vladimir;
Kolarević, Vjekoslav; Đapić, Tomislav

Source / Izvornik: **Collegium Antropologicum, 2010, 34, 1063 - 1067**

Journal article, Published version

Rad u časopisu, Objavljena verzija rada (izdavačev PDF)

Permanent link / Trajna poveznica: <https://um.nsk.hr/um:nbn:hr:105:496464>

Rights / Prava: [In copyright](#)/[Zaštićeno autorskim pravom.](#)

Download date / Datum preuzimanja: **2025-01-05**



Repository / Repozitorij:

[Dr Med - University of Zagreb School of Medicine
Digital Repository](#)



Vertebroplasty – High Viscosity Cement *versus* Low Viscosity Cement

S. Rapan¹, S. Jovanović¹, G. Gulan², V. Boschi³, V. Kolarević¹, T. Đapić⁴

¹ Department of Orthopaedic Surgery, Osijek University Hospital Center, Osijek, Croatia

² Department for Orthopaedic Surgery »Lovran«, Rijeka University Hospital Center, Rijeka, Croatia

³ Department of Traumatology, Split University Hospital Center, Split, Croatia

⁴ Department for Orthopaedic Surgery »Šalata«, Zagreb University Hospital Center, Zagreb, Croatia

ABSTRACT

The patients with intensive pain caused by the vertebra body fracture were treated by application of low viscosity cement (LVC), (Vertebroplastic, DePuy) and high viscosity cement (HVC), (Confidence, DePuy,) into the body, by means of diascopy through unilateral transpedicular approach. Application of LVC was made in 75 patients, on 109 vertebrae, and HVC was applied in 12 patients on 14 vertebrae. Application of LVC was performed on 48 thoracic and 61 lumbar vertebrae and 5 thoracic and 9 lumbar vertebrae were stabilized with HVC. 43 patients were treated for malignancy and in 38 for osteoporosis. For LVC, preoperative VAS score was 8.32 and 2.23 ($p < 0.00001$) 24 hours after surgery, and it remained stable 3 month later. For HVC, preoperative VAS score was 7.99 and it was 2.5 ($p < 0.00001$) 24 hours after surgery and 3 months later. In the group of patients treated with LVC, there was 1 serious complication, a paraparesis caused by the leakage of cement into the spinal canal, which was partially recovered after decompression and rehabilitation treatment and 2 superficial infections with *S. epidermidis* which were cured by means of antibiotics. In 32 vertebrae (32) cement leakage extra ossal, either into vein plexus or intradiscal during surgery were noticed. When HVC was applied, intradiscal leakage occurred in one case only (8%). By means of Wilcoxon paired test a significant difference was found between the preoperative VAS, and the values immediately after surgery and 3 months later ($Z = 7.52$, $p < 0.00001$) when LVC was applied., and with HVC it was ($Z = 3.04$, $p < 0.00001$), which indicates that the fast achieved pain reduction remained stable during the 3 month follow-up. The vertebroplasty is a safe and efficient surgical method in treatment of compressive vertebrae fractures which do not react to the conventional method of treatment. This method, when HVC is applied, shows significantly less complications related to cement leakage.

Key words: vertebroplasty, high viscosity cement, low viscosity cement

Introduction

Compressive vertebral fracture is a frequent complication caused by osteoporosis and expansion on malignant tumors into the skeleton. Frequency of these fractures increases with age, and they include compression, collapse and wedging of the body causing kyphosis.

These fractures lead to the significant rate of morbidity and mortality, nourishment disorders, lungs function troubles, lack of self-reliance, increased pains and psychic disorder caused by pains and drugs.

Traditional method of treating vertebrae fractures include the use of narcotics, analgesics, non steroidal anti-inflammatory drugs (NSAID), resting, and the use of or-

thosis, and in the case of malignancies – hormonal, radiotherapy and chemotherapy. In most patients, the pain is reduced within 2–3 months, while the pain persists in smaller number of cases, so that they make a group where surgery is indicated as well.

Vertebroplasty is a stabilization surgery achieving its effect by applying the cement through a needle into the broken vertebral body by means of diascopy in situ, without correction of kyphosis, and with the aim to relieve the pain..

A number of papers and studies describe vertebroplasty as a safe and efficient method in treatments of patho-

logical fractured vertebrae^{1–10}. This method is accompanied with some complications, both local and general ones. Frequency of complications is much higher in treatment of malignancy than in osteoporosis.

The most frequent complication includes the cement leakage extra-ossal from the vertebra body to the surrounding tissue caused by too high quantity of cement applied, inadequate selection of patients, poor surgery technique or inadequate cement viscosity^{11–14}.

The difference between the high viscosity cement (HVC) and low viscosity cement (LVC) in treatment the pain, and complications occurring during and after the surgery are discussed in the paper.

Patients and Methods

In the period from 2005 to August 2009, 87 patients were treated in 87 surgeries with a method of vertebroplasty in the Orthopedic Department of the Osijek University Hospital Center.

The research covered patients with pains in the back caused by osteoporotic vertebral fractures, who did not react positively to the conservative method of treatment, or caused by a malignant process with or without previously performed hormonal, radio or chemotherapy. Surgery was not performed if the LL X-ray showed that the fractured vertebral body collapsed over 90% (vertebra plana).

For the purpose of the method efficiency evaluation, all patients filled in the VAS questionnaire with a scale from 1 to 10 before surgery, 24 hours and 3 months after surgery.

Surgery

All surgeries were performed by one surgeon under local or general anesthesia, if they could not tolerate the local one. Surgery is carried out in a prone position, the fractured vertebra is located by means of diascopy, the operation area is washed and covered, and the ski and subcutaneous tissue is anesthetized with lidocaine when applying local anesthesia

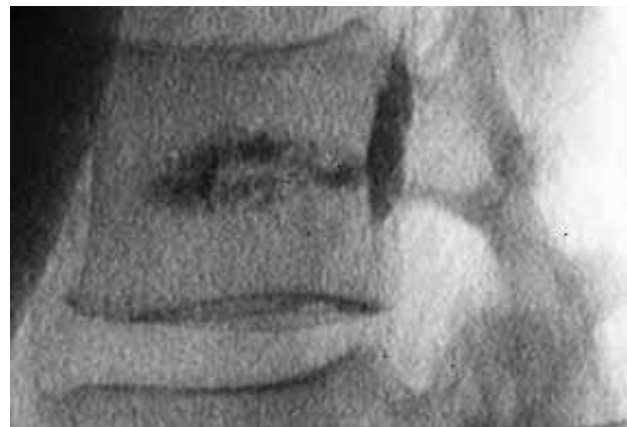

Fig 2. The cement leakage into basivertebral veins marked by arrow.

Through a small skin incision, an 11-gauge needle for bone biopsy is placed in the centre of pedicle in AP and then, it is followed-up on diascope and inserted, in LL direction to the first third of the vertebral body. Once we are satisfied with the needle position, cement of relevant viscosity is applied in the vertebral body. Diascopy is very important during the whole process of the cement application in order to notice its leakage and stop applying the cement on time to prevent more serious complications. LVC (Vertebroplastic, Depuy Acromed), and HVC (Confidence, Depuy Spine) were used.

The cement application is completed when are satisfied with the cement position in the last quarter of the body in LL direction (Figure 1) or if epidural, venous or intradiscal extravasation of cement occurred (Figure 2). Depending on the ambient temperature of the operating room, the time from the beginning of mixing to the beginning of application was 4 to 8 minutes for LVC, while HVC could be applied immediately after the 30 second mixing.

Active time was some 10 minutes for HVC, and for LVC it took 2 to 3 minutes until its complete hardening.

When applying LVC the needles were not removed before the end of polymerization to prevent spreading of cement on the paraspinal musculature if the needle is removed earlier, and when HVC was used, the needles were

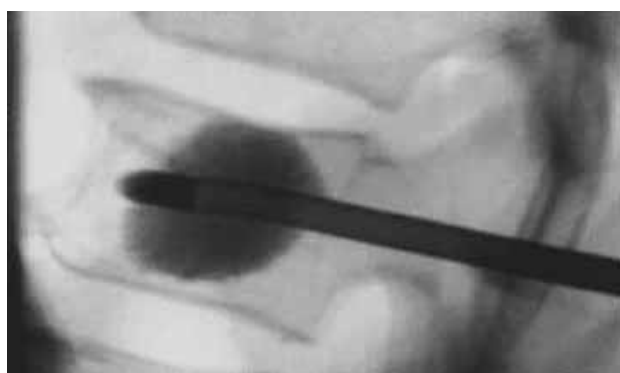

Fig 1. X-ray of lumbar vertebral in lateral projection taken after application of cement showing good position.

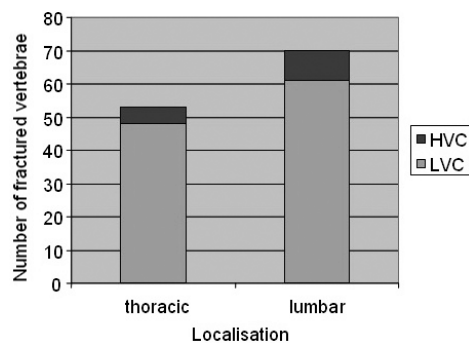


Fig 3. Distribution of patients according to the fracture location.

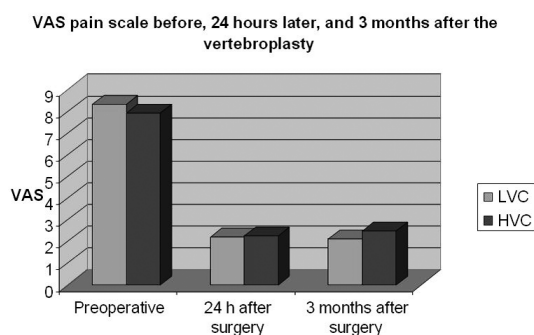


Fig 4. Pain scale before and after vertebroplasty.

removed immediately after cement application was completed, because due to its high viscosity there was no possibility for the cement leakage from the needle into surrounding area, and therefore surgery with HVC was much shorter. The patient remains in bed for minimum one hour, and 24 hours after surgery the patient is discharged from the hospital, after having filled-in the Visual analog scale (VAS) questionnaire.

Results

87 patients (62 women, 25 men, aged from 29 to 82) have been tested 24 hours and 3 months after surgery. 87 surgeries were carried on 123 vertebrae. In the period from April 2005 to December 2008 109 vertebrae in 75 patients were treated with LVC (Vertebroplastic, DePuy, Acromed), and 14 vertebrae in 12 patients were treated by applying HVC (Confidence, DePuy Spine) in the period December 2008 to August 2009. The LVC volume applied amounted to 3 mL on average (1.5–5 mL), and 3.3 mL (2–4), respectively. Local anesthesia was applied in 23 and general anesthesia in 64 surgeries. The surgery using LVC was performed on 48 thoracic and 61 lumbar vertebrae. (Figure 3). LVC was used on 43 patients for malignancy and in 32 for osteoporosis.

Vertebroplasty using HVC was used on 12 patient, on 14 vertebrae for malignancy and in 4 for osteoporosis. The surgery was performed on 5 thoracic and 9 lumbar vertebrae. (Figure 3).

The average surgery time was 52 (30–80) minutes on average for LVC, and 41.5 (25–50) minutes for HVC, and average stay in hospital was about 2 (1–4) days. The average pain suffering prior to surgery was 26 (2–124) days.

Pain reduction was significant, *per* VAS score from 8.32 ± 0.84 before surgery to 2.23 ± 0.79 (–72.63%) 24 hours later, 2.13 ± 0.74 three months after surgery for LVC, and VAS before surgery was 7.99 ± 0.79 , 2.25 ± 0.62 and 2.5 ± 0.52 three months after surgery for HVC.

For patients in whom LVC was applied, the Wilcoxon paired test demonstrated a significant difference between preoperative VAS score and the value measured 24 hours after surgery ($n=75$, $Z=7.52$, $p<0.00001$), and 3 months after surgery ($Z=7.52$, $p<0.00001$), while there is a compliance between two VAS measurements after

surgery ($Z=0.94$, $p=0.17$), which indicates that the fast achieved pain reduction remained stable during the 3 month follow-up (Figure 4).

For patients in whom HVC was applied, the Wilcoxon paired test demonstrated a significant difference between preoperative VAS score and the value measured 24 hours after surgery ($n=12$, $Z=3.04$, $p<0.00001$), and 3 months after surgery ($Z=3.04$, $p<0.00001$), while there is a compliance between two VAS measurements after surgery which indicates that the fast achieved pain reduction remained stable during the 3 month follow-up.

There was 1 serious complication when LVC was applied, i.e. the cement leakage into the spinal canal followed by paraparesis. After urgent decompression, paravertebral corticosteroids and rehabilitation treatment, the female patient was partially recovered. In 2 (1.8%) patients superficial infections with *S.epidermidis* occurred, which were cured by peroral administration of antibiotics and lesion toilet.

By diascopy during the surgery in 32 vertebrae (32%) cement leakage from the fractured vertebral body was evidenced which did not cause any aggravation of patients' clinical status. At vertebroplasty with HVC asymptomatic cement leakage during surgery through end plate into the intravertebral discus.

Discussion

In pathologically changed bone a vertebral fracture may result in constant pains despite analgesic and anti-rheumatic treatment, resting or immobilization. As osteoporotic fractures are connected with older age, and metastatic with poor general condition, beside the pain, the conditions is worsened due to reduced mobility, urinary disorders, depression or neurological disorders. Similarly, because of bad quality of bones, conventional surgery methods of stabilization, ostrosynthesis and lumbar fusion had no success. Vertebroplasty is a surgical method for achieving stabilization of fracture in a pathologically changed vertebral body, when due to osteoporosis, tumor or malignancy, the conventional methods of treatment fail.

By this method, stabilization is achieved about 10 minutes after application of cement into the vertebral body, and analgesic effect is either a result of preventing micro-movements or of destruction of nerve ends by thermal reaction during the polymerization of cement¹⁵.

Somewhat shorter duration of the surgery with HVC in our research can be attributed to earlier beginning of application of HVC cement from the beginning of mixing, a three and half years' experience with surgeries using LVC, and also to the fact that, when working with LVC, we had waited polymerization of cement to end to prevent, at removal of a needle, leakage of cement in the surrounding musculature. Because of too fast transition from fully soft to too hard condition, work with HVC provided significantly higher relaxedness and confidence.

The success of this method of treatment in pain reduction by 75–90% is described by many authors^{1–10}, and our result of pain reduction by 72.63% with LVC and 68.72% with HVC is in the line with this statement. There is no statistically significant difference in success of treatment in pain reduction between LVC and HVC. There is no direct dependence between the quantity of cement applied and the level of reduction in pain^{16,17}.

This method also causes numerous complications, general and local ones. Frequency of complications is much higher in treatment of malignancy (up to 10%) than in osteoporosis (1 to 3%)⁶.

Force enabling the cement flow through trabecular bone is of crucial importance for uniform distribution of cement among trabeculae. Extra-ossal leakage is the most frequent complication of vertebroplasty, and it occurs on the trabecular bone with the lowest resistance. The risk of cement leakage into the spinal canal correlates with bone destruction, so that the surgery is contra-indicated in more serious destructions of vertebral body¹⁸.

There is a direct dependence between cement leakage into the spinal canal and the quantity of cement applied during the surgery on the fractured vertebral body^{19,20}, as there is a direct dependence between of mixing time and application of cement, wherein after 10 minutes from the beginning of mixing there is almost no leakage during application¹⁸. In his investigation Boger²¹ noticed a direct dependence between the ambient temperature (operation room) and the patient's body temperature and the cement viscosity.

Use of a side-opening cannula instead of a central-opening one, the risk of cement leakage into the canal is reduced from 68% to 22%²².

Cement leakage into the inter-vertebral disc increases the risk of new fracture of adjacent vertebral body²³.

Ali Ali¹¹ did not notice dependence either between the fracture of adjacent vertebral body with the amount of cement applied or its leakage.

In spite of high percentage of cement leakage (0.5–65.6%)^{11,24–27}, only about 7.5% of the cases were

symptomatic¹⁶ and they respond to conservative treatment with antirheumatics and the use of corticosteroids. Neurological disturbance asking for decompression of spinal canal and cement removal make only 1% of complications^{28–32}. Cotten³³ and Barragan-Campus³⁴, state that cement is frequently leaking into the spinal canal (52%), into the neuroforamen (27.6%), and into the intervertebral disc about 27.6%.

In our case, there was cement leakage in 32 (32%) of total of 109 vertebrae treated when LVC was used, and in one case (0.92%) cement leakage into the spinal canal resulted in paraparesis, and then in decompression of spinal canal.

When HVC was used, there was cement leakage only in one case (7.1%), which corresponds with Anselmetti's results²⁴, wherein cement leakage into the veins plexus occurred in 8.2% and into the disc occurred in 6.1%.

Confirmation of cement leakage in our study is based on diascopy during surgery and X-ray taken after surgery. We did not take by routine CT or MRI, because all the patients, with no occurrence of cement leakage, had no subjective disturbances, but it can be assumed that the percentage of cement leakage into adjacent tissue would be higher if these diagnostic methods were used by routine.

In our research, although two groups of patients were not equal in size, the success of vertebroplasty in treatment of pain was equal, but the group treated with HVC showed significantly less complications related to cement leakage.

Higher cement viscosity, exact spinal tap needle position and diascopy during the whole procedure and especially during the application of cement are crucial and significantly reduce the possibility of having the serious complication.

Conclusion

Vertebroplasty with HVC is a method that includes all advantages of this method but it also minimizes the risk of cement leakage extra ossal which makes it significantly safer for the surgeon and for the patient as well.

REFERENCES

1. ANSELMETTI GC, CORGNIER A, DEBERNADI F, REGGE D, Radiol Med, 110 (2005) 262. — 2. CHEUNG G, CHOW E, HOLDEN L, VIDMAR M, DANJOUX C, YEE AJ, CONNOLY R, FINKLSTEIN J, Can Assoc Radiol J, 57 (2006) 13. — 3. VOORMOLEN MH, LOHLE PN, FRNSEN H, JUTTMANN JR, DE WAAL MALEFLIJT J, LAMPMANN LE, Ned Tijdschr Geneesk, 147 (2003) 1549. — 4. FESSL R, ROEMER FW, BOHNDORF K, Rof, 177 (2005) 884. — 5. HOCHMUTH K, PROSCHEK D, SCHWARZ W, MACK M, KURTH AA, VOGL TJ, Eur Radiol, 16 (2006) 998. — 6. AFZAL S, DHAR S, VASAVADA NB, AKBAR S, Pain Physician, 10 (2007) 559. — 7. GILL JB, KUPER M, CHIN PC, ZHANG Y, SCHUTT R JR, Pain Physician, 10 (2007) 583. — 8. RAPAN S, JOVANOVIC S, GULAN G, Coll Antropol, 33 (2009) 911. — 9. EWANS AJ, JENSEN ME, KIP KE, DE NARDO AJ, LAWLER GJ, NEGIN GA, REMLEY KB, BOUTIN SM, DUNNAGAN SA, Radiology, 226 (2003) 366. — 10. PONGSOIPETCH B, J Med Assoc Thai, 90 (2007) 479. — 11. ALI ALI F, BARROW T, LUKE K, AJNR Am J Neuroradiol, [Epub ahead of

12. KIM YJ, LEE JW, PARK KW, YEOM JS, JEONG HS, PARK JM, KANG HS, Radiology, 251 (2009) 250. — 13. LEE MJ, DUMONSKI M, CAHILL P, STANLEY T, PARK D, SINGH K, Spine, 34 (2009) 1228. — 14. ATHREYA S, MATHIAS N, ROGERS P, EDWARDS R, Cardiovasc Intervent Radiol, 32 (2009) 817. — 15. ANSELMETTI GC, MANCA A, KANIKA K, MURPHY K, EMINEFENDIC H, MASALA S, REGGE D, Cardiovasc Intervent Radiol, 32 (2009) 491. — 16. BARRAGAN-CAMPOS HM, VALLEE JN, LO D, CORMIER E, JEAN B, ROSE M, ASTAGNEAN P, CHIRAS J, Radiology, 238 (2006) 354. — 17. KAUFMANN TJ, TROUT AT, KALLMES DF, AJNR Am J Neuroradiol, 27 (2006) 1933. — 18. BAROUD G, CROOKSHANK M, BOHNER M, Spine, 31 (2006) 2562. — 19. RYU KS, PARK CK, KIM MC, KANG JK, J Neurosurg, 96 (2002) (Suppl) 56. — 20. RYU KS, PARK CK, KIM MC, KANG JK, J Neurosurg, 96 (2002) (Suppl) 56. — 21. BOGER A, WHEELER KD, SCHENK B, HEINI PF, Eur Spine J, 18 (2009) 1272. — 22. FIGUERE-NDO N, BARRA F, MORAES L, RÖTTA R, CASULARI LA, Arq Neuro-

- psiquiatr, 67 (2009) 377. — 23. LIN EP, EKHOLOM S, HIWATASHI A, WESTESSON PL, AJNR Am J Neuroradiol, 25 (2004) 175. — 24. ANSELMETTI GC, ZOARSKI G, MANCA A, MASALA S, EMINEFENDIC H, RUSSO F, REGGE D, Cardiovasc Intervent Radiol, 31(2008) 937. — 25. WANG HL, JIANG ZG, WANG ZG, ZHU J, ZHAO HT, Zhongguo Gu Shang, 22 (2009) 783. — 26. KOH YH, HAN D, CHA JH, SEONG CK, KIM J, CHOI YH, Acta Radiol, 48 (2007) 315. — 27. SHAPIRO S, ABEL T, PURVINES S, J Neurosurg, 98 (2003) (Suppl) 90. — 28. WUU CC, LIN MH, YANG SH, CHEN PQ, SHIH TT, Eur Spine J, 16 (2007) (Suppl) 326. — 29. CHEN YJ, TN TS, CHEN WH, CHEN CC, LEE TS, Spine, 31 (2006) 379. — 30. TSAI TT, CHEN WJ, LAI PL, CHEN LH, NIU CC, FU TS, WONG CB, Spine, 28 (2003) 457. — 31. CHEN JK, LEE HM, SHIH JT, HUNG ST, Spine, 32 (2007) 358. — 32. LE BJ, LEE SR, YOO TY, Spine, 27 (2002) 419. — 33. COTTEN A, DEWATRE F, CORDET B, Radiology 200, (1996) 525. — 34. BARRAGAN-CAMPOS HM, VALLEE JN, LO D, CORMIER E, JEAN B, ROSE M, ASTAGNEAN P, CHIRAS J, Radiology, 238 (2006) 354.

S. Rapan

Department of Orthopaedic surgery, Osijek University Hospital Center, J. Huttlera 4, 31 000 Osijek, Croatia
e-mail: sasa.rapan@gmail.com

VERTEBROPLASTIKA – VISOKOVISKOZNI CEMENT NASPRAM NISKOVISKOZNOG CEMENTA

SAŽETAK

Ispitanici s jakim boli uslijed loma trupa kralješka liječeni su aplikacijom niskoviskoznog (NVC), (Vertebroplastic, DePuy) i visokoviskoznog (VVC), (Confidence, DePuy) cementa u trup uz pomoć dijaskopije, unilateralnim transpedikularnim pristupom. Aplikacija (NVC) je učinjena u 75 pacijenata, na 109 kralježaka, a (VVC) u 12 pacijenata, na 14 kralježaka. Zahvat je uz primjenu NVC učinjen na 48 torakalnih i 61 slabinskog, a uz pomoć VVC stabilizirano je 5 torakalnih i 9 slabinskih kralježaka. 49 pacijenata liječeno je zbog malignog oboljenja, a 38 zbog osteoporoze. Prijeoperacijski VAS iznosio je prosječno 8,32 za NVC, nakon 24 sata 2,23 ($p < 0,00001$) i ostao je nepromjenjen 3 mjeseca iza operacije. Kod liječenja VVC prijeoperacijski VAS iznosio je 7,99, da bi nakon 24 sata i 3 mjeseca nakon iznosio 2,5 ($p < 0,00001$). U skupini liječenih NVC imali smo jedan slučaj istjecanja cementa u spinalni kanal s posljedičnom paraparezom, koja se djelomično oporavila nakon dekompresije i rehabilitacije. U dva slučaja imali smo površinsku infekciju S. Epidermidisom koja je izliječena primjenom antibiotika. U 32 kralješka (32%) evidentirali smo intraoperacijski istjecanje cementa ekstraosalno, u venski splet ili intradiskalno. Kod uporabe VVC u samo jednom slučaju (8%) došlo je istjecanja cementa intradiskalno. Wilcoxonovim testom vezanih parova utvrđena je značajna razlika između prijeoperacijskog VAS-a, te vrijednostima odmah i 3 mjeseca nakon operacije ($Z = 7,52$, $p < 0,00001$) kod rada NVC, a kod rada VVC ($Z = 3,04$, $p < 0,00001$), što upućuje na brzo smanjenje bolova nakon operacije, koje ostaje stabilno i 3 mjeseca nakon. Vertebroplastika je sigurna, djelotvorna operacijska metoda u liječenju kompresivnih lomova trupa kralješka koji ne reagiraju na konzervativan način liječenja. Ova metoda uz primjenu VVC ima znatno manje komplikacija vezanih za istjecanje cementa.