

# Late diagnosis and treatment: blunt traumatic rupture of the aortic root

---

Gašparović, Hrvoje; Šeparović Hanževački, Jadranka; Štern-Padovan, Ranka; Biočina, Bojan

Source / Izvornik: **European Journal of Cardiothoracic Surgery, 2011, 40**

Journal article, Accepted version

Rad u časopisu, Završna verzija rukopisa prihvaćena za objavljivanje (postprint)

<https://doi.org/10.1016/j.ejcts.2010.11.021>

Permanent link / Trajna poveznica: <https://urn.nsk.hr/urn:nbn:hr:105:540096>

Rights / Prava: [In copyright](#)/[Zaštićeno autorskim pravom.](#)

Download date / Datum preuzimanja: **2025-01-17**



Repository / Repozitorij:

[Dr Med - University of Zagreb School of Medicine Digital Repository](#)





## Središnja medicinska knjižnica

**Gašparović H., Šeparović Hanževački J., Štern-Padovan R., Biočina B.  
(2011) *Late diagnosis and treatment: blunt traumatic rupture of the  
aortic root.* European Journal of Cardiothoracic Surgery, [Epub ahead  
of print]. ISSN 1010-7940**

<http://www.elsevier.com/locate/issn/10107940>

<http://www.sciencedirect.com/science/journal/10107940>

<http://dx.doi.org/10.1016/j.ejcts.2010.11.021>

<http://medlib.mef.hr/935>

University of Zagreb Medical School Repository

<http://medlib.mef.hr/>

## Late diagnosis and treatment: Blunt traumatic rupture of the aortic root

Hrvoje Gasparovic, Jadranka Separovic Hanzevacki, Ranka Stern-Padovan, Bojan

Biocina

Departments of Cardiac Surgery, Cardiology and Radiology, School of Medicine,  
University of Zagreb, Croatia

Correspondence:

Hrvoje Gasparovic, M.D., PhD, FETCS

Department of Cardiac Surgery

University Hospital Rebro Zagreb

Kispaticeva 12

10 000 Zagreb

Croatia

Tel: xx385-1-236-7517

Fax: xx385-1-236-7531

E-mail: [HGASPAROVIC@GMAIL.COM](mailto:HGASPAROVIC@GMAIL.COM)

Word count: 50

Key words: blunt trauma, aortic root, aortic insufficiency

A 48-year-old man was referred for, an initially unrecognized, contained aortic root rupture three months after a vehicular accident. Echocardiography showed aortic insufficiency secondary to noncoronary cusp prolapse (Fig. 1). Computed tomography demonstrated an aortic root injury (Fig. 2A), which was confirmed intraoperatively (Fig. 2B). He underwent aortic root replacement.

Figure 1. (A) Transesophageal echocardiogram demonstrated a pseudoaneurysm of the aortic root (arrows). (B) Prolapse of the noncoronary cusp was identified which resulted in massive aortic insufficiency (arrow)

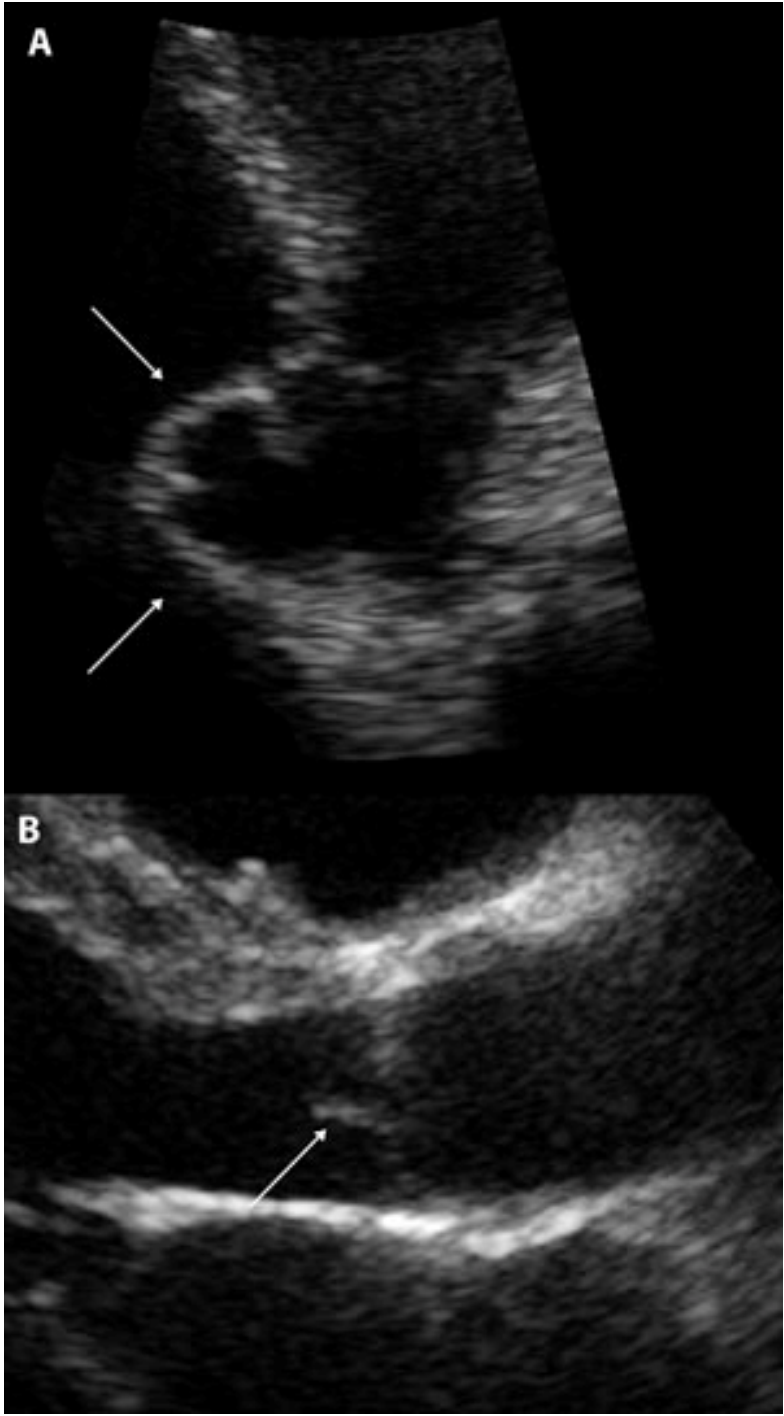


Figure 2. (A) Three-dimensional reconstruction of contrast enhanced chest computed tomography showed a contrast filled cavity communicating with the aortic root (arrows). (B) Intraoperative photograph of the aortic root illustrating a wide orifice of the traumatic pseudoaneurysm (arrows).

