

# Equivalent: Post-Cesarean Peritonitis Caused by Hysterorrhaphy Dehiscence with Puerperal Acute Abdomen Syndrome

---

Pavoković, Dino

Professional thesis / Završni specijalistički

2022

Degree Grantor / Ustanova koja je dodijelila akademski / stručni stupanj: **University of Zagreb, School of Medicine / Sveučilište u Zagrebu, Medicinski fakultet**

Permanent link / Trajna poveznica: <https://um.nsk.hr/um:nbn:hr:105:914646>

Rights / Prava: [In copyright](#)/[Zaštićeno autorskim pravom.](#)

Download date / Datum preuzimanja: **2024-07-13**



Repository / Repozitorij:

[Dr Med - University of Zagreb School of Medicine Digital Repository](#)



**SVEUČILIŠTE U ZAGREBU**

**MEDICINSKI FAKULTET**

**Dino Pavoković**

**Post-Cesarean Peritonitis Caused by  
Hysterorrhaphy Dehiscence with Puerperal  
Acute Abdomen Syndrome**

**ZAVRŠNI SPECIJALISTIČKI RAD**



**Zagreb, lipanj, 2022.**

**SVEUČILIŠTE U ZAGREBU**

**MEDICINSKI FAKULTET**

**Dino Pavoković**

**Post-Cesarean Peritonitis Caused by  
Hysterorrhaphy Dehiscence with Puerperal  
Acute Abdomen Syndrome**

**ZAVRŠNI SPECIJALISTIČKI RAD**

**Zagreb, lipanj, 2022.**

Rad je prijavljen kao ekvivalent završnom specijalističkom radu sukladno Pravilniku o poslijediplomskim specijalističkim studijima Medicinskog fakulteta Sveučilišta u Zagrebu.

**Rad je prihvaćen 09. lipnja 2020. i objavljen 22. srpnja 2020. u časopisu '*Zeitschrift für Geburtshilfe und Neonatologie*'**

---

Izvorni rad ima 3 stranice, 2 slike i 11 literaturnih navoda.

***Posebne zahvale:***

*- supruzi **Moniki** i sinu **Juraju** na podršci, strpljenju i trpljenju mojih višesatnih psihofizičkih izbivanja zbog proučavanja, učenja i ulaganja u istraživanje izabrane struke,*

*- roditeljima **Zdravku** i **Branki** na odricanju, ulaganju, odgoju i pravilnom usmjeravanju braće i mene kako bi postali skromni odnosno bolji ljudi,*

*- mentoru profesoru **Dubravku Habeku** na kontinuiranoj podršci i poticanju mog napretka u kliničkom i znanstvenom znanju u ginekologiji i porodništvu,*

*- komentorici izv. profesorici **Lani Škrgatić** na osobno nezaboravnoj i nesebičnoj pomoći te susretljivosti prilikom završetka mog specijalističkog usavršavanja te prenesenom znanju iz ginekološke endokrinologije...*

## Sadržaj

Abstract.....	5
1. Introduction.....	6
2. Case Report.....	7
3. Discussion.....	9
4. References.....	13
Životopis.....	15
Izvorni rad.....	17

## **Abstract**

We present an overview of the case of a patient with early hysterorrhaphy dehiscence (uteroperitoneal fistula) with endomyometritis and post-cesarean section peritonitis and puerperal acute abdomen in a 35-year-old puerpera. A exploratory relaparotomy, necrectomy, and resuture of the dehiscent part of the hysterotomy were performed with placement of hemostatic sponges on the same portion of the uterus with good recovery.

## **1. Introduction**

We are witnessing an increasing trend of cesarean sections worldwide, resulting in a consequent increase in postoperative complications. Frequent early postoperative complications include infections, dehiscences, hemorrhages, and hysterectomies, and late complications such as uterine scar dehiscence, malplacentaion, endometritis, chronic pelvic pain, pelvic adhesions, and menstrual disorders [1–3]. Early puerperal dehiscence of the uterine scar after cesarean section is very rare, with a frequency between 0.06–3.8 % [4]. We present an overview of the case of a patient with early hysterorrhaphy dehiscence with endomyometritis and post-cesarean section peritonitis. The initial presentation of puerperal acute abdomen made this case clinically striking.



## 2. Case Report

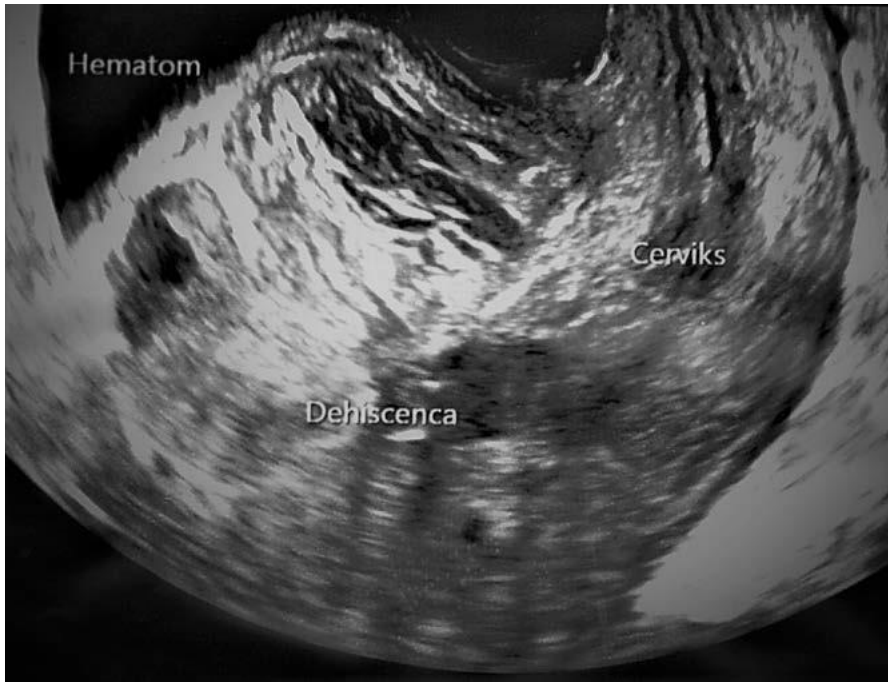
A 35-year-old patient (G2 P2), who had undergone a cesarean section 4 days before, was examined in an emergency gynecological ambulance for subfebrility and poor general condition with exacerbated pain in the pelvis and bladder. The elective iterative cesarean section was done with the Misgav-Ladach technique because of the macrosomic infant and previous cesarean section. Continuous locked hysterorrhaphy stood out from the operative course that was uncomplicated. The early postoperative period was duly completed with discharge on the 3rd day. Her previous delivery was completed by cesarean section 2 years before because of cephalopelvic disproportion and a macrosomic infant. On examination in the emergency room, patient was normotensive with tachycardia (110–120/min) and febrile (38.5–39 °C). A local finding was the primary healing of a postoperative incision skin wound, and breast with sustained lactation and without signs of inflammation. Under vaginal specula the findings were: lochia appropriate for puerperal day, subinvolution of uterus, extremely painful to palpation, signs of hypogastric peritonism, with softer painful resistance up to 8 cm in the area of hysterorrhaphy. On ultrasonography of the lower anterior part of the uterus, a subvesical, sharply restricted inhomogeneous formation with a diameter of 6 cm communication and isoechogenicity with the contents of the uterus without Doppler sign was suspected, which raised a suspicion of partial dehiscence of the uterine scar with secondary effusion of the contents into the subvesical space (**Fig. 1**). The other finding of the ultrasound was normal. Laboratory tests were marked by elevated CRP (109) and anemia (Hgb 105), with other inflammatory parameters being normal. Antibiotics were prescribed (clindamycin 3 × 900 mg, metronidazole 3 × 500 mg). Given the suspected persistent uterine bleeding by uterine scar dehiscence with signs of peritonitis and acute abdomen, exploratory laparotomy was indicated. A Pfannenstiel relaparotomy was performed (at the site of previous cesarean sections) and an

8-cm hematoma was found below the vesicouterine pouch. The covered hematoma extended from the bottom of the anterior of the excavation being evacuated. Further inspection presented dehiscence and necrosis of the medial part of the hysterotomy with minor venous active bleeding (**Fig. 2**). Other sutures were tightened with visible avascularization of the margins of the locking parts of the sutures and initial signs of marginal necrosis. A necrectomy was performed, and the dehiscent part of the hysterotomy was resutured with placement of hemostatic sponges on the same portion of the uterus. Lavage was done with saline and a Redon drain was placed. In the postoperative course with antibiotic therapy and thromboprophylaxis, a reactive increase in inflammatory parameters was present on the 2nd day (CRP 208) with subsequent and prolonged regression weeks after the surgery. The patient's general condition was good with normal vital parameters and local findings, and she was discharged home after 9 days.

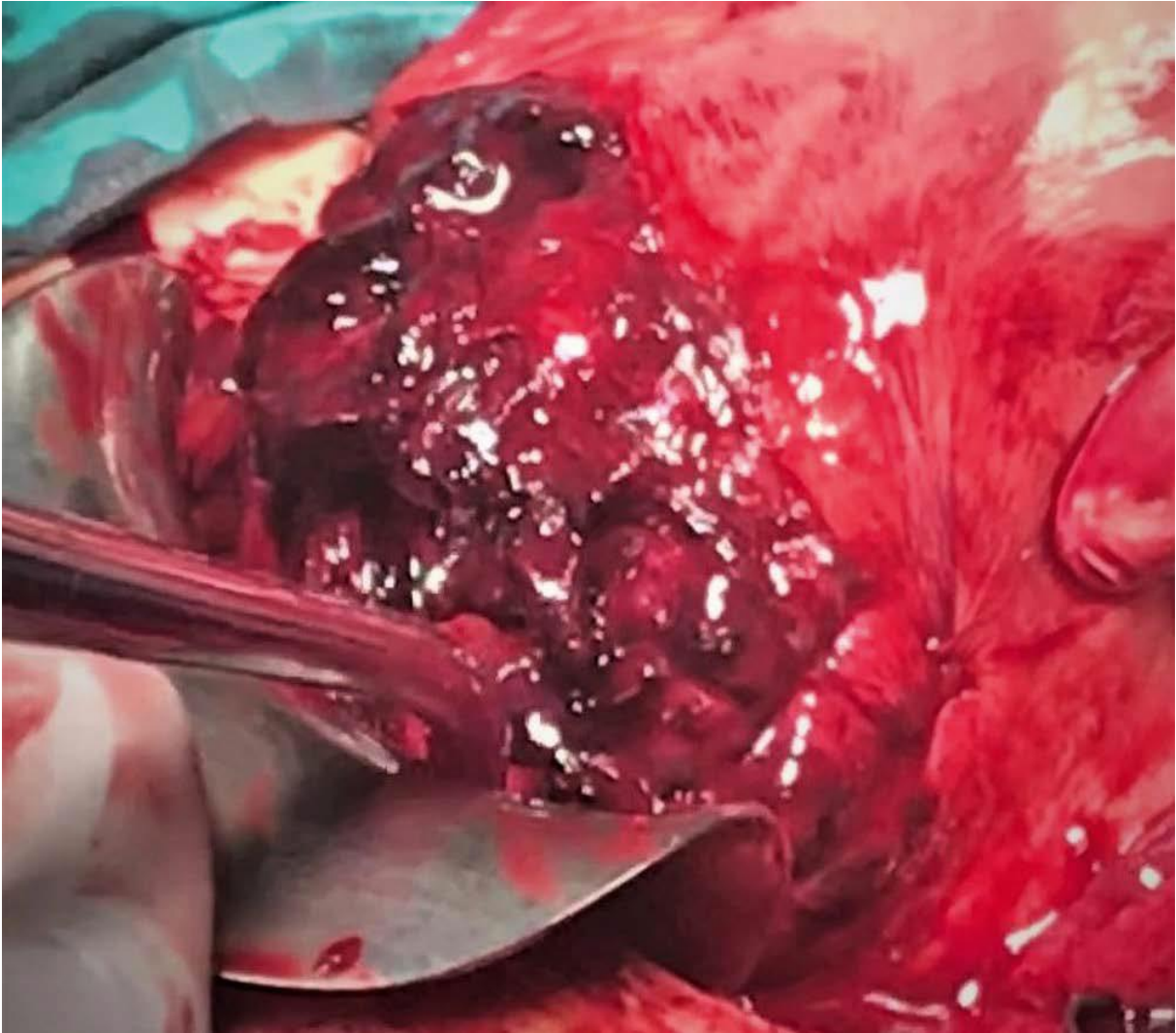
### **3. Discussion**

Early postpartum uterine dehiscence is the opening of hysterorrhaphy after a cesarean section and is a very rare condition. In the early postpartum period, opening of the uterine incision leaves the arcuate uterine veins open with active bleeding and subsequent postpartum hemorrhage [5]. There are numerous risk factors that can cause this condition: diabetes, emergency surgery, infection, suture technique, uterine incision hematoma, and retrovesical hematoma [6]. Cases of successful conservative treatment with broad-spectrum antibiotics in patients of good general condition without signs of severe hemorrhage and infection have been described, as well as cases of hysterectomy in severe cases of infection and the presence of abscesses [6, 7]. In the event that dehiscence leads to severe local and/or systemic infection, a laparotomy should be performed and the hysterotomy resutured with revision [5]. In the presence of endomyometritis and abscesses, hysterectomy is recommended [6]. In our case, we assume that active hemorrhage from a single arcuate vein and tightened locked uterine sutures were responsible for the cascade of polypathogenesis that occurred in the patient's early postpartum period. Active postpartum hemorrhage from the described vein caused dehiscence of the medial part of the hysterorrhaphy and consequently the formation of a retrovesical hematoma and secondary anemia. The tightened, locked-suture uterotomy caused ischemia and then necrosis of the focal part of the myometrium with the appearance of initially localized inflammation – myometritis – and was then aided by secondary anemia and propagation of uterine puerperal contents into localized peritonitis [8–10]. Laboratory tests were dominated by the already high CRP values, which are explained by the ‘contribution’ from the recent cesarean section but also to a larger extent by the development of a secondary inflammatory condition. In light of the worsening of the general and clinical condition during observation, conservative antibiotic treatment was not possible, and exploratory laparotomy and revision were indicated.

Preservation of the uterus was decided by resolving the causes that led to the consequent condition (evacuation of the hematoma, necrectomy, re-hysterorrhaphy). In the postoperative period, there was a significant improvement in the general and clinical status. Despite adequate antibiotic therapy, a slower decline in CRP was observed over a month, which is explained by the slow resorption of local inflammatory mediators (localized necrosis and inflammation) [11]. Ultrasound evaluation plays an important role in the diagnosis of uterotomy dehiscence and postpartum hemorrhage, whereas treatment depends primarily on the general/clinical status of the puerpera. The locking hysterorrhaphy technique can be risky for ischemic scarring and possible necrosis with dehiscence, so it should be avoided. One-way, nonlocking sutures should be used. In our case, because of the localization of the inflammatory state without the presence of abscesses on explorative laparotomy, the uterus was successfully preserved along with the patient's future reproductive capacity.



**Fig. 1** Ultrasound pictures of hysterorrhaphy dehiscence.



**Fig. 2** Intraoperative findings of the hematoma and hysterorrhaphy dehiscence.

#### 4. References

- [1] Wagner MS, Bédard MJ. Postpartum uterine wound dehiscence: a case report. *J Obstet Gynaecol Can* 2006; 28: 713–715
- [2] Royo P, Manero MG, Olartecoechea B et al. Two-dimensional power Doppler-three-dimensional ultrasound imaging of a cesarean section dehiscence with utero-peritoneal fistula: a case report. *J Med Case Rep* 2009; 3: 42
- [3] Alwani M, Mishra S, Thakur R. Generalized peritonitis with uterine incision necrosis with dehiscence following cesarean section presenting as genitourinary fistula: a unique complication. *J Med* 2014; 3: 762–766
- [4] Shaamash AH, Ahmed AG, Abdel Latef MM et al. Routine postpartum ultrasonography in the prediction of puerperal uterine complications. *Int J Gynaecol Obstet* 2007; 98: 93–99
- [5] Sengupta Dhar R, Misra R. Postpartum uterine wound dehiscence leading to secondary PPH: unusual sequelae. *Case Rep Obstet Gynecol* 2012; 154685
- [6] Ida A, Kubota Y, Nosaka M et al. Successful management of a cesarean scar defect with dehiscence of the uterine incision by using wound lavage. *Case Rep Obstet Gynecol* 2014; 421014
- [7] El-Agwany AS. Septic postpartum uterine dehiscence. *J Med Ultras* 2018; 26: 59–61
- [8] Stearns-Kurosawa DJ, Osuchowski MF, Valentine C et al. The pathogenesis of sepsis. *Annu Rev Pathol* 2011; 6: 19–48
- [9] Reyftmann L, Nguyen A, Ristic V et al. Partial uterine wall necrosis following Cho hemostatic sutures for the treatment of postpartum hemorrhage. *Gynecol Obstet Fertil* 2009; 37: 579–582

[10] Benkirane S, Saadi H, Serji B et al. Uterine necrosis following a combination of uterine compression sutures and vascular ligation during a postpartum hemorrhage: a case report. *Intern J Surg Case Rep* 2017; 38: 5–7

[11] Pova P. C-reactive protein: a valuable marker of sepsis. *Intensive Care Med* 2002; 28: 235–243



## OSOBNI PODACI I ŽIVOTOPIS



Ime i prezime:	Dino Pavoković
Adresa:	Ljudevita Gaja 55, 33000 Virovitica
E-mail:	pavokovic@hotmail.com
Državljanstvo:	hrvatsko
Datum i mjesto rođenja:	29. lipanj 1988., Virovitica

Rođen 29.06.1988. u Virovitici gdje sam završio osnovnu i osnovnu glazbenu školu (smjer glasovir) te srednju prirodoslovnu-matematičku gimnaziju. Medicinski fakultet sam upisao u Osijeku te sam ga završio 2013. godine. Pripravnički staž obavio sam u specijalističkoj ordinaciji obiteljske medicine u Osijeku kod dr. Jadranke Pralas.

Specijalist sam ginekologije i opstetricije u Općoj bolnici Virovitica. Tijekom obavljanja specijalističkog usavršavanja završio sam poslijediplomske specijalističke studije 'Ultrazvuk u ginekologiji i porodništvu' i 'Fetalna medicina i opstetricija'. Završio sam poslijediplomske tečajeve I. kategorije iz Ultrazvuka u ginekologiji i porodništvu, Opstetričke pelveoperineologije, Porodničkih operacija, Ginekološke endoskopije i kirurgije.

Licencirani sam predavač nastavnog predmeta 'Pružanje prve pomoći osobama ozlijeđenim u prometnoj nesreći', licencirani spasilac na otvorenim i zatvorenim vodama te specijalist za spašavanje iz poplava u sklopu Hrvatskog Crvenog križa. Dobitnik sam priznanja za

višegodišnje volontiranje te doprinosa u razvoju i promicanju rada Gradskih društava Crvenog križa u Virovitici i Osijeku.

U slobodno vrijeme izvan nastavnih aktivnosti u školi i na fakultetu aktivno sam se bavio plivanjem (PK Virovitica i PK Osijek Žito) te se mogu pohvaliti titulama: najboljeg sportaša grada Virovitice (2005. i 2006. god.) zbog značajnih regionalnih, državnih i međunarodnih uspjeha, najboljeg sveučilišnog plivača za vrijeme studiranja, najboljeg nacionalnog spasilaca (2010. i 2011. god.) te sudjelovanjem kao reprezentativac na svjetskim spasilačkim prvenstvima (2009. god. – Njemačka, 2010. – Egipat).

Trenutno najljepše vrijeme provodim uz suprugu i sina, te uz rekreativno bavljenje sportom.

Pavoković D, Cerovac A, Ljuca D, Habek D. Post-Cesarean Peritonitis Caused by Hysterorrhaphy Dehiscence with Puerperal Acute Abdomen Syndrome. *Z Geburtshilfe Neonatol.* 2020 Dec;224(6):374-376. doi: 10.1055/a-1203-0983. Epub 2020 Jul 22. PMID: 32698222.

# Post-Cesarean Peritonitis Caused by Hysterorrhaphy Dehiscence with Puerperal Acute Abdomen Syndrome

## Authors

Dino Pavoković<sup>1</sup>, Anis Cerovac<sup>2, 3</sup>, Dženita Ljuca<sup>4, 5</sup>, Dubravko Habek<sup>1, 6</sup>

## Affiliations

- 1 University Department of Gynecology and Obstetrics, Clinical Hospital „Sveti Duh“ Zagreb, Zagreb, Croatia
- 2 Department for Gynecology and Obstetrics, General Hospital Tešanj, Tešanj, Bosnia and Herzegovina
- 3 Department of Anatomy, University of Tuzla Faculty of Medicine, Tuzla, Bosnia and Herzegovina
- 4 Clinic for Gynecology and Obstetrics, Tuzla, University Clinical Center Tuzla, Bosnia and Herzegovina
- 5 Department of Gynecology and Obstetrics, University of Tuzla Faculty of Medicine, Tuzla, Bosnia and Herzegovina
- 6 Department of Gynecology and Obstetrics, Croatian Catholic University, Zagreb, Croatia

## Key words

caesarean section, acute abdomen, hysterorrhaphy, dehiscence

received 28.03.2020

accepted 09.06.2020

## Bibliography

DOI <https://doi.org/10.1055/a-1203-0983>

Online-Publikation: 2020

Z Geburtsh Neonatol

© Georg Thieme Verlag KG Stuttgart · New York

ISSN 0948-2393

## Correspondence

Dr. Anis Cerovac

Department for Gynecology and Obstetrics

University of Tuzla Faculty of Medicine

Univerzitetska br 1

750 000 Tuzla

Bosnia and Herzegovina

Tel : 0038761051929

cerovac.anis@gmail.com

## ABSTRACT

We present an overview of the case of a patient with early hysterorrhaphy dehiscence (uteroperitoneal fistula) with endomyometritis and post-cesarean section peritonitis and puerperal acute abdomen in a 35-year-old puerpera. A exploratory laparotomy, necrectomy, and resuture of the dehiscence part of the hysterotomy were performed with placement of hemostatic sponges on the same portion of the uterus with good recovery.

## Introduction

We are witnessing an increasing trend of cesarean sections worldwide, resulting in a consequent increase in postoperative complications. Frequent early postoperative complications include infections, dehiscences, hemorrhages, and hysterectomies, and late complications such as uterine scar dehiscence, malplacentaion, endometriosis, chronic pelvic pain, pelvic adhesions, and menstrual disorders [1–3]. Early puerperal dehiscence of the uterine scar after cesarean section is very rare, with a frequency between 0.06–3.8% [4].

We present an overview of the case of a patient with early hysterorrhaphy dehiscence with endomyometritis and post-cesarean section peritonitis. The initial presentation of puerperal acute abdomen made this case clinically striking.

## Case Report

A 35-year-old patient (G2 P2), who had undergone a cesarean section 4 days before, was examined in an emergency gynecological

ambulance for subfebrility and poor general condition with exacerbated pain in the pelvis and bladder. The elective iterative cesarean section was done with the Misgav-Ladach technique because of the macrosomic infant and previous cesarean section. Continuous locked hysterorrhaphy stood out from the operative course that was uncomplicated. The early postoperative period was duly completed with discharge on the 3<sup>rd</sup> day. Her previous delivery was completed by cesarean section 2 years before because of cephalopelvic disproportion and a macrosomic infant. On examination in the emergency room, patient was normotensive with tachycardia (110–120/min) and febrile (38.5–39 °C). A local finding was the primary healing of a postoperative incision skin wound, and breast with sustained lactation and without signs of inflammation. Under vaginal specula the findings were: lochia appropriate for puerperal day, subinvolution of uterus, extremely painful to palpation, signs of hypogastric peritonism, with softer painful resistance up to 8 cm in the area of hysterorrhaphy. On ultrasonography of the lower anterior part of the uterus, a subvesical, sharply restricted inhomogeneous

geneous formation with a diameter of 6 cm communication and isoechogenicity with the contents of the uterus without Doppler sign was suspected, which raised a suspicion of partial dehiscence of the uterine scar with secondary effusion of the contents into the subvesical space (► Fig. 1). The other finding of the ultrasound was normal. Laboratory tests were marked by elevated CRP (109) and anemia (Hgb 105), with other inflammatory parameters being normal. Antibiotics were prescribed (clindamycin 3 × 900 mg, metronidazole 3 × 500 mg). Given the suspected persistent uterine bleeding by uterine scar dehiscence with signs of peritonitis and acute abdomen, exploratory laparotomy was indicated. A Pfannenstiel relaparotomy was performed (at the site of previous cesarean sections) and an 8-cm hematoma was found below the vesicouterine pouch. The covered hematoma extended from the bottom of the anterior of the excavation being evacuated. Further inspection presented dehiscence and necrosis of the medial part of the hysterotomy with minor venous active bleeding (► Fig. 2). Other sutures were tightened with visible avascularization of the margins of the locking parts of the sutures and initial signs of marginal necrosis. A necrectomy was performed, and the dehiscent part of the hysterotomy was resutured with placement of hemostatic sponges on the same portion of the uterus. Lavage was done with saline and a Redon drain was placed. In the postoperative course with antibiotic therapy and thromboprophylaxis, a reactive increase in inflammatory parameters was present on the 2<sup>nd</sup> day (CRP 208) with subsequent and prolonged regression weeks after the surgery. The patient's general condition was good with normal vital parameters and local findings, and she was discharged home after 9 days.

## Discussion

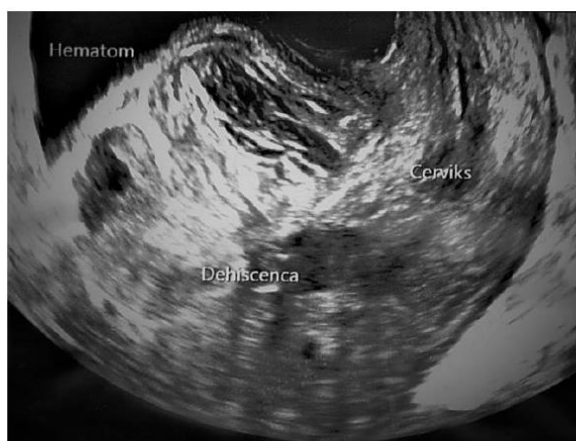Early postpartum uterine dehiscence is the opening of hysterorrhaphy after a cesarean section and is a very rare condition. In the early postpartum period, opening of the uterine incision leaves the

arcuate uterine veins open with active bleeding and subsequent postpartum hemorrhage [5]. There are numerous risk factors that can cause this condition: diabetes, emergency surgery, infection, suture technique, uterine incision hematoma, and retrovesical hematoma [6].

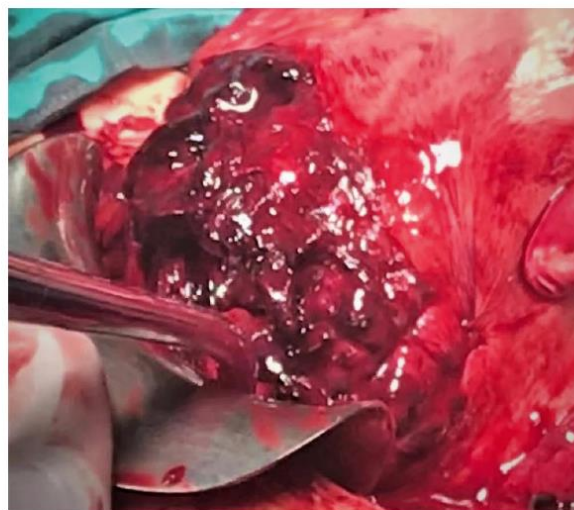Cases of successful conservative treatment with broad-spectrum antibiotics in patients of good general condition without signs of severe hemorrhage and infection have been described, as well as cases of hysterectomy in severe cases of infection and the presence of abscesses [6, 7]. In the event that dehiscence leads to severe local and/or systemic infection, a laparotomy should be performed and the hysterotomy resutured with revision [5]. In the presence of endomyometritis and abscesses, hysterectomy is recommended [6].

In our case, we assume that active hemorrhage from a single arcuate vein and tightened locked uterine sutures were responsible for the cascade of poly-pathogenesis that occurred in the patient's early postpartum period. Active postpartum hemorrhage from the described vein caused dehiscence of the medial part of the hysterorrhaphy and consequently the formation of a retrovesical hematoma and secondary anemia. The tightened, locked-suture hysterotomy caused ischemia and then necrosis of the focal part of the myometrium with the appearance of initially localized inflammation – myometritis – and was then aided by secondary anemia and propagation of uterine puerperal contents into localized peritonitis [8–10]. Laboratory tests were dominated by the already high CRP values, which are explained by the 'contribution' from the recent cesarean section but also to a larger extent by the development of a secondary inflammatory condition.

In light of the worsening of the general and clinical condition during observation, conservative antibiotic treatment was not possible, and exploratory laparotomy and revision were indicated. Preservation of the uterus was decided by resolving the causes that led to the consequent condition (evacuation of the hematoma,



► Fig. 1 Ultrasound pictures of hysterorrhaphy dehiscence.



► Fig. 2 Intraoperative findings of the hematoma and hysterorrhaphy dehiscence.

necrectomy, re-hysterorrhaphy). In the postoperative period, there was a significant improvement in the general and clinical status. Despite adequate antibiotic therapy, a slower decline in CRP was observed over a month, which is explained by the slow resorption of local inflammatory mediators (localized necrosis and inflammation) [11].

Ultrasound evaluation plays an important role in the diagnosis of uterotomy dehiscence and postpartum hemorrhage, whereas treatment depends primarily on the general/clinical status of the puerpera. The locking hysterorrhaphy technique can be risky for ischemic scarring and possible necrosis with dehiscence, so it should be avoided. One-way, nonlocking sutures should be used.

In our case, because of the localization of the inflammatory state without the presence of abscesses on explorative laparotomy, the uterus was successfully preserved along with the patient's future reproductive capacity.

### Conflict of Interest

The authors declare that they have no conflict of interest.

### References

- [1] Wagner MS, Bédard MJ. Postpartum uterine wound dehiscence: a case report. *J Obstet Gynaecol Can* 2006; 28: 713–715
- [2] Royo P, Manero MG, Olartecoechea B et al. Two-dimensional power Doppler-three-dimensional ultrasound imaging of a cesarean section dehiscence with utero-peritoneal fistula: a case report. *J Med Case Rep* 2009; 3: 42
- [3] Alwani M, Mishra S, Thakur R. Generalized peritonitis with uterine incision necrosis with dehiscence following cesarean section presenting as genitourinary fistula: a unique complication. *J Med* 2014; 3: 762–766
- [4] Shaamash AH, Ahmed AG, Abdel Latef MM et al. Routine postpartum ultrasonography in the prediction of puerperal uterine complications. *Int J Gynaecol Obstet* 2007; 98: 93–99
- [5] Sengupta Dhar R, Misra R. Postpartum uterine wound dehiscence leading to secondary PPH: unusual sequelae. *Case Rep Obstet Gynecol* 2012; 154685
- [6] Ida A, Kubota Y, Nosaka M et al. Successful management of a cesarean scar defect with dehiscence of the uterine incision by using wound lavage. *Case Rep Obstet Gynecol* 2014; 421014
- [7] El-Agwany AS. Septic postpartum uterine dehiscence. *J Med Ultras* 2018; 26: 59–61
- [8] Stearns-Kurosawa DJ, Osuchowski MF, Valentine C et al. The pathogenesis of sepsis. *Annu Rev Pathol* 2011; 6: 19–48
- [9] Reyftmann L, Nguyen A, Ristic V et al. Partial uterine wall necrosis following Cho hemostatic sutures for the treatment of postpartum hemorrhage. *Gynecol Obstet Fertil* 2009; 37: 579–582
- [10] Benkirane S, Saadi H, Serji B et al. Uterine necrosis following a combination of uterine compression sutures and vascular ligation during a postpartum hemorrhage: a case report. *Intern J Surg Case Rep* 2017; 38: 5–7
- [11] Povoia P. C-reactive protein: a valuable marker of sepsis. *Intensive Care Med* 2002; 28: 235–243