

The assessment of tumor-infiltrating lymphocytes in invasive apocrine carcinoma of the breast in relation to the HER2 status

Gatalica, Zoran; Kuzmova, Nataliya; Rose, Inga; Ulamec, Monika; Perić-Balja, Melita; Skenderi, Faruk; Vranic, Semir

Source / Izvornik: **Biomolecules and Biomedicine, 2024, 24, 256 - 261**

Journal article, Published version

Rad u časopisu, Objavljena verzija rada (izdavačev PDF)

<https://doi.org/10.17305/bb.2023.9868>

Permanent link / Trajna poveznica: <https://um.nsk.hr/um:nbn:hr:105:253311>

Rights / Prava: [Attribution 4.0 International](#) / [Imenovanje 4.0 međunarodna](#)

Download date / Datum preuzimanja: **2024-06-29**










Repository / Repozitorij:

[Dr Med - University of Zagreb School of Medicine
Digital Repository](#)



RESEARCH ARTICLE

The assessment of tumor-infiltrating lymphocytes in invasive apocrine carcinoma of the breast in relation to the HER2 status

Zoran Gatalica ^{1,2}, Nataliya Kuzmova ¹, Inga Rose ¹, Monika Ulašec ^{3,4}, Melita Peric-Balja ⁵, Faruk Skenderi ⁶, and Semir Vranic ^{7*}

In the current study, we assessed the prevalence and molecular features of HER2-low phenotype in the apocrine carcinomas of the breast (ApoCa) and its relationship with tumor-infiltrating lymphocytes (TILs). A cohort of 64 well-characterized therapy-naïve ApoCa was used. The TIL distribution was assessed using the hematoxylin and eosin whole slide/scanned images following the international TILs working group recommendations. Next-generation sequencing (NGS) was performed in a subset of HER2-low ApoCa. All patients were women, with a mean age of 62 years. Forty-three carcinomas were pure apocrine carcinoma (PAC; ER−/AR+), and the remaining 21 were classified as apocrine-like carcinomas (ALCs; ER+/-, AR+/-). HER2/neu was positive (score 3+ by IHC and/or amplified by FISH) in 20/43 (47%) PAC and 4/21 (19%) ALC. The prevalence of HER2-low expression (scores 1+ or 2+ without *HER2* amplification) in ApoCa was 39% without significant differences between PAC and ALC ($P = 0.14$); however, the HER2-low phenotype was more prevalent in triple-negative PAC than in ALC ($P < 0.001$). Levels of TILs were low ($\leq 10\%$) in 74% of ApoCa (median: 5%, range 0%–50%). TIL levels were significantly higher in ALC than in PAC ($P = 0.02$). HER2 status had no impact on TIL distribution ($P = 0.45$). The genomic profile of HER2-low ApoCa was similar to other subtypes of ApoCa. ApoCa has predominantly low TIL, particularly PAC. The prevalence of the HER2-low phenotype in ApoCa is high, which should have therapeutic and clinical implications given the recently approved therapies with antibody–drug conjugates (ADCs) for HER2-low breast cancers.

Keywords: Breast cancer, special types, apocrine carcinoma, tumor-infiltrating lymphocytes (TILs), HER2-low.

Introduction

Apocrine carcinoma of the breast (ApoCa) is a rare (~1%), special type of breast cancer with characteristic apocrine morphology and steroid receptor expression profile: estrogen receptor (ER)-negative and androgen receptor (AR)-positive [1, 2]. Most ApoCa are categorized as triple-negative carcinomas; however, *HER2/neu* overexpression (score 3+) has been reported in 30%–50% of ApoCa caused by the *HER2/neu* gene amplification [1, 3–6]. Recently, HER2-low breast cancers, defined by HER2 scores 1+ or 2+ without *HER2/neu* gene amplification, have come into clinical focus due to the marked therapeutic efficiency of trastuzumab deruxtecan (DS-8201) in metastatic, HER2-low breast cancers [7]. Trastuzumab deruxtecan (DS-8201) is an antibody–drug conjugate (ADC) composed of a humanized anti-HER2 monoclonal antibody linked to the topoisomerase I inhibitor payload via a linker [8, 9]. The prevalence of HER2-low expression in metastatic breast cancers of no special type (NST) is ~60% but has not yet been specifically explored in ApoCa [10].

Tumor-infiltrating lymphocytes (TILs) play a pivotal role in mediating response to cytotoxic chemotherapy and improving the clinical outcomes of breast cancer patients [11]. TIL-enriched breast cancers, mainly ER-negative carcinomas, may also be more responsive to immunotherapy with immune checkpoint inhibitors (ICIs) [12]. The evaluation of stromal TILs has been a subject of controversy due to their subjective morphologic assessment. However, substantial efforts have been undertaken to improve and standardize the TIL assessment in breast cancer. Thus, the International TILs Working Group 2014 published recommendations and practical guidelines to enable more reliable and reproducible assessment of stromal TILs in breast cancer [13]. Numerous studies have explored and confirmed the clinical relevance of stromal TILs in breast cancer, leading to incorporating this parameter into the routine assessment of all early triple-negative breast cancers (TNBCs) as a prognostic biomarker (Level 1B evidence) [14]. However, the St. Gallen International Breast Cancer Consensus 2021 and the current breast cancer clinical guidelines do not

¹Reference Medicine, Phoenix, Arizona, USA; ²The University of Oklahoma Health Sciences Center, Oklahoma, USA; ³Ljudevit Jurak Clinical Department of Pathology and Cytology, Sestre Milosrdnice University Hospital Center, Zagreb, Croatia; ⁴Department of Pathology and Scientific Group for Research on Epigenetic Biomarkers, University of Zagreb School of Medicine, Zagreb, Croatia; ⁵Oncological Pathology Department, Ljudevit Jurak Clinical Department of Pathology and Cytology, Sestre Milosrdnice University Hospital Center, Zagreb, Croatia; ⁶Department of Pathology, Sarajevo School of Science and Technology, Sarajevo, Bosnia and Herzegovina; ⁷College of Medicine, QU Health, Qatar University, Doha, Qatar.

*Correspondence to Semir Vranic: semir.vranic@gmail.com or svranic@anubih.ba

DOI: 10.17305/bb.2023.9868

© 2023 Gatalica et al. This article is available under a Creative Commons License (Attribution 4.0 International, as described at <https://creativecommons.org/licenses/by/4.0/>).

endorse a routine TIL assessment in breast cancer, nor do they recommend the de-escalation of chemotherapy based on the TIL status [15]. On the other hand, the status of stromal TILs in ApoCa has been rarely analyzed with limited available data (reviewed in [16]).

In the current study, we investigated the status of TILs in a cohort of ApoCa, and also analyzed the prevalence and molecular features of the HER2-low phenotype in ApoCa and its impact on TILs.

Materials and methods

Sample collection

Formalin-fixed paraffin-embedded (FFPE) surgical samples and/or microscopic slides of ApoCa cases were retrieved from the Department of Pathology at The University of Oklahoma Health Sciences Center ($n = 6$) [17], the Ljudevit Jurak Clinical Department of Pathology and Cytology at Sestre Milosrdnice University Hospital Center (Zagreb, Croatia) ($n = 7$) [18], and from the authors' consultation cases ($n = 51$) collected during their diagnostic breast pathology services. All cases were graded using the Nottingham histologic grade and re-reviewed for the current study [19]. The status of ER, progesterone (PR), and HER2/neu receptors was routinely utilized during the diagnostic work-up, following the international CAP/ASCO guidelines [20, 21]. HER2-low was defined as scores 1+ and 2+ by IHC without *HER2/neu* gene amplification, as determined by in situ hybridization assays [21]. In addition, immunohistochemical androgen receptor (AR) expression was utilized for the molecular classification of ApoCa [3, 4, 14]. The tumors were considered positive for AR if they exhibited positivity in $\geq 10\%$ of the cancer cells' nuclei [3].

Molecular classification of apocrine carcinomas (ApoCa)

As earlier proposed, all ApoCa cases were classified based on their characteristic morphology and steroid receptors status: cases that were ER-negative and AR-positive were classified as pure apocrine carcinomas (PACs), while the remaining cases with variable expression of ER and AR (ER+/-, AR+/-) were classified as apocrine-like carcinomas (ALCs) [3, 4, 17].

Assessment of tumor-infiltrating lymphocytes (TIL)

TILs were assessed in the stromal compartment, denoted as percentage stromal TILs (% stromal TILs). The assessment excluded TILs located outside the tumor borders, around in situ components, and within normal ducts/lobules. The areas affected by the crush artifacts, tumor necrosis, extensive stromal hyalinization, and the previous core biopsy sites were also excluded. Only mononuclear cells (lymphocytes and plasma cells) were scored, while polymorphonuclear leukocytes were excluded. The stromal TILs were reported as a continuous variable [13]. The average stromal TIL percentage was calculated for samples with two or more slides available. In cases of intratumoral heterogeneity, different areas were scored, and the average was taken as the final percentage of stromal TILs [13]. TIL assessment was conducted using either glass slides or scanned images. Slides were scanned using the Philips Intellisite Pathology Solution Ultra Fast Scanner® (Philips Medical Systems Nederland

B.V.) and reviewed using Aperio ImageScope® 12.3 version (Leica Microsystems, Wetzlar, Germany).

Next-generation sequencing for HER2-low ApoCa

Next-generation sequencing (NGS) was performed on selected ApoCa cases using the commercially available platform of Caris Life Sciences (Phoenix, AZ, USA), and the method was previously reported [3, 22–24].

Ethical statement

All cases were de-identified and pseudo-anonymized for the purposes of this study. For samples sourced from the University of Oklahoma College of Medicine, approval was granted by the Institutional Review Board of the University of Oklahoma (Approval number: IRB#12866), while the Croatian samples received approval from the Ethical Committee of the Sestre Milosrdnice University Hospital Center (Approval number: EP-13659/21-11).

Statistical analysis

Pearson's chi-squared test explored statistically significant differences between the expected and the observed frequencies in categorical variables. For 2×2 contingency tables, Fisher's exact test was used. All statistical analyses were performed using the IBM Statistical Package for the Social Sciences (IBM SPSS, version 27). Statistical significance was set at $P < 0.05$.

Results

Clinicopathologic characteristics of the ApoCa cohort

The demographic and pathologic characteristics of the ApoCa cohort are summarized in Table 1. All 64 patients were women diagnosed with primary, treatment-naïve ApoCa. The mean age of the patients was 62.4 years, with an age range of 31–83 years. All ApoCa cases were categorized as either grade 2 (44%) or grade 3 (56%) carcinomas. Based on the steroid receptor profile, 43 ApoCa cases (67%) were classified as PAC, while 21 ApoCa cases were identified as ALCs (Table 1).

HER2 status in the ApoCa cohort

HER2/neu data were retrieved from the previous histopathologic reports. HER2/neu was positive (score 3+ by IHC and/or amplified by FISH) in 24/64 (37.5%) of ApoCa cases, including 20/43 (47%, 95% CI: 33%–61%) PAC and 4/21 ALC (19%, 95% CI: 8%–40%) ($P < 0.001$). The prevalence of HER2-low expression (scores 1+ and 2+ without *HER2* amplification) in ApoCa was 39% without significant differences between PAC and ALC (37% vs 43%, $P = 0.14$); however, the HER2-low phenotype was more prevalent in triple-negative PAC than in ALC (70% vs 43% $P < 0.001$) (Table 2 and Figure 1A and 1B).

TIL status in the ApoCa cohort

Stromal TILs were fully assessable in 61 out of the 64 cases (95%). The remaining three cases were predominantly apocrine ductal carcinomas in situ (DCIS) with limited invasive component for stromal TIL assessment (microinvasive carcinomas).

Table 1. Overview of the major demographic and pathologic characteristics of the ApoCa cohort

Characteristic (Parameter)	Results (n = 64 cases)
Age (mean, range)	62.4 years (31–83 years)
Sex	Female (64, 100%)
Subtypes	Pure apocrine carcinomas (ER−/AR+): 43/64 (67%): 23 triple-negative and 20 HER2/neu positive cases Apocrine-like carcinomas (ER−/+, AR−/+): 21/64 (33%): 4 HER2/neu positive cases
Tumor grade	Grade 2: 28 cases (44%) Grade 3: 36 cases (56%)
HER2/neu status	Negative (15/64, 23%) Positive (24/64, 38%) HER2-low (25/64, 39%)
TIL status (mean, median, range)	12%, 5%, 0%–50%

TIL: Tumor-infiltrating lymphocytes; ER: Estrogen receptor; AR: Androgen receptor; ApoCa: Apocrine carcinomas of the breast.

Table 2. Molecular subtypes of apocrine carcinomas differed significantly concerning HER2 status

		Molecular subtypes			Total
		PAC (Triple-negative)	PAC (HER2+)	ALC	
HER2 status	Negative	7 (30%)	0 (0%)	8 (38%)	15 (23%)
	Positive	0 (0%)	20 (100%)	4 (19%)	24 (37.5%)
	HER2-low	16 (70%)	0 (0%)	9 (43%)	25 (39%)
Total		23 (36%)	20 (31%)	21 (33%)	64

PAC: Pure apocrine carcinomas; ALC: Apocrine-like carcinoma.

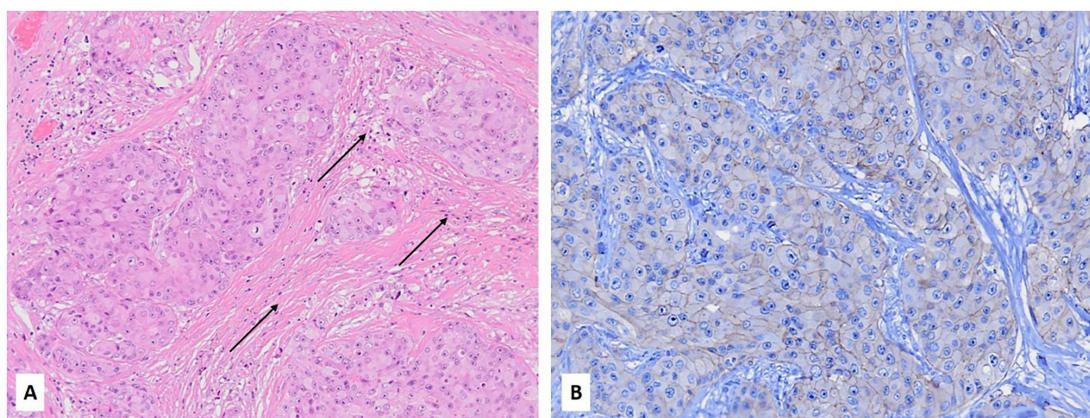


Figure 1. (A) Hematoxylin and eosin stain of a case of PAC (ER−/AR+) of the breast with low TIL expression (~1%), as indicated by black arrows (10x); The same case exhibited 2+ HER2 expression by immunohistochemistry (20x); (B) A subsequent FISH assay revealed no HER2/neu gene amplification (HER2/CEP17 ratio = 1.13). PAC: Pure apocrine carcinoma; TIL: Tumor-infiltrating lymphocyte; FISH: Fluorescent in situ hybridization.

The median of the stromal TILs was 5% (mean 12%), with a range of 0%–50% (Figure 1B). Overall, levels of the stromal TILs in ApoCa were low, with 45/61 (74%) having stromal TILs ≤ 10% (Table 3 and Figure 1A). Only five cases (all ALC) were markedly enriched with stromal TIL (=50%) (Table 3 and Figure 2), and

the difference was statistically significant ($P = 0.02$). The HER2 status, including HER2-low phenotype, did not impact the stromal TIL distribution ($P = 0.45$). Additionally, there was no correlation between the levels of stromal TILs and the patient's age or tumor grade ($P > 0.05$).

Table 3. Levels of tumor-infiltrating lymphocytes according to the molecular subtype of apocrine carcinoma

Tumor-infiltrating lymphocytes (%)	Molecular subtypes of apocrine carcinoma			Total
	Pure apocrine carcinoma		Apocrine-like carcinoma	
	Triple-negative	HER2+		
0%	1	1	2	4
1%	1	5	6	12
2%	1	0	0	1
5%	8	4	4	16
10%	7	2	3	12
20%	1	3	1	5
30%	2	4	0	6
50%	0	0	5	5
Total	21	19	21	61

Table 4. Mutational profile of HER2-low ApoCa

Case	HER2 status	Molecular subtype	Mutational profile
Case#1	Score 2+ without amplification	PAC	<i>PIK3CA, H1047R</i>
Case#2	Score 1+	PAC	<i>PTEN, P248_V249del, PTEN, Q214X</i>
Case#3	Score 1+	PAC	<i>PTEN, P213L, TP53, C141Y</i>
Case#4	Score 1+	PAC	<i>PIK3CA, E542K, KRAS, G12D</i>
Case#5	Score 2+ without amplification	PAC	<i>BRAF, D594F</i>

PAC: Pure apocrine carcinomas; ApoCa: Apocrine carcinomas of the breast.

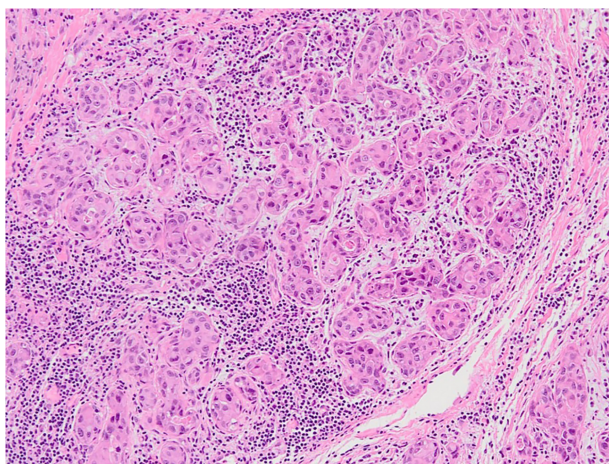


Figure 2. A case of apocrine-like (ER+/AR+) HER2-low (score 1+) carcinoma with moderate (~50%) TIL expression (Hematoxylin and eosin, 10x). TIL: Tumor-infiltrating lymphocyte.

NGS profile of HER2-low ApoCa

The mutational profile of HER2-low ApoCa was available for five cases of PAC. The most notable pathogenic mutations observed *PTEN* (2/5), *PIK3CA* (2/5), *TP53* (1/5), *BRAF* (1/5), and *KRAS* (1/5) (Table 4).

Discussion

ApoCa is a rare breast cancer subtype with limited targeted therapy options, beyond the anti-HER2 treatment modalities for HER2-positive (3+) cases [14, 16]. Recent breakthroughs in treating advanced, HER2-low (2+) breast cancers with the ADC trastuzumab deruxtecan have been reported [7, 25]. The clinical trial DESTINY-Breast04 (ClinicalTrials.gov number, NCT03734029) revealed significantly longer overall and progression-free survival in the patients with HER2-low breast cancers treated with trastuzumab deruxtecan, compared to those treated with conventional chemotherapy [7]. This led to the Food and Drug Administration (FDA) approval of the drug for all previously treated advanced HER2-low breast cancers [26]. Therefore, recognizing HER2-low breast cancers, particularly in the metastatic setting, has become clinically relevant for the proper management of breast cancer patients. Our study revealed a relatively high prevalence (39%) of HER2-low phenotype in the ApoCa cohort. This prevalence aligns with a recently published systematic review with meta-analysis that revealed an overall HER2-low phenotype prevalence of 36% among >4000 breast cancer patients with TNBC [27]. Therefore, our findings may provide additional, valuable treatment options for a substantial proportion of the patients with advanced ApoCa.

Although limited to only five cases, our mutational profiling revealed a preponderance of ApoCa for mutations within the PIK3CA/PTEN and MAPK signaling pathways [3, 5, 28]. These data indicate that HER2-low ApoCa shares similar molecular features to other ApoCa subtypes and aligns with the recent data from NST carcinomas that revealed that HER2-low is not a distinct clinical and molecular subtype of breast cancer [29–32].

The treatment with ICIs has markedly improved the outcomes of numerous cancer subtypes, including TNBC, with agents like pembrolizumab. Predictive biomarkers for ICI include PD-L1 expression, tumor mutational burden (TMB), and microsatellite instability-high (MSI-H) status. So far, PD-L1 expression on immune cells has been validated as a predictive biomarker in breast cancer. In contrast to the recent study of Ni et al. [33], previous data indicate that ApoCa exhibits low PD-L1 expression, low TMB, and consistently displays MSI stability (reviewed in [5, 16, 28], and [34–36]). High stromal TIL presence has been a feature of ER-negative breast carcinomas, particularly TNBC [37, 38]. Although not entirely validated and approved, high stromal TIL levels may indicate good responses to conventional chemotherapy and ICIs. Additionally, stromal TIL is also a potent prognostic factor associated with favorable clinical outcomes in early-stage TNBC [38]. Specifically, high stromal TIL levels in stage II TNBC is associated with better outcomes compared to stage I TNBC with lower TIL levels [39]. Three previous studies revealed low stromal TILs in triple-negative ApoCa and a low enrichment with CD3+ and CD8+ lymphocytes, consistent with our results, particularly in PAC [35, 36, 40]. Based on both current data and previous studies, ApoCa patients appear to be less likely responsive to ICIs.

A limitation of our study is the lack of clinical and follow-up information; hence, we could not correlate the status of TIL with the patient's outcome. We also used the initially proposed recommendations for TIL assessment by the International TILs in Breast Cancer Working Group (now renamed as the International Immuno-Oncology Biomarker Working Group). These guidelines were later revised to include the assessment of the invasive front of cancers, defined as a 1-mm rim around the tumor. The HER2/neu results were derived from previous histopathologic reports and were not subject to central re-review.

Conclusion

ApoCa of the breast, particularly PAC, does not appear to be enriched with the stromal TIL, which, along with low-PD-L1, low TMB, and microsatellite stable status known from previous studies, make these cancers less amenable to the treatment with ICI. HER2-low ApoCa exhibits similar TIL features and mutational profiles to other ApoCa subtypes. However, HER2-low expression in approximately 40% of ApoCa cases provides a valuable predictive biomarker to trastuzumab deruxtecan, opening a new avenue for treating advanced diseases. Further clinical studies (trials) should confirm the clinical relevance of our observations.

Acknowledgments

The preliminary data from the study were presented at the 35th European Congress of Pathology, Dublin, 2023. The authors thank Mike Nelson, Daniel Gatalica, Matthew Wilgenbusch, and Sheena Conant (all at Reference Medicine) for their excellent technical support.

Conflicts of interest: Authors declare no conflicts of interest.

Funding: Authors received no specific funding for this work.

Submitted: 01 September 2023

Accepted: 27 September 2023

Published online: 02 October 2023

References

- [1] Provenzano E, Gatalica Z, Vranic S. Carcinoma with apocrine differentiation. In: Breast tumours. 5th ed. Lyon: IARC; 2019.
- [2] Gatalica Z. Immunohistochemical analysis of apocrine breast lesions: consistent over-expression of androgen receptor accompanied by the loss of estrogen and progesterone receptors in apocrine metaplasia and apocrine carcinoma in situ. *Pathol Res Pract* 1997;193(11–12):753–8. [https://doi.org/10.1016/S0344-0338\(97\)80053-2](https://doi.org/10.1016/S0344-0338(97)80053-2).
- [3] Vranic S, Marchio C, Castellano I, Botta C, Scalzo MS, Bender RP, et al. Immunohistochemical and molecular profiling of histologically defined apocrine carcinomas of the breast. *Hum Pathol* 2015;46(9):1350–9. <https://doi.org/10.1016/j.humpath.2015.05.017>.
- [4] Vranic S, Tawfik O, Palazzo J, Bilalovic N, Eyzaguirre E, Lee LM, et al. EGFR and HER-2/neu expression in invasive apocrine carcinoma of the breast. *Mod Pathol* 2010;23(5):644–53. <https://doi.org/10.1038/modpathol.2010.50>.
- [5] Vranic S, Feldman R, Gatalica Z. Apocrine carcinoma of the breast: a brief update on the molecular features and targetable biomarkers. *Bosn J Basic Med Sci* 2017;17(1):9–11. <https://doi.org/10.17305/bjbm.2016.1811>.
- [6] Skenderi F, Alahmad MAM, Tahirovic E, Alahmad YM, Gatalica Z, Vranic S. HER2-positive apocrine carcinoma of the breast: a population-based analysis of treatment and outcome. *Breast Cancer Res Treat* 2022;193(2):523–33. <https://doi.org/10.1007/s10549-022-06578-4>.
- [7] Modi S, Jacot W, Yamashita T, Sohn J, Vidal M, Tokunaga E, et al. Trastuzumab deruxtecan in previously treated HER2-low advanced breast cancer. *N Engl J Med* 2022;387(1):9–20. <https://doi.org/10.1056/NEJMoa2203690>.
- [8] Modi S, Saura C, Yamashita T, Park YH, Kim SB, Tamura K, et al. Trastuzumab deruxtecan in previously treated HER2-positive breast cancer. *N Engl J Med* 2020;382(7):610–21. <https://doi.org/10.1056/NEJMoa1914510>.
- [9] Tamura K, Tsurutani J, Takahashi S, Iwata H, Krop IE, Redfern C, et al. Trastuzumab deruxtecan (DS-8201a) in patients with advanced HER2-positive breast cancer previously treated with trastuzumab emtansine: a dose-expansion, phase I study. *Lancet Oncol* 2019;20(6):816–26. [https://doi.org/10.1016/S1470-2045\(19\)30097-X](https://doi.org/10.1016/S1470-2045(19)30097-X).
- [10] Tarantino P, Hamilton E, Tolaney SM, Cortes J, Morganti S, Ferraro E, et al. HER2-low breast cancer: pathological and clinical landscape. *J Clin Oncol* 2020;38(17):1951–62. <https://doi.org/10.1200/JCO.19.02488>.
- [11] Stanton SE, Disis ML. Clinical significance of tumor-infiltrating lymphocytes in breast cancer. *J Immunother Cancer* 2016;4:59. <https://doi.org/10.1186/s40425-016-0165-6>.
- [12] El Bairi K, Haynes HR, Blackley E, Fineberg S, Shear J, Turner S, et al. The tale of TILs in breast cancer: a report from the International Immuno-Oncology Biomarker Working Group. *NPJ Breast Cancer* 2021;7(1):150. <https://doi.org/10.1038/s41523-021-00346-1>.
- [13] Salgado R, Denkert C, Demaria S, Sirtaine N, Klauschen F, Pruneri G, et al. The evaluation of tumor-infiltrating lymphocytes (TILs) in breast cancer: recommendations by an International TILs Working Group

2014. *Ann Oncol* 2015;26(2):259–71. <https://doi.org/10.1093/annonc/mdl450>.
- [14] WHO classification of tumour editorial board. In: *Breast tumours*. 5th ed. Lyon: IARC; 2019.
- [15] Valenza C, Taurelli Salimbeni B, Santoro C, Trapani D, Antonarelli G, Curigliano G. Tumor infiltrating lymphocytes across breast cancer subtypes: current issues for biomarker assessment. *Cancers (Basel)* 2023;15(3):767. <https://doi.org/10.3390/cancers15030767>.
- [16] Vranic S, Gatalica Z. An update on the molecular and clinical characteristics of apocrine carcinoma of the breast. *Clin Breast Cancer* 2022;22(4):e576–e85. <https://doi.org/10.1016/j.clbc.2021.12.009>.
- [17] Gatalica Z, Stafford P, Vranic S. Alpha-methylacyl-CoA racemase (AMACR) protein is upregulated in early proliferative lesions of the breast irrespective of apocrine differentiation. *Hum Pathol* 2022;129:40–6. <https://doi.org/10.1016/j.humpath.2022.08.002>.
- [18] Gupta I, Ulapec M, Peric-Balja M, Ramic S, Al Moustafa AE, Vranic S, et al. Presence of high-risk HPVs, EBV, and MMTV in human triple-negative breast cancer. *Hum Vaccin Immunother* 2021;17(11):4457–66. <https://doi.org/10.1080/21645515.2021.1975452>.
- [19] Elston CW, Ellis IO. Pathological prognostic factors in breast cancer. I. The value of histological grade in breast cancer: experience from a large study with long-term follow-up. *Histopathology* 1991;19(5):403–10. <https://doi.org/10.1111/j.1365-2559.1991.tb00229.x>.
- [20] Allison KH, Hammond MEH, Dowsett M, McKernin SE, Carey LA, Fitzgibbons PL, et al. Estrogen and progesterone receptor testing in breast cancer: ASCO/CAP guideline update. *J Clin Oncol* 2020;38(12):1346–66. <https://doi.org/10.1200/JCO.19.02309>.
- [21] Wolff AC, Somerfield MR, Dowsett M, Hammond MEH, Hayes DF, McShane LM, et al. Human epidermal growth factor receptor 2 testing in breast cancer: American Society of Clinical Oncology–College of American Pathologists guideline update. *Arch Pathol Lab Med Online ahead of print*. <https://doi.org/10.1200/JCO.22.02864>.
- [22] Gargano SM, Senarathne W, Feldman R, Florento E, Stafford P, Swensen J, et al. Novel therapeutic targets in salivary duct carcinoma uncovered by comprehensive molecular profiling. *Cancer Med* 2019;8(17):7322–9. <https://doi.org/10.1002/cam4.2602>.
- [23] Vranic S, Palazzo J, Sanati S, Florento E, Contreras E, Xiu J, et al. Potential novel therapy targets in neuroendocrine carcinomas of the breast. *Clin Breast Cancer* 2019;19(2):131–6. <https://doi.org/10.1016/j.clbc.2018.09.001>.
- [24] Vranic S, Stafford P, Palazzo J, Skenderi F, Swensen J, Xiu J, et al. Molecular profiling of the metaplastic spindle cell carcinoma of the breast reveals potentially targetable biomarkers. *Clin Breast Cancer* 2020;20(4):326–31.E1. <https://doi.org/10.1016/j.clbc.2020.02.008>.
- [25] Vranic S, Beslija S, Gatalica Z. Targeting HER2 expression in cancer: new drugs and new indications. *Bosn J Basic Med Sci* 2021;21(1):1–4. <https://doi.org/10.17305/bjbm.2020.4908>.
- [26] FDA approves fam-trastuzumab deruxtecan-nxki for HER2-low breast cancer: FDA [Internet]. [cited 2023 Jun 15] Available from: <https://www.fda.gov/drugs/resources-information-approved-drugs/fda-approves-fam-trastuzumab-deruxtecan-nxki-her2-low-breast-cancer>
- [27] Ergun Y, Akagunduz B, Karacin C, Turker S, Ucar G. The effect of HER2-low status on pathological complete response and survival in triple-negative breast cancer: a systemic review and meta-analysis. *Clin Breast Cancer*. 2023;23(6):567–75. <https://doi.org/10.1016/j.clbc.2023.05.015>.
- [28] Sun X, Zuo K, Yao Q, Zhou S, Shui R, Xu X, et al. Invasive apocrine carcinoma of the breast: clinicopathologic features and comprehensive genomic profiling of 18 pure triple-negative apocrine carcinomas. *Mod Pathol* 2020;33(12):2473–82. <https://doi.org/10.1038/s41379-020-0589-x>.
- [29] Fernandez AI, Liu M, Bellizzi A, Brock J, Fadare O, Hanley K, et al. Examination of low ERBB2 protein expression in breast cancer tissue. *JAMA Oncol* 2022;8(4):1–4. <https://doi.org/10.1001/jamaoncol.2021.7239>.
- [30] Miglietta F, Griguolo G, Bottosso M, Giarratano T, Lo Mele M, Fassan M, et al. Evolution of HER2-low expression from primary to recurrent breast cancer. *NPJ Breast Cancer* 2021;7(1):137. <https://doi.org/10.1038/s41523-021-00343-4>.
- [31] Tarantino P, Jin Q, Tayob N, Jeselsohn RM, Schnitt SJ, Vinciguilla J, et al. Prognostic and biologic significance of ERBB2-low expression in early-stage breast cancer. *JAMA Oncol* 2022;8(8):1177–83. <https://doi.org/10.1001/jamaoncol.2022.2286>.
- [32] Hein A, Hartkopf AD, Emons J, Lux MP, Volz B, Taran FA, et al. Prognostic effect of low-level HER2 expression in patients with clinically negative HER2 status. *Eur J Cancer* 2021;155:1–12. <https://doi.org/10.1016/j.ejca.2021.06.033>.
- [33] Ni Y, Tsang JY, Shao Y, Poon IK, Tam F, Shea KH, et al. Combining analysis of tumor-infiltrating lymphocytes (TIL) and PD-L1 refined the prognostication of breast cancer subtypes. *Oncologist* 2022;27(4):e313–e27. <https://doi.org/10.1093/oncolo/oyab063>.
- [34] Mills AM, C EG, S MW, C MB, Atkins KA. Pure apocrine carcinomas represent a clinicopathologically distinct androgen receptor-positive subset of triple-negative breast cancers. *Am J Surg Pathol* 2016;40(8):1109–16. <https://doi.org/10.1097/PAS.0000000000000671>.
- [35] Boissiere-Michot F, Jacot W, Massol O, Mollevi C, Lazennec G. CXCR2 levels correlate with immune infiltration and a better prognosis of triple-negative breast cancers. *Cancers (Basel)* 2021;13(10):2328. <https://doi.org/10.3390/cancers13102328>.
- [36] Dusenbery AC, Maniaci JL, Hillerson ND, Dill EA, Bullock TN, Mills AM. MHC class I loss in triple-negative breast cancer: a potential barrier to PD-1/PD-L1 checkpoint inhibitors. *Am J Surg Pathol* 2021;45(5):701–7. <https://doi.org/10.1097/PAS.0000000000001653>.
- [37] Stanton SE, Adams S, Disis ML. Variation in the incidence and magnitude of tumor-infiltrating lymphocytes in breast cancer subtypes: a systematic review. *JAMA Oncol* 2016;2(10):1354–60. <https://doi.org/10.1001/jamaoncol.2016.1061>.
- [38] Loi S, Drubay D, Adams S, Pruneri G, Francis PA, Lacroix-Triki M, et al. Tumor-infiltrating lymphocytes and prognosis: a pooled individual patient analysis of early-stage triple-negative breast cancers. *J Clin Oncol* 2019;37(7):559–69. <https://doi.org/10.1200/JCO.18.01010>.
- [39] Loi S, Salgado R, Adams S, Pruneri G, Francis PA, Lacroix-Triki M, et al. Tumor infiltrating lymphocyte stratification of prognostic staging of early-stage triple negative breast cancer. *NPJ Breast Cancer* 2022;8(1):3. <https://doi.org/10.1038/s41523-021-00362-1>.
- [40] Chowell D, Morris LGT, Grigg CM, Weber JK, Samstein RM, Makarov V, et al. Patient HLA class I genotype influences cancer response to checkpoint blockade immunotherapy. *Science* 2018;359(6375):582–7. <https://doi.org/10.1126/science.aao4572>.

Related articles published in BJBMS

1. Concordance of PD-L1 expression and CD8+ TIL intensity between NSCLC and synchronous brain metastases
Sebnem Batur et al., BJBMS, 2020
2. Prognostic value of aldehyde dehydrogenase 1 (ALDH1) in invasive breast carcinomas
Hale Demir et al., BJBMS, 2018
3. Apocrine carcinoma of the breast: A brief update on the molecular features and targetable biomarkers
Semir Vranic et al., BJBMS, 2017