

# European consensus-based interdisciplinary guideline for diagnosis and treatment of basal cell carcinoma - update 2023

---

**Peris, Ketty; Fagnoli, Maria Concetta; Kaufmann, Roland; Arenberger, Petr; Bastholt, Lars; Seguin, Nicole Basset; Bataille, Veronique; Brochez, Lieve; del Marmol, Veronique; Dummer, Reinhard; ...**

*Source / Izvornik:* **European Journal of Cancer, 2023, 192**

**Journal article, Published version**

**Rad u časopisu, Objavljena verzija rada (izdavačev PDF)**

<https://doi.org/10.1016/j.ejca.2023.113254>

*Permanent link / Trajna poveznica:* <https://um.nsk.hr/um:nbn:hr:105:040164>

*Rights / Prava:* [Attribution-NonCommercial-NoDerivatives 4.0 International/Imenovanje-Nekomercijalno-Bez prerada 4.0 međunarodna](#)

*Download date / Datum preuzimanja:* **2024-10-08**



*Repository / Repozitorij:*

[Dr Med - University of Zagreb School of Medicine Digital Repository](#)





## Original Research

# European consensus-based interdisciplinary guideline for diagnosis and treatment of basal cell carcinoma—update 2023



Ketty Peris <sup>a,b,\*,1</sup>, Maria Concetta Fargnoli <sup>c,1</sup>, Roland Kaufmann <sup>d</sup>, Petr Arenberger <sup>e</sup>, Lars Bastholt <sup>f</sup>, Nicole Basset Seguin <sup>g</sup>, Veronique Bataille <sup>h</sup>, Lieve Brochez <sup>i</sup>, Veronique del Marmol <sup>j</sup>, Reinhard Dummer <sup>k</sup>, Ana-Marie Forsea <sup>l</sup>, Caroline Gaudy-Marqueste <sup>m</sup>, Catherine A. Harwood <sup>n</sup>, Axel Hauschild <sup>o</sup>, Christoph Höller <sup>p</sup>, Lidija Kandolf <sup>q</sup>, Nicole W.J. Kellerners-Smeets <sup>r,s</sup>, Aimilios Lallas <sup>t</sup>, Ulrike Leiter <sup>u</sup>, Josep Malvehy <sup>v</sup>, Branka Marinović <sup>w</sup>, Zeljko Mijuskovic <sup>q</sup>, David Moreno-Ramirez <sup>x</sup>, Eduardo Nagore <sup>y</sup>, Paul Nathan <sup>z</sup>, Alexander J. Stratigos <sup>aa</sup>, Eggert Stockfleth <sup>ab</sup>, Luca Tagliaferri <sup>ac</sup>, Myrto Trakatelli <sup>ad</sup>, Ricardo Vieira <sup>ae</sup>, Iris Zalaudek <sup>af</sup>, Claus Garbe <sup>u</sup>, On behalf of EADO<sup>A</sup>, EDF<sup>B</sup>, ESTRO<sup>C</sup>, UEMS<sup>D</sup> and EADV<sup>E</sup> 2

<sup>a</sup> *Institute of Dermatology, Catholic University of the Sacred Heart, Rome, Italy*

<sup>b</sup> *Fondazione Policlinico Universitario A. Gemelli, IRCCS, Rome, Italy*

<sup>c</sup> *Department of Biotechnological and Applied Clinical Sciences, University of L'Aquila, L'Aquila, Italy*

<sup>d</sup> *Department of Dermatology, Venereology and Allergology, University Hospital Frankfurt, Germany*

<sup>e</sup> *Department of Dermatovenereology, Third Faculty of Medicine, Charles University, Prague, Czech Republic*

<sup>f</sup> *Department of Oncology, Odense University Hospital, Denmark*

<sup>g</sup> *Dermatology Department, Saint-Louis Hospital, Paris, France*

<sup>h</sup> *Twin Research and Genetic Epidemiology Unit, School of Basic & Medical Biosciences, King's College London, London SE1 7EH, UK*

<sup>i</sup> *Department of Dermatology, University Hospital Ghent, Ghent, Belgium*

<sup>j</sup> *Department of Dermatology, Erasme Hospital, Université Libre de Bruxelles, Brussels, Belgium*

<sup>k</sup> *Department of Dermatology, University Hospital Zurich and University Zurich, Switzerland*

<sup>l</sup> *Department of Oncologic Dermatology, Elias University Hospital Bucharest, Carol Davila University of Medicine and Pharmacy Bucharest, Bucharest, Romania*

<sup>m</sup> *Aix-Marseille University, Dermatology and Skin Cancer Department, APHM, Marseille, France*

\* *Corresponding author: Department of Dermatology - Catholic University, Fondazione Policlinico Universitario A. Gemelli – IRCCS Rome, Largo Agostino Gemelli 8, 00168 Rome, Italy.*

*E-mail address: [ketty.peris@unicatt.it](mailto:ketty.peris@unicatt.it) (K. Peris).*

<sup>1</sup> *Contributed equally*

<sup>2</sup> *See members of “EADO<sup>A</sup>, EDF<sup>B</sup>, ESTRO<sup>C</sup>, UEMS<sup>D</sup> and EADV<sup>E</sup>” group in Appendix*

<https://doi.org/10.1016/j.ejca.2023.113254>

0959-8049/© 2023 The Author(s). Published by Elsevier Ltd. This is an open access article under the CC BY-NC-ND license (<http://creativecommons.org/licenses/by-nc-nd/4.0/>).

<sup>n</sup> Centre for Cell Biology and Cutaneous Research, Blizard Institute, Barts and the London School of Medicine and Dentistry, Queen Mary University of London, London, UK

<sup>o</sup> Department of Dermatology, University of Kiel, Kiel, Germany

<sup>p</sup> Department of Dermatology, Medical University of Vienna, Austria

<sup>q</sup> Department of Dermatology, Faculty of Medicine, Military Medical Academy, Belgrade, Serbia

<sup>r</sup> GROW-School for Oncology and Reproduction, Maastricht University, Maastricht, Netherlands

<sup>s</sup> Department of Dermatology, Maastricht University Medical Centre, Maastricht, Netherlands

<sup>t</sup> First Department of Dermatology, Aristotle University, Thessaloniki, Greece

<sup>u</sup> Centre for Dermatooncology, Department of Dermatology, Eberhard-Karls University, Tuebingen, Germany

<sup>v</sup> Department of Dermatology, Hospital Clinic de Barcelona (Melanoma Unit), University of Barcelona, IDIBAPS, Barcelona & CIBERER, Barcelona, Spain

<sup>w</sup> Department of Dermatology and Venereology, University Hospital Center Zagreb, Croatia

<sup>x</sup> Dermatology. Medicine School, University of Seville, University Hospital Virgen Macarena, Seville-Spain

<sup>y</sup> Department of Dermatology, Instituto Valenciano de Oncologia, Valencia, Spain

<sup>z</sup> Mount-Vernon Cancer Centre, Northwood, UK

<sup>aa</sup> First Department of Dermatology-Venereology, National and Kapodistrian University of Athens, School of Medicine, Andreas Sygros Hospital, Athens, Greece

<sup>ab</sup> Department of Dermatology, Skin Cancer Center, Ruhr-University Bochum, 44791 Bochum, Germany

<sup>ac</sup> Fondazione Policlinico Universitario A. Gemelli IRCCS, UOC di Radioterapia, Dipartimento di Scienze Radiologiche, Radioterapiche ed Ematologiche, Rome, Italy

<sup>ad</sup> Second Department of Dermatology, Aristotle University Medical School, Papageorgiou General Hospital, Thessaloniki, Greece

<sup>ae</sup> Coimbra Hospital and University Centre, Coimbra, Portugal

<sup>af</sup> Dermatology Clinic, University of Trieste, Trieste, Italy

Received 13 July 2023; Accepted 18 July 2023

Available online 28 July 2023

## KEYWORDS

Basal cell carcinoma;  
Guidelines;  
Classification;  
Surgical therapy;  
Topical therapy;  
Destructive therapy;  
Photodynamic therapy;  
Radiation therapy;  
Electrochemotherapy;  
Hedgehog inhibitors;  
Immunotherapy;  
Gorlin syndrome

**Abstract** Basal cell carcinoma (BCC) is the most common malignant tumour in white populations. Multidisciplinary experts from European Association of Dermato-Oncology (EADO), European Dermatology Forum, European Society for Radiotherapy and Oncology (ESTRO), Union Européenne des Médecins Spécialistes, and the European Academy of Dermatology and Venereology developed updated recommendations on diagnosis and treatment of BCC. BCCs were categorised into ‘easy-to-treat’ (common) and ‘difficult-to-treat’ according to the new EADO clinical classification. Diagnosis is based on clinico-dermatoscopic features, although histopathological confirmation is mandatory in equivocal lesions. The first-line treatment of BCC is complete surgery. Micrographically controlled surgery shall be offered in high-risk and recurrent BCC, and BCC located on critical anatomical sites. Topical therapies and destructive approaches can be considered in patients with low-risk superficial BCC. Photodynamic therapy is an effective treatment for superficial and low-risk nodular BCCs. Management of ‘difficult-to-treat’ BCCs should be discussed by a multidisciplinary tumour board. Hedgehog inhibitors (HHIs), vismodegib or sonidegib, should be offered to patients with locally advanced and metastatic BCC. Immunotherapy with anti-PD1 antibodies (cemiplimab) is a second-line treatment in patients with a progression of disease, contraindication, or intolerance to HHI therapy. Radiotherapy represents a valid alternative in patients who are not candidates for or decline surgery, especially elderly patients. Electrochemotherapy may be offered when surgery or radiotherapy is contraindicated. In Gorlin patients, regular skin examinations are required to diagnose and treat BCCs at an early stage. Long-term follow-up is recommended in patients with high-risk BCC, multiple BCCs, and Gorlin syndrome.

© 2023 The Author(s). Published by Elsevier Ltd. This is an open access article under the CC BY-NC-ND license (<http://creativecommons.org/licenses/by-nc-nd/4.0/>).

## 1. Information about the guidelines

### 1.1. Societies in charge

These guidelines were developed on behalf of the European Dermatology Forum (EDF), as decided at the

EDF meeting in January 2017. The European Association of Dermato-Oncology (EADO) coordinated the authors’ contributions within its Guideline Program in Oncology (GPO). The responsible editor is Claus Garbe (senior author) and the coordinator of the guideline is Ketty Peris (first author). In

order to guarantee the interdisciplinary character of these guidelines, they were developed in cooperation with the EDF), European Society for Radiotherapy and Oncology (ESTRO), Union Européenne des Médecins Spécialistes (UEMS), and European Academy of Dermatology and Venereology (EADV). Thirty-two experts from 13 countries, all of which were delegates of national and/or international medical societies, collaborated in the development of these guidelines.

### 1.2. Financing of these guidelines

The guidelines were supported by grants from the EADO for the guideline meetings. The authors did this work on a voluntary basis and did not receive any honorarium or reimbursement. Guidelines development group members stated their conflicts of interest in the relevant section.

### 1.3. Disclaimer

Medicine is subject to a continuous development process. This entails that all statements, especially regarding diagnostic and therapeutic procedures, can only reflect scientific knowledge current at the time of printing of these guidelines. Upmost care was applied with respect to stated therapeutic recommendations and selection as well as dosage of drugs. Nevertheless, users are prompted to use package inserts and expert information by the manufacturers as backup and, in case of doubt, consult a specialist. Pursuant to the public interest, questionable discrepancies shall be communicated to the GPO editors. The user remains responsible for all diagnostic and therapeutic applications, medications, and doses. Registered trademarks (protected product names) are not specified in these guidelines. From the absence of respective indications, it may thus not be inferred that product names are unprotected.

This work is protected by copyright in all its parts. Any utilisation outside the provision of the copyright act without the written permission by the GPO of the EADO is prohibited and punishable by law. No part of this work may be reproduced in any way without written permission by the GPO. This applies in particular to duplications, translations, microfilming, storage, application, and utilisation in electronic systems, intranets, and internet.

### 1.4. Scope

These guidelines were written to assist clinicians in diagnosis and treatment of basal cell carcinoma (BCC) patients. This update was initiated mainly due to the publication of a new clinical classification and implementation of novel advances in the diagnosis of BCC (non-invasive imaging techniques) and treatment (e.g. electrochemotherapy [ECT] and immunotherapy) of patients with difficult-to-treat BCC. The

use of these guidelines in the clinical routine should improve patient care.

### 1.5. Target population

The present guidelines contain recommendations regarding diagnosis, therapy, and follow-up of patients with BCC, addressing in detail all aspects of BCC management, from the common types of tumours to those which are 'difficult-to-treat' or 'advanced.'

### 1.6. Objectives

The guidelines are developed primarily for those clinicians who are caring for patients with BCC. A new classification system is introduced based on 'real-life' scenarios of complex cases rather than a simple 'stepwise' prognostic model like TNM, which is less easily applicable to BCC. Emphasis is given on the evolving field of non-invasive imaging techniques for BCC diagnosis and systemic therapy for advanced BCC, for example, targeted therapy and immunotherapy. Prevention issues are also briefly addressed.

### 1.7. Audience and period of validity

This set of guidelines will assist healthcare providers in managing their patients according to the current standards of care and evidence-based medicine. It is not intended to replace national guidelines accepted in their original country. These guidelines reflect the best-published data available at the time the report was prepared. Caution should be exercised in interpreting the data; results of future studies may modify conclusions or recommendations in this report. In addition, it may be necessary to deviate from these guidelines for individual patients or under special circumstances. Just as adherence to the guidelines may not constitute defence against a claim of negligence, deviation from them should not necessarily be deemed negligent. These guidelines will require updating approximately every 3 years (Expire date: December 2026) but advance in medical sciences may demand an earlier update.

### 1.8. Principles of methodology

The guidelines published here are an update of the existing European consensus-based (EDF/EADO/EORTC) interdisciplinary guidelines for the management of BCC (former version 2019) [1] and based on other up-to-date guidelines, including the National Comprehensive Cancer Network (NCCN) Clinical Practice Guidelines in Oncology for BCC (version 1.2023) (<https://www.nccn.org>) and the British Association of Dermatologists guidelines for the management of individuals with BCC 2021 [2]. *De novo* literature search was conducted by the authors by Medline search in English language publications with the last search date on

15th March 2023. The methodology of these updated guidelines was based on the standards of the AGREE II instrument [3]. Recommendations are based on the level of best-quality available evidence and good clinical practice (GCP).

The levels of evidence were graded according to the Oxford classification (Table 1). The grades of recommendation were classified as follows:

A: Strong recommendation. Syntax: ‘shall.’

B: Recommendation. Syntax: ‘should.’

C: Weak recommendation. Syntax: ‘may/can.’

X: Should not be recommended.

0: Recommendation pending. Currently not available or not sufficient evidence to make a recommendation in favour or against.

Expert consensus was provided wherever adequate evidence is not available.

### 1.9. Consensus-building process

The consensus-building process was conducted as follows: in a first round, medical expert who participated in their national guidelines development processes was involved in producing an initial draft. In a second round, the selected experts from different specialties and different scientific societies (EADO, EDF, ESTRO, UEMS, EADV) contributed to these guidelines. A consensus meeting was held in Rome, Italy, on 25th November 2022, with final outcomes: (1) the approval of the text and (2) a consensus rate of agreement of at least 80%, for recommendations provided in structured boxes and the algorithm. Voting of the recommendations included the selection of ‘Agree,’ ‘Disagree,’ or ‘Abstention’ vote, and the possibility of providing comments. Thirty-two experts were present in the consensus meeting. The finalisation of the draught and recommendations was conducted among all coauthors through emailing in April 2023.

## 2. Definition

BCC, a skin carcinoma derived from epidermal cells, is the most frequent malignant tumour in humans. Named for the optical similarity in appearance between the cells at the periphery of tumour islets to the cells of the basal layer of the epidermis, BCC is nowadays thought to arise from stem cells of the hair follicle [4–6]. It typically arises on sun-exposed sites of fair-skinned individuals with the head and neck region being the most common localisation. As chronic sun exposure is the most important carcinogen, the incidence of BCC is higher in elderly patients with a peak at around 80 years of age [7–9]. BCC most commonly presents as a slow growing, skin-coloured nodule with a pearly shiny appearance and arborising vessels visible on the tumour surface upon clinical or dermatoscopic inspection, with larger tumours showing central ulceration. Superficial BCC (sBCC) is another frequent subtype, mainly related to intermittent sun exposure and preferentially located on

the trunk. Variants of BCC may present as pigmented tumours or sclerosing lesions in the presence of a more extensive stromal component. BCC has a very low propensity to metastasise with fewer than 1% of patients being affected, but it can progress to large, locally advanced, and often deeply infiltrating tumours if not early detected, mismanaged, or neglected [10,11].

## 3. Epidemiology

BCC accounts for about 75% of all keratinocyte cancers. The average lifetime risk for white-skinned individuals to develop BCC is approximately 30% [10]. The epidemiology of BCC is difficult to describe accurately as routine recording of BCC is often not performed by cancer registries, and not all BCC cases are sent for histopathological diagnosis [12]. In addition, because most cancer registries record only the first histopathologically confirmed BCC per patient, the true incidence of BCC may be significantly underestimated [13]. The increasing incidence of BCC has been reported in many countries all over the world as a result of changed sun-exposure behaviours and a general ageing population. There are large regional variations in reported incidence rates of BCC due to the geographic location (latitude) of the study population, study period, and methods for registering BCC [14]. The highest incidence has been reported in Australia, followed by the United States (US) and Europe [15]. In Northern European countries, BCC incidence has been shown to increase with age, with a more pronounced increase for women compared to men. Furthermore, a relatively higher incidence increase of BCC has been observed in young individuals compared to old individuals over time, especially for women [15,16]. In a recent analysis of the Swedish national registry (data from 2004 to 2017), the age-standardised person-based incidence rose from 308 per 100,000 in 2004 to 405 per 100,000 in 2017 [17]. In addition, aggressive BCC subtypes appear to be increasing faster than other subtypes [17]. A study on the incidence and trends of first and multiple BCCs in The Netherlands reported a decrease in annual incidences of 3.6% for males and 3.0% for females aged 30–39 years [18]. For patients aged ≥50 years, an ever-increasing trend was found. Over the next 10 years, the incidence of BCC is expected to increase by 30–4% (males) and 25–3% (females). In a qualitative systematic review, no significant difference in risk for all-cause mortality has been reported in patients with a history of BCC [19]. Patients diagnosed with a first BCC have a remarkable increased risk of developing a second BCC and, less frequently, a squamous cell carcinoma (SCC) or melanoma. This elevated risk may vary geographically [20,21].

A very small percentage of patients with BCC develop high-frequency BCC (HF-BCC) without associated



Table 1  
Oxford levels of evidence.

Question	Step 1 (Level 1 <sup>a</sup> )	Step 2 (Level 2 <sup>a</sup> )	Step 3 (Level 3 <sup>a</sup> )	Step 4 (Level 4 <sup>a</sup> )	Step 5 (Level 5)
<b>How common is the problem?</b>	Local and current surveys (or censuses)	Systematic review of surveys that allow matching to local circumstances <sup>b</sup>	Local non-random sample <sup>b</sup>	Case series <sup>b</sup>	n/a
<b>Is this diagnostic or monitoring test accurate? (Diagnosis)</b>	Systematic review of cross-sectional studies with consistently applied reference standard and blinding	Individual cross-sectional studies with the consistently applied reference standard and blinding	Non-consecutive studies or studies without consistently applied standards <sup>b</sup>	Case-control studies or 'poor or non-independent reference standard' <sup>b</sup>	Mechanism-based reasoning
<b>What will happen if we do not add a therapy? (Prognosis)</b>	Systematic review of inception cohort studies	Inception cohort studies	Cohort study or control arm of randomised trial <sup>a</sup>	Case-series or case-control studies, or poor quality prognostic cohort study <sup>b</sup>	n/a
<b>Does this intervention help? (Treatment benefits)</b>	Systematic review of randomised trials or <i>n</i> -of-1 trials	Randomised trial or observational study with dramatic effect	Non-randomised controlled cohort/follow-up study <sup>b</sup>	Case-series, case-control studies, or historically controlled studies <sup>b</sup>	Mechanism-based reasoning
<b>What are the COMMON harms? (Treatment harms)</b>	Systematic review of randomised trials, systematic review of nested case-control studies, <i>n</i> -of-1 trial with the patient you are raising the question about, or observational study with dramatic effect	Individual randomised trial or (exceptionally) observational study with dramatic effect	Non-randomised controlled cohort/follow-up study (postmarketing surveillance) provided there are sufficient numbers to rule out a common harm. (For long-term harms, the duration of follow-up must be sufficient) <sup>b</sup>	Case-series, case-control, or historically controlled studies <sup>b</sup>	Mechanism-based reasoning
<b>What are the RARE harms? (Treatment harms)</b>	Systematic review of randomised trials or <i>n</i> -of-1 trial	Randomised trial or (exceptionally) observational study with dramatic effect			
<b>Is this (early detection) test worthwhile? (Screening)</b>	Systematic review of randomised trials	Randomised trial	Non-randomised controlled cohort/follow-up study <sup>b</sup>	Case-series, case-control, or historically controlled studies <sup>b</sup>	Mechanism-based reasoning

Oxford Centre for Evidence-Based Medicine 2011 Levels of Evidence.

<sup>a</sup> Level may be graded down based on study quality, imprecision, indirectness (study PICO does not match questions PICO), because of inconsistency between studies, or because the absolute effect size is very small; level may be graded up if there is a large or very large effect size.

<sup>b</sup> As always, a systematic review is generally better than an individual study.

germline mutations and clinical phenotype of genetic syndromes. HF-BCC has been defined as  $\geq 9$  BCCs diagnosed over a 3-year period and associated with male sex and a history of SCC and melanoma. Patients with HF-BCC also have an increased risk of lymphoma, leukaemia, breast, and colon cancer [22–24].

Advanced BCC includes locally advanced BCC (laBCC) and metastatic BCC (mBCC). A retrospective US cohort study reported that laBCC accounts for 0.8% of all BCC cases (age-adjusted incidence rate: 1.83 per 100,000 persons, which is projected to 4399 cases in the US population). Rates of aBCC were highest for patients older than 65 years and for males [25]. Histologically confirmed mBCCs are extremely rare, with an estimated incidence of 0.0028–0.55% [26]. In a retrospective analysis of a tertiary referral centre, 0.6% of BCCs were classified as severe, including BCC inappropriate for surgery or radiotherapy, mBCC, or BCC requiring extensive treatment [27]. However, the real incidence, prevalence, and mortality of mBCC are still underestimated since staging examinations were not routinely performed in the past and registers of advanced BCC have been recently introduced.

#### 4. Aetiology and genetics

Different hypotheses have been formulated on the cell of origin of BCC. Whereas most BCCs seem to arise from stem cells of the hair follicle [5,6], some authors contend that BCC stem cells are located in the interfollicular epidermis and infundibulum and not in the hair bulge [4]. It has been suggested that, depending on the carcinogenic agent involved, different stem cell compartments may be targeted and subsequently give rise to BCC. Notably, BCC cell lines have not been easily developed, suggesting that their isolation and proliferation require unidentified environmental or cellular factors.

The main carcinogenic factor is ultraviolet light (UV), which explains why most tumours are located on sun-exposed sites. Indeed, BCC is one of the most highly mutated human tumours (i.e. tumour mutational burden [TMB] is 65 mutations/megabases, compared with 14 mutations/megabases for melanoma) [28,29] and harbours a large percentage of UV-induced mutations (C:T or CC:TT transitions at dipyrimidine sites) [30]. In addition, indoor tanning (sunbeds, solarium) has been associated with a higher risk of skin cancers including BCC, with a dose-response relationship [31–33]. Other causal environmental carcinogens include ionising radiation and arsenic. Light pigmentary characteristics (fair skin colour, red hair, blue eyes), increasing age, immunodeficiency (including iatrogenic immunosuppression, HIV, and haematological malignancies) are also important aetiological factors. *MC1R* gene variants have been shown to modulate pigmentation characteristics and to be associated with a higher risk of developing sporadic BCC, with an OR (95% confidence interval [CI]) of 1.39 (1.15–1.69) [34].

BCCs are usually sporadic tumours and, at the genetic level, the main pathogenetic driver is the activation of the Hedgehog (Hh) pathway with inactivating mutations of *PTCH1* on chromosome 9q22.3 identified in about 90% of sporadic BCCs and activating mutations of *SMO* in approximately 10%. Alterations of the Hh pathway are also found in other Hh-dependent tumours such as medulloblastoma and neuroblastoma [35]. All of these tumours may develop in patients with Gorlin syndrome, a rare genetic disorder predisposing to multiple BCCs, due to germline mutations in *PTCH1* and, less frequently, in *PTCH2*, *SMO*, and *SUFU*. A small percentage of BCCs have no mutations in the Hh pathway. Other driver mutations have also been found in cancer-related genes such as *MYCN*, *PPP6C*, *STK19*, *LATS1*, *ERBB2*, *PIK23C*, *N-RAS*, *K-RAS*, and *H-RAS*, and loss of function of *PTPN14*, *RBI*, and *FBXW7*. Mutations in the *P53* gene are frequently observed [30]. However, to date, no genetic profile has been associated with a specific histopathological subtype. Changes in the Hippo pathway are also implicated in BCC development, including upregulation of the transcriptional activators YAP1 and Taz [36].

Genetic changes may underlie the resistance of a subset of patients to Hedgehog inhibitors (HHIs). Primary resistance of BCCs may occur by the activation of non-canonical Hh pathways or signalling through additional pathways. Recently, it has been reported that HHI primary resistant BCCs share molecular abnormalities common to secondary resistant tumours (mutations in *SMO* and *MYCN*), are highly rearranged, and have activation of the Hippo-Yap and WNT pathways [37]. Secondary HHI resistance is explained by mutations in *SMO* either impairing drug binding or activating *SMO* at different levels. In addition, copy number changes in *SUFU* and *Gli2* have been observed in secondary resistant tumours [28,29].

BCC is also characterised by a low immunogenicity due to the downregulation of proteins involved in antigen modification and presentation, such as transporters associated with antigen processing-1 (*TAP-1*) and major histocompatibility complex I (*MHC-I*), and to diminished infiltration by CD4<sup>+</sup> and CD8<sup>+</sup> T-cells with an increased presence of regulatory T-cells (T-regs), and immunosuppressive effects driven by *IL-10* and *Th2 cytokines* [38,39].

In addition to Gorlin syndrome, other genetic diseases also predispose to the development of BCC (Table 2). Among these, *xeroderma pigmentosum* is due to germline mutations in DNA nucleotide excision repair genes [40]. Patients develop multiple tumours, including BCC and also melanoma and cutaneous SCC, often at an early age. Bazex–Dupré–Christol syndrome is an X-linked dominant genodermatosis characterised by follicular atrophoderma, congenital hypotrichosis, hypohidrosis, facial milia, and multiple BCCs [41] and is associated with small tandem noncoding intergenic

Table 2  
Most frequent genodermatoses with the occurrence of BCC.

Genodermatosis	Affected gene	Transmission mode	Main characteristics
<i>Xeroderma pigmentosum</i>	DNA repair genes	Recessive	Multiple skin tumours (BCC, cSCC, melanoma, others); precancerous lesions; freckles and hypopigmented macules on sun-exposed areas; neurological defects
Gorlin syndrome	<i>PTCH, SMO, SUFU</i>	Dominant	Multiple BCCs; odontogenic keratocysts; palmo-plantar pits; skeletal abnormalities; other developmental defects
Bazex–Dupré–Christol syndrome	X-linked dysregulation of <i>ARHGAP36</i>	Dominant	Multiple BCCs; follicular atrophoderma; congenital hypotrichosis; hypohidrosis; facial milia
Oculocutaneous albinism	<i>TYR, OCA2</i>	Recessive	Multiple skin tumours including BCC; albinism; nystagmus; strabismus; diminished visual acuity.
Muir–Torre syndrome	Mismatch repair genes ( <i>MLH1, MSH2, MSH6</i> )	Dominant	Sebaceous gland neoplasms; keratoacanthomas; cSCC and BCC; one or more visceral malignancies, particularly gastrointestinal or genito-urinary.

BCC, basal cell carcinoma; cSCC, cutaneous squamous cell carcinoma.

duplications at chromosome Xq26.1, which are likely to dysregulate *ARHGAP36* [42]. Oley syndrome, a possible X-linked variant of Bazex–Dupré–Christol syndrome, and Rombo syndrome, with an uncertain genetic basis, are further rare genodermatoses associated with BCC [43]. BCCs may develop in other genodermatoses, including disorders of melanin biosynthesis (oculocutaneous albinism and Hermansky–Pudlak syndrome), DNA replication/repair (Bloom, Werner, Rothmund–Thomson, and Muir–Torre syndromes), immune response (cartilage-hair hypoplasia and epidermodysplasia verruciformis), and genodermatoses affecting the folliculosebaceous structures (Cowden and Schöpf–Schulz–Passarge).

### 5. New EADO classification and staging: common and difficult-to-treat BCC

The natural history of a BCC is usually that of a slow-growing skin cancer starting from a tiny papule, growing for years without any aggressiveness into a nodule or a plaque, sometimes ulcerated, leaving time to be diagnosed and managed correctly.

A few clinical forms of common BCC, such as superficial, nodular, morpheic, and ulcerated (ulcus rodens), are recognised. However, common BCCs are highly polymorphic and sometimes difficult to classify into one of these subtypes. BCCs should not be mistakenly regarded as ‘indolent cancers,’ a reputation which they deserve only when they are treated early and adequately. Destructive growth and invasion of surrounding tissues usually occur while the rate of metastasis is very low. If BCC lesions are not treated for years or relapse several times after surgery, they become progressively ‘locally advanced.’ ‘Advanced’ BCC is a term that was introduced when patients who were not candidates for surgery and radiotherapy were sought for studies with targeted HHIs. Although not clearly defined, the word ‘advanced’ usually implies that (1) there has been a long history without treatment and/or repeated failures of

treatments or recurrences, (2) there is extensive tissue destruction in the surrounding anatomical area, and (3) it has become difficult or impossible to cure the tumour with standard surgery (unresectable) or radiotherapy.

We recently introduced a more pragmatic and operational classification for BCC into ‘easy-to-treat’ BCC, which includes the most common BCC, and ‘difficult-to-treat’ BCC [44,45]. More than 90% of BCCs are easy to treat through standard surgery or a range of alternative blind treatments during the initial months or years after diagnosis. Difficult-to-treat BCCs include ‘all laBCCs’ and common BCCs which, for any reason, pose specific management difficulties. These reasons may be (1) the technical difficulty of maintaining function and aesthetics due to the size or location (eyes, nose, lips, and ears) of the tumour; (2) the poorly defined borders often associated with morpheic subtype or recurrence; (3) multiple recurrences on the face (often requiring much larger excision); (4) prior radiotherapy; (5) patient’s reluctance to accept the consequences of surgery; and (6) patient’s comorbidities interfering with surgery. Difficult-to-treat BCCs are quite heterogeneous with increasing difficulty of treatment and increasing risk of recurrence. The five-group EADO classification describes five different practical patterns, namely (1) common BCCs which are difficult to treat for any reason linked to the tumour (e.g. location requiring technical skills, poorly defined borders, prior recurrence) and/or to the patient (poor general status, comorbidities, unwillingness to cooperate); (2) BCCs difficult to treat because of the number of lesions; (3) large and/or destructive tumours out of critical areas; (4) large and/or destructive tumours in critical or functionally significant areas (nose, periorificial) and (5) giant and/or deeply invasive tumours involving extracutaneous tissue [44,45] (Fig. 1).

Regarding staging, BCCs do not follow the three-step process, that is, tumour, nodal involvement, and distant metastases, making the TNM classification irrelevant.








Risk	Stage	Characteristics	Illustrative pictures	DTT-BCC Group (part 1)
Easy To Treat and low risk of recurrence	I	Low-risk common BCC  None of the other stages characteristics. <i>Recurrences only come from blind treatments, or insufficient surgical margins.</i>		Not included
	Common BCC	IIA	Common BCC but management is more complex than usual for any reason linked to the tumor (location requiring technical skill, poorly defined tumor borders, prior recurrence) and/or to the patient (poor general status, comorbidities, or unwillingness to cooperate ...).  <i>Good results and low rate of recurrence expected with surgery even if technically complicate, when the patient cooperates.</i>	
IIB		DTT-BCC mainly due to multiplicity of common BCC  Very high number of common BCC (>10) or multiple complex BCC (> 5) in the setting of apparently sporadic cases or in Gorlin syndrome*.  *When at least 1 of the multiple BCC can be classified III or IV, the patient will be classified accordingly, and not IIB		2
Advanced BCC		IIIA	Locally advanced DTT-BCC out of critical areas  Large and/or destructive tumors in non-critical or functionally significant areas.  <i>Deemed curable without expected functional mutilations.</i>	
	IIIB	Locally advanced DTT-BCC in critical areas  Large and/or destructive tumors in critical or functionally important areas (periorificial, nose, ...).  <i>Deemed curable by surgery, but functional impairment and/or mutilation are inevitable.</i>		4
	IIIC	Extremely advanced DTT- BCC  Giant and/or deeply invasive tumors involving extracutaneous tissue (bone, muscles, vital or sensorial structures) responsible for an extreme clinical situation.  <i>Cure cannot be expected by surgery whatever its extent.</i>		5
Metastatic BCC	IV	Distant metastases*.  *Whatever the initial BCC staging, patient must be classified IV when metastatic.		Not included

Fig. 1. EADO classification and staging for BCC. BCC, basal cell carcinoma; EADO, European Association of Dermato-Oncology. DDT, difficult-to-treat

The five patterns of clinical situations were used as a basis to generate a four-stage classification covering the whole spectrum of BCCs, from the common easy-to-treat tumours up to the very rare metastatic cases (Fig. 1) [45]. EADO-stage I includes most of the BCCs, which are easy-to-treat and low risk. EADO-stage II comprises common BCC considered difficult-to-treat for any reasons linked to the patient or tumour (stage IIA) and BCCs considered difficult-to-treat because of their number (stage IIB). Stage III encompasses large and destructive tumours out of (stage IIIA) or on (stage IIIB) critical/functional areas and extremely destructive tumours (stage IIIC). Finally, stage IV refers to mBCCs. The prognostic value of this classification has not been demonstrated and will have to be assessed prospectively, bearing in mind that progression-free survival or overall survival curves are not meaningful for these tumours, which are not measurable by response evaluation criteria in solid tumours (RECIST) criteria, and can destroy large anatomic areas without affecting survival.

### 5.1. Definition of low- and high-risk BCC

BCC can also be classified according to the risk of recurrence into low and high risk (2, <https://www.nccn.org>). All difficult-to-treat BCCs are at high risk of recurrence mainly because of difficulty in the management

that often leads to compromise with regard to ideal treatment and recommended safety margins of excision. Most easy-to-treat BCCs are at low risk of recurrence. However, some apparently easy-to-treat BCCs may still be at risk of recurrences such as those located on the H area of the face, those with aggressive histological characteristics (perineural and/or perivascular involvement), and those in immunosuppressed patients. All BCCs managed by ablative procedures without histopathological control instead of surgical excision could be considered at high risk of recurrence. It must however be mentioned that not all recurrences have the same implications. A recurrence of an invasive BCC on the eyelids, nose, lips, and ears significantly increases the risk of deleterious consequences, whereas a recurrence of an sBCC on the back will be easily managed.

## 6. Diagnosis

### 6.1. Clinical and dermatoscopic diagnosis

BCC most commonly clinically occurs as a pink/reddish, pearly, or translucent papule, plaque, or nodule with arborising vessels visible on the tumour surface and may appear pigmented exhibiting a brown, black, or bluish colouration. It has a slow progressive course, and, in time, central ulceration may occur. In the case of

infiltrative or morpheic BCCs, they may resemble a flat or atrophic scar-like lesion. In a systematic review of studies on BCC diagnosis, naked eye examination had a sensitivity of 66.9% and specificity of 97.2% that increased to 85.0% and 98.2%, respectively, with the addition of dermatoscopy. The pooled sensitivity and specificity of dermatoscopy for the diagnosis of BCC were 91.2% and 95.0%, respectively, and were higher for pigmented than non-pigmented BCC. Sensitivity increased when dermatoscopy was performed by experts and when the diagnosis was based on in-person dermatoscopy as opposed to dermatoscopic photographs [46]. The main value of dermatoscopy is in the differential diagnosis of BCC with melanoma, SCC including Bowen's disease, and benign tumours. However, the BCC subtype has to be assessed histopathologically in equivocal lesions [47].

Dermatoscopic criteria for BCC are branching and linear vessels (arborising and superficial telangiectasias), multiple erosions, ulceration, bluish-grey clods of variable size (ovoid nests, globules, and focused dots), radial lines connected to a common base (leaf-like areas), radial lines converging to a central dot or clod (spoke-wheel areas), clods within a clod (concentric structures), and structureless white areas (porcelain structures, white crossing lines, or white clods (Fig. 2, Table 3) [48]. Recently, multiple aggregated yellow-white globules have been described as a new diagnostic dermatoscopic feature of BCC particularly in high-risk subtypes on the head and neck [49]. It has been shown that individuals with multiple BCCs will exhibit a prevailing signature pattern among their tumours [50]. In a systematic review analysing 31 studies including 5950 BCCs, the most common dermatoscopic features detected in BCC were arborising vessels (59%), shiny white structures (49%), and large blue-grey ovoid nests (34%). However, the frequency of these criteria depends on the subtype [51].

The nodular subtype of BCC presents clinically as a reddish to skin-coloured, sometimes translucent papule, nodule, or plaque, most commonly located on the head/neck area. The most striking dermatoscopic features are branching, focused vessels (arborising vessels, consisting of focused, bright red large stem vessels with multiple fine ramifications) [48,52]. In pigmented tumours, bluish-grey clods of variable size are also commonly observed.

sBCC presents as scaly erythematous patch or plaque that usually is well demarcated and is typically located on the trunk and lower extremities. Often, multiple lesions are present. Dermatoscopically, it exhibits white to pinkish-red structureless areas, multiple small erosions and, if any, small focused linear vessels mainly at the border [53]. In pigmented lesions, the presence of radial lobules connected to a common base (leaf-like areas), radial lines converging to a central dot or clod (spoke-wheel areas), and clods within a clod (concentric structure) facilitate the diagnosis. Using polarised

dermatoscopy, the presence of short white lines (chrysalis structures) represents an additional feature for the diagnosis of sBCC [46]. Importantly, the presence of bluish-grey clods and branching linear vessels are negative predictors for the diagnosis of sBCC [54].

Morpheic BCC presents as a reddish plaque or a scar-like area with ill-defined borders. Upon dermatoscopy, white structureless areas and fine arborising vessels are the most common structures. Ulceration is usually not present [55].

Basosquamous carcinoma typically appears as an ulcerated, facial nodule or plaque in elderly males with photodamaged skin [56]. Dermatoscopically, these tumours may exhibit overlapping features of both BCC and invasive SCC, including unfocused (peripheral) arborising vessels, keratin masses, white structureless areas, superficial scales, ulceration or blood crusts, blue-grey blotches, and blood spots in keratin masses [57].

Clinical diagnosis confirmed on dermatoscopy without histopathological examination is acceptable for the small nodular subtype on typical locations such as the head/neck or trunk, for the superficial subtypes located on the trunk and extremities, and for multiple BCCs in Gorlin syndrome. However, in cases of suspicious lesions on the face or when the tumour exhibits features associated with aggressive forms, biopsy and histopathology are recommended. In addition to clinical diagnosis, dermatoscopy has also been found to be a useful tool in the preoperative prediction of the BCC subtype and in the non-invasive assessment of tumour response to topical treatments [54,58,59].

## 6.2. Other non-invasive imaging techniques

Additional non-invasive skin-imaging tools that have been shown to be of high diagnostic value in dermatoscopically equivocal tumours are reflectance confocal microscopy (RCM), optical coherence tomography (OCT), and line-field confocal (LC)-OCT, which are often only accessible in specialised skin cancer centres [60–62]. RCM allows the recognition of BCC in equivocal lesions with a high sensitivity and specificity [63]. In a meta-analysis, RCM showed a sensitivity estimate of 0.97 (95% CI, 0.90–0.99) and a specificity estimate of 0.93 (95% CI, 0.88–0.96) for BCC diagnosis [64]. A recent prospective, randomised multicentre study showed non-inferiority of *in vivo* RCM for diagnosing and subtyping BCC before surgery versus standard care (planned excision based on the histopathological diagnosis and subtype of a punch biopsy) for surgical treatment in patients with clinically suspected BCC [65]. RCM has been used to monitor the response to non-surgical treatments in sBCC and in multiple BCCs in the context of genodermatosis [66,67].

OCT has unique advantages such as margin detection (deep and lateral), speed, and large field of

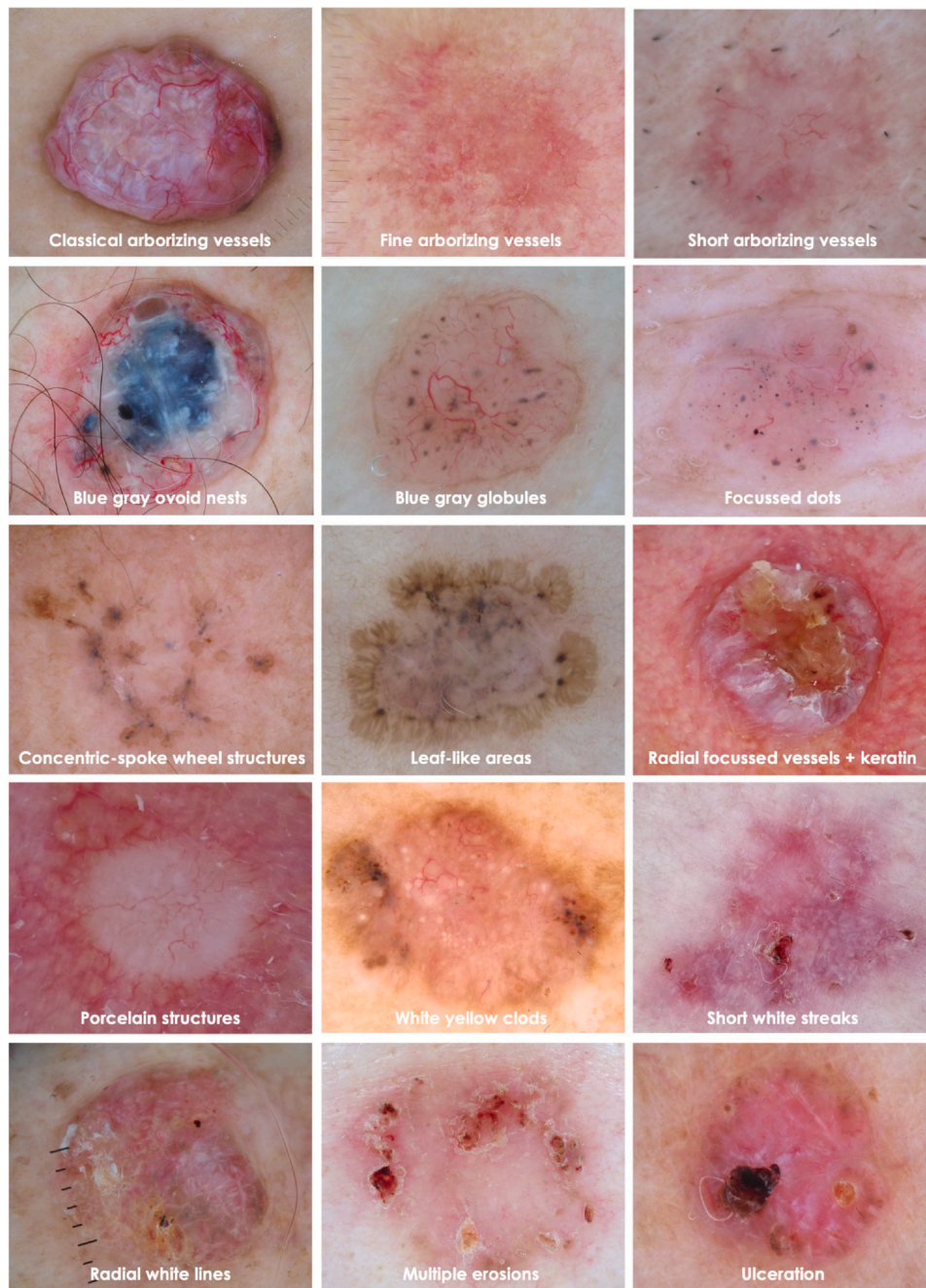


Fig. 2. Dermatoscopic criteria of BCC.

view. It may enable streamlined management in selected cases of BCC and better selection of treatment modalities (surgical versus non-surgical) [68]. In a meta-analysis, it was shown that OCT improves the sensitivity and specificity when compared with visual inspection plus dermatoscopy in clinically challenging lesions [69]. In a multicentre prospective study, OCT allowed discrimination of sBCC from non-sBCC and non-BCC lesions with a detection rate of 97.8% for BCC. Subtyping without the need for biopsy was possible in 44% of the patients with a predictive value for the diagnosis of sBCC of 84.3% versus 98.8% for non-sBCC [70]. In addition, OCT-guided diagnosis

was shown to be non-inferior to regular punch biopsy for the diagnosis of BCC in a multicentre randomised trial [71]. The combination of RCM and OCT (LC-OCT) may enable accurate diagnosis and depth assessment in lesions clinically suggestive of BCC, identification of key histopathological features of infiltrative BCC, and presurgical evaluation aiding in the assessment of margins and tumour depth before Mohs micrographic surgery [72–74]. LC-OCT combines the advantages of RCM with cellular resolution to 400  $\mu\text{m}$  of depth and those of OCT such as 3-D imaging of the tissue with vertical and horizontal sections. In recent retrospective studies, it was



Table 3  
Description and significance of dermatoscopic criteria for the diagnosis of BCC.

Criterion	Description	Significance
Classical arborising vessels	Large diameter focused vessels with multiple branching ramification	Nodular
Fine arborising vessels	Small diameter focused vessels with few branches	Infiltrative
Short arborising vessels	Small focused vessels	Superficial
Large ovoid nests	Well-circumscribed large oval structures not intimately connected	Nodular-infiltrative
Blue–grey globules	Islands of small circumscribed oval structures	Nodular-infiltrative
Focused dots	Small focused pinpoint dots	Nodular-infiltrative
Concentric structures	Small concentric oval structures with a inner grey and outer translucent rim	Superficial
Spoke-wheel structures	Radial brown fingerlike projections arising from a grey ovoid centre	Superficial
Leaf-like areas	Radial brown fingerlike projections that do not arise from a pigmented centre	Superficial
Yellow globules	Round yellow-to-white structures	Nodular-infiltrative
Porcelain white structures	White structureless areas	Infiltrative
Radial white lines	Radial white lines	Pinkus
Shiny white structure	Short white crossing lines	Superficial
Multiple erosions	Multiple small yellow-to-brown clods	Superficial
Ulceration	Usually centrally located haemorrhagic, brown–black clods	Nodular

### Box 1 Clinical diagnosis.

Clinical diagnosis	Evidence-based recommendation
Grade of recommendation C	Superficial and nodular BCCs can be diagnosed based on clinical examination with the assistance of non-invasive techniques, without the need for histological confirmation
Level of evidence 3	[48,52–54] Strength of consensus: 100%
BCC, basal cell carcinoma.	

### Box 2 Non-invasive diagnostic procedures—Dermatoscopy.

Non-invasive diagnosis—Dermatoscopy	Evidence-based recommendation
Grade of recommendation A	Dermatoscopy improves the accuracy of clinical diagnosis of BCC
Level of evidence 1	[46,51] Strength of consensus: 100%
BCC, basal cell carcinoma.	

### Box 3 Non-invasive diagnosis—Other techniques.

Non-invasive diagnosis—Other techniques	Evidence-based recommendation
Grade of recommendation A	Non-invasive imaging with reflectance confocal microscopy and/or optical coherence tomography shall be used, when available, to improve the diagnostic accuracy in difficult to recognize BCCs
Level of evidence 1	[62–64,68–70] Strength of consensus: 100%
BCC, basal cell carcinoma.	

reported a good agreement between LC-OCT and histopathology in the preoperative assessment of different BCC subtypes and the usefulness in monitoring imiquimod treatment of sBCCs [75–78].

### 6.3. Histopathological diagnosis

Histopathological examination is always mandatory in equivocal lesions and in any ulcerated or large tumour



**Box 4** Histopathological diagnosis.

Histopathological diagnosis	Evidence-based recommendation
Grade of recommendation B	Histopathological confirmation is mandatory in equivocal lesions, in ulcerated or large tumours, and in BCCs located in high-risk areas
Level of evidence 3	[47] Strength of consensus: 100%

BCC, basal cell carcinoma.

for which the diagnosis is uncertain. Furthermore, high-risk BCCs require histopathological diagnosis to assess the surgical margins. Multiple biopsies are recommended in laBCC to confirm the histopathological subtype. In the case of low-risk subtypes, non-invasive imaging techniques may be sufficient to confirm the diagnosis, especially when the tumour is scheduled for topical or destructive treatments. Incisional biopsy is indicated to confirm recurrences after surgery or destructive or topical treatments in low-risk subtypes.

Histopathological subtypes of BCC stratified by the risk of recurrence described in the current WHO classification include [79] (1) lower risk: nodular, superficial, pigmented, infundibulocystic (a variant of BCC with adnexal differentiation), fibroepithelial; (2) higher risk: basosquamous carcinoma, sclerosing/morpheic, infiltrating, BCC with sarcomatoid differentiation, micronodular. Mixed forms of these subtypes are frequently found as well as collision tumours with SCC. Differential diagnosis with SCC can be difficult: immunohistochemical markers such as the Ber-EP4 antibody (marker for BCC) and the epithelial membrane antigen (EMA, marker for SCC) are very helpful. This applies in particular to the assessment of excision margins in micrographic surgery and the differentiation between benign follicular hyperplasia and parts of BCCs. A recent position paper of experts proposed a simplified histopathological classification unifying sclerosing, infiltrating, and micronodular BCCs into a single ‘infiltrative’ BCC subtype [80].

The histopathological report should include subtype, lateral and deep margin status, presence or absence of perineural invasion, and angiolymphatic invasion.

## 7. Staging work up

On clinical presentation, a detailed medical history should be collected and physical examination, with an emphasis on complete skin examination, be performed. Total body skin examination is recommended because patients with BCC have a high risk of developing additional skin tumours, both keratinocyte carcinomas and melanoma [81].

Imaging studies are not needed in patients with low-risk BCC. For advanced BCC, the imaging modality is chosen based on site and suspected extent of the disease (i.e. local, regional, metastatic) after a discussion in the multidisciplinary team. If soft-tissue involvement or perineural disease is suspected, magnetic resonance imaging (MRI) with contrast is preferred whereas, if bone disease is suspected, Computed tomography with or without contrast is preferred.

## 8. Management of common (easy-to-treat and difficult-to-treat) BCC

### 8.1. Surgery

Most primary BCCs can be easily treated by surgery or by non-surgical methods for certain subtypes. However, BCCs with a high risk of recurrence need to be treated more aggressively. The risk of recurrence mainly increases with tumour size, localisation on the facial H-zone, aggressive histopathological subtype, previous recurrences, or long-term immunosuppression. Certain tumours can be locally advanced with the destruction of adjacent tissues or difficult to treat for other reasons, which might need discussion in a multidisciplinary board regarding appropriate therapy. Fig. 3 illustrates the EADO treatment algorithm.

Surgical excision is a very effective treatment for primary BCC. Scalpel excision is performed using either a standard excision (2D) with safety margins or a micrographically controlled stepwise procedure (3D). Recurrence rates largely depend on excisional techniques and vary from < 1% to 8% at 5 years after surgery with best outcomes reported for micrographically controlled surgery [82–85].

Surgical removal by destructive (blind) treatments and non-surgical modalities (topical treatments or photodynamic therapy [PDT]) can be used for low-risk BCCs when surgery is contraindicated or impractical. However, a higher risk of treatment failure has been reported with destructive or non-surgical treatments as compared to surgical excision [86]. Histopathological examination of damaged tissue is not possible using topical or destructive treatment

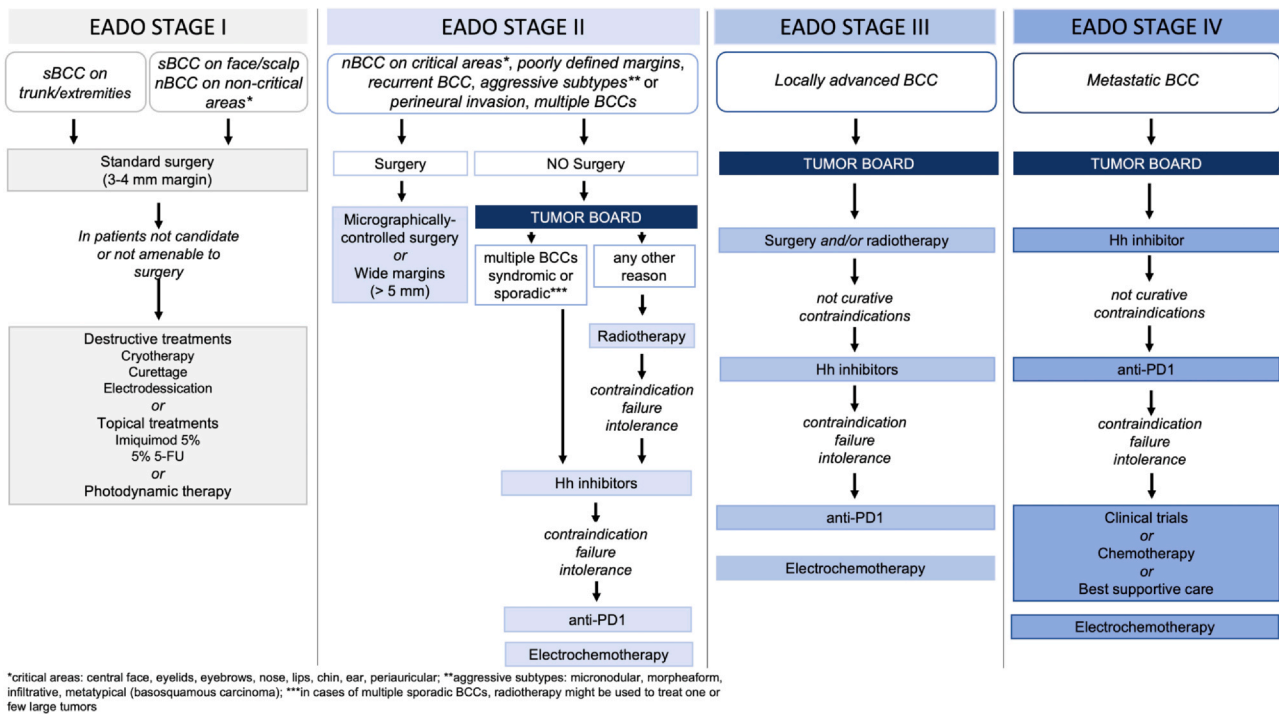


Fig. 3. Treatment algorithm for BCC. BCC, basal cell carcinoma; EADO, European Association of Dermato-Oncology; 5-FU, 5-fluorouracil; nBCC, nodular subtype of BCC; sBCC, superficial BCC.

**Box 5 Surgery.**

Surgery	Evidence-based recommendation
Grade of recommendation A Level of evidence 1	Surgical excision followed by histopathological confirmation shall be offered as standard of care to treat BCC [82–85] Strength of consensus: 100%
BCC, basal cell carcinoma.	

**Box 6 Topical or destructive treatments.**

Topical or destructive treatments	Consensus-based statement
GCP	Topical or destructive (blind) treatments can be considered for low-risk superficial and nodular BCC in patients declining surgery or not amenable to surgery Strength of consensus: 100%
BCC, basal cell carcinoma; GCP, good clinical practice.	

techniques. Moreover, deeper parts of tumours might not be reached because of methodology-inherent penetration limits (e.g. PDT) or only with an inappropriate risk of tissue scarring (e.g. deep cryotherapy). As a rule, blind techniques should be avoided in BCCs in which a deeper tissue invasion cannot be ruled out and in those at increased risk for subclinical spread or local recurrence.

*8.1.1. Standard excision with 2D histology*

The purpose of surgical therapy is to eliminate both the clinically apparent tumour and its microscopic extension into normal-appearing skin. Standard removal of BCC therefore includes the circumferential excision of all visible tumour borders together with an adequate adjacent safety margin of clinically uninvolved tissue. Histopathological assessment of the excised tumour bed

**Box 7** 2D surgical margins—Low-risk BCC.

2D surgical margins—Low-risk BCC	Consensus-based statement
GCP	In low-risk BCCs, a safety margin of 3–4 mm is recommended for standard excision with 2D histology Strength of consensus: 100%
BCC, basal cell carcinoma; GCP, good clinical practice.	

**Box 8** 2D surgical margins—High-risk BCC.

2D surgical margins—High-risk BCC	Consensus-based statement
GCP	High-risk BCCs should be excised with a safety margin of at least 5 mm, if anatomically feasible Strength of consensus: 100%
BCC, basal cell carcinoma; GCP, good clinical practice.	

**Box 9** Re-excision after narrow margins.

Re-excision after narrow margins	Consensus-based statement
GCP	If histologically-free margins are reported, re-excision is not required Strength of consensus: 100%
GCP, good clinical practice.	

**Box 10** Surgery with 3D histology.

Surgery with 3D histology	Evidence-based recommendation
Grade of recommendation A Level of evidence 1	Micrographically controlled surgery (3D) shall be offered in high-risk BCC (recurrent, aggressive subtypes, location in critical anatomical sites, poorly defined margins) <a href="#">[99–101,105,108]</a> Strength of consensus: 100%
BCC, basal cell carcinoma.	

**Box 11** Re-excision after incomplete excision.

Re-excision after incomplete excision	Evidence-based recommendation
Grade of recommendation A Level of evidence 3	Incompletely excised BCC lesions, particularly high-risk BCCs, and those incompletely removed at the deep margin, shall be re-excised <a href="#">[109–111]</a> Strength of consensus: 100%
BCC, basal cell carcinoma.	

**Box 12** Curettage plus electrodesiccation and cryotherapy.

Curettage ± electrodesiccation and cryotherapy	Evidence-based recommendation
Grade of recommendation C	Curettage ± electrodesiccation and cryotherapy may be alternative treatments for small, low-risk BCC
Level of evidence 2	[120,121] Strength of consensus: 100%
BCC, basal cell carcinoma.	

**Box 13** Laser ablation.

Laser ablation	Evidence-based recommendation
Grade of recommendation X	There is insufficient evidence to determine the effectiveness of laser for treatment of BCC
Level of evidence 4	[120,122,127–129] Strength of consensus: 100%
BCC, basal cell carcinoma.	

**Box 14** 5% Imiquimod—Superficial and nodular BCC.

5% Imiquimod—Superficial and nodular BCC	Evidence-based recommendation
Grade of recommendation B	Topical 5% imiquimod should be used in the treatment of primary superficial and small nodular BCC
Level of evidence 1	[133,135,137,138,140] Strength of consensus: 100%
BCC, basal cell carcinoma.	

**Box 15** 5% 5-Fluorouracil.

5% 5-Fluorouracil	Evidence-based recommendation
Grade of recommendation B	Topical 5% 5-FU should be used for the treatment of superficial BCC
Level of evidence 2	Topical 5-FU is inferior to imiquimod and non-inferior to MAL-PDT in the treatment of superficial BCC [133] Strength of consensus: 100%
5-FU, 5-fluorouracil; BCC, basal cell carcinoma; MAL, methyl aminolevulinate; PDT, photodynamic therapy.	

**Box 16** PDT with MAL or ALA.

PDT with MAL or ALA	Evidence-based recommendation
Grade of recommendation B	Photodynamic therapy using 5-ALA or MAL in combination with red light should be used for the treatment of superficial and low-risk nodular BCC
Level of evidence 1	PDT is less effective than imiquimod 5% [126,133,138] Strength of consensus: 75%
AFL, ablative fractional laser; BCC, basal cell carcinoma; MAL, methyl aminolevulinate; PDT, photodynamic therapy.	



**Box 17** Radiotherapy.

Radiotherapy	Consensus-based recommendation
Grade of recommendation A Level of evidence 1	Radiotherapy shall be used in patients who are not candidates for surgery or decline surgery [138,163] Strength of consensus: 100%

**Box 18** Surgery—Locally advanced BCC.

Surgery—Locally advanced BCC	Consensus-based recommendation
GCP	Decision on the potential suitability, indication, and technique in locally advanced BCC shall be made in a multidisciplinary team Strength of consensus: 100%
BCC, basal cell carcinoma; GCP, good clinical practice.	

**Box 19** Hedgehog inhibitors.

Hedgehog inhibitors	Evidence-based recommendation
Grade of recommendation B Level of evidence 3	Hedgehog inhibitors should be offered to patients with locally advanced or metastatic BCC [182,183,185,188] Strength of consensus: 100%
BCC, basal cell carcinoma.	

**Box 20** Immunotherapy.

Immunotherapy	Evidence-based recommendation
Grade of recommendation B Level of evidence 3	Anti-PD1 immunotherapy should be offered as second-line treatment in patients who progress or have contraindications to hedgehog inhibitors [193] Strength of consensus: 100%

**Box 21** Best supportive care.

Best supportive care	Consensus-based statement
GCP	An early involvement of the interdisciplinary best supportive care team is recommended for symptomatic patients with locally advanced and metastatic BCC Strength of consensus: 100%
BCC, basal cell carcinoma; GCP, good clinical practice.	

is routinely performed in a cross-sectional fashion with the examination of vertical sample cuts (bread loaf sections for 2D histology) obtained from formalin-fixed, paraffin-embedded tissue.

Recommendations on safety margins in BCC standard excision vary according to the risk profile of each tumour. Current guidelines suggest a range of peripheral margins between 2 mm and 5 mm in low-risk tumours

**Box 22** Follow-up.

Follow-up	Consensus-based statement
GCP	Follow-up is recommended in patients with BCC in 3–12 monthly intervals according to the risk category Strength of consensus: 100%

BCC, basal cell carcinoma; GCP, good clinical practice.

and between 5 mm and 15 mm in high-risk lesions [2,87,88]. In addition to other factors (e.g. primary or recurrent lesion, histopathological subtype, presence or absence of perineural invasion), tumour size is crucial in predicting the risk of subclinical extension. A meta-analysis including 16,066 lesions demonstrated a 3-mm surgical margin to be safe in achieving a 95% cure rate for non-morpheaform lesions  $\leq 2$  cm [89]. A tumour of 2 cm with additional high-risk features would require a safety margin of at least 13 mm to achieve the same relative certainty of complete removal [90]. In clinically well-defined pigmented common BCCs, margins of only 2–3 mm have been shown to yield a removal rate of 99% [91,92]. Smaller margins may also be considered in sites where reconstructive options are limited and subsequent reconstruction is intended in a setting of micrographic (3D) surgery [60,93]. Guidelines addressing the deep margins recommend an excision up to subcutaneous tissue and in lesions on the head, down to the level of the fascia, perichondrium, or periosteum [2,87].

The use of non-invasive techniques (dermatoscopy, RCM, OCT, LC-OCT) has been investigated to define the preoperative margins more precisely and to detect tumours outside the clinically visible borders, particularly in non-pigmented ill-defined BCC lesions [60,94]. However, implementation in clinical practice still needs further studies.

#### 8.1.2. Re-excision after histologically narrow margins

Clinical and histopathological margins do not necessarily correspond. This might be due to the fact that tumour infiltration, which is not clinically visible, may extend within the area of the surrounding safety margins and to the shrinkage of excised tissue after fixation for histopathological examination. Although shrinkage is less in aged and elastotic skin, a percentage shrinkage of 17–20% in length and about 10% in width can be expected [95,96]. Nevertheless, there are currently no data supporting the need for re-excision in the event of a complete excision with histologically narrow margins.

#### 8.1.3. Micrographically controlled surgery

Micrographically controlled surgery (3D histology with different possible approaches of examining vertical and/or horizontal planes) best enables the complete examination of surgical margins. It represents a safe and proven method to confirm thorough resection of

infiltrating tumours, especially at problematic sites, while preserving the adjacent tissue. This provides aesthetic results that are superior or equivalent to non-surgical and less safe procedures [97]. Micrographically controlled surgery is both an efficient and cost-effective procedure providing the highest cure rates [98]. In a prospective randomised trial comparing standard 2D excision with micrographic 3D surgery, the 10-year cumulative probability of recurrence for primary BCC was 12.2% after standard excision and 4.4% after micrographically controlled surgery ( $p = 0.100$ ). For recurrent BCCs, the cumulative 10-year recurrence probability was 13.5% and 3.9% for 2D and 3D excision, respectively ( $p = 0.023$ ) [99]. Apart from a higher risk of incomplete excision with an increased likelihood of recurrence, standard 2D excision and reconstruction might result in more invasive or cosmetically less desirable reconstruction compared to 3D excision [100,101]. Primary BCCs associated with a high risk of local recurrence or subclinical extension and those in cosmetically or functionally sensitive locations, as the central face, or BCCs exhibiting aggressive growth patterns are candidates for a stepwise surgery with 3D histology (if technically available) [97,102–105]. In addition, recurrent tumours should undergo microscopically controlled surgery because the cure rates for recurrent BCCs are inferior to those of primary lesions with a reported re-recurrence rate at 5 years between 11.6% and 17.4% [106,107]. In 174 recurrent BCC lesions of the head and neck treated with micrographic surgery, the recurrence rate was only 4.6% with a calculated 5-year cumulative probability of re-recurrence of 2.9% [108].

#### 8.1.4. Procedure in the event of incomplete excision

Incomplete excision, where one or more surgical margins still contain neoplastic cells, has been reported in 4.7–24% of excisions and is influenced by surgical experience, anatomical site, histopathological subtype of tumour, and excision of multiple lesions during one procedure [109–113]. A recent meta-analysis comprising 106,832 BCCs, reported an overall proportion of incomplete excisions of 11% with the lowest numbers for patients treated by dermatologists (6.2%) [114]. Recurrence after surgery of incompletely excised BCC ranges from 26% to 41% after 2–5 years of follow-up, and the maximum number of tumour recurrences has been

detected in BCC series with a predominance of the morpheic type [109]. The absence of residual tumour cells in the surgical specimen can be observed in about half of the BCCs after re-excision because of positive surgical margins. However, the risk of further recurrences among tumours that have already recurred once is more than 50%, especially when both lateral and deep margins are involved [111]. Some incompletely excised lesions may demonstrate a more aggressive histopathological subtype when the lesion recurs [115]. Therefore, retreatment is suggested in aggressive tumours prone to high recurrence rates (e.g. micronodular or multifocal tumours) or those in which the deep surgical margins are involved, particularly when they are located in the midface or other complicated sites [109]. Micrographically controlled surgery (3D) should be considered in the latter situations. In a setting of micrographically controlled (3D) surgery, re-excision in the presence of a positive margin is part of the stepwise procedure. Lesions with surgical margins that are tangential or extremely close to the tumour should be managed as incompletely excised. Radiotherapy should be considered in patients with a high risk of not having a complete resection with surgery. Finally, clinical follow-up could also be considered for non-aggressive, small (< 2 cm) lesions on the trunk.

### 8.2. Destructive therapies

Destructive therapies with curettage, electrocautery (electrodesiccation), cryosurgery (also referred to as cryotherapy), and laser ablation are therapeutic options for low-risk superficial and nodular BCCs. Curettage allows histopathological assessment, which is not possible with cryotherapy or laser ablation due to tissue destruction.

Curettage ± electrodesiccation are treatment options suggested for low-risk primary BCCs, although there is no international consensus regarding the optimal protocol [116]. Efficacy is highly dependent on tumour characteristics, anatomical location, and operator skills. The overall reported 5-year recurrence rates vary from 3% to 20% with lower recurrence rates for low-risk lesions located on the trunk and extremities. High recurrence rates are reported for facial and recurrent BCC and for BCCs on terminal hair-bearing skin [116,117]. No significant differences regarding surgical complications, postoperative recovery, aesthetic appearance, and patient satisfaction were recently found in patients with superficial, < 1 cm BCC, treated with curettage and electrodesiccation compared to those treated with conventional surgery, as assessed three months after the procedure [118].

Randomised clinical trials (RCTs) comparing cryotherapy with several other treatment modalities (PDT, surgery, radiotherapy) have reported recurrence rates for cryotherapy ranging from 6% at 1 year to 39% after 2 years of follow-up [119,120]. A single-centre, randomised,

controlled non-inferiority trial demonstrated high tumour clearance rates of both curettage alone (95.7%) and cryosurgery (100%) for treatment of superficial, 5–20 mm BCCs on non-facial areas after 1 year, though the non-inferiority analysis was inconclusive [121].

An RCT of 240 patients compared clinical complete response rates of limb and trunk sBCCs treated with surgery, cryotherapy, and carbon dioxide (CO<sub>2</sub>) laser ablation: surgery was found to be more effective in comparison to the other treatments, whereas the complete response rates with CO<sub>2</sub> laser and cryotherapy were statistically not significant [120].

CO<sub>2</sub>, erbium yttrium aluminium garnet (Er:YAG), and neodymium-doped yttrium aluminium garnet (Nd:YAG) lasers ablate tissue through the vaporisation of tissue water, either in full ablative or fractional mode [122,123]. Tissue interaction and efficacy rates depend on operator settings, and there are no standard operational procedures. A few studies have evaluated the efficacy of laser ablation for the treatment of BCC, mainly as pretreatment before PDT, and no data are available on long-term follow-up [124–126]. Results from an RCT including 39 patients showed a higher rate of complete responses at 3 months and a lower rate of local relapses at 12 months in patients with small primary nodular BCCs treated with Er:Yag laser combined with ablative fractional laser (AFL)-PDT compared to patients treated with methyl aminolevulinic acid (MAL)-PDT [122]. Treatment with long-pulsed Nd:YAG laser showed promising results in 11 patients with nodular BCC and sBCC after a mean follow-up of 9 months (range 6–15 months) with minimal scarring and no long-term adverse events [127]. Similarly, good results in tumour clearance and recurrence rates have been reported in 102 patients with primary and recurrent BCCs treated with Nd:YAG laser, as assessed 2 months and 1 year after treatment evaluated using OCT. Only one treatment was sufficient for small lesions (< 5 mm), while larger lesions usually required more treatment sessions [128]. In 31 patients, long-pulsed 1064 nm Nd:YAG laser was used in non-aggressive BCCs, less than 16 mm in size, located on the trunk or extremities, with complete histopathological clearance of the tumour in 90% of the lesions at 1 month [129]. However, incomplete tumour clearance was detected in 31% of 78 BCCs 3 months after treatment with Nd:YAG laser with a large number of side-effects and poor cosmetic outcome [130].

### 8.3. Topical therapies

Topical therapies should be considered in patients with superficial and low-risk, nodular BCC, declining surgical intervention or if surgery is contraindicated due to patient-related factors (age, comorbidities, concomitant medications, logistic difficulties). Two topical agents are

approved for sBCC, namely imiquimod 5% and 5% 5-fluorouracil (5-FU).

### 8.3.1. Imiquimod

Imiquimod is an immune response modifier indicated for the treatment of sBCC in immunocompetent adults, applied once daily, five times per week for 6 weeks.

A non-inferiority, RCT compared imiquimod 5% cream (once daily, five times a week for 6 weeks) with 5% 5-FU (twice daily for 4 weeks) and MAL-PDT (two sessions with an interval of 1 week) in patients with sBCC followed up for 5 years [131–133]. The overall estimate of treatment success at 1 year was 83.4% for imiquimod, 80.1% for 5% 5-FU, and 72.8% for MAL-PDT, supporting that topical 5% 5-FU was non-inferior and imiquimod 5% was superior to MAL-PDT for treatment of sBCC [131]. Tumour thickness and adnexal extension of sBCC appeared not to predict treatment failure [134]. Five-years after treatment, the probability of tumour-free survival was 80.5% for imiquimod, 70.0% for 5% 5-FU, and 62.7% for MAL-PDT, confirming that imiquimod 5% is superior to both MAL-PDT and 5% 5-FU in the treatment of patients with primary sBCC [133]. Limited evidence is available on the efficacy of imiquimod for BCC of the nodular type. In a recent systematic review on the efficacy of imiquimod for the treatment of nodular BCC, imiquimod showed 77.4% clinical and 72.9% histopathological clearance rates for nodular BCC, with a recurrence rate of 1.8% after an average follow-up of 13.0 months [135]. The efficacy of imiquimod 5% cream versus surgical excision was assessed in patients with low-risk superficial and nodular BCC, once daily for 6 weeks (superficial) or 12 weeks (nodular), with a successful response in 84% and 98% of the patients ( $p < 0.0001$ ), respectively, at 3 years from the start of treatment [136]. The 5-year follow-up data of this trial were comparable to the 3-year data, reporting maintenance of the clinical benefit in 82.5% of imiquimod-treated patients versus 97.7% of the surgery group ( $p < 0.001$ ) [137]. Local erythema, swelling, erosion, crusting, irritation, and itching are often reported as moderate or severe in patients treated with imiquimod. Approximately 5% of treated patients also experience systemic flu-like symptoms [131]. Imiquimod represents a clinically useful alternative to surgery in the treatment of low-risk, single or multiple sBCC [138]. Combination therapies with curettage or cryotherapy have been reported, but they need to be further investigated and might be discussed on an individual basis for nodular BCC.

### 8.3.2. 5-Fluorouracil

The 5% formulation of the antimetabolite 5-FU is licensed for the treatment of sBCC with two applications daily for 3–6 weeks. A few studies evaluated the efficacy of 5% 5-FU in sBCC with no long-term follow-up data [139,140]. As described above, a recent RCT comparing

5% 5-FU with imiquimod 5% and MAL-PDT in sBCC demonstrated that topical 5-FU is inferior to imiquimod and non-inferior to MAL-PDT in the treatment of sBCC after 3 [132] and 5 years of follow-up [133]. Rates of local side-effects are similar to those seen with imiquimod, but flu-like symptoms were not observed [131].

### 8.4. Photodynamic therapy

PDT combines the use of a topical photosensitizer (5-aminolaevulinic acid [ALA] or MAL) and illumination with visible light, leading to the production of reactive oxygen species, resulting in apoptosis and selective tumour cell necrosis. MAL cream and ALA nanoemulsion formulation are currently approved in Europe for the treatment of low-risk superficial and nodular BCCs. Treatment consists of two sessions 1 week apart [141,142].

PDT with 5-ALA or MAL should be considered in patients with non-aggressive, low-risk BCC, that is, small superficial and nodular types not exceeding 2 mm tumour thickness, where surgery is not suitable or contraindicated due to patient-related limitations (age and comorbidities, medications, logistic difficulties) [124]. Less common histopathological variants, as morpheic, pigmented and micronodular BCCs, as well as BCCs in areas with high risk of tumour recurrence and deep penetration (facial 'H'-zone) should not be treated with PDT. MAL-PDT achieved clearance rates of 92–97% for sBCC at 3 months, with recurrence rates of 9% at 1 year and 22% at 5 years [119,125]. In a real-life prospective head-to-head comparison study, the cumulative probability of tumour-free survival at 5 years after treatment of sBCCs was 62.7% for MAL-PDT compared to 80.5% for imiquimod 5% cream and 70.8% for 5-FU. [133].

For nodular BCC treated by MAL-PDT, 91% were clinically clear at 3 months, with a sustained lesion clearance response rate of 76% after 5 years of follow-up [126]. MAL-PDT was equivalent to surgery (92% versus 99% initial clearance, 9% and 0% recurrences at 1 year, respectively) for sBCC but inferior to excision for nodular BCC when recurrence rates are compared (14% and 4% recurrences at 5 years, respectively) [125,126]. Clearance rates were equivalent when MAL-PDT was compared with cryotherapy for the treatment of sBCC with no difference in the 5-year recurrence rates with either treatment (20% with cryotherapy versus 22% with MAL-PDT,  $p = 0.86$ ) [119]. The cosmetic outcome, however, was superior following PDT compared with either surgery or cryotherapy [119,126]. PDT using the ALA nanoemulsion gel was compared with MAL in the treatment of non-aggressive BCC (superficial and nodular < 2 cm). At 12 months after the last PDT treatment, 93.4% of the ALA-treated patients were complete responders compared with 91.8% in the MAL group, establishing non-inferiority ( $p < 0.0001$ ) [143]. A cohort of 33 patients (138 lesions) with Gorlin syndrome were treated by topical or systemic PDT with an overall local



control rate at 12 months of 56.3% of the lesions [144]. Excellent cosmetic results with high patient satisfaction have been reported after PDT [141], although pain/discomfort during illumination is the prominent adverse effect of conventional PDT [124]. Discontinuous illumination (fractionation) was proposed to increase the efficacy of PDT by permitting tissue reoxygenation during 'dark' periods. Fractionated ALA-PDT produced a superior response in sBCC versus single PDT (88% versus 75%, respectively) but significantly lower than conventional two-stage MAL-PDT (70.7% versus 76.5%, respectively), 5 years after treatment [145,146]. In nodular BCC, the 5-year cumulative probability of recurrence after surgical excision (2.3%) was lower than after fractionated ALA-PDT with prior debulking (30.7%) [147]. New photosensitising agents and delivery systems for PDT in BCC are currently under investigation.

### 8.5. Combined therapies

Combining treatment modalities relies on the complementary or synergistic mechanisms of action of each of them and should be reserved for clinical situations that are not suitable for standard treatment, such as surgery.

Partial destruction of nodular or pigmented BCC prior to MAL-PDT can increase the cure rate. In nodular BCC, pretreatment with CO<sub>2</sub>, Er:YAG, diode lasers, or surgical debulking increases the cure rates up to 92.9–98.9% [148]. UltraPulse CO<sub>2</sub> laser prior to the standard two MAL-PDT sessions had a complete clinical clearance of 100% and a recurrence-free rate of 97.1% after a mean follow-up period of 32.2 months [149]. CO<sub>2</sub> laser followed by two/three cycles of MAL-PDT provided better responses in BCC thinner than 2 mm with a 93.6% 5-year recurrence-free rate and a direct cost saving of 43% [150]. One single session of Er:YAG AFL-primed MAL-PDT determined a complete response rate of 84.2% at 3 months compared with 50% after two MAL-PDT sessions and a 1-year recurrence rate of 6.3% and 55.6%, respectively [122]. Contact cryotherapy applied after CO<sub>2</sub> laser ablation and MAL-PDT in a small case series of BCCs resulted in complete response and no recurrences after 22 months of follow-up [151]. The use of AFL to increase the delivery of cisplatin and 5-FU in low-risk superficial and nodular BCCs showed overall complete tumour clearance in 89% (17/19) and 79% (15/19) of cases at 6 and 12 months, respectively [152].

Curettage debulking with complete removal of macroscopic pigment followed by MAL-PDT showed a complete response in 76.2% and a 1-year recurrence rate of 19.1% in pigmented BCC [153]. The reduction of the tumour burden of nodular BCC with curettage prior to imiquimod showed a clearance rate of 96% at an average of 36 months follow-up [154]. In one RCT, the 1-year free of recurrence rate was 86.3% for nodular

BCC patients treated with curettage and imiquimod and 100% for those treated with surgery [155].

The combination of PDT with imiquimod has been reported in small case series or case reports [156]. The cure rate for recurrent BCCs increased from 60% to 75% when imiquimod was administered after two sessions of PDT compared to PDT alone [157]. Cryotherapy in imiquimod-refractory BCCs resulted in 83% of clinical response rate [158]. In addition, cryotherapy applied between the second and fifth weeks of imiquimod treatment (immunocryosurgery) achieved an efficacy of 95% in primary nodular BCCs with a 5-year tumour-free rate of 91.4% [159].

Neoadjuvant treatment with imiquimod prior to Mohs surgery showed a significant reduction of the tumour size and resulted in a smaller surgical defect compared to vehicle [160]. However, it can produce discontinuous tumour nests, reducing the accuracy of margin evaluation during Mohs surgery [161]. Adjuvant ALA-PDT after Mohs surgery in facial superficial and nodular BCCs showed recurrences in 1 of 84 lesions after 2 years [162].

The level of evidence of combined treatment is low because most combinations are supported by small series and/or short follow-up time and are applied in off-label situations.

### 8.6. Radiotherapy

Radiotherapy is a valid alternative to surgery and may be considered as a primary treatment in patients who are not candidates for surgery (e.g. locally advanced disease, comorbidities, or those who decline surgery) or in cases when curative surgery is not possible or could be disfiguring or burdened by poor aesthetic outcome [163,164], including BCCs located on the face (i.e. eyelid, nose, lip) or large lesions on the ear, forehead, or scalp [165,166]. A systematic review and network meta-analysis on primary BCC analysing 40 randomised trials and five non-randomised studies with variable follow-up, reported an estimated recurrence rate of 3.5% after radiotherapy, that is fully comparable to standard surgery (3.8%) and Mohs surgery (3.8%) [163]. The risk of developing a radiotherapy-induced secondary skin cancer is negligible using appropriate radiation doses but needs to be considered in younger patients together with discussion on long-term cosmesis.

Different radiotherapy techniques have been developed to date: external beam radiotherapy (surface/orthovoltage X-rays, electron, and megavoltage photon treatment) remains the most used treatment modality. However, interstitial interventional radiotherapy (or interstitial brachytherapy) and contact radiotherapy (surface brachytherapy and electronic brachytherapy) represent alternative treatment strategies. The choice between external beam radiotherapy and brachytherapy must consider many factors: lesion size, location and infiltration depth,

team expertise, and institutional resources [164]. Results of brachytherapy are comparable to those obtained with external beam radiotherapy with the advantage of the rapid dose falloff allowing to spare the surrounding tissue [164,167,168]. Furthermore, the use of intensity-modulated brachytherapy (stepping source technique) allows optimisation and individualisation of the dose distribution, especially when the implant configuration is difficult due to anatomical reasons [168]. Various prescription schedules are used in external beam radiotherapy and brachytherapy. The total prescribed dose and fractionation should reflect the differences in radiobiological effectiveness between different radiation modalities. Advanced lesions may be treated with megavoltage radiation to doses between 60 and 70 Gy, using 2 Gy fractions, five fractions per week; hypofractionated approaches such as 45 Gy in 10 fractions or 54 Gy in 18 fractions represent equi-effective treatment schedules. Hypofractionated radiotherapy results in good cosmetic outcomes [169], although the dose per fraction should also be defined on the basis of the tumour site and possible functional and aesthetic results. Indeed, protracted fractionation seems to be associated with improved cosmetic results and should be utilised for poorly vascularised or cartilaginous areas (NCCN, version 1.2023; <https://www.nccn.org>). The prescribed dose must encompass all visible tumour plus an appropriate variable margin (clinical target volume), sparing as much as possible the surrounding healthy structures [164]. Irrespective of treatment intent (definitive, adjuvant, palliative), dosimetric and technical considerations should be surveyed by a certified medical physicist.

Radiotherapy is an overall safe procedure, although it can be associated with complications such as a transient acute, rarely erosive, radiation-induced dermatitis and chronic onset of depigmentation and telangiectasias. We suggest avoiding radiotherapy in young patients as the potential risk of long-term trophic disorders is not well addressed; however, if needed, the decision should be shared in the context of the multidisciplinary tumour board.

Radiotherapy may be also considered after incomplete resection with microscopic (R1) or macroscopic (R2) residual tumour, when the tumour board does not consider follow-up or a wide surgical excision as the best option.

### 8.7. Electrochemotherapy

ECT is a treatment option that may be offered when surgery or radiotherapy are not feasible or contra-indicated [138]. ECT provides its antitumor effect through the permeabilisation of cancer cells to chemotherapeutic agents (bleomycin or cisplatin) by means

of short, high-voltage, electric pulses which destabilise the cell membrane barrier allowing their intracellular access. The main advantages of ECT are high local tumour control with minimal damage to normal tissue, limited side-effects, and good cost/benefit ratio. Over the past 20 years, ECT has been applied mainly in a palliative setting allowing the control of bleeding and mass-related symptoms. Data from the International Network for Sharing Practice in ECT (InspECT), a pan-European collaboration of centres encompassing different specialties that treat cutaneous malignancies, support that ECT is a consistent and reliable treatment option in specific settings of patients. The reported overall response and complete response rates for BCC with ECT were 96% and 85%, respectively [170]. A registry-based study of InspECT reported 623 BCCs of 330 patients treated with bleomycin-ECT with complete response after a single ECT course in 81% of patients. Toxicity included skin ulceration (overall, 16%; G3, 1%) and hyperpigmentation (overall, 8.1%; G3, 2.5%). At a 17-month follow-up, 9.3% of patients experienced local recurrence/progression [171]. A prospective RCT investigating ECT versus surgery in patients with BCC reported no evidence of recurrence at 5 years in 97.5% of BCC lesions treated with surgery and in 87.5% of those treated with ECT [172]. ECT can be used in the treatment of locally advanced or recurrent BCC when standard treatments are not feasible, with good tumour control and functional results without systemic adverse events.

## 9. Management of advanced BCC

### 9.1. Surgical therapy of laBCC

Front-line surgical therapy of laBCC is hampered by the difficulty of achieving the complete removal of the tumour (R0 resection) and by potential major surgical morbidity that may result from complete resection. However, surgery is expected to play a role in the palliative setting (i.e. unmanageable bleeding tumours, unbearable pain, etc.), and as part of the neoadjuvant approach once systemic therapy succeeds in reducing tumour burden, allowing a downstaging of the surgical procedure in functionally sensitive locations [173,174]. The appropriate management of patients with laBCC should be planned in the context of the skin cancer multidisciplinary tumour board after complete physical examination and imaging studies (Computed tomography-scan, MRI) aimed at identifying invasion of deep structures (bone, muscles, vessels) and perineural invasion.

### 9.2. Radiotherapy of laBCC

In the management of laBCC, radiation therapy is considered in the palliative setting to improve patient's quality of life, especially for alleviating cancer-

associated symptoms/signs such as pain, bleeding, and ulceration [175]. In this setting, short-course accelerated-hypofractionated radiotherapy can be performed by delivering the total dose with few fractions, increasing the dose per fraction, resulting in better patient's compliance [176]. However, radiotherapy (external beam or interventional) can also be proposed with a curative intent for laBCC due to recent technological innovations, especially intensity-modulated and image-guided radiotherapy, which provide high-precision treatments with excellent local control and a low rate of side-effects [177,178]. Preliminary evidence seems to encourage the combination of radiotherapy with systemic therapies, either HHI or immunotherapy, in a neoadjuvant setting or as a concomitant approach [179,180] based on the potential synergistic effect, and the fact that the dose of radiotherapy may be modulated according to the clinical response.

### 9.3. Hedgehog inhibitors

Vismodegib and sonidegib are specific inhibitors of an oncogenic protein named Smoothened and are both approved by FDA and EMA for the treatment of patients with laBCC who are not candidates for surgery or radiotherapy; vismodegib is also approved for mBCC whereas sonidegib is approved for mBCC only in Switzerland and Australia. The oral dose is 150 mg/day for vismodegib and 200 mg/day for sonidegib.

A phase 2 pivotal clinical trial (ERIVANCE) in patients with laBCC and mBCC treated with vismodegib showed an overall response rate of 43% or 60% for laBCC and 30% or 45% for mBCC by independent review or site investigator, respectively. The median duration of response was 7.6 months, and the median progression-free survival was 9.5 months in both cohorts [181]. The long-term update of ERIVANCE after 39 months of follow-up showed an investigator-assessed overall response rate of 60.3% in the laBCC group (20 patients with complete response and 18 patients with partial response) and of 48.5% in the mBCC group (all partial responses). The median duration of response was 26.2 months for laBCC) and 14.8 months for mBCC. Median overall survival was not estimable in the laBCC cohort and was 33.4 months in the mBCC cohort [182]. The results of the ERIVANCE trial have been confirmed by a global safety study (STEVIE) that revealed a response rate (investigator-assessed) of 68.5% for laBCC and 36.9% for mBCC after a median follow-up of 17.9 months [183]. In the sonidegib pivotal clinical trial (BOLT), the objective response was 43% (central review) or 67% (investigator review) for laBCC and 15% (central review) or 23% (investigator review) for mBCC for the 200 mg daily dose after a median follow-up of 13.9 months, using very stringent modified RECIST criteria. The duration of tumour response was 20.2 months and progression-free survival was 22.0 months

(investigator review) [184]. The final 42-month analysis of BOLT reported an objective response rate of 56% for laBCC and of 8% for mBCC per central review. The median duration of response was 26.1 months in laBCC and 24.0 months in mBCC. The median progression-free survival was 22.1 months (not estimable) for laBCC and 13.1 months for mBCC [185]. Multiple BCCs in patients with Gorlin syndrome should be considered as laBCCs and treated accordingly. They have been included as small subgroups in the pivotal clinical trials of vismodegib (ERIVANCE) and sonidegib (BOLT). In a multicentre, randomised, double-blind, placebo-controlled, phase 2 trial, a significant reduced rate of new surgically eligible BCCs and a reduction in size of the existing BCCs were observed in Gorlin patients treated with vismodegib compared with patients in the placebo group [186].

Reinduction with HHI in 12 patients with advanced BCC who failed a first-line HHI and second-line anti-PD1 inhibitor was recently reported with a 33% complete/partial response, 50% stable disease, and 17% progression [187].

In laBCCs, a neoadjuvant treatment with a HHI with the intention to shrink lesions can be discussed, although there are no randomised data to prove its beneficial outcome. In the VISMONEO study, 55 patients with BCC considered inoperable or operable with functional or major aesthetic impact were treated with oral vismodegib 150 mg/d for 4–10 months. In 44 (80%) patients, a downstaging of the surgical procedure was possible after HHI neoadjuvant treatment [173].

Radiotherapy could be used in combination with HHI [180] and may be indicated after surgery when perineural invasion is present [177].

During treatment with HHI, class-specific adverse events such as muscle spasms, taste alterations, hair loss, fatigue, and weight loss appear in most patients and lead to treatment discontinuation in approximately 30% of patients [188]. No treatment-related deaths have been reported in clinical trials with HHI. Different preventive and management strategies related to address the side-effects have been proposed to improve patients' quality of life and clinical benefit [189]. Drug holidays or dose reduction have been considered alternatives in the management of drug toxicities from HHIs [190].

### 9.4. Immunotherapy

The rationale of using anti-PD1 immunotherapy in patients with advanced BCC stemmed from several lines of experimental and clinical evidence: i) BCC has one of the highest TMB of any human malignancy and is in the same range as for cutaneous SCC; ii) BCC represents a UV-induced tumour with immunogenic features; iii) the risk of BCC is 10 times higher in organ transplant recipients and other groups with induced or acquired lack of immunosurveillance than in the general population,

suggesting that adaptive immune responses are specifically important in this disease [191,192]. Therefore, patients with laBCC and mBCC can be considered as good candidates for a response to immune checkpoint inhibitors like PD-1 antibodies. In 2021, a pivotal clinical trial investigating intravenous cemiplimab (REGN-ONC 1620), a recombinant IgG4 human monoclonal anti-PD-1 antibody, in patients with advanced BCC was published [193]. This single-arm, phase 2, multicenter clinical trial included patients who had progressed or were intolerant to previous HHI therapies. Eighty-four laBCC patients received cemiplimab with the conventional dose of 350 mg intravenously every 3 weeks for up to 93 weeks or until progression or unacceptable toxicity. In an independent central review, the primary endpoint (overall response rate) of the clinical trial was met. The objective response rate was 31%. Five patients (6%) had a complete response. Apart from the conventional adverse events known for all anti-PD-1 antibodies in other cancer entities, there were no specific new adverse events observed. In addition, there were no treatment-related deaths. The cohort of patients with laBCC was updated at the EADO conference 2022 (21st–23rd April 2022, Sevilla, Spain; Stratigos et al.) with a longer follow-up time (15.9 months). A complete response was observed in 7.1% of patients and partial response in 25.0%, with an observed duration of response of 85.2% at 6 months. The disease control rate was 79.8%. The median progression-free survival was 16.5 months while the median for overall survival had not been reached. At 2 years, 80.3% of the patients are still alive. There were no new safety signals. A primary analysis on 54 patients with mBCC from REGN-ONC 1620 was recently presented and currently submitted. One complete response (1.9%) and 12 partial responses (22.2%) with a median duration of response of 16.7 months were shown. The median progression-free survival was 8.3 months, while the median overall survival had not been reached. At 12 months, 84.4% of patients were still alive. There were no new safety signals reported, and the tolerability of cemiplimab in the mBCC cohort was similar to that of the laBCC cohort. In summary, cemiplimab provided a clinically meaningful antitumoral activity in mBCC and laBCC patients, who had progressed or were intolerant to conventional first-line HHIs. The safety profile was generally consistent with previous reports on cemiplimab and other PD-1 inhibitors. Cemiplimab has been approved by FDA and EMA in 2021 and represents the only approved PD-1 antibody for advanced BCC patients.

### 9.5. Chemotherapy

The use of systemic chemotherapy for mBCC has been addressed only in case reports and case series. Most patients with widespread metastases received platinum-based chemotherapies. The response rate was not higher

than 20–30%, but occasionally response rates up to 60% have been reported. However, in almost all successfully treated cases, the response duration was no longer than 2–3 months [194]. Chemotherapy might be considered for laBCC and mBCC in patients who are not responsive or have progressed after HHI and PD-1 inhibitors, alone or in combination with radiotherapy.

### 9.6. Best supportive care

In advanced BCC, most frequently occurring in elderly patients, health-related quality of life (HRQoL) is an important consideration when determining the best treatment plan and should be evaluated continuously during treatment. Several tools such as the EORTC QLQ-C30 are widely used for this purpose [195]. Consideration should be given to nutritional, psychological, social, and existential needs to improve overall quality of life in the palliative setting consulting a palliative care specialist/team (WHO Definition of Palliative Care; <https://www.who.int/cancer/palliative/definition/en/>). Advanced care planning, conversations about wishes, needs, and values of individual patients should be started.

Advanced BCC may cause signs/symptoms related to the depth of infiltration and local cancer involvement as pain, ulceration, exudate, and odour, which have a great impact on HRQoL and patients' well-being. Pain should be assessed regularly using validated pain scales [195]. The visual analogue scale, the verbal rating scale, and the numerical rating scale (NRS) are the most frequently used. When the score exceeds 2 of 10, a conversation about pain is required. Analgesics for chronic pain are best taken orally and should be prescribed on a regular basis instead of an 'as required' schedule [196]. The WHO proposes a sequential three-step analgesic ladder strategy, from non-opioids (paracetamol, non-steroidal anti-inflammatory drugs [NSAIDs]) to weak opioids to strong opioids according to pain scores [197]. However, if a patient already suffers from intermediate (NRS 4) to severe (NRS 7) pain, weak opioids (e.g. tramadol, dihydrocodeine, and codeine) might be best added immediately to the mild analgesics. In ulcerated or exuding tumours, surgery, radiotherapy, or ECT should be discussed to achieve local control or alleviate symptoms [171,198]. Radiotherapy is particularly helpful to relieve pain, to stop haemorrhage, and to limit tumour extension to adjacent critical areas such as the orbits [175]. A daily rinsing with tap water or sodium chloride cleaning fluid is mandatory to control odour. In a large review, evidence was found for topical metronidazole (gel or solution in concentrations of 0.75–0.8%, once daily for at least 14 days), sodium chloride dressing, activated carbon dressing, and curcumin ointment [199]. Topical metronidazole is effective against anaerobic bacteria and protozoa, but it can also be orally administered (500 mg three times daily, for



10–14 days). Absorbent dressing made up of viscose or polyester impregnated with sodium chloride acts through the hypertonic effect produced on the lesion [199]. In a randomised study, 0.2% polyhexamethylene biguanide achieved no malignant wound odour by day 8 in all patients and proved to be equally effective as metronidazole 0.8% solution [200,201]. Furthermore, odour control significantly improved the general HRQoL. Applying zinc oxide paste or silicone gel on the surrounding skin can prevent maceration due to tumour exudate. Application of calcium alginate dressings, dressings with xylometazoline or adrenaline (1:1000) or silver nitrate can temporarily stop bleeding [201]. Management strategies of bleeding depend on severity and are based on local modalities, such as haemostatic agents and dressings, radiotherapy, endoscopic ligation and coagulation in case of gastrointestinal bleeding, and transcatheter arterial embolisation [202].

## 10. Clinical trials

A number of second-generation agents inhibiting the Hh signalling pathway are currently being studied such as patidegib, saridegib (IPI-926), taladegib (LY2940680), and silmitasertib (CX4945). Topical patidegib 2% and 4% have been reported to reduce facial BCCs in patients with Gorlin syndrome, and the 2% gel has been further studied in a phase 3 clinical trial which has now been completed (NCT03703310). Silmitasertib (CX-4945), an ATP-competitive, small molecule inhibitor of casein-kinase II (NCT03897036), is being investigated in laBCC and mBCC resistant to SMO inhibition. Intralesional treatments are a strong focus of ongoing clinical trials with the advantage of reduced dosage, increased activity due to a higher local concentration and possibly a reduction of immune-related adverse events in comparison to intravenous administration. One study is investigating the role of intralesional cemiplimab in BCC and cutaneous SCC (NCT03889912). Several trials are evaluating the effect of oncolytic viruses like TVEC (NCT03458117) or RP-1 (tested for cutaneous malignancies in organ transplant recipients, NCT04349436). Intralesional application of L19IL2/L19TNF (Daromun/Fibromun)—IL-2 or TNF linked to a human single-chain variable fragment directed against the extra-domain B of fibronectin—is tested in two trials that also include patients with advanced BCC (NCT04362722, NCT05329792). Other intralesional treatments include IFx-Hu2.0, a pDNA-encoding Emm55 autologous cancer cell vaccine (NCT04925713), and STP705, a siRNA in an advanced nanoparticle delivery system that targets TGF- $\beta$ 1 and COX-2, currently being evaluated in a phase II, dose escalation study (NCT04669808). ASN002, an intralesional recombinant adenovirus vector, delivering the human interferon (IFN)-gene into BCC cells leading to a

sustained local IFN $\gamma$  concentration, is investigated in a phase II trial in patients with multiple sporadic BCCs or Gorlin syndrome in combination with vismodegib (NCT04416516).

Similar to melanoma and cutaneous SCC, there is also strong interest in the neoadjuvant treatment of advanced BCC. A phase 2 trial investigating neoadjuvant sonidegib followed by surgery or imiquimod is currently recruiting patients (NCT03534947). Early clinical data on 18 patients from an ongoing neoadjuvant trial of TVEC in BCC (neo-BCC) showed a reduction in tumour size with improved operability in most patients (Ressler et al., poster presented at ESMO 2022). Pembrolizumab is assessed as a perioperative, neoadjuvant/adjunct therapy, in patients with resectable advanced BCC of the head and neck (NCT04323202). Combination systemic therapies are being investigated in patients with unresectable, advanced BCC. A phase 2 trial compares anti-PD1 nivolumab in combination with anti-CTLA4 (ipilimumab) or anti-LAG3 (relatlimab) in patients who progressed on single-agent nivolumab (NCT03521830). A single-centre phase II study is testing the combination of intravenous cemiplimab with pulsed oral sonidegib (NCT04679480), based on an expected synergistic effect. For updates of clinical trials, visit the website at <https://clinicaltrials.gov>.

## 11. Follow-up

Follow-up should be performed in patients with BCC because of the risk of local recurrence, subsequent BCC development as well as increased risk of the development of other skin cancers (SCC and melanoma) [1,203]. There is no evidence that intensive follow-up results in better outcomes (burden of disease, cosmetic results) in patients with low-risk BCC [204,205]. However, a recent study showed that BCC patients need to receive all the relevant information tailored to their situation, and therefore it seems reasonable to provide one follow-up visit for all BCC patients to discuss their diagnosis and treatment, to counsel them about sun-protection measures, and to stress the importance of self-monitoring for possible local recurrence and new skin cancers [206]. The risk of tumour recurrence depends on the histopathological subtype, size, and location of the primary tumour and the treatment used. For most primary BCCs treated according to guidelines, this risk is low. However, recurrence rates are higher for recurrent BCC or BCC at high-risk sites on the face with further increase for multiple lesions [207,208]. Patients with recurrent lesions should therefore be counselled accordingly and should be advised to come back for clinical evaluations if they notice any changes at the site of previous surgery. Most metachronous BCCs occur within the first 3 years after diagnosis, but the risk remains elevated over time [209,210]. A meta-analysis

observed a pooled mean 5-year cumulative risk of a subsequent BCC of 36%, comparable to another observational study [204,210]. When primary BCCs are found in large numbers and the age of onset is below 30 years, the patient should be screened for potential Gorlin syndrome. These patients are also at increased risk of other tumours, and their care needs to be discussed at multidisciplinary meetings with a team having experience in looking after these high-risk patients in whom surgical modalities may not be optimal or feasible. A recent systematic review highlighted the lack of consistent follow-up recommendations among available guidelines for BCC [203]. Overall, there seem to be two groups of patients that would require a more rigorous and long-term follow-up: (1) patients who are at high risk for recurrent lesions, such as those who have already been treated for recurrent BCC, and (2) patients with a history of multiple BCCs. These patients should benefit from a follow-up every 12 months for 3–5 years (if not lifelong). In cases of difficult-to-treat or advanced BCC, follow-up should be discussed by a multidisciplinary team at a frequency dictated by each individual case.

## 12. Diagnosis and management of patients with Gorlin syndrome

Gorlin syndrome is a rare, autosomal dominant familial cancer syndrome with a high degree of penetrance and variable expression. Its prevalence is estimated at one per 40,000–60,000 persons. Gorlin syndrome is caused by mutations in the *PTCH1* gene, with *de novo* mutations occurring in 20–30% of patients, and more rarely by mutations in *SMO*, *SUFU*, and *PTCH2* genes [211].

The diagnosis of Gorlin syndrome is established in a proband with the following findings: two major diagnostic criteria and one minor diagnostic criterion or one major and three minor diagnostic criteria [212]. *Major criteria*: multiple BCCs (> 5 in a lifetime) or a BCC before 30 years of age, lamellar (sheet-like) calcification of the falx, jaw keratocyst before 20 years of age, medulloblastoma (desmoplastic variant), palmar/plantar pits, first-degree relative with Gorlin syndrome. *Minor criteria*: lymphomesenteric or pleural cysts, macrocephaly (occipitofrontal circumference > 97th centile), cleft lip/palate, vertebral/rib anomalies observed on chest X-ray and/or spinal X-ray, preaxial or postaxial polydactyly, ovarian/cardiac fibromas, ocular anomalies.

Genetic testing should be performed in selected patients with suspected Gorlin syndrome: (1) prenatal testing if known familial mutation; (2) confirmatory diagnosis in patients with some clinical signs but not meeting criteria as this would allow for increased surveillance and improved patient care outcomes; (3) predictive testing for patients with an affected family member who is at risk but does not meet clinical criteria

[211]. Approaches to molecular testing may include serial testing of a single gene (*PTCH1*, *SUFU*), the use of a multigene panel, and more comprehensive genomic testing [213]. Radiological abnormalities such as dysmorphisms or other skeletal anomalies may be seen in up to 60% of patients with Gorlin syndrome, but investigations for diagnostic criteria should be avoided if they remain without therapeutic consequences to keep X-ray exposure as low as possible [214].

Close surveillance and regular skin examinations carried out by a dermatologist trained in skin cancer detection and dermatoscopy are required to diagnose and treat BCCs at an early stage. Total body skin examination, including scalp and genitalia, should be carried out annually starting at the age of 10 years in carriers of *PTCH1* variants and at the age of 20 years in *SUFU* variant carriers, and then every 4–6 months [215]. Depending on the number, size, location, and subtype of BCCs, treatment approaches used for sporadic BCC, besides radiotherapy, can be considered. The benefit of surgery should be weighed against the high risk of recurrent or newly developing BCCs and should be limited to solitary high-risk BCCs. Vice versa, small or superficial variants in low-risk areas outside the face may be managed by topical treatments and/or by careful watchful waiting during follow-up. Radiotherapy must be avoided because of the carcinogenic effect of X-rays resulting in the formation of new BCCs. The management of locally advanced tumours should be discussed in the context of a multidisciplinary tumour board [213]. There is emerging evidence about some specific genotype–phenotype correlations in patients with Gorlin syndrome, which has led to the introduction of specific follow-up recommendations. Patients with *SUFU* pathogenic variants are significantly more likely than those with *PTCH1* pathogenic variants to develop medulloblastoma, meningioma, or ovarian fibroma [216]. In addition, Gorlin patients with skeletal abnormalities have been reported to be at greater risk for developing more numerous and severe BCCs as well as other neoplastic growths including keratocystic odontogenic tumours and ovarian fibromas [217]. According to these findings, more vigilant lifetime multidisciplinary surveillance should be considered for these patients starting in childhood.

Besides regular skin examinations, additional imaging investigations are recommended for associated extracutaneous abnormalities. In particular, childhood brain MRI surveillance for the risk of medulloblastoma is justified in *SUFU*-related, but not in *PTCH1*-related, Gorlin syndrome. Finally, the Host Genome Working Group suggests annual follow-up by a medical geneticist or paediatric/adult physician familiar with the syndrome to check for non-tumoral manifestation of the syndromes, educate on red flag symptoms, and ensure that all screening procedures are performed [215]. A summary of screening and follow-up schemes according to Guerrini-

Table 4  
Recommended screening for patients with Gorlin syndrome.

Specialist	Screen for	Method of screening	PTCH1 variant carriers	SUFU variant carriers	Comments
Geneticist	Dysmorphic features and genetic counselling	Physical examination, mutational analysis including prenatal tests	-	-	-
Dermatologist	Basal cell carcinoma	Full body skin inspection	Annually at age of 10 years (earlier if previous RT)	Annually at age of 20 years (earlier if previous RT)	At the time of the first BCC, follow-up should be shortened to 4–6 months
Dentist	Odontogenic keratocysts	Orthopantomogram MRI (preferred)	Annually at age of 2 years/at age of 8 years	-	Reduction to once every 3 years from the age of 30 in case of lack of pathological findings
Neurologist	Medulloblastoma	Brain MRI	Brain MRI only if neurological symptoms present	Brain MRI every 3–4 months during the first 3 years, then every 6 months until the age of 5 years	Expert opinion based on the assumption that early diagnosis may reduce mortality
Neurologist	Meningioma	Brain MRI	-	Every 3–5 years beginning at the age of 30 years	If previously treated with craniospinal irradiation performed every 3–5 years
Gynaecologist	Ovarian tumours	Ultrasound	Once at the age of 18 years	Every 3 years starting at age of 5 years	-
Cardiologist	Cardiac fibroma	Electrocardiogram	At the time of diagnosis of Gorlin syndrome, ideally in the first 6 months of life	At the time of diagnosis of Gorlin syndrome, ideally in the first 6 months of life	-

BCC, basal cell carcinoma; MRI, magnetic resonance imaging; RT, radiotherapy.

Rousseau et al. [215] and Verkouteren et al. [214] is listed in Table 4.

### 13. Primary prevention

#### 13.1. Sun protection and preventive measures

The mainstay of primary prevention consists of avoiding excessive exposure to UV, both natural from the sun and from artificial sources, due to the proven role of UV radiation in the development of BCC. A strong association between BCC development and the number of sunburns is documented [218]. Also, tanning bed users have an increased risk of BCC compared to non-tanning bed users, and the risk is even higher for individuals who use a tanning bed for the first time at the age of less than 20 years [31,219]. Exposure to excessive solar radiation can be reduced by seeking shade, wearing appropriate, covering clothes, and using sunscreens. The use of tanning beds should be avoided. UV-protection measures should be observed in particular by individuals at high-risk, as children and adolescents, subjects with sun-sensitive phototypes, with personal or family history of skin cancer, with immunosuppression and in individuals who spend extended time outdoors for professional or recreational activities. Patients diagnosed with BCC have an increased risk of developing further skin cancers [220,221]. Therefore, it is recommended that all BCC patients should be educated about the avoidance of excessive exposure to UV radiation, both solar and from sunbeds, and about regular skin surveillance.

#### 13.2. Chemoprevention

Regarding oral supplements, some studies have suggested that Mediterranean diet [222] and high caffeine intake [223] decrease the risk of BCC, although no conclusive evidence exists supporting a particular dietary pattern as preventive measure for BCC. Oral supplementation of antioxidants (selenium, vitamin A, beta-carotene) has not reduced the incidence of BCC in a meta-analysis of RCT and cannot be recommended [224]. Vitamin D should be supplemented if deficient, especially in individuals practicing consistent, comprehensive photoprotection. No further benefit of vitamin D supplementation has been proven yet for the prevention of BCC. Nicotinamide is a water-soluble form of vitamin B<sub>3</sub> (niacin) that is considered to play a role in enhancing the repair of photodamaged DNA and prevent the immune-inhibitory effects of UV radiation [225]. In a phase III RCT, oral nicotinamide 500 mg twice daily for 12 months was associated with a 20% reduction of the development rate of BCC in immunocompetent patients with previous multiple skin cancer history [226]. The effect appeared limited to the duration of treatment. Therefore, nicotinamide is a safe

**Box 23** Diagnosis—Gorlin syndrome.

Diagnosis—Gorlin syndrome	Consensus-based statement
GCP	The diagnosis of Gorlin syndrome is based on clinical criteria. Genetic testing for germline mutations in the Hedgehog pathway can be offered in selected cases Strength of consensus: 100%
GCP, good clinical practice.	

**Box 24** Management of Gorlin patients.

Management of Gorlin patients	Consensus-based statement
GCP	Treatment of patients with Gorlin syndrome requires a multidisciplinary approach. In selected patients, treatment with Hedgehog inhibitors can be considered. Strength of consensus: 100%
GCP, good clinical practice.	

and inexpensive solution that could be taken into consideration to enhance the prevention of BCC in this category of high-risk patients. Evidence is not sufficient to recommend nicotinamide for the primary prevention of BCC in the general population. In a recent 12 month, placebo-controlled trial, supplementation with oral nicotinamide did not lead to lower numbers of BCCs in immunosuppressed solid-organ transplant recipients [227]. While oral retinoids are used for the chemoprevention of SCC in high-risk patients, current evidence shows a low efficacy and does not support their use for the prevention of BCC, especially considering the benefits versus side-effects risk balance. A meta-analysis of 11 studies estimated a 10% risk reduction of BCC among patients using any NSAIDs (relative risk [RR], 0.90 [95% CI, 0.84–0.97]). A smaller, not statistically significant inverse association was observed for non-aspirin NSAIDs (RR, 0.93 [95% CI, 0.86–1.02]) [228]. These effects were strongest in the high-risk population with actinic keratoses or skin cancer history. The effect size was low, the studies heterogeneous, and more research is warranted on the dosing, timing, type, and potential confounders of the preventive effect of NSAIDs before a recommendation can be made regarding their use for the chemoprevention of BCC, especially taking into consideration their potential cardiovascular adverse effects on long-term use. There is currently no evidence supporting the efficacy of topical treatments, including tazarotene and tretinoin, for the primary prevention of BCC [229,230].

**14. Communication with patients**

When diagnosing BCC, it is important to explain to patients that these tumours are only locally invasive and

will not have any detrimental effects on survival unless in rare high-risk or advanced cases. Even though most tumours are growing slowly, the potential consequences of foregoing treatment should be explained. There may be a need to discuss surgery-associated morbidity as the psychological impact of disfiguring surgery cannot be underestimated. The patient should always be offered choices when treating BCC, where appropriate. This is especially relevant when different referral pathways lead patients to either surgical or dermatological services because the availability of different treatment modalities may differ between specialties. In elderly patients, the choice of curettage and cautery for BCC (when appropriate for low-risk BCCs) needs to be discussed, as this can also avoid more invasive surgical treatments with grafts and flaps. Patients who have had radiotherapy in the past are also at an increased risk of BCC on the irradiated site, mainly of low-risk and infundibolocystic subtype [231,232], and these patients cannot be treated with radiotherapy again for the risk of major complications. Therefore, it is important to check for previous radiotherapy in the field in the past medical history. Immunosuppressed patients with BCC should be followed up in dedicated clinics as these patients are at high risk of SCC as well. There are a lot of debates and controversial studies on the risks and benefits of increasing vitamin D intake in BCC patients. In a recent meta-analysis, it was ascertained that the literature supports keeping vitamin D serum levels below 30–60 nmol/L, considering it to be a balanced level [233]. Patients with BCC should be informed that they should remain vigilant and keep an eye for potential recurrences as well as new primaries. The risk of developing a second BCC is 10 times the risk of the general population [220]. If patients present with multiple



primaries at the onset, they should be warned that their risk of relapse is higher. Truncal BCCs, especially of the superficial types, often have multiple new primaries in the first 5 years after the original diagnosis [234]. There are patients who may need long-term follow-up, as discussed before, and these are likely to be those with high-risk tumours, high-risk sites, multiple BCCs, and Gorlin syndrome. Patients with Gorlin syndrome should be reassured as these patients often become highly anxious about having multiple skin cancers. Although they present with a large number of tumours from a young age, the BCCs usually are not as aggressive as sporadic BCCs. When proposing systemic treatment with HHI in Gorlin syndrome, patients should be made aware of the side-effects and the clinician should carefully weigh the advantages and disadvantages of such treatments on a case-by-case basis. Most Gorlin patients treated with HHI do not stay on the drug for more than 6 months as significant side-effects are common (especially muscle cramps), and these may be severe [188]. These agents are therefore unlikely to be the answer for long-term management, and intermittent dosing should be openly discussed with patients. The use of non-surgical options is especially important in Gorlin patients and needs to be considered as much as possible and discussed at every visit with the patient. In suspected Gorlin syndrome, there is also a need to discuss potential genetic testing. Gorlin families have a small increased risk of other rare cancers, so it is important that the family is aware of this, as any unusual symptoms in the future need to be taken seriously with earlier detection of cancers [235].

## Funding

None.

## CRedit authorship contribution statement

**Ketty Peris:** Conceptualization; Writing – review & editing; Writing – original draft; Supervision. **Maria Concetta Fagnoli:** Conceptualization; Writing – review & editing; Writing – Original draft; Supervision. **Roland Kaufmann:** Conceptualization; Writing – review & editing; Supervision. **Petr Arenberger:** Conceptualization; Writing – review & editing; Supervision. **Lars Bastholt:** Conceptualization; Writing – review & editing; Supervision. **Nicole Basset Seguin:** Conceptualization; Writing – review & editing; Supervision. **Veronique Bataille:** Conceptualization; Writing – review & editing; Supervision. **Lieve Brochez:** Conceptualization; Writing – review & editing; Supervision. **Veronique del Marmol:** Conceptualization; Writing – review & editing; Supervision. **Reinhard Dummer:** Conceptualization; Writing – review & editing; Supervision. **Ana-Marie Forsea:** Conceptualization; Writing – review & editing; Supervision. **Caroline Gaudy-Marqueste:** Conceptualization; Writing – review & editing; Supervision.

**Catherine A. Harwood:** Conceptualization; Writing – review & editing; Supervision. **Axel Hauschild:** Conceptualization; Writing – review & editing; Supervision. **Christoph Höller:** Conceptualization; Writing – review & editing; Supervision. **Lidija Kandolf:** Conceptualization; Writing – review & editing; Supervision. **Nicole W. J. Kellerners-Smeets:** Conceptualization; Writing – review & editing; Supervision. **Aimilios Lallas:** Conceptualization; Writing – review & editing; Supervision. **Ulrike Leiter:** Conceptualization; Writing – review & editing; Supervision. **Joseph Malvey:** Conceptualization; Writing – review & editing; Supervision. **Branka Marinović:** Conceptualization; Writing – review & editing; Supervision. **Zeljko Mijuskovic:** Conceptualization; Writing – review & editing; Supervision. **David Moreno-Ramirez:** Conceptualization; Writing – review & editing; Supervision. **Eduardo Nagore:** Conceptualization; Writing – review & editing; Supervision. **Paul Nathan:** Conceptualization; Writing – review & editing; Supervision. **Alexander J. Stratigos:** Conceptualization; Writing – review & editing; Supervision. **Eggert Stockfleth:** Conceptualization; Writing – review & editing; Supervision. **Luca Tagliaferri:** Conceptualization; Writing – review & editing; Supervision. **Myrto Trakatelli:** Conceptualization; Writing – review & editing; Supervision. **Ricardo Vieira:** Conceptualization; Writing – review & editing; Supervision. **Iris Zalaudek:** Conceptualization; Writing – review & editing; Supervision. **Claus Garbe:** Conceptualization; Writing – review & editing; Writing – original draft; Supervision.

## Declaration of Competing Interest

The authors declare that they have no known competing financial interests or personal relationships that could have appeared to influence the work reported in this paper.

## Appendix

<sup>A</sup> European Association of Dermato-Oncology, <sup>B</sup> European Dermatology Forum, <sup>C</sup> European Society for Radiotherapy and Oncology, <sup>D</sup> European Union of Medical Specialists (Union Européenne des Médecins Spécialistes), <sup>E</sup> European Academy of Dermatology and Venereology.

## References

- [1] Peris K, Fagnoli MC, Garbe C, Kaufmann R, Bastholt L, Seguin NB, et al. European Dermatology Forum (EDF), the European Association of Dermato-Oncology (EADO), the European Organization for Research and Treatment of Cancer (EORTC). Diagnosis and treatment of basal cell carcinoma: European consensus-based interdisciplinary guidelines. *Eur J Cancer* 2019;118:10–34. <https://doi.org/10.1016/j.ejca.2019.06.003>.
- [2] Nasr I, McGrath EJ, Harwood CA, Botting J, Buckley P, Budny PG, et al. British Association of Dermatologists' Clinical Standards Unit. *British Association of Dermatologists*

- guidelines for the management of adults with basal cell carcinoma 2021. *Br J Dermatol* 2021;185:899–920. <https://doi.org/10.1111/bjd.20524>.
- [3] Brouwers MC, Kho ME, Browman GP, Burgers JS, Cluzeau F, Feder G, et al. AGREE Next Steps Consortium. AGREE II: advancing guideline development, reporting and evaluation in health care. *CMAJ* 2010;182:e839–42. <https://doi.org/10.1503/cmaj.090449>.
- [4] Youssef KK, Van Keymeulen A, Lapouge G, Beck B, Michaux C, Achouri Y, et al. Identification of the cell lineage at the origin of basal cell carcinoma. *Nat Cell Biol* 2010;12:299–305. <https://doi.org/10.1038/ncb2031>.
- [5] Wang GY, Wang J, Mancianti ML, Epstein Jr. EH. Basal cell carcinomas arise from hair follicle stem cells in Ptlh1(+/-) mice. *Cancer Cell* 2011;19:114–24. <https://doi.org/10.1016/j.ccr.2010.11.007>.
- [6] Peterson SC, Eberl M, Vagnozzi AN, Belkadi A, Veniaminova NA, Verhaegen ME, et al. Basal cell carcinoma preferentially arises from stem cells within hair follicle and mechanosensory niches. *Cell Stem Cell* 2015;16:400–12. <https://doi.org/10.1016/j.stem.2015.02.006>.
- [7] Lomas A, Leonardi-Bee J, Bath-Hextall F. A systematic review of worldwide incidence of nonmelanoma skin cancer. *Br J Dermatol* 2012;166:1069–80. <https://doi.org/10.1111/j.1365-2133.2012.10830.x>.
- [8] Leiter U, Eigentler T, Garbe C. Epidemiology of skin cancer. *Adv Exp Med Biol* 2014;810:120–40. [https://doi.org/10.1007/978-1-4939-0437-2\\_7](https://doi.org/10.1007/978-1-4939-0437-2_7).
- [9] Rogers HW, Weinstock MA, Feldman SR, Coldiron BM. Incidence estimate of nonmelanoma skin cancer (keratinocyte carcinomas) in the U.S. population, 2012. *JAMA Dermatol* 2015;151:1081–6. <https://doi.org/10.1001/jamadermatol.2015.1187>.
- [10] Cameron MC, Lee E, Hibler BP, Barker CA, Mori S, Cordova M, et al. Basal cell carcinoma: epidemiology; pathophysiology; clinical and histological subtypes; and disease associations. *J Am Acad Dermatol* 2019;80:303–17. <https://doi.org/10.1016/j.jaad.2018.03.060>.
- [11] Basset-Seguín N, Herms F. Update in the management of basal cell carcinoma. *Acta Derm Venereol* 2020;100:adv00140 <https://doi.org/10.2340/00015555-3495>.
- [12] Backman E, Oxelblom M, Gillstedt M, Dahlén Gyllencreutz J, Paoli J. Basal cell carcinoma: epidemiological impact of clinical versus histopathological diagnosis. *J Eur Acad Dermatol Venereol* 2023;37:521–7. <https://doi.org/10.1111/jdv.18774>.
- [13] Richmond-Sinclair NM, Pandeya N, Ware RS, Neale RE, Williams GM, van der Pols JC, et al. Incidence of basal cell carcinoma multiplicity and detailed anatomic distribution: longitudinal study of an Australian population. *J Invest Dermatol* 2009;129:323–8. <https://doi.org/10.1038/jid.2008.234>. Epub 2008 Jul 31.
- [14] Dessinioti C, Antoniou C, Katsambas A, Stratigos AJ. Basal cell carcinoma: what's new under the sun. *Photochem Photobiol* 2010;86:481–91. <https://doi.org/10.1111/j.1751-1097.2010.00735.x>.
- [15] Verkouteren JAC, Ramdas KHR, Wakkee M, Nijsten T. Epidemiology of basal cell carcinoma: scholarly review. *Br J Dermatol* 2017;177:359–72. <https://doi.org/10.1111/bjd.15321>.
- [16] Birch-Johansen F, Jensen A, Mortensen L, Olesen AB, Kjær SK. Trends in the incidence of nonmelanoma skin cancer in Denmark 1978–2007: rapid incidence increase among young Danish women. *Int J Cancer* 2010;127:2190–8. <https://doi.org/10.1002/ijc.25411>.
- [17] Kappelin J, Green AC, Ingvar Å, Ahnlied I, Nielsen K. Incidence and trends of basal cell carcinoma in Sweden: a population-based registry study. *Br J Dermatol* 2022;186:963–9. <https://doi.org/10.1111/bjd.20964>.
- [18] Schreuder K, Hollestein L, Nijsten TEC, Wakkee M, Louwman MWJ. A nationwide study of the incidence and trends of first and multiple basal cell carcinomas in the Netherlands and prediction of future incidence. *Br J Dermatol* 2022;186:476–84. <https://doi.org/10.1111/bjd.20871>.
- [19] Wehner MR, Cidre Serrano W, Nosrati A, Schoen PM, Chren MM, Boscardin J, et al. All-cause mortality in patients with basal and squamous cell carcinoma: a systematic review and meta-analysis. *J Am Acad Dermatol* 2018;78:663–672.e3. <https://doi.org/10.1016/j.jaad.2017.11.026>.
- [20] Flohil SC, van der Leest RJ, Arends LR, de Vries E, Nijsten T. Risk of subsequent cutaneous malignancy in patients with prior keratinocyte carcinoma: a systematic review and meta-analysis. *Eur J Cancer* 2013;49:2365–75. <https://doi.org/10.1016/j.ejca.2013.03.010>.
- [21] Verkouteren JAC, Smedinga H, Steyerberg EW, Hofman A, Nijsten T. Predicting the risk of a second basal cell carcinoma. *J Invest Dermatol* 2015;135:2649–56. <https://doi.org/10.1038/jid.2015.244>.
- [22] Kuo KY, Batra P, Cho HG, Li S, Chahal HS, Rieger KE, et al. Correlates of multiple basal cell carcinoma in a retrospective cohort study: sex, histologic subtypes, and anatomic distribution. *J Am Acad Dermatol* 2017;77:233–234.e2. <https://doi.org/10.1016/j.jaad.2017.02.047>.
- [23] Saldanha G, Ording AG, Bylsma LC, Darvalics B, Solis D, Tang JY, et al. High-frequency basal cell carcinoma in Danish patients: prevalence and consistency. *J Eur Acad Dermatol Venereol* 2020;34:e646–8. <https://doi.org/10.1111/jdv.16512>.
- [24] Chiang A, Solis DC, Rogers H, Sohn GK, Cho HG, Saldanha G, et al. Prevalence and risk factors for high-frequency basal cell carcinoma in the United States. *J Am Acad Dermatol* 2021;84:1493–5. <https://doi.org/10.1016/j.jaad.2020.07.088>.
- [25] Goldenberg G, Karagiannis T, Palmer JB, Lotya J, O'Neill C, Kisa R, et al. Incidence and prevalence of basal cell carcinoma (BCC) and locally advanced BCC (LABCC) in a large commercially insured population in the United States: a retrospective cohort study. *J Am Acad Dermatol* 2016;75:957–966.e2. <https://doi.org/10.1016/j.jaad.2016.06.020>.
- [26] Bisceglia M, Panniello G, Galliani CA, Centola M, D'Errico MM, Minenna E, et al. Metastatic basal cell carcinoma of the skin: a comprehensive literature review, including advances in molecular therapeutics. *Adv Anat Pathol* 2020;27:331–53. <https://doi.org/10.1097/PAP.0000000000000267>.
- [27] Dreier J, Cheng PF, Bogdan Alleman I, Gugger A, Hafner J, Tschopp A, et al. Basal cell carcinomas in a tertiary referral centre: a systematic analysis. *Br J Dermatol* 2014;171:1066–72. <https://doi.org/10.1111/bjd.13217>.
- [28] Atwood SX, Sarin KY, Whitson RJ, Li JR, Kim G, Rezaee M, et al. Smoothed variants explain the majority of drug resistance in basal cell carcinoma. *Cancer Cell* 2015;27:342–53. <https://doi.org/10.1016/j.ccell.2015.02.002>.
- [29] Sharpe HJ, Pau G, Dijkgraaf GJ, Basset-Seguín N, Modrusan Z, Januario T, et al. Genomic analysis of smoothed inhibitor resistance in basal cell carcinoma. *Cancer Cell* 2015;27:327–41. <https://doi.org/10.1016/j.ccell.2015.02.001>.
- [30] Pellegrini C, Maturo MG, Di Nardo L, Ciciarelli V, Gutiérrez García-Rodrigo C, Fargnoli MC. Understanding the molecular genetics of basal cell carcinoma. *Int J Mol Sci* 2017;18:2485. <https://doi.org/10.3390/ijms18112485>.
- [31] Wehner MR, Shive ML, Chren MM, Han J, Qureshi AA, Linos E. Indoor tanning and non-melanoma skin cancer: systematic review and meta-analysis. *BMJ* 2012;345:e5909 <https://doi.org/10.1136/bmj.e5909>.
- [32] An S, Kim K, Moon S, Ko KP, Kim I, Lee JE, et al. Indoor tanning and the risk of overall and early-onset melanoma and non-melanoma skin cancer: systematic review and meta-analysis. *Cancers ((Basel))* 2021;13:5940. <https://doi.org/10.3390/cancers13235940>.
- [33] Dessinioti C, Stratigos AJ. An epidemiological update on indoor tanning and the risk of skin cancers. *Curr Oncol* 2022;29:8886–903. <https://doi.org/10.3390/curroncol29110699>.

- [34] Tagliabue E, Fargnoli MC, Gandini S, Maisonneuve P, Liu F, Kayser M, et al. M-SKIP Study Group. MC1R gene variants and non-melanoma skin cancer: a pooled-analysis from the M-SKIP project. *Br J Cancer* 2015;113:354–63. <https://doi.org/10.1038/bjc.2015.231>.
- [35] Yauch RL, Dijkgraaf GJ, Alicke B, Januario T, Ahn CP, Holcomb T, et al. Smoothed mutation confers resistance to a Hedgehog pathway inhibitor in medulloblastoma. *Science* 2009;326(5952):572–4. <https://doi.org/10.1126/science.1179386>.
- [36] Yuan Y, Salinas Parra N, Chen Q, Iglesias-Bartolome R. Oncogenic Hedgehog-smoothened signaling depends on YAP1-TAZ/TEAD transcription to restrain differentiation in basal cell carcinoma. *J Invest Dermatol* 2022;142:65–76.e7. <https://doi.org/10.1016/j.jid.2021.06.020>.
- [37] Yurchenko AA, Pop OT, Ighlahriz M, Padioleau I, Rajabi F, Sharpe HJ, et al. Frequency and genomic aspects of intrinsic resistance to vismodegib in locally advanced basal cell carcinoma. *Clin Cancer Res* 2022;28:1422–32. <https://doi.org/10.1158/1078-0432.CCR-21-3764>.
- [38] Hall ET, Fernandez-Lopez E, Silk AW, Dummer R, Bhatia S. Immunologic characteristics of nonmelanoma skin cancers: implications for immunotherapy. *Am Soc Clin Oncol Educ Book* 2020;40:1–10. [https://doi.org/10.1200/EDBK\\_278953](https://doi.org/10.1200/EDBK_278953).
- [39] Heppt MV, Gebhardt C, Hassel JC, Alter M, Gutzmer R, Leiter U, et al. Long-term management of advanced basal cell carcinoma: current challenges and future perspectives. *Cancers (Basel)* 2022;14:4547. <https://doi.org/10.3390/cancers14194547>.
- [40] Lehmann J, Seebode C, Martens MC, Emmert S. *Xeroderma pigmentosum* - facts and perspectives. *Anticancer Res* 2018;38:1159–64. <https://doi.org/10.21873/anticancer.12335>.
- [41] AlSabbagh MM, Baqi MA. Bazex-Duprè-Christol syndrome: review of clinical and molecular aspects. *Int J Dermatol* 2018;57:1102–6. <https://doi.org/10.1111/ijd.14065>.
- [42] Liu Y, Banka S, Huang Y, Hardman-Smart J, Pye D, Torrello A, et al. Germline intergenic duplications at Xq26.1 underlie Bazex-Duprè-Christol basal cell carcinoma susceptibility syndrome. *Br J Dermatol* 2022;187:948–61. <https://doi.org/10.1111/bjd.21842>.
- [43] Krakowski AC, Hafeez F, Westheim A, Pan EY, Wilson M. Advanced basal cell carcinoma: what dermatologists need to know about diagnosis. *J Am Acad Dermatol* 2022;86(6S):S1–13. <https://doi.org/10.1016/j.jaad.2022.03.023>.
- [44] Grob JJ, Guminski A, Malvey J, Basset-Seguín N, Bertrand B, Fernandez-Penas P, et al. Position statement on classification of basal cell carcinomas. Part 1: unsupervised clustering of experts as a way to build an operational classification of advanced basal cell carcinoma based on pattern recognition. *J Eur Acad Dermatol Venereol* 2021;35:1949–56. <https://doi.org/10.1111/jdv.17466>.
- [45] Grob JJ, Gaudy-Marqueste C, Guminski A, Malvey J, Basset-Seguín N, Bertrand B, et al. Position statement on classification of basal cell carcinomas. Part 2: EADO proposal for new operational staging system adapted to basal cell carcinomas. *J Eur Acad Dermatol Venereol* 2021;35:2149–53. <https://doi.org/10.1111/jdv.17467>.
- [46] Reiter O, Mimouni I, Gdalevich M, Marghoob AA, Levi A, Hodak E, et al. The diagnostic accuracy of dermoscopy for basal cell carcinoma: a systematic review and meta-analysis. *J Am Acad Dermatol* 2019;80:1380–8. <https://doi.org/10.1016/j.jaad.2018.12.026>.
- [47] Roozeboom MH, Kreukels H, Nelemans PJ, Mosterd K, Winnepenninckx VJ, Abdul Hamid MA, et al. Subtyping basal cell carcinoma by clinical diagnosis versus punch biopsy. *Acta Derm Venereol* 2015;95:996–8. <https://doi.org/10.2340/00015555-2113>.
- [48] Altamura D, Menzies SW, Argenziano G, Zalaudek I, Soyer HP, Sera F, et al. Dermoscopy of basal cell carcinoma: morphologic variability of global and local features and accuracy of diagnosis. *J Am Acad Dermatol* 2010;62:67–75. <https://doi.org/10.1016/j.jaad.2009.05.035>.
- [49] Navarrete-Dechent C, Liopyris K, Rishpon A, Marghoob NG, Cordova M, Dusza SW, et al. Association of multiple aggregated yellow-white globules with nonpigmented basal cell carcinoma. *JAMA Dermatol* 2020;156:882–90. <https://doi.org/10.1001/jamadermatol.2020.1450>.
- [50] Zalaudek I, Moscarella E, Longo C, de Pace B, Argenziano G. The "signature" pattern of multiple Basal cell carcinomas. *Arch Dermatol* 2012;148:1106. <https://doi.org/10.1001/archdermatol.2012.2228>.
- [51] Reiter O, Mimouni I, Dusza S, Halpern AC, Leshem YA, Marghoob AA. Dermoscopic features of basal cell carcinoma and its subtypes: a systematic review. *J Am Acad Dermatol* 2021;85:653–64. <https://doi.org/10.1016/j.jaad.2019.11.008>.
- [52] Suppa M, Micantonio T, Di Stefani A, Soyer HP, Chimenti S, Fargnoli MC, et al. Dermoscopic variability of basal cell carcinoma according to clinical type and anatomic location. *J Eur Acad Dermatol Venereol* 2015;29:1732–41. <https://doi.org/10.1111/jdv.12980>.
- [53] Ahnslide I, Zalaudek I, Nilsson F, Bjellerup M, Nielsen K. Preoperative prediction of histopathological outcome in basal cell carcinoma: flat surface and multiple small erosions predict superficial basal cell carcinoma in lighter skin types. *Br J Dermatol* 2016;175:751–61. <https://doi.org/10.1111/bjd.14499>.
- [54] Lallas A, Tzellos T, Kyrgidis A, Apalla Z, Zalaudek I, Karatolias A, et al. Accuracy of dermoscopic criteria for discriminating superficial from other subtypes of basal cell carcinoma. *J Am Acad Dermatol* 2014;70:303–11. <https://doi.org/10.1016/j.jaad.2013.10.003>.
- [55] Conforti C, Giuffrida R, Zalaudek I, Guarneri F, Cannavò SP, Pizzichetta MA, et al. Dermoscopic findings in the presurgical evaluation of basal cell carcinoma. A prospective study. *Dermatol Surg* 2021;47:e37–41. <https://doi.org/10.1097/DSS.0000000000002471>.
- [56] Sgouros D, Apalla Z, Theofilis M, Damaskou V, Kokkalis G, Kitsiou E, et al. How to spot a basosquamous carcinoma: a study on demographics, clinical-dermatoscopic features and histopathological correlations. *Eur J Dermatol* 2021;31:779–84. <https://doi.org/10.1684/ejd.2021.4178>.
- [57] Giacomel J, Lallas A, Argenziano G, Reggiani C, Piana S, Apalla Z, et al. Dermoscopy of basosquamous carcinoma. *Br J Dermatol* 2013;169:358–64. <https://doi.org/10.1111/bjd.12394>.
- [58] Apalla Z, Lallas A, Tzellos T, Sidiropoulos T, Lefaki I, Trakatelli M, et al. Applicability of dermoscopy for evaluation of patients' response to nonablative therapies for the treatment of superficial basal cell carcinoma. *Br J Dermatol* 2014;170:809–15. <https://doi.org/10.1111/bjd.12749>.
- [59] Conforti C, Pizzichetta MA, Vichi S, Toffolutti F, Serraino D, Di Meo N, et al. Sclerodermiform basal cell carcinomas vs. other histotypes: analysis of specific demographic, clinical and dermoscopic features. *J Eur Acad Dermatol Venereol* 2021;35:79–87. <https://doi.org/10.1111/jdv.16597>.
- [60] Que SKT. Research techniques made simple: noninvasive imaging technologies for the delineation of basal cell carcinomas. *J Invest Dermatol* 2016;136:e33–8. <https://doi.org/10.1016/j.jid.2016.02.012>. PMID: 27012561.
- [61] Venturini M, Gualdi G, Zanca A, Lorenzi L, Pellacani G, Calzavara-Pinton PG. A new approach for presurgical margin assessment by reflectance confocal microscopy of basal cell carcinoma. *Br J Dermatol* 2016;174:380–5. <https://doi.org/10.1111/bjd.14244>.
- [62] Edwards SJ, Osei-Assibey G, Patalay R, Wakefield V, Karner C. Diagnostic accuracy of reflectance confocal microscopy using VivaScope for detecting and monitoring skin lesions: a systematic review. *Clin Exp Dermatol* 2017;42:266–75. <https://doi.org/10.1111/ced.13055>.



- [63] Guitera P, Menzies SW, Longo C, Cesinaro AM, Scolyer RA, Pellacani G. In vivo confocal microscopy for diagnosis of melanoma and basal cell carcinoma using a two-step method: analysis of 710 consecutive clinically equivocal cases. *J Invest Dermatol* 2012;132:2386–94. <https://doi.org/10.1038/jid.2012.172>.
- [64] Kadouch DJ, Schram ME, Leeflang MM, Limpens J, Spuls PI, de Rie MA. In vivo confocal microscopy of basal cell carcinoma: a systematic review of diagnostic accuracy. *J Eur Acad Dermatol Venereol* 2015;29:1890–7. <https://doi.org/10.1111/jdv.13224>.
- [65] Kadouch DJ, Elshot YS, Zupan-Kajcovski B, van Haersma de With ASE, van der Wal AC, et al. One-stop-shop with confocal microscopy imaging vs. standard care for surgical treatment of basal cell carcinoma: an open-label, noninferiority, randomized controlled multicentre trial. *Br J Dermatol* 2017;177:735–41. <https://doi.org/10.1111/bjd.15559>.
- [66] Segura S, Puig S, Carrera C, Lecha M, Borges V, Malvehy J. Non-invasive management of non-melanoma skin cancer in patients with cancer predisposition genodermatosis: a role for confocal microscopy and photodynamic therapy. *J Eur Acad Dermatol Venereol* 2011;25:819–27. <https://doi.org/10.1111/j.1468-3083.2010.03871.x>.
- [67] Zou Y, Zhu X, Xia R. Reflectance confocal microscopy follow-up of multifocal superficial basal cell carcinomas treated with imiquimod 5% cream. *Dermatol Pract Concept* 2022 1;12(4):e2022207 <https://doi.org/10.5826/dpc.1204a207>.
- [68] Reddy N, Nguyen BT. The utility of optical coherence tomography for diagnosis of basal cell carcinoma: a quantitative review. *Br J Dermatol* 2019;180:475–83. <https://doi.org/10.1111/bjd.17201>.
- [69] Ferrante di Ruffano L, Takwoingi Y, Dinnes J, Chuchu N, Bayliss SE, Davenport C, et al. Cochrane Skin Cancer Diagnostic Test Accuracy Group. Computer-assisted diagnosis techniques (dermoscopy and spectroscopy-based) for diagnosing skin cancer in adults. *Cochrane Database Syst Rev* 2018;12:CD013186 <https://doi.org/10.1002/14651858.CD013186>.
- [70] Adan F, Mosterd K, Kelleners-Smeets NWJ, Nelemans PJ. Diagnostic value of optical coherence tomography image features for diagnosis of basal cell carcinoma. *Acta Derm Venereol* 2021;101:adv00607 <https://doi.org/10.2340/actadv.v101.421>.
- [71] Adan F, Nelemans PJ, Essers BAB, Brinkhuizen T, Dodemont SRP, Kessels JPHM, et al. Optical coherence tomography versus punch biopsy for diagnosis of basal cell carcinoma: a multicentre, randomised, non-inferiority trial. *Lancet Oncol* 2022;23:1087–96. [https://doi.org/10.1016/S1470-2045\(22\)00347-3](https://doi.org/10.1016/S1470-2045(22)00347-3).
- [72] Sahu A, Yélamos O, Iftimia N, Cordova M, Alessi-Fox C, Gill M, et al. Evaluation of a combined reflectance confocal microscopy-optical coherence tomography device for detection and depth assessment of basal cell carcinoma. *JAMA Dermatol* 2018;154:1175–83. <https://doi.org/10.1001/jamadermatol.2018.2446>.
- [73] Gill M, Sahu A, Alessi-Fox C, Cordova M, Gonzalez S, Iftimia N, et al. Angulated small nests and cords: key diagnostic histopathologic features of infiltrative basal cell carcinoma can be identified using integrated reflectance confocal microscopy-optical coherence tomography. *J Cutan Pathol* 2021;48:53–65. <https://doi.org/10.1111/cup.13871>.
- [74] Aleissa S, Navarrete-Dechent C, Cordova M, Sahu A, Dusza SW, Phillips W, et al. Presurgical evaluation of basal cell carcinoma using combined reflectance confocal microscopy-optical coherence tomography: a prospective study. *J Am Acad Dermatol* 2020;82:962–8. <https://doi.org/10.1016/j.jaad.2019.10.028>.
- [75] Suppa M, Fontaine M, Dejonckheere G, Cinotti E, Yélamos O, Diet G, et al. Line-field confocal optical coherence tomography of basal cell carcinoma: a descriptive study. *J Eur Acad Dermatol Venereol* 2021;35:1099–110. <https://doi.org/10.1111/jdv.17078>.
- [76] Ruini C, Schuh S, Gust C, Kendziora B, Frommherz L, French LE, et al. Line-field optical coherence tomography: in vivo diagnosis of basal cell carcinoma subtypes compared with histopathology. *Clin Exp Dermatol* 2021;46:1471–81. <https://doi.org/10.1111/ced.14762>.
- [77] Verzi AE, Micali G, Lacarrubba F. Line-field confocal optical coherence tomography may enhance monitoring of superficial basal cell carcinoma treated with imiquimod 5% cream: a pilot study. *Cancers* 2021;13:4913. <https://doi.org/10.3390/cancers13194913>.
- [78] Cinotti E, Brunetti T, Cartocci A, Tognetti L, Suppa M, Malvehy J, et al. Diagnostic accuracy of line-field confocal optical coherence tomography for the diagnosis of skin carcinomas. *Diagnostics* 2023;13:361. <https://doi.org/10.3390/diagnostics13030361>.
- [79] Elder E, Massi D, Scolyer RA, Willemze R. WHO classification of skin tumors. Lyon: IARC.; 2018.
- [80] Fernández-Figueras MT, Malvehy J, Tschandl P, Rutten A, Rongioletti F, Requena L, et al. Study Group Collaborators (Validation Group). Position paper on a simplified histopathological classification of basal cell carcinoma: results of the European Consensus Project. *J Eur Acad Dermatol Venereol* 2022;36:351–9. <https://doi.org/10.1111/jdv.17849>. Epub 2021 Dec 21. PMID: 34931722.
- [81] Chen J, Ruczinski I, Jorgensen TJ, Yenokyan G, Yao Y, Alani R, et al. Nonmelanoma skin cancer and risk for subsequent malignancy. *J Natl Cancer Inst* 2008;100:1215–22. <https://doi.org/10.1093/jnci/djn260>.
- [82] Kofler L, Breuninger H, Schreiber RH, Eichner M, Häfner HM, Schnabl SM. Three-dimensional histology vs. serial section histology in the treatment of primary basal cell carcinoma: a randomized, prospective, blinded study of 569 tumours. *J Eur Acad Dermatol Venereol* 2021;35:1323–30. <https://doi.org/10.1111/jdv.17155>.
- [83] Thomson J, Hogan S, Leonardi-Bee J, Williams HC, Bath-Hextall FJ. Interventions for basal cell carcinoma: abridged Cochrane systematic review and GRADE assessments. *Br J Dermatol* 2021;185:499–511. <https://doi.org/10.1111/bjd.19809>.
- [84] Lacerda PN, Lange EP, Luna NM, Miot HA, Nogueira VSN, Abbade LPF. Recurrence rate of basal cell carcinoma among different micrographic surgery techniques: systematic review with meta-analysis. *J Eur Acad Dermatol Venereol* 2022;36:1178–90. <https://doi.org/10.1111/jdv.18048>.
- [85] Fraga SD, Besaw RJ, Murad F, Schmults CD, Waldman A. Complete margin assessment versus sectional assessment in surgically excised high-risk keratinocyte carcinomas: a systematic review and meta-analysis. *Dermatol Surg* 2022;48:704–10. <https://doi.org/10.1097/DSS.0000000000003462>.
- [86] Fukumoto T, Fukumoto R, Oka M, Horita N. Comparing treatments for basal cell carcinoma in terms of long-term treatment-failure: a network meta-analysis. *J Eur Acad Dermatol Venereol* 2019;33:2050–7. <https://doi.org/10.1111/jdv.15796>.
- [87] Nahhas AF, Scarbrough CA, Trotter S. A review of the global guidelines on surgical margins for nonmelanoma skin cancers. *J Clin Aesthet Dermatol* 2017;1:37–46.
- [88] Lang BM, Balermipas P, Bauer A, Blum A, Brölsch GF, Dirschka T, et al. S2k guidelines for cutaneous basal cell carcinoma - part 2: treatment, prevention and follow-up. *J Dtsch Dermatol Ges* 2019;17:214–30. <https://doi.org/10.1111/ddg.13755>.
- [89] Gulleth Y, Goldberg N, Silverman RP, Gastman BR. What is the best surgical margin for a Basal cell carcinoma: a meta-analysis of the literature. *Plast Reconstr Surg* 2010;126:1222–31. <https://doi.org/10.1097/PRS.0b013e3181ea450d>.
- [90] Kuijpers DI, Thissen MR, Neumann MH. Basal cell carcinoma: treatment options and prognosis, a scientific approach to a common malignancy. *Am J Clin Dermatol* 2002;3:247–59. <https://doi.org/10.2165/00128071-200203040-00003>.



- [91] Ito T, Inatomi Y, Nagae K, Nakano-Nakamura M, Nakahara T, Furue M, et al. Narrow-margin excision is a safe, reliable treatment for well-defined, primary pigmented basal cell carcinoma: an analysis of 288 lesions in Japan. *J Eur Acad Dermatol Venereol* 2015;29:1828–31. <https://doi.org/10.1111/jdv.12689>.
- [92] Lin SH, Cheng YW, Yang YC, Ho JC, Lee CH. Treatment of pigmented basal cell carcinoma with 3 mm surgical margin in Asians. *Biomed Res Int* 2016;2016:7682917 <https://doi.org/10.1155/2016/7682917>.
- [93] Kim ES, Yang CE, Chung YK. Does reduction of the oncologic safety margin for facial basal cell carcinoma result in higher recurrence rates? *Arch Craniofac Surg* 2021;22:135–40. <https://doi.org/10.7181/acfs.2021.00206>.
- [94] Lupu M, Voiculescu VM, Caruntu A, Tebeica T, Caruntu C. Preoperative evaluation through dermoscopy and reflectance confocal microscopy of the lateral excision margins for primary basal cell carcinoma. *Diagnostics* 2021;11:120. <https://doi.org/10.3390/diagnostics11010120>.
- [95] Kerns MJ, Darst MA, Olsen TG, Fenster M, Hall P, Grevey S. Shrinkage of cutaneous specimens: formalin or other factors involved? *J Cutan Pathol* 2008;35:1093–6. <https://doi.org/10.1111/j.1600-0560.2007.00943.x>.
- [96] Blasco-Morente G, Garrido-Colmenero C, Pérez-López I, Carretero-García S, Martín-Castro A, Arias-Santiago S, et al. Study of shrinkage of cutaneous surgical specimens. *J Cutan Pathol* 2015;42:253–7. <https://doi.org/10.1111/cup.12401>.
- [97] Löser CR, Rompel R, Möhrle M, Häfner HM, Kunte C, Hassel J, et al. S1 guideline: microscopically controlled surgery (MCS). *J Dtsch Dermatol Ges* 2015;13:942–51. <https://doi.org/10.1111/ddg.12665>.
- [98] Kauvar AN, Cronin Jr. T, Roenigk R, Hruza G, Bennett R, American Society for Dermatologic Surgery. Consensus for non-melanoma skin cancer treatment: basal cell carcinoma, including a cost analysis of treatment methods. *Dermatol Surg* 2015;41:550–71. <https://doi.org/10.1097/DSS.0000000000000296>.
- [99] van Loo E, Mosterd K, Krekels GA, Roozeboom MH, Ostertag JU, Dirksen CD, et al. Surgical excision versus Mohs' micrographic surgery for basal cell carcinoma of the face: a randomised clinical trial with 10 year follow-up. *Eur J Cancer* 2014;50:3011–20. <https://doi.org/10.1016/j.ejca.2014.08.018>.
- [100] Wain RA, Tehrani H. Reconstructive outcomes of Mohs surgery compared with conventional excision: a 13-month prospective study. *J Plast Reconstr Aesthet Surg* 2015;68:946–52. <https://doi.org/10.1016/j.bjps.2015.03.012>.
- [101] Alsaif A, Hayre A, Karam M, Rahman S, Abdul Z, Matteucci P. Mohs micrographic surgery versus standard excision for basal cell carcinoma in the head and neck: systematic review and meta-analysis. *Cureus* 2021;13:e19981 <https://doi.org/10.7759/cureus.19981>.
- [102] Ad Hoc Task Force, Connolly SM, Baker DR, Coldiron BM, Fazio MJ, Storrs PA, Vidimos AT, et al. AAD/ACMS/ASDSA/ASMS 2012 appropriate use criteria for Mohs micrographic surgery: a report of the American Academy of Dermatology, American College of Mohs Surgery, American Society for Dermatologic Surgery Association, and the American Society for Mohs Surgery. *J Am Acad Dermatol* 2012;67:531–50. <https://doi.org/10.1016/j.jaad.2012.06.009>.
- [103] Hoorens I, Batteuw A, Van Maele G, Lapierre K, Boone B, Ongenaes K. Mohs micrographic surgery for basal cell carcinoma: evaluation of the indication criteria and predictive factors for extensive subclinical spread. *Br J Dermatol* 2016;174:847–52. <https://doi.org/10.1111/bjd.14308>.
- [104] Dika E, Veronesi G, Patrizi A, De Salvo S, Misciali C, Baraldi C, et al. It's time for Mohs: micrographic surgery for the treatment of high-risk basal cell carcinomas of the head and neck regions. *Dermatol Ther* 2020;33:e13474 <https://doi.org/10.1111/dth.13474>.
- [105] Brown AC, Brindley L, Hunt WTN, Earp EM, Veitch D, Mortimer NJ, et al. A review of the evidence for Mohs micrographic surgery. Part 2: basal cell carcinoma. *Clin Exp Dermatol* 2022;47:1794–804. <https://doi.org/10.1111/ced.15266>.
- [106] Silverman MK, Kopf AW, Bart RS, Grin CM, Levenstein MS. Recurrence rates of treated basal cell carcinomas. Part 3: surgical excision. *J Dermatol Surg Oncol* 1992;18:471–6. <https://doi.org/10.1111/j.1524-4725.1992.tb03307.x>.
- [107] Mosterd K, Krekels GA, Nieman FH, Ostertag JU, Essers BA, Dirksen CD, et al. Surgical excision versus Mohs' micrographic surgery for primary and recurrent basal-cell carcinoma of the face: a prospective randomised controlled trial with 5-years' follow-up. *Lancet Oncol* 2008;9:1149–56. [https://doi.org/10.1016/S1470-2045\(08\)70260-2](https://doi.org/10.1016/S1470-2045(08)70260-2).
- [108] Kuiper EM, van den Berge BA, Spoo JR, Kuiper J, Terra JB. Low recurrence rate of head and neck basal cell carcinoma treated with Mohs micrographic surgery: a retrospective study of 1021 cases. *Clin Otolaryngol* 2018;43:1321–7. <https://doi.org/10.1111/coa.13176>.
- [109] Bozan A, Gode S, Kaya I, Yaman B, Uslu M, Akyildiz S, et al. Long-term follow-up of positive surgical margins in basal cell carcinoma of the face. *Dermatol Surg* 2015;41:761–7. <https://doi.org/10.1097/DSS.0000000000000394>.
- [110] Borghi A, Corazza M, Ricci M, Perazzolli G, Virgili A. Basal cell carcinoma incompletely excised: a case-control study on recurrence. *G Ital Dermatol Venereol* 2016;151:145–53.
- [111] Masud D, Moustaki M, Staruch R, Dheansa B. Basal cell carcinoma: risk factors for incomplete excision and results of re-excision. *J Plast Reconstr Aesthet Surg* 2016;69:652–6. <https://doi.org/10.1016/j.bjps.2015.12.024>.
- [112] Kappelin J, Nielsen K, Nilsson F, Bjellerup M, Ahnlied I. Surgical treatment of basal cell carcinoma: a case series on factors influencing the risk of an incomplete primary excision. *J Eur Acad Dermatol Venereol* 2020;34:2518–25. <https://doi.org/10.1111/jdv.16327>.
- [113] Daviti M, Lallas K, Dimitriadis C, Moutsoudis A, Eleftheriadis V, Eftychidou P, et al. Real-life data on the management of incompletely excised basal cell carcinoma. *Dermatology* 2023 2;239(3):429–35. <https://doi.org/10.1159/000529367>.
- [114] Nolan GS, Kiely AL, Totty JP, Wormald JCR, Wade RG, Arbyn M, et al. Incomplete surgical excision of keratinocyte skin cancers: a systematic review and meta-analysis. *Br J Dermatol* 2021;184:1033–44. <https://doi.org/10.1111/bjd.19660>.
- [115] Boulinguez S, Grison-Tabone C, Lamant L, Valmary S, Viraben R, Bonnetblanc JM, et al. Histological evolution of recurrent basal cell carcinoma and therapeutic implications for incompletely excised lesions. *Br J Dermatol* 2004;151:623–6. <https://doi.org/10.1111/j.1365-2133.2004.06135.x>.
- [116] Silverman MK, Kopf AW, Grin CM, Bart RS, Levenstein MJ. Recurrence rates of treated basal cell carcinomas. Part 1: overview. *J Dermatol Surg Oncol* 1991;17:713–8. <https://doi.org/10.1111/j.1524-4725.1991.tb03424.x>.
- [117] Rodriguez-Vigil T, Vázquez-López F, Perez-Oliva N. Recurrence rates of primary basal cell carcinoma in facial risk areas treated with curettage and electrodesiccation. *J Am Acad Dermatol* 2007;56:91–5. <https://doi.org/10.1016/j.jaad.2006.07.007>.
- [118] Bastos LMH, Carvalho LP, Haddad GR, Miola AC, Schmitt JV. Curettage and electrocoagulation versus surgical excision in the treatment of low-risk basal cell carcinoma - Postoperative follow-up and satisfaction at three months: randomized clinical trial. *An Bras Dermatol* 2022;97:384–6. <https://doi.org/10.1016/j.abd.2020.12.011>.
- [119] Basset-Seguín N, Ibbotson SH, Emtestam L, Tarstedt M, Morton C, Maroti M, et al. Topical methyl aminolaevulinate photodynamic therapy versus cryotherapy for superficial basal cell carcinoma: a 5 year randomized trial. *Eur J Dermatol* 2008;18:547–53. <https://doi.org/10.1684/ejd.2008.0472>.

- [120] Zane C, Facchinetti E, Arisi M, Ortel B, Calzavara-Pinton P. Pulsed CO<sub>2</sub> laser ablation of superficial basal cell of limbs and trunk: a comparative randomized clinical trial with cryotherapy and surgical ablation. *Dermatol Surg* 2017;43:920–7. <https://doi.org/10.1097/DSS.0000000000001106>.
- [121] Backman EJ, Polesie S, Berglund S, Gillstedt M, Sjöholm A, Modin M, et al. Curettage vs. cryosurgery for superficial basal cell carcinoma: a prospective, randomised and controlled trial. *J Eur Acad Dermatol Venereol* 2022;36:1758–65. <https://doi.org/10.1111/jdv.18209>.
- [122] Choi SH, Kim KH, Song KH. Er:YAG ablative fractional laser-primed photodynamic therapy with methyl aminolevulinic acid as an alternative treatment option for patients with thin nodular basal cell carcinoma: a 12-month follow-up results of a randomized, prospective, comparative trial. *J Eur Acad Dermatol Venereol* 2016;30:783–8. <https://doi.org/10.1111/jdv.13453>.
- [123] Genouw E, Verheire B, Ongenaes K, De Schepper S, Creyten D, Verhaeghe E, et al. Laser-assisted photodynamic therapy for superficial basal cell carcinoma and Bowen's disease: a randomized inpatient comparison between a continuous and a fractional ablative CO<sub>2</sub> laser mode. *J Eur Acad Dermatol Venereol* 2018;32:1897–905. <https://doi.org/10.1111/jdv.14989>.
- [124] Collier NJ, Haylett AK, Wong TH, Morton CA, Ibbotson SH, McKenna KE, et al. Conventional and combination topical photodynamic therapy for basal cell carcinoma: systematic review and meta-analysis. *Br J Dermatol* 2018;179:1277–96. <https://doi.org/10.1111/bjd.16838>.
- [125] Szeimies RM, Ibbotson S, Murrell DF, Rubel D, Frambach Y, de Berker D, et al. Excilight Study Group. A clinical study comparing methyl aminolevulinic acid photodynamic therapy and surgery in small superficial basal cell carcinoma (8–20 mm), with a 12-month follow-up. *J Eur Acad Dermatol Venereol* 2008;22:1302–11. <https://doi.org/10.1111/j.1468-3083.2008.02803.x>.
- [126] Rhodes LE, de Rie MA, Leifsdottir R, Yu RC, Bachmann I, Goulden V, et al. Five-year follow-up of a randomized, prospective trial of topical methyl aminolevulinic acid photodynamic therapy vs surgery for nodular basal cell carcinoma. *Arch Dermatol* 2007;143:1131–6. <https://doi.org/10.1001/archderm.143.9.1131>.
- [127] Ahluwalia J, Avram MM, Ortiz AE. Outcomes of long-pulsed 1064 nm Nd:YAG laser treatment of basal cell carcinoma: a retrospective review. *Lasers Surg Med* 2019;51:34–9. <https://doi.org/10.1002/lsm.23041>.
- [128] Markowitz O, Bressler MY. Combining Nd:YAG laser with optical coherence tomography for nonsurgical treatment of basal cell carcinoma. *Lasers Surg Med* 2022;54:105–12. <https://doi.org/10.1002/lsm.23455>.
- [129] Ortiz AE, Anderson RR, DiGiorgio C, Jiang SIB, Shafiq F, Avram MM. An expanded study of long-pulsed 1064 nm Nd:YAG laser treatment of basal cell carcinoma. *Lasers Surg Med* 2018. <https://doi.org/10.1002/lsm.22803>. Epub ahead of print. PMID: 29436720.
- [130] Kranz S, Brunnermeier G, Yilmaz P, Thamm J, Schiele S, Müller G, et al. Optical coherence tomography-guided Nd:YAG laser treatment and follow-up of basal cell carcinoma. *Lasers Surg Med* 2023 5;55(3):257–67. <https://doi.org/10.1002/lsm.23638>. 10.1002/lsm.23638.
- [131] Arits AH, Mosterd K, Essers BA, Spoorenberg E, Sommer A, De Rooij MJ, et al. Photodynamic therapy versus topical imiquimod versus topical fluorouracil for treatment of superficial basal-cell carcinoma: a single blind, non-inferiority, randomised controlled trial. *Lancet Oncol* 2013;14:647–54. [https://doi.org/10.1016/S1470-2045\(13\)70143-8](https://doi.org/10.1016/S1470-2045(13)70143-8).
- [132] Roozeboom MH, Arits AHMM, Mosterd K, Sommer A, Essers BAB, de Rooij MJM, et al. Three-year follow-up results of photodynamic therapy vs. imiquimod vs. fluorouracil for treatment of superficial basal cell carcinoma: a single-blind, noninferiority, randomized controlled trial. *J Invest Dermatol* 2016;136:1568–74. <https://doi.org/10.1016/j.jid.2016.03.043>.
- [133] Jansen MHE, Mosterd K, Arits AHMM, Roozeboom MH, Sommer A, Essers BAB, et al. Five-year results of a randomized controlled trial comparing effectiveness of photodynamic therapy, topical imiquimod, and topical 5-fluorouracil in patients with superficial basal cell carcinoma. *J Invest Dermatol* 2018;138:527–33. <https://doi.org/10.1016/j.jid.2017.09.033>.
- [134] Roozeboom MH, van Kleef L, Arits AH, Mosterd K, Winnepenninckx VJ, van Marion AM, et al. Tumor thickness and adnexal extension of superficial basal cell carcinoma (sBCC) as determinants of treatment failure for methylaminolevulinic acid (MAL)-photodynamic therapy (PDT), imiquimod, and 5-fluorouracil (FU). *J Am Acad Dermatol* 2015;73:93–8. <https://doi.org/10.1016/j.jaad.2015.03.048>.
- [135] Huang CM, Kirchhof MG. Topical imiquimod as a treatment option for nodular basal cell carcinoma: a systematic review. *J Cutan Med Surg* 2020;24:495–503. <https://doi.org/10.1177/1203475420931770>.
- [136] Bath-Hextall F, Ozolins M, Armstrong SJ, Colver GB, Perkins W, Miller PS, et al. Surgery Versus Imiquimod for Nodular Superficial Basal Cell Carcinoma (SINS) Study Group. Surgical excision versus imiquimod 5% cream for nodular and superficial basal-cell carcinoma (SINS): a multicentre, non-inferiority, randomised controlled trial. *Lancet Oncol* 2014;15:96–105. [https://doi.org/10.1016/S1470-2045\(13\)70530-8](https://doi.org/10.1016/S1470-2045(13)70530-8).
- [137] Williams HC, Bath-Hextall F, Ozolins M, Armstrong SJ, Colver GB, Perkins W, et al. Surgery Versus Imiquimod for Nodular and Superficial Basal Cell Carcinoma (SINS) Study Group. Surgery versus 5% imiquimod for nodular and superficial basal cell carcinoma: 5-year results of the SINS randomized controlled trial. *J Invest Dermatol* 2017;137:614–9. <https://doi.org/10.1016/j.jid.2016.10.019>.
- [138] Thomson J, Hogan S, Leonardi-Bee J, Williams HC, Bath-Hextall FJ. Interventions for basal cell carcinoma of the skin. *Cochrane Database Syst Rev* 2020;11:CD003412. <https://doi.org/10.1002/14651858.CD003412.pub3>.
- [139] Micali G, Lacarrubba F, Nasca MR, Ferraro S, Schwartz RA. Topical pharmacotherapy for skin cancer: part II. Clinical applications. *J Am Acad Dermatol* 2014;70(6):979.e1–979.e12. <https://doi.org/10.1016/j.jaad.2013.12.037>. quiz 9912. PMID: 24831325.
- [140] Algarin YA, Jambusaria-Pahlajani A, Ruiz E, Patel VA. Advances in topical treatments of cutaneous malignancies. *Am J Clin Dermatol* 2023;24:69–80. <https://doi.org/10.1007/s40257-022-00731-x>.
- [141] Collier NJ, Rhodes LE. Photodynamic therapy for basal cell carcinoma: the clinical context for future research priorities. *Molecules* 2020;25:5398. <https://doi.org/10.3390/molecules25225398>.
- [142] Wong TH, Morton CA, Collier N, Haylett A, Ibbotson S, McKenna KE, et al. British Association of Dermatologists and British Photodermatology Group guidelines for topical photodynamic therapy 2018. *Br J Dermatol* 2019;180:730–9. <https://doi.org/10.1111/bjd.17309>.
- [143] Morton CA, Dominicus R, Radny P, Dirschka T, Hauschild A, Reinhold U, et al. A randomized, multinational, noninferiority, phase III trial to evaluate the safety and efficacy of BF-200 aminolaevulinic acid gel vs. methyl aminolaevulinic acid cream in the treatment of nonaggressive basal cell carcinoma with photodynamic therapy. *Br J Dermatol* 2018;179:309–19. <https://doi.org/10.1111/bjd.16441>.
- [144] Lancaster J, Swindell R, Slevin F, Sheridan L, Allan D, Allan E. Efficacy of photodynamic therapy as a treatment for Gorlin syndrome-related basal cell carcinomas. *Clin Oncol (R Coll Radiol)* 2009;2:502–8. <https://doi.org/10.1016/j.clon.2009.03.004>.
- [145] de Vrijlder HC, Sterenborg HJ, Neumann HA, Robinson DJ, de Haas ER. Light fractionation significantly improves the

- response of superficial basal cell carcinoma to aminolaevulinic acid photodynamic therapy: five-year follow-up of a randomized, prospective trial. *Acta Derm Venereol* 2012;92:641–7. <https://doi.org/10.2340/00015555-1448>.
- [146] van Delft LCJ, Nelemans PJ, Kessels JPHM, Kreukels H, Roozeboom MH, de Rooij MJM, et al. Long-term efficacy of photodynamic therapy with fractionated 5-aminolevulinic acid 20% versus conventional two-stage topical methyl aminolevulinate for superficial basal-cell carcinoma. *Dermatology* 2022;238:1044–9. <https://doi.org/10.1159/000524745>.
- [147] Roozeboom MH, Aardoom MA, Nelemans PJ, Thissen MR, Kelleners-Smeets NW, Kuijpers DI, et al. Fractionated 5-aminolevulinic acid photodynamic therapy after partial debulking versus surgical excision for nodular basal cell carcinoma: a randomized controlled trial with at least 5-year follow-up. *J Am Acad Dermatol* 2013;69:280–7. <https://doi.org/10.1016/j.jaad.2013.02.014>.
- [148] Smucler R, Vlk M. Combination of Er:YAG laser and photodynamic therapy in the treatment of nodular basal cell carcinoma. *Lasers Surg Med* 2008;40:153–8. <https://doi.org/10.1002/lsm.20606>.
- [149] Shokrollahi K, Javed M, Aeuyung K, Ghattaura A, Whitaker IS, O'Leary B, et al. Combined carbon dioxide laser with photodynamic therapy for nodular and superficial basal cell carcinoma. *Ann Plast Surg* 2014;73:552–8. <https://doi.org/10.1097/SAP.0b013e3182773ed2>.
- [150] Azzopardi EA, Abdelrahman W, Azzopardi E, O'Leary B, Yarrow J, Miles N, et al. Treatment of cutaneous basal cell carcinoma with combined laser extirpation and methyl aminolevulinic acid: five-year success rates. *Ann R Coll Surg Engl* 2021;103:263–71. <https://doi.org/10.1308/rcsann.2020.7020>.
- [151] Kim SA, Lee KS, Cho JW. Photodynamic therapy combined with cryotherapy for the treatment of nodular basal cell carcinoma. *Oncol Lett* 2013;6:939–41. <https://doi.org/10.3892/ol.2013.1504>.
- [152] Fredman G, Wenande E, Hendel K, Togsverd-Bo K, Haedersdal M. Efficacy and safety of laser-assisted combination chemotherapy: a follow-up study of treatment with 5-fluorouracil and cisplatin for basal cell carcinoma. *Lasers Surg Med* 2022;54:113–20. <https://doi.org/10.1002/lsm.23497>. Epub 2021 Dec 5. PMID: 34865224.
- [153] Gracia-Cazaña T, González S, Juarranz A, Gilaberte Y. Methyl aminolevulinic acid photodynamic therapy combined with curettage debulking for pigmented basal cell carcinoma. *Photodermatol Photoimmunol Photomed* 2017;33:228–32. <https://doi.org/10.1111/phpp.12313>.
- [154] Tillman Jr DK, Carroll MT. A 36-month clinical experience of the effectiveness of curettage and imiquimod 5% cream in the treatment of basal cell carcinoma. *J Drugs Dermatol* 2008;7(1 Suppl 1):s7–14.
- [155] Sinx KAE, Nelemans PJ, Kelleners-Smeets NWJ, Winnepenninckx VJL, Arits AHMM, Mosterd K. Surgery versus combined treatment with curettage and imiquimod for nodular basal cell carcinoma: one-year results of a non-inferiority, randomized, controlled trial. *J Am Acad Dermatol* 2020;83:469–76. <https://doi.org/10.1016/j.jaad.2020.04.053>.
- [156] Lucena SR, Salazar N, Gracia-Cazaña T, Zamarrón A, González S, Juarranz A, et al. Combined treatments with photodynamic therapy for non-melanoma skin cancer. *Int J Mol Sci* 2015;16:25912–33. <https://doi.org/10.3390/ijms161025912>.
- [157] Osiecka B, Jurczyszyn K, Ziółkowski P. The application of Levulan-based photodynamic therapy with imiquimod in the treatment of recurrent basal cell carcinoma. *Med Sci Monit* 2012;18:PI5–9. <https://doi.org/10.12659/msm.882449>.
- [158] Messegueur F, Serra-Guillen C, Echeverria B, Requena C, Sanmartin O, Llombart B, et al. A pilot study of clinical efficacy of imiquimod and cryotherapy for the treatment of basal cell carcinoma with incomplete response to imiquimod. *J Eur Acad Dermatol Venereol* 2012;26:879–81. <https://doi.org/10.1111/j.1468-3083.2011.04177.x>.
- [159] Gaitanis G, Bassukas ID. A review of immunocryosurgery and a practical guide to its applications. *Diseases* 2021;9:71. <https://doi.org/10.3390/diseases9040071>.
- [160] Torres A, Niemeyer A, Berkes B, Marra D, Schanbacher C, González S, et al. 5% imiquimod cream and reflectance-mode confocal microscopy as adjunct modalities to Mohs micrographic surgery for treatment of basal cell carcinoma. *Dermatol Surg* 2004;30:1462–9. <https://doi.org/10.1111/j.1524-4725.2004.30504.x>.
- [161] Moehrl M, Breuninger H, Schippert W, Häfner HM. Letter: imiquimod 5% cream as adjunctive therapy for primary, solitary, nodular basal cell carcinomas before Mohs micrographic surgery: a randomized, double-blind, vehicle-controlled study. *Dermatol Surg* 2010;36:428–30. <https://doi.org/10.1111/j.1524-4725.2009.01464.x>.
- [162] Zhang J, Lu Y, Zhang X, Yang Y, Kou H, Wang Y. Clinical efficacy of Mohs surgery combined with topical photodynamic therapy for facial basal cell carcinoma. *J Cancer Res Ther* 2020;16:1051–5. [https://doi.org/10.4103/jcrt.JCRT\\_987\\_19](https://doi.org/10.4103/jcrt.JCRT_987_19).
- [163] Drucker AM, Adam GP, Rofeberg V, Gazula A, Smith B, Moustafa F, et al. Treatments of primary basal cell carcinoma of the skin: a systematic review and network meta-analysis. *Ann Intern Med* 2018;169:456–66. <https://doi.org/10.7326/M18-0678>.
- [164] Guinot JL, Rembielak A, Perez-Calatayud J, Rodríguez-Villalba S, Skowronek J, Tagliaferri L, et al. GEC ESTRO. GEC-ESTRO ACROP recommendations in skin brachytherapy. *Radiother Oncol* 2018;126:377–85. <https://doi.org/10.1016/j.radonc.2018.01.013>.
- [165] Frakulli R, Galuppi A, Cammelli S, Macchia G, Cima S, Gambacorta MA, et al. Brachytherapy in non melanoma skin cancer of eyelid: a systematic review. *J Contemp Brachytherapy* 2015;7:497–502. <https://doi.org/10.5114/jcb.2015.56465>.
- [166] Bussu F, Tagliaferri L, Mattiucci G, Parrilla C, Dinapoli N, Micciché F, et al. Comparison of interstitial brachytherapy and surgery as primary treatments for nasal vestibule carcinomas. *Laryngoscope* 2016;126:367–71. <https://doi.org/10.1002/lary.25498>.
- [167] Tagliaferri L, Bussu F, Fionda B, Catucci F, Rigante M, Gambacorta MA, et al. Perioperative HDR brachytherapy for reirradiation in head and neck recurrences: single-institution experience and systematic review. *Tumori* 2017;103:516–24. <https://doi.org/10.5301/tj.5000614>.
- [168] Kovács G, Martínez-Monge R, Budrukkar A, Guinot JL, Johansson B, Strnad V, et al. GEC-ESTRO Head & Neck Working Group. GEC-ESTRO ACROP recommendations for head & neck brachytherapy in squamous cell carcinomas: 1st update - Improvement by cross sectional imaging based treatment planning and stepping source technology. *Radiother Oncol* 2017;122:248–54. <https://doi.org/10.1016/j.radonc.2016.10.008>.
- [169] Zaorsky NG, Lee CT, Zhang E, Keith SW, Galloway TJ. Hypofractionated radiation therapy for basal and squamous cell skin cancer: a meta-analysis. *Radiother Oncol* 2017;125:13–20. <https://doi.org/10.1016/j.radonc.2017.08.011>.
- [170] Clover AJP, de Terlizzi F, Bertino G, Curatolo P, Odili J, Campana LG, et al. Electrochemotherapy in the treatment of cutaneous malignancy: outcomes and subgroup analysis from the cumulative results from the pan-European International Network for Sharing Practice in Electrochemotherapy database for 2482 lesions in 987 patients (2008-2019). *Eur J Cancer* 2020;138:30–40. <https://doi.org/10.1016/j.ejca.2020.06.020>.
- [171] Bertino G, Muir T, Odili J, Groselj A, Marconato R, Curatolo P, et al. The InspECT Bcc Working Group. Treatment of basal cell carcinoma with electrochemotherapy: insights from the InspECT Registry (2008-2019). *Curr Oncol* 2022;29:5324–37. <https://doi.org/10.3390/curroncol29080423>.



- [172] Clover AJP, Salwa SP, Bourke MG, McKiernan J, Forde PF, O'Sullivan ST, et al. Electrochemotherapy for the treatment of primary basal cell carcinoma: A randomised control trial comparing electrochemotherapy and surgery with five year follow up. *Eur J Surg Oncol* 2020;46:847–54. <https://doi.org/10.1016/j.ejso.2019.11.509>.
- [173] Bertrand N, Guerreschi P, Basset-Seguín N, Saiag P, Dupuy A, Dalac-Rat S, et al. Vismodegib in neoadjuvant treatment of locally advanced basal cell carcinoma: first results of a multicenter, open-label, phase 2 trial (VISMONEO study): neoadjuvant vismodegib in locally advanced basal cell carcinoma. *EclinicalMedicine* 2021;35:100844. <https://doi.org/10.1016/j.eclinm.2021.100844>.
- [174] Gupta N, Ruiz ES. Current perspectives in the treatment of locally advanced basal cell carcinoma. *Drug Des Devel Ther* 2022;16:183–90. <https://doi.org/10.2147/DDDT.S325852>.
- [175] Vuong W, Lin J, Wei RL. Palliative radiotherapy for skin malignancies. *Ann Palliat Med* 2017;6:165–72. <https://doi.org/10.21037/apm.2016.11.10>.
- [176] Donati CM, Macchia G, Siepe G, Zamagni A, Benini A, Cellini F, et al. Short course palliative radiotherapy in advanced solid tumors: a pooled analysis (the SHARON project). *Sci Rep* 2022;12:20978. <https://doi.org/10.1038/s41598-022-25602-7>.
- [177] Mendenhall WM, Amdur RJ, Hinerman RW, Cognetta AB, Mendenhall NP. Radiotherapy for cutaneous squamous and basal cell carcinomas of the head and neck. *Laryngoscope* 2009;119:1994–9. <https://doi.org/10.1002/lary.20608>.
- [178] Lancellotta V, Kovács G, Tagliaferri L, Perrucci E, Rembielak A, Stingeni L, et al. The role of personalized Interventional Radiotherapy (brachytherapy) in the management of older patients with non-melanoma skin cancer. *J Geriatr Oncol* 2019;10:514–7. <https://doi.org/10.1016/j.jgo.2018.09.009>.
- [179] Malmontet T, Dousset L, Gerard E, Ouhabra N, Pham-Ledard A, Beylot-Barry M. Synergie de la séquence immunothérapie par anti-PD1 et radiothérapie au cours d'un carcinome basocellulaire avancé [Synergistic effect of anti-PD1 immunotherapy then radiotherapy in advanced basal cell carcinoma]. *Ann Dermatol Venereol* 2020;147:228–32. <https://doi.org/10.1016/j.annder.2019.08.019>.
- [180] Weissman JP, Samlowski W, Meoz R. Hedgehog inhibitor induction with addition of concurrent superficial radiotherapy in patients with locally advanced basal cell carcinoma: a case series. *Oncologist* 2021;26:e2247–53. <https://doi.org/10.1002/onco.13959>.
- [181] Sekulic A, Migden MR, Oro AE, Dirix L, Lewis KD, Hainsworth JD, et al. Efficacy and safety of vismodegib in advanced basal-cell carcinoma. *N Engl J Med* 2012;366:2171–9. <https://doi.org/10.1056/NEJMoa1113713>.
- [182] Sekulic A, Migden MR, Basset-Seguín N, Garbe C, Gesierich A, Lao CD, et al. ERIVANCE BCC Investigators. Long-term safety and efficacy of vismodegib in patients with advanced basal cell carcinoma: final update of the pivotal ERIVANCE BCC study. *BMC Cancer* 2017;17:332. <https://doi.org/10.1186/s12885-017-3286-5>.
- [183] Basset-Seguín N, Hauschild A, Kunstfeld R, Grob J, Dréno B, Mortier L, et al. Vismodegib in patients with advanced basal cell carcinoma: primary analysis of STEVIE, an international, open-label trial. *Eur J Cancer* 2017;86:334–48. <https://doi.org/10.1016/j.ejca.2017.08.022>.
- [184] Migden MR, Guminski A, Gutzmer R, Dirix L, Lewis KD, Combemale P, et al. Treatment with two different doses of sonidegib in patients with locally advanced or metastatic basal cell carcinoma (BOLT): a multicentre, randomised, double-blind phase 2 trial. *Lancet Oncol* 2015;16:716–28. [https://doi.org/10.1016/S1470-2045\(15\)70100-2](https://doi.org/10.1016/S1470-2045(15)70100-2).
- [185] Dummer R, Guminski A, Gutzmer R, Lear JT, Lewis KD, Chang ALS, et al. Long-term efficacy and safety of sonidegib in patients with advanced basal cell carcinoma: 42-month analysis of the phase II randomized, double-blind BOLT study. *Br J Dermatol* 2020;182:1369–78. <https://doi.org/10.1111/bjd.18552>.
- [186] Tang JY, Ally MS, Chanana AM, Mackay-Wiggan JM, Aszterbaum M, Lindgren JA, et al. Inhibition of the hedgehog pathway in patients with basal-cell nevus syndrome: final results from the multicentre, randomised, double-blind, placebo-controlled, phase 2 trial. *Lancet Oncol* 2016;17:1720–31. [https://doi.org/10.1016/S1470-2045\(16\)30566-6](https://doi.org/10.1016/S1470-2045(16)30566-6).
- [187] DeTemple VK, Hassel JC, Sachse MM, Grimmelmann I, Leiter U, Gebhardt C, et al. Reinduction of Hedgehog Inhibitors after Checkpoint Inhibition in Advanced Basal Cell Carcinoma: A Series of 12 Patients. *Cancers ((Basel))* 2022 7;14(21):5469. <https://doi.org/10.3390/cancers14215469>. PMID: 36358887; PMCID: PMC9658899.
- [188] Nguyen A, Xie P, Litvinov IV, Lefrançois P. Efficacy and safety of sonic hedgehog inhibitors in basal cell carcinomas: an updated systematic review and meta-analysis (2009-2022). *Am J Clin Dermatol* 2023;24(3). <https://doi.org/10.1007/s40257-023-00763-x>. PMID: 36795228.
- [189] Lacouture ME, Dréno B, Ascierto PA, Dummer R, Basset-Seguín N, Fife K, et al. Characterization and management of hedgehog pathway inhibitor-related adverse events in patients with advanced basal cell carcinoma. *Oncologist* 2016;21:1218–29. <https://doi.org/10.1634/theoncologist.2016-0186>.
- [190] Lear JT, Dummer R, Guminski A. Using drug scheduling to manage adverse events associated with hedgehog pathway inhibitors for basal cell carcinoma. *Oncotarget* 2021;12:2531–40. <https://doi.org/10.18632/oncotarget.28145>.
- [191] Chalmers ZR, Connelly CF, Fabrizio D, Gay L, Ali SM, Ennis R, et al. Analysis of 100,000 human cancer genomes reveals the landscape of tumor mutational burden. *Genome Med* 2017;9:34. <https://doi.org/10.1186/s13073-017-0424-2>.
- [192] Kreher MA, Noland MMB, Konda S, Longo MI, Valdes-Rodriguez R. Risk of melanoma and nonmelanoma skin cancer with immunosuppressants, part I: calcineurin inhibitors, thio-purines, IMDH inhibitors, mTOR inhibitors, and corticosteroids. *J Am Acad Dermatol* 2023;88:521–30. <https://doi.org/10.1016/j.jaad.2022.11.044>.
- [193] Stratigos AJ, Sekulic A, Peris K, Bechter O, Prey S, Kaatz M, et al. Cemiplimab in locally advanced basal cell carcinoma after hedgehog inhibitor therapy: an open-label, multi-centre, single-arm, phase 2 trial. *Lancet Oncol* 2021;22:848–57. [https://doi.org/10.1016/S1470-2045\(21\)00126-1](https://doi.org/10.1016/S1470-2045(21)00126-1).
- [194] Peris K, Tambone S, Kostaki D, Varrassi E, Fargnoli MC. Treatments of advanced basal cell carcinoma: a review of the literature. *G Ital Dermatol Venereol* 2016;151:77–86.
- [195] Scotté F, Bossi P, Carola E, Cudenneq T, Dielenseger P, Gomes F, et al. Addressing the quality of life needs of older patients with cancer: a SIOG consensus paper and practical guide. *Ann Oncol* 2018;29:1718–26. <https://doi.org/10.1093/annonc/mdy228>.
- [196] Fallon M, Giusti R, Aielli F, Hoskin P, Rolke R, Sharma M, et al. ESMO Guidelines Committee. Management of cancer pain in adult patients: ESMO Clinical Practice Guidelines. *Ann Oncol* 2018;29:iv166–91. <https://doi.org/10.1093/annonc/mdy152>.
- [197] World Health Organization. WHO guidelines for the pharmacological and radiotherapeutic management of cancer pain in adults and adolescents. Geneva: World Health Organization; 2018.
- [198] Gehl J, Sersa G, Matthiessen LW, Muir T, Soden D, Occhini A, et al. Updated standard operating procedures for electrochemotherapy of cutaneous tumours and skin metastases. *Acta Oncol* 2018;57:874–82. <https://doi.org/10.1080/0284186X.2018.1454602>.
- [199] da Costa Santos CM, de Mattos Pimenta CA, Nobre MR. A systematic review of topical treatments to control the odor of



- malignant fungating wounds. *J Pain Symptom Manage* 2010;39:1065–76. <https://doi.org/10.1016/j.jpainsymman.2009.11.319>.
- [200] Villela-Castro DL, Santos VLCG, Woo K. Polyhexanide versus metronidazole for odor management in malignant (fungating) wounds: a double-blinded, randomized, clinical trial. *J Wound Ostomy Continence Nurs* 2018;45:413–8. <https://doi.org/10.1097/WON.0000000000000460>.
- [201] Woo KY, Sibbald RG. Local wound care for malignant and palliative wounds. *Adv Skin Wound Care* 2010;23:417–28. <https://doi.org/10.1097/01.ASW.0000383206.32244.e2>.
- [202] Pereira J, Phan T. Management of bleeding in patients with advanced cancer. *Oncologist* 2004;9:561–70. <https://doi.org/10.1634/theoncologist.9-5-561>.
- [203] Mirali S, Tang E, Drucker AM, Turchin I, Gooderham M, Levell N, et al. Follow-up of patients with keratinocyte carcinoma: a systematic review of clinical practice guidelines. *JAMA Dermatol* 2023;159:87–94. <https://doi.org/10.1001/jamadermatol.2022.4590>.
- [204] Flohil SC, van der Leest RJ, Arends LR, de Vries E, Nijsten T. Risk of subsequent cutaneous malignancy in patients with prior keratinocyte carcinoma: a systematic review and meta-analysis. *Eur J Cancer* 2013;49:2365–75. <https://doi.org/10.1016/j.ejca.2013.03.010>.
- [205] van der Leest RJT, Hollestein LM, Liu L, Nijsten T, de Vries E. Risks of different skin tumour combinations after a first melanoma, squamous cell carcinoma and basal cell carcinoma in Dutch population-based cohorts: 1989–2009. *J Eur Acad Dermatol Venereol* 2018;32:382–9. <https://doi.org/10.1111/jdv.14587>.
- [206] van Egmond S, Wakkee M, Droger M, Bastiaens MT, van Rengen A, de Roos KP, et al. Needs and preferences of patients regarding basal cell carcinoma and cutaneous squamous cell carcinoma care: a qualitative focus group study. *Br J Dermatol* 2019;180:122–9. <https://doi.org/10.1111/bjd.16900>.
- [207] Work Group; Invited Reviewers, Kim JYS, Kozlow JH, Mittal B, Moyer J, Olencki T, Rodgers P. Guidelines of care for the management of basal cell carcinoma. *J Am Acad Dermatol* 2018;78:540–59. <https://doi.org/10.1016/j.jaad.2017.10.006>.
- [208] Armstrong LTD, Magnusson MR, Guppy MPB. Risk factors for recurrence of facial basal cell carcinoma after surgical excision: a follow-up analysis. *J Plast Reconstr Aesthet Surg* 2017;70:1738–45. <https://doi.org/10.1016/j.bjps.2017.04.006>.
- [209] Flohil SC, Koljenović S, de Haas ER, Overbeek LI, de Vries E, Nijsten T. Cumulative risks and rates of subsequent basal cell carcinomas in the Netherlands. *Br J Dermatol* 2011;165:874–81. <https://doi.org/10.1111/j.1365-2133.2011.10488.x>.
- [210] Wehner MR, Linos E, Parvataneni R, Stuart SE, Boscardin WJ, Chren MM. Timing of subsequent new tumors in patients who present with basal cell carcinoma or cutaneous squamous cell carcinoma. *JAMA Dermatol* 2015;151:382–8. <https://doi.org/10.1001/jamadermatol.2014.3307>.
- [211] Huq AJ, Walsh M, Rajagopalan B, Finlay M, Trainer AH, Bonnet F, et al. Mutations in *SUFU* and *PTCH1* genes may cause different cutaneous cancer predisposition syndromes: similar, but not the same. *Fam Cancer* 2018;17:601–6. <https://doi.org/10.1007/s10689-018-0073-7>.
- [212] Bree AF, Shah MR, BCNS Colloquium Group. Consensus statement from the first international colloquium on basal cell nevus syndrome (BCNS). *Am J Med Genet A* 2011;155A:2091–7. <https://doi.org/10.1002/ajmg.a.34128>.
- [213] Spadari F, Pulicari F, Pellegrini M, Scribante A, Garagiola U. Multidisciplinary approach to Gorlin-Goltz syndrome: from diagnosis to surgical treatment of jawbones. *Maxillofac Plast Reconstr Surg* 2022;44:25. <https://doi.org/10.1186/s40902-022-00355-5>.
- [214] Verkouteren BJA, Cosgun B, Reinders MGHC, Kessler PAWK, Vermeulen RJ, Klaassens M, et al. A guideline for the clinical management of basal cell naevus syndrome (Gorlin-Goltz syndrome). *Br J Dermatol* 2022;186:215–26. <https://doi.org/10.1111/bjd.20700>.
- [215] Guerrini-Rousseau L, Smith MJ, Kratz CP, Doergeloh B, Hirsch S, Hopman SMJ, et al. Current recommendations for cancer surveillance in Gorlin syndrome: a report from the SIOPE host genome working group (SIOPE HGWG). *Fam Cancer* 2021;20:317–25. <https://doi.org/10.1007/s10689-021-00247-z>.
- [216] Evans DG, Oudit D, Smith MJ, Rutkowski D, Allan E, Newman WG, et al. First evidence of genotype-phenotype correlations in Gorlin syndrome. *J Med Genet* 2017;54:530–6. <https://doi.org/10.1136/jmedgenet-2017-104669>.
- [217] Betancourt NJ, Qian MF, Pickford JR, Bailey-Healy I, Tang JY, Teng JMC. Gorlin syndrome: assessing genotype-phenotype correlations and analysis of early clinical characteristics as risk factors for disease severity. *J Clin Oncol* 2022;40:2119–27. <https://doi.org/10.1200/JCO.21.02385>.
- [218] Neale RE, Davis M, Pandeya N, Whiteman DC, Green AC. Basal cell carcinoma on the trunk is associated with excessive sun exposure. *J Am Acad Dermatol* 2007;56:380–6. <https://doi.org/10.1016/j.jaad.2006.08.039>.
- [219] Karagas MR, Zens MS, Li Z, Stukel TA, Perry AE, Gilbert-Diamond D, et al. Early-onset basal cell carcinoma and indoor tanning: a population-based study. *Pediatrics* 2014;134:e4–12. <https://doi.org/10.1542/peds.2013-3559>.
- [220] Marcil I, Stern RS. Risk of developing a subsequent non-melanoma skin cancer in patients with a history of non-melanoma skin cancer: a critical review of the literature and meta-analysis. *Arch Dermatol* 2000;136:1524–30. <https://doi.org/10.1001/archderm.136.12.1524>.
- [221] Kiiski V, de Vries E, Flohil SC, Bijl MJ, Hofman A, Stricker BH, et al. Risk factors for single and multiple basal cell carcinomas. *Arch Dermatol* 2010;146:848–55. <https://doi.org/10.1001/archdermatol.2010.155>.
- [222] Leone A, Martínez-González MÁ, Martín-Gorgojo A, Sánchez-Bayona R, De Amicis R, Bertoli S, et al. Mediterranean diet, Dietary Approaches to Stop Hypertension, and Pro-vegetarian dietary pattern in relation to the risk of basal cell carcinoma: a nested case-control study within the Seguimiento Universidad de Navarra (SUN) cohort. *Am J Clin Nutr* 2020;112:364–72. <https://doi.org/10.1093/ajcn/nqaa127>.
- [223] Song F, Qureshi AA, Han J. Increased caffeine intake is associated with reduced risk of basal cell carcinoma of the skin. *Cancer Res* 2012;72:3282–9. <https://doi.org/10.1158/0008-5472.CAN-11-3511>.
- [224] Myung SK, Kim Y, Ju W, Choi HJ, Bae WK. Effects of antioxidant supplements on cancer prevention: meta-analysis of randomized controlled trials. *Ann Oncol* 2010;21:166–79. <https://doi.org/10.1093/annonc/mdp286>.
- [225] Damian DL, Patterson CR, Stapelberg M, Park J, Barnetson RS, Halliday GM. UV radiation-induced immunosuppression is greater in men and prevented by topical nicotinamide. *J Invest Dermatol* 2008;128:447–54. <https://doi.org/10.1038/sj.jid.5701058>.
- [226] Chen AC, Martin AJ, Choy B, Fernández-Peñas P, Dalziel RA, McKenzie CA, et al. A phase 3 randomized trial of nicotinamide for skin-cancer chemoprevention. *N Engl J Med* 2015;373:1618–26. <https://doi.org/10.1056/NEJMoa1506197>.
- [227] Allen NC, Martin AJ, Snaird VA, Eggins R, Chong AH, Fernández-Peñas P, et al. Nicotinamide for skin-cancer chemoprevention in transplant recipients. *N Engl J Med* 2023;388:804–12. <https://doi.org/10.1056/NEJMoa2203086>.
- [228] Muranushi C, Olsen CM, Green AC, Pandeya N. Can oral nonsteroidal antiinflammatory drugs play a role in the prevention of basal cell carcinoma? A systematic review and meta-analysis. *J Am Acad Dermatol* 2016;74:108–119.e1. <https://doi.org/10.1016/j.jaad.2015.08.034>.

- [229] Weinstock MA, Bingham SF, Digiiovanna JJ, Rizzo AE, Marcolivio K, Hall R, et al. Veterans Affairs Topical Tretinoin Chemoprevention Trial Group. Tretinoin and the prevention of keratinocyte carcinoma (Basal and squamous cell carcinoma of the skin): a veterans affairs randomized chemoprevention trial. *J Invest Dermatol* 2012;132:1583–90. <https://doi.org/10.1038/jid.2011.483>.
- [230] Tang JY, Chiou AS, Mackay-Wiggan JM, Aszterbaum M, Chanana AM, Lee W, et al. Tazarotene: randomized, double-blind, vehicle-controlled, and open-label concurrent trials for basal cell carcinoma prevention and therapy in patients with basal cell nevus syndrome. *Cancer Prev Res* 2014;7:292–9. <https://doi.org/10.1158/1940-6207.CAPR-13-0305>.
- [231] Cardoso JC, Alves F, Carreira IM, Tellechea O. Basal cell carcinomas after radiotherapy show more frequent follicular differentiation than tumors from sun-exposed areas: immunohistochemical study with a special focus on infundibulocystic basal cell carcinoma. *Am J Dermatopathol* 2022 1;44(12):879–85. <https://doi.org/10.1097/DAD.0000000000002321>. PMID: 36395444.
- [232] Thorsness SL, Freites-Martinez A, Marchetti MA, Navarrete-Dechent C, Lacouture ME, Tonorezos ES. Nonmelanoma skin cancer in childhood and young adult cancer survivors previously treated with radiotherapy. *J Natl Compr Canc Netw* 2019 1;17(3):237–43. <https://doi.org/10.6004/jnccn.2018.7096>. PMID: 30865918; PMCID: PMC7401699.
- [233] Abdelwahab R, Huang R, Potla S, Bhalla S, AlQabandi Y, Nandula SA, et al. The relationship between vitamin D and basal cell carcinoma: a systematic review. *Cureus* 2022;14:e29496 <https://doi.org/10.7759/cureus.29496>.
- [234] Ramachandran S, Fryer AA, Smith A, Lear J, Bowers B, Jones PW, et al. Cutaneous basal cell carcinomas: distinct host factors are associated with the development of tumors on the trunk and on the head and neck. *Cancer* 2001;92:354–8. [https://doi.org/10.1002/1097-0142\(20010715\)92:2<354::aid-cnrc1330>3.0.co;2-f](https://doi.org/10.1002/1097-0142(20010715)92:2<354::aid-cnrc1330>3.0.co;2-f).
- [235] Jaju PD, Ransohoff KJ, Tang JY, Sarin KY. Familial skin cancer syndromes: Increased risk of nonmelanotic skin cancers and extracutaneous tumors. *J Am Acad Dermatol* 2016;74:437–51. <https://doi.org/10.1016/j.jaad.2015.08.073>.