

# De novo immune complex-mediated membranoproliferative glomerulonephritis after COVID-19 vaccination

---

Zagorec, Nikola; Bojić, Martin; Kasumović, Dino; Šenjug, Petar; Ljubanović, Danica Galešić; Galešić, Krešimir; Horvatić, Ivica

Source / Izvornik: **Clinical Kidney Journal, 2023, 16, 1183 - 1185**

Journal article, Published version

Rad u časopisu, Objavljena verzija rada (izdavačev PDF)

<https://doi.org/10.1093/ckj/sfad056>

Permanent link / Trajna poveznica: <https://um.nsk.hr/um:nbn:hr:105:548148>

Rights / Prava: [Attribution-NonCommercial 4.0 International/Imenovanje-Nekomercijalno 4.0 međunarodna](#)

Download date / Datum preuzimanja: **2024-11-29**




Repository / Repozitorij:

[Dr Med - University of Zagreb School of Medicine Digital Repository](#)



## LETTER TO THE EDITOR

## De novo immune complex-mediated membranoproliferative glomerulonephritis after COVID-19 vaccination

Nikola Zagorec <sup>1,\*</sup>, Martin Bojić<sup>2</sup>, Dino Kasumović<sup>1</sup>, Petar Šenjug<sup>2,3</sup>, Danica Galešić Ljubanović<sup>2,3</sup>, Krešimir Galešić<sup>1,2</sup> and Ivica Horvatić<sup>1,2,\*</sup>

<sup>1</sup>Department of Nephrology and Dialysis, Dubrava University Hospital, Zagreb, Croatia, <sup>2</sup>School of Medicine, University of Zagreb, Zagreb, Croatia and <sup>3</sup>Department of Pathology and Cytology, Dubrava University Hospital, Zagreb, Croatia

\*Equal contribution to the work.

Correspondence to: Nikola Zagorec; E-mail: [nikola.zagi@gmail.com](mailto:nikola.zagi@gmail.com)

Although vaccines against coronavirus disease 2019 (COVID-19) are generally well tolerated, since mass vaccination against COVID-19 began, the number of vaccine-linked cases of the *de novo* or relapsing glomerular diseases has been growing. Most cases have been associated with mRNA and adenovirus vector deliveries vaccines [1–7]. Göndör *et al.* recently reported a case of relapse of idiopathic immune complex-mediated membranoproliferative glomerulonephritis (IC-MPGN) after Pfizer's vaccine [8]. Although mentioned in article by Fenoglio *et al.* [7], to the best of our knowledge, *de novo* IC-MPGN triggered by COVID-19 vaccine has not been yet described according to available literature. We report a case of *de novo* IC-MPGN after the first dose of AstraZeneca vaccine.

**Case description:** A 65-year-old man with history of arterial hypertension, right-side nephrectomy due to trauma and diabetes mellitus type 2 of 2 months' duration presented to emergency department on 27 April 2021 with rapid-onset shortness of breath. His chronic medication included metformine, statin, perindopril and amlodipine. He had no previous adverse reactions to vaccines or history of hypersensitivity. On 7 April he received the first dose of AstraZeneca COVID-19 vaccine and polymerase chain reaction (PCR) severe acute respiratory syndrome coronavirus 2 (SARS-CoV-2) of nasopharyngeal swab was negative. He was diagnosed with bilateral segmental pulmonary embolism (PE) and incipient bilateral pulmonary effusion, and admitted to regional hospital. Complete blood cell count was

normal, serum creatinine (sCr) was 88  $\mu\text{mol/L}$ , serum albumin was 38 g/L and urine sediment was normal with proteins 1+ on dipstick. Diagnostic workup excluded deep venous thrombosis and there was no evidence of underlying malignant disease. He was treated with dalteparin and a low dose of furosemide, and after 7 days was discharged with rivaroxaban (5 mg twice daily), long-acting insulin, metformine/empagliflozin, statin and perindopril/amlodipine. Four days after hospital discharge (31 days after vaccination), he noticed progressive lower limb swelling and urine foaming and, due to worsening of symptoms and development of severe hypertension (210/110 mmHg), was referred to emergency department on 14 May. Diagnostic workup revealed elevated sCr (159  $\mu\text{mol/L}$ ), progression of pleural effusions, proteinuria (dipstick 3+) and erythrocyturia. At that moment, he was respiratory sufficient and not prone to hospitalization. He was recommendation for additional furosemide (40 mg twice daily) and antihypertensive therapy, and was referred to a nephrologist urgently. He visited a private nephrologist on 24 May (laboratory data shown in Table 1). Rivaroxaban was replaced with reduced dose of apixaban (2.5 mg twice daily) and eplerenone (12.5 mg twice daily) was added to the prior therapy. Despite strong recommendation for additional inpatient workup and treatment, he was not prone to hospitalization until 30 September, when he was admitted in our hospital (PCR to SARS-CoV-2 was negative). After kidney ultrasound evaluation, kidney biopsy was performed due to

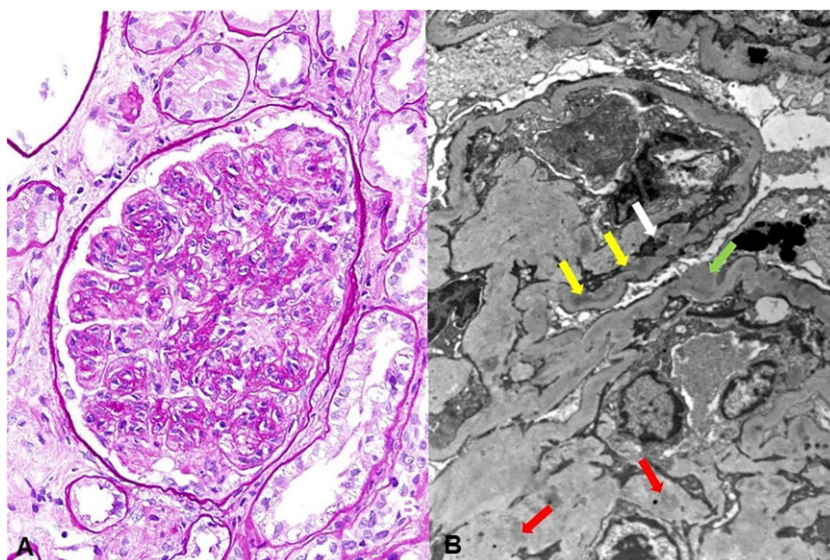
Received: 18.1.2023; Editorial decision: 20.3.2023

© The Author(s) 2023. Published by Oxford University Press on behalf of the ERA. This is an Open Access article distributed under the terms of the Creative Commons Attribution-NonCommercial License (<https://creativecommons.org/licenses/by-nc/4.0/>), which permits non-commercial re-use, distribution, and reproduction in any medium, provided the original work is properly cited. For commercial re-use, please contact [journals.permissions@oup.com](mailto:journals.permissions@oup.com)

**Table 1: Relevant patient's characteristics over time and treatment response.**

Patient's characteristics (units, ref.)	24 May 2021	30 September 2021 (Bx)	13 January 2023
Hemoglobin (g/L, 138–175)	143	122	128
Gross hematuria	No	No	No
Erythrocyturia (per HPF, <3)	>100	>100	6–10
24-h proteinuria (g/day, <0.15)	4+ (dipstick)	25	0.9
Serum creatinine ( $\mu\text{mol/L}$ , 64–104)	324	315	220
eGFR ( $\text{mL/min/1.73 m}^2$ , $\geq 60$ )	16	17	26
Serum albumin (g/L, 41–51)	23	28	45
Total cholesterol (mmol/L, <5)	n/a	8.1	4.9
Triglycerides (mmol/L, 1.7)	n/a	2.5	1.6
C4 (mg/L, 0.1–0.4)	n/a	0.51	n/a
C3 (mg/L, 0.9–1.8)	n/a	1.48	n/a

Bx, kidney biopsy; n/a, not available; HPF, high-powered field; eGFR, estimated glomerular filtration rate.



**Figure 1:** (A) Membranoproliferative pattern in glomerulus, periodic acid-Schiff stain, original magnification  $\times 400$ . (B) Remodeling of glomerular basement membrane with mesangial interposition (white arrow) and subendothelial (yellow arrows), subepithelial (green arrow) and mesangial immune deposits (red arrows), transmission electron microscopy, original magnification  $\times 5000$ .

persistent nephrotic-nephritic syndrome with renal insufficiency and refractory hypertension. Table 1 summarizes the relevant patient data. Histopathological analysis showed a membranoproliferative pattern of injury with immunoglobulin G, C3 and C1q deposits on immunofluorescence and characteristic findings on electron microscopy (Fig. 1). Chronic changes were mild and diagnosis of IC-MPGN of unclear etiology was established. The extensive clinical workup including complement system analysis ruled out neoplasia, infections, hematologic and other malignant disorders, as well as complement system dysregulation. Anti-SARS-CoV-2 serology performed 6 months after vaccination was negative. Methylprednisolone (MP) 1 mg/kg therapy was started and after workup completion, he received six doses of cyclophosphamide (500 mg) in a 3-week period. Low dose of MP was continued, and after a follow-up of 15 months, significant reduction of proteinuria was achieved with minimal erythrocyturia and stable renal function (Table 1).

We reported a case of *de novo* IC-MPGN in a patient who received AstraZeneca COVID-19 vaccine 31 days before onset of

first symptoms. Extensive diagnostic workup did not reveal any underlying cause of IC-MPGN which supports the possible role of vaccine-induced immune response in the pathogenesis of the disease. Preceding PE could be also linked to AstraZeneca vaccine and early stage of the ongoing nephrotic state could contribute to development of PE [9]. Selected immunosuppressive treatment was very effective in proteinuria reduction and stabilization of kidney function. To the best of our knowledge, there is only one mention of *de novo* MPGN after a second dose of Moderna vaccine in the literature, but without detailed description [7]. Sethi et al. reported a case of IC-MPGN after COVID-19 infection in a patient with previously known focal segmental glomerulosclerosis [10]. There is a report of MPGN in animal medicine after probable over-vaccination in dog [11]. Although the temporal association between vaccination and onset of first nephrologic symptoms in our case is consistent with previously reported cases of COVID-19 vaccine-linked nephrologic conditions, causality between vaccine and MPGN can only be presumed, so further investigations are needed to clarify this relationship.

## FUNDING

No funding was received for this work.

## AUTHORS' CONTRIBUTIONS

Conceptualization, N.Z., M.B and I.H.; methodology, N.Z., P.Š. and D.G.L.; validation, K.G., D.G.L. and I.H.; investigation, N.Z., M.B. and D.K.; data curation, D.K., M.B. and P.Š.; writing—original draft preparation, N.Z. and I.H.; writing—review and editing, D.K., P.Š., D.G.L., K.G. and I.H.; visualization, P.Š. and D.G.L.; supervision, D.G.L., K.G. and I.H.; all authors have read and agreed to the published version of the manuscript.

## CONFLICT OF INTEREST STATEMENT

All authors declare no conflict of interest.

## REFERENCES

1. Klomjit N, Priya AM, Fervenza FC. et al. COVID 19 vaccination and glomerulonephritis. *Kidney Int Rep* 2021;**6**:2969–78. <https://doi.org/10.1016/j.ekir.2021.09.008>.
2. Bomback AS, Kudose S, D'Agati VD. De novo and relapsing glomerular diseases after COVID-19 vaccination: what do we know so far? *Am J Kidney Dis* 2021;**78**:477–80. <https://doi.org/10.1053/j.ajkd.2021.06.004>.
3. Tan HZ, Tan RY, Choo J. et al. Is COVID-19 vaccination unmasking glomerulonephritis? *Kidney Int* 2021;**100**:469–71. <https://doi.org/10.1016/j.kint.2021.05.009>.
4. Morlidge C, El-Kateb S, Jeevaratnam P. et al. Relapse of minimal change disease following the AstraZeneca COVID-19 vaccine. *Kidney Int* 2021;**100**:459. <https://doi.org/10.1016/j.kint.2021.06.005>.
5. Gillion V, Jadoul M, Demoulin N. et al. Granulomatous vasculitis after the AstraZeneca anti-SARS-CoV-2 vaccine. *Kidney Int* 2021;**100**:706–7. <https://doi.org/10.1016/j.kint.2021.06.033>.
6. Villa M, Diaz-Crespo F, Perez de Jose A. et al. A case of ANCA-associated vasculitis after AZD1222 (Oxford–AstraZeneca) SARS-CoV-2 vaccination: casualty or causality? *Kidney Int* 2021;**100**:937–8. <https://doi.org/10.1016/j.kint.2021.07.026>.
7. Fenoglio R, Lalloni S, Marchisio M. et al. New onset biopsy-proven nephropathies after COVID vaccination. *Am J Nephrol* 2022;**53**:325–30. <https://doi.org/10.1159/000523962>.
8. Göndör G, Ksiazek SH, Regele H. et al. Development of crescentic membranoproliferative glomerulonephritis after COVID-19 vaccination. *Clin Kidney J* 2022;**15**:2340–2. <https://doi.org/10.1093/ckj/sfac222>.
9. Dag Berild J, Bergstad Larsen V, Myrup Thiesson E. et al. Analysis of thromboembolic and thrombocytopenic events after the AZD1222, BNT162b2, and mRNA-1273 COVID-19 vaccines in 3 Nordic countries. *JAMA Netw Open* 2022;**5**:e2217375.
10. Sethi S, D'Costa MR, Hermann SM. et al. Immune-complex glomerulonephritis after COVID-19 infection. *Kidney Int Rep* 2021;**6**:1170–3. <https://doi.org/10.1016/j.ekir.2021.02.002>.
11. Ortloff A, Morán G, Olavarría A. et al. Membranoproliferative glomerulonephritis possibly associated with over-vaccination in a cocker spaniel. *J Small Anim Pract* 2010;**51**:499–502. <https://doi.org/10.1111/j.1748-5827.2010.00978.x>.