

Endometriosis

Kerner, Miro

Master's thesis / Diplomski rad

2024

Degree Grantor / Ustanova koja je dodijelila akademski / stručni stupanj: **University of Zagreb, School of Medicine / Sveučilište u Zagrebu, Medicinski fakultet**

Permanent link / Trajna poveznica: <https://um.nsk.hr/um:nbn:hr:105:439727>

Rights / Prava: [In copyright](#)/[Zaštićeno autorskim pravom.](#)

Download date / Datum preuzimanja: **2025-01-11**



Repository / Repozitorij:

[Dr Med - University of Zagreb School of Medicine Digital Repository](#)



**UNIVERSITY OF ZAGREB
MEDICAL STUDIES IN ENGLISH**

Miro Kerner

Endometriosis

Graduate thesis



Zagreb, 2024

This graduate thesis has been made at the Clinical Hospital Centre Zagreb, Department of Obstetrics & Gynecology, Petrova 13, under the supervision, guidance, and mentorship of doc. dr. sc. Vladimir Banović, MD.
This thesis has been submitted for grading in the academic year 2023/2024.

LIST OF ABBREVIATIONS:

AFS- American Fertility Society

ASMR- The American Society for Reproductive Medicine

ESHRE- European Society of Human Reproduction and Embryology

BMI- Body mass index

CA-125 – Cancer antigen 125

DIE- Deep infiltrating endometriosis

IL-1, 6, 8 – Interleukin 1,6,8

TNF – Tumor necrosis factor

VEGF – Vascular endothelial growth factor

GnRH – Gonadotropin-releasing hormone

OE- Ovarian endometriosis

COCs – Combined oral contraceptives

NSAID – Non-steroidal anti-inflammatory drugs

COX-1, COX-2 – Cyclooxygenase 1&2

LH – Luteinizing hormone

FSH – Follicle-stimulating hormone

DRE- Digito-rectal examination

MDPA – Medroxyprogesterone acetate

IUD – Intrauterine device

FDA – Food and Drug Administration

DNA- Deoxyribonucleic acid

TVUS- Transvaginal ultrasound

TAUS- Transabdominal ultrasound

SPRM- Selective progesterone receptor modulators

SERM- Selective estrogen receptor modulators

LUNA – Laser uterosacral nerve ablation

RCOG- Royal College of Obstetricians and Gynecologists

ER- Estrogen receptor

PR- Progesterone receptor

EFI- Endometriosis fertility index

AAGL- American Association of Gynecologic Laparoscopists

VEGF- Vascular endothelial growth factor

AI- Aromatase inhibitors

MRI- Magnetic resonance imaging

CT- Computerized tomography

PGE2- Prostaglandin E2

NGF- Nerve growth factor

SWB- Subjective well-being

QoL- Quality of life

ART- Artificial reproductive technology

IUI- Intrauterine insemination

IVF- In vitro fertilization

TABLE OF CONTENTS:

SUMMARY	
SAŽETAK	
1. INTRODUCTION	1
2. HISTORY OF ENDOMETRIOSIS	2
3. PATHOPHYSIOLOGY AND RISK FACTORS	3
4. HISTOPATHOLOGY OF ENDOMETRIOSIS	8
5. CLINICAL SIGNS AND SYMPTOMS	12
6. BURDEN OF ENDOMETRIOSIS	14
7. EPIDEMIOLOGY OF ENDOMETRIOSIS	17
7.1 The prevalence and incidence of endometriosis	17
7.2 Problems regarding data analysis.....	18
7.3 Epidemiology of subtle endometriosis.....	18
7.4 Epidemiology of classical endometrial lesions.....	19
7.5 Epidemiology of cystic ovarian endometriosis.....	19
7.6 Epidemiology of deep infiltrative endometriosis.....	19
7.7 Epidemiology of peritoneal endometriosis	20
8. DIAGNOSIS OF ENDOMETRIOSIS	20
8.1 Clinical picture.....	20
8.2 Clinical physical examination.....	21
8.3 Blood biomarkers.....	22
8.4 Radiological examination (US, MRI, CT).....	23
8.5 Role of investigative Laparoscopy and patho-histology.....	28
9. CLASSIFICATION AND TYPES OF ENDOMETRIOSIS	29
9.1 Revised American Society for Reproductive Medicine (rASRM)	30
9.2 The ENZIAN	30
9.3 The Endometriosis Fertility Index (EFI).....	31
9.4 American Association of Gynecological Laparoscopists (AAGL).....	31
10. MANAGEMENT AND THERAPY	32
10.1 Pharmacologic therapy.....	33
10.1.1 Progestins.....	35

10.1.2	Combined oral contraceptives.....	36
10.1.3	GnRH agonists	37
10.1.4	GnRH antagonists	38
10.1.5	Aromatase inhibitors.....	39
10.1.6	Danazole	39
10.1.7	Selective progesterone receptor modulators (SPRMs)	40
10.1.8	Selective estrogen receptor modulators (SERMs)	40
10.2	Surgical therapy	41
10.2.1	Surgical treatment of Ovarian endometriomas	42
10.2.2	Surgical treatment of peritoneal endometriosis	44
10.2.3	Surgical treatment of Deep pelvic endometriosis	44
10.2.4	Laparoscopic uterosacral nerve ablation (LUNA).....	46
10.2.5	Presacral neurectomy (PSN).....	46
10.2.6	Oophorectomy (adnexectomy).....	47
10.2.7	Hysterectomy	47
10.3	Combined therapy.....	48
10.4	Residual endometriotic lesions	49
11.	ENDOMETRIOSIS AND INFERTILITY.....	50
12.	CONCLUSION	53
13.	GRATITUDE.....	54
14.	LITERATURE	55

SUMMARY

Author: Miro Kerner

Title: Endometriosis

Endometriosis is a gynecologic chronic inflammatory disease branded by the presence of ectopic endometrial tissue outside the uterus, frequently in the pelvis. Core symptoms of endometriosis are chronic pelvic pain, dysmenorrhea, dyspareunia, and infertility. John Sampson first described it and named it in 1920s. Endometriosis is a complex disease with an unknown correct origin. There are several mentioned theories with retrograde menstruation from fallopian tubes as the main one. Endometriosis has a heavy burden on patients and their relatives, as they lose capacity for work and coitus due to severe pain. It is believed that endometriosis is present in 5-10% of women of reproductive age. Diagnosis of endometriosis is by thorough patient history, clinical exam, and diagnostic workup (Ultrasound, MR). Unfulfilled diagnosis leads to investigative laparoscopy plus endometrial tissue biopsy which was once considered a “gold standard” for diagnosis. Investigative laparoscopy and visualization of the location and size of endometrial lesions is the only definitive diagnosis. Endometriosis treatment modalities include pharmacological, surgical, or combined treatment. Infertile women have the additional option of assisted reproductive technology. Treatment is not curative; it is usually suppressive (symptomatic) and tries to reduce the pain and burden. Pharmacological treatment relies on hormones that create a state of hypoestrogenism. These include progestogens, oral hormonal contraceptives, and gonadotropin-releasing hormone analogs, they suppress the size of the lesion and symptoms. Drugs currently under exploration as potential therapies, including aromatase inhibitors, gonadotropin-releasing hormone antagonists, and selective modulators of progesterone and estrogen receptors, have demonstrated value in reducing endometriotic lesions in experimental models. Surgical therapy is usually done laparoscopically when the first line pharmacologic treatment fails when the lesions are too big or when endometriosis is severe. Surgery is carefully elected to preserve the patient’s fertility and ovarian reserves.

Keywords: endometriosis, epidemiology, diagnosis, classification, treatment

SAŽETAK

Autor: Miro Kerner

Naslov: Endometrioza

Endometrioza je kronična upalna bolest obilježena prisutnošću ektopičnog endometrijskog tkiva izvan maternice, najčešće u zdjelici. Glavni simptomi endometrioze su kronična zdjelčna bol, dismenoreja, dispareunija i neplodnost. John Sampson je prvi opisao i imenovao ovu bolest. Endometrioza je kompleksna bolest nepoznatog točnog podrijetla. Postoji nekoliko teorija koje objašnjavaju njezin nastanak, s retrogradnom menstruacijom iz jajovoda kao glavnom teorijom. Endometrioza predstavlja veliko opterećenje za pacijentice i njihove obitelji, jer gube radnu sposobnost i sposobnost za spolne odnose zbog jake boli. Vjeruje se da je endometrioza prisutna kod 5-10% žena reproduktivne dobi. Dijagnoza se postavlja temeljem detaljne anamneze pacijentice, kliničkog pregleda i dijagnostičkih pretraga (ultrazvuk, MR). Kada ove metode ne daju zadovoljavajuću dijagnozu, provodi se istražna laparoskopija i biopsija endometrijskog tkiva, što je nekada smatrano "zlatnim standardom" za dijagnozu. Istražna laparoskopija i vizualizacija mjesta i veličine endometrijskih lezija jedina je konačna dijagnoza. Metode liječenja endometrioze uključuju farmakološko, kirurško ili kombinirano liječenje. Neplodne žene imaju dodatnu mogućnost asistiranu reproduktivnu tehnologiju. Liječenje nije kurativno, obično je supresivno, s ciljem smanjenja boli i opterećenja bolesti. Farmakološko liječenje uglavnom se oslanja na hormone koji smanjuju stvaranje estrogena. To uključuje gestagene, oralne hormonske kontraceptive i analoge gonadotropin-otpustajućeg hormona, koji suprimiraju veličinu lezija i simptome. Trenutno se istražuju lijekovi kao potencijalne terapije, uključujući inhibitore aromataze, antagoniste gonadotropin-otpustajućeg hormona i selektivne modulatore progesteronskih i estrogenskih receptora, koji su pokazali učinkovitost u smanjenju endometrijskih lezija u eksperimentalnim modelima. Kirurško liječenje obično se provodi laparoskopijom kada prvi red farmakološkog liječenja ne uspije, kada su lezije prevelike ili kada je endometrioza teška. Kirurški zahvati pažljivo se biraju kako bi se očuvala plodnost pacijentice i rezerva jajnika.

Ključne riječi: endometrioza, epidemiologija, dijagnoza, klasifikacija, liječenje

1. INTRODUCTION

In this overview paper we will cover a throbbing health issue, specific emphasis on epidemiology, diagnostic methods, and types of different treatment options. We will mention theories about endometriosis pathophysiology and pathobiology, as it is, unclear. We will discuss clinical signs and symptoms and how to suspect and treat this disease. Endometriosis is described as the presence of tissue resembling the inner lining of the uterus found outside the uterus itself. It is a chronic nonmalignant, otherwise known as, benign disease of the female reproductive tract (1). Endometriosis is considered a spectrum disease with a variability of subtypes and clinical presentations. Endometriosis is classically defined as a chronic disease characterized by endometrial-like tissue present outside of the uterus and is thought to arise by retrograde menstruation. However, this description is outdated and no longer reflects the true scope and manifestations of the disease. Endometriosis is now recognized as a systemic disorder, impacting the liver, adipose tissue, and metabolism, inducing inflammation, and altering gene expression beyond the pelvic region (2,3). This broader understanding will help with diagnostic and treatment. Endometrial lesions can manifest in many forms, including on the peritoneum, as surface growths, or as cysts on the ovaries, and can penetrate deeply into surrounding tissues. While the exact cause of endometriosis remains unclear, several theories attempt to explain its development. One option is retrograde menstruation, where menstrual tissue flows backward through the fallopian tubes into the pelvic cavity, potentially leading to the implantation of endometrial tissue in abnormal locations. However, this doesn't fully account for the development of endometriosis, suggesting other factors such as hormonal, inflammatory, or immune conditions may also play a role (2,3). The local environment likely influences the persistence of these lesions. It is important to note that while endometriotic growths resemble uterine tissue, they are not identical (2).

Endometriosis affects a considerable portion of women of reproductive age (5-10%) and is a usual cause of chronic pelvic pain (3). Unfortunately, many women experience a delay in diagnosis leading to prolonged suffering and difficult in assessing real prevalence. Early detection and treatment, ideally during adolescence when symptoms often begin, can help alleviate pain, prevent disease progression, and preserve fertility. Despite an elevated risk of ovarian cancer, preventive measures are available. However, barriers such as cost and diverse

symptoms hinder early diagnosis. Developing non-invasive diagnostic tools could facilitate earlier intervention, improving patients' lives and reproductive outcomes (3,4).

Current diagnostic methods and potential biomarkers for endometriosis are not yet sensitive or specific enough for widespread use (5,6). This review aims to explore the epidemiology of endometriosis and evaluate existing diagnostic tools and potential biomarkers to manage the disease better and to understand the quality of life for both adult and adolescent patients. Diagnosis is an interplay of clinical history and clinical examination, alongside diagnostic tools like ultrasound and magnetic resonance imaging. On time diagnosis is crucial in pain management. The only certain diagnoses typically involve direct visualization and histological examination, with treatment options including surgical removal and hormonal manipulation to alleviate symptoms. There is no cure for endometriosis, only a suppression of symptoms. Investigative laparoscopy was once thought to have been the gold standard of diagnosis and modern medicine has brought that into question. While surgery may offer some relief, its efficacy is limited, prompting contemplation of assisted reproductive technologies (3,4,5).

2. HISTORY OF ENDOMETRIOSIS

A recent dispute has arisen regarding the existence of early accounts describing the condition known as endometriosis. One of the initial inquiries in this debate is: "Who was the first to identify endometriosis?" The study of gynecologic diseases in women dates back over 4000 years (1). Hippocrates noted the link between menstrual dysfunction, pain, and infertility around 460 to 370 BC. This condition was initially documented by Daniel Shroen in 1690 in his publication "Disputatio Inauguralis Medica de Ulceribus Ulceri." Arthur Duff later outlined the symptoms of this illness in 1769 (1,2). In 1860, Carl von Rokitansky identified benign endometrial-like structures in ovarian tumors. Thomas Russel first described an ovary containing uterine mucosa in 1899, and in the early 1900s, Thomas Cullen detailed the microscopic features of endometriosis (1,2).

In 1908, a monograph authored by T.S. Cullen on adenomyosis was released (1,2). John Sampson, known as the "father of endometriosis," described twenty-three cases of hemorrhagic ovarian cysts with endometriosis in 1921 and proposed the term "endometriosis" in 1925 (2). Navrital and Kramer in 1936 set a theory that endometriosis arises from vascular spread. Javert,

in 1949 proposed that origin has different etiology factors like implantation theory, transport via lymphatic and vascular vessels, and penetration of endometrial tissue from uterine muscles. Weed and others, in 1980, proposed that the foundation of endometriosis stems from the failure of immune system in Mullerian ducts. Malick in 1982 proposed that endometriosis is a congenital or acquired weakness of fibrinolytic activity of the peritoneum (2,4). Beginning with J.A. Sampson's original theory, subsequent years of research have given rise to new hypotheses seeking to explain endometriosis. Despite extensive scientific investigation over time, Sampson's theory continues to prevail as the dominant hypothesis regarding the etiology of endometriosis (2,3).

3. PATHOPHYSIOLOGY AND RISK FACTORS

The exact pathogenesis of endometriosis is not completely understood; however, several theories have been proposed to classify the cause of endometriosis (3,4). The term "endometriosis" was devised by Sampson in 1927, inspired by previous portrayals of similar tissues by Rokitansky and Cullen. Endometriosis is characterized by the presence of endometrium-like glands and tissue outside the uterus, and their occurrence is unknown (4). The disease remains poorly understood, and research is vital for prevention, diagnosis, and treatment. It is thought that endometriosis arises from different back etiological risk factors. (figure 1.) While no animal model perfectly replicates human endometriosis, studies on endometriotic tissues provide valuable perceptions of the condition's pathophysiology. The current medical consensus is that primary endometriotic implants are formed from endometrial particles that reach the pelvic peritoneum through menstrual reflux (3).

Risk factors associated with endometriosis contain various aspects. Consistently reported patterns suggest that early onset of menstruation, shorter menstrual cycles, and lower body mass index (BMI) are associated with a heightened risk of endometriosis, while greater parity is linked to a lower risk. However, findings regarding factors like childhood and adult physical activity, dietary habits, exposure to environmental toxins, lactation, night shift work, and smoking have been conflicting. Further research is needed to explore the impact of early life and adolescent exposures on endometriosis risk, as risk profiles may differ between women diagnosed during adolescence and those diagnosed later in adulthood. Recent findings are intriguing, as they indicate that BMI is not correlated with the development of endometriosis (4). Nevertheless,

there has been a marked uptick in endometriosis cases among obese women compared to those with a normal weight (2). Diet plays a significant role in preventing the onset of endometriosis. Consuming green vegetables and fresh fruits is widely regarded as highly beneficial, while high red meat intake is associated with being malevolent (2,4). A crucial element in preventing primary endometriosis is maintaining a healthy lifestyle (2,3).

One of the below listed theories tries to explain the etiology of lesions, but after its formation, implementation of lesions begins. Implantation of endometrial tissue starts with adhesion. This is followed by the breakdown of the extracellular matrix and the growth and spread of the lesion. Ectopic endometrial tissue with differentiated glands and stroma usually needs estrogen for further development. This tissue triggers an immune-inflammatory response in the pelvic environment, producing anti-endometrial antibodies and reducing cellular immunity. The formation of the primary implant can damage the mesothelium, and immune responses can also cause similar damage. Additionally, lowered cellular immunity leads to inflammation which in turn causes fibroblast infiltration and gives endometrial lesions their characteristic fibrotic surroundings (3,4,5,6).

Sampson projected that cystic ovarian endometriosis may result from retrograde menstruation. This theory is appealing because menstrual fluid, demonstrated to contain living cells as early as 1921, has shown potential for implantation and growth, as evidenced by studies involving subcutaneous injection in 1958 and growth in vitro and on the chicken semipermeable membrane (3). The chief theory on the cause of endometriosis, suggests that the condition results from fragments of endometrial tissue shed during menstruation that implant in the abdominal cavity via the fallopian tubes (4). This theory is supported by observations of endometrial glands in the fallopian tubes and blood during menstruation. Another theory posits that undifferentiated endometrial cells shed during menstruation can self-renew in the pelvis or peritoneal cavity, contributing to the development of endometriosis. Factors such as outflow obstruction and cesarean scar sites have also been associated with the condition (5). Studies in nonhuman primates have shown that injecting menstrual products into the peritoneal cavity or inducing retrograde menstruation can lead to the development of endometriosis, emphasizing the role of retrograde menstruation in the disease (5,6).

Dr. Cullen was the first one to come across this idea in his work *Adenomyoma of the Uterus* (1908) (5,6). Endometriosis has been documented in extrapelvic sites such as the diaphragm, pleura, lung, and pericardium, where retrograde menstruation is not possible. These findings have led to the hypothesis of celomic metaplasia in the pathogenesis of endometriosis (4). Marsh and Laufer described five cases of endometriosis in premenarchial girls aged 8.5 to 13 years who lacked any obstructive anomaly, indicating that some instances of endometriosis may arise from mechanisms other than retrograde menstruation (4). In 1942, Gruenwald described the celomic metaplasia theory, suggesting that celomic epithelium, due to its embryological relationship with Müllerian ducts, can give rise to endometriosis in various parts of the body (2,4). Furthermore, studies propose that endocrine-disrupting chemicals might induce the transformation or activation of these celomic cells (2,4). The elevated incidence of endometriosis in women exposed to diethylstilbestrol in utero further supports the notion that, under hormonal influence, these celomic cells can undergo metaplastic changes, culminating in endometriosis (4).

Ectopic endometrial tissue has been found in female fetuses, which suggests that problem is during embryogenesis might lead to endometriosis. This could happen because leftover embryonic cells from the Wolffian or Müllerian ducts might turn into endometriotic lesions when exposed to estrogen (3). Dr. Bulun explained that changes in the DNA of pelvic tissue cells, like hypomethylation of SF1 and ER- β promoters, due to environmental or genetic factors during development, can make someone more likely to develop endometriosis. This theory is called embryogenic rest (4).

Endometriosis, a condition marked by the presence of endometrial tissue beyond the uterus, isn't solely linked to retrograde menstruation. Instead, it is believed that during menstruation, endometrial cells might journey through the uterine vasculature or lymphatic system and relocate to other areas. This is called the theory of metastasis (4). These cells can flourish in favorable environments, potentially leading to endometriosis in places outside the pelvic region, like lymph nodes, lungs, liver, and brain. Research by Samani et al. using a mouse model revealed the existence of endometriosis-derived cells in numerous organs, suggesting that the widespread spread of the disease might be more prevalent than previously understood (4,6). While the movement of endometrial cells via lympho-vascular channels likely plays a role in the

development of endometriosis, it isn't the primary means of disease dissemination, as the occurrence of endometriosis in distant organs is relatively rare (4).

Undifferentiated cells with the capacity to self-renew and give rise to more differentiated daughter cells are known as stem cells. Endometrium typically contains mesenchymal stem cells. While menstrual material is directed outside of the uterus during retrograde menstruation, it could be the Mesenchymal stem cell differentiation inside this backflow that leads to the development of endometriosis. A great deal of research has been done on the molecular biology needed for endometrial implants to develop and survive. Briefly, the necessary mechanisms are the multiplication of the ectopic endometrial cells, infiltration into the mesothelium and survival, and attachment of endometrial cells to the pelvic peritoneum in areas of previous damage (4,6). Angiogenesis may then lead to the establishment of endometriosis's focal point and the possibility of future enlargement for endometriosis (4,7).

The role of hormones is important for both the formation and upkeep of endometriosis. Just like how the normal endometrium in the uterus grows, it is thought that the abnormal tissue outside the uterus is controlled by these hormones too. Both the normal and abnormal tissues might be extra sensitive to estrogen, making endometriosis worse (5). Also, the endometriotic tissue might have more estrogen because nearby cells change other hormones into estrogen. But progesterone, which usually balances out estrogen, does not work as well in people with endometriosis because their endometrium has fewer receptors for it, called progesterone resistance. It is now known that certain cells in endometriosis have messed up chemical patterns, making them less responsive to progesterone (4,6). This means that endometriosis can stick around longer, causing ongoing inflammation (4).

While all women are thought to experience some degree of retrograde menstruation, 4% of women develop endometriosis (4). This is due to the theory of altered immunity. The adherence and proliferation of endometriotic cells depend on a sufficient and favorable microenvironment. Endometriosis is thought to be associated with altered cell-mediated immunity, which prevents immune cells from identifying and attacking endometriotic deposits. In patients with endometriosis, cellular immunity is compromised, evidenced by a lower number of T-cells and improper activation of NK cells, which reduces their cytotoxic effect (5). There is often an increased presence of macrophages and leukocytes around the endometrial implants and in the peritoneal fluid. These cells secrete cytokines and growth factors such as IL-1, IL-6, IL-8

(interleukins), TNF (tumor necrosis factor), and VEGF (vascular endothelial growth factor), resulting in the proliferation of the implants and enhanced vascular supply (4,5).

Sampson proposed retrograde menstruation as the cause of cystic ovarian endometriosis, supported by evidence of menstrual fluid containing viable cells capable of implantation and growth (7,8). However, the retrograde menstruation and implantation theory fails to explain all clinical observations, such as extragenital endometriosis or its occurrence in individuals without endometrium. The last factor influencing endometriosis is the role of genetics and epigenetics. It has long been recognized that families of affected patients have a higher risk of developing endometriosis. It is still unknown what causes the mutation or change (4). Monozygotic twins' occurrence of endometriosis also supports the idea that there is an underlying rise in genetic vulnerability. According to molecular research, the eutopic endometrium in endometriosis cases exhibits a variety of molecular abnormalities, such as the activation of the WNT gene (mouse mammary tumor virus) and biosynthetic cascades that lead to an increase in the production of prostaglandins, cytokines, estrogen, and metalloproteinases (4,5). A minimum of five chromosomal regions are significantly linked with endometriosis by a meta-analysis of eleven genome-wide association studies. Additionally, 79% of deep endometriotic lesions in research that used exome sequencing to analyze the lesions had somatic mutations. Mutations were detected in 26% of these lesions in genes known to be cancer drivers, including ARID1A, PIK3CA, KRAS, and PPP2R1A. Interestingly, these alterations were restricted to epithelial cells. These results could help to explain why deeply infiltrating endometriosis tends to be harder to treat than superficial peritoneal lesions (3,4,5).

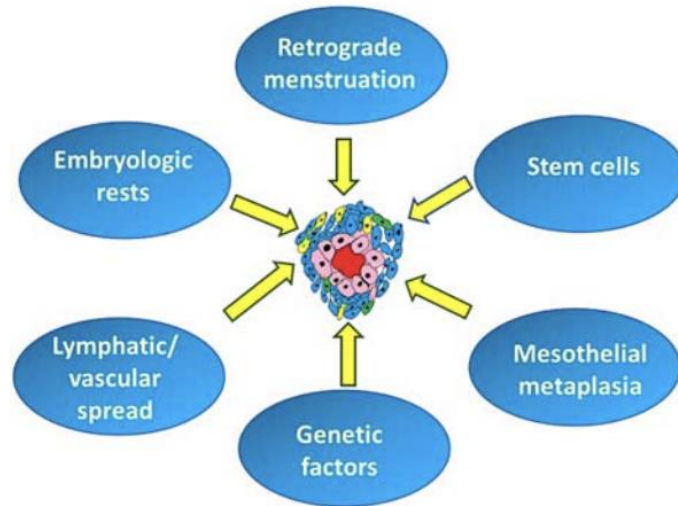


figure 1. Accounts for all the variables that are etiologic for endometriosis. Modified and adjusted from Koninckx PR, Ussia A, Adamyan L, Wattiez A, Gomel V, Martin DC. Pathogenesis of endometriosis: the genetic/epigenetic theory (3).

4. HISTOPATHOLOGY OF ENDOMETRIOSIS

According to Brosen's histological classification from 1993, diverse types of endometrioses can be identified (1,4). The mucosal type occurs within ovarian endometrial cysts. The peritoneal type displays diverse morphology with multiple foci, including early glandular or follicular lesions, advanced black, wrinkled changes, and white fibrotic lesions. Lastly, the glandular type is characterized by the prevalence of fibrous-muscular tissue and is commonly linked to deeply infiltrating endometriosis (2,3). So, the macroscopical histologic division from 1993 is 1. Ovarian endometriosis, 2. Superficial peritoneal endometriosis and, 3. Deep infiltrating endometriosis (2).

Ovarian endometriosis is the most common type and is characterized by numerous reddish nodules on the ovarian surface, called endometrioma. Endometriomas are often called chocolate cysts and are fused as the menstrual cycles continue and are filled with menstrual blood. Superficial peritoneal endometriosis is a type with involvement of superficial lesions. In the early stage, they are non-pigmented and poorly vascularized, which changes with time (from reddish to blue) and the degree of fibrosis increases with time progression. Deep infiltrating

endometriosis is characterized as a type that invades into nearby tissues more than 5 mm deep, creating endometriotic nodules surrounded by fibromuscular tissue. Deep infiltrating endometriosis can affect other organs (the colon, bladder, ureters, Douglas pouch) (4,6,8).

Endometriosis typically occurs in several pelvic locations, including the ovaries (figure 2. a) uterosacral ligaments (figure 2. b), broad or round ligaments (figure 2. c), rectovaginal septum, cul-de-sac, serosa of the uterus, fallopian tubes (figure 3.), ectocervix (figure 4.), and other pelvic organs. Chronic hematosalpinx, marked by blood accumulation in the fallopian tube, can be observed in conjunction with endometriosis affecting the ovary or fallopian tube (3,9). A deep comprehension of the histo-pathogenesis and pathophysiology of endometriosis is vital for the advancement of innovative diagnostic and therapeutic methods for this debilitating condition (10,11).

Diagnosing endometriosis microscopically is usually straightforward. We look for at least two of these things: endometrial glands, endometrial stroma, and hemosiderin-laden macrophages. The glands are typically lined with a specific type of epithelium and surrounded by a bunch of small endometrial stromal cells. When endometrial tissue in the ovary bleeds, it forms a cyst called an endometrioma (9,10). These cysts are different from normal ovarian cysts because they have fibrotic walls, and adhesions on the surface, and are filled with a brownish material. During menstruation, bleeding occurs within the cysts, leading to inflammation and the formation of specific cells called pseudoxanthoma cells (3,9,10). Endometriotic glands and stroma hold estrogen receptor (ER) and progesterone receptor (PR), and we use CD10 staining, which we use to identify stromal cells (3).

The differential diagnosis of endometriosis includes conditions like endosalpingiosis, low-grade endometrial stromal sarcoma, and adenosarcoma. Identifying features such as typical areas of sarcoma, mitotic activity, and vascular invasion help differentiate these conditions. Endometriosis involving the cervix presents a range of potential diagnoses from benign changes to malignant subtypes like endocervical adenocarcinoma (4,6).

Endometriosis has been linked with ovarian epithelial tumors and various other types of cancers and chronic medical conditions. Numerous studies have investigated the relationship between endometriosis and ovarian epithelial tumors, with around 16 studies showing a statistically significant positive connection (risk ratio = 4.6; 95%) (3,12). Women with endometriosis have a 2- to 3-fold increased risk of developing ovarian epithelial tumors, with

clear cell carcinoma and endometrioid carcinoma being the most common, followed by borderline sero-mucinous tumors (3,12,13). Although most studies showed no association between endometriosis and endometrial cancer, reports suggested a positive association, and 1 study reported an inverse association (13,14,15).

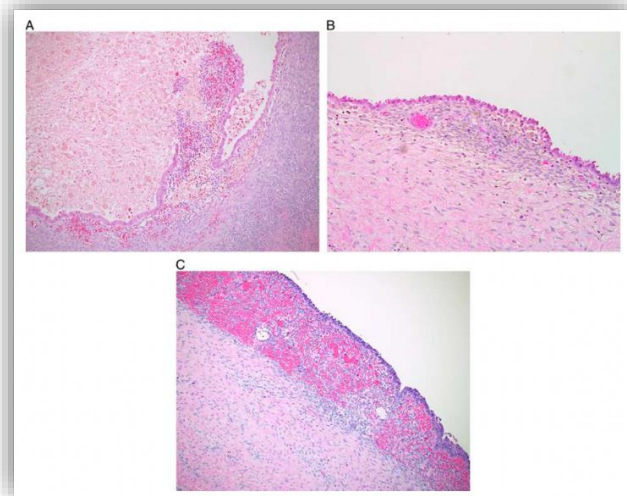


figure 2. a) Microscopical image of the ovary. b) Microscopic image of uterosacral ligaments. c) A microscopic image of the round ligament of the uterus notes the characteristic endometrial gland and stroma invasion. Image modified and adjusted from Arafah M, Rashid S, Akhtar M. Endometriosis: A Comprehensive Review (4).

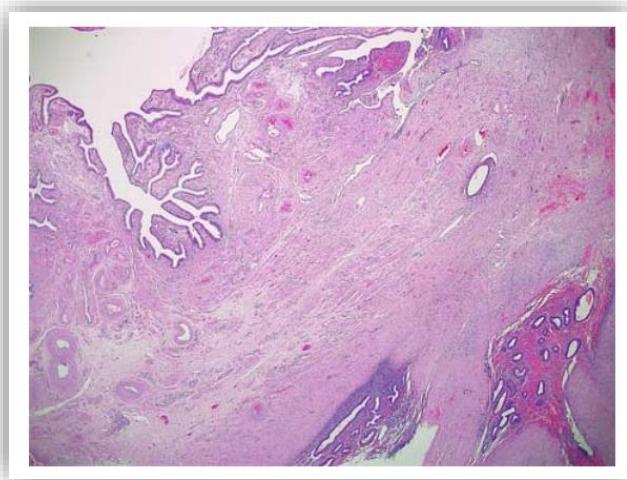


figure 3. Involvement of fallopian tubes of endometriosis with visible mesosalpinx. Image modified and adjusted from Arafah M, Rashid S, Akhtar M. Endometriosis: A Comprehensive Review (4).

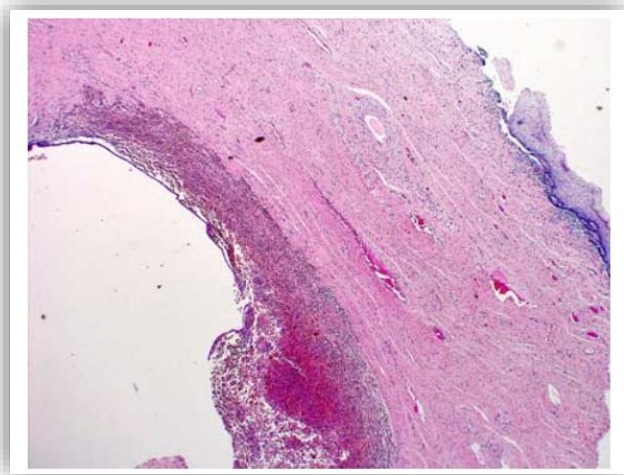


figure 4. Microscopical image of ectocervix biopsy with visible endometriosis surrounded by hemosiderophages. Image modified and adjusted from Arafah M, Rashid S, Akhtar M. Endometriosis: A Comprehensive Review (4).

Surgical pathology's importance of diagnosing endometriosis entails identifying a combination of at least two of three essential components: 1. endometrial stromal cells, 2. endometrial epithelial cells, and 3. evidence of chronic bleeding within endometrium-like tissue, such as the presence of red blood cell accumulations and hemosiderin-laden macrophages (immune cells that ingest blood pigment) (16,17). Moreover, fibrosis, characterized by the presence of fibroblasts and extracellular matrix, commonly surrounds endometriotic implants, suggesting significant inflammation and tissue restructuring (18,19).

5. CLINICAL SIGNS AND SYMPTOMS

Endometriosis, a complex and often debilitating condition, presents a variety of symptoms, typically in combination. Women with endometriosis typically exhibit symptoms that peak during their reproductive years, often exacerbated during menstruation (table 1.). Endometriosis is extremely rare in hypoestrogenic states like premenarchal, or post-menopausal (4). Clinical signs can be grouped according to their frequency so often we say the three most common symptoms are: Pelvic pain, dysmenorrhea (gradually increasing acute premenstrual pain), and dyspareunia (table 2.) (4,20). Symptoms of endometriosis are typically cyclical, but they are not predictive. The symptoms usually begin a few days before each menstrual period and subside once menstruation starts (20). One common manifestation is infertility, affecting many women with the condition. Endometriosis is often asymptomatic and is frequently discovered during evaluations for infertility (4). Pain is another hallmark symptom, often characterized by chronic pelvic discomfort (20,21). This pain can be cyclic, mirroring the menstrual cycle, or constant, resulting from repeated inflammation caused by ectopic endometrial tissue. Over time, this inflammation may lead to the formation of adhesions, exacerbating the pain, which causes discomfort and work absence. Severe dysmenorrhea, or painful menstrual periods, is frequently reported among individuals with endometriosis and may also be indicative of concurrent adenomyosis, a related condition (20,21,22). Dyspareunia, or painful sexual intercourse, particularly deep pain, suggests potential involvement of the uterosacral ligaments (4,20). Dysuria, or painful urination, signals possible bladder or peritoneal involvement, or even invasion into the bladder itself. Dyschezia, difficulty with bowel movements, and cyclic pararectal bleeding may occur in cases where rectovaginal nodules invade the rectal mucosa,

further complicating the symptom profile (20,21). Chronic fatigue is another common complaint among those with endometriosis, likely stemming from the physical and emotional toll of living with chronic pain and the associated stress (20). Additional symptoms such as fatigue, dyschezia, gastrointestinal disturbances, abdominal bloating, nausea, and stomach discomfort, particularly during menstruation, may also arise, with variations depending on the specific site of endometrial involvement, such as lower urinary tract symptoms in cases of urinary bladder endometriosis (4,20). Importantly, pain symptoms in endometriosis are often nonspecific, leading to delays in diagnosis that can extend up to 10 years in some cases (21). Furthermore, it's noteworthy that a significant proportion of individuals, ranging from 2%-50%, may experience endometriosis without any noticeable symptoms at all (20).

These would be clinically important questions a doctor must ask patients with endometriosis: How severe is your pelvic pain, and does it interfere with daily activities? Do you have painful menstrual periods (dysmenorrhea), and if so, how debilitating are they? Have you noticed pain during sexual intercourse (dyspareunia), and if so, where? Are you experiencing difficulties with fertility, or have you had trouble getting pregnant? Are you experiencing any other symptoms such as fatigue, gastrointestinal issues, or urinary problems?

Key point for history taking when considering endometriosis
→ Chronic pelvic pain (pain that persists more than 3 months)
→ Common symptom cluster DYSMENORRHEA, DYSPAREUNIA, DYSCHEZIA, DYSURIA
→ Symptoms based on organ systems: Genital tract: post-coital bleeding Urinary tract: dysuria, hematuria, pollakiuria, flank pain GI: dyschezia, boating, diarrhea, constipation, nausea, emesis Diaphragm: shoulder pain, subcostal pain, pneumothorax Nerve involvement: sciatic pain worse in menses General fatigue and malaise
→ Infertility

table 1. Shows classical endometrial symptoms. Taken and adjusted from Singh SS, Allaire C, Al-Nourhji O, Bougie O, Bridge-Cook P, Duigenan S, Kroft J, Lemyre M, Leonardi M, Leyland N, Maheux-Lacroix S, Wessels J, Wahl K, Yong PJ. Guideline No.449: Diagnosis and Impact of Endometriosis - A Canadian Guideline. (61)

Common symptoms	Percentage %
Dysmenorrhea	60-80%
Chronic pelvic pain	40-50%
Dyspareunia	40-50%
Infertility	30-50%
Severe menstrual pain and dysmenorrhea	10-20%
Tenesmus, dyschezia, hematochezia, diarrhea	1-2%
Dysuria, pollakiuria, hematuria	1-2%

table 2. Shows us the prevalence of symptoms according to their incidence in patients diagnosed with endometriosis. Modified and adjusted from Bulletti C, Coccia ME, Battistoni S, Borini A. Endometriosis, and infertility. (59)

6. BURDEN OF ENDOMETRIOSIS

Endometriosis is a chronic, inflammatory disease affecting more than 170 million women worldwide and up to 10% of women of reproductive age (22,23). Chronic diseases cause a variety of burdens in patients' lives which must be considered. The burden of a disease takes a toll not only on a patient's physical health but on their financial, social, psychological, and family health and habits. Endometriosis symptoms play a significant role in their mental health, leading to conditions like depression and anxiety, and straining their social connections (24,25). Moreover, it hampers sexual relationships and social interactions, while also causing significant economic burdens on both individuals and society due to decreased work productivity and increased healthcare utilization. As a result, the symptoms of endometriosis significantly disrupt women's lives, profoundly impacting their overall quality of life (22,23).

Diagnosed symptomatic women are more inclined to endure a lower quality of life, notably in areas such as pain, physical capabilities, limitations in both physical and mental roles, and social functioning when compared to symptomatic women without the condition (26,27). Two-thirds of endometriosis patients report a negative QoL impact, due to pain (22). In a recent real-world study conducted in Europe, encompassing 27,840 women (VIPOS), it was found that the majority (82.8%) reported experiencing at least one of the classical triads of pain symptoms associated with endometriosis, including pelvic pain, painful menstrual periods, and pain during or after sexual intercourse (22,28). It is important to distinguish different factors associated with low quality of life:

Mental health and endometriosis are correlated with major studies, as patients experience mental health problems such as anxiety and depression. Because of differences in study design and outcome measures, the prevalence of depression among women with endometriosis varies widely, ranging from 10% to as high as 86%, compared to 14% in healthy controls, while estimates for anxiety range from 10%-79% in women with endometriosis, compared to 12% in healthy controls (28,29,30,). The experience of chronic pain can result in diminished mental well-being, while mood disorders, in turn, have the potential to impact how pain is perceived (22,25).

Symptoms related to endometriosis can impact the sexual lives of women by reducing both the frequency and quality of intercourse, ultimately compromising overall sexual activity, self-esteem, and satisfaction (23,31). The adverse effects of endometriosis on sexual intimacy stem from dyspareunia, chronic pelvic pain, and psychological factors, particularly depression (23,32,33). Vercellini et al. conducted a study comparing three groups: women with rectovaginal endometriosis (n = 100), peritoneal and/or ovarian endometriosis (n = 100), and a group of healthy controls (n = 100) (32). The study found that women with endometriosis reported more frequent and severe deep dyspareunia, leading to poorer sexual functioning compared to controls (67%, 53%, and 26%, respectively) (23,32). However, there were no statistically significant differences observed between women with different types of endometriosis localization (rectovaginal or peritoneal/ovarian) (22,23,32). Worst QoL and worst dyspareunia have patients with DIE (33).

In a recent study assessing subjective well-being (SWB) and health-related quality of life (HRQoL), findings revealed that women with endometriosis reported a detrimental effect on

their relationships, particularly due to a perceived lack of understanding and support from others (23,34). Research has indicated that women often experience feelings of shame regarding their condition, leading them to feel left alone from discussing their health with their employer, colleagues, friends, and family members (23,35).

Endometriosis is additionally linked to significant financial strain, encompassing direct expenses such as physician consultations, surgical procedures, treatments, diagnostic tests, and hospital stays, as well as indirect costs resulting from productivity declines (22,23,36). The economic burden of endometriosis has been extensively studied in literature. According to findings from the EndoCost study, a prospective, multicenter survey conducted across 10 European countries, the average annual total cost per patient with endometriosis in 2008 amounted to €10,000, covering both healthcare expenditures and productivity losses (23,37). Items of health care costs were surgery (29% of health care costs), monitoring tests (19%), hospitalization (18%), and physician visits (16%). A big study involving many countries found that women with endometriosis missed about 11 hours of work per week on average (absenteeism) (37). Additionally, they were less productive while working, losing over 6 hours per week due to reduced efficiency (presenteeism) (23,36,38). Endometriosis is the third leading cause of gynecologic hospitalizations in the United States and a major reason for hysterectomies (4). Endometriosis, being a chronic and multifaceted condition, carries a notable psychosocial burden that significantly diminishes the quality of life (figure 5.). This burden is driven by the presence of pain, disturbances in social and intimate connections, and, in certain cases, compromised fertility. Additionally, endometriosis imposes considerable economic challenges, both on an individual and societal scale, due to healthcare expenses, treatment costs, and decreased productivity in the workplace (23,28,31).

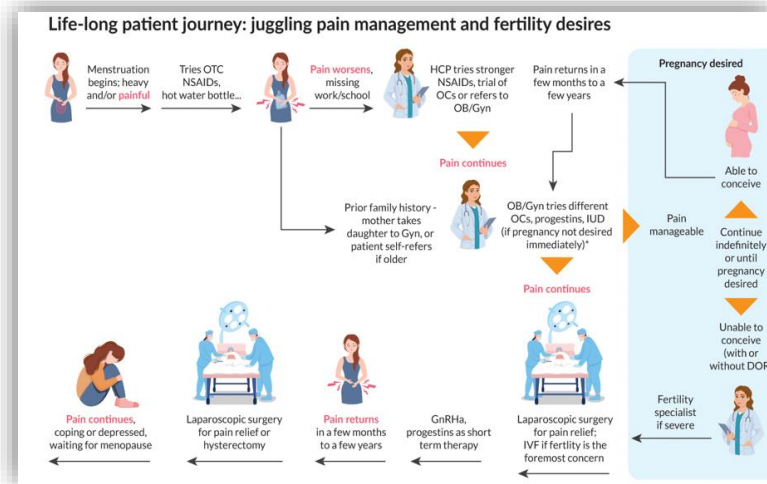


figure 5. Explains a life cycle and the constant burden of a patient struggling with EM. Modified and adjusted from Yen CF, Hamdan M, Hengrasmee P, Huang Z, Jeong K, Dao LA, Lertvikool S, Mogan S, Pal B, Sumapradja K, Wu MH, Yap-Garcia MIM, Donovan C, Christopher S, Kim MR. Improving the diagnosis of endometriosis in Asia-Pacific: Consensus from the Asia-Pacific Endometriosis Expert Panel for Endometriosis (22).

7. EPIDEMIOLOGY OF ENDOMETRIOSIS

7.1 The prevalence and incidence of endometriosis

Determining the prevalence and incidence rates of endometriosis in the general population is hard and challenging because a definitive diagnosis necessitates histopathological evaluation of a surgically obtained sample (4). The often-mentioned prevalence of endometriosis in women of childbearing age is 10% - 15% (4,39). Most cases of endometriosis occur in women between their first menstrual period (menarche) and menopause. The disease is most common between the age groups of 25 to 45 (4,40).

Studies have indicated that the risk of endometriosis is linked to ethnicity, with Asian women having a 9-fold higher risk compared to European American white women (4,41). Also, more cases of endometriosis are being reported among women with higher socioeconomic status and those in higher-level jobs (4,42). Abundant studies consistently show that having a family

history of endometriosis raises the risk of developing the condition. First-degree relatives, like parents or siblings, face a 3- to 9-fold higher risk of developing the disease (4,42,43).

There is not much information available about the incidence of endometriosis in the general population. Houston et al. discovered that from 1970 to 1979, the general rate of histologically confirmed endometriosis was 160.4 per 100,000 person-years among women aged 15 to 49. The highest rate occurred between 35 and 44 years, reaching 342.3 per 100,000 person-years (44,45). In a different study in a well-developed USA in the nearby region there was another study suggesting similar incidence numbers (44). Leibson et al. found that between 1987 and 1999, the general rate of clinically diagnosed endometriosis was 187 per 100,000 person-years among women aged over 15 (46). The peak incidence was observed between ages 25 and 34, reaching 380.6 per 100,000 person-years (44,46).

7.2. Problems regarding data analysis

The primary methodological challenges in studying endometriosis, whether in clinical settings, populations, or laboratories, involve selecting a valid (I) definition for what constitutes a case of endometriosis, and (II) comparison group, as well as (III) defining the appropriate time frame to capture exposures, outcomes, and disease progression to address the goals of the study (44,47). Determining the precise onset of endometriosis is difficult as symptoms typically need to reach a certain threshold before seeking evaluation. In the case of endometriosis, the literature suggests an average delay of 7 years from symptom onset to surgical diagnosis (44,48).

It is important to mention that endometriosis comes in different “shapes and sizes” affecting patients differently. Regarding women experiencing pain or infertility, the prevalence of subtle was 80%, classical was 50%, cystic ovarian was 30%, and deep involving endometriosis was 1-5% reported in cases (43).

7.3 Epidemiology of subtle endometriosis

Subtle endometriosis is discovered in 40% of women who do not show any symptoms. Among women experiencing pain or infertility, over 60% have subtle lesions (39,49,50). Subtle endometriosis refers to an endometrial finding on laparoscopy. The occurrence of endometriosis decreases as women age (43,51,52). The epidemiology of subtle endometriosis over time doesn't

support the conclusion that its prevalence has been increasing in recent decades, as the data are not sufficient to draw that conclusion, but as the research data evolve so will the premise (43).

7.4 Epidemiology of classical endometrial lesions

In asymptomatic women, typical lesions were reported in up to 5% of women who needed therapy; for instance, in 4% of women undergoing tubal ligation, and in 1.6% and 2.2% in Norway (53,54). In the study, the risk was higher in women with early menarche, frequent menstruation, pelvic pain, infertility, and those without children (43).

Among adolescents suffering from severe dysmenorrhea, 50% were diagnosed with endometriosis (55). For women experiencing both pain and infertility, typical lesions were found in 40-70% of cases, with an average of 33% (43,56,57).

7.5 Epidemiology of cystic ovarian endometriosis

There isn't any crucial evidence suggesting that the prevalence of cystic ovarian endometriosis has been rising in recent decades. Also, no link has been found between cystic ovarian endometriosis and pollution or lifestyle factors. The connection with ovarian cancer remains uncertain. Ovarian endometriomas can be detected in 4–10% of women of childbearing age and 50% of women undergoing infertility treatment (43,58).

7.6 Epidemiology of deep infiltrative endometriosis

The prevalence of cystic ovarian endometriosis in the general population falls between 0.2 and 0.5%. For women facing both pain and infertility, this rate increases to an estimated 3 to 10%. Interestingly, 10 to 20% of women referred to Leuven for pain were diagnosed with deep endometriosis (43,59). There's no solid evidence showing that deep endometriosis is becoming more common or that it's caused by pollution or lifestyle choices (59). However, well-known surgeons who specialize in deep endometriosis, and who have performed between 1000 and 3000 surgeries each over the past two decades, strongly believe that deep endometriosis is becoming more severe, and more common too, but that's just subjective thinking (43,49).

7.7 Epidemiology of peritoneal endometriosis

Peritoneal endometriosis can be found in 15–50% of all women diagnosed with endometriosis. They are often common and are associated with the retrograde menstruation hypothesis as the foundation (4). Peritoneal endometriosis often comes with ovarian endometriosis and can be seen in DIE. PE results of epidemiology cannot be entirely correct as a lot of them are difficult to spot via TVUS as they are superficially located. Diagnosis is usually made on investigative laparoscopy (54).

8. DIAGNOSIS OF ENDOMETRIOSIS

A clinician's method of diagnosis should be personalized for each patient, considering their clinical presentation, priorities, and unique needs (60). Endometriosis requires an accurate and timely diagnosis to provide reciprocal and adequate care, as well as protection against complications (22). As we discussed in the previous chapter, in symptomatic patients, we can clearly distinguish three major symptoms of Endometriosis which are:

pelvic pain, menstrual irregularities(dysmenorrhea) and painful intercourse (Dyspareunia).

When we talk about diagnosis, we must dilute what we consider when establishing a diagnosis.

The important fact is that patients are often diagnosed late (7-10 years on average) (4). An immense help comes from diagnostic tools. Diagnostic tools are as follows: clinical picture (symptoms), clinical physical examination, blood biomarkers, radiology examinations (TVUS, TAUS, MR, and CT), pathohistology, and surgical conformational laparoscopy (22).

8.1 Clinical picture

When evaluating a patient suspected of having endometriosis, it's important to start with a detailed history. This includes going over their symptoms, medical background, past treatments, how it affects their quality of life, and their care goals. It's also essential to document their medical, surgical, and family history, especially any cases of endometriosis in the family, to understand the full clinical picture (61).

Patients with endometriosis often experience pelvic pain, but it can also be related to many other conditions, as explained in detail in the SOGC Chronic Pelvic Pain Guideline.

(61,62) Higher and more frequent pelvic pain especially around menstruation indicates a higher probability of endometriosis. (63,64) Between 50% and 80% of patients diagnosed with endometriosis report having dysmenorrhea and up to 70% of individuals experiencing dysmenorrhea will be diagnosed with endometriosis (62,63,64,65).

In people diagnosed with endometriosis, about 10-30% to 30-50% may face infertility. Among those experiencing infertility despite normal ovulation and a partner with normal sperm count, up to 50% may receive a diagnosis of endometriosis (61,66,67).

8.2 Clinical physical examination

Doing a physical exam is key to diagnosing endometriosis, and some parts of it require specific training and skills. The link between physical examination results and the presence of endometriosis is not flawless, as some variables play a role in it. Crucial parts of every diagnostic physical exam are the speculum exam, bimanual palpation, and digital-rectal examination (DRE) (60) (table 3.). In 87% of cases after the exam a diagnosis is established, and if a patient cannot have the exam further diagnostic tools and imaging are needed (60). DRE is needed for palpation of deep endometrioma nodules (4,55,60).

Clinicians palpate for uterine or adnexal tenderness, a retroverted fixture, uterosacral ligament nodules, and any pelvic masses, covering all the palpable sectors (41,60). A tenderness on palpation of the posterior fornix is the most common finding (41). Discovering abnormalities on a physical examination in the front, back, or side compartments shows believable specificity and favorable positive and negative predictive values for diagnosing endometriosis (61). Hudelist et al. discovered a connection between pelvic examinations focused on specific areas (such as the right or left ovary, cul-de-sac) and confirming endometriosis through pathology. Their findings showed sensitivity ranging from 23%-88% and specificity from 89%-100%, with accuracy values ranging between 86%- 99% in a cohort of 200 patients (68). Despite these good numbers, our physical examination percentage is about 50% accurate for posterior and deep infiltrative endometriosis, but when considered with history and other diagnostical tools, a diagnosis will be made with time posing as a sacrifice (68,69).

<ul style="list-style-type: none"> → General evaluation of well being Vital signs if sudden worsening Mental status and pain scale assessment BMI
<ul style="list-style-type: none"> → Inspection of vaginal mucosa Assessing for posterior vaginal fornix lesions
<ul style="list-style-type: none"> → Myofascial examination of superficial, deep, and low abdominal wall Evaluate tone, tenderness, allodynia or hyperalgesia
<ul style="list-style-type: none"> → Bimanual examination of each compartment for pain, stiffness and nodularity: Central: uterine position, mobility, size, texture Anterior: posterior cystic wall, vesico-uterine space Lateral: adnexa and pelvic lateral walls Postero-lateral: uterosacral ligaments, vagina Posterior: pouch of Douglas, anterior wall of rectum
<ul style="list-style-type: none"> → Digito-rectal examination (according to some guidelines is always obligatory) is obligatory if abnormal finding of posterior vaginal wall

table 3. Shows structured examination procedures while trying to establish a diagnosis of endometriosis. Modified and adjusted from Singh SS, Allaire C, Al-Nourhji O, Bougie O, Bridge-Cook P, Duigenan S, Kroft J, Lemyre M, Leonardi M, Leyland N, Maheux-Lacroix S, Wessels J, Wahl K, Yong PJ. Guideline No.449: Diagnosis and Impact of Endometriosis - A Canadian Guideline (61).

8.3 Blood biomarkers

Biological biomarkers, or simply biomarkers, are measurable indicators of some biological state or condition. They are often used in medical research and clinical practice to assess health, diagnose diseases, and monitor treatment responses (59). The topic of endometrial biomarkers is a controversial and well-discussed problem, marked by ongoing debates in the scientific community due to the complexity and variability of the biomarkers themselves and the challenges in achieving consistent sensitivity and specificity. Even though many studies have been done, there's still a lack of large, multicenter validation studies, which means the results are not very consistent between different studies. But right now, no biomarkers for endometriosis

have been approved by the U.S. Food and Drug Administration (FDA) (61). The question that many scientists are trying to answer is: “Is there significant clinical improvement by measuring biomarkers?” According to the guidelines of the Croatian Society for Endometriosis, there is no need for biomarkers as they hold no clinical value (60). Out of all the biomarkers studied, only four: anti-endometrial autoantibodies, interleukin-6 (IL-6), carbohydrate antigen-19.9, and carbohydrate antigen-125 (CA-125) had been researched enough to provide a evocative assessment of how accurate they are (69). Currently, among all the biomarkers examined, CA-125 emerges as the most hopeful and extensively researched. It's crucial to stress that CA-125 levels may rise in different gynecologic conditions like menstruation, pregnancy, and benign pelvic masses, as well as in gynecologic cancers (in which they are primary biomarkers and are used widely) such as ovarian, fallopian tube, or peritoneal cancers, and pelvic inflammatory disease. It can also increase in non-gynecologic situations like liver cirrhosis. Because of this, CA-125 alone isn't enough to definitively confirm, or definitively rule out endometriosis (61).

8.4 Radiological examination (US, MRI, CT)

Traditionally, investigative laparoscopy was regarded as the "gold standard" investigation for endometriosis. However, it is important to acknowledge the drawbacks that come with it, such as the associated costs, risks associated with general anesthesia, and the time required for postoperative recovery (70). Ultrasound (as a primary) and MRI (as a secondary) continue to be the new “gold standard” imaging methods for investigating endometriosis because it is affordable, has high sensitivity and specificity, and are readily available (Table 4.). When compared to surgery, imaging offers several advantages, including good accessibility, lower costs, faster results, and being non- or minimally invasive (70,71).

IMAGING	ADVANTAGE	DISADVANTAGE
Ultrasound (basic & advanced)	<ul style="list-style-type: none"> → Can detect endometrioma → Can assess non-endometrial pathologies → High tolerability → Low cost → Can detect adhesions → Allows anatomic mapping and staging for surgery 	<ul style="list-style-type: none"> → Difficult detection of superficial and deep endometriosis → Performance and interpretation are operator dependent
MRI	<ul style="list-style-type: none"> → Images appear same for everyone → Overall high accuracy in OE → Allows anatomic mapping and staging → Good tolerability → Allows anatomic mapping and staging for surgery → Can assess for non-endometrial pelvic pathology 	<ul style="list-style-type: none"> → Static assessment → Unable to detect superficial and deep endometriosis → High cost → Interpretation is operator dependent
CT	<ul style="list-style-type: none"> → Can detect causes of acute pain → CT-urography can help with urinary endometrial involvement 	<ul style="list-style-type: none"> → Radiation exposure → Limited detection in ovarian, SE and DIE

Table 4. Shows all the positive and negative values of radiological imaging modalities. The term advanced ultrasound refers to new ultrasound techniques. Modified and adjusted from Singh SS, Allaire C, Al-Nourhji O, Bougie O, Bridge-Cook P, Duigenan S, Kroft J, Lemyre M, Leonardi M, Leyland N, Maheux-Lacroix S, Wessels J, Wahl K, Yong PJ. Guideline No.449: Diagnosis and Impact of Endometriosis - A Canadian Guideline (61).

The role of ultrasound in endometriosis detection and diagnosis is the most effective and primary method, but it remains to have disadvantages. As with all diagnostic methods, the effectiveness of imaging for endometriosis relies on the skill of the operator. (61,72).

Transabdominal and transvaginal ultrasounds (TAUS, TVUS) enable the evaluation of the uterus, ovaries, and rectouterine pouch for fluid or masses, but are tricky when talking about deep pelvic

endometriosis and deep pelvic structure involvements. TVUS has a good specificity for discovering endometriosis lesions above 20mm and upon the procedure, there is a characteristic “ground glass” appearance for ovarian endometriosis (72). The sliding sign is a technique used to check for rectouterine obliteration, although it’s not always reported or evaluated consistently. This sign looks at how the rectum and uterus move against each other. If an experienced sonographer sees a positive sliding sign, it means the organs move freely. A negative sliding sign might indicate deep endometriosis, past surgical adhesions, or pelvic inflammatory disease (61). The ultrasonographic presence of endometriosis is an important subtopic of diagnostic discussion. When talking about the sonographic appearance of endometriosis we must account for the location, so we divided it accordingly. Three different pelvic compartments are recognized: anterior, middle, and posterior (62,70).

The anterior compartment includes structures such as the urinary bladder, distal ureters, vesicovaginal septum, vesico-uterine pouch, and round ligaments. Deep endometriosis (DE) affecting the urinary tract is most frequently found in the bladder, with incidences reaching up to 85-90% in cases involving urinary tract complications (figure 6.). This is shown by irregularities or nodules on the bladder wall, thickening of the bladder wall with decreased echogenicity, and abnormal hypo-echogenicity. Superficial endometriosis can be observed in the vesico-uterine pouch within the anterior compartment. Additionally, this superficial form of the disease may also affect the bladder's serosal layer without penetrating the muscular wall (70,73).

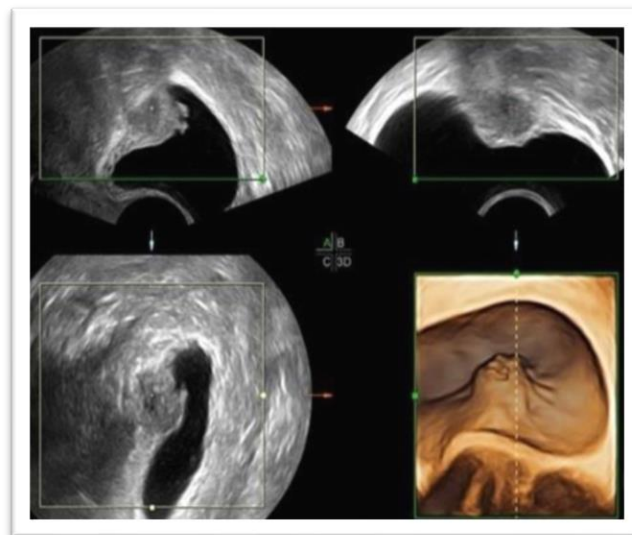


figure 6. TVUS pictures of the same bladder endometriosis (2D and 3D pictures). Modified and adjusted from Guerriero S, Ajossa S, Pagliuca M, Borzacchelli A, Deiala F, Springer S, et al. *Advances in imaging for assessing pelvic endometriosis* (77).

The middle compartment consists of the vagina, uterus, Fallopian tubes, and ovaries. For patients with vaginal endometriosis, the vaginal walls typically show decreased elasticity and potential thickening from endometriosis infiltration, causing tenderness during transvaginal examinations (70,74). If the uterus is anteverted or retroflexed, it may suggest late-stage anatomical distortion caused by deep endometriosis (DE), where the fundus is pulled backward. This observation should raise concerns, signaling the likely presence of advanced endometriosis (70). Abnormalities in the fallopian tubes are often observed in individuals with endometriosis. These abnormalities are typically present as hydrosalpinx or hematosalpinx. On sonography, this presents as cystic tubular structures exhibiting a 'cogwheel' appearance due to the presence of tubal folds (70,73).

Endometrioma remains a prevalent manifestation of endometriosis, observed in approximately 55% of patients (35). Additionally, it indicates the severity of the disease, as individuals with endometrioma are more likely to have deep endometriosis (DE) (70,75). A standard description of an endometrioma characterizes it as a single-chambered cyst displaying internal ground glass echogenicity, without any visible vascularity (figure 7.) (73,76). The presence of adherent ovaries, referred to as the 'kissing ovaries' sign, indicates the occurrence of pelvic adhesions and deep endometriosis. Endometriomas are mostly found in the middle compartment (70,76).

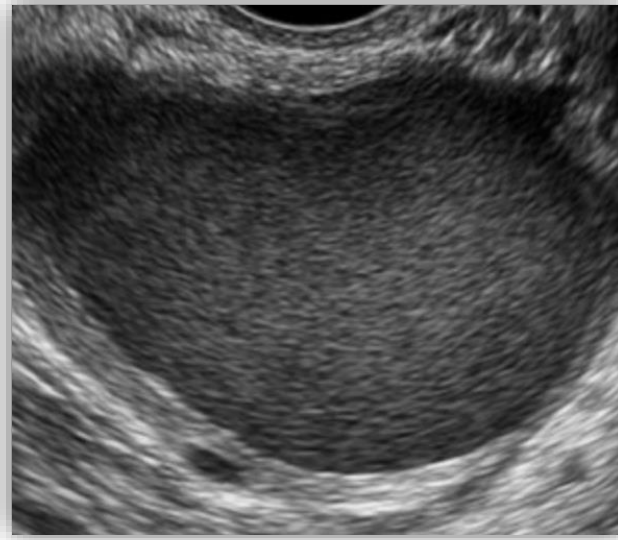

figure 7. TVUS image of endometrioma. Modified and adjusted from Orlov S, Jokubkiene L. Prevalence of endometriosis and adenomyosis at Transvaginal Ultrasound examination in symptomatic women (77).

The posterior compartment encompasses several structures, including the pouch of Douglas, torus uterinus, rectovaginal septum, uterosacral ligaments, and rectosigmoid colon. Superficial endometriosis (SE) consists of lesions found on the surface of the pelvic peritoneum and organs, lacking deeper involvement (70,77). Typically, this condition is diagnosed during laparoscopy, as it was previously challenging to visualize using ultrasound. However, advancements in ultrasound technology now allow for the visualization of superficial endometriosis (SE) on the uterosacral ligaments and pouch of Douglas. These lesions usually present as irregular hypoechoic nodules without associated vascularity, typically measuring less than 5 mm in depth (70,78). Deep endometriosis (DE) often manifests as solid nodules or thickening of the visceral walls, appearing hypo/isoechoic on imaging. These nodules are frequently found in the torus uterinus, uterosacral ligaments, pouch of Douglas, and rectosigmoid colon (70,79). Uterosacral ligaments are the most common location for deep infiltrating endometriosis (80). Involvement of the uterosacral ligaments is indicated by the presence of hypoechoic nodules or linear thickening located behind the upper vagina or within the surrounding fat of the ligaments (70,81). Deep endometriosis affecting the rectovaginal septum is indicated by the appearance of a hypoechoic nodule located between the rectum and the posterior

vaginal wall, typically positioned between the introitus and the external axis (figure 8.) (70,76). Deep endometriosis involving the intestines is observed in about 8-12% of endometriosis cases, with nearly 93% of these cases affecting the rectum or rectosigmoid colon. Typical signs are “comet tail” (hypoechoic lesions with a thinner tail at one end) and “moose antler sign” (abnormal tissue with irregular retraction and adhesions appearing like spikes) (78).

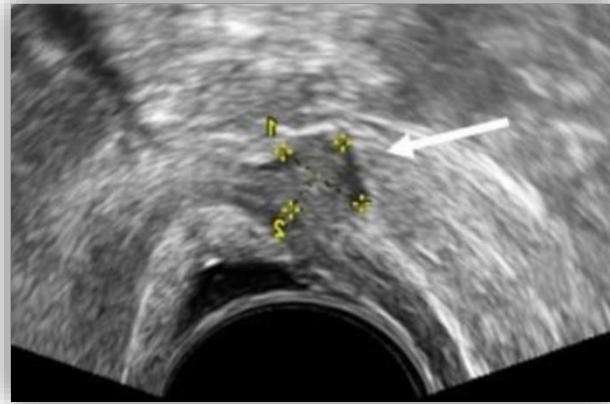


figure 8. TVUS image of rectouterine involvement of endometriosis. Modified and adjusted from Guerriero S, Ajossa S, Pagliuca M, Borzacchelli A, Deiala F, Springer S, et al. *Advances in imaging for assessing pelvic endometriosis* (77).

MRI & CT are not often used alone to diagnose endometriosis but are good diagnostic tools for localizing, measuring, describing, and staging disease severity. MR can, with good precision, diagnose soft tissue lesions associated with DIE. They are often used as a part of pre-surgical planning and allow doctors to statically visualize lesions (61).

8.5 Role of investigative Laparoscopy and patho-histology

For a long time, surgery has been considered the gold standard for diagnosing endometriosis. However, there is a need to update this historical perspective to better reflect our current understanding of how the disease presents. A comprehensive evaluation involving patient history, physical examination, advanced imaging, and patient preferences usually results in a

surgical strategy. This strategy helps guide an operative laparoscopy aimed at both diagnosing and treating the disease during a single procedure. However, a practical implementation of this is obscure in other countries because of a lack of advanced ultrasound knowledge and access (61). Investigative laparoscopy is typically conducted shortly after menstruation, and if repeated, it is coordinated with the menstrual cycle. Using laparoscopy solely for diagnostic purposes should no longer be the primary method of investigation. The concept of image-guided surgical exploration acknowledges that specific types of deep-seated disease may go unnoticed during routine laparoscopy, particularly when there is no peritoneal or ovarian endometriosis present (61,81). A common scenario of this involves deep endometriosis in the lower rectum, resulting in the obliteration of the cul-de-sac. Compared to relying solely on diagnostic laparoscopy, preoperative ultrasound guided by experts may offer better detection of deep rectosigmoid endometriosis (81). Visualization enables the detection of a variety of lesions, including unpigmented, red, black-blue, brown, yellow, and white, as well as atypical ones in the form of spots, polyps, cysts, fibrosis, adhesions, pockets, and hypervascularization (81,82).

Pathology remains the definitive method for diagnosing endometriosis. During surgery, it is recommended to collect histologic samples from the affected peritoneum, deep nodules, and/or endometriomas to confirm visual observations (83). Accurate evaluation can be compromised if specimens are extensively damaged by surgical energy devices or if the sampling is incomplete. As we discussed in the patho-histology section, pathological diagnosis can be made upon the presence of at least 2 of the following 3 features: endometrial-type glands, endometrial stroma, and foamy or hemosiderin-laden macrophages (4,61). However, diagnosing endometriosis through histology can be challenging in larger cystic lesions. In these cases, the glandular component may become denuded, and the endometrial stroma in well-established lesions may become thinned or replaced by fibrosis or elastosis (61,83).

9. CLASSIFICATION AND TYPES OF ENDOMETRIOSIS

Endometriosis comes in several types: ovarian endometriosis (appearing as either superficial lesions or cysts), peritoneal endometriosis with various presentations, deep infiltrating endometriosis (DIE), and endometriosis in other locations. Peritoneal endometriosis, ovarian

cysts (chocolate cysts), and nodules of deeply infiltrating endometriosis are the most common types. (2,83).

Diagnosing and categorization of endometriosis is complex due to the variability in lesion location, extent, and symptom presentation. Various classification systems have been developed, each with different uses and relevance for specialists and patients. A unified classification system would standardize the staging of endometriosis, streamline treatment approaches, and enhance prognostic tools for evaluating pregnancy rates in patients aiming to preserve or regain fertility after treatment. Until a universal system is established, using a combination of the four most common scoring systems is advised to best represent the disease's morphological presentation. American Society for Reproductive Medicine (rASRM), endometriosis fertility index (EFI), and more recently, ENZIAN, American Association of Gynecologic Laparoscopists (AAGL) endometriosis staging (81,83).

9.1. Revised American Society for Reproductive Medicine (rASRM)

The revised American Society for Reproductive Medicine scoring system categorizes endometriosis into four stages based on the severity, size, depth, location, and quantity of lesions. Stage I, indicating minimal disease, scores 1–5 points; Stage II, indicating mild disease, scores 6–15 points; Stage III, indicating moderate disease, scores 16–40 points; and Stage IV, indicating severe disease, scores more than 40 points. Large ovarian endometriotic lesions greater than 3 cm are assigned 20 points, while dense adhesions on the ovaries and fallopian tubes receive 16 points. A complete obliteration of the posterior cul-de-sac is immediately classified as severe, with a score of 40 points. Although the initial scoring system was introduced in 1979 and revised in 1985 and 1997 to address the poor correlation between disease stage and pain severity, this issue remains largely unresolved (figure 9.) (84,85).

9.2. The ENZIAN

ENZIAN score was introduced in Austria back in 2005 as an attempt to address the limitations of the rASRM system. Unlike rASRM, ENZIAN focuses more on deep infiltrating endometriosis. Instead of giving incremental scores, ENZIAN provides descriptions of where the deep lesions are located. It assigns values based on which organ compartment is involved, using

capital letters like P, O, T, A, B, C, and F, and rates the extent of endometriosis as 1, 2, or 3. If organs come in pairs, each side gets a suffix, and if the ovaries or tubes can't be seen, they're marked with "m" or "x". Studies have shown that ENZIAN is quite accurate, with a low false positive rate of 4%, and it's very useful for planning surgeries (84,86). However, how accurate ENZIAN is depends on how well it's used. Only when both imaging and comprehensive surgery are done together that the score it gives can be trusted for deciding on the next steps of treatment and discussing outcomes with patients (84,87).

9.3. The Endometriosis Fertility Index (EFI)


EFI was developed in 2010 as a tool to assess the likelihood of pregnancy in patients diagnosed with endometriosis through surgery, who are trying to conceive without the use of in vitro fertilization (IVF) (84,88). The Endometriosis Fertility Index (EFI) is calculated post-surgical assessment. It rates reproductive organ function from 0 (no function) to 4 (optimal function) for each structure like fimbria, fallopian tubes, and ovaries on both sides. The least function score (LF) is determined by the lowest score on each side or doubled if one ovary is missing. This LF contributes to the surgical EFI factor score, combined with the historical factor score to give the final EFI score. It ranges from 0 to 10, indicating the poorest (0) to the most favorable (10) projected pregnancy outcome (88).

9.4. American Association of Gynecological Laparoscopists (AAGL)

In 2021, the American Association of Gynecological Laparoscopists (AAGL) introduced a new staging system for endometriosis, which is based on anatomy. This new system outperforms the rASRM system in evaluating the complexity of surgical procedures. The scores in this system were adjusted and normalized to offer an average measure of surgical complexity at different sites (84). Unlike the ASRM system, AAGL divides endometriosis into four stages but is notably more accurate in predicting the complexity of surgeries. Additionally, there's a stronger link between the AAGL stage of endometriosis and symptoms such as dysmenorrhea, dyspareunia, and overall pain experienced by individual patients. This scoring system enables a dependable assessment of patients before surgery, leading to more informed discussions about prognosis and better anticipation of potential postoperative risks (84,89).

The matter of standardization is a prominent one, although each of the four classification systems outlined here has its own merits, their effectiveness for both specialists and patients

varies inconsistently (83,84,90). The rASRM scale is frequently used because it's easy to understand. However, it doesn't give much detail about symptoms or how complicated surgery might be. The AAGL scoring system explains these aspects better (84).



AMERICAN SOCIETY FOR REPRODUCTIVE MEDICINE
REVISED CLASSIFICATION OF ENDOMETRIOSIS

Patient's Name _____ Date _____
 Stage I (Minimal) - 1-5 Laparoscopy _____ Laparotomy _____ Photography _____
 Stage II (Mild) - 6-15 Recommended Treatment _____
 Stage III (Moderate) - 16-40
 Stage IV (Severe) - >40
 Total _____ Prognosis _____

PERITONEUM	ENDOMETRIOSIS			
	< 1cm	1-3cm	> 3cm	
PERITONEUM	Superficial	1	2	4
	Deep	2	4	6
OVARY	R Superficial	1	2	4
	Deep	4	16	20
	L Superficial	1	2	4
	Deep	4	16	20
POSTERIOR CULDESAC OBLITERATION	Partial	Complete		
		4	40	
OVARY	ADHESIONS			
	< 1/3 Enclosure	1/3-2/3 Enclosure	> 2/3 Enclosure	
	R Filmy	1	2	4
	Dense	4	8	16
	L Filmy	1	2	4
	Dense	4	8	16
TUBE	R Filmy	1	2	4
	Dense	4*	8*	16
	L Filmy	1	2	4
	Dense	4*	8*	16

*If the fimbriated end of the fallopian tube is completely enclosed, change the point assignment to 16.

figure 9. ASRM classification. Modified and adjusted form Revised American Society for Reproductive Medicine classification of endometriosis: 1996 American Society for Reproductive Medicine (85).

10. MANAGEMENT AND THERAPY

Endometriosis is challenging to treat due to its chronic nature and the complexity of its symptoms, which often vary greatly among individuals. In previous paragraphs we noted that endometriosis is a chronic disease with different appearances and classifications, we also mentioned that the only truly accurate confirmation is PHD-laparoscopy (4,91). This makes this disease difficult to manage as most of the patients are diagnosed late. The primary reason for initiating treatment for endometriosis is the presence of symptoms related to endometrial lesions. These symptoms include pain of varying intensity and location, as well as fertility challenges (2). Because endometriosis leads to intense pain and a high chance of infertility, most treatments

focus on reducing symptoms like painful periods and painful coitus, while also trying to improve fertility and the chances of getting pregnant (91). Pharmacological, surgical, and combination treatments are used to treat endometriosis, with emphasis on combined therapy, as it is mostly used (2,92). Yet, as per international guidelines, the choice of whether and when to elect for surgery is usually influenced by the patient's preferences, the seriousness of the condition, and their fertility objectives (60,91). In recent times, there has been an increasing trend towards empirical pharmacological treatment, particularly for patients who are not good candidates for surgery. Empirical therapy has been shown to prevent disease progression and postpone the need for invasive procedures (92). The primary approach in current medical treatments for endometriosis involves addressing both the disease and its symptoms by either plummeting estrogen levels locally or throughout the body, or by directly impacting the hormonal activity of endometriosis lesions. While all existing hormonal therapies seem to have similar effectiveness, their tolerability profiles differ (93,94). The primary (1st line treatment) long-term treatments commonly utilized are progestins and combined oral contraceptives (COCs). However, these therapies may result in irregular bleeding patterns, breast tenderness, and mood disturbances for some women (93,95). Secondary (2nd line treatment) hormonal therapies include GnRH agonists, which prompt a state of lowered estrogen levels resembling menopause, causing symptoms like hot flashes and potential reduction in bone mineral density. Consequently, they are generally reserved for short-term applications (93,96). Surgical procedures involve the excision or removal of endometrial implants, the ablation of uterosacral nerves using methods such as endo-coagulation, electrocautery, or laser treatment, presacral neurectomy, and hysterectomy with bilateral salpingo-oophorectomy, which have a good and similar result as pharmacologic therapy (41). To this day modern medicine recognizes three different therapeutic modalities:

- Pharmacologic- (NSAID, Combined oral contraceptives, Progestins, GnRH agonists, GnRH antagonists, Aromatase inhibitors, SERMs, SPRMs)
- Surgical- (laparoscopy or laparotomy, rhizotomy, hysterectomy)
- Combined- (pharmacologic + surgical)

10.1 Pharmacologic therapy

Pharmacologic therapy also called hormonal therapy is divided into a) symptomatic and b) hormonal aims to decrease the symptoms, esp. pain, and to suppress lesion growth (17).

a) Symptomatic therapy (NSAIDs)

Symptomatic therapy also referred to as pain management, is the universal first choice of drug that will be given to a patient experiencing pain associated with endometriosis and commonly involves the use of nonsteroidal anti-inflammatory drugs (NSAIDs) (97). NSAIDs influence symptoms of dysmenorrhea, dyspareunia, and chronic pelvic pain by inhibiting COX-1 and COX-2. This is due to their minimal side effects, coupled with the fact that many NSAIDs are accessible without a prescription (97,98). There is abundant evidence that NSAIDs cause a decrease in prostaglandins and other COX products associated with the pain pathway, indicating that prostaglandins play a significant role in pain onset (98). NSAIDs will not help in non-menstrual (hormonal) problems of endometriosis. Long-term usage of NSAIDs can have side effects which are gastrointestinal issues such as stomach pain, indigestion, and ulcers, as well as potential kidney problems, fluid retention, and increased blood pressure. NSAIDs can be used alone or as a combined management plan with other medications (60). There were no studies suggesting that one NSAID is better than another. NSAID benefit comes if pains are tolerable and mild and as their mechanism of action isn't directed at ovulation, they have no contraceptive properties (98).

b) Hormonal therapy

Hormonal therapy is a type of pharmaceutical therapy that acts on hormonal imbalances in endometriosis patients. The recommendation and guidelines reference prescribing hormonal treatment—combined OCs, progestagens, anti-progestogens, or GnRH agonists.

Endometriosis is categorized as an estrogen-dependent disorder, where increased estrogen receptor (ER) activity plays a crucial role in stimulating cell proliferation and advancing the disease (99). Compared to women without the condition, endometriotic lesions exhibit elevated estradiol production and reduced estradiol deactivation (99,100). Medications targeting estrogen secretion or estrogen receptor (ER) activity include GnRH analogs, while GnRH antagonists, aromatase inhibitors, and selective estrogen receptor modulators (SERMs) are currently in various stages of development as potential therapies (99). Apart from its reliance on estrogen, numerous pieces of evidence indicate a pattern of progesterone resistance in the development of endometriosis. Endometriotic lesions generally demonstrate a decrease in

progesterone receptor expression compared to healthy endometrial tissue, and they often lack expression of progesterone receptor B. Research showed us that in endometriosis patients, the transcripts for both PR-A and PR-B are disrupted in normal endometrial tissue, while only the PR-A transcript expressed is found in endometriotic implants (99,100,101). The currently available drugs, that influence progesterone secretion and/or progesterone receptor (PR) activity, consist of progestins (given orally, intravaginally, intrauterine, or subcutaneously) along with selective progesterone receptor modulators (99,102).

10.1.1 Progestins

Progestins are widely used drugs and have been used for over 30 years. They act as an antiestrogenic effect leading to decidualization and endometrial atrophy (98). The progestin mechanism of action is interfering with pulsatile GnRH secretion from the hypothalamus, and consequently lowering LH and FSH secreted by hypophysis. By lowering LH and FSH it leads to a state of hypoestrogenism. Hypoestrogenism then leads to inhibition of estrogenic receptors and consequent decidualization and endometrial atrophy. One big component of this is metalloproteinase inhibition, which is considered a major enzyme crucial for ectopic endometrial implantation and growth (98,99).

Medroxyprogesterone acetate (MPA), Dienogest, and Norethisterone acetate are the main drugs from this family, and they are used for the treatment of endometriosis (98). Oral medroxyprogesterone acetate (MPA) is used for the long-term treatment of endometriosis and is as effective as GnRH analogs in reducing pain and enhancing health-related quality of life. However, the optimal dosage of MPA has not yet been understood as MPA needs higher doses meaning more frequent side effects. Common side effects include localized pain, acne, and vasodilation. The depot formulation of MPA (DMPA) is primarily used for contraception and is widely utilized by women globally. It is typically administered as a single 150 mg intramuscular injection every three months. This drug is not recommended for patients trying to conceive, as it prolongs menstrual cycles (99).

Dienogest (DNG) belongs to the norethindrone family of testosterone derivatives, but it is distinguished from norethisterone acetate by the addition of a cyanomethyl group. This cyanomethyl group gives DNG its strong antiandrogenic effect. DNG has a weaker antiestrogenic effect and this leads to weak symptoms of low estrogen (99).

Dienogest (2 mg) per day leads to anovulation and moderately reduces estrogen production. It also decreases levels of various factors, including prostaglandin E2 (PGE2), inflammatory cytokines like interleukin (IL)-6, IL-8, and estrogen synthetase aromatase (103). Additionally, DNG downregulates angiogenesis factors such as vascular endothelial growth factor (VEGF) and nerve growth factor (NGF) in both endometrial and endometriotic cells. This means that DNG has anti-inflammatory, antiangiogenic, and antiproliferative effects (99,103,104). It is considered that DNG has the strongest effect on eutrophic and ectopic endometrium because of that it has good results in treating pelvic pain, dysmenorrhea, and dyspareunia at an optimal dosage of 2mg/day (103). DNG also showed good results in long term therapy and patients wanting pregnancy (99). Alternative use of progestins is intrauterine device loaded with levonorgestrel. It is a 19-nortestosteron gel which acts upon endometrium by atrophy and inactivation. It shows good results in treating endometrial symptoms and a good long-term solution for patients wanting to get pregnant. It offers almost 5-year-old solutions for as a contraceptive and long term endometriosis therapy. Another alternative therapy is transdermal patch of etonogestrel showing promising results for deep endometriosis (103,104).

Progestogens can cause a range of side effects that vary depending on the specific medication and the individual. Common side effects include irregular bleeding or spotting, weight gain, and breast tenderness. Many users also experience mood changes or depression, headaches, and nausea. Other possible side effects are acne, fluid retention, decreased libido, fatigue, and abdominal pain or discomfort. The severity and combination of these side effects can differ among individuals. Progestagens are utilized empirically to treat chronic pelvic pain, diagnosed endometriosis, and recurring pain in patients (99,103,104).

10.1.2 Combined oral contraceptives

COCs are a combination of estrogenic and progestogenic components which are taken perorally. Most often it is a low dosage combination of 15-30 µg ethinyl estradiol or 2 mg estradiol valerate, combined with drospirenon, gestoden, and Dienogest (104,105). Low doses of hormones suppress the release of GnRH from the hypothalamus, as well as the mid-cycle surge of FSH and LH. Subsequently, ovulation is inhibited, leading to a hypoestrogenic state characterized reduction in menstrual flow, decidualization of endometriotic implants, and decreased cell proliferation of both ectopic and eutopic endometrial tissue. Ovarian function is

suppressed, along with the metabolism of arachidonic acid into prostaglandins. This effectively reduces pelvic pain and menstrual cramps (105). Monophasic oral contraceptives offer the option of continuous or cyclic usage. In the cyclic schedule, oral contraception is taken for 21 consecutive days, followed by a 7-day pause to facilitate endometrial shedding and pseudo menstruation (104,105). Monophasic oral contraceptives are extensively employed due to their excellent tolerability and reduced adverse effects. They are suitable for adolescents and women who are not intending pregnancy because of their contraceptive efficacy. COCs are indicated in patients with chronic pelvic pain, diagnosed endometriosis, and patients with chronic menstrual pain. Even with the low doses of combined oral contraceptives (COCs) 20 to 30 µg, which are equivalent to 4 to 6 times the natural estrogen dose and considering the changes in estrogen receptors (ER) and progesterone receptors (PR) in endometriosis, administering COCs may result in estrogen dominance in the presence of progesterone resistance (105,106). Possible side effects may include irregular bleeding, breast tenderness, nausea, headaches, mood swings, nausea, sweating etc. Combined oral contraceptives are contraindicated in certain circumstances where their use could pose significant risks to health. Absolute contraindications include a history of blood clots or certain clotting disorders, previous heart attack or stroke, severe liver disease, specific types of migraines with aura, known or suspected breast cancer or other estrogen-sensitive cancers, uncontrolled high blood pressure, smoking in individuals over 35 years old, pregnancy, breastfeeding, and known allergy to any component of the contraceptive (104,105,106).

10.1.3 GnRH agonists

Since the 1990s, labeled drugs like goserelin, leuprolide, nafarelin, buserelin, and triptorelin, known as gonadotropin-releasing hormone agonists (GnRH-a), have been utilized to manage endometriosis (103). These medications work by binding to GnRH receptors, initially triggering the pituitary gland to release luteinizing hormone (LH) and follicle-stimulating hormone (FSH) within the first 10 days of treatment. As a result, continuous and prolonged exposure to these agents triggers the downregulation of GnRH receptors, leading to decreased levels of LH and FSH and the suppression of estrogen production in the ovaries (105). Because of the extremely low estrogen levels, there is endometrial atrophy, regression, and resorption, leading to a state akin to pseudo-menopause caused by GnRH analogs (105,107). Due to their

cost, limited accessibility, and side effects, GnRH agonists are utilized as secondary treatment options for pelvic pain linked to endometriosis (106). Treatment with GnRH agonists is linked to notable hypoestrogenic side effects, such as amenorrhea, vasomotor symptoms, sleep disturbances, urogenital atrophy, and accelerated bone loss. Hence, it is not advised to use GnRH agonists for more than 6 months (105,107). It is mandatory to include the so-called "add-back therapy," which involves either progesterone monotherapy or a combination of estrogen and progesterone (105).

The use of GnRH analogs is recommended for cases of confirmed endometriosis that do not respond to initial treatment. This treatment is considered beneficial preparation for surgery or IVF procedures and is commonly employed as a secondary preventive measure following surgical intervention (105,106). Recent research has revealed that combining progestins and estrogens as additional therapy outperforms using progestin alone, especially in preserving bone mineral density and maintaining normal body weight (105,108).

10.1.4 GnRH antagonists

Gonadotropin-releasing hormone antagonists work by attaching to the pituitary GnRH receptor, just like GnRH analogs. This results in an immediate decrease in gonadotropins and the production and release of gonadal steroids (99). In contrast to GnRH agonists, antagonists do not induce the initial flare-up phase and lead to a swift onset of the therapeutic effect (105). They are administered per orally (99,104).

Elagolix, a short-acting GnRH antagonist, has recently been approved in the USA for managing moderate to severe pain associated with endometriosis. In contrast to traditional GnRH agonists, elagolix suppresses LH and FSH levels dose-dependently by blocking endogenous GnRH signaling. This leads to a modulation of estradiol levels, providing relief from endometriosis-related pain while avoiding the occurrence of severe hypoestrogenism (103,105). Elagolix is indicated as a 2nd line treatment if 1st line fails and as a post-operative measure. Because of their comparable mode of action to GnRH analogs, these drugs also trigger side effects resembling menopause. Hot flashes, headaches, vaginal dryness, and notably, decreased bone density, can be mitigated by incorporating additional add-back therapy (99,105). Relugolix and linzagolix are two recently developed oral GnRH antagonists undergoing advanced clinical trials for the treatment of pain related to endometriosis and showing good promise (104).

10.1.5 Aromatase inhibitors

Aromatase inhibitors (AIs) disrupt the process of converting androgens to estrogens by inhibiting aromatase activity (testosterone and androstenedione to estradiol and estrone). They also reduce estrogen production in endometriotic tissue both locally and in the ovaries. This, in turn, causes endometrial tissue atrophy and a decrease in lesions (99,106). The third-generation aromatase inhibitors (anastrozole, letrozole, exemestane, and vorozole) exhibit greater potency and specificity towards the aromatase enzyme (100). Although this class of drugs is not approved by the FDA (Food and Drug Administration), prospective and randomized studies suggest that when combined with estrogens, progestins, and GnRH agonists, they effectively reduce pain and the size of rectal nodules and endometriomas (99,109).

They are indicated as a 2nd line therapy and management of pain symptoms in endometriosis, post and preoperatively. Aromatase inhibitors can lead to various side effects, including hot flashes, joint and muscle pain, osteoporosis, vaginal dryness, fatigue, mood changes, headaches, nausea, and elevated cholesterol levels. Postmenopausal women may face an increased risk of cardiovascular events while taking these medications. Because of these severe side effects, the ESHRE guidelines recommend therapy in conjunction with COCs, progestins, or GnRH agonists for patients experiencing drug-resistant pain and recto-vaginal endometriosis resistant to surgery. An important note is that AI's can cause ovarian cysts (99,100,105).

10.1.6 Danazole

The synthetic androgen 2,3-isoxazole, derived from 17 ethynyl testosterone, has mild androgenic effects but strong antiestrogenic properties (99). It works by inhibiting gonadotropin release, competing with steroidogenic enzymes, affecting immune function, and reducing cell proliferation. In clinical studies, it has shown effectiveness in alleviating symptoms of pain related to endometriosis (99). Danazol is efficient in managing pain associated with endometriosis, and its effectiveness seems to persist even after treatment is stopped. However, its usage is restricted due to androgenic adverse effects such as seborrhea, hypertrichosis, weight gain, reduction in HDL levels, and increase in LDL levels. Danazol also has a direct effect on the

endometrium, leading to atrophy and regression of endometrial lesions (105). Danazol is notably effective in managing dysmenorrhea owing to its pseudo-menopausal impact and can be employed for addressing recurrent pain post-surgical treatment, and today is used as a 3rd line therapy. ESHRE and SOGC emphasize the importance of considering the side effects associated with Danazol (106). WES recommends its use solely in women who have previously undergone well-tolerated treatment with Danazol (106).

10.1.7 Selective progesterone receptor modulators (SPRMs)

Selective progesterone receptor modulators (SPRMs) interact with progesterone receptors to block or modify downstream effects (99,106). They hold promise for greater efficacy and versatility compared to conventional treatments for endometriosis for several reasons. Firstly, they selectively inhibit endometrial proliferation without inducing systemic effects of estrogen deprivation. Secondly, they can reversibly suppress endometrial bleeding by directly affecting endometrial blood vessels. Lastly, SPRMs have the potential to specifically decrease endometrial prostaglandin production in a tissue-specific manner (99). SPRMs are ligands for progesterone receptors that function selectively as agonists, antagonists, or partial agonists/antagonists on various progesterone target tissues and therefore have been extensively researched (105). Mifepristone, asoprisnil, ulipristal acetate, lonaprisan and telapristone acetate are some of the SPRMs. SPRMs are usually well tolerated. Common side effects include headaches, abdominal pain, nausea, dizziness, and heavy menstrual bleeding (99). Mifepreston is the most widely researched and shows good promise with endometriosis symptoms (107).

10.1.8 Selective estrogen receptor modulators (SERMs)

The tissue-selective activity of selective estrogen receptor modulators (SERMs) enables some molecules to primarily act as antagonists in the breast and uterus, while functioning as agonists in the skeleton. For instance, raloxifene has been approved for treating postmenopausal osteoporosis (99). SERMs bind to estrogen receptors (ER- α and ER- β) in target cells, acting as agonists in some tissues and antagonists in others. Because of this selective action, they have been proposed for treating endometriosis and are currently being investigated. Bazedoxifene (BZA) is a new SERM used to treat osteoporosis and counteracts estrogen-induced stimulation

of the uterine endometrium. BZA is under investigation for its usefulness in endometriosis treatment (110).

10.2 Surgical therapy

Surgical treatment aims to reduce endometriosis-related symptoms, enhance quality of life, and improve or maintain fertility in infertile patients (61). Surgical treatment remains the ultimate option for patients who do not respond to medication, experience no symptom improvement, or have extensive symptoms and pain. The selection of the appropriate surgical treatment depends on the patient's age, desire to maintain future fertility, severity of symptoms, type of endometriosis, QoL, and the location of the lesions (2). Most patients are women within a reproductive age and desire for future pregnancy, as doctors we are commanded to respect their wishes and try with conservative surgery. Patients who are not within reproductive age, have severe dyspareunia/dysmenorrhea without response to previous medical therapy, or do not wish to get pregnant are subjected to radical surgery (110).

When talking about surgical methods we are dividing them into 2 general categories called laparoscopy and laparotomy. Laparoscopy is the gold standard for the surgical treatment of endometriosis (61). All the clinical guidelines recommend laparoscopic surgery over laparotomy for treating chronic pain and infertility caused by endometriosis. This preference is due to reduced pain, shorter hospital stays, quicker recovery times, and better cosmetic outcomes associated with laparoscopy (111,112). Some guidelines don't (ESHRE, CNGOF) recommend preoperative hormonal therapy and other guidelines do (NICE and SOGC), as a preventative measure. For surgical categorization, the best option is the ENZIAN classification score (111). The ENZIAN classification system has been demonstrated to be sufficiently precise and is rooted for describing the localization of lesions, making it highly reliable for surgical planning (84,86). Laparoscopic surgery aims to alleviate pain, infertility, and other endometriosis symptoms by restoring normal anatomy through lesion removal, adhesiolysis, and organ repair (110). However, while it can restore anatomy, it may not fully reverse the underlying inflammatory and biomolecular changes linked to persistent pain and infertility, such as progesterone resistance and altered cell activity (110). As we noted in a previous discussion if lesions are present at diagnostic laparoscopy, guidelines recommend removing them. In this way, diagnostic

laparoscopy serves a dual function. Laparoscopy uses surgical techniques called excision and ablation as a method of removal of lesions (112).

Additional surgical treatment options include addressing pain through procedures like presacral neurectomy (PSN) and laparoscopic uterosacral nerve ablation (LUNA), along with definitive radical interventions like hysterectomy and oophorectomy (112,113).

Surgical procedures have their advantages, but there are some disadvantages like surrounding tissue damage, ovarian damage (special concern is with IVF patients), and residual tissue (112,113).

10.2.1 Surgical treatment of Ovarian endometriomas

As mentioned earlier, ovarian endometriomas are found in 2–10% of women in their childbearing years and 50% of women undergoing infertility treatment. OE is the most common form of endometriosis (39). Surgery for endometriomas is recommended, particularly for pain and infertility, if the endometrioma measures 4 cm or larger. Surgery for endometriomas measuring up to 3 cm is not recommended. In such cases, if the patient does not meet the criteria for primary infertility treatment, hormonal therapy should be recommended, with regular patient monitoring every 4-6 months (112). In infertile patients with minimal endometriomas (up to 3 cm), ART may be recommended as an option, or surgery may be considered (while ensuring the exclusion of male infertility) (60).

During preoperative planning for endometrioma removal, it's crucial to evaluate the extent, size, and location of the endometriomas. Additionally, ruling out hydronephrosis and asymptomatic hydronephrosis is essential, as ovaries with endometriotic cysts typically adhere to the ovarian fossa, which may lead to ureteral obstruction (111,112). As a part of preoperative communication, you need to explain to the patients what risk factors are possible. The risk factors associated with surgery for endometriosis of the ovary include potential complications such as infection, severe bleeding (emphasis on ovarian artery), injury to surrounding organs or structures (ovarian reserves), development of adhesions, and the possibility of recurrence of endometriosis lesions. Additionally, there are general risks related to surgery, such as anesthesia complications and postoperative pain (113).

Laparoscopic removal is the standard approach for ovarian endometriomas, offering three treatment options: surgical excision (cystectomy), CO2 laser ablation, and electrocoagulation

(110). According to Muzii and Miller it's not just the act of surgery itself but rather the quality of the surgery that matters. They emphasize that while surgery is considered the gold standard treatment for ovarian endometriomas, it should be carried out with precision and expertise by a surgeon who is specifically trained in the appropriate techniques (114,115).

Cystectomy is the preferred method of OE treatment and offers the best outcome to surrounding tissues. In summary, the cystectomy steps are as follows: visualize the targeted ovary and identify adhesions then drain; after draining the cyst, an incision is made to locate the cleavage plane without damaging nearby blood vessels. Saline or diluted synthetic vasopressin aids in identifying the plane, while gentle traction separates the cyst capsule from the ovarian tissue carefully so as not to damage ovarian reserves and the ovarian artery nearby. After removing the lesions, samples are sent to a histologist, and the rest is placed in an endoscopic bag. Spot bipolar coagulation ensures hemostasis once needed. Monofilament sutures may be required for larger cysts, while smaller ones may not need sutures for closure (110,111). Whenever possible, stripping and completely removing the cysts are regarded as the optimal choices due to their lower recurrence rates and improved pregnancy rates, especially in cases of infertility. However, this process demands expertise and precision (114).

Laser beam ablation is another surgical method that utilizes the laser beam to ablate the complete inner surface of the cyst wall. Adjusting the power between 30–55 W for the CO₂ laser beam and 6–10 W for the CO₂ fiber. The objective is to vaporize the endometriotic cyst lining until the hemosiderin pigment-stained tissue is no longer visible, transitioning from reddish to yellow-white. Complete vaporization of the entire depth of the cyst capsule isn't required as the endometriotic tissue is only superficial. Make sure to vaporize the border of the cyst opening thoroughly (111,112).

Plasma ablation is another possibility of treatment and it's done by plasma. Use plasma energy in coagulation mode, set between 10 to 40, with the handpiece positioned approximately 5 mm from the surface, to ablate the entire inner surface of the cyst wall. The goal is to vaporize the endometriotic cyst lining until the hemosiderin pigment-stained tissue is no longer visible, indicating a color change from reddish to white-xanthous. Ensure thorough treatment of all areas, including ablation of the edges of the invagination site (111,112).

As we discussed earlier, the most favorable technique is cystectomy. Guidelines tell us that cystectomy is recommended over drainage and coagulation due to lower recurrence rates

post-cystectomy, leading to significant symptom improvement (61). A combination of excision and ablation techniques can be employed to minimize excessive bleeding and reduce the risk of removing or damaging ovarian tissue near the ovarian hilum, especially in cases involving larger endometriomas (110,111).

10.2.2 Surgical treatment of peritoneal endometriosis

As we discussed previously, PE is one of the most common presentations of this disease and often comes with OE or DIE. Peritoneal endometriosis (CNGOF, NICE, WES, ACOG, and ASRM) recommendations concur that women with suspected mild endometriosis and infertility should be evaluated as potential candidates for surgical intervention (113). Treatment options are the same as for OE, with excision as the best method. In cases of infertility, surgery targeting superficial peritoneal endometriosis or endometriomas may enhance the likelihood of natural conception. However, this approach needs to be weighed against alternative options such as assisted reproductive technologies (115).

10.2.3 Surgical treatment of Deep pelvic endometriosis

Histological analysis revealed active glandular and stromal tissue, marked by the presence of mitoses and glycogen accumulation, extending 5 mm beneath the peritoneal surface. Other definitions of deep endometriosis (DE) are based on the disease's location, including involvement of the bowel, bladder, ureter, vagina, parametrium (cardinal ligament), and diaphragm (115,116). DE is considered a difficult type of endometriosis as it often involves multiple surrounding tissues and structures, considering this it is best to refer the patient to a specialist hospital for DE, where they have a multidisciplinary team (60). Deep endometriosis (DE) typically involves the uterosacral ligament, vagina, rectovaginal septum, ureter, bladder, and intestines, and rarely diaphragm (116). DE is a surgical challenge. Therefore, we need a good preoperative assessment like the size and location of the lesions, along with the patient's age and pregnancy expectations, previous surgeries, endometrial pain, and symptoms, number of lesions, adhesions (which are common), previous therapies, QoL, the patient is asked about their urinary and GI symptoms if present, etc. The indication for surgery is based on the clinical presentation, disease symptoms, and the extent of the disease (115). The only absolute indication for surgery

in asymptomatic endometriosis is parametrial infiltration with ureteral obstruction. The gold standard for treating deep pelvic endometriosis is laparoscopic surgery. Laparoscopic surgery offers advantages such as reduced postoperative pain, shorter hospital stays, and faster recovery compared to open surgery (laparotomy). Laparotomy is helpful only in cases of severe DE (60).

It's estimated that roughly 5 to 12% of patients experience deep endometriosis affecting the intestines, with about 90% of lesions located on the sigmoid colon or rectum (39). When a patient comes with rectal bleeding (hematochezia), a colonoscopy is necessary to differentiate primary bowel disease (116). Current surgical methods for addressing colorectal lesions include segmental resection, discoid excision, and superficial resection, also known as "serosal shaving." If deep (infiltrating) lesions extend into the muscular layer, occasionally involving the submucosa and even the mucosa, partial or complete thickness removal discoid excision or segmental bowel resection may be required. Serosal shaving, as the name says, is reserved for the mucosal layer (116,117).

Infiltration reaching the mucosa and invasion covering more than 50% of the circumference has been proposed as indications for bowel resection. Surgery for deep endometriosis is linked with late complications such as bowel and ureteral perforations occurring later, as well as the development of rectovaginal and ureterovaginal fistulas and postoperative bleeding (117). Many studies have tried but until now, the superiority of any of the surgical options in terms of reducing recurrence rates and pain, as well as enhancing quality of life, has not been demonstrated and has similar outcomes (116).

Bladder endometriosis, even when necessitating full-thickness resection, can be effectively managed through laparoscopic surgery, provided meticulous care is taken to avoid injuring the intramural part of the ureter. To mitigate this risk, a stent should be inserted when the lesion is near the ureter, and the bladder should be opened as high as possible to facilitate precise localization of the ureter. The bladder wall is typically sutured in two layers, though some argue that one layer may suffice, and a bladder catheter is retained for 7–10 days (117). Preoperative assessment should emphasize urinary tract (clinical exam and US) as a precaution. Possible postoperative complications include secondary bleeding with bladder tamponade, postoperative hydronephrosis, dysuria, anuria, and the formation of fistulas (116).

It's possible for distant organs such as the diaphragm to be affected, and women may then complain of referred shoulder pain. Preoperative assessment is thoracic surgeon consultation and

pulmonary signs and symptoms evaluation if present (116). Superficial lesions can be removed through coagulation or ablation, while larger lesions with diaphragmatic fenestrations require multidisciplinary removal. The most common complication of surgical intervention on the diaphragm is pneumothorax, others include bleeding, infection, and spreading of endometriosis (117).

The most severe form of DIE is a condition referred to as a “frozen pelvis”. A frozen pelvis refers to a condition where the pelvic organs, such as the uterus, ovaries, and surrounding tissues, become adhered together due to inflammation, scarring, or previous surgeries (116).

10.2.4 Laparoscopic uterosacral nerve ablation (LUNA)

Laparoscopic ablation of the uterosacral nerves represents another option in the treatment of dysmenorrhea, dyspareunia, and chronic pelvic pain in patients with endometriosis (116). LUNA is designed to disrupt the efferent nerve fibers in the uterosacral ligament to diminish uterine pain. However, there seems to be little evidence to support the performance of this procedure. The double-blind randomized controlled trial (RCT) conducted by Sutton et al., as previously discussed, indicated that adding Laparoscopic Uterosacral Nerve Ablation (LUNA) to laser vaporization of endometriosis did not enhance pain scores (117). Interestingly, in this meticulously designed double-blinded trial, patients who underwent LUNA in addition to the procedure experienced less favorable outcomes at the 6-month mark in terms of both dysmenorrhea and chronic non-menstrual pain. Even though a considerable number of women opt for this surgical intervention, the latest guidelines do not provide evidence supporting its efficacy in alleviating pain related to endometriosis when compared to conservative laparoscopic surgery aimed at removing endometriotic lesions (118).

10.2.5 Presacral neurectomy (PSN)

Presacral neurectomy has shown effectiveness in addressing chronic pelvic pain and dysmenorrhea (119). The concept behind its use for pain relief is grounded in the understanding

of the sensory pathways from the pelvic organs, which traverse the inferior and superior hypogastric plexus located in the presacral region and extend to the spinal columns. Unfortunately, a subset of patients (20-25%) treated with medication for severe, debilitating pelvic pain do not see improvement. Hence, presacral neurectomy has become an alternative management option for chronic pelvic pain and dysmenorrhea, especially for those unresponsive to medical treatment (119). Given the variety of structures in this region, the procedure is highly technically challenging, particularly when conducted via laparoscopy. Thus, it must be performed cautiously to prevent injuries to major blood vessels and ureters. The primary intraoperative complication is bleeding from the sacral venous plexus, with postoperative issues including constipation, urinary incontinence, and the need for reoperations (120).

According to studies, conservative surgery supplemented with presacral neurectomy (PN) may offer superior relief from midline pain with a similar incidence of operative complications compared to conservative surgery alone, although with a potential increase in postoperative constipation risk (119,120).

10.2.6 Oophorectomy (adnexectomy)

Adnexectomy is a surgical procedure for the removal of fallopian tubes and ovaries. Adnexectomy can be done alongside a hysterectomy. Adnexectomy, with or without hysterectomy, should be reserved for women who have no pregnancy need and to whom is explained the impact of castration on other health parameters such as risk of osteoporosis, sexual dysfunction, and other menopausal issues (118,119). As we mentioned before, endometriosis patients are mostly young, reproductive-age women who we would rather treat according to their wishes, and we need to explain to them what a premature menopause would mean. Removal of ovaries can be done by laparoscopy or laparotomy, with emphasis on laparoscopy (120).

10.2.7 Hysterectomy

Hysterectomy as a surgical method is the removal of the uterus and surrounding tissue (connective tissue, ligation of blood vessels). Types of hysterectomies are laparoscopic, abdominal, and vaginal (110). The definitive surgical treatment comprises a complete

hysterectomy and removal of both fallopian tubes and ovaries, which can be done abdominally or laparoscopically. Additionally, it involves addressing adhesions and excising any visible endometriosis lesions. This approach is recommended for women who have finished childbearing and for those experiencing severe symptoms or who have not responded to conservative medical or surgical interventions (118,119).

There are several types of hysterectomy procedures, each with distinct implications and surgical approaches. Subtotal or supracervical hysterectomy involves the removal of only the body (corpus) of the uterus, leaving the cervix intact. In contrast, total hysterectomy, the most common procedure, entails the complete removal of both the corpus and cervix of the uterus, often referred to as a simple hysterectomy (119). On the other hand, radical hysterectomy is typically reserved for cases of early-stage cervical carcinoma and necessitates the removal of not only the uterus and cervix but also surrounding tissues such as the cardinal ligaments, uterosacral ligaments, and upper vagina (20).

Before consenting to the surgical procedure, patients should be informed about the risks and consequences of this irreversible intervention, as well as the potential complications, including postoperative bleeding and injuries to surrounding organs. It's also important to note that hysterectomy may not necessarily alleviate the symptoms of the disease (111,116). Most commonly the usual endometrial simple hysterectomy with laparoscopy technique is used. But laparoscopic simple hysterectomy encounters a lot of adhesions and endometrial difficulties, so the operation outcome is highly dependent on the operator. Following the completion of this procedure, it is essential to ensure the preservation of the integrity of the bladder and intestines, particularly in cases involving extensive dissection (116).

10.3 Combined therapy

In treatment, a combination of surgery with either preoperative or postoperative pharmacological treatment may be utilized. Before surgery, GnRH agonists may be administered for three months. These medications decrease the size and extent of lesions and soften adhesions, making the surgical procedure more manageable and detailed (110). After surgery, medication treatment is employed to reduce the recurrence rate following surgery and can alleviate pain symptoms. For this purpose, combined oral contraceptives and intrauterine devices releasing levonorgestrel are commonly used (119). Long-term treatment is not recommended due to the

high cost and potential development of side effects. Combined oral contraceptives have proven effective in controlling symptoms following surgery, but their effects are not enduring (121). Recent studies tried to assess the effectiveness of pre- and post-surgical combined therapy and data shows inconclusive data on the effectiveness of medical therapy for endometriosis, particularly regarding the timing of hormonal suppression therapy relative to surgery (120). We found that women receiving postoperative medical therapy may benefit in terms of reduced disease recurrence and increased chances of pregnancy compared to those receiving no therapy or placebo. However, evidence is deficient for hormonal suppression therapy at other times concerning surgery for women with endometriosis (122). Some guidelines prefer the combined therapies and their action while others do not (60,111).

10.4 Residual endometriotic lesions

A recurrence is defined as any lesion detected through diagnostic imaging or during surgery, following the complete excision of all endometriotic lesions in a previous operation there are 4 subtypes of residual recurrent endometriosis. Recurrence based on symptoms is determined by patient history but isn't confirmed through imaging methods or surgical intervention (115). Recurrence based on imaging methods involves identifying the recurrence through imaging techniques, regardless of whether the patient is symptomatic. Laparoscopically confirmed recurrence is when endometriosis is visualized during a laparoscopy, but no biopsy is taken for histological verification. Finally, histologically confirmed recurrence occurs when endometriosis is seen during laparoscopy, and a sample is taken and confirmed through histological examination (60,119).

Prevention of reappearance of endometriosis is divided into surgical and hormonal. Surgical prevention is recommended to be done by cystectomy, rather than drainage and coagulation (ablation) of the ovarian endometrioma (larger than 4cm). It is important to consider the potential damage to the ovary and the consequent reduction in ovarian reserve (60).

Hormonal therapy for endometriosis reappearance is done by using a levonorgestrel-releasing IUD or combined hormone therapy for at least 24 months as an option for the secondary prevention of dysmenorrhea associated with endometriosis. For patients who do not wish to conceive after surgery for endometrioma or deep infiltrating endometriosis (DIE), long-term hormonal suppression is recommended (118). This aims at the secondary prevention of

endometrioma and DIE, as well as the prevention of symptoms associated with endometriosis (59).

It is important to consider the possibility of residual disease, previous suboptimal surgeries, and the presence of undiagnosed adenomyosis, especially if a recurrence occurs very soon after the initial procedure (59,60).

11. ENDOMETRIOSIS AND INFERTILITY

As we mentioned in topic 5, endometriosis symptoms cause fertility disturbances. Patients experience symptoms of infertility and decreased fecundity. Normal fecundity in healthy women is between 0.15-0.20 per month. Women with endometriosis typically experience reduced monthly fecundity, ranging from 0.02 to 0.1 per month (123). Also, endometriosis is linked to a lower rate of live births, late menarche, shorter breastfeeding, and lower reproductive potential (59,123). Infertility is experienced in 30-50 % of women with endometriosis, infertile women are 6 to 8 times more likely to have endometriosis than fertile women. Fifty percent of infertility patients have been diagnosed with endometriosis (59). Infertility in endometriosis is not completely understood regarding etiology but some factors are recognized and are believed to influence infertility. These mechanisms encompass distorted pelvic anatomy, endocrine and ovulatory irregularities, modified peritoneal function, interference with sperm transport, disruption of gamete interaction, slowed zygote cleavage, reduced endometrial receptivity, and alterations in both hormonal and cell-mediated processes within the endometrium. The severity and extent of the disease are highly linked with spontaneous pregnancy, with 50 % of patients with mild disease can conceive spontaneously. As the severity of the disease increases, the rate of spontaneous pregnancy plunges exponentially (124).

Ectopic endometrial tissue in the pelvis causes inflammatory responses which cause adhesion development, and distortion of normal pelvic anatomy (123). Normal pelvic anatomy then causes tubulo-ovarian abnormality contributing to infertility. Additionally, this inflammatory surrounding causes disturbances in ovulation, transport, quality, and implantation of oocytes (123,124).

A complex interplay of humoral and cellular immunity factors governs the growth and inflammatory behavior of ectopic endometrial implants and impacts embryo implantation, and it is not well understood (59). Patients with endometriosis show evidence of polyclonal

autoimmune activation of B cells. Their endometrium produces higher levels of IgA and IgG. Furthermore, autoantibodies against endometrial antigens are present, likely reflecting the endometrium's physiological response to ectopic tissue. Affected females have decreased levels of an enzyme crucial for synthesizing the endometrial ligand for L-selectin. This ligand coats the trophoblast on the surface of the blastocyst. As a result of shifts in the endometrium's ability to accept implantation and the immune system's response, implantation failures and early spontaneous miscarriages ensue (59,123,124).

Treatment modalities are as mentioned in topic 9 but are highly dependent on disease severity. The typical pharmaceutical approach aims at managing endometriosis symptoms by blocking estrogen production and stopping ovulation, but this can have negative impacts on fertility. The decision regarding surgical intervention is based on the clinical presentation considering the patient's pain, overall health, preferences and desires, previous surgeries, other infertility factors, ovarian reserve, and the estimated EFI score. It is advised for women to visit a specialist in ART. Routine surgery is not recommended for patients with mild forms of endometriosis (ASRM I/II) before ART to increase the chance of spontaneous pregnancy and childbirth, as they could have spontaneous pregnancy. Surgery before ART is recommended to alleviate symptoms of the disease and in instances where follicles are unavailable. Reports on infertility in patients with ASRM III have found that the likelihood of spontaneous conception is only 30%, whereas, in ASRM IV, there is almost no chance of spontaneous conception (123). So, as the research showed us for patients with moderate to severe (ASRM III/IV) endometriosis patients desiring pregnancy it is advised to have laparoscopic surgery as it is the most effective infertility treatment, increasing the chances by 60-70% depending on severity. Surgery should not be carried out in ovarian type as it may lead to damage to the ovarian reserve (59, 123,124). Women desiring pregnancy should not be prescribed postoperative hormone suppression as it is necessary to increase the likelihood of pregnancy in the early postoperative period (59,60).

Assisted reproductive techniques currently stand as the most effective treatment for infertility linked to endometriosis. These procedures typically include in vitro fertilization, gamete intrafallopian transfer, and controlled superovulation insemination. However, while they yield immediate improvements in cyclic pregnancy rates by tackling the symptoms, they don't necessarily result in long-term enhancements in fertility. Today ART therapy has a different

approach to lowering surgical interventions. In assisted reproduction, the main techniques often employed include intrauterine insemination (IUI) and in vitro fertilization (IVF) (60).

Intrauterine insemination is usually the original choice for treating infertility in many patients due to its frank nature. If other treatments fail, in vitro fertilization is considered as an alternative (59,124). Whether to surgically treat endometriosis before IVF procedures is still contested. Surgical treatment progresses postoperative pregnancy rates, proposing it may boost IVF success (124).

12. CONCLUSION

Endometriosis is a chronic disease that is benevolent but with very malicious consequences on patients' lives. Endometriosis is manifested by pelvic pain, dysmenorrhea, dyspareunia, and infertility. Pain is a very constant symptom that affects everyday life and leaves a strain on women's psychological health and economic burden. Endometriosis patients are mostly young women of reproductive age. There has not been a medical consensus, but it is considered that endometriosis incidence is rising. It is crucial to achieve an early diagnosis and to control disease and symptoms progression. Diagnosis is achieved with a good clinical history, examination, and imaging. The previous "gold standard" approach was investigative laparoscopy and biopsy. Current medical guidelines lean towards non-invasive techniques of diagnosis. For optimal pain management and improved reproductive capability, timely treatment of patients is crucial. The choice of therapy depends on the patient's age, the severity and extent of the disease, the intensity of the pain, infertility, and the patient's personal preferences. Treatment options, including hormonal medications, surgical interventions, and combined therapies, effectively alleviate symptoms, reduce pain, improve infertility, and improve quality of life. Upon discontinuation of any treatment, a significant percentage experience disease recurrence. Surgical treatment is mostly done by laparoscopic technique, which aims to enhance reproduction, disease suppression, and overall quality of life. Surgical treatment has its own "cost" of surrounding tissue damage, ovarian damage, and peritoneal damage essentially negatively influencing reproduction. It is advised for infertility patients to have artificial hormonal treatment instead of surgery.

Limitations associated with current therapeutic options prompt the exploration of novel treatment modalities that could effectively ameliorate symptoms, eradicate lesions, and decrease recurrence rates, all while minimizing adverse effects and maintaining affordability. Ongoing research activities have uncovered promising programs of medications for managing endometriosis, with some already in clinical use, while others await future clinical trials that may demonstrate their potential efficacy.

13. GRATITUDE

I am grateful for the support, reassurance, patience, and encouragement that my excellent mentor Dr. sc. Prof. Vladimir Banović has provided throughout this academic year. I learned a lot from him.

I want to say special thanks to my family, especially to my deceased father and my loving mother for always believing in me. Not forgetting my two grandmas, also had an important role in keeping me well-fed and happy.

I want to say special thanks to my girlfriend and friends, thanks for everything, I couldn't have made it without you.

And lastly, I would like to express my gratitude to everyone at Zagreb Medical University for teaching me how to grow and become a better version of myself.

14. LITERATURE

1. Benagiano G., Brosens I., Lippi D. The history of endometriosis. *Gynecol. Obstet. Investig.* 2014;78:1–9.
2. Smolarz B, Szyłło K, Romanowicz H. Endometriosis: Epidemiology, Classification, Pathogenesis, Treatment and Genetics (Review of Literature). *Int J Mol Sci.* 2021 Sep 29;22(19):10554.
3. Koninckx PR, Ussia A, Adamyan L, Wattiez A, Gomel V, Martin DC. Pathogenesis of endometriosis: the genetic/epigenetic theory. *Fertil Steril.* 2019 Feb;111(2):327-340.
4. Arafah M, Rashid S, Akhtar M. Endometriosis: A Comprehensive Review. *Adv Anat Pathol.* 2021 Jan;28(1):30-43.
5. Cullen TS. Adenomyoma of the round ligament. *Johns Hopkins Hosp Bull* 1896; 7:112–4.
6. Cullen TS. Adenoma-myoma uteri diffusum benignum. *J Hopkins Hosp Bull* 1896; 6:133–7.
7. Sampson JA. Benign and malignant endometrial implants in the peritoneal cavity, and their relation to certain ovarian tumors. *Surg Gynecol Obstet* 1924; 38:287–311.
8. Sampson JA. Peritoneal endometriosis due to the menstrual dissemination of endometrial tissue into the peritoneal cavity. *Am J Obstet Gynecol* 1927; 14:422–69.
9. Kurman RJ. Blaustein's Pathology of the Female Genital Tract. New York, NY: Springer Berlin Heidelberg; 2019. 7th edition, page 211.
10. Clement PB, Young RH, Scully RE. Necrotic pseudoxanthomatous nodules of ovary and peritoneum in endometriosis. *Am J Surg Pathol.* 1988 May;12(5):390-7.
11. Burney RO, Giudice LC. Pathogenesis and pathophysiology of endometriosis. *Fertil Steril.* 2012 Sep;98(3):511-9.
12. Kvaskoff M, Mu F, Terry KL, et al. Endometriosis: a high-risk population for major chronic diseases? *Hum Reprod Update.* 2015; 21:500–516.
13. McCluggage WG. Endometriosis-related pathology: a discussion of selected uncommon benign, premalignant and malignant lesions. *Histopathology.* 2020; 76:76–92.
14. Shafrir AL, Farland LV, Shah DK, et al. Risk for and consequences of endometriosis: a critical epidemiologic review. *Best Pract Res Clin Obstet Gynaecol.* 2018; 51:1–15.

15. Zondervan KT, Becker CM, Koga K, Missmer SA, Taylor RN, Viganò P. Endometriosis. *Nat Rev Dis Primers*. 2018 Jul 19;4(1):9.
16. Borghese B, Santulli P, Marcellin L, Chapron C. Définition, description, formes anatomo-cliniques, pathogénèse et histoire naturelle de l'endométriose, RPC Endométriose CNGOF-HAS [Definition, description, clinicopathological features, pathogenesis and natural history of endometriosis: CNGOF-HAS Endometriosis Guidelines]. *Gynecol Obstet Fertil Senol*. 2018 Mar;46(3):156-167.
17. Bulun SE, Yilmaz BD, Sison C, Miyazaki K, Bernardi L, Liu S, Kohlmeier A, Yin P, Milad M, Wei J. Endometriosis. *Endocr Rev*. 2019 Aug 1;40(4):1048-1079.
18. Vercellini P, Viganò P, Somigliana E, Fedele L. Endometriosis: pathogenesis and treatment. *Nat Rev Endocrinol*. 2014;10(5):261–275.
19. Bulun SE. Endometriosis. *N Engl J Med*. 2009 Jan 15;360(3):268-79.
20. Kaplan medicine Tamara Callahan, MD, MPP Assistant Professor Department of Obstetrics and Gynecology Division of Gynecologic Specialties Vanderbilt University Medical Center Nashville, Tennessee Aaron B. Caughey, MD, MPP, MPH, PhD: 6th edition
21. Up-to-date online clinical handbook Walters Kluwer available at <https://www.wolterskluwer.com/en/solutions/uptodate>
22. Yen CF, Hamdan M, Hengrasmee P, Huang Z, Jeong K, Dao LA, Lertvikool S, Mogan S, Pal B, Sumapradja K, Wu MH, Yap-Garcia MIM, Donovan C, Christopher S, Kim MR. Improving the diagnosis of endometriosis in Asia-Pacific: Consensus from the Asia-Pacific Endometriosis Expert Panel for Endometriosis. *Int J Gynaecol Obstet*. 2023 Dec;163(3):720-732.
23. Della Corte L, Di Filippo C, Gabrielli O, Reppuccia S, La Rosa VL, Ragusa R, Fichera M, Commodari E, Bifulco G, Giampaolino P. The Burden of Endometriosis on Women's Lifespan: A Narrative Overview on Quality of Life and Psychosocial Wellbeing. *Int J Environ Res Public Health*. 2020 Jun 29;17(13):4683.
24. Rush G., Misajon R. Examining subjective wellbeing and health-related quality of life in women with endometriosis. *Health Care Women Int*. 2018;39:303–321.
25. Marinho M.C.P., Magalhaes T.F., Fernandes L.F.C., Augusto K.L., Brilhante A.V.M., Bezerra L. Quality of Life in Women with Endometriosis: An Integrative Review. *J Womens Health (Larchmt)* 2018;27:399–408.
26. Nnoaham KE, Hummelshoj L, Webster P, et al. Impact of endometriosis on quality of life and work productivity: a multicenter study across ten countries. *Fertil Steril*. 2011; 96:366-373.e8.

27. Gao X, Yeh YC, Outley J, Simon J, Botteman M, Spalding J. Health related quality of life burden of women with endometriosis: a literature review. *Curr Med Res Opin.* 2006; 22:1787-1797.
28. Becker K, Heinemann K, Imthurn B, et al. Real-world data on symptomology and diagnostic approaches of 27,840 women living with endometriosis. *Sci Rep.* 2021; 11:20404.
29. Facchin F, Barbara G, Saita E, et al. Impact of endometriosis on quality of life and mental health: pelvic pain makes the difference. *J Psychosom Obstet Gynaecol.* 2015; 36:135-141.
30. Vitale SG, La Rosa VL, Rapisarda AMC, Lagana AS. Impact of endometriosis on quality of life and psychological well-being. *J Psychosom Obstet Gynaecol.* 2017; 38:317-319.
31. Mabrouk M., Del Forno S., Spezzano A., Raimondo D., Arena A., Zanello M., Leonardi D., Paradisi R., Seracchioli R. Painful Love: Superficial Dyspareunia and Three Dimensional Transperineal Ultrasound Evaluation of Pelvic Floor Muscle in Women with Endometriosis. *J. Sex Marital. Ther.* 2019:1–10.
32. Vercellini P., Somigliana E., Buggio L., Barbara G., Frattaruolo M.P., Fedele L. “I can’t get no satisfaction”: Deep dyspareunia and sexual functioning in women with rectovaginal endometriosis. *Fertil. Steril.* 2012; 98:1503–1511.e1.
33. La Rosa VL, De Franciscis P, Barra F, Schiattarella A, Tropea A, Tesarik J, Shah M, Kahramanoglu I, Marques Cerentini T, Ponta M, Ferrero S. Sexuality in women with endometriosis: a critical narrative review. *Minerva Med.* 2020 Feb;111(1):79-89.
34. Rush G., Misajon R. Examining subjective wellbeing and health-related quality of life in women with endometriosis. *Health Care Women Int.* 2018; 39:303–321.
35. Seear K. The etiquette of endometriosis: Stigmatisation, menstrual concealment and the diagnostic delay. *Soc. Sci. Med.* 2009;69:1220–1227.
36. Simoens S., Dunselman G., Dirksen C., Hummelshoj L., Bokor A., Brandes I., Brodzky V., Canis M., Colombo G.L., DeLeire T., et al. The burden of endometriosis: Costs and quality of life of women with endometriosis and treated in referral centres. *Hum. Reprod.* 2012;27:1292–1299.
37. Finan P.H., Goodin B.R., Smith M.T. The association of sleep and pain: An update and a path forward. *J Pain.* 2013;14:1539–1552.

38. Soliman AM, Fuldeore M, Snabes MC. Factors associated with time to endometriosis diagnosis in the United States. *J Womens Health (Larchmt)*. 2017;26:788-797.
39. Giudice L. Managing symptomatic endometriosis. *Sex Reprod Menopause*. 2011;9(suppl):S31–S33. Available at: [https://www.fertstert.org/article/S0015-0282\(12\)01955-3/fulltext](https://www.fertstert.org/article/S0015-0282(12)01955-3/fulltext)
40. Eskenazi B, Warner ML. Epidemiology of endometriosis. *Obstet Gynecol Clin North Am*. 1997 Jun;24(2):235-58.
41. Dai Y, Li X, Shi J, et al. A review of the risk factors, genetics and treatment of endometriosis in Chinese women: a comparative update. *Reprod Health*. 2018;15:82.
42. Parazzini F, Esposito G, Tozzi L, et al. Epidemiology of endometriosis and its comorbidities. *Eur J Obstet Gynecol Reprod Biol*. 2017;209:3–7.
43. Ávalos Marfil A, Barranco Castillo E, Martos García R, Mendoza Ladrón de Guevara N, Mazheika M. Epidemiology of Endometriosis in Spain and Its Autonomous Communities: A Large, Nationwide Study. *Int J Environ Res Public Health*. 2021 Jul 25;18(15):7861.
44. Shafir AL, Farland LV, Shah DK, Harris HR, Kvaskoff M, Zondervan K, Missmer SA. Risk for and consequences of endometriosis: A critical epidemiologic review. *Best Pract Res Clin Obstet Gynaecol*. 2018 Aug; 51:1-15.
45. Houston DE, Noller KL, Melton LJ 3rd, Selwyn BJ, Hardy RJ. Incidence of pelvic endometriosis in Rochester, Minnesota, 1970-1979. *Am J Epidemiol*. 1987 Jun;125(6):959-69.
46. Leibson CL, Good AE, Hass SL, Ransom J, Yawn BP, O'Fallon WM, Melton LJ 3rd. Incidence and characterization of diagnosed endometriosis in a geographically defined population. *Fertil Steril*. 2004 Aug;82(2):314-21.
47. Walter AJ, Hentz JG, Magtibay PM, Cornella JL, Magrina JF. Endometriosis: correlation between histologic and visual findings at laparoscopy. *Am J Obstet Gynecol*. 2001 Jun;184(7):1407-11; discussion 1411-3.
48. Guo SW, Wang Y. The prevalence of endometriosis in women with chronic pelvic pain. *Gynecol Obstet Invest*. 2006;62(3):121-30.
49. Koninckx, P.R., Ussia, A., Keckstein, J. et al. Epidemiology of subtle, typical, cystic, and deep endometriosis: a systematic review. *Gynecol Surg* 13, 457–467 (2016).

50. Nnoaham KE, Hummelshoj L, Webster P, D'Hooghe T, de Cicco Nardone F, De Cicco Nardone C, et al. Impact of endometriosis on quality of life and work productivity: a multicenter study across ten countries. *Fertil Steril* 2011; 96:366e373 e8.
51. Balasch J, Creus M, Fábregues F, Carmona F, Ordi J, Martínez-Román S, Vanrell JA. Visible and non-visible endometriosis at laparoscopy in fertile and infertile women and in patients with chronic pelvic pain: a prospective study. *Hum Reprod*. 1996 Feb;11(2):387-91.
52. Vercellini P, Parazzini F, Bolis G, Carinelli S, Dindelli M, Vendola N, Luchini L, Crosignani PG. Endometriosis and ovarian cancer. *Am J Obstet Gynecol*. 1993 Jul;169(1):181-2.
53. Parasar P, Ozcan P, Terry KL. Endometriosis: Epidemiology, Diagnosis and Clinical Management. *Curr Obstet Gynecol Rep*. 2017 Mar;6(1):34-41.
54. Cramer DW, Missmer SA. The epidemiology of endometriosis. *Ann N Y Acad Sci* 2002;955:11-22.
55. Koninckx PR, Ussia A, Adamyan L, Tahlak M, Keckstein J, Wattiez A, Martin DC. The epidemiology of endometriosis is poorly known as the pathophysiology and diagnosis are unclear. *Best Pract Res Clin Obstet Gynaecol*. 2021 Mar;71:14-26.
56. Moen MH, Schei B. Epidemiology of endometriosis in a Norwegian county. *Acta Obstet Gynecol Scand* 1997;76:559-62.
57. Janssen EB, Rijkers AC, Hoppenbrouwers K, Meuleman C, D'Hooghe TM. Prevalence of endometriosis diagnosed by laparoscopy in adolescents with dysmenorrhea or chronic pelvic pain: a systematic review. *Hum Reprod Update* 2013;19:570-82.
58. Zondervan KT, Cardon LR, Kennedy SH. What makes a good case-control study? Design issues for complex traits such as endometriosis. *Hum Reprod* 2002;17:1415-23.
59. Bulletti C, Coccia ME, Battistoni S, Borini A. Endometriosis and infertility. *J Assist Reprod Genet*. 2010 Aug;27(8):441-7.
60. HDZE- Croatian Society for Endometriosis 2024- guide lines, available at: <https://endom.coredl.ai/index.php/category/objave/>
61. Singh SS, Allaire C, Al-Nourhji O, Bougie O, Bridge-Cook P, Duigenan S, Kroft J, Lemyre M, Leonardi M, Leyland N, Maheux-Lacroix S, Wessels J, Wahl K, Yong PJ. Guideline No.449: Diagnosis and Impact of Endometriosis - A Canadian Guideline. *J Obstet Gynaecol Can*. 2024 Mar 28;46(5):102450.
62. Allaire C, Yong PJ, Bajzak K, et al. Guideline No. 445: Management of Chronic Pelvic Pain. *Journal of Obstetrics and Gynaecology Canada* 2024; 46:102283

63. Apostolopoulos NV, Alexandraki KI, Gorry A, Coker A. Association between chronic pelvic pain symptoms and the presence of endometriosis. *Arch Gynecol Obstet* 2016; 293:439e445.
64. Singh S, Soliman AM, Rahal Y, et al. Prevalence, Symptomatic Burden, and Diagnosis of Endometriosis in Canada: Cross-Sectional Survey of 30 000 Women. *J Obstet Gynaecol Can* 2020; 42:829-838.
65. Schliep KC, Mumford SL, Peterson CM, Chen Z, Johnstone EB, Sharp HT, Stanford JB, Hammoud AO, Sun L, Buck Louis GM. Pain typology and incident endometriosis. *Hum Reprod.* 2015 Oct;30(10):2427-38.
66. Peterson CM, Johnstone EB, Hammoud AO, Stanford JB, Varner MW, Kennedy A, Chen Z, Sun L, Fujimoto VY, Hediger ML, Buck Louis GM; ENDO Study Working Group. Risk factors associated with endometriosis: importance of study population for characterizing disease in the ENDO Study. *Am J Obstet Gynecol.* 2013 Jun;208(6):451.e1-11.
67. Ashrafi M, Sadatmahalleh SJ, Akhoond MR, Talebi M. Evaluation of Risk Factors Associated with Endometriosis in Infertile Women. *Int J Fertil Steril.* 2016 Apr-Jun;10(1):11-21.
68. Hudelist G, Oberwinkler KH, Singer CF, Tuttlies F, Rauter G, Ritter O, Keckstein J. Combination of transvaginal sonography and clinical examination for preoperative diagnosis of pelvic endometriosis. *Hum Reprod.* 2009 May;24(5):1018-24.
69. Young SL. Nonsurgical approaches to the diagnosis and evaluation of endometriosis. *Fertil Steril.* 2024 Feb;121(2):140-144.
70. Tan S, Leonardi M, Lo G, Lee E. Role of ultrasonography in the diagnosis of endometriosis in infertile women: Ovarian endometrioma, deep endometriosis, and superficial endometriosis. *Best Pract Res Clin Obstet Gynaecol.* 2024 Feb; 92:102450.
71. Nisenblat V, Bossuyt PM, Farquhar C, Johnson N, Hull ML. Imaging modalities for the non-invasive diagnosis of endometriosis. *Cochrane Database Syst Rev.* 2016 Feb 26;2(2):CD009591.
72. Rosefort A, Huchon C, Estrade S, Paternostre A, Bernard JP, Fauconnier A. Is training sufficient for ultrasound operators to diagnose deep infiltrating endometriosis and bowel involvement by transvaginal ultrasound? *J Gynecol Obstet Hum Reprod.* 2019 Feb;48(2):109-114.

73. Collins BG, Ankola A, Gola S, McGillen KL. Transvaginal US of Endometriosis: Looking Beyond the Endometrioma with a Dedicated Protocol. *Radiographics*. 2019 Sep-Oct;39(5):1549-1568.
74. Arezzo F, Cormio G, La Forgia D, Kawosha AA, Mongelli M, Putino C, Silvestris E, Oreste D, Lombardi C, Cazzato G, Cicinelli E, Loizzi V. The Application of Sonovaginography for Implementing Ultrasound Assessment of Endometriosis and Other Gynaecological Diseases. *Diagnostics (Basel)*. 2022 Mar 27;12(4):820.
75. Somigliana E, Viganò P, Parazzini F, Stoppelli S, Giambattista E, Vercellini P. Association between endometriosis and cancer: a comprehensive review and a critical analysis of clinical and epidemiological evidence. *Gynecol Oncol*. 2006 May;101(2):331-41.
76. Orlov S, Jokubkiene L. Prevalence of endometriosis and adenomyosis at Transvaginal Ultrasound examination in symptomatic women. *Acta Obstet Gynecol Scand* 2022;101(5):524–31.
77. Guerriero S, Ajossa S, Pagliuca M, Borzacchelli A, Deiala F, Springer S, et al. Advances in imaging for assessing pelvic endometriosis. *Diagnostics* 2022;12(12): 2960.
78. Quesada J, Härmä K, Reid S, Rao T, Lo G, Yang N, Karia S, Lee E, Borok N. Endometriosis: A multimodal imaging review. *Eur J Radiol*. 2023 Jan;158:110610.
79. Bazot M, Daraï E. Diagnosis of deep endometriosis: clinical examination, ultrasonography, magnetic resonance imaging, and other techniques. *Fertil Steril* 2017; 108(6):886–94.
80. Collins BG, Ankola A, Gola S, McGillen KL. Transvaginal US of Endometriosis: Looking Beyond the Endometrioma with a Dedicated Protocol. *Radiographics*. 2019 Sep-Oct;39(5):1549-1568.
81. Guerriero S, Condous G, van den Bosch T, Valentin L, Leone FP, Van Schoubroeck D, Exacoustos C, Installé AJ, Martins WP, Abrao MS, Hudelist G, Bazot M, Alcazar JL, Gonçalves MO, Pascual MA, Ajossa S, Savelli L, Dunham R, Reid S, Menakaya U, Bourne T, Ferrero S, Leon M, Bignardi T, Holland T, Jurkovic D, Benacerraf B, Osuga Y, Somigliana E, Timmerman D. Systematic approach to sonographic evaluation of the pelvis in women with suspected endometriosis, including terms, definitions and measurements: a consensus opinion from the International Deep Endometriosis Analysis (IDEA) group. *Ultrasound Obstet Gynecol*. 2016 Sep;48(3):318-32.
82. Goncalves MO, Siufi Neto J, Andres MP, Siufi D, de Mattos LA, Abrao MS. Systematic evaluation of endometriosis by transvaginal ultrasound can accurately replace diagnostic laparoscopy, mainly for deep and ovarian endometriosis. *Hum Reprod*. 2021 May 17;36(6):1492-1500.

83. Clement PB. The pathology of endometriosis: a survey of the many faces of a common disease emphasizing diagnostic pitfalls and unusual and newly appreciated aspects. *Advances in anatomic pathology* 2007;14:241-260.
84. Pašalić E, Tambuwala MM, Hromić-Jahjefendić A. Endometriosis: Classification, pathophysiology, and treatment options. *Pathol Res Pract.* 2023 Nov; 251:154847.
85. FERTILITY AND STERILITY® Special contribution Revised American Society for Reproductive Medicine classification of endometriosis: 1996 American Society for Reproductive Medicine. Available at: <https://pubmed.ncbi.nlm.nih.gov/9130884/>
86. F. Tuttlies, J. Keckstein, U. Ulrich, M. Possover, K.W. Schweppe, M. Wustlich, O. Buchweitz, R. Greb, O. Kandolf, R. Mangold, W. Masetti, K. Neis, G. Rauter, N. Reeka, O. Richter, A.E. Schindler, M. Sillem, V. Terruhn, H.R. Tinneberg, ENZIAN-Score, eine Klassifikation der tief infiltrierenden Endometriose, *Zent. Gynakol.* 127 (2005) 275–281.
87. V. Di Paola, R. Manfredi, F. Castelli, R. Negrelli, S. Mehrabi, R. Pozzi Mucelli, Detection and localization of deep endometriosis by means of MRI and correlation with the ENZIAN score, *Eur. J. Radiol.* vol. 84 (4) (2015) 568–574.
88. G.D. Adamson, D.J. Pasta, Endometriosis fertility index: the new validated endometriosis staging system, *Fertil. Steril.* 94 (2010) 1609–1615.
89. M.S. Abrao, M.P. Andres, C.E. Miller, J.A. Gingold, M. Rius, J.S. Neto, F. Carmona, AAGL 2021 endometriosis classification: an anatomy-based surgical complexity score, e1, *J. Minim. Invasive Gynecol.* 28 (2021) 1941–1950.
90. Lee SY, Koo YJ, Lee DH. Classification of endometriosis. *Yeungnam Univ J Med.* 2021 Jan;38(1):10-18.
91. Dai Y, Li X, Shi J, Leng J. A review of the risk factors, genetics and treatment of endometriosis in Chinese women: a comparative update. *Reprod Health.* 2018 May 21;15(1):82.
92. Basta A., Brucka A., Górski J., Kotarski J., Kulig B., Oszukowski P., Poręba R., Radowicki S., Radwan J., Sikora J., et al. Stanowisko Zespołu Ekspertów Polskiego Towarzystwa Ginekologicznego dotyczące diagnostyki i metod leczenia endometriozy. *Ginekol. Pol.* 2012; 83:871–876.
93. Becker CM, Gattrell WT, Gude K, Singh SS. Reevaluating response and failure of medical treatment of endometriosis: a systematic review. *Fertil Steril.* 2017 Jul;108(1):125-136.
94. Giudice L.C. Clinical practice. Endometriosis. *N Engl J Med.* 2010; 362:2389–2398.

95. Crosignani P, Olive D., Bergqvist A., Luciano A. Advances in the management of endometriosis: an update for clinicians. *Hum Reprod Update*. 2006; 12:179–189.
96. Lee D.Y., Lee J.Y., Seo J.W., Yoon B.K., Choi D. Gonadotropin-releasing hormone agonist with add-back treatment is as effective and tolerable as dienogest in preventing pain recurrence after laparoscopic surgery for endometriosis. *Arch Gynecol Obstet*. 2016
97. Allaire C, Bedaiwy MA, Yong PJ. Diagnosis and management of endometriosis. *CMAJ*. 2023 Mar 14;195(10):E363-E371.
98. Brown J, Crawford TJ, Allen C, Hopewell S, Prentice A. Nonsteroidal anti-inflammatory drugs for pain in women with endometriosis. *Cochrane Database Syst Rev*. 2017 Jan 23;1(1):CD004753.
99. Tosti C, Biscione A, Morgante G, Bifulco G, Luisi S, Petraglia F. Hormonal therapy for endometriosis: from molecular research to bedside. *Eur J Obstet Gynecol Reprod Biol*. 2017 Feb;209:61-66.
100. Bulun SE. Endometriosis. *N Engl J Med*. 2009 Jan 15;360(3):268-79.
101. Attia GR, Zeitoun K, Edwards D, Johns A, Carr BR, Bulun SE. Progesterone receptor isoform A but not B is expressed in endometriosis. *J Clin Endocrinol Metab* 2000; 85:2897–902.
102. Angioni S, Cofelice V, Pontis A, Tinelli R, Socolov R. New trends of progestins treatment of endometriosis. *Gynecol Endocrinol*. 2014 Nov;30(11):769-73.
103. Ferrero S, Remorgida V, Venturini PL, Bizzarri N. Endometriosis: the effects of dienogest. *BMJ Clin Evid* 2015;2015.
104. Lazzeri L, Luisi S, Petraglia F. Progestins for the treatment of endometriosis: an update. *J Endometr* 2010;2(4):169–81.
105. Vannuccini S, Clemenza S, Rossi M, Petraglia F. Hormonal treatments for endometriosis: The endocrine background. *Rev Endocr Metab Disord*. 2022 Jun;23(3):333-355.
106. Casper RF. Progestin-only pills may be a better first-line treatment for endometriosis than combined estrogen-progestin contraceptive pills. *Fertil Steril*. 2017;107(3):533–536.
107. Levine D, Kaufman L, Cuenca VG, Badawy SZA. Cell growth effects of leuprolide on cultured endometrioma cells. *J Reprod Med*. 2007;52(7):581–584.

108. DiVasta AD, Feldman HA, Sadler Gallagher J, Stokes NA, Laufer MR, Hornstein MD, et al. Hormonal add-back therapy for females treated with gonadotropin-releasing hormone agonist for endometriosis: a randomized controlled trial. *Obstet Gynecol.* 2015;126(3):617–627.
109. Schwartz K, Llarena NC, Rehmer JM, Richards EG, Falcone T. The role of pharmacotherapy in the treatment of endometriosis across the lifespan. *Expert Opin Pharmacother.* 2020;1-11
110. Clemenza S, Sorbi F, Noci I, Capezzuoli T, Turrini I, Carriero C, Buffi N, Fambrini M, Petraglia F. From pathogenesis to clinical practice: Emerging medical treatments for endometriosis. *Best Pract Res Clin Obstet Gynaecol.* 2018 Aug;51:92-101.
111. Working group of ESGE, ESHRE and WES; Saridogan E, Becker CM, Feki A, Grimbizis GF, Hummelshoj L, Keckstein J, Nisolle M, Tanos V, Ulrich UA, Vermeulen N, De Wilde RL. Recommendations for the Surgical Treatment of Endometriosis. Part 1: Ovarian Endometrioma. *Hum Reprod Open.* 2017 Dec 19;2017(4).
112. Bafort C, Beebejaun Y, Tomassetti C, Bosteels J, Duffy JM. Laparoscopic surgery for endometriosis. *Cochrane Database Syst Rev.* 2020 Oct 23;10(10).
113. Kalaitzopoulos DR, Samartzis N, Kolovos GN, Mareti E, Samartzis EP, Eberhard M, Dinas K, Daniilidis A. Treatment of endometriosis: a review with comparison of 8 guidelines. *BMC Womens Health.* 2021 Nov 29;21(1):397.
114. Rolla E. Endometriosis: advances and controversies in classification, pathogenesis, diagnosis, and treatment. *F1000Res.* 2019 Apr 23;8:F1000 Faculty Rev-529.
115. Muzii L, Miller CE. The singer, not the song. *J Minim Invasive Gynecol.* 2011 Sep-Oct;18(5):666-7.
116. Working group of ESGE, ESHRE, and WES; Keckstein J, Becker CM, Canis M, Feki A, Grimbizis GF, Hummelshoj L, Nisolle M, Roman H, Saridogan E, Tanos V, Tomassetti C, Ulrich UA, Vermeulen N, De Wilde RL. Recommendations for the surgical treatment of endometriosis. Part 2: deep endometriosis. *Hum Reprod Open.* 2020 Feb 12;2020.
117. Koninckx PR, Ussia A, Adamyan L, Wattiez A, Donnez J. Deep endometriosis: definition, diagnosis, and treatment. *Fertil Steril* 2012; 98:564–571.
118. Gambone JC, Mittman BS, Munro MG, Scialli AR, Winkel CA; Chronic Pelvic Pain / Endometriosis Working Group. Consensus statement for the management of chronic pelvic pain and endometriosis: proceedings of an expert-panel consensus process. *Fertil Steril.* 2002 Nov;78(5):961-72.
119. Chen FP. Laparoscopic presacral neurectomy for chronic pelvic pain. *Chang Gung Med J.* 2000 Jan;23(1):1-7.

120. Miller LE, Bhattacharyya R, Miller VM. Clinical Utility of Presacral Neurectomy as an Adjunct to Conservative Endometriosis Surgery: Systematic Review and Meta-Analysis of Controlled Studies. *Sci Rep.* 2020 Apr 23;10(1):6901.
121. ACOG Committee on Practice Bulletins-Gynecology ACOG practice bulletin. Practice bulletin no. 114: management of endometriosis. *Obstet Gynecol.* 2010; 116: 223– 36.
122. Chen I, Veth VB, Choudhry AJ, Murji A, Zakhari A, Black AY, et al. Pre- and postsurgical medical therapy for endometriosis surgery. *Cochrane Database Syst Rev.* 2020 Nov 18;11.
123. Collins JA, Burrows EA, Wilan AR. The prognosis for live birth among untreated infertile couples. *Fertil Steril.* 1995;64(1):22–28.
124. Practice Committee of the American Society for Reproductive Medicine (ASRM) Endometriosis and Infertility. *Fertil Steril.* 2006;14: S156–S160.

CURRICULUM VITAE

I was born on the 4th of May 1998. in Zagreb.
From 2005-2013 I went to elementary school "J. J. Strossmayer" in Zagreb where I started to learn Latin and old Greek. My education continues from 2013 until 2017. During that period, I went to Classical gymnasium in Zagreb, where I continued to learn Latin and Greek.
In the year 2017. I got accepted into medical studies in English, University of Medicine Zagreb. I'm fluent in Croatian, English and I studied Latin and Greek for 8 years. I also studied Italian in high school and elementary school for 8 years.

Email: miro.kerner45@gmail.com

Tel: +385994537675