

Microvascular surgery

Moiguer, Ron

Master's thesis / Diplomski rad

2024

Degree Grantor / Ustanova koja je dodijelila akademski / stručni stupanj: **University of Zagreb, School of Medicine / Sveučilište u Zagrebu, Medicinski fakultet**

Permanent link / Trajna poveznica: <https://um.nsk.hr/um:nbn:hr:105:364684>

Rights / Prava: [In copyright](#)/[Zaštićeno autorskim pravom.](#)

Download date / Datum preuzimanja: **2025-03-20**



Repository / Repozitorij:

[Dr Med - University of Zagreb School of Medicine Digital Repository](#)



University of Zagreb
School of Medicine

Ron Moiguer
Microvascular Surgery
Graduate Thesis



Zagreb, 2024

This graduation thesis was made at the Department of Plastic - Reconstructive and Breast Surgery, University Hospital Center Zagreb, Croatia, mentored by prof. dr. sc. Davor Mijatović, dr. med., and was submitted for evaluation in the academic year 2023/2024.

Abbreviations

FF - Free flap

FFT - Free flap transfer

AR – Augmented reality

CT – Computed tomography

MRI – Magnetic Resonance Imaging

ETE – End-to-end

ETS – End-to-side

IVG – Interposition vein graft

NSA – non-suture anastomosis

ADS – Acoustic Doppler Sonography

RFFF – Radial Forearm Free Flap

LABC – Lateral antebrachial cutaneous

MABC – Medial antebrachial cutaneous

FFF – Fibula Free Flap

LDF – Latissimus Dorsi Flap

TDA – Thoracodorsal artery

TDAP – Thoracodorsal artery Perforator flap

ALT – Anterolateral Thigh flap

LFCA – Lateral Femoral Circumflex artery

ASIS – Anterior superior iliac spine

CSA – Circumflex scapular artery

TRAM – Transverse Rectus Abdominis Myocutaneous

MS – Muscle-sparing

DIEP – Deep Inferior Epigastric Perforator

Table of contents

Summary	4
Sažetak	5
1.Introduction	6
2. Microvascular surgery	8
2.1 Technical equipment	8
2.2 Microvascular technique	10
2.2.1. End-to-end anastomosis	10
2.2.2. End-to-side anastomosis	11
2.2.3. Venous grafts	12
2.2.4. Non-suture anastomosis	12
2.2.5. Monitoring	13
2.3 Free flaps	14
2.3.1. Free Flaps Classification	14
2.3.2. Radial forearm flap	15
2.3.3. Fibula flap	18
2.3.4. Latissimus dorsi flap	22
2.3.5. Anterolateral thigh flap	25
2.3.6. Scapular flap	28
2.3.7. Rectus flap	31
3. Conclusion	34
4. Acknowledgements	35
5. References	36
6. Biography	43

Summary

Microvascular surgery

Ron Moiguer

Microvascular surgery, or Microsurgery, is the highly specialized field that involves manipulating, repairing, and repositioning of small blood vessels and nerves. Allowing for moving of large skin segments, fat, and bones from one bodily location to another, microvascular surgery is used to help patients with various cancers, severed limbs or digits, fractures, or severely injured tissues through reconstructions, free tissue transfers, and replantation. Using highly specialized equipment such as microscopes, tiny needles, and ultra-fine sutures, microvascular surgeons can operate on blood vessels so small that they are barely visible to the naked eye. Following trauma or disease, surgical operations may leave patients with unsatisfactory functional or cosmetic results. With the introduction of microvascular surgery in the mid 20's, surgeons can address these issues. Careful selection of grafts and precise anastomosis are at the core of successful surgery. Depending on the location and type of tissue, microvascular surgeons can select grafts best suited to their needs. Vital tissue, or "Flap" from various locations of the body can be partially or completely detached to help the surgeon repair complex defects. "Free flap" means that the graft is completely detached from its original place, or "donor site", to be transplanted onto another location, also known as the "recipient site". To ensure that the flap is accepted and to establish proper circulation, anastomosis is made between the vessels of the two sites. Clinical outcomes play a crucial role in evaluating the success of microvascular surgery, and this encompasses factors such as success rates, complications, and patient satisfaction. This thesis will provide overview of some of the microvascular techniques and methods.

Key words: Microvascular surgery, Microsurgery, free flap, grafts, anastomosis.

Sažetak

Mikrovaskularna kirurgija

Ron Moiguer

Mikrovaskularna kirurgija, ili mikrokirurgija, je visoko specijalizirano područje koje uključuje manipuliranje, popravljavanje i premještanje malih krvnih žila i živaca. Omogućujući premještanje velikih dijelova kože, masnog tkiva i kostiju s jednog dijela tijela na drugi, mikrovaskularna kirurgija koristi se kako bi se pomoglo pacijentima s različitim oblicima raka, odrezanim udovima ili prstima, prijelomima ili teško oštećenim tkivima putem rekonstrukcija, slobodnih presađaka tkiva i replantacija. Koristeći visoko specijaliziranu opremu poput mikroskopa, malih igala i ultrafinih šavova, mikrovaskularni kirurzi mogu operirati krvne žile tako male da su komajte vidljive golim okom. Nakon traume ili bolesti, kirurški zahvati mogu ostaviti pacijente s nezadovoljavajućim funkcionalnim ili kozmetičkim rezultatima. Uvođenjem mikrovaskularne kirurgije sredinom 20-ih godina, kirurzi mogu riješiti te probleme. Pažljiv odabir presađaka i precizna anastomoza ključni su za uspješnu operaciju. Ovisno o lokaciji i vrsti tkiva, mikrovaskularni kirurzi mogu odabrati presađke koji najbolje odgovaraju njihovim potrebama. Vitalno tkivo, ili "flap", s različitih mjesta tijela može se djelomično ili potpuno odvojiti kako bi pomoglo kirurgu u popravljavanju kompleksnih defekata. "Slobodni flap" znači da je presađak potpuno odvojen od svog izvornog mjesta, ili "donorske lokacije", kako bi se presađio na drugo mjesto, također poznato kao "primateljsko mjesto". Kako bi se osiguralo da je flap prihvaćen i da se uspostavi pravilna cirkulacija, izrađuje se anastomoza između žila na dvije lokacije. Klinički ishodi igraju ključnu ulogu u procjeni uspjeha mikrovaskularne kirurgije, a to obuhvaća faktore kao što su postotak uspjeha, komplikacije i zadovoljstvo pacijenata. Ova disertacija pružit će pregled nekih mikrovaskularnih tehnika i metoda.

Ključne riječi: Mikrovaskularna kirurgija, mikrokirurgija, slobodni flap, presađci, anastomoza

1. Introduction

Microvascular surgery has emerged as a revolutionary field enabling delicate work within the surgical field that once deemed impossible. It is a term describing the surgical techniques with the use of a microscope, and today it is used in various specialties including plastic surgery, general surgery, otolaryngology, orthopedics, neurosurgery, gynecology, and many more. Its uses among other include breast reconstructions, traumatic wounds, organs transplantations, atrial or venous insufficiency, reanimation surgery for facial paralysis, and amputations. One of the defining characteristics of microvascular surgery is its ability to restore form and function, prevent infections and provide optimal cosmesis.

Dating to early 20th century, advancements and achievements in the field were brought which resulted in revolution of microvascular surgery. In 1902, Alexis Carrel was the first to perform end-to-end anastomosis which remains a cornerstone technique in the field to this day. He was later awarded a noble prize for medicine and physiology for his surgical technique in the anastomosis of arteries (1). In 1921, Carl-Olof Siggesson Nylen, a Swedish otologist, designed and built the first surgical microscope in the university of Stockholm. He first used it for complicated by labyrinthine fistula. Binocular microscope, developed by Nylen's colleague Gunnar Holmgren, soon replaced Nylen's microscope in 1922 (1).

In 1960's, the introduction of "free flap" (FF), or free microvascular tissue transfer, has started to emerge. With Julius Jacobson and Ernesto Suarez perfecting the micro anastomotic technique by 1960. Jacobson and Suarez coupled vessels as small as 1.4mm in diameter (2). The use of free flaps then quickly developed as surgeons around the world continued perfecting the technique and utilize it to their needs. In 1964, for example, Yoshi Nakayama completed the first free flap transfer (FFT) of intestinal segments to the head and neck region. After that in 1965 surgeons in China performed the first toe-to-thumb transfer (3). Developments and utilization of different kinds of free

flaps, from different regions of the body, continued to emerge and changed the view on reconstructive surgery.

Despite its remarkable achievements, microvascular surgery is not without challenges. The technical demands of working at a microscopic scale require a high level of skill and dexterity, necessitating extensive training and experience. This thesis will give a review of the commonly used equipment, techniques, different types of flaps and post-amputation surgeries of fingers of the hand.

2. Microvascular surgery

2.1. Technical equipment

To perform successful microvascular surgery, surgeon rely on specially crafted equipment, designed to perform delicate and precise maneuvers at a microscopic level. From magnification systems to microsurgical instruments, each piece of equipment plays a crucial role in ensuring optimal outcomes and minimizing the risk of complications.

Microscope

Surgical microscope, or operative microscope, is the heart of microsurgery. It provides magnification, illumination, and clear view of the surgical field. The microscope can be divided into three parts: body, light source, and supporting structure (4). The microscope is usually mounted on an on-caster stand, which allows mobility during surgery while making sure the whole apparatus is stable. A series of lenses is what allows for a magnification between 3-40 times while obtaining precise focusing (5). Newer microscopes are equipped with high-definition display with further developments integrating Augmented Reality (6). Although still in development, AR will allow for better visualization, and overlaying of CT, MRI, and angiography, which will assist surgeons navigating in the surgical field (7).

Instruments

To perform microvascular surgery, instruments with very fine tip and grasping end are required. Instruments with a length of 11-12 cm are best suited to avoid contact with the microscope or other equipment, jeopardizing sterility (8). Forceps are the basic instrumentation. Jewler's forceps are used almost continuously during the operation to handle tissue and suture tying (9). Both straight and angled forceps are used. The latter is used when going under a vessel is need or performing a patency test. Micro mosquito forceps are used to hold blood vessels and prevent blood loss. Vessel dilators are used to

gently dilate blood vessels before suturing it back together. Scissors are also used during surgery. Dissecting scissors have slightly curved blades with rounded tips which is important in order to avoid making a hole in the vessel while cutting it (9). Adventitia scissors are very sharp with straight tip used to gently trim the adventitia of the vessel. Vascular clamps are important instruments used to clamp damaged vessels. A micro needle holder is also required.

Sutures

For suturing a flat body needle is ideal for optimal handling and tapered tip to avoid laceration for the vessels during placement. Monofilament nylon, either 9/0 or 10/0, is used for most microvascular anastomosis (10).

2.2. Microvascular Technique

Microvascular surgery techniques require high levels of precision and skills. These techniques enable surgeons to perform delicate procedures involving the reconnection of tiny blood vessels, allowing for the transplantation of tissue, repair of defects, and reconstruction of complex anatomical structures. To perform successful operation a surgeons must make sure they are sitting comfortably without interruptions, have good visualization of the vessels being operated on, atraumatic preparation of the vessel's stump, make sure the vessels being anastomosed are of the same diameter, avoid tension, kinking, and twisting of the vessel's end during anastomosis, and make sure the anastomoses do not lie in the immediate vicinity of bifurcations (11).

2.2.1. End-to-end Anastomosis

End-to-end (ETE) anastomosis is the most common used technique in microvascular surgery. First, the vessels are dissected gently, avoiding unnecessary trauma, and clamped. Vessels being anastomosed should be of the same size. If there is a size difference exists and it is not too great, dilation of the smaller vessel can be performed or cutting it in an oblique fashion (12). When difference in size is too great, End-to-side (ETS) anastomosis technique should be used. Suturing in ETE anastomosis most commonly use interrupted, continuous, and sleeve techniques. Interrupted suturing technique derived from Carrel's triangular technique is the fundamental technique to which all new anastomotic techniques are compared to (13). This technique begins by placing three stitches one third around the circumference of the anastomosis, at an angle of 120 degrees. By placing these stitches, the vessel can be retracted to form a triangle. Then, the two triangulated vessels are approximated, and continuous or interrupted suturing can be performed completing the anastomosis. The interrupted and continuous suturing techniques have similar patency rates although continuous suturing takes less time to perform (14). Another suturing technique in ETE anastomosis is the sleeve technique. This technique involves invagination of a smaller caliber

vessels into the lumen of a larger caliber vessel, is simpler and faster to perform and causes less trauma to the vessels (12). While performing the anastomosis is important to avoid damage to the vessel intima, triggering coagulation and formation of thrombosis.




Figure 1. End-to-End Anastomosis, Triangulation technique. Adapted from (15)

2.2.2. End-to-side Anastomosis

ETS anastomosis is a useful microvascular technique when ETE anastomosis cannot be performed, or the recipient vessel is large and there is a significant difference between the vessel's diameters (2). It is also used when there is one vessel supplying an end organ, such as a limb, which in this case it is mandatory to perform ETS (12). Firstly, the donor vessel is cut and clamped. It is cut in a slightly oblique fashion so when the two sites are joined, it will lie in the direction of the blood flow (2). Then a cut is made in the recipient vessel's side in a diameter matching that of the donor vessel and clamped on both sides of the cut. Continuous suturing is used for most ETS anastomoses although interrupted suturing is used for smaller vessels (2). Complication rates between ETE and ETS, namely thrombosis and flap failure, are similar (16), so the decision on which technique to use is on case-to-case basis and surgical needs.

2.2.3. Venous Grafts

Interposition vein grafting (IVG) play a pivotal role in the field of microvascular surgery. It was first described in 1907 when Eric Lexer used the Saphenous vein to reconstruct a defect of the Axillary artery (17). They serve as a conduit whenever a direct anastomosis between the vessels is not feasible, for example when the flap pedicle is too short or there is an extensive zone of injury (2). "Zone of injury" is an important concept in the field of microsurgery. It is the area surrounding a wound, which may not appear nonviable after initial debridement. Vessels in the zone of injury are more prone to complications (18) and needed to be debrided. In these instances, IVG can be employed to compensate for the length of the injured vessels. Venous grafts can be autologous, using the patient's own veins, most commonly the Saphenous or Cephalic vein, or synthetic. In the field of microvascular surgery, venous grafts are used in reconstructive procedures, composite tissue transplantations, or following trauma. The surgical technique for using venous grafts in microvascular surgery most commonly employ an arteriovenous (AV) loop, or "Corlett loop". Meticulous dissection and preparation of the recipient and donor vessels is performed. A temporary fistula (loop) is created using the graft. After the flap is harvested, the loop is divided and anastomosed to the arterial and venous pedicles of the flap (19). A study performed in 2015 showed success rate of over 95% for IVG used for primary free flap reconstructions, although it was lower for salvage procedures (20).

2.2.4. Non-suture Anastomosis

Non-suture anastomosis (NSA) is a topic still being studied as an alternative to the traditional anastomoses using sutures. 5 methods have been described performing NSA: rings, clips, adhesives, stents, and laser welding (21). Although these techniques are being described as faster and less traumatic to the vessel's wall than traditional suturing anastomosis, each method is

associated with his own complications. Due to this, suture anastomosis is still considered the standard technique in microvascular surgery (21).

2.2.5. Monitoring

Postoperative monitoring is crucial in ensuring successful microvascular FFT. Today, thanks to improvements in monitoring and surgical techniques, FFT success rate is more than 95% (22). Vascular complication typically take place in the first 48 hours post operation (23). Monitoring aims to detect early FF failure and ensure patency and integrity of anastomoses thereby reducing morbidity and mortality. Several techniques are available for postoperative monitoring. These can be clinical, technological, or a combination of both. Today the gold standard in FF monitoring is a combination of clinical examination and Acoustic Doppler Sonography (ADS) (24). Clinical examination of FF includes evaluation of the characteristics of the flap such as temperature, color, capillary refill time, size, turgor and bleeding characteristics (24). It has the advantages of being inexpensive, fast and reliable in detecting FF failure. ADS is an adjunct to clinical examination. It utilizes frequencies of ultrasound to reflect changes in blood flow. For example, a change in signal quality from triphasic to monophasic could be an indication for early arterial occlusion (24). In contrast, venous occlusion may go unrecognized initially, later presenting as the "blood hammer phenomenon" on arterial signal (25). If no signal is detected it can be a sign of advanced vascular compromise and immediate intervention is necessary (26). ADS has the advantages of it being non-invasive, inexpensive, and easy to use. However, it requires experienced operator for accurate monitoring.

2.3. Free Flaps

Free flaps represent a cornerstone of modern microvascular surgery, offering versatile solutions for complex tissue reconstruction and restoration of form and function. These microsurgical procedures involve the transfer of different types and sizes of tissues, with their respective blood supply, from one part of the body to another. With the emergence of FF in the 1960's, the management of complex wounds or tumors, that were deemed inoperable, has revolutionized, and now are routinely performed. Free flaps differ from pedicled flaps. Using pedicled flaps, tissue is transferred while still attached to their origin blood supply, while free flaps are detached completely and reattached to vessels at the recipient site.

2.3.1. Free Flaps Classification

Free flaps can be classified based on their circulation, and tissue composition.

Circulation:

- 1) "Designated" FF: These flaps are classified based on source arteries. That is, a segmental or distributing artery that supplies a particular body region (27). Dissection of these flaps is conducted in an anterograde fashion, from the root of the vessels to its distal branches, to the specific anatomical region it provides (28).
- 2) "Free style" FF: These flaps are based on the perforator vessel, that is a vessel that passes through the muscle and fascia to the skin (29). Detection of these vessels is required, and it is performed using hand-held Doppler, then dissection is performed in a retrograde fashion along the perforator (30).
- 3) Conjoined FF – A large flap consisting of different flap territories, each with his own vascular supply, that have common physical boundaries (31). It may be necessary to perform "intraflap" anastomoses better the vessels of these distinct flap territories (28). Branch-based conjoined flap describes flaps in

which the vessels supplying these territories arise from the same perforator vessel (31).

Tissue composition: The type of tissue can be skin, fascia, muscle, bone, nerve, cartilage, or a combination, with the latter named "complex" flaps.

- 1) Fascial flap – consists only of fascia, without overlying skin.
- 2) Fasciocutaneous – consists of skin, subcutaneous adipose tissue, superficial and deep fascia, containing vascular network enabling the use of a larger flap (29).
- 3) Musculocutaneous – consists of muscle with the overlying skin and subcutaneous tissue. These flaps carry the risk of significant donor site morbidity (28).
- 4) Perforator flaps – these are based on the perforator vessel passing through the muscle to the skin. These flaps enable to harvest only the skin and subcutaneous tissue, without sacrificing the underlying muscle, thereby significantly reducing donor site morbidity (28).
- 5) Osteomyocutaneous - consists of the tissues mentioned above plus the underlying bone and are used whenever bone reconstruction is also needed.

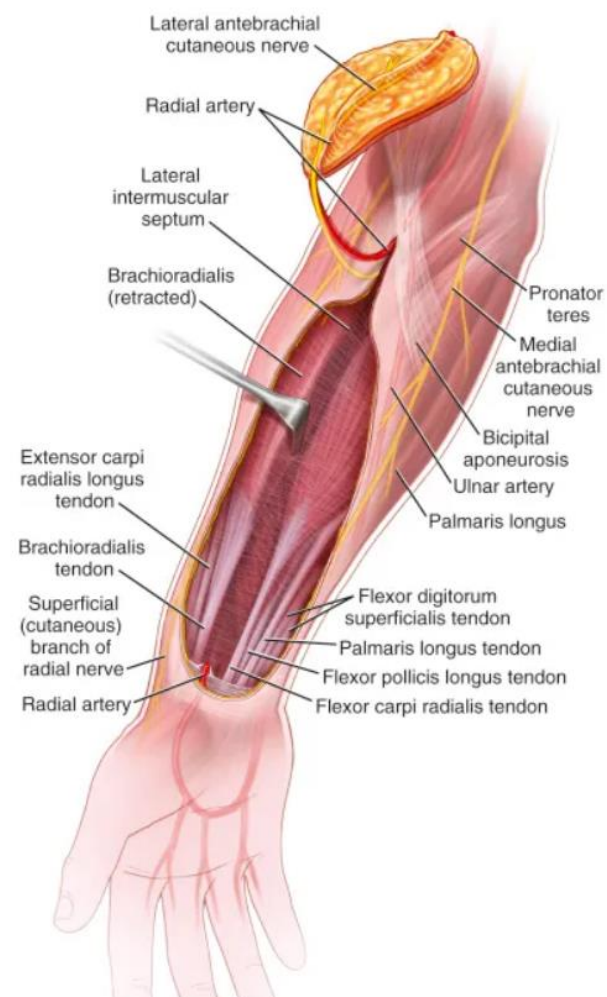
2.3.2. Radial Forearm Free Flap

Radial Forearm Free Flap (RFFF), originally named the "Chinese" flap, proved to be a reliable and versatile tool in the field of reconstructive surgery. First described by Dr. Yang et al. in the early 1980's (32), RFFF gained popularity throughout the year and today is most used for defects of the hypopharynx, oral cavity, pharynx and esophagus, and scalp (33), as well as the hand, and distal part of the lower leg (29). Being thin, flexible, with mostly hairless skin and long pedicle, make this flap ideal for reconstruction of

complex, three-dimensional defects (34). Adding to its versatility, RFFF can be harvested as innervated segment and be reinnervated at the recipient site.

Anatomy:

RFFF can be harvested as a fascial, fasciocutaneous, or osteocutaneous flap (33). Its pedicle is based on the fasciocutaneous perforators from the radial artery and their accompanying veins, namely the cephalic vein, and is located within the intermuscular septum between the flexor carpi radialis and the brachioradialis muscles. Whenever an innervated segment (Sensate flap) is required, the Lateral and Medial antebrachial cutaneous nerves (LABC and MABC, respectively) could be located proximally in the antecubital fossa, and trace distally as they enter the flap segment (35). If osseous component is required, a 10–12-centimeter segment of the radial bone, with up to one-third of its circumference may be harvested. The radial bone receives blood supply through branches of the radial artery that passes through the flexor pollicis longus muscle. For this reason, whenever an osteocutaneous flap is required, some part of the muscle must be harvested as well to ensure circulation to the bony segment (35).



*Figure 2. Radial Forearm Flap anatomy.
Adapted from (36)*

Indications:

Some of the indications for RFFF include intraoral reconstruction, nasal reconstruction, general sensate reconstruction, upper limb reconstruction, penile reconstruction, mandibular reconstruction, lower limb reconstruction, ear reconstruction, pharyngoesophageal reconstruction, and burn scar release.

Procedure:

Before the operation the surgeon must ensure the extremity has enough collateral circulation to allow harvesting of RFFF with the radial artery. This is done using the Allen test. When looking at collateral circulation of the distal upper extremity two arterial branches must be taken into consideration, the superficial and deep palmar branches, arising from both the radial and ulnar arteries. The deep palmar branch receives most of its blood supply from the radial artery, however the contribution from the ulnar artery is sufficient in more than 97% of the time to supply the arm (37). Preoperatively the test can be performed using the clinician's hands or Doppler probe, and intraoperatively using Ackland microvascular clamp and a Doppler probe to confirm preoperative Allen test prior to ligating the radial artery (38). A positive test means the patient has enough collateral circulation and the radial artery may be harvested. A negative test excludes that, and it is a contraindication for RFFF harvest (38). The surgery is performed under general anesthesia. The patient is prepared, the correct arm is marked and placed in a 90-degree angle from the patient's body, and a tourniquet is placed (33). Typically, the dissection begins distally. The distal border is incised down to the deep fascia, and the radial artery is identified between the tendons of the brachioradialis and flexor carpi radialis muscles. The flap is elevated in an ulnar to radial direction in the subdermal plane. While doing that the surgeon must identify the cephalic vein, which is included in the flap, and the superficial branch of the radial nerve, which needs to be preserved to avoid numbness in that area (33). The radial artery is dissected up to its origin in the brachial artery. When ready to be transferred, the vessels are ligated and divided, and the flap is elevated along with its pedicle. At this point the tourniquet is removed, and hemostasis is achieved. The distal donor site, from which the skin paddle itself was harvested, is closed using a split-thickness skin graft from the thigh, while the proximal end is sutured after drain placement, and finally the arm is covered and placed in a volar arm splint with the wrist in 45-degree angle (33).

Postoperative complications:

Donor site complications can be divided into aesthetic or functional and can range from incomplete or delayed healing of the skin graft, sensory deficits in the distribution of superficial branches of the radial artery, or hand stiffness (33). According to a retrospective study performed on 100 patients, delayed healing of skin graft was reported in around 20% of cases. Sensation was reduced in around 24%. 28% complained of poor aesthetic result, and functional impairment in 16%-36%, depending on the type of flap being harvested (39).

2.3.3. Fibula Free Flap

First describe by Taylor et al. in 1975 (40), Fibula free flap (FFF) as a vascularized bone graft, had been used by reconstructive surgeons for years as viable method of reconstruction of bony defect, in particularly the mandible. It was later, in 1992 that Chuan et al. described the osteomyocutaneous composite flap in functional reconstruction of the upper limb (41). Among the many way FFF can be deployed, the free vascularized fibular flap is unique in the way that it provides immediate mechanical support but can also reshape and grow according to the patient's situation (42). Today FFF is used as a reliable method for bony reconstruction following trauma, tumor resection, infections as well as other indications.

Anatomy:

The fibula is a long a straight bone measuring between 35-40 cm in length and around 2.5 cm in width. Its blood supply is derived mainly from the peroneal artery and accompanying veins. To supply the fibula, the peroneal artery divides into the dominant nutrient artery, that enters the fibula through the nutrient foramen, divides into the long descending and short ascending branches, and provides endosteal supply, and minor periosteal and muscular branches to provide periosteal supply (43). Perforators which passes through

the thin posterolateral crural septum separating the soleus and peroneus longus and brevis muscles in the middle third of the leg and the flexor hallucis longus, which together with soleus can be incorporated as an osteomyocutaneous flap, and peroneal muscles in the distal third of the leg, provide blood supply to a skin paddle that is situated at the lateral aspect of the middle and distal thirds of the lower leg, which can be incorporated as an osteocutaneous flap (44). The lateral sural nerve supply most of the sensory innervation to the lateral calf skin territory, and can be incorporated into the flap, although not routinely performed (43).

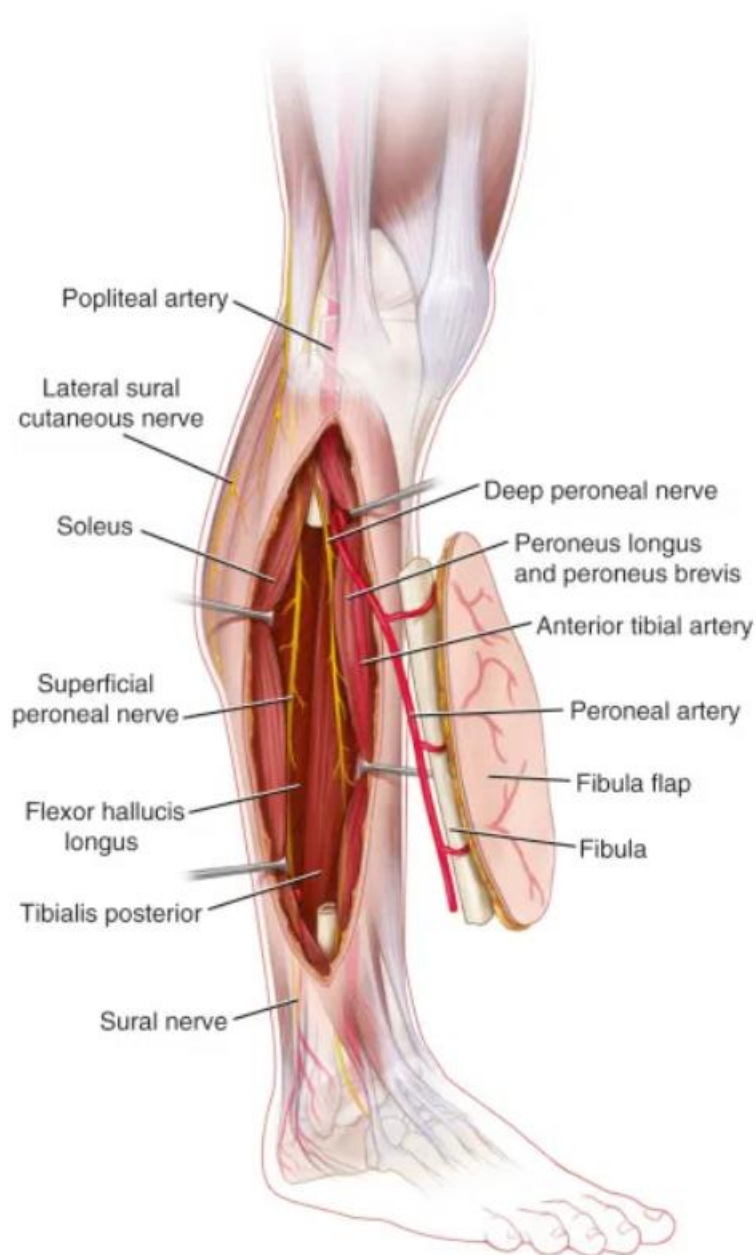


Figure 3. Fibula Free Flap anatomy. Adapted from (43)

Indications:

Some of the indications for FFF includes mandibular reconstruction, traumatic bony defects >6cm in length, bony defects after tumor surgery, resistant pseudarthrosis, limb length discrepancy, chronic osteomyelitis with bone loss, vascularized epiphyseal transfer (for growing child following tumor resection), osteonecrosis of the head of humerus/femur (45).

Procedure:

Preoperatively the vascular status of the lower leg where the flap is planned to be harvested from needs to be evaluated. The dorsalis pedis and posterior tibial arteries should be palpated and have strong pulses. In case there is suspicion regarding their quality, Doppler ultrasonography could be employed, as peripheral artery disease is a contraindication to flap harvest (46). Neurological assessment should also take place preoperatively since postoperative peroneal nerve palsy could occur (45). Peroneal artery assessment using angiography might be necessary to detect anomalies such as peroneal arteria magna, where one or both tibial arteries is hypoplastic, making the peroneal artery is the sole supplier of the foot, thereby harvesting it could result in foot ischemia (47). The surgery is performed under general anesthesia with a tourniquet over the lower leg, the recipient site prepared, the donor site is marked according to the indication, and the patient is positioned with the lower leg in internal rotation to allow access to the operation site. Initially, Taylor et al. in 1975 described the harvest of FFF in a posterior approach (40). However, it was Gilbert in 1979 who described the lateral approach, which proved to be simpler and faster (48). The surgeons make a longitudinal incision along the lateral lower leg. Dissection is carried out following the fascial planes separating the peroneal muscles, soleus, peroneus longus and brevis, and the rest of the muscles of the fascial compartments of the lower leg, from the bones (44). The central portion of the

fibula is most harvested as the distal 5 cm is important for ankle stability and the proximal 5 cm is usually avoided due to potential damaging of the peroneal nerve (45). Distal osteotomy is taken place using oscillating saw and lateral traction is applied to the fibula which usually exposes the peroneal vessels (44). When arriving at the posterior compartment, the tibialis posterior muscle is carefully dissected and separated from the vascular pedicle in a distal-to-proximal fashion for approximately 5 cm, while more proximal dissection could take place only after the proximal osteotomy (44). Proximal osteotomy should be preformed very carefully as the peroneal vessels lie posteriorly to the fibula. After both osteotomies and the rest of the muscle fibers are separated from the bone, the tourniquet is deflated perfusion of the fibula and skin pedicle should be observed. Then the tourniquet is reinflated, and the vascular pedicle is ligated to allow flap transfer to the recipient site (44). Pedicle length can vary between 2-6 cm depending on the surgical indication and the length of bone being harvested. Closure is preformed after placing a suction tube and a split-thickness skin graft. Fixation of the flap could be done by using different hardware, such as intramedullary nails or compression plates, depending on the type of reconstruction (45).

Postoperative complications:

Although the use of FFF has been proved as a reliable method, postoperative complications are not uncommon. Graft fracture was the most common reported complication. According to some studies, the use of fibular flap for large bony defects resulted in tibial stress fracture and femoral stress fracture in 35% and 32% of the patients, respectively (49). A prospective cohort following 157 patients (50) reported perioperative donor site complications in 31.2% of patients, some of which are skin graft loss (15%), cellulitis (10%), and wound dehiscence (8%). The same study reported long term complications in 17% of patients, including leg weakness (8%), ankle instability (4%), great toe contracture (9%), and decreased ankle mobility (12%), although functionally, 96% of patients returned to their preoperative ambulatory level (50).

2.3.4. Latissimus Dorsi Flap

The Latissimus Dorsi flap (LDF), as a pedicled or free flap is one of the most used flaps in reconstructive surgery. First described by Iginio Tansini in 1906 for the coverage of mastectomy defects (51) but later forgotten until the 1970's when Olivari re-described it for the use of large radiation ulcers of the chest wall (52). In 1978, Boswick was first to describe the use of LDF for breast reconstruction following radical mastectomy (53). The use of LDF and a free flap was then described by Maxwell in the same year (54). Today, LDF is used as a myocutaneous flap with many head, neck, and torso applications and can provide large amount of pliable soft tissue for versatile reconstructive indications.

Anatomy:

The Latissimus dorsi is a broad back muscle and one of the largest and strongest in the human body. It originates as a broad aponeurosis from the spinous processes of the lower thoracic, lumbar, and spinal vertebrae, as well as the posterior outer rim of the iliac crest. The superior medial portion is covered by the trapezius muscle, otherwise the rest of the muscle is situated subcutaneously and superficial to all other muscles in the back (55). It covers a portion of the paraspinal muscle and most of the serratus anterior muscle. In the middle portion it has tight attachment to the 10th, 11th, and 12th ribs, and its fiber interdigitate with that of the serratus anterior. Superiorly, its fiber run under that of the teres major and its inserts to the lesser tubercle of the humerus and the medial lip of the intertubercular groove in a spiral fashion (55). It primarily acts as an extender, adductor, and medial rotator of the humerus. LDF pedicle is composed of the thoracodorsal artery (TDA) and vein as well as minor perforating branches of the posterior intercostal arteries (56). The TDA arises from the subscapular artery, which originates from the axillary artery, courses anteriorly to the muscle and enters it from underneath, approximately 4 cm distal to the inferior scapular border and 2.5 cm lateral to the medial border of the latissimus dorsi muscle (55). The TDA measures 6-

12 cm and 3mm in diameter in a normal man. Inside the muscle it divided into 2 main branches, the horizontal and descending branches, which parallel the superior and lateral border of the muscle. These branches form anastomoses with large diameter with each other and with the intercostal perforators and give off 4-7 cutaneous perforator branches through the muscle (55). It is important to note that variation in the thoracodorsal artery exist between individual as well as certain anomalies (57). LDF receives motor innervation from the thoracodorsal nerve, which arises from the brachial plexus. Sensory innervation from the posterior branches of the lateral cutaneous branches of the intercostal nerves to provide cutaneous sensibility laterally, and lateral branches of the posterior rami (VI through XII) posteriorly, not routinely used to reinnervate the flap (55).

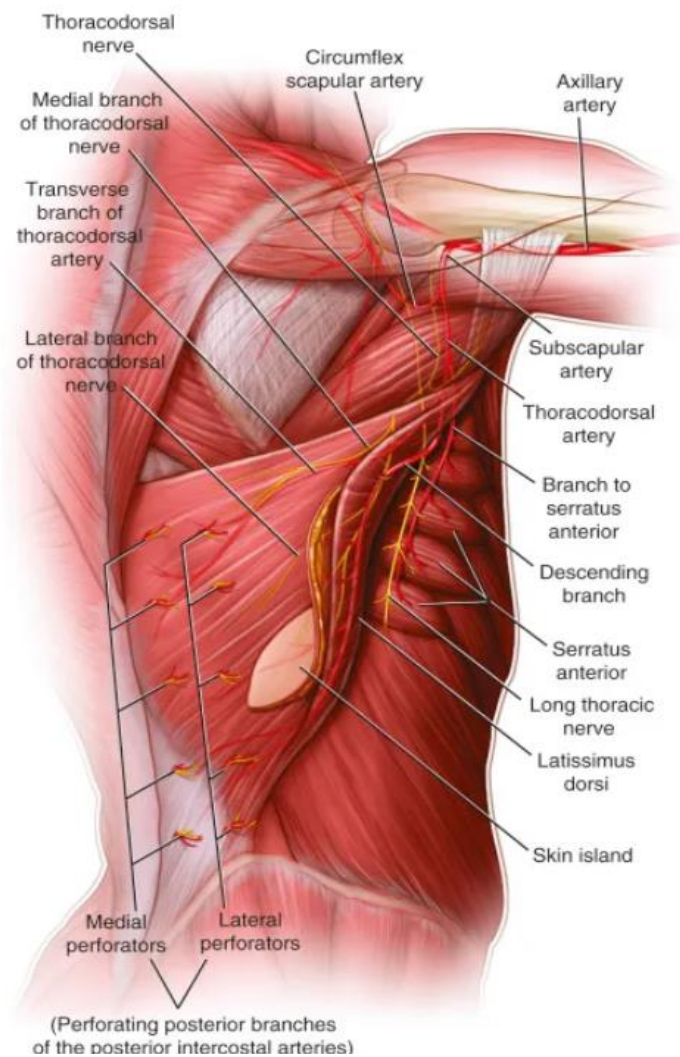


Figure 4. Latissimus Dorsi flap anatomy. Adapted from (55)

Indications:

LDF is indicated whenever a large defect the requires a broad soft tissue coverage, especially in the head, neck, and chest. It can be used as a pedicled flap in breast reconstruction (TDAP), as well as upper limbs or other thorax and back defects. In the field of microsurgery, it is used as a free flap especially in head and neck area for intraoral lesions, facial reanimation, or other defects, as well as in reconstruction of the upper limbs below the elbow, lower limbs, and abdominal wall defects (56).

Procedure:

Besides routine preoperative assessment of the patient condition, in the case of LDF, no preoperative imaging for vessels assessment at the donor site is required. However, blood loss can be significant so matched blood should be prepared in case of transfusion requirement (58). The marking of the flap design or also preformed preoperatively. While in the operating room the patient is placed in a lateral decubitus position to allow access to the operating site. An initial incision is carried just inferior to the mid-axillary line down to the anterior superior iliac crest. The dissection is proceeded deeply until the lateral edge of the latissimus is identified (58). Blunt dissection is continued along the surface of the muscle, with skin perforator ligated and divided in case of a muscle flap or left as part of the flap in case of a myocutaneous flap (56). Muscle fibers of different back muscles and that of the serratus anterior must be separated from that of the latissimus during dissection. Whether a skin paddle is required as part of a myocutaneous flap, it is included while dissecting medially along with its perforators. If skin paddle is not needed, it can be separated from the surface of the muscle using electrocautery (58). The fascial origin is incised from the iliac crest and thoracic vertebrae and the muscle is elevated to expose the deep surface. The vascular pedicle is identified, isolated, and collateral vessels are ligated and divided, except of the branch to the serratus anterior which should be left until the end to prevent involuntary traction of the pedicle (56). The needed amount of muscle is harvested, and the humeral insertion site is identified, separated from the teres major, and divided from the humerus. The vascular

pedicle is dissected until the desired length is achieved, and the flap is ready to be transferred to its new location. Direct closure of the donor site can be done with flaps up to 8 cm in width, however larger flap may require the use of skin graft (56).

Postoperative complications:

The most common donor site complication associated with LDF harvesting is seroma formation even with appropriate drainage placement. Hypertrophic scar and volume deficit may also occur at the donor site, as well as hematoma formation and chronic back pain (60).

2.3.5. Anterolateral Thigh Flap

First described by Song et al. in 1984 (61), the ALT has proved as a versatile and reliable reconstructive method in the realm of microvascular surgery. It gained its popularity especially in Asia where it replaced the use of RFFF for head and neck reconstructions (62). Today it is used as cutaneous, fasciocutaneous, and myocutaneous flap for various reconstructive indications.

Anatomy:

Blood supply to the ALT derived from the descending branch of the lateral femoral circumflex artery (LFCA). The LFCA arises from the femoral artery and give rise to the ascending, transverse, and descending branches. The descending branch runs deep to rectus femoris and sartorius muscles and descends medial to the vastus lateralis muscle giving off branches to supply the muscle. It continues to course in the intermuscular septum between the vastus lateralis and the rectus femoris muscle while giving off perforators to supply overlying skin. Some of these perforators pierce through the vastus lateralis which may be included as part of a myocutaneous flap. Two veins accompany the descending branch and its perforators and are included as part of the flap pedicle. Variations do exist in the origin and course of the

LFCA and its branches but if the surgeon keep to the principle of flap harvesting, including careful retrograde vessel dissection, it has little to no clinical significant (62). Sensory innervation to the skin of the ALT is derived from the lateral femoral cutaneous nerve (63).

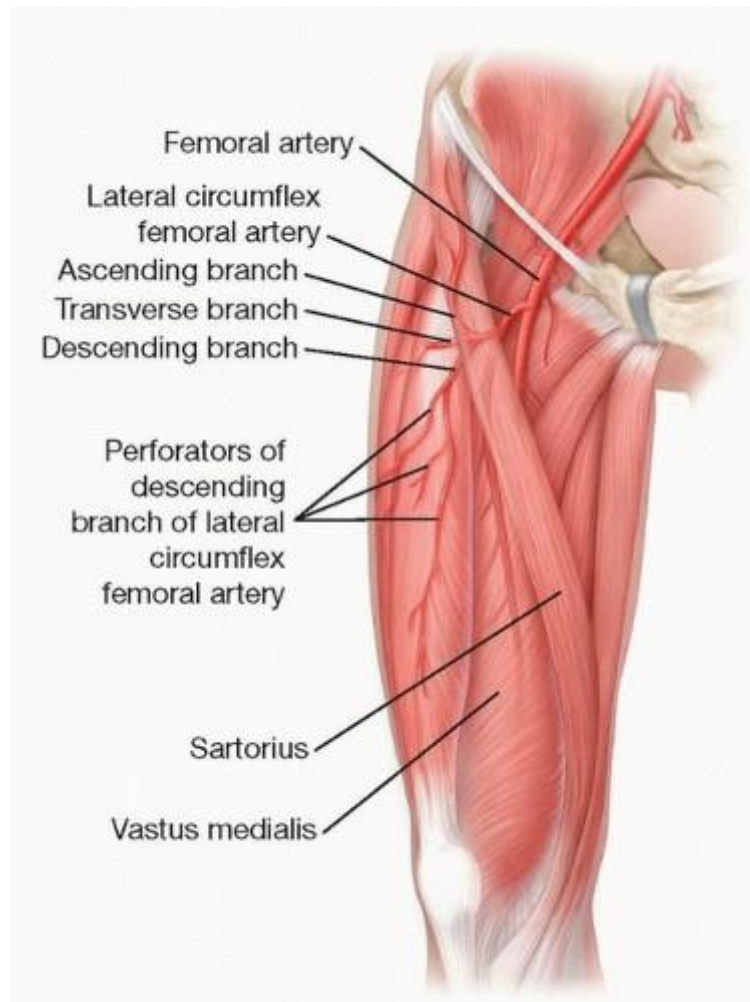


Figure 5. Anterolateral Thigh flap anatomy. Adapted from (63)

Indications:

There are various clinical applications for the ALT. It is mainly used in the reconstruction of head and neck region, namely for pharyngeal and esophageal reconstruction, craniofacial defect, and floor of the mouth repair. It is also used in reconstructions of the breast, upper and lower extremities, and genital area (62).

Procedure:

Preoperative identification and assessment of the perforators and vascular pedicle is required using Doppler ultrasonography. In the operation room the patient is placed in a supine position with his leg secured so it will not move during the operation. Markings are made according to the flap design and a line is drawn from the ASIS down to the lateral border of the patella. In most cases, most important perforators will be located at the center of this line (62). Dissection of the flap is straight-forward and can be performed in the suprafascial or subfascial planes. With the suprafascial approach identifying the perforators and dissection is somewhat more challenging, however, it has the advantage of allowing thinner flap and avoids muscle herniation. Dissection in the subfascial plane results in a thicker flap but identifying and dissecting the perforators are easier (62). The graft is retracted and the intermuscular septum between the rectus femoris and vastus lateralis is separated using blunt dissection. The rectus femoris is retracted medially, exposing the descending branch of the LFCA in the intermuscular plane along the medial border of the vastus lateralis. Perforators are dissected in a retrograde fashion down to the descending branch. The vascular pedicle composed of the descending branch and its perforator is dissected and raised. If myocutaneous flap is desired, perforators to, and thin segment of the vastus lateralis should be harvested. The flap design is finalized, and the flap can be raised to be moved to its desired location (64). Closure of donor site can be preformed by primary closure or skin grafting depending on the flap dimensions (62).

Postoperative complications:

Systematic review, identifying 42 articles, described donor site complications associated with ALT. The most common complication was lateral thigh paresthesia, which occurred in 24% of patients. Other complications include musculoskeletal dysfunction, hypertrophic scarring or wound dehiscence, donor site pain, seroma, and hematoma. Very few (0.09%) experienced partial muscle necrosis and compartment syndrome (65).

2.3.6. Scapular and Parascapular Flaps

The scapular flap was first described by dos Santos (66) and the Parascapular flap by Nasif et al. (67) are versatile methods in reconstructive surgery. Based on branches from the subscapular artery, these flaps can incorporate skin, fascia, bone, or combination of all, and can be used in combination of other flaps, for example the latissimus dorsi flap (68). The scapular flap is widely used today primarily for reconstruction of facial area, among other uses.

Anatomy

The subscapular artery, a branch of the axillary artery, divides into the circumflex scapular artery (CSA) and the thoracodorsal artery (TDA). The CSA travels through a triangular space formed by the triceps muscle laterally, teres minor superiorly, and the teres major inferiorly, divides into the horizontal and descending branch to supply the scapular and parascapular fasciocutaneous flaps, respectively. It gives off branches to the teres minor and major muscles, the subscapularis muscle, cutaneous branches to the skin, and the lateral border of the scapular bone which anastomose with a branch of the TDA at the tip of the scapula. The TDA supplies the latissimus dorsi and serratus anterior muscles. It is also the main supply to the tip of the scapula which can be used as part of osteocutaneous flap. The variable blood supply to the lateral border of the scapula by the CSA and the tip by the TDA, allow the harvesting of separated vascularized bone segments to be included in the flap (69). Variations do exist and both the CSA and TDA can arise directly from the axillary artery in some cases (70). Two venae accompany the CSA, are present in the vascular pedicle, and ultimately drain to the axillary vein. Sensory innervation to the flap region is through the posterior and lateral branches of the third, fourth, and fifth intercostal nerves. Since there is no single large nerve that supplies the region, it is not used as a sensate flap, however, when used for facial reconstruction it regains fair amount of sensation without any special nervous connections (71).

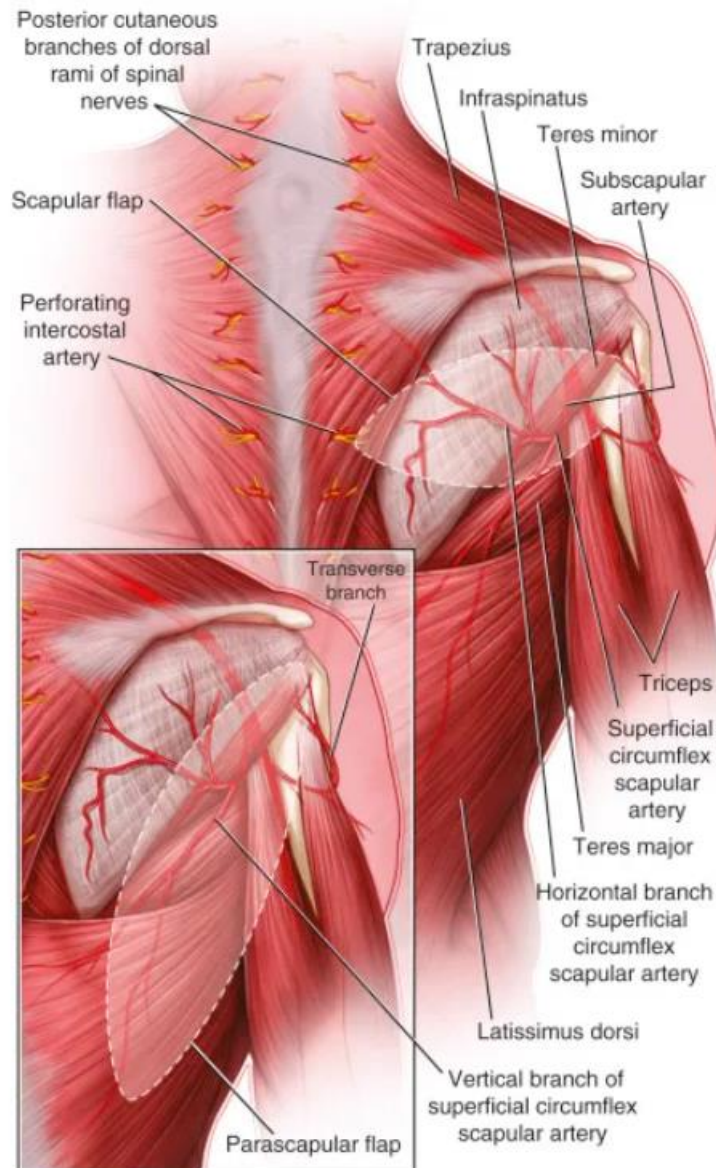


Figure 6. Scapular and parascapular flaps anatomy. Adapted from (71)

Indications:

The versatility of the scapular and parascapular flaps, and the different tissue that can be incorporated into them, make them the flap of choice in complex, multidimensional reconstructions especially in the head, neck, and facial areas (69). They can be used in bony reconstructions of the orbit, face, skull base, and mandible, as well in soft tissue reconstructions in cases of facial asymmetry or atrophy, as in cases of Treacher Collins syndrome or Parry-

Romberg syndrome. They are also used in upper or lower extremities reconstruction with or without bone (69).

Procedure:

Besides assessing the patient's general clinical condition prior to surgery, no special preoperative studies are required (71). The patient should be positioned and secured in a lateral decubitus position with their arm abducted. The triangular space and tip of the scapula should be palpated, and skin paddle drawn according to desired flap design. The skin paddle is centered over the triangular space with the scapular flap oriented horizontally, along the axis of the horizontal branch of CSA, while the parascapular oriented obliquely, along the axis of the descending branch (69). Incision is made over the triangular space through the skin and subcutaneous tissue. The triceps, teres minor and major, are identified and retracted to expose the CSA and accompanying veins. Incision is carried to the dorsal thoracic fascia and the flap is isolated on its vascular pedicle. Branches to the teres minor, major and infrascapular muscles are divided as proximal pedicle dissection is carried to junction with the TDA. These branches may be preserved if muscular component is desired with the flap. Vascularized bone segments may be included and depending on which part of the scapula is harvested may include periosteal branched from the CSA, if lateral segment is included, or branches of the TDA, if tip of scapula is included, or combination of both (69). After flap elevation, donor site may be closed directly or using a skin graft, depending on the size of the defect. If bone is included, reattachment of the teres major may be necessary (69).

Postoperative complications:

Scapular and parascapular flaps are associated with less complication when compared with other free flap. However, although rare, some of these may include seroma, hematoma, infection, unfavorable scar, and limited shoulder and upper limb function following operation (72).

2.3.7. Rectus Abdominis Flaps

Since its introduction in 1975 by Brown et al. (73), Rectus abdominis flap and its variants became one of the most used flaps in various reconstructive indications, especially in microsurgical breast reconstruction in breast cancer patients. It may be transferred as a muscular, myocutaneous, or fasciocutaneous flap (74). It was in 1979 when Holmström described the free transverse abdominis myocutaneous (TRAM) flap (75), which over time evolved to include the muscle-sparing (MS) TRAM and the deep inferior epigastric perforator (DIEP) flap, which are commonly used today for these indications, and minimize donor site morbidity by reducing the amount of fascia and muscle harvested.

Anatomy:

The Rectus abdominis are pair of muscles originating from the pubic symphysis and inserting on the linea alba at the costal cartilage of the fifth, sixth, and seventh ribs. Each muscle is enclosed by the rectus sheath, which forms fascial isolation and is composed of the aponeuroses of the abdominal wall muscles. The rectus muscle is supplied by 2 dominant pedicles. Superiorly by the deep superior epigastric artery (DSEA), a branch of the internal mammary artery, and by the deep inferior epigastric artery (DIEA), a branch of the external iliac artery, and their accompany veins.

These vessels form intramuscular anastomosis with each other and send perforators through the muscle to supply the overlying skin (74). The flap receives motor and sensory innervation from T7-T12 intercostal nerves.

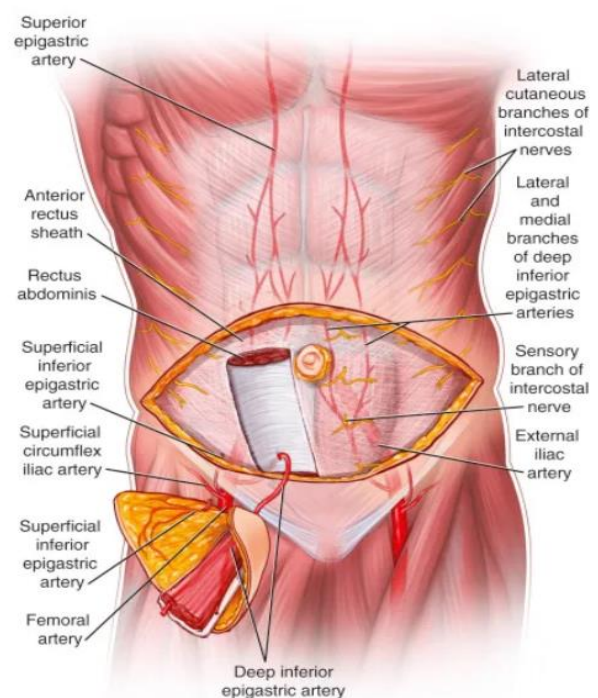


Figure 7. Rectus abdominis flap anatomy. Adapted from (74)

Indications:

Thanks to its versatility, convenient position, and reliable vascular supply, rectus abdominis flap and its variant are used in various reconstructive indications. As already stated, these flaps are used extensively in breast reconstructions. They are also used for head and neck defects, after total glossectomy and skull-base defects for example, and upper and lower extremities defects (76).

Procedure:

Preoperative assessment of a patient going rectus abdominis flap harvest is crucial, especially physical examination of the abdominal wall. Abdominal examination should pay close attention to locating any abdominal scars as they may indicate damage to the vascular pedicle. Any suspicion to damage to the vascular pedicle should be investigated using Doppler ultrasonography (74). Surgical technique varies according to which type of flap is selected, whether it is TRAM, MS-TRAM, or DIEP. The decision on which flap to choose is dependent on the quality and location of the perforators (77). For this type of operation, the patient should be placed in a supine position. All flap harvests are done under loupe magnification. First the skin island is incised down to the rectus sheath fascia, and the superficial inferior epigastric artery and vein are identified, dissected, and preserved. If TRAM or MS-TRAM flap is desired, the transverse, ellipse shaped, skin island is dissected off the rectus sheath from lateral to medial until the lateral row of perforators from the DIEA are seen, on the side of chosen pedicle. Dissection proceeds in a similar manner in the side contralateral to the chosen pedicle side, until the lateral perforators are encountered, only here the lateral row of perforators are clipped and divided, and the flap is elevated to expose the medial row of perforators (77). A fascia-sparing technique is used to open the rectus sheath fascia to expose the underlying rectus abdominis muscle. The rectus sheath is then divided from the underlying muscle in its lateral and medial border and the rectus abdominis is carefully dissected inferiorly to expose the DIEA. With the vascular pedicle identified and isolated, the muscle attachment at the pubic symphysis is detached to allow for the dissection of the pedicle. Dissection of

the pedicle proceeds until sufficient length is achieved. Various amount of muscle may be included in the flap by dividing it at the border of the perforators, depending on the choice between TRAM or MS-TRAM, with the latter, only small amount of muscle will be included around the perforators (77). The deep inferior epigastric pedicle is left intact until the recipient site is prepared. Upon completion of the recipient site, the pedicle is ligated, and the flap is ready to be transferred. If the perforator vessels alone are harvested, the flap is referred to as a DIEP flap, sparing the entire rectus abdominis muscle, potentially reducing donor-site morbidity (77). Depending on the extent of fascia harvested, it can be closed primarily or using a mesh (76). Nonetheless, meticulous closure of the donor site is required to prevent weakening of the abdominal wall (77).

Postoperative complications:

Besides usual donor site complications associated with tissue harvesting such as infections and seroma formation, rectus abdominis flap harvesting is associated with abdominal hernia, the risk of which can be minimized using tension-free closure and depends on the extent of fascia being sacrificed (78).

3. Conclusion

Since its introduction in the 20th century, microvascular surgery has revolutionized the field of reconstructive surgery, through its role in collaboration with virtually every field in medicine, it changed the way of managing complex oncologic patients, patients with complex trauma, or patients with congenital anomalies, offering new solutions for addressing complex defects and enhancing patient outcome.

Microvascular surgery had and still going through never-ending evolution, driven by advancements in technology, refined surgical techniques, and a deeper understanding of vascular anatomy. Creativity and the desire to constantly improve methods and outcome is what driven main characters in the field to find new ways, design new flap options, to develop the practice.

Free flaps, the cornerstone of microvascular surgery, represent the ingenuity of the great minds behind the field. Today, microvascular surgeons have the freedom the select different flap designs from various locations of the body, based on their preferences, creativity, and surgical expertise.

Microvascular surgery represents one of the most delicate, precise, and technically challenging surgical fields, and its great roles and methods go beyond the scope of this thesis. Here, we went through some of the methods, techniques, and reconstructive options that a microvascular surgeon possess. However, the field is so vast and going through continuous development, that it would take much more than what is written here to fully comprehend its complexion.

4. Acknowledgments

I would like to thank my mentor who supported and guided me through the process of writing this thesis.

I would also like to thank my parents and family for their support during the past 6 years, whom without, it wouldn't be the same.

5. References

1. Mavrogenis, A.F., Markatos, K., Saranteas, T. *et al.* The history of microsurgery. *Eur J Orthop Surg Traumatol* 29, 247–254 (2019). <https://doi.org/10.1007/s00590-019-02378-7>
2. Russell J. Corlett IS (2015). The Microvascular Anastomosis. In M. N. J. Brian Boyd, *Operative Microsurgery* (p.3-6). Mc Graw Hill Education.
3. Fang F, Chung KC. An evolutionary perspective on the history of flap reconstruction in the upper extremity. *Hand Clin.* 2014 May;30(2):109-22, v. doi: 10.1016/j.hcl.2013.12.001. Epub 2014 Feb 24. PMID: 24731604; PMCID: PMC4160825.
4. Ma L, Fei B. Comprehensive review of surgical microscopes: technology development and medical applications. *J Biomed Opt.* 2021 Jan;26(1):010901. doi: 10.1117/1.JBO.26.1.010901. PMID: 33398948; PMCID: PMC7780882.
5. Carolina Martis, A. L. (2003). Microneurosurgery. In R. B. Michael J. Aminoff, *Encyclopedia of the Neurological Sciences* (p. 145-150). Academic .Press
6. Shuhaiber JH. Augmented reality in surgery. *Arch Surg.* 2004 Feb;139(2):170-4. doi: 10.1001/archsurg.139.2.170. PMID: 14769575.
7. J. Garcia Giraldez, H. Talib, M. Caversaccio, M. A. Gonzalez Ballester, "Multimodal augmented reality system for surgical microscopy," *Proc. SPIE* 6141, *Medical Imaging 2006: Visualization, Image-Guided Procedures, and Display*, 61411S (13 March 2006); <https://doi.org/10.1117/12.651267>
8. Biemer WD (1982). Technical equipment. In *Reconstructive Microvascular .Surgery* (p.10). Springer-Verlag
9. Acland RD (2008). *Acland's Practice Manual for Microvascular Surgrey* third edition. Indian Society for Surgery of the Hand.
10. MacDonald JD. Learning to perform microvascular anastomosis. *Skull Base.* 2005 Aug;15(3):229-40. doi: 10.1055/s-2005-872598. PMID: 16175232; PMCID: PMC1214708
11. Biemer WD. (1982). Suture Technique in Microvascular Surgery. In *Reconstructive Microvascular Surgery* (p.17). Springer-Verlag

12. Siemionow MZ, Zor F. Microsurgical Techniques in Reconstructive Surgery. In Plastic and Reconstructive Surgery (p. 3-9). Springer-Verlag London 2015
13. Morris DJ, Pribaz JJ. The interrupted-continuous microsurgical suture technique. *Microsurgery*. 1992;13(2):103-5. doi: 10.1002/micr.1920130211. PMID: 1569880.
14. Barros RSM, Leal RA, Teixeira RKC, Yamaki VN, Feijó DH, Gouveia EHH, Valente AL, Silva DJ Feitosa-Junior, Carvalho LTF. Continuous versus interrupted suture technique in microvascular anastomosis in rats. *Acta Cir Bras*. 2017 Sep;32(9):691-696. doi: 10.1590/s0102-865020170090000001. PMID: 29019586.
15. Moritz WR, Raman S, Pessin S, Martin C, Li X, Westman A, Sacks JM. The History and Innovations of Blood Vessel Anastomosis. *Bioengineering (Basel)*. 2022 Feb 15;9(2):75. doi: 10.3390/bioengineering9020075. PMID: 35200428; PMCID: PMC8869402.
16. Ahmadi I, Herle P, Miller G, Hunter-Smith DJ, Leong J, Rozen WM. End-to-End versus End-to-Side Microvascular Anastomosis: A Meta-analysis of Free Flap Outcomes. *J Reconstr Microsurg*. 2017 Jul;33(6):402-411. doi: 10.1055/s-0037-1599099. Epub 2017 Mar 4. PMID: 28259112.
17. Staudacher, M.. (2004). Die erste autologe Venentransplantation von .Erich Lexer (1907). *Gefässchirurgie*. 9. 64-67. 10.1007/s00772-003-0329-9
18. Cepas, Adas MD1,2; Kiiski, Juha MD, PhD1; Majava, Marja MD, PhD1; Kholová, Ivana MD, PhD3; Kaartinen, Ilkka MD, PhD1. Myth-busting the zone of injury concept: a prospective study on the vascular response to high-energy lower extremity trauma. *Plastic and Reconstructive Surgery* (2023) 136(2):402-411. doi:10.1097/PRS.00000000000010980, August 10, 2023. | DOI: 10.1097/PRS.00000000000010980
19. Yu JL, Tolley PD, Kneib C, Miller EA, Crowe CS. Current concepts in microsurgical soft tissue reconstruction of lower extremity trauma in a single-vessel extremity. *Plast Aesthet Res* 2022;9:37. <http://dx.doi.org/10.20517/2347-9264.2021.124>
20. Jonas A. Nelson, John P. Fischer, Ritwik Grover, Stephen J. Kovach, David W. Low, Suhail K. Kanchwala, L. Scott Levin, Joseph M. Serletti, Liza C. Wu. Vein grafting your way out of trouble: Examining the utility and efficacy of vein grafts in microsurgery. *Journal of Plastic, Reconstructive & Aesthetic Surgery*. Volume 68, Issue 6. 2015. ISSN 1748-6815. <https://doi.org/10.1016/j.bjps.2015.02.008>
21. C J Zeebregts, R H Heijmen, J J van den Dungen, R van Schilfgaarde, Non-suture methods of vascular anastomosis, *British Journal of Surgery*, Volume 90, Issue 3, March 2003, Pages 261–271, <https://doi.org/10.1002/bjs.4063>

22. Khatri N, Zhang S, Kale SS. Current Techniques for Postoperative Monitoring of Microvascular Free Flaps. *J Wound Ostomy Continence Nurs.* 2017 Mar/Apr;44(2):148-152. doi: 10.1097/WON.0000000000000314. PMID: 28267121.
23. Chen KT, Mardini S, Chuang DC, Lin CH, Cheng MH, Lin YT, Huang WC, Tsao CK, Wei FC. Timing of presentation of the first signs of vascular compromise dictates the salvage outcome of free flap transfers. *Plast Reconstr Surg.* 2007 Jul;120(1):187-195. doi: 10.1097/01.prs.0000264077.07779.50. PMID: 17572562.
24. Knoedler S, Hoch CC, Huelsboemer L, Knoedler L, Stögner VA, Pomahac B, Kauke-Navarro M, Colen D. Postoperative free flap monitoring in reconstructive surgery-man or machine? *Front Surg.* 2023 Feb 22;10:1130566. doi: 10.3389/fsurg.2023.1130566. PMID: 36911625; PMCID: PMC9992807.
25. Teven, Chad M. MD; Pflibsen, Lacey R. MD; Rebecca, Alanna M. MD, MBA; Lettieri, Salvatore C. MD. A Subtle Clinical Finding in Free Tissue Transfer: The Blood Hammer Phenomenon. *Plastic and Reconstructive Surgery - Global Open* 8(8):p e3062, August 2020. | DOI: 10.1097/GOX.00000000000003062
26. Hallock GG. Acoustic Doppler sonography, color duplex ultrasound, and laser Doppler flowmetry as tools for successful autologous breast reconstruction. *Clin Plast Surg.* 2011 Apr;38(2):203-11. doi: 10.1016/j.cps.2011.03.001. PMID: 21620145.
27. Ives A, Taylor GI. (2015). The Angiosome concept. In M. N. J. Brian Boyd, *Operative Microsurgery* (p.7-27). Mc Graw Hill Education.
28. Blondeel P. (2015). Principles of Free Flap Design and Elevation. In M. N. J. Brian Boyd, *Operative Microsurgery* (p.28-38). Mc Graw Hill Education.
29. Mijatović D. (2022). Plastic, reconstructive and cosmetic surgery. In Mijatović D, Augustin G, Dobrić I, Sultić Ž, *Surgery. školska knjiga.*
30. Chang C, Wong C, Wei F. Free-style free flap. 2008. ISSN 0020-1383. DOI: <https://doi.org/10.1016/j.injury.2008.05.020>. (<https://www.sciencedirect.com/science/article/pii/S0020138308002593>)
31. Hallock GG. Branch-based conjoined perforator flaps. *Plast Reconstr Surg.* 2008 May;121(5):1642-1649. doi: 10.1097/PRS.0b013e31816aa022. PMID: 18453988.
32. Yang GF, Chen PJ, Gao YZ, Liu XY, Li J, Jiang SX, He SP. Forearm free skin flap transplantation: a report of 56 cases. 1981. *Br J Plast Surg.* 1997 Apr;50(3):162-5. doi: 10.1016/s0007-1226(97)91363-1. PMID: 9176001.
33. Rengifo D, Lian TT. Radial Forearm Tissue Transfer. [Updated 2023 Jul 10]. In: *StatPearls [Internet]. Treasure Island (FL): StatPearls Publishing; 2024 Jan-. Available from: <https://www.ncbi.nlm.nih.gov/books/NBK560796/>*

34. Giordano L, Bondi S, Ferrario F, Fabiano B, Bussi M. Radial forearm free flap surgery: a modified skin-closure technique improving donor-site aesthetic appearance. *Acta Otorhinolaryngol Ital.* 2012 Jun;32(3):158-63. PMID: 22767980; PMCID: PMC3385055.

35. Brian Boyd J. (2015). Radial Forearm Flaps. In M. N. J. Brian Boyd, *Operative Microsurgery* (p.200-207). Mc Graw Hill Education.

36. Themes, U. (2019, March 3). *Radial Forearm Flap*. Plastic Surgery Key [Internet]. <https://plasticsurgerykey.com/radial-forearm-flap/>

37. Patsalis T, Hoffmeister HE, Seboldt H. Arterielle Dominanz der Hand [Arterial dominance of the hand]. *Handchir Mikrochir Plast Chir.* 1997 Sep;29(5):247-50. German. PMID: 9424450.

38. Zisquit J, Velasquez J, Nedeff N. Allen Test. [Updated 2022 Sep 19]. In: StatPearls [Internet]. Treasure Island (FL): StatPearls Publishing; 2024 Jan-. Available from: <https://www.ncbi.nlm.nih.gov/books/NBK507816/>

39. Richardson D, Fisher SE, Vaughan ED, Brown JS. Radial forearm flap donor-site complications and morbidity: a prospective study. *Plast Reconstr Surg.* 1997 Jan;99(1):109-15. doi: 10.1097/00006534-199701000-00017. PMID: 8982193.

40. Taylor GI, Miller GD, Ham FJ. The free vascularized bone graft. A clinical extension of microvascular techniques. *Plast Reconstr Surg.* 1975 May;55(5):533-44. doi: 10.1097/00006534-197505000-00002. PMID: 1096183.

41. Chuang DC, Chen HC, Wei FC, Noordhoff MS. Compound functioning free muscle flap transplantation (lateral half of soleus, fibula, and skin flap). *Plast Reconstr Surg.* 1992 Feb;89(2):335-9. doi: 10.1097/00006534-199202000-00024. PMID: 1732905.

42. Beris AE, Lykissas MG, Korompilias AV, Vekris MD, Mitsionis GI, Malizos KN, Soucacos PN. Vascularized fibula transfer for lower limb reconstruction. *Microsurgery.* 2011 Mar;31(3):205-11. doi: 10.1002/micr.20841. Epub 2011 Feb 25. PMID: 21360586.

43. Themes, U. (2019, March 3). *Fibula Flap*. Plastic Surgery Key [Internet]. Retrieved February 25, 2024, from <https://plasticsurgerykey.com/fibula-flap-2/>

- 44.. Jones NF. (2015). Vascularized Fibular Bone Graft and Free Fibular Osteocutaneous Flap. In M. N. J. Brian Boyd, *Operative Microsurgery* (p.186-199). Mc Graw Hill Education.
45. Taqi M, Raju S. Fibula Free Flaps. [Updated 2022 Sep 26]. In: StatPearls [Internet]. Treasure Island (FL): StatPearls Publishing; 2024 Jan-. Available from: <https://www.ncbi.nlm.nih.gov/books/NBK564337/>
46. Bumbasirevic M, Stevanovic M, Bumbasirevic V, Lesic A, Atkinson HD. Free vascularised fibular grafts in orthopaedics. *Int Orthop*. 2014 Jun;38(6):1277-82. doi: 10.1007/s00264-014-2281-6. Epub 2014 Feb 22. PMID: 24562850; PMCID: PMC4037521.
47. Rahmel BB, Snow TM, Batstone MD. Fibular free flap with arteria peronea magna: the role of preoperative balloon occlusion. *J Reconstr Microsurg*. 2011 Mar;27(3):169-72. doi: 10.1055/s-0030-1270531. Epub 2011 Jan 18. PMID: 21246484.
48. Gilbert, A. (1979). Vascularized transfer of the fibular shaft. *Int J Microsurg*, 1(2), 100-102.
49. de Boer HH, Wood MB, Hermans J. Reconstruction of large skeletal defects by vascularized fibula transfer. Factors that influenced the outcome of union in 62 cases. *Int Orthop*. 1990;14(2):121-8. doi: 10.1007/BF00180115. PMID: 2373557.
50. Momoh AO, Yu P, Skoracki RJ, Liu S, Feng L, Hanasono MM. A prospective cohort study of fibula free flap donor-site morbidity in 157 consecutive patients. *Plast Reconstr Surg*. 2011 Sep;128(3):714-720. doi: 10.1097/PRS.0b013e318221dc2a. PMID: 21572380.
51. Tansini, I. (1906). Sopra il mio nuovo processo di amputazione della mammella. *Gazz Med Ital*, 57(57), 141.
52. Olivari N. The latissimus flap. *Br J Plast Surg*. 1976 Apr;29(2):126-8. doi: 10.1016/0007-1226(76)90036-9. PMID: 776304.
53. Bostwick J 3rd, Vasconez LO, Jurkiewicz MJ. Breast reconstruction after a radical mastectomy. *Plast Reconstr Surg*. 1978 May;61(5):682-93. doi: 10.1097/00006534-197805000-00004. PMID: 347475.
54. Maxwell GP, Stueber K, Hoopes JE. A free latissimus dorsi myocutaneous flap: case report. *Plast Reconstr Surg*. 1978 Sep;62(3):462-6. doi: 10.1097/00006534-197809000-00033. PMID: 358230.
55. Themes, U. (2019, March 3). *Latissimus Dorsi Flap*. Plastic Surgery Key [Internet]. <https://plasticsurgerykey.com/latissimus-dorsi-flap-2/>
56. Angrigiani C. (2015). Latissimus Dorsi Flaps. Flap. In M. N. J. Brian Boyd, *Operative Microsurgery* (p.111-123). Mc Graw Hill Education.

57. Cho HG, Kang B, Ryu JY, Choi KY, Yang JD, Chung HY, Cho BC, Lee J, Park HY, Lee JS. Anatomical View of Thoracodorsal Artery Variants Using Computed Tomography Angiography. *J Reconstr Microsurg*. 2023 Oct;39(8):640-647. doi: 10.1055/a-2040-1651. Epub 2023 Feb 21. PMID: 36809783.
58. Vincent A, Hohman MH. Latissimus Dorsi Myocutaneous Flap. [Updated 2023 Mar 1]. In: StatPearls [Internet]. Treasure Island (FL): StatPearls Publishing; 2024 Jan-. Available from: <https://www.ncbi.nlm.nih.gov/books/NBK564377/>
59. Uzun H, Bitik O, Ersoy US, Bilginer B, Aksu AE. Comparison of Musculocutaneous and Fasciocutaneous Free Flaps for the Reconstruction of the Extensive Composite Scalp and Cranium Defects. *J Craniofac Surg*. 2018 Oct;29(7):1947-1951. doi: 10.1097/SCS.0000000000005052. PMID: 30204725.
60. Burgjic M, Bruant Rodier C, Wilk A, Bodin F, Rifatbegović A, Halilbasic E, Burgjic M, Brkic E, Avdagic H. Complications following autologous latissimus flap breast reconstruction. *Bosn J Basic Med Sci*. 2010 Feb;10(1):65-7. doi: 10.17305/bjbm.2010.2739. PMID: 20192934; PMCID: PMC5596614.
61. Song YG, Chen GZ, Song YL. The free thigh flap: a new free flap concept based on the septocutaneous artery. *Br J Plast Surg*. 1984 Apr;37(2):149-59. doi: 10.1016/0007-1226(84)90002-x. PMID: 6713155.
62. Landuyt KV. The Anterolateral Thigh Flap for Lower Extremity Reconstruction. *Semin Plast Surg*. 2006 May;20(2):127-32. doi: 10.1055/s-2006-941720. PMCID: PMC2884768.
63. Themes, U. (2019, October 14). Lien JR. Chung KC. *Free Anterolateral Thigh Flap*. Plastic Surgery Key [Internet]. <https://plasticsurgerykey.com/free-anterolateral-thigh-flap>
64. P. Yu. (2015). Anterolateral Thigh and Tensor Fascia Lata Flaps. In M. N. J. Brian Boyd, *Operative Microsurgery* (p.139-150). Mc Graw Hill Education.
65. Collins J, Ayeni O, Thoma A. A systematic review of anterolateral thigh flap donor site morbidity. *Can J Plast Surg*. 2012 Spring;20(1):17-23. doi: 10.1177/229255031202000103. PMID: 23598761; PMCID: PMC3307676.
66. dos Santos LF. The vascular anatomy and dissection of the free scapular flap. *Plast Reconstr Surg*. 1984 Apr;73(4):599-604. doi: 10.1097/00006534-198404000-00014. PMID: 6709742.
67. Nassif TM, Vidal L, Bovet JL, Baudet J. The parascapular flap: a new cutaneous microsurgical free flap. *Plast Reconstr Surg*. 1982 Apr;69(4):591-600. doi: 10.1097/00006534-198204000-00001. PMID: 7071197.

68. Aviv JE, Urken ML, Vickery C, Weinberg H, Buchbinder D, Biller HF. The combined latissimus dorsi-scapular free flap in head and neck reconstruction. *Arch Otolaryngol Head Neck Surg.* 1991 Nov;117(11):1242-50. doi: 10.1001/archotol.1991.01870230058008. PMID: 1747226.
69. Summer E. Hanson and John W. Siebert. (2015). *Scapular and Parascapular Flaps*. In M. N. J. Brian Boyd, *Operative Microsurgery* (p.124-129). Mc Graw Hill Education.
70. Barrett TF, Orlowski H, Rich J, Jackson RS, Pipkorn P, Puram SV. Anatomic variants of the subscapular-thoracodorsal arterial system: A radiologic analysis of 200 arterial systems. *Oral Oncol.* 2022 Feb;125:105682. doi: 10.1016/j.oraloncology.2021.105682. Epub 2022 Jan 5. PMID: 34998174; PMCID: PMC8926423.
71. Themes, U. (2019, March 3). *Scapular and Parascapular Flaps*. Plastic Surgery Key [Internet]. <https://plasticsurgerykey.com/scapular-and-parascapular-flaps-2/>
72. Wallner J, Rieder M, Schwaiger M, Remschmidt B, Zemann W, Pau M. Donor Site Morbidity and Quality of Life after Microvascular Head and Neck Reconstruction with a Chimeric, Thoracodorsal, Perforator-Scapular Flap Based on the Angular Artery (TDAP-Scap-aa Flap). *J Clin Med.* 2022 Aug 19;11(16):4876. doi: 10.3390/jcm11164876. PMID: 36013116; PMCID: PMC9410144.
73. Brown RG, Vasconez LO, Jurkiewicz MJ. Transverse abdominal flaps and the deep epigastric arcade. *Plast Reconstr Surg.* 1975 Apr;55(4):416-21. PMID: 123346.
74. Themes, U. (2019, March 3). *Rectus Abdominis Flap*. Plastic Surgery Key [Internet]. <https://plasticsurgerykey.com/rectus-abdominis-flap-2/>
75. Holmström H. The free abdominoplasty flap and its use in breast reconstruction. An experimental study and clinical case report. *Scand J Plast Reconstr Surg.* 1979;13(3):423-27. doi: 10.3109/02844317909013092. PMID: 396670.
76. Chang DW. (2015). *Rectus Abdominis Flaps*. In M. N. J. Brian Boyd, *Operative Microsurgery* (p.72-83). Mc Graw Hill Education.
77. Chang DW. Breast Reconstruction with Microvascular MS-TRAM and DIEP Flaps. *Arch Plast Surg.* 2012 Jan;39(1):3-10. doi: 10.5999/aps.2012.39.1.3. Epub 2012 Jan 15. PMID: 22783484; PMCID: PMC3385301.
78. Wu LC, Bajaj A, Chang DW, Chevray PM. Comparison of donor-site morbidity of SIEA, DIEP, and muscle-sparing TRAM flaps for breast reconstruction. *Plast Reconstr Surg.* 2008 Sep;122(3):702-709. doi: 10.1097/PRS.0b013e3181823c15. PMID: 18766032.

6. Biography

Ron Moiguer was born on July 16, 1995, in Haifa, Israel. Graduated from Carmel Zvulun high school. Completed 3 years of military service in the IDF prior to starting medical school in the university of Zagreb and received the Dean's award for the 1st year of medical school.