

Common pitfalls in abdominal aortic surgery and how to deal with them

Perera, Hettiarachchige Tikiri Ooshadhi Shalane

Master's thesis / Diplomski rad

2024

Degree Grantor / Ustanova koja je dodijelila akademski / stručni stupanj: **University of Zagreb, School of Medicine / Sveučilište u Zagrebu, Medicinski fakultet**

Permanent link / Trajna poveznica: <https://um.nsk.hr/um:nbn:hr:105:779195>

Rights / Prava: [In copyright](#)/[Zaštićeno autorskim pravom.](#)

Download date / Datum preuzimanja: **2024-11-26**



Repository / Repozitorij:

[Dr Med - University of Zagreb School of Medicine Digital Repository](#)



UNIVERSITY OF ZAGREB
SCHOOL OF MEDICINE

Hettiarachchige Tikiri Oshadhi Shalane Perera

**Common Pitfalls in Abdominal Aortic
Surgery and how to Deal with them**

GRADUATION THESIS



ZAGREB, 2024

This graduate thesis was made at the Department of Surgery, University Hospital Centre Zagreb, mentored by Ass. Prof. Tomislav Meštrović and was submitted for evaluation in the academic year 2023/2024.

ABBREVIATIONS

AAA - Abdominal Aortic Aneurysm

ACS - Abdominal Compartment Syndrome

IAH - Intra-Abdominal Hypertension

ACT - Activated Clotting Time

BMI - Body Mass Index

BSA - Body Surface Area

CKD - Chronic Kidney Disease

CTA - Computerized Tomography Angiography

DHI - Diameter-To-Height Index

DVT - Deep Vein Thrombosis

EVAR - Endovascular Aneurysm Repair

GFR - Glomerular Filtration Rate

IBE – Iliac Branch Endograft

MI - Myocardial Infarction

MMP - Matrix Metalloproteinase

MRA - Magnetic Resonance Angiography

MRI - Magnetic Resonance Imaging

OR - Odds Ratio

PE - Pulmonary Embolism

SCI - Spinal Cord Injury

VTE - Venous Thromboembolism

CONTENTS

SUMMARY	6
SAŽETAK	7
INTRODUCTION	8
ANATOMY	8
HISTOLOGY	9
PATHOPHYSIOLOGY	9
CLINICAL FEATURES AND SIGNIFICANCE	12
DIAGNOSTIC TECHNIQUES	15
OPEN ABDOMINAL AORTIC ANEURYSM REPAIR SURGERY	17
TECHNIQUE	17
TRANSPERITONEAL REPAIR	17
RETROPERITONEAL REPAIR	19
COMMON PITFALLS/COMPLICATIONS OF OPEN SURGERY AND HOW TO DEAL WITH THEM	22
MYOCARDIAL ISCHEMIA	22
RESPIRATORY FAILURE	22
RENAL FAILURE	23
COLONIC ISCHEMIA	23
SPINAL ISCHEMIA	25
VENOUS THROMBOSIS	25
ERECTILE DYSFUNCTION	25
EVAR	28
TECHNIQUE	29
COMMON PITFALLS/COMPLICATIONS OF EVAR AND HOW TO DEAL WITH THEM	30
ENDOLEAKS	30
Type I Endoleak	30
Type II Endoleak	30
Type III Endoleak	31
Type IV Endoleak	31
Type V Endoleak	31

STENT MIGRATION	32
GRAFT LIMB OCCLUSION	32
RENAL ARTERY OCCLUSION.....	32
NECK DILATION	33
ENDOGRAFT INFECTION	33
PELVIC ISCHEMIA	35
STENT-GRAFT FATIGUE.....	35
POST-IMPLANTATION SYNDROME	35
EVAR VERSUS OPEN REPAIR.....	36
CONCLUSION	38
ACKNOWLEDGEMENTS.....	39
REFERENCES	40
BIOGRAPHY.....	43

SUMMARY

TITLE: Common pitfalls in abdominal aortic surgery and how to deal with them

AUTHOR: Shalane Perera

An aneurysm is a focal enlargement of an artery to 1.5 times its normal diameter or more. Most abdominal aortic aneurysms are asymptomatic until they rupture, but some are detected when an imaging study is done for other purposes. The risk factors for abdominal aortic aneurysms are smoking, male sex, age (above sixty-five), hypertension, ischemic heart disease, peripheral vascular disease and positive family history. There are many different modalities that can be used to diagnose an abdominal aortic aneurysm, but ultrasonography is used for screening since it is economical and doesn't expose the patients to ionizing radiation. Abdominal aortic aneurysm can be managed either medically or surgically. Medical management involves therapy to reduce cardiovascular risk factors and quitting smoking, which is appropriate for asymptomatic individuals with smaller aneurysm sizes. The need for surgical intervention for abdominal aortic aneurysms is based on the size (diameter of 5.0 cm or greater for women and 5.5 cm or greater for men), the rate of progression and the presence of symptoms. While a symptomatic aneurysm needs to be treated urgently (as it is a sign of impending rupture), since rupture of the abdominal aortic aneurysm is a medical emergency that requires immediate repair. There are two primary methods of abdominal aortic aneurysm repair: open and endovascular (EVAR). EVAR is preferred over open surgical intervention, due to its lower morbidity and mortality rates, minimal invasiveness, shorter length of hospital stay, and lower rate of complications such (as myocardial infarction, respiratory failure, renal failure, colonic ischemia and graft infections). On the other hand, EVAR has demonstrated specific complications related to increased long-term morbidity and mortality, such as endoleaks and stent-graft migration. The aim of this study is to elucidate the common pitfalls in open and endovascular repair of abdominal aortic aneurysms, and the prevention and treatment of complications.

KEYWORDS: Abdominal Aortic Aneurysms, Pitfalls, Complications, EVAR, Open Surgery, Reintervention

SAŽETAK

NASLOV: Uobičajene zamke u operaciji abdominalne aorte i kako se s njima nositi

AUTOR: Shalane Perera

Aneurizma je žarišna dilatacija arterije na 1,5 puta njezinog normalnog promjera ili više. Većina aneurizama abdominalne aorte je asimptomatska sve dok ne pukne, iako se neke otkriju kada se radi slikovna studija u druge svrhe. Čimbenici rizika za nastanak aneurizme abdominalne aorte su pušenje, muški spol, dob iznad šezdeset i pet godina, hipertenzija, ishemijska bolest srca, periferne vaskularne bolesti i pozitivna obiteljska anamneza. Postoji mnogo različitih modaliteta koji se mogu koristiti za dijagnosticiranje aneurizme trbušne aorte, ali ultrazvuk se koristi za probir jer je ekonomičan i ne izlaže pacijente ionizirajućem zračenju. Aneurizma abdominalne aorte može se liječiti konzervativno ili kirurški. Konzervativno liječenje uključuje terapiju za smanjenje kardiovaskularnih čimbenika rizika i prestanak pušenja, što je prikladno za asimptomatske osobe s manjom veličinom aneurizme. Potreba za kirurškom intervencijom kod aneurizme abdominalne aorte temelji se na veličini (promjer 5,0 cm ili veći za žene i 5,5 cm ili veći za muškarce), brzini progresije i prisutnosti simptoma. Dok simptomatsku aneurizmu treba hitno liječiti (kao znak prijeteće rupture), ruptura aneurizme trbušne aorte je emergentno medicinsko stanje koje zahtijeva trenutni popravak. Postoje dvije primarne metode popravka aneurizme abdominalne aorte: otvorena i endovaskularna (EVAR). EVAR se preferira u odnosu na otvorenu kiruršku intervenciju, zbog manje neposredne stope morbiditeta i mortaliteta, minimalne invazivnosti i potrebe za kraćim boravkom u bolnici te zbog manje stope komplikacija kao što su infarkt miokarda, respiratorno zatajenje, zatajenje bubrega, ishemija debelog crijeva i infekcije presatka. S druge strane, EVAR je pokazao specifične komplikacije povezane s povećanim dugoročnim morbiditetom i mortalitetom, kao što su *endoleak* i migracija stent-grafta. Cilj ove studije je razjasniti uobičajene zamke kod otvorenog i endovaskularnog popravka aneurizama abdominalne aorte, kako bi se poboljšala prevencija i liječenje komplikacija.

KLJUČNE RIJEČI: aneurizma abdominalne aorte, komplikacije i problemi, reintervencija.

INTRODUCTION

This review paper brings an insight into the history of abdominal aortic aneurysm repair as well as the current state of the art and possible development in the field of abdominal aortic aneurysm repair. The emphasis is on the common pitfalls and complications of surgical and endovascular treatment of abdominal aortic aneurysms.

Aortic disease has been a major problem for many decades, even though medical solutions existed, treatment of abdominal aortic aneurysms didn't progress much until the discovery of surgical techniques to repair them. The open surgical method for abdominal aortic repair surgery has been present since it was first described by Dubost in 1952. Though the open technique is still used, the invention of EVAR by Dr. Juan C. Parodi, in the 1990s has revolutionized AAA repair.

ANATOMY

Most of the abdominal and pelvic organs are supplied with blood via the abdominal aorta. The celiac artery is the primary branch of the abdominal aorta, dividing into the left gastric artery, the splenic artery, and the common hepatic artery. The superior mesenteric artery is situated immediately below the celiac trunk. It provides blood to the pancreas, the ascending and transverse colon, and the jejunum and ileum in the small intestine. The rectum, sigmoid colon, and descending colon are supplied with blood via the inferior mesenteric artery, that rises just above the level of the third lumbar vertebra.

The kidneys have their own blood supply coming from the renal arteries, originating just below the superior mesenteric artery. The gonads receive blood flow from the gonadal arteries. The posterior part of the abdominal aorta gives rise to the lumbar arteries, that provide blood to the meninges, vertebrae, spinal cord, and the muscles of the abdominal wall. The middle suprarenal arteries are small arteries supplying the adrenal glands. The inferior phrenic arteries supply blood to the diaphragm and rise from the abdominal aorta just below the diaphragm. The abdominal aorta splits into the left and right common iliac arteries at the level of the fourth vertebra. The pelvic organs are supplied with blood by

the internal iliac arteries, while the lower limbs are supplied by external iliac arteries, which proceed as femoral arteries below the inguinal ligaments (1).

HISTOLOGY

The classification of the aneurysms can be categorized into true or false, the latter often referred to as pseudoaneurysms, relies on whether the abnormality involves widening of the entire vascular wall (known as true aneurysm) or if it constitutes a confined hematoma formed due to vessel damage (known as pseudoaneurysm). In pseudoaneurysm, the structure resembling a “wall” comprises connective tissue that has developed in response to the contained hematoma.

Aneurysms are also categorized based on their site (such as aortic or splenic) and their size. *Ectasia* indicates a moderate expansion, where an artery is enlarged, but less than 50% the usual size. While *arteriomegaly* describes widespread, consistent enlargement of numerous arterial sections, dilated to more than 50% of the normal size. For an artery to be considered aneurysmal the diameter has to be 50% greater than the normal diameter of the artery or more. *Arteriomegaly* serves as a descriptive expression rather than indicative of a precise diagnosis, likely forming a component of genetic syndrome involving the degeneration of arteries that has not been fully delineated.

When there are numerous aneurysms in different anatomical regions or when aneurysmal degeneration occurs in the context of *arteriomegaly*, the word “*aneurysmosis*” is sometimes used to characterize such changes. Then there is dissection vs dissecting aneurysm, a dissecting aneurysm and dissections both include the separation of layers inside the artery wall; however, the term “*dissecting aneurysm*” particularly designates this condition when it occurs in conjunction with an aneurysm (1,2).

PATHOPHYSIOLOGY

The mechanical characteristics of the aortic wall are determined by collagen and elastic fibers (3–5). The aortic wall’s media is home to most elastic fibers connected to smooth muscle cells. The polymeric form of collagen is also an important constituent of the

surrounding fibrous adventitia and the media. The vascular wall's structural integrity is preserved, and tensile strength is provided by two distant forms of fibrillar collagen, known as type I and type III. Proteoglycans are involved in the organization of the aortic wall in addition to collagen and elastic fibers.

Changes to the connective tissue in the aortic wall are associated with the development of abdominal aortic aneurysm. Most significant histological characteristics of the aneurysmal tissue are fragmentation and loss of the elastic fibers with medial attenuation. The adventitial tissue, where collagen predominates, is what gives the aorta its resistance in this setting. Further imbalance in collagen turnover may favor collagen degradation that ultimately results in rupture.

Medial smooth muscle cells and adventitial fibroblasts generate proteases that are responsible for the modification of elastin and collagen in the aortic wall together with lymphomonocytic infiltration. These inflammatory cells are a result of medial neovascularization, which is another characteristic of abdominal aortic aneurysm. Elastin fragments, proinflammatory cytokines, chemokines and prostaglandin derivatives produced by resident mesenchymal cells as well as inflammatory cells themselves, all contribute to the development of abdominal aortic aneurysms. Matrix metalloproteinases (MMPs) triggered locally by plasmin, produced by plasminogen activators or by other MMPs, break down collagen and elastic fibers. In animal models, the involvement of plasmin and MMP in the development of abdominal aortic aneurysm has been verified. There is also an increase in tissue inhibitors of matrix metalloproteinases (TIMPs) in the aneurysm wall. Experimental investigations where antiproteases are overexpressed or genetically inactivated proved more evidence for the significance of this imbalance in the formation of aneurysms.

Another crucial part in the development of abdominal aortic aneurysms is thought to be due to the decrease in smooth muscle cell density in the elastic media in addition to the rarefaction of its extracellular matrix. The vascular wall smooth muscle cells are involved in the remodeling of arterial walls by producing different extracellular matrix proteins, proteases and their inhibitors. Smooth muscle cells also function as a barrier against proteolysis and inflammation. It has been demonstrated that *in vitro* aortic smooth muscle

cells produce less monocyte chemoattractant protein-1 (MCP-1), a key inflammatory mediator in the abdominal aortic aneurysm, when subjected to cyclic stretching as opposed to static culture. This finding supports the idea that smooth muscle cells have a paracrine protective role.

In most patients, the development of abdominal aortic aneurysms correlates with mural thrombus. In contrast to arterial occlusive disorders, aortic aneurysms preserve blood flow, which causes the thrombus's components to continuously reconstruct. While the thrombus can significantly reduce the tension on the aneurysmal wall, as it thickens, it promotes hypoxia of the aortic media, which can cause an increase in inflammation and medial neovascularization (3–5).

RISK FACTORS

A study by Altobelli and associates, carried out in 2018, evaluated risk factors for AAA (6). This study presented findings from observational studies examining the prevalence of AAAs. Various systematic reviews and meta-analyses included in the review reported AAA prevalence rates ranging from 1.4 - 6.2%, while other studies showed rates between 0.3 and 12.4%, potentially influenced by differences in the age group studied. Additionally, the study conducted a new meta-analysis focusing on risk factors for AAA (smoking, gender, hypertension and family history), incorporating updated data. The review also highlighted variations in organized screening practices for AAA, noting that while UK and Sweden have nationwide screening programs, other countries primarily have local initiatives, with significant regional differences in screening coverage.

The study determined a significant correlation between smoking and the development of abdominal aortic aneurysms. It emphasized that smoking and male gender as main risk factors for AAA, with male smokers at particularly high risk. Studies have shown that countries with reduced cigarette consumption also exhibit lower AAA prevalence rates. Additionally, smoking is correlated with the diameter of the aorta, with smokers having larger aortas and significantly higher risk of AAA compared to non-smokers. Current smokers are more likely to develop AAA at younger ages, and the risk increases with the

duration of smoking, likewise smoking cessation reduces the risk of aortic rupture. While AAA prevalence is generally higher in males, some studies suggest that females may also be at significant risk. This association with males might be due to their higher predisposition to cardiovascular disease, known as the “male disadvantage”.

Apart from smoking and male gender, the study also identified older age, hypertension and low high-density lipoprotein (HDL) cholesterol level as significant risk factors for abdominal aortic aneurysms, warranting further investigation. Additionally, the results indicated a family history of AAA as a risk factor, although caution was advised due to wide confidence intervals potentially affecting the pooled effect size. Other conditions such as ischemic heart disease, previous myocardial infarction, peripheral vascular disease, chronic obstructive respiratory disease were also linked to AAA (6).

Other risk factors alongside oxidative stress includes an autoimmune aspect characterized by significant infiltration of lymphocytes and myocytes into the aortic wall, accompanied by immunoglobulin G deposition. Smoking induces a heightened inflammatory reaction within the aortic wall. Increased tension and disrupted flow in the infrarenal aorta also contribute to aneurysm formation and rupture. Moreover, there is a notable risk for first-degree relatives of AAA patients with 12 - 19 % likelihood of developing an aneurysm (2,6,7).

CLINICAL FEATURES AND SIGNIFICANCE

Abdominal aortic aneurysms can manifest with a variety of signs and symptoms, although they may not always be present, especially in the early stages. Furthermore, the presentation of AAAs varies, it can be asymptomatic or asymptomatic and also depends on whether they have ruptured. Asymptomatic AAA is typically discovered incidentally during routine physical examination imaging studies for other medical conditions or screening programs. Patients may not experience any discomfort or specific symptoms related to the aneurysm itself. Diagnosis is usually confirmed through imaging tests such as ultrasound, CT scans or MRIs (1,8).

When symptoms from the aneurysm become apparent, the condition is known as symptomatic AAA. While there are many other symptoms, persistent or sporadic intense and throbbing back or stomach pain may be one of them. Patients may experience abdominal pulsation, especially if the aneurysm is big. Additional signs and symptoms could be pain or discomfort in the legs, groin, or chest; they could also point to problems such as peripheral artery disease or blood clots. When an aneurysm presses against the esophagus or diaphragm, some individuals may have symptoms including trouble eating or breathing. These symptoms are related to compression of adjacent structures.

The presence of symptoms is an ominous sign of an imminent rupture. Ruptured AAA is usually fatal if left untreated and is therefore considered a medical emergency. An abrupt, intense back or abdominal pain that may spread to the legs, buttocks, or groin is a common sign of ruptured AAA. The pain may be strong, severe, or even ripping, according to the patient. Internal bleeding can present as lightheadedness, fainting, tachycardia, hypotension, pale skin, and cold sweats. Some patients may develop signs of shock, including confusion, weakness, and loss of consciousness. Ruptured AAA requires immediate medical attention and emergency surgery to repair the artery and stop the bleeding (1,8,9).

As awareness grows regarding the diverse nature of different factors that contribute to AAAs, there is a shift towards precision medicine, moving away from a one-size-fits-all approach. The existing was established through epidemiological studies, which has faced criticism due to concerns about their applicability across populations. Consequently, the widely accepted threshold for intervention based on AAA diameter, beyond which risk of rupture escalates, has also come under scrutiny. Despite AAA diameter traditionally serving as the primary indicator of rupture and symptomatic presentation, several studies indicated that a significant proportion of smaller AAAs (< 4.5 cm) can also rupture.

The study by Khan and associates encompassed nearly 65,000 patients who underwent surgical repair for AAAs, among whom over 10,000 exhibited symptomatic AAAs, including ruptured cases (10). In the study that the authors carried out the analysis indicated that utilizing the diameter-to-height index (DHI) outperforms relying solely on diameter in predicting symptoms or rupture. A rise in DHI per unit corresponded to a 70%

higher likelihood of a symptomatic AAA presentation, marking the highest Odds Ratio (OR) compared to other rupture predictors. Independent protective factors included the use of statins, beta-blockers, aspirin and ACE inhibitor. These findings highlight an area for potential enhancement on the care of patients under AAA surveillance, considering that more than half of symptomatic patients in the study were not prescribed the mentioned medications.

There is notable variation in the spread of aneurysmal disease across the aorta. Compared to the thoracic part of the aorta, the abdominal aorta has an aneurysm prevalence that is at least nine times higher. Aortic aneurysms are often linked to family history of the disease, according to several studies, even in cases where they are not linked to uncommon conditions like Marfan syndrome or Ehlers-Danlos syndrome type IV.

Various measurements have been investigated, including body mass index (BMI) and body surface area (BSA), in relation to abdominal aortic aneurysm (AAA) diameter. Specifically, BSA indexed to AAA diameter showed better predictive capability for rupture risk in women compared to AAA diameter alone. Finite element analysis studies have suggested a connection between height and aortic wall stress. Some smaller studies have indicated that the AAA wall stress, a biomechanical factor, surpasses AAA diameter in predicting rupture. Similarly, in a study of 100 computed tomography (CT) scans it was concluded that vertebral body diameter indexed to AAA diameter outperformed AAA diameter alone in rupture prediction. Furthermore, findings from thoracic aortic aneurysm research have suggested the use of relative aneurysm sizing for rupture prediction.

Weight-based BSA or BMI may not accurately reflect sizing due to weight fluctuations over time. Additionally, obesity-related conditions like hypertension and diabetes could confound results. The role of hypertension in the formation and rupture of AAAs, as well as the paradoxical relationship between diabetes and AAAs, remain unclear. More intricate metrics, such as peak wall stress requiring CT scanning, may not be feasible for all patients.

Confirming previous findings, the study revealed a higher likelihood of symptomatic AAAs among women compared to men (24.6% vs 19.9%; $P < 0.001$), while fewer women

presented with asymptomatic AAAs compared to men (75.4% vs 80.1%; $P < 0.001$). Limited research has dealt with the influence of sex hormones on AAA formation. Analysis of AAA diameter distribution and symptomatic presentation indicated that women have tendency to become symptomatic at smaller AAA diameters than men, although this difference lessened when AAA diameter was adjusted for height. Multivariate analysis further demonstrated that sex modified the risk associated with symptomatic presentation and diameter-to-height Index (DHI).

Similarly, the study identified a comparable interaction with race, where Black patients were less likely to present with symptomatic AAAs at the same DHI compared to other patients. This finding aligns with previous studies, which suggested a protective effect of Black race. However, Black patients experienced more postoperative complications, such as renal failure and the need for reoperation, compared to White and Asian patients (10).

DIAGNOSTIC TECHNIQUES

European Society for Vascular Surgery Guidelines recommend ultrasound screening for the early detection of AAA in high-risk populations to reduce death from aneurysmal rupture. A high-risk group definition depends on local conditions, such as disease prevalence, life expectancy, and healthcare structure, but generally, it includes 65-year old men, irrespective of a history of smoking, first-degree relatives of patients with AAA, people with other peripheral aneurysms and recipients of organ transplantations. It is also noted that in populations with decreasing prevalence, a strategy based on smoking status could be a more effective alternative to general screening (11).

Modern imaging techniques significantly contribute to the identification and characterization of aneurysms. Ultrasound (US) examination has shown remarkable sensitivity and specificity. Although US may encounter limitations due to patient physique, it is noteworthy that it circumvents the complications associated with more invasive procedures, radiation exposure and contrast medium administration. US serves as an excellent option for screening and assessing diameter. However, it is important to

acknowledge that US may not be optimal for detecting ruptures since it can't visualize all segments of the aortic wall and retroperitoneal hematomas confidently. Furthermore, in emergency examinations in non-fasted patients, achieving ideal image acquisition may be challenging. It has been approximated that US could miss up to 50% of aneurysm ruptures.

Computed tomography imaging offers superior visualization of AAAs, with enhanced consistency in diameter measurements compared to ultrasound. CT, especially when combined with iodinated contrast for CT angiography, furnishes comprehensive anatomical details, revealing features like vessel calcification defects, thrombus presence, and three-dimensional reconstructions, aiding in surgical planning. However, drawbacks associated with CTA include significant exposure to radiation, especially with repeated examinations, and challenges related to the use of iodinated contrast agents, particularly in populations with a high prevalence of kidney disease.

Magnetic resonance imaging and magnetic resonance angiography exhibit similar sensitivity to CT in detecting abdominal aortic aneurysms. Unlike CT, MRI fails to visualize aortic wall calcifications, which can be crucial for surgical planning. Although iodinated contrasts are unnecessary for MRI, MRA employs gadolinium, which is linked to nephrogenic systemic fibrosis development in individuals with reduced glomerular filtration rate (GFR). Additionally, MRI availability may be restricted in patients with incompatible metallic implants or foreign objects. Nonetheless, the capacity to capture dynamic images throughout the cardiac cycle could potentially offer clinical benefits.

Contrast angiography is not the recommended technique for surveillance or screening for AAAs because of its intrusive nature. According to the American College of Radiology imaging guidelines, it is usually saved for situations requiring more in-depth aneurysm characterization or intervention (e.g., preoperative embolization of an accessory renal artery before endovascular aneurysm repair) (1,12).

OPEN ABDOMINAL AORTIC ANEURYSM REPAIR SURGERY

TECHNIQUE

There are two primary methods of AAA repair - open and endovascular. Nowadays the endovascular approach is performed more frequently, since it has fewer potential risks and lower early morbidity and mortality, but in surgical emergencies an endovascular abdominal aortic aneurysm repair may be converted into an open procedure if needed.

TRANSPERITONEAL REPAIR

A vertical incision is made down the middle of the abdomen. The omentum and transverse colon are lifted upward, while the small intestine is gently pushed to one side within the right side of the abdomen. To keep the incision open, a self-retaining retractors are employed. To access the aorta, the ligament of Treitz is cut, and the third and fourth portions of the duodenum are moved to the patient's right (1,13,14). Lymphatic and connective tissues around the aorta are tied off and cut. Special care is taken to avoid harming the inferior mesenteric vein, though it may be divided if necessary for better access. The incision in the back of the peritoneum is extended downward in the same plane to fully expose the section of the aorta below the kidneys. Starting slightly to the left of the aorta near the ligament of Treitz, the incision in the peritoneum curves to the right of the aortic centerline to prevent damage to the inferior mesenteric artery. If a tube graft is to be implanted with the distal connection directly to the aorta, dissection is limited to just above the branching point of the common iliac arteries.

An increasing percentage of patients with short or nonexistent infrarenal necks in their aneurysms need open aneurysm procedures. Because of these aneurysms' origin close to the renal arteries, suprarenal clamping might be needed, requiring more aortic exposure. The back of the peritoneum is opened upwards to the level of the renal veins to do this. It is important to take note of the renal vein's location in the preoperative CT scan. If it is positioned anteriorly, it can usually be relocated by severing the branches that nourish the gonads, adrenal glands, and the lumbar area to improve exposure of the upper aorta. As an alternative, it can be ligated central to the inflow site of gonadal and

suprarenal veins, but doing so raises the possibility of kidney issues following surgery. To maintain adequate venous drainage, it is imperative to make the timely decision to ligate the left renal vein. Once the vein is severed, the branches that supply the gonads, adrenal glands, and lumbar region must be preserved. The cut should be made as close to the inferior vena cava as possible to help with this and to improve exposure.

The upper part of the aorta, known as the supraceliac aorta, is reached by separating the lesser omentum or gastrohepatic ligament. The aorta is located by palpation, and the fibers covering the right side of the diaphragm are cut using electric cautery. It can be helpful to move the left lobe of the liver by cutting the left triangular and coronary ligaments, as well as the falciform ligament. But this isn't always necessary. Having a nasogastric tube in place helps to locate the esophagus, protecting it from accidental harm. The esophagus is usually pulled to the left side during the procedure. The aorta can be dissected towards the front down to the level of the celiac axis, but caution is needed to avoid harming the pancreas as the dissection moves downwards.

For suprarenal aneurysms, the preferred method of approach is through a retroperitoneal exposure. However, it is possible to access the entire visceral segment of the aorta through the abdomen by rotating the internal organs towards the left side. To do this, the left colon is freed by making an incision in the back of the peritoneum just beside the Toldt line. The incision is extended upwards through the phrenicocolic ligament and then towards the aortic hiatus underneath the diaphragm. The space between Gerota's fascia and the back of the abdominal wall is opened, allowing the colon, pancreas, spleen and left kidney to be moved towards the middle.

The location for clamping near the beginning and the end of the afflicted area are identified once the pertinent sections of the aorta have been exposed. It is recommended against encircling the vessels with tapes or silastic vessel loops because this step increases the danger of harming the tissues behind, especially the iliac veins. The aorta must be exposed just enough to apply the clamp securely. To prevent damaging or rupturing closely related venous structures, extreme caution should be used. To stop any blood clots from traveling to the legs while the proximal clamp is being applied, distal clamps on the iliac arteries are usually positioned first. Also, before clamping, the patient

is given systemic heparinization. After clamping, a longitudinal incision is made in the aorta to open the aneurysm, and it forms a T shape at both the proximal and distal ends to facilitate the attachment of a graft. The aneurysm sac's residual blood clots are removed. A continuous polypropylene suture is used to complete the end-to-end proximal anastomosis. Exposure is aided using self-retaining retractors inside the aneurysm sac or using aortic retention sutures. Similar steps are taken for the distal reconstruction.

After finishing the proximal and distal anastomoses, the aneurysm sac is sealed around the graft using a continuous absorbable suture. Similarly, the last layer of the peritoneum is closed. Both actions serve to shield the bowel from the retroperitoneal space and prevent direct contact between the bowel and the graft. If it's not possible to bring the sac or retroperitoneum together over the graft, the omentum can be utilized to cover it. It's crucial to ensure that there's a clear separation between the graft and the intestines to avoid potential formation of an aortoenteral fistula. The intestines are then placed back into their normal position, and the front layer of the abdominal wall is closed in the manner preferred by the surgeon (1,13,14).

RETROPERITONEAL REPAIR

The incision begins at the 10th intercostal space along the back, near the armpit, though its exact location may vary depending on the extent of the aneurysm. It continues downward onto the abdomen, running alongside and parallel to the outer edge of the left rectus muscle, ending below the belly button at a level predetermined by the planned arterial reconstruction (1,13,14). Skin and subcutaneous tissues are cut to expose the outer layer of the anterior abdominal wall. Layers of muscle - the external oblique, internal oblique and transversus abdominis - are sequentially opened over a short distance using a combination of careful probing and electrocautery. Particular attention is paid to avoid piercing the peritoneum. The peritoneum is then gently separated from the abdominal wall using cautious digital manipulation, allowing access into the abdominal cavity up to the level of the diaphragm.

Enhanced exposure can be achieved by extending the incision into the chest through the 10th intercostal space, contiguous with the abdominal portion of the incision, and cutting

a small portion of the diaphragm (approximately 2 to 3 cm). The left psoas muscle is located, and contents within the peritoneal and retroperitoneal areas are carefully guided towards the front along the length of the incision, and away from the underside of the diaphragm. This reveals the entire length of the abdominal aorta. During this process the left ureter, which runs in front of the aorta and left common iliac artery, is identified and safeguarded. Similarly, by staying on a plane directly in front of the iliac arteries, the right ureter can also be identified and safeguarded. To assist with exposure, a self-retaining retractor may be employed. If the patient has a posterior left renal vein, it may be advisable not to move the kidney during the aortic exposure and to leave it in its original position in the retroperitoneum. Alternatively, if necessary, it can be divided for better exposure if the gonadal branch is preserved.

To improve access to visceral part of the aorta and locate a suitable site for clamping above the celiac artery, the portion of the diaphragm is divided. An appropriate location for clamping is determined, and the aorta is carefully dissected along its front and back surfaces, taking care to avoid damaging any lumbar arteries or veins situated behind it. Once more, it is not advisable to attempt encircling the aorta or iliac arteries entirely, as this increases the risk of injuring the esophagus, vena cava, or iliac veins. The left renal artery is located and traced next to its origin to prevent damage during the opening of the aorta. Additionally, branches of the left renal vein originating from the lumbar region are identified, tied off, and cut to prevent tearing.

Using a retroperitoneal incision is highly beneficial for repairing suprarenal and type IV thoracoabdominal aortic aneurysms due to the excellent exposure it offers. Following heparinization and clamping above the celiac artery, the aneurysm is opened with a longitudinal incision along the aorta until reaching the level of the proximal aorta. At this point, the incision is extended into a T-shape, ensuring prior identification and ligation of the renal lumbar veins to prevent injury to them during this step. The left renal artery is carefully freed from the aortic wall, with a small surrounding section of the aorta, and gently moved away from the immediate surgical field. Once the upper limit of the aneurysm is accessed, the celiac, the superior mesenteric artery (SMA), and right renal arteries are located within the aorta. Any significant narrowing found on preoperative

imaging or during surgery can be managed by either removing the plaque or deploying a stent through the opened aorta. The upper end of the graft is shaped to accommodate these arteries, and the upper anastomosis is completed using a continuous polypropylene suture. After clamping the upper part of the graft, the clamp above the celiac artery is removed to allow blood flow to the abdominal organs and the right kidney. Revascularization of the left kidney is then performed by creating a bypass from the graft. Once the connection to the left renal artery is finished, the aortic clamp is shifted lower on the graft to ensure renal blood supply. It's crucial to minimize ischemic time in this area, emphasizing the importance of proper surgical technique and attention to detail. At this stage, any bleeds are stitched closed. By delaying the removal of blood clots, the time of reduced blood flow to internal organs and kidneys is minimized, as there's no need to waste time managing bleeding while the clamp is positioned above the celiac artery. Additionally, the blood clots serve to block the vessels that bleed backwards, reducing blood loss. The process of rebuilding the lower part of the artery continues in a similar fashion to the transabdominal approach.

Once bleeding is controlled, the self-retaining retractor system is taken out, and the peritoneal sac is restored to its usual position. Since the peritoneum hasn't been pierced, the graft remains separate from abdominal viscera. Hence, there's no need to close the aneurysm sac after the AAA repair. However, any tears in the peritoneum should be closed using a continuous absorbable suture. The operating table is adjusted to reduce tension on the wound during closure, and the flank incision is closed in multiple layers. The ribs and diaphragm can be included using a single continuous absorbable suture. The operating table is adjusted to reduce tension on the wound during closure, and the incision on the flank is closed in multiple layers. The ribs and diaphragm can be included in the closure of the transversus abdominis and internal oblique muscles using a single continuous absorbable suture. Special care is needed to prevent unintended damage to the colon during closure. The external oblique, along with its associated fascia, is closed over it, as it provides the necessary strength for the closure (1,13,14).

COMMON PITFALLS/COMPLICATIONS OF OPEN SURGERY AND HOW TO DEAL WITH THEM

Adverse events can occur regardless of adequate perioperative care. Post-procedural systemic complications include myocardial ischemia, respiratory and renal failure. Local and surgical-specific complications include end-organ and limb ischemia, bleeding, compartment syndrome etc.

MYOCARDIAL ISCHEMIA

Patients with pre-existing cardiac risk factors have an increased risk of cardiac complications during surgery, partially due to aortic cross-clamping during aneurysm repair, which increases cardiac afterload. Through thorough preoperative imaging, the incidence of myocardial events during surgery can be limited. However, despite these measures, myocardial infarction still affects approximately 10% of patients during the perioperative period. Research indicates that administering beta-blockers perioperatively to patients undergoing major noncardiac surgeries decreases the likelihood of cardiovascular events and in-hospital deaths, as demonstrated by extensive retrospective population studies and prospective randomized trials. Similarly, a smaller observational study focusing on patients undergoing AAA repair found that the use of beta-blockers was linked to a significant reduction in in-hospital mortality (1,15,16).

RESPIRATORY FAILURE

Extubating the patient post-surgery is dependent on the complexity of the surgical procedure. Usually, for more complex repairs that require tight control over the upper part of the aorta, it's better to keep the patient on a breathing tube. Patients frequently require fluids for 12 to 36 hours, due to blood pressure changes brought on by clamping the upper portion of the aorta. Following standard guidelines, it is safe to remove the breathing tube once the patient is stable and there are no signs of bleeding. Despite efforts to limit prolonged intubation, pulmonary complications such as pneumonia occur in 17% of patients. Post-operative lung complications are associated with increased morbidity (1,16,17).

RENAL FAILURE

After abdominal aortic aneurysms repair surgery, patients are at a significant risk of developing renal complications. After surgery, 10% of Medicare patients have some degree of renal insufficiency, although only approximately 0.5% require renal replacement therapy. After elective surgery for aortic aneurysms near the kidneys, 15-20% of patients get renal insufficiency, but only approximately 3.5% require dialysis, according to a review of numerous publications on the subject. During the surgery and post-operative recovery phase, it is crucial to closely monitor fluid levels and administer sufficient fluids intravenously to prevent further kidney injury (1,15,16).

COLONIC ISCHEMIA

Colonic ischemia, which occurs in 0.2 - 6% of cases after open aneurysm repair, is due to several factors, including ligation of inferior mesenteric artery, failure to restore blood flow to the hypogastric arteries, blockages in the iliofemoral arteries, stenosis in the superior mesenteric artery, and the other conditions like atheroembolism, retractor injury, or previous colonic surgery. It's interesting to note that the true incidence of undiagnosed illness is higher; research indicates that 13% of patients had visible damage during follow-up exams following aortic surgery and 30% of patients have tissue damage. Symptoms like early postoperative diarrhea, bleeding from the rectum, or other signs of gastrointestinal bleeding require prompt investigation for a diagnosis. Bloody stool is often the main symptom. It is possible to carry out quick, low-risk procedures like colonoscopies or flexible sigmoidoscopies. In large studies, intestinal ischemia has a mortality rate of 25 - 55%, which can soar to 90% if bowel removal is necessary. Therefore, patients should receive aggressive fluid resuscitation and broad-spectrum antibiotics targeting gut bacteria. Those with mild disease or limited tissue involvement may be managed conservatively, while those with severe symptoms or widespread tissue damage may require emergency surgery to remove affected bowel segments. Sometimes, the extent of tissue damage is hard to determine, and exploratory surgery may be necessary to confirm the diagnosis. It's better to perform surgery and find no issue than to miss severe damage which could lead to bowel perforation (1,16,17).

LOWER EXTREMITY ISCHEMIA

Patients who undergo open surgery for aneurysm repair face a higher risk of sudden lower limb ischemia. It's crucial to assess blood flow to the lower extremities both before waking up from anesthesia and before leaving the operating room. If there's a loss of pulses or other signs of limb ischemia right after surgery, it could indicate technical problems with the anastomotic complications, damage as a result of clamping, sudden blood clot formation, or the presence of an acute embolism, all of which need immediate attention. Careful surgical technique is vital, especially when suturing the connections to diseased blood vessels, and caution is necessary when placing clamps to avoid dislodging cholesterol deposits or harming blood vessels. Also, maintaining adequate systemic blood thinning to prevent clots is essential and can be monitored using activated clotting time (ACT) tests, with the heparin doses adjusted accordingly (1,15,16).

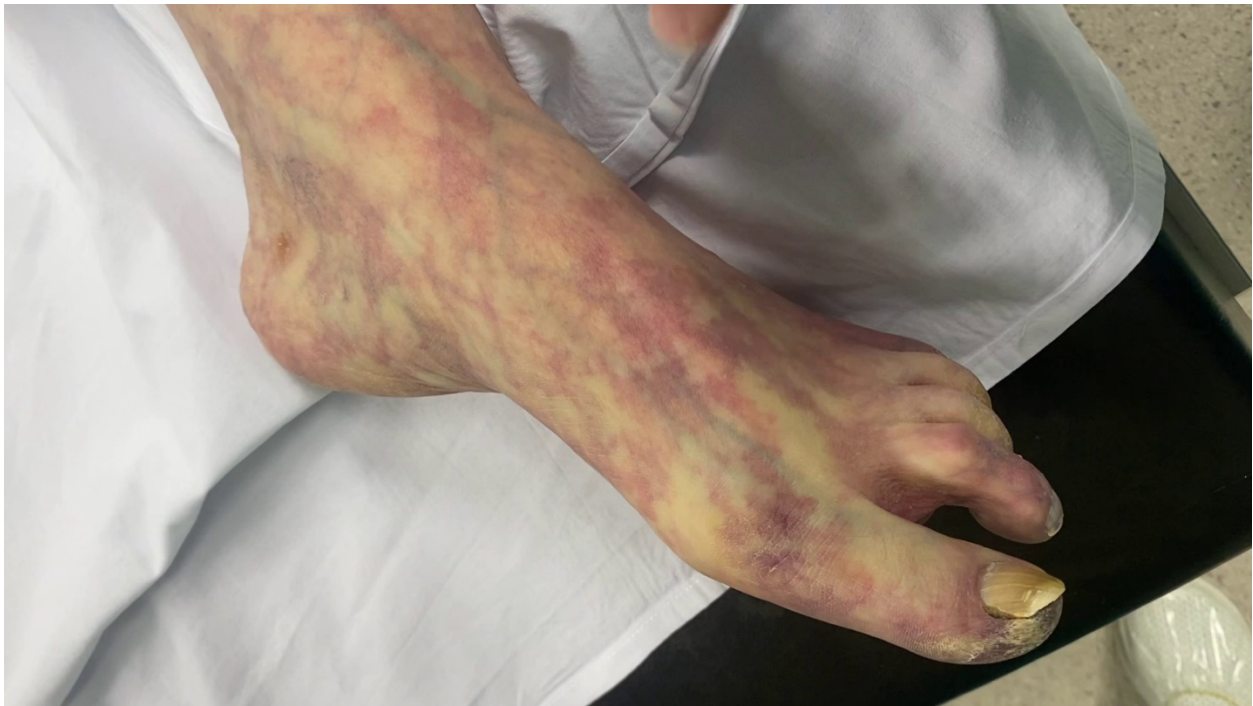

Figure 1. Acute limb ischemia, manifested by pallor and mottled skin appearance (Source: Archives of the Division of Vascular Surgery, Department of Surgery, University Hospital Center Zagreb – "Rebro", Croatia).

SPINAL ISCHEMIA

Spinal cord injury (SCI) after open surgery for abdominal aortic aneurysm (AAA) is exceedingly uncommon. Typically, the reported rates are below 1%, even for repairs involving the upper portion of the aorta, though they may rise when including patients undergoing extensive thoracoabdominal aneurysm repair. The largest risk factor seems to be the degree of proximal aortic coverage; however other factors like prior thoracic or aortic procedures, the location and the duration of the aortic cross-clamp, patency of the internal iliac arteries, and significant intraoperative or postoperative hypotension most probably also plays a part (1,16).

VENOUS THROMBOSIS

Following aortic surgery, pulmonary embolism (PE) and lower extremity deep vein thrombosis (DVT) are clinically uncommon occurrences due to the use of systemic anticoagulation. But even with mechanical and pharmacological prophylaxis, VTE can be identified at a rate up to 8% with routine surveillance using lower extremity duplex ultrasonography. The society for Vascular Surgery recommends preventative measures like compression devices and early mobility for all AAA surgery patients, alongside medical prophylaxis with low molecular weight heparin. As for PE, it's relatively rare, occurring in only about 1.4% of cases (1,15–17).

ERECTILE DYSFUNCTION

Open AAA repair may impair male sexual function, due to autonomic nerve and pelvic blood flow disturbances. Preserving blood supply to the internal iliac arteries and preventing damage to the autonomic nerves surrounding the aortic bifurcation is a crucial step in minimizing sexual dysfunction during open repair. Over time, advancements in technology have led to the development of new tools capable of addressing challenging anatomies and treating very high-risk patients. EVAR has become a potent alternative to traditional open repair surgery, establishing a less invasive approach in the treatment of AAA patients, with no risk of direct damage to autonomic nerves. Studies have shown that EVAR can result in similar rates of sexual dysfunction compared to open surgery, but patients tend to recover faster to their preoperative level of function with EVAR than with

open surgery. Sexual dysfunction in patients undergoing AAA repair remain poorly understood in terms of its significance and how often it occurs (18,19).

ABDOMINAL COMPARTMENT SYNDROME

Sometimes after the AAA repair, an abdominal compartment syndrome (ACS) occurs postoperatively, marked by intra-abdominal hypertension (IAH) greater than 20 mmHg coupled with new organ dysfunction or failure. It is treated by emergent abdominal decompression with temporary placement of “Bogota bag” (sterile urinary bag). Afterwards, the abdominal wall defect is treated by mesh repair (Figure 2) and NPWT therapy (Figure 3), or by plastic-reconstructive surgery (20,21).

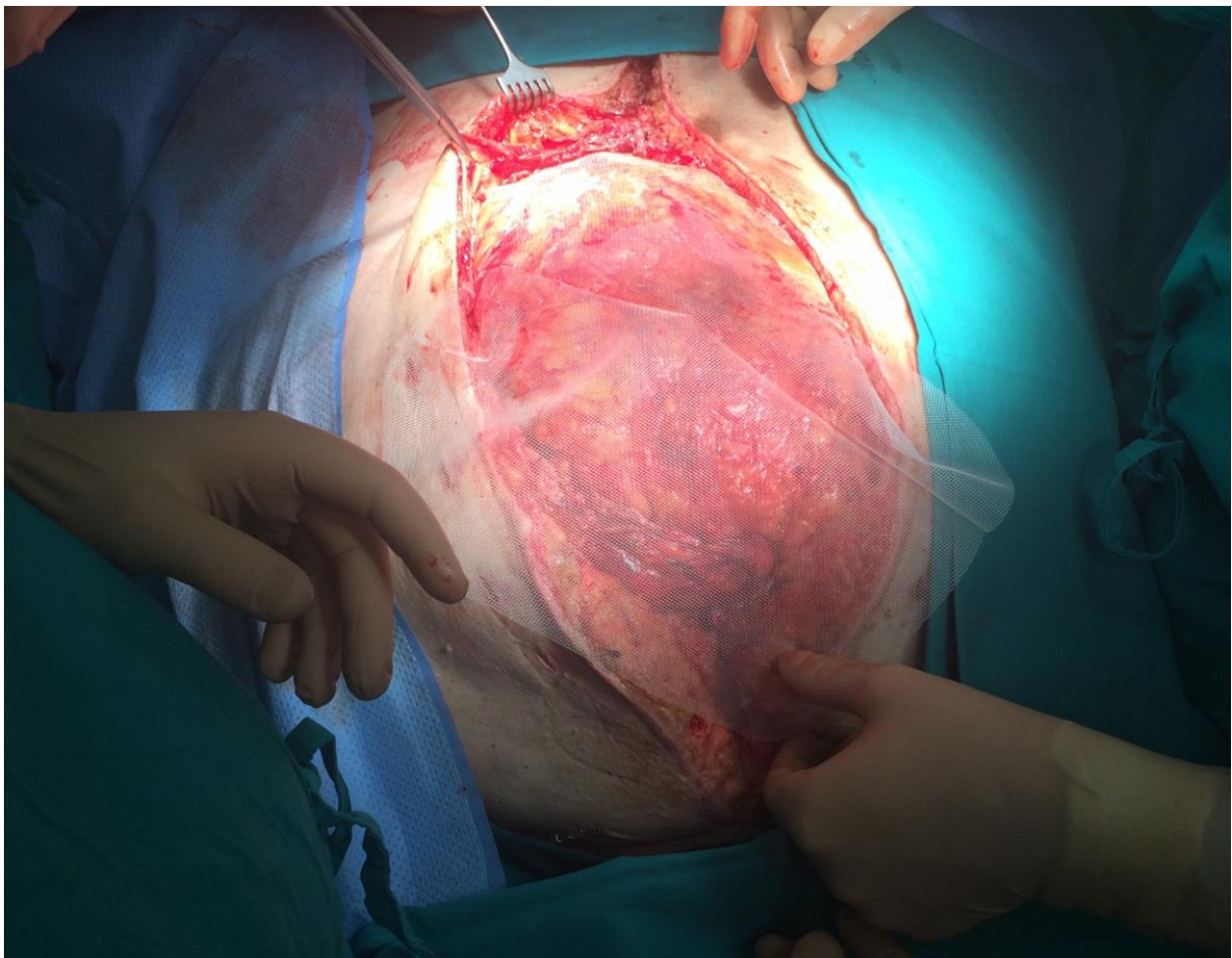


Figure 2. Mesh-repair of the abdominal wall after decompression for abdominal compartment syndrome after emergent AAA surgery (Source: Archives of the Division of Vascular Surgery, Department of Surgery, University Hospital Center Zagreb – “Rebro”, Croatia).

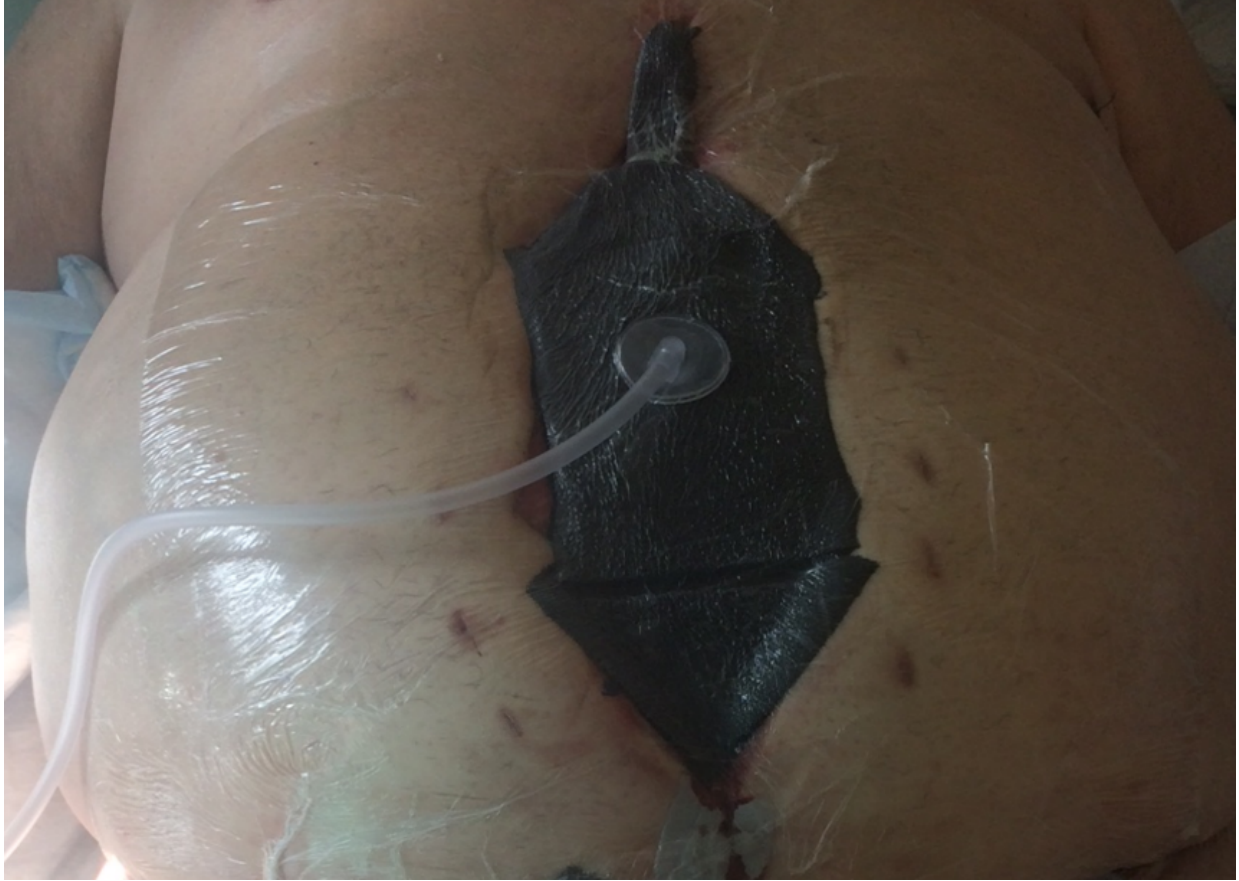

Figure 3. Negative pressure wound therapy in the treatment of abdominal wall defect after decompression due to abdominal compartment syndrome after emergent AAA repair (Source: Archives of the Division of Vascular Surgery, Department of Surgery, University Hospital Center Zagreb – “Rebro”, Croatia).

EVAR

EVAR is a procedure where a stent-graft is used to line the inside of the aorta. This device is made of materials like stainless steel or nitinol with a coating of impermeable fabric like polytetrafluoroethylene or polyester and is inserted through the femoral arteries under fluoroscopy guidance. By sealing both, above (proximal) and below (distal) the aneurysm, it blocks off the aneurysm from the systemic circulation. The aim is to prevent it from rupturing. Currently, three types of stent-graft configurations are in use: tube, bifurcated (Figure 4) and aorto-uni-iliac (AUI) (22).

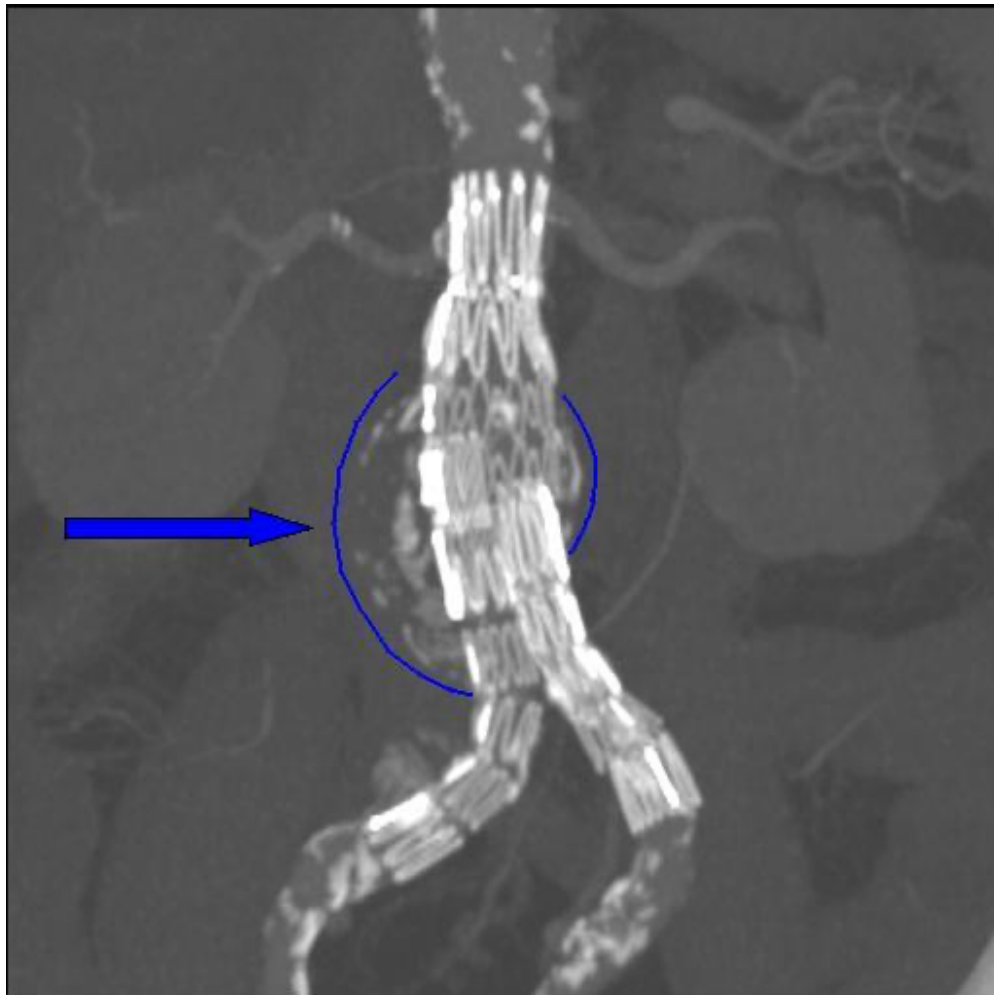


Figure 4. Dr. Haudebourg: Abdominal aortic endoprosthesis, CT scan [Internet]. (Source: Wikipedia, accessed: 02 June 2024). Available from: <https://en.wikipedia.org/wiki/File:Endovasc.jpg>.

TECHNIQUE

In the past, open exposure was followed by a common femoral artery puncture performed under direct view to gain femoral access. Like open reconstructions, the common femoral artery may be exposed through vertical or oblique skin incisions. To enable artery dissection, the fascia is cut vertically, regardless of the exact incision type. While either incision offers a great possible site for arterial puncture, the former permits better access for expansion of the cut, in case of a need to urgently revascularize the iliac artery or lower limb.

Two suture-mediated methods have been reported for percutaneous femoral access utilizing either the Abbott ProStar XL or Abbott Perclose ProGlide™ systems (Abbott, Abbot Park, IL, USA). Both techniques involved accessing the common femoral artery blindly or with ultrasound guidance using micropuncture or standard needles. With the micropuncture approach, a 4 French (Fr) sheath replaces the entry needle, followed by oblique angiography on the same side to confirm access to the common femoral artery. When using a standard entry needle, it should still be exchanged for a sheath to ensure optimal access to the anterior wall of the common femoral artery before proceeding.

When selecting and deploying a graft, it's important to consider factors like the length and the angulation of the proximal aortic neck (which should be at least 10-15 mm long with less than 60° of angulation), the diameter of the aorta at the proximal (up to 32 mm) and distal landing zones, the area of the aorta with the smallest diameter, the tortuosity and presence of steno-occlusive disease of the iliac arteries. The steps for deploying the graft may differ depending on the chosen endograft, but there are some shared aspects and a few distinctions worth noting. Deciding on which side to deliver, depends on factors like the diameter of the access vessels, the tortuosity and diameter of the iliac arteries and the length of the main body. If there's a narrowing in one iliac artery, delivering through the wider vessel would pose less risk of injury to the iliac artery (23,24).

COMMON PITFALLS/COMPLICATIONS OF EVAR AND HOW TO DEAL WITH THEM

ENDOLEAKS

Patients who have undergone EVAR require lifelong monitoring to check for any enlargement of the aneurysms and presence of endoleaks. Endoleaks happen when blood flows into the aneurysm sac after the placement of a stent. Identifying endoleaks is crucial because they can lead to the enlargement of the aneurysm and potential rupture. Various imaging methods are employed for surveillance, including conventional x-rays, computed tomography (CT), ultrasound, nuclear imaging, magnetic resonance angiography, and traditional angiography. Among these, triphasic computed tomographic angiography (CTA) is the most frequently used imaging method to assess the results of EVAR after surgery and is highly accurate in detecting endoleaks. There are five types of endoleaks (1,16,25).

Type I Endoleak

In type 1 endoleak there is persistent blood leakage into the sac from either the proximal (type 1A) or distal (type 1B) area surrounding the graft. Type 1 endoleaks are usually handled in the operating theater by deploying bare metal stents or by extending the proximal device to buttress the radial support in the neck, with or without the use of renal artery snorkeling or by encroachment procedures to maintain renal artery blood flow. Another technique for treating proximal type 1 endoleaks is the aortic wrap procedure, which involves wrapping a 12-mm Hemashield patch around the aortic neck. Reversing the distal common iliac artery dilation with type 1B endoleak involves either using a branched iliac device (Zenith or Gore) or occluding the hypogastric artery and extending it to the external iliac artery (1,26).

Type II Endoleak

Type II endoleak occurs when the sac around the graft continues to fill from side branches like the inferior mesenteric artery, lumbar arteries, or the middle sacral artery. Unlike type I and type III endoleaks, type II endoleaks often resolve on their own within 6-12 months after the stent-graft repair, with up to 80% resolving spontaneously. Additionally, the risk

of aneurysm rupture from a type II endoleak is low. Therefore, they are typically left untreated unless there's evidence of aneurysmal sac expansion. Persistent type II endoleaks are usually linked to a large endoleak cavity, flow between inflow and outflow arteries, and large open inferior mesenteric and lumbar arteries. The treatment of type II endoleaks remains controversial, with rates ranging from 10-25%. Treatment may involve embolization using coils or N-butyl cyanoacrylate glue. Embolization of the inferior mesenteric artery can be done through the superior mesenteric artery via the marginal artery of Drummond or by catheterizing the sac through the femoral artery and advancing the wire and catheter into the aneurysm sac (1,16, 26).

Type III Endoleak

Type III endoleak arises from fabric erosion or a breach between stent-graft parts. Although only modular grafts are prone to component separation, all devices can experience graft failure. Treating fabric-related type III endoleaks involves relining the stent-graft or bridging components to seal the defect. In instances where device parts are widely separated due to excessive twisting, accessing both components with a wire can be challenging. In such cases, trans brachial access with a snare may be beneficial. Plain x-rays are often more effective at identifying potential component separation as they offer a broader view of the stent graft's structure. During re-intervention, arteriography with a pigtail catheter in the main body of the stent graft and below the upper fixation site aids in distinguishing between type I and type III endoleaks (1,26).

Type IV Endoleak

Type IV endoleaks, arising from graft fabric porosity, are less common with modern stent grafts and typically emerge within 30 days of implantation. Generally, no treatment is necessary as they are temporary and self-resolving (1,26).

Type V Endoleak

Type V endoleak, also known as "endotension," refers to increased pressure within the aneurysm sac without a visible endoleak. It's thought to be caused by either an undetectable endoleak or the transmission of systemic pressure through thrombus. Such leaks are identified using CT scans. Treatment usually involves relining proximal and or distal extensions, if it can't be resolved this way surgical intervention is necessary (1,26).

STENT MIGRATION

Stent migration refers to the downward movement of the stent graft, which can lead to the loss of its fixation and cause a type IA endoleak. Less commonly, the iliac limbs of the stent graft may migrate upward, and in rare cases, the stent graft may move upwards to encroach upon the renal arteries. Factors such as neck angulation, shorter neck length, neck thrombosis, and larger neck diameter contribute to the likelihood of caudal migration. To prevent migration in patients with short and angulated necks, some manufacturers have adjusted their devices to enhance flexibility. Additionally, devices like Zenith and Excluder incorporate active fixation features such as barbs that embed into the aortic wall to provide additional security against migration (1).

GRAFT LIMB OCCLUSION

After EVAR of the abdominal aorta, reports indicate that around 2-4% of patients may experience kinking or occlusion of the endograft limbs. Most patients with limb occlusion experience symptoms like buttock, thigh, or calf claudication, while pain at rest is rare. Typically, the occluded limb can be reopened using techniques like thrombolysis or surgical thrombectomy, often with iliac stenting as an additional measure. When a kink is identified and treated with a stent, the chances of maintaining patency are high. Arteriography with oblique views can help pinpoint the issue, and intravascular ultrasound (IVUS) and pullback pressure measurement may detect graft infoldings, which may not be visible on arteriography. In cases where limb recanalization isn't possible, procedures like femoral-femoral bypass or axillofemoral bypass are performed to restore blood flow to the affected leg (1,16,27).

RENAL ARTERY OCCLUSION

Renal artery occlusion can happen due to either accidental coverage of the renal artery origins by the stent-graft or from embolization. Typically, stent-graft coverage occurs during the procedure itself, as delayed upward migration of the stent graft post-EVAR is rare. During the procedure, even with systemic heparinization, it may not be immediately obvious if the graft is impinging on the renal artery orifice. If discovered during surgery, attempts can be made to rescue renal stenting through either the femoral or brachial

approach to maintain renal artery flow. If detected later, surgical procedures like open hepatorenal or splenorenal bypass may be necessary. If it occurs bilaterally it is called “chimney” (1,28).

NECK DILATION

While the juxta renal part of the aorta is less susceptible to dilation compared to the infrarenal region, it can still expand post-EVAR, leading to issues like migration and type I endoleaks, increasing the risk of rupture. However, it's important not to oversize the stent graft excessively, as studies have shown that more than 30% oversizing with the Zenith stent graft could elevate the risks of migration and aneurysm expansion (1).

ENDOGRAFT INFECTION

According to the reports, 3.0% - 4.4% of instances after abdominal aortic EVAR, develop endograft infection. It is linked to significant mortality rates, which typically result from septic shock and range from 25 - 50%. If intraprocedural contamination is the origin of the endograft infection, the infection could develop soon after the procedure. If the infection develops later on following repair, it can be the consequence of an infection at a distant site that has colonized the endograft (Figure 5). Aortoenteric fistula development is a rare consequence of endograft infection. Typically, leukocytosis, fever, and back pain are prevalent in patients. Conservative treatment involves the administration of antibiotics. A more aggressive approach to treatment involves the removal of the endograft and replacing it with one that is coated with antibiotics. The clinical circumstance and the patient's comorbidities have a significant impact on the clinical strategy (16).

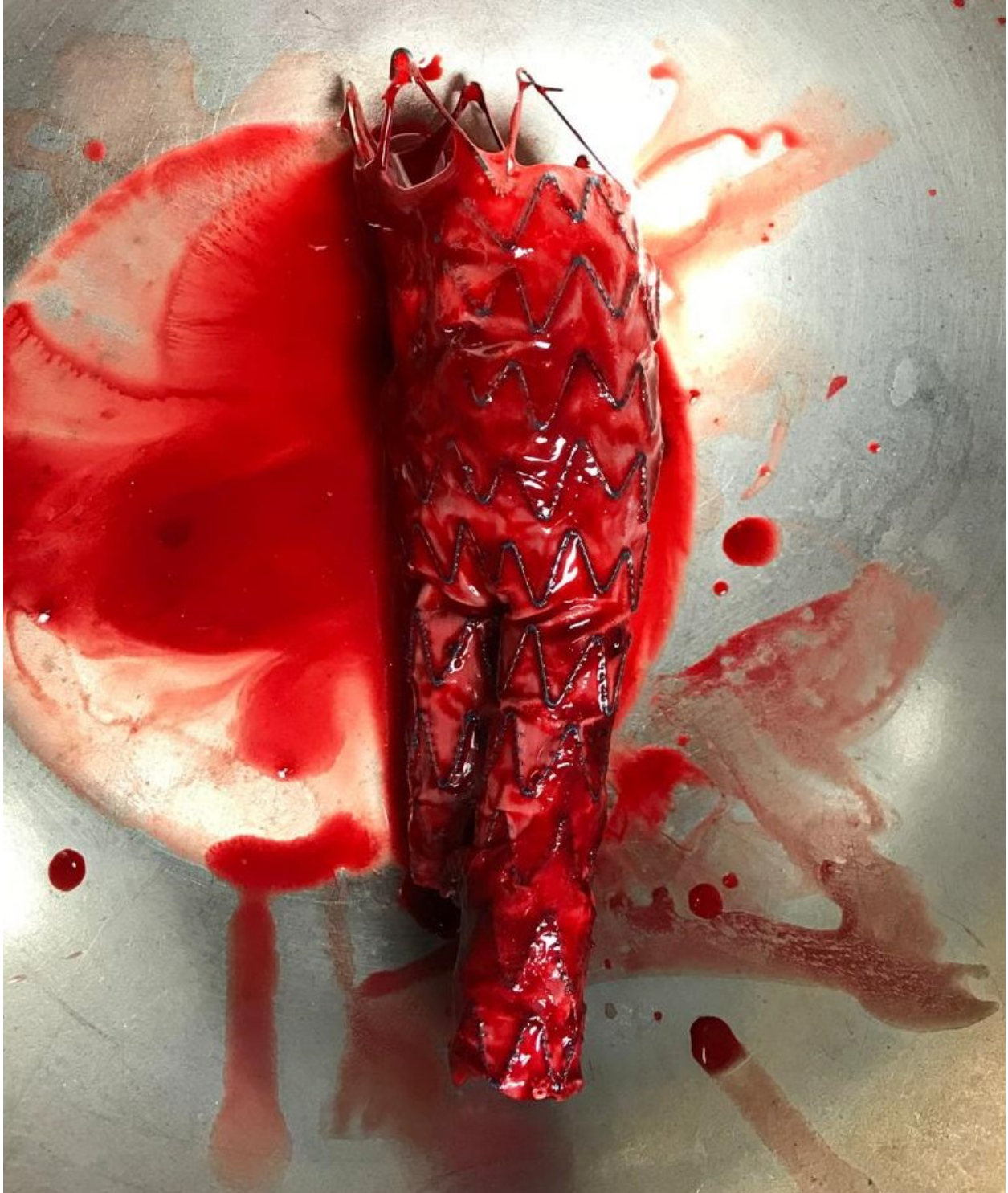

Figure 5. Infected aortic stent-graft after extraction (Source: Archives of the Division of Vascular Surgery, Department of Surgery, University Hospital Center Zagreb – “Rebro”, Croatia).

PELVIC ISCHEMIA

Pelvic ischemia can occur after EVAR of the abdominal aorta, particularly when internal iliac artery embolization is performed intentionally. This procedure is used to facilitate the extension of endograft limbs or to address internal iliac artery aneurysms. Symptoms experienced by patients' post-embolization include gluteal claudication, erectile dysfunction, rectal ischemia and perineal skin necrosis. Gluteal claudication affect around 31 - 35% of patients, while erectile dysfunction occurs in about 17 - 24% of them. Generally, symptoms improve spontaneously, though bilateral internal iliac artery embolization poses a higher risk of persistent symptoms. Various intraoperative strategies to prevent these complications include using iliac branched devices (IBE), surgical revascularization of the internal iliac artery, modifications to existing endografts, placement of parallel endografts. Other organs that may experience ischemia also include colon and spinal cord (1,16, 29).

STENT-GRAFT FATIGUE

The aortic stent graft faces ongoing mechanical strain during the heart's pumping cycle, leading to potential fractures in barbs and stent struts. While the original Zenith stent was made of stainless steel, newer stent grafts are typically crafted from nitinol due to its flexibility and ability to conform. Not every stent failure necessitates immediate action; there's typically enough redundancy in the number of barbs and stents per ring to maintain proper fixation and support even if some components are compromised (1).

POST-IMPLANTATION SYNDROME

Post-implantation syndrome, which can follow EVAR, is reported in about 13 - 60% of cases. It's believed to result from an immune-mediated reaction triggered by endothelial action in response to the endograft material. Symptoms are a consequence of systemic inflammatory response, marked by fever, leukocytosis and increased levels of inflammatory markers like CRP, TNF-alpha, and IL-6. The syndrome is easily treated with aspirin and then observed (16,30).

EVAR VERSUS OPEN REPAIR

Comparable results have been found for the two methods in previous trials that compared the management of AAAs using open repair versus endovascular stent grafting in terms of medium and long-term mortality and morbidity rates. However, EVAR has had lower rates of morbidity, including a decrease in the requirement for blood transfusions and shorter length of stay in the hospital and critical care unit. Because EVAR is a minimally invasive treatment, it is recommended for high-risk, elderly, or patients with comorbidities, especially when it is anatomically possible. AAAs have been treated using EVAR or open surgical repair; the effectiveness of these procedures have been assessed by comprehensive clinical research, with a primary focus on mortality and morbidity rates. Patients' quality of life may be improved by endovascular stent graft repair because of its minimally invasive nature. But also, on the other hand the drawbacks of EVAR include the need for close monitoring of the patient for endoleaks, graft failure, ongoing aneurysmal sac expansion, especially when one considers the possibility of complications necessitating open or endovascular re-surgery (31).

As a result of apparent benefits of EVAR, there has been the development of a new "endovascular-first" strategy for the treatment of ruptured AAA. The percentage of ruptured AAAs treated with EVAR has increased annually, while there is still a debate on the data supporting EVAR as the major treatment for ruptured AAA. It was apparent as stated previously that patients with EVAR were older and had higher BMIs than those with open surgery. This may be because EVAR is less invasive, hence it was chosen to treat patients with worse overall health. Compared to patients undergoing open surgery, these patients did however, have comparable mortality, less problems and quicker recovery times. Being consistent with earlier clinical data, patients receiving EVAR recovered more quickly and experienced fewer episodes of pneumonia and intestinal obstruction than those receiving open surgery. As a result, it can more effectively illustrate why EVAR would be the best strategy for ruptured AAA. Furthermore, other studies have shown that the EVAR patient group had a smaller aneurysmal neck angle and longer neck length. It's probable that selection bias is introduced since AAA's shape is better

suited for EVAR. Therefore, for patients with ruptured AAA, EVAR can offer a more stable technique regardless of hemodynamic statuses of the patient (32).

In a study by Yei and associates it was found that when open repair and EVAR were compared in the long run, open repair showed better outcomes. After 6 years open repair showed a 17% lower mortality rate, 24% lower chance of rupture, and a 33% lower risk of reintervention. Also, late ruptures have been speculated to have a significant role on determining long-term mortality of EVAR patients. EVAR has been shown to be associated with higher risk of late rupture, it is believed to be due to delayed type II endoleak, graft migration and graft infection (33).

A study by Moulakakis and associates found that individuals with high risk for open repair benefitted from EVAR, but both procedures had equivalent outcomes in low-risk patients (with appropriate anatomy for EVAR). As a result, there should be a trade-off between risks and benefits when considering between the two procedures. The patient's life expectancy, level of fitness and anatomic appropriateness influences the choice of repair. In case of a ruptured AAA the best technique based on growing evidence is EVAR over open repair (34).

CONCLUSION

While open repair has been the longstanding gold standard for abdominal aortic aneurysm, EVAR continues to be in the forefront. EVAR continues to evolve and advance in technology and techniques. EVAR being the less invasive option and demonstrating potentially better outcomes in selected patients. However, challenges such as long-term durability and complications managing EVAR are on-going, but the continuous refinement of surgical and endovascular techniques indicates a bright future, both for open and for endovascular aortic surgery. Ultimately, a personalized approach is needed and a focus on a patient-to-patient basis, and not one-size-fits-all ideology. This allows for the optimization of patient outcomes, minimizing of risks and the advancement in the field of vascular surgery.

ACKNOWLEDGEMENTS

I would like to thank my mentor, assistant professor Tomislav Meštrović, MD, PhD, from the Department of Vascular Surgery at the University Hospital Center Zagreb, KBC Rebro for his guidance, assistance and support during the process of writing my thesis.

I also want to thank professors, Predrag Pavić and Anko Antabak, for their time and assistance.

Lastly, I want to thank my family and friends, especially my mother, for their encouragement and support throughout my education.

REFERENCES

1. Sidawy AN, Perler BA. Rutherford's Vascular Surgery and Endovascular Therapy, 2-Volume Set, E-Book. 10th edition. Elsevier; 2022. 12036 p.
2. Obel LM, Diederichsen AC, Steffensen FH, Frost L, Lambrechtsen J, Busk M, et al. Population-Based Risk Factors for Ascending, Arch, Descending, and Abdominal Aortic Dilations for 60-74-Year-Old Individuals. *J Am Coll Cardiol*. 2021 Jul 20;78(3):201–11.
3. Sakalihasan N, Limet R, Defawe OD. Abdominal aortic aneurysm. *The Lancet* [Internet]. 2005 [cited 2024 Jun 15];365(9470). Available from: <https://orbi.uliege.be/handle/2268/114255>
4. Michel JB, Martin-Ventura JL, Egidio J, Sakalihasan N, Treska V, Lindholt J, et al. Novel aspects of the pathogenesis of aneurysms of the abdominal aorta in humans. *Cardiovasc Res*. 2011 Apr 1;90(1):18–27.
5. Anidjar S, Kieffer E. Pathogenesis of Acquired Aneurysms of the Abdominal Aorta. *Ann Vasc Surg*. 1992 May 1;6(3):298–305.
6. Altobelli E, Rapacchietta L, Profeta VF, Fagnano R. Risk Factors for Abdominal Aortic Aneurysm in Population-Based Studies: A Systematic Review and Meta-Analysis. *Int J Environ Res Public Health*. 2018 Dec 10;15(12):2805.
7. Gilbert R, Upchurch J, Schaub TA. Abdominal Aortic Aneurysm. *Am Fam Physician*. 2006 Apr 1;73(7):1198–204.
8. Woodrow P. Abdominal aortic aneurysms: clinical features, treatment and care. *Nurs Stand R Coll Nurs G B* 1987. 2011 Aug 17;25(50):50–7; quiz 58.
9. Patel SN, Kettner NW. Abdominal Aortic Aneurysm Presenting as Back Pain to a Chiropractic Clinic: A Case Report. *J Manipulative Physiol Ther*. 2006 Jun 1;29(5):409.e1-409.e7.
10. Khan MA, Nejim B, Faateh M, Mathlouthi A, Aurshina A, Malas MB. Association of abdominal aortic aneurysm diameter indexed to patient height with symptomatic presentation and mortality. *J Vasc Surg*. 2022 May 1;75(5):1606-1615.e2.
11. Wanhainen A, Van Herzele I, Bastos Goncalves F, Bellmunt Montoya S, Berard X, Boyle JR, et al. Editor's Choice -- European Society for Vascular Surgery (ESVS) 2024 Clinical Practice Guidelines on the Management of Abdominal Aorto-Iliac Artery Aneurysms. *Eur J Vasc Endovasc Surg*. 2024 Feb;67(2):192–331.
12. Kostun ZW, Malik RK. Screening for abdominal aortic aneurysms. *Clin Imaging*. 2016 Mar 1;40(2):321–4.

13. Woo EY, Damrauer SM. Abdominal Aortic Aneurysms. Open Surgical Treatment. [Internet]. Thoracic Key. 2016 [cited 2024 Jun 15]. Available from: <https://thoracickey.com/abdominal-aortic-aneurysms-5/>
14. Blackstock CD, Jackson BM. Open Surgical Repair of Abdominal Aortic Aneurysms Maintains a Pivotal Role in the Endovascular Era. *Semin Interv Radiol*. 2020 Oct;37(4):346–55.
15. Studzińska D, Polok K, Chwała M, Zaczek M, Szczeklik W. The incidence of cardiovascular and other major complications after open abdominal aortic surgery. *Pol Heart J Kardiologia Pol*. 2023;81(9):870–7.
16. Daye D, Walker TG. Complications of endovascular aneurysm repair of the thoracic and abdominal aorta: evaluation and management. *Cardiovasc Diagn Ther*. 2018 Apr;8(Suppl 1):S138–56.
17. Zatevakhin II, Matyushkin AV, Mustafin AKh, Frantsevich AM, Bogomazov IYu, Zabadaeva OB. Endovascular surgery for complications after open surgery of abdominal aorta. *Khirurgiya Zhurnal Im NI Pirogova*. 2023;(10):124.
18. Donato G, Pasqui E, Gargiulo B, Casilli G, Ferrante G, Galzerano G, et al. Prevalence of Erectile Dysfunction in Patients With Abdominal Aortic Aneurysm: An Exploratory Study. *Front Cardiovasc Med*. 2022 Feb 28;
19. Xenos ES, Stevens SL, Freeman MB, Pacanowski JP, Cassada DC, Goldman MH. Erectile Function after Open or Endovascular Abdominal Aortic Aneurysm Repair. *Ann Vasc Surg*. 2003 Sep 1;17(5):530–8.
20. Bajardi G, Pecoraro F, Mirabella D, Bracale U, Bellisi M. Abdominal Compartment Syndrome (ACS) after Abdominal Aortic Aneurysm (AAA) open repair. *Ann Ital Chir*. 2009 Sep 1;80:369–74.
21. Teicher EJ, Pasquale MD, Cipolle MD. Abdominal Compartment Syndrome. *Oper Tech Gen Surg*. 2008 Mar;10(1):39–59.
22. England A, Mc Williams R. Endovascular Aortic Aneurysm Repair (EVAR). *Ulster Med J*. 2013 Jan;82(1):3–10.
23. Phade SV, Garcia-Toca M, Kibbe MR. Techniques in Endovascular Aneurysm Repair. *Int J Vasc Med*. 2011;2011:964250.
24. Elahwal M, Nash T, Yusuf SW. Through and Through Wire Technique for Stabilization of EVAR Main Body during Contralateral Limb Deployment. *Ann Vasc Surg*. 2021 Jul 1;74:515–7.
25. White SB, Stavropoulos SW. Management of Endoleaks following Endovascular Aneurysm Repair. *Semin Interv Radiol*. 2009 Mar;26(1):33–8.

26. Buth J, Harris PL, van Marrewijk C, Fransen G. The significance and management of different types of endoleaks. *Semin Vasc Surg.* 2003 Jun 1;16(2):95–102.
27. Shintani T, Obara H, Matsubara K, Hayashi K, Hayashi M, Ono S, et al. Impact of Stent Graft Design on External Iliac Artery Limb Occlusion Rates After Endovascular Aneurysm Repair: Post-hoc Analysis of a Japanese Multicentre Database. *Eur J Vasc Endovasc Surg.* 2019 Dec;58(6):839–47.
28. Franchin M, Fontana F, Piacentino F, Tozzi M, Piffaretti G. Postoperative “Chimney” for Unintentional Renal Artery Occlusion after EVAR. *Case Rep Vasc Med.* 2014;2014:170198.
29. Jean-Baptiste E, Brizzi S, Bartoli MA, Sadaghianloo N, Baqué J, Magnan PE, et al. Pelvic ischemia and quality of life scores after interventional occlusion of the hypogastric artery in patients undergoing endovascular aortic aneurysm repair. *J Vasc Surg.* 2014 Jul 1;60(1):40-49.e1.
30. Martinelli O, Girolamo AD, Belli C, Gattuso R, Baratta F, Gossetti B, et al. Incidence of Post-Implantation Syndrome with Different Endovascular Aortic Aneurysm Repair Modalities and Devices and Related Etiopathogenetic Implications. *Ann Vasc Surg.* 2020 Feb 1;63:155–61.
31. Akbulut M, Aksoy E, Kara İ, Cekmecelioglu D, Koksall C. Quality of Life After Open Surgical versus Endovascular Repair of Abdominal Aortic Aneurysms. *Braz J Cardiovasc Surg.* 2018 May 1;33(3):265–70.
32. Wang T, Zhao J, Yuan D, Ma Y, Huang B, Yang Y, et al. Comparative effectiveness of open surgery versus endovascular repair for hemodynamically stable and unstable ruptured abdominal aortic aneurysm. *Medicine (Baltimore).* 2018 Jul 6;97(27):e11313.
33. Yei K, Mathlouthi A, Naazie I, Elsayed N, Clary B, Malas M. Long-term Outcomes Associated With Open vs Endovascular Abdominal Aortic Aneurysm Repair in a Medicare-Matched Database. *JAMA Netw Open.* 2022 May 13;5(5):e2212081.
34. Moulakakis KG, Dalainas I, Kakisis J, Mylonas S, Liapis CD. Endovascular Treatment versus Open Repair for Abdominal Aortic Aneurysms: The Influence of Fitness in Decision Making. *Int J Angiol Off Publ Int Coll Angiol Inc.* 2013 Mar;22(1):9–12.

BIOGRAPHY

Shalane Perera, was born in Dusseldorf, Germany, in 1992. She attended high school in Sri Lanka, where she took part in athletic contests as well as science fairs. After graduating from high school, she attended the University of Oregon and obtained a bachelor's degree in biology. Then she went on to attend the University of Zagreb, School of Medicine, in the MSE program.