

# Dacryocystorhinostomy Ab Externo

---

Yamin, Zohar

Master's thesis / Diplomski rad

2024

Degree Grantor / Ustanova koja je dodijelila akademski / stručni stupanj: **University of Zagreb, School of Medicine / Sveučilište u Zagrebu, Medicinski fakultet**

Permanent link / Trajna poveznica: <https://um.nsk.hr/um:nbn:hr:105:351979>

Rights / Prava: [In copyright](#)/[Zaštićeno autorskim pravom.](#)

Download date / Datum preuzimanja: **2024-12-14**



Repository / Repozitorij:

[Dr Med - University of Zagreb School of Medicine Digital Repository](#)



**UNIVERSITY OF ZAGREB  
SCHOOL OF MEDICINE**

**Zohar Yamin**

# **Dacryocystorhinostomy Ab Externo**

**GRADUATE THESIS**



Zagreb, 2024.

This graduation thesis was made at the Department of ophthalmology and Optometry, University Hospital Centre Zagreb, School of Medicine University of Zagreb.

Mentor: Asst. Prof. Jelena Juri Mandić

This paper was submitted for evaluation in the academic year 2023/2024.

## **Abbreviations:**

ALC- Anterior lacrimal crest

CC- Common canaliculus

CNLDO- Congenital nasolacrimal duct obstruction

DCR- Dacryocystorhinostomy

EN-DCR- Endonasal Dacryocystorhinostomy

EX-DCR- External Dacryocystorhinostomy

FEDT- Functional endoscopic dye test

IM- Inferior meatus

IT- Inferior turbinate

LA- lacrimal area

LA- Lacrimal sac

LA-DCR- Laser-assisted Dacryocystorhinostomy

MCT- Medial canthal tendon

NLD- Nasolacrimal duct

NLDO- Nasolacrimal duct obstruction

PANDO- Primary acquired nasolacrimal duct obstruction

PLC- Posterior lacrimal crest

SALDO- Secondary acquired lacrimal drainage obstruction

SANDO- Secondary acquired nasolacrimal duct obstruction

## Summary

### Dacryocystorhinostomy Ab Externo

External dacryocystorhinostomy (DCR) surgery is a widely employed procedure in ophthalmology for the treatment of nasolacrimal duct obstruction (NLDO). This surgical intervention involves modifying the nasal anatomy to restore the normal drainage of tears. Two primary techniques are utilized: the external approach and the endoscopic approach.

The external approach, considered the gold standard in DCR surgery, offers distinct advantages owing to its comprehensive visualization of the involved anatomy. This method requires a creation of small incision in the lateral aspect of the nose, providing direct access to the nasolacrimal system. The surgeon benefits from a clear and unobstructed view, facilitating precise identification and removal of any possible obstructive material within the lacrimal sac. Consequently, the external approach ensures a higher likelihood of successful outcomes.

Moreover, the external approach permits optimal exposure of the lacrimal sac and nasal bone, which may necessitate manipulation during the procedure. This unimpeded access enables meticulous intervention, ensuring thorough eradication of pathological elements and promoting favorable postoperative results.

Furthermore, the external approach is particularly advantageous in cases necessitating revision surgery or those characterized by complex anatomical variations. It enables the surgeon to navigate through scar tissue or previous surgical alterations, facilitating meticulous correction of the lacrimal drainage.

While the endoscopic approach has gained popularity due to its minimally invasive nature, it may not be universally applicable. The limited visualization and restricted access inherent to the endoscopic technique may impede the surgeon's ability to execute precise adjustments and address intricate anatomical anomalies.

## SAŽETAK

### Dakriocistorinostomija Vanjski Pristup

Dakriocistorinostomija Vanjski Pristup (DCR) široko je korišten postupak u oftalmologiji za liječenje obstrukcije suznog aparata. Ova kirurška intervencija uključuje modificiranje nosne anatomije kako bi se uspostavila normalna drenaža suza. Koriste se dvije osnovne tehnike: vanjski pristup i endoskopski pristup.

Vanjski pristup, koji se smatra zlatnim standardom u vanjskoj DCR kirurgiji, nudi različite prednosti zahvaljujući sveobuhvatnoj vizualizaciji nazalne anatomije. Ova metoda podrazumijeva formiranje malog reza u medijalnom očnom kutu, čime se omogućuje izravan pristup proksimalnom dijelu suznog puta. Kirurg ima koristi od jasnog i neometanog pogleda, olakšavajući preciznu identifikaciju i uklanjanje eventualne opstruktivne lezije unutar suzne vrećice. Posljedično, vanjski pristup osigurava veću vjerojatnost uspješnih ishoda.

Štoviše, vanjski pristup omogućuje optimalno izlaganje suzne vrećice i nosne kosti, što može zahtijevati manipulaciju tijekom postupka. Taj nesmetan pristup omogućuje minucioznu intervenciju, osiguravajući temeljito iskorjenjivanje patoloških elemenata i pospješujući povoljne postoperativne rezultate.

Nadalje, vanjski pristup posebno je koristan u slučajevima koji zahtijevaju reviziju kod onih koje karakteriziraju složene anatomske varijacije. Kirurgu se tim pristupom olakšava navigacija kroz ožiljno tkivo ili uzrokovane prethodnim kirurškim intervencijama, olakšavajući precizno uspostavljanje novog puta za drenažu suza.

Iako je endoskopski pristup stekao popularnost zbog svoje minimalno invazivne prirode, nije univerzalno primjenjiv. Ograničena vizualizacija i ograničeni pristup svojstveni endoskopskoj tehnici mogu spriječiti kirurgovu sposobnost da izvrši precizne prilagodbe i riješi zamršene anatomske anomalije.

## Contents

Summary.....	
SAŽETAK.....	
Introduction .....	1
History of the procedure .....	2
Anatomy and physiology of the lacrimal system.....	4
Indications for dacryocystorhinostomy .....	11
External dacryocystorhinostomy - technique.....	17
Surgical follow up .....	29
Complications intra/post operative .....	31
Conclusion .....	33
References.....	34

## Introduction

External dacryocystorhinostomy (DCR) is a commonly performed surgery in ophthalmology to address nasolacrimal duct obstruction (NLDO). Nasolacrimal duct obstruction (NLDO) is a common condition characterized by the blockage or narrowing of the nasolacrimal duct, resulting in epiphora. NLDO can cause significant discomfort and visual impairment. Surgical interventions, such as external dacryocystorhinostomy (DCR), are often necessary to restore normal tear drainage (1).

The external approach involves creating a small incision between medial canthus of the eye and lateral aspect of the nose, providing direct access to the nasolacrimal system. The external DCR technique is considered the gold standard due to its superior outcomes and efficacy in complex cases.

A study by Tarbet and Custer evaluated the success, patient satisfaction, and economic cost of external DCR. They found that external DCR had a high success rate, with 95% of patients experiencing resolution of epiphora and improvement in symptoms. Patient satisfaction was also high, with 98% of patients reporting satisfaction with the surgery. Additionally, the economic cost of external DCR was found to be lower comparable to other surgical options for NLDO (2).

However, it is important to note that external DCR surgery carries potential risks and complications, including bleeding, infection, liquorrhea, scarring, and failure to achieve adequate tear drainage. Thorough preoperative evaluation and patient selection, as well as meticulous surgical technique and postoperative care, are crucial in ensuring successful outcomes (2).



## History of the procedure

The surgical treatment of dacryocystitis has a rich history that can be traced back to ancient times. In the first century, Celsus described a method of puncturing the lacrimal bone with heated cautery to establish an artificial tube into the nose, while in the second century, Galen carried out a similar procedure. Advancements in lacrimal physiology and nasal and lacrimal anatomy during the seventeenth century onwards, led to the development of more sophisticated techniques.

In the early 20th century, various approaches were attempted for the treatment of dacryocystitis. Early methods included, draining the lacrimal sac into the maxillary sinus or using intranasal approaches, with success rates ranging from 63% to 100% in different studies (3,4). External dacryocystorhinostomy (DCR) procedures were also explored during this time.

The earliest operation that would resemble a modern external DCR was attempted by Woolhouse in England in the 18th century (5). By the early 20th century, others attempted to open the sac without removing most of it. Various stenting materials were used to maintain the patency of the ostium. These included, leaving a thread, placing a gold cannula, placing a ball of catgut suture and placing gauze wicks which were periodically exchanged. Recreating a duct by placing a skin graft wrapped around a piece of wax had also been tried. Some authors reported success rates of 70–85% (3).

A significant milestone in the history of DCR was reached in 1904 with Toti's publication, which is considered the first modern description of external DCR (6). Toti's technique involved making an external incision, elevating the periosteum and sac, creating a bony ostium, and excising the medial wall of the sac. In 1914, suturing of the sac and nasal mucosal flaps was introduced (3).

Further advancements were made in the 1920s by Depuy-Dutemps (Figure 1.), Bourguet, and Ohm. They advocated for suturing both the posterior and anterior flaps in

DCR procedures. Depuy-Dutemps and Bourguet reported a success rate of 94% with their modified technique (6).

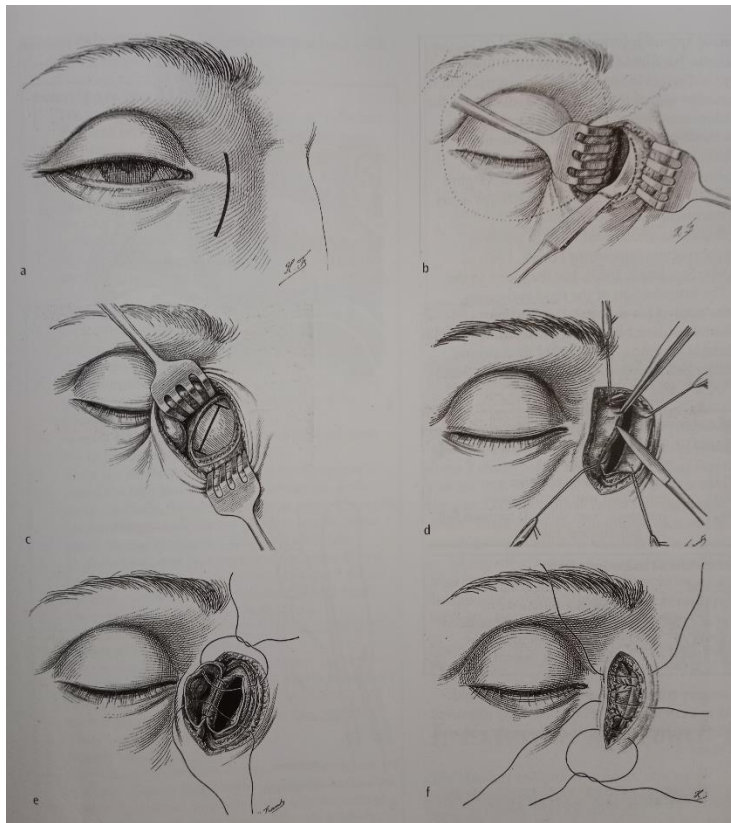


Figure 1. Original drawing of external dacryocystorhinostomy surgery (from Dupuy-Dutemps, 1921) (6).

Throughout the 20th century, several modifications were introduced to address challenges in flap suturing and bleeding control during DCR procedures. These modifications included, different incision placements, techniques for elevating the medial canthal tendon, and the use of tools such as chisels, rongeurs, bone trephines, or burrs. There were also debates regarding the placement of stenting material, flap sutures, cautery of posterior flaps, and whether to suture the posterior flaps.

Overall, the history of dacryocystitis surgical treatment is marked by significant milestones achieved by pioneering individuals such as Celsus, Galen, Toti, Depuy-Dutemps, and Bourguet, whose contributions have shaped the techniques and approaches used in modern DCR procedures (3–5,7).

# Anatomy and Physiology of the lacrimal system

## **Part A: Anatomy of the lacrimal system**

The lacrimal system is responsible for the production (secretion), distribution, collection and drainage of tears, which are essential for maintaining the health and lubrication of the ocular surface (8). Tears are produced by the main lacrimal glands and by the glands of Wolfring and Krause, which are the accessory lacrimal tissues. Blinking of the eyelid distributes the tears over the surface of the eye and advance the tear meniscus along the eyelid margins. The tears enter the puncta at the medial ends of the eyelids, passing into the lower and upper canaliculi and through the common canaliculus into the lacrimal sac. The tears drain from the lacrimal sac into the nasolacrimal duct and, through its inferior opening under the inferior turbinate (IT) into the inferior meatus (IM) and basically into the floor of the nose (9). The relations of the lacrimal sac and nasolacrimal duct, to the structures of the lateral nasal wall and the ethmoid sinus, are essential for understanding DCR surgery. In this part of the Anatomy, the review will be subdivided into soft tissues and bones of the skull, which are important to understanding the procedure and techniques of the DCR surgery.

### **Soft tissues**

The lacrimal gland, eyelids, puncta and canaliculi, lacrimal sac, nasolacrimal duct, and nose are the six key soft tissues (Figure 2.).

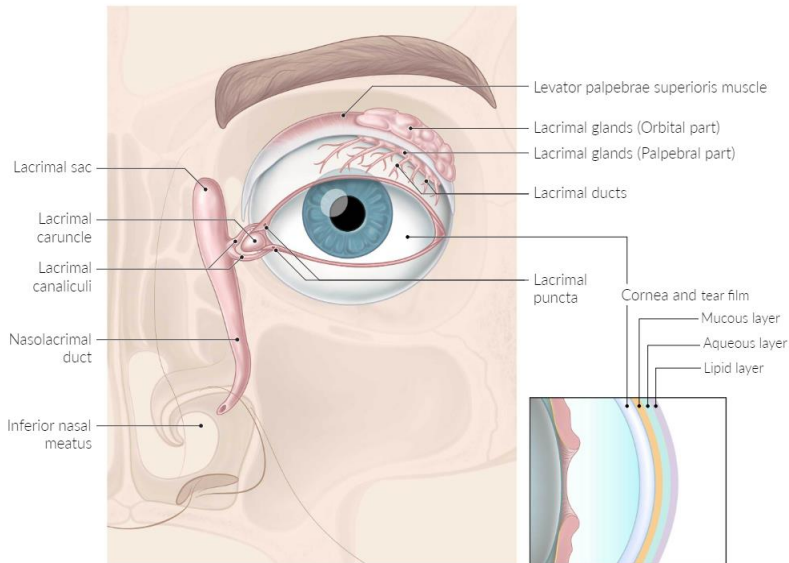


Figure 2. Lacrimal apparatus and tear film layers. Main image: ventral view of lacrimal apparatus; inset: sagittal section of cornea and tear film (10).

Tears are produced by the **lacrimal glands**, located in the upper outer corner of the each orbit. The gland is divided into two main lobes: the orbital lobe and the palpebral lobe (8). The orbital lobe is situated within the orbit, while the palpebral lobe is located within the upper and lower eyelids (fig 1.1). The lacrimal gland is innervated by the parasympathetic fibers of the facial nerve, which stimulate tear production. These fibers synapse in the pterygopalatine ganglion before reaching the gland. Additionally, sympathetic fibers from the superior cervical ganglion also contribute to lacrimal gland innervation, regulating tear production under certain conditions (11). The accessory lacrimal glands of Krause and Wolfring are found mainly in the upper conjunctival fornix and tarsal conjunctiva (8).

The distribution of tears is controlled by the **eyelids**, and tear drainage is aided by the orbicularis medial heads that surround the lacrimal sac (9). The eyelids can be divided by lamellae: anterior, middle and posterior. Each lamella consist of few layers and structures. The anterior lamella contain the orbicularis oculi muscle and the levator aponeurosis (upper eyelid). The middle lamella in the upper eyelid contain the levator aponeurosis and muscle, Muller's superior tarsal muscle, while in the lower eyelid the lamella contain the capsulopalbebral fascia, smooth muscle similar to Muller's superior

tarsal muscle and the pre-capsulopalbebral fascia fat pad. The posterior lamella contain the tarsal plate and the conjunctiva (8,9). The **orbicularis oculi** muscle is composed of two parts one is the orbital portion and the other is the palpebral portion, which has preseptal and pretarsal parts. The insertion of the orbicularis at the medial canthus around the lacrimal sac are called heads. The medial heads are an important part of the lacrimal system, therefore the area around the medial canthus is called the lacrimal area (LA) (9). In 1961, Jones demonstrated the insertion of the superficial and deep heads of the orbicularis around the lacrimal sac and into the posterior lacrimal crest (12). The deep heads of the pretarsal orbicularis are known as Horner's muscle, which is part of the lacrimal pump. Horner published in 1823, original drawing and description of this muscle (13). The LA is between the puncta and the medial canthal tendon (MCT), a fibrous extension of orbicularis forward onto the flat part of the ascending frontal process of the maxilla, and inserts as far as the naso-maxillary suture. As mentioned before, the superficial and deep heads of the two palpebral parts of orbicularis, surround the canaliculi and lacrimal sac. This muscle heads are fixed strongly to the bone, and therefore on blinking the eyelids are pulled medially and posteriorly, aid in propelling the tear meniscus along the lower eyelid, compress the canaliculi and dilate the lacrimal sac (lacrimal pump according to Jones) (12). The MCT blends with the periosteum in the superior part of lacrimal fossa. It is perforated by the canaliculi. The **puncta** lie on the top of a small elevation called lacrimal papilla, and surrounded by a ring of fibrous tissue. They located at the medial end of both upper and lower eyelids, and open into the lacrimal lake adjacent to the junction of the plica semilunaris and bulbar conjunctiva. The lacrimal papilla are surrounded by pretarsal orbicularis fibers, which become deep heads at the posterior lacrimal crest and therefore pull the puncta medially and posteriorly as described above (9). The proximal **canaliculi** are short and vertically (approx. 2mm), and then widen to form ampulla, before bending medially in 90 degrees to form the horizontal part (approx. 9mm). The lower canaliculus is slightly longer than the upper, reflecting the more lateral position of lower punctum (between 0.5-1.0mm). The canaliculi curve posteriorly and medially towards the lacrimal sac, in keeping with normal medial eyelid curvature. After passing the MCT they bend anteriorly and meet to form the common canaliculus (CC) (0-5mm

long) (9). The CC is directed anteriorly before it enters the lacrimal sac, forming an acute angle with the sac (>45 degree). As shown by Schaeffer in 1912, based on histological serial sections and were confirmed by Tucker in 1996, from rigid methylmethacrylate casts of the canaliculi, sac and duct (14,15). Those anatomical orientation and angles of the canaliculi and CC, are important consideration in probing into the sac when necessary. The acute angle of entry of the CC into the sac, creates kind of a valve across the opening- the valve of Rosenmüller (9). The **lacrimal sac** is a small reservoir located within the lacrimal fossa, a depression in the lacrimal bone on the antero-medially side of the orbit (8). The sac is 12-15mm tall, 4-6mm antero-posteriorly, but only 2-3mm wide. The entrance of the CC is 3-5mm below the apex of the sac so-called the fundus, and that below the body. The lacrimal fossa is lined by thin orbital periosteum, which can be easily lifted off during external DCR. The lacrimal sac is enveloped on its supero-medial aspect by lacrimal fascia derived from MCT, which fuses with the periosteum. In addition, thick lacrimal fascia surrounds the sac laterally. Since the fascia is weak and can be stretched anteriorly, inferior to the anterior limb of MCT due to the fascia connection of Horner's muscle, typically swelling of lacrimal sac is visible. Lacrimal sac fistulas, track anteriorly through the soft lacrimal fascia and orbicularis to the skin surface (9,16). At the end of the lacrimal sac, the proximal part of **nasolacrimal duct** (NLD), which lies just within the lacrimal fossa, continue downwards to the nose floor exit at the IM. The NLD has an interosseous part (approx. 12mm) and an intermeatal part (approx. 5mm). It has anterior-posterior orientation and slopes laterally, keeping the slope of the lateral nasal wall. NLD opens on the anterior part of the lateral wall in the inferior meatus. The duct opening varies in size and shape, with variable fold of mucosa, the valve of Hasner. NLD is embedded in the bony nasolacrimal canal formed by: maxillary bone, lacrimal bone and inferior turbinate bone. Contrary to the lacrimal sac, the lumen of NLD is narrower and the wall is thicker. The lacrimal sac and the NLD seems to appear anatomically continuous, but are separate structures. From the outside, the difference lies in the more numerous and prominent veins surrounding the duct than the sac. On the inside of the duct, there is focal narrowing (valve of Krause) (8,9,14). Regarding the sino-nasal anatomy, the most important part of the **nose** the lacrimal surgeon should keep in mind is, the lateral nasal

wall and its structures. The lower lacrimal system (lacrimal sac and NLD) is in close proximity to the lateral nasal wall throughout its course. The nose protrudes from the mid face. The soft tissues are supported by a skeleton, consisting of the two nasal bone superiorly and lateral cartilage inferiorly. The nasal septum forms most of the nasal bridge. Nasal fractures may be associated with bony fractures around the nasolacrimal canal. The nasal cavity or space is divided by the septum into two similar but asymmetrical parts. Each nasal space has a floor, narrow roof, a lateral nasal wall and medially the septum. The important structures on the lateral wall are: superior turbinate, middle turbinate, inferior turbinate and corresponding meatuses especially the inferior meatus, which the NLD opening is approximately 1 cm posterior to the anterior tip of the inferior turbinate. It may have mucosal flap as mentioned before – the valve of Hasner. The relation of the lacrimal sac to the lateral wall is variable. The sac may be relatively high, normal or low compare to the adjacent anterior nasal space. This simply reflect different sized of nasal space and mid-face body development (9).

### **Osteology**

Maxilla, lacrimal, inferior turbinate and ethmoid bones, are four bones which are associated with the lacrimal drainage system. In addition, there are two bony lacrimal region, one is orbital, lacrimal fossa and the other is nasal, nasolacrimal duct which end in the inferior meatal. The lacrimal fossa is bordered by, the anterior lacrimal crest (ALC) on the frontal process of the maxilla, and posteriorly by the posterior lacrimal crest (PLC) on the lacrimal bone. Inferiorly, the fossa becomes completely encircled by bone, when it became the nasolacrimal duct. The maxilla and lacrimal bones forming the fossa, join at the lacrimal-maxillary suture within the fossa. The shape of the fossa varies. If the lacrimal bone predominates, the floor is very weak and easily removed during lacrimal surgery, on the other hand if the maxilla predominates, the floor is very dense. In 1911, Whitnall demonstrated that ethmoid air cells are located medially to the upper part of the fossa, in approximately 90 per cent of skulls, which later was supported by Blaylock et al. in 1990, with the help of more recent computer tomographic evaluation (17,18). The nasolacrimal canal starts in the infero-anterior orbital floor, approximately 5 mm from the rim. It descends interosseously approximately 12 mm long

and incline posteriorly at 15 degree angle and laterally (depend on the size of the face), towards the first molar tooth. The width of the canal is narrower in women than in men. As Groessl postulated, that fact may partly explain the higher incidence of nasolacrimal duct obstruction (NLDO) in women (19). The maxilla partly encircle the opening of the canal. In the interosseous portion, the lateral two third of the canal is formed by the medial wall of the maxilla, while the medial aspect is formed by the descending portion of the lacrimal bone in its upper part, and by the inferior turbinate in its lower part. The lacrimal bone also called, the ossa unguis, as its size, shape and thin profile resembles a large toenail. It has an orbital aspect and a nasal aspect, with superior, inferior, medial and lateral sides. The posterior half (posterior to PLC) is thicker than the anterior half, which form part of the lacrimal fossa. The process hamalaris (bony hook) at the lower end of the PLC contributes in part to the opening of nasolacrimal canal.

### **Part B: Physiology of the lacrimal system**

The tear film (approximately 40  $\mu\text{m}$  thick) is composed of three layers: the **lipid**, **aqueous**, and **mucin** layer. Each layer has a different composition that dictates its function. The lipid layer (about 0.1  $\mu\text{m}$  thick), which is the outermost layer, is composed of meibum, a mixture of lipids secreted by the meibomian glands with the help of glands of Zeis and Moll. It functions to reduce evaporation of the aqueous layer and prevent overflow of tears onto the eyelids. The aqueous layer (about 7  $\mu\text{m}$  thick and 20 per cent of total thickness), which is the middle layer, is composed of water, electrolytes, and proteins. Aqueous tears are secreted by the lacrimal gland and by the accessory glands of Krause and Wolfring. It functions to provide nutrients and oxygen to the cornea and conjunctiva, as well as remove waste products. The mucin layer (30  $\mu\text{m}$  thick), which is the innermost layer and adjacent to cornea, is composed of mucins, glycoproteins secreted by goblet cells and epithelial cells. It functions to anchor the tear film to the ocular surface (corneal epithelial microvilli) and provide a smooth surface for the aqueous layer to spread over. The tear film thickness is reduced when the eyes are open, due to evaporation. Evaporation is reduced by lipid layer and by eyelid closure. The volume of tear film decreases with age, and when the cornea is anaesthetized. The basal tear secretion rate, equals the rate of tear drainage, evaporation and



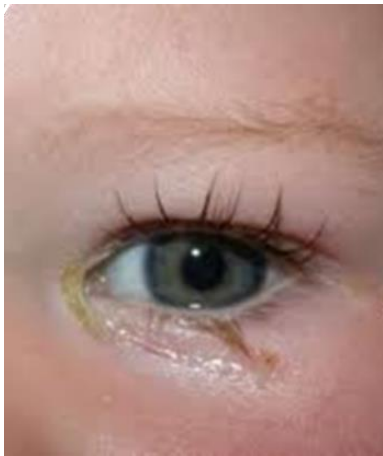reabsorption. **Increased tear production or decreased drainage results in a watering eye.** Basal tear secretion is about 1.2  $\mu\text{l}/\text{min}$ , total volume per day is 10 ml. Reflex aqueous tear secretion, especially from lacrimal gland, increases this up to 100-fold. The conjunctival fornices hold 3-4  $\mu\text{l}$ , the marginal tear strip 2-3  $\mu\text{l}$  and the pre-corneal tear film 1  $\mu\text{l}$  (8,9,20,21). The lacrimal pump mechanism, which involves blinking and the movement of the eyelids, facilitates tear flow into the puncta and through the canaliculi, lacrimal sac, and nasolacrimal duct. Adequate tear drainage depends on a functioning lacrimal pump mechanism. Tear enter the puncta at approximately 0.6  $\mu\text{l}/\text{min}$  (22). The tear meniscus drainage to the sac is explained by numerous effects, passive and active mechanisms. From the lacrimal lake, there is a continual passive low rate of tear drainage into both opened puncta when the eyelids are not blinking, due to Krehbiel's phenomenon, capillary action and normal eyelid downhill slope. Actively, eyelid blinking distributes the pre-corneal tear film and propels the marginal tear strips medially towards the lacrimal lake. At the beginning of the blink's closing phase, the punctal apertures are observed to raise themselves from the lid margin, enabling a powerful encounter and occlusion by the time the closing lid is halfway down. After the lid closes completely, the ampulla, lacrimal sac and canaliculi are compressed, which forces the fluid inside, to pass down the drainage system. In addition, a Venturi effect may exist in the distal canaliculi, accelerating tear flow towards the CC and sac. Orbicularis contraction, including Horner's muscle (as mention above) moves the eyelid medially, the canaliculi shortening and their lumen compression. The lacrimal fascia is pulled laterally, which enables sac filling. A Bernoulli effect, occur in the ampulla and sac. Once tears are in the sac, backflow is reduced by the valve of Rosenmüller. The suction, is created by the elastic expansion of the channels during the blink's opening phase. As the vacuum is dissolved and tear fluid from the marginal tear strips is pulled into the puncta, the punctal areas are seen to "pop" apart in the later portion of this opening. Tears enter the puncta secondary, to reduced intra-canalicular pressure, completing the eye blink and tear drainage cycle (23,24). Although it is very logic, and in fact true to say that by simply gravity, tear drained passively from sac to NLD, tear drainage from sac to nose has also an active role. As Horner's muscle dilates the upper part of the lacrimal sac, it is believed that it also induces a peristaltic effect by

compressing the lower sac, which help with drainage by spiral arrangement of the collagen and elastic fibres surrounding the NLD, according to Thale (25). The reabsorption of tears occur in the epithelium of NLD, can explain the fact that tear flow rate from the lower end of NLD is 10 times less than the tear flow entering the puncta. Emptying of the venous plexus is facilitated by the spiral motion explained above. Some of the aging changes that affect the overall normal tear drainage and lacrimal pump are, reduction in tear volume and quality after 40 years of age. Lacrimal pump dysfunction such as, eyelid laxity and orbicularis descend, punctual eversion, entropion and ectropion, can all lead to watering eye as well as nasolacrimal duct stenosis, which is common in elderly (4:1 , to women) (9). Understanding the detailed anatomy and physiology of the lacrimal drainage system, is crucial for diagnosing and managing various lacrimal drainage disorders, and particularly nasolacrimal duct obstruction (NLDO).

## Indications for dacryocystorhinostomy

Watering eye develops, when there is a disturbance in the balance between the production and secretion of tears, and between the tear drainage outflow. When the problem is of overproduction, this is referred to as hypersecretion or lacrimation. Contrary, when there is an insufficient drainage, it is referred to as epiphora. Since DCR surgery deals with the bypass of the lacrimal drainage system, the term epiphora is the most appropriate term for symptom and sign of the tearing eye. Accurate history and systemic examination enable the examiner to correctly distinguish between those two entities (9). There are many etiologies of epiphora from different anatomical pathways, all connected to the outflow of tears. Not all of the causes are treated by DCR. Some common etiologies are classified between congenital and acquired causes of epiphora, and the acquired causes is subdivided to primary and secondary causes. The term functional epiphora is used when there is epiphora with patent syringing, with the absence of any causes for hypersecretion. Contrary, there is a possibility of having obstruction of NLD with no complain of epiphora, especially in elderly patients, which have an age related reduction in tear production (9). Congenital nasolacrimal duct obstruction (CNLDO) is the com-

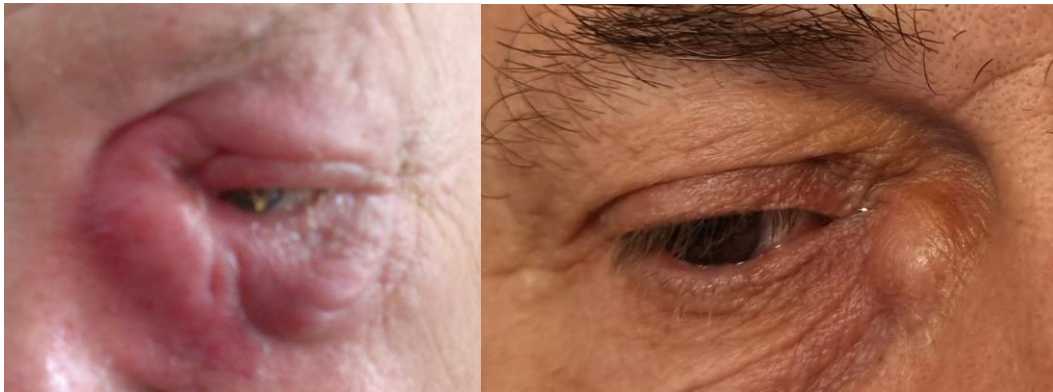most common cause of childhood epiphora, other causes include the congenital atresia, craniofacial disorders and other pathologies (26). Indications of dacryocystorhinostomy in children includes four main indications: Unresolved CNLDO after probing or intubation (Picture 1.), punctual agenesis with canalicular atresia; canalicular atresia and acquired canalicular disease.



Picture 1. Unresolved CNLDO after probing, courtesy of Asst. Prof. Jelena Juri Mandić.

At birth, up to 50 per cent of NLD are still not patent, spontaneous resolution is highest in the first month of life, and 96 per cent resolve in the first year without intervention (27). Those children that have persisted CNLDO, with the unilateral epiphora as the commonest symptom, as well as possible chronic dacryocystitis, are managed first by conventional treatment like lacrimal sac massage. Massage may mechanically accelerate the opening of the lower end of NLD at the level of the valve of Hasner. Then, there is the possibility of probing, the procedure which include dilating the punta the canaliculus, and syringing the NLD in order to open the obstruction. The effectiveness of probing reduced with age, because more severe obstructions remain after the initial spontaneous resolution, and it is more likely that intubation or DCR will be required, according to a retrospective study by Mannor et al (1999) (28). If probing fails, the next step is another probing usually after 3 months, and can be involve by another approach like endoscopic endonasal monitor syringe and probing. If probing fails again, silicon intubation may be required (29). As written above, DCR is not the first or second line of management concerning CNLDO, but considered when intubation is unlikely to succeed, i.e.

when extensive block where the probe cannot pass beyond the sac. Although it is only a possible third line of choice, external DCR provide 90 -93 per cent rate of success when dealing with the first indication, unresolved CNLDO after probing or intubation (30). The second indication worth mentioning is, punctal agenesis with canalicular atresia. Children with punctal agenesis are often asymptomatic, and epiphora is developed when there is coexistent CNLDO. Usually, simple agenesis detected by visible papilla and membrane overlying the edge. When punctal agenesis with canalicular atresia is suspected, it can be shown as no visible papilla or membrane. If there is severe NLDO, DCR with retrograde intubation may be indicate (31). As for adults, indications for DCR surgery includes three main indications: The first and commonest one is **primary acquired nasolacrimal duct obstruction (PANDO)** (Picture 2.) (32).

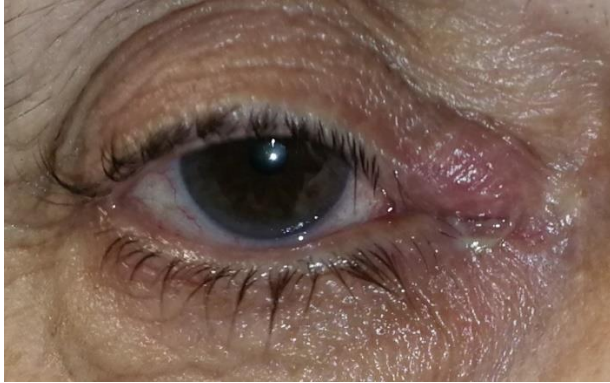

Picture 2. Acute dacryocystitis (left) and Chronic dacryocystitis (right) in elderly patient, courtesy of Asst. Prof. Jelena Juri Mandić.

The second is **secondary acquired nasolacrimal duct obstruction (SANDO)** (1), and finally the already discussed, the **persistent congenital nasolacrimal duct obstruction (CNLDO)** (27). In 1986, Linberg first used the term PANDO to characterize the most typical etiology of adult epiphora (32). It is thought that persistent mucosal inflammation, increasing fibrosis, and nasolacrimal duct narrowing within the stiff nasolacrimal canal are the etiopathophysiology of PANDO. Coexisting membranous occlusion can be caused by inflammation that extends up into the lacrimal sac, and affects the common entryway (Valve of Rosenmüller). Another possible factor, is increased venous stasis in the venous sinusoids-cavernous body around the nasolacrimal duct. PANDO is more

common in women than in men and affects the elderly (33). It encompasses a range of diseases, from minimal constriction to total blockage. Thus, stenosis occurs before total obstruction, when syringing is patent and typically involves regurgitation (9). The clinical findings of PANDO are, functional epiphora (when NLD is partially blocked), full obstructive epiphora, mucocoele, acute dacryocystitis (usually associated with a total block), optional membranous or distal CC blockage and dacryoliths (inspissated mucus and cellular debris) (32). Acute dacryocystitis is characterized by pain, previous epiphora, erythema, and swelling generally located below the medial canthal ligament tendon (34). The hallmark of lacrimal sac mucocele is, mucopurulent material-induced dilatation and distension of the lacrimal sac (LS), due to blockage of the nasolacrimal duct. Adult lacrimal sac mucocele is typically a consequence of long-term dacryocystitis, which is brought on by persistent blockage of the NLD and subsequent canaliculi occlusion (35). At the intersection of the CC and sac, at the medial end valve of Rosenmüller, membranous obstruction takes place. This happens as a result of irritation of the mucosa. It could be only one that is present or it could be linked to nasolacrimal duct stenosis. During probing, there is typically a slight constriction that is felt as a "pop." There are more severe blockages that are hard to get past with probing, particularly when a non-expressible mucocoele is present (9). Patients with dacryolithiasis, are likely to have a shorter history of epiphora and previous attacks of dacryocystitis at presentation. Based on review from 1988 of more than one hundred patients which undergo DCR surgery, in more than ten per cent, dacryolithiasis were found (36). The etiopathogenesis of PANDO appears to be multifactorial. Hormonal microenvironments, vascular factors, and tear proteomics play dominant roles, as shown in a systemic review published in 2019 by Ali and Paulsen (37). The second indication for DCR surgery is SANDO. The term SALDO (secondary acquired lacrimal drainage obstruction) was adopted in 1992 by Bartley, to cover wide range of secondary causes of epiphora (1). Secondary acquired nasolacrimal duct obstruction (SANDO) is caused by a specific secondary etiology, and is the most common cause of persistent epiphora. SANDO or SALDO can be caused by infectious, inflammatory, neoplastic, traumatic, and mechanical factors, each with its own pathophysiology. Bartley's SALDO classification, is focused on the etiology in relation of the location of the lacrimal drainage involved (puncta, canaliculi, sac or

NLD). Regarding infectious pathogenesis, the condition can be from bacterial origin like actinomyces Israeli or chlamydia, which will affect mostly the puncta and canaliculi (Picture 3.).



Picture 3. Upper canaliculitis, courtesy of Asst. Prof. Jelena Juri Mandić.

Viral aetiology can consist of herpes simplex or herpes zoster which involve the same proximal parts as bacteria, while fungal origin (especially candida and aspergillus infections) in other hand, can compromise not only the proximal parts, but the sac as well. In the case of parasitic origin, the puncta, canaliculi, sac and the NLD can be affected. Regarding inflammatory etiopathogenesis, Bartley divide the condition to endogenous versus exogenous. Endogenous conditions like granulomatous polyangiitis (GPA) formerly known as Wegener's granulomatosis or sarcoidosis affect the sac and NLD, while cicatricial pemphigoid and Stevens-Johnson syndrome affect puncta and canaliculi. Exogenous conditions like eyedrops, radiation, fluorouracil, allergy, and burns affect the proximal pathway, while pyogenic granuloma can and usually do affect the distal pathway. Regarding neoplasia as aetiology of SANDO, it can be divided into primary, secondary and metastatic causes. Primary relative common tumors, like papilloma or squamous cell carcinoma can affect any part in the lacrimal drainage pathway, while lymphoma and haemangiopericytoma affect mainly the sac. Secondary tumors like basal cell carcinoma, adenocystic carcinoma, leukemia and lymphoma affect the canaliculi or the sac. Metastatic breast carcinoma, melanoma and prostatic carcinoma affect mostly the lacrimal sac. As will be detailed later in the discussion, lacrimal sac exploration is one of the advantages while performing external DCR surgery, especially if the surgeon suspect

lacrimal sac tumour. Regarding the trauma as an aetiology it can be divided to medical therapy and accidental trauma. Proximal parts (puncta and canaliculi) affected in the case of punctal plugs, probing and silicon intubation. Sinus or nasal surgery are common cause of traumatic SALDO. Soft tissue lacerations (i.e. periocular dog bite injuries, (38) ) are affecting the canaliculi and sac. In one study, that review the CT scans of 25 patients with fractures of the nasolacrimal fossa and canal, due to motor vehicle accidents, they identifies three types of nasolacrimal fractures and their associations, with simple unilateral facial fractures or complex mid-face fractures. Complications related to nasolacrimal sac and duct injuries were documented in five patients, fewer than expected (39). Regarding mechanical causes of SALDO, Bartley classified them into internal versus external causes. Internal mechanical causes like dacryoliths or migrated medical device (e.g. punctal plug) affect canaliculi and distal parts. External mechanical causes consists of, "kissing puncta", conjunctivochalasis and frontal or ethmoidal mucocele. As discussed above, Bartley cover wide range of secondary causes of epiphora from infection, inflammation, neoplasia, trauma and mechanical. Any part of the lacrimal drainage system can be affected including the NLD (1,40,41). Diagnosis of SANDO is primarily clinical, with additional tests such as dye disappearance test, probing and irrigation test, and imaging with CT or MRI used to confirm the diagnosis. Comparing patients with watery eyes to those with cataracts and macular region pathology, one study in Croatia sought to determine the patient's quality of life and degree of depression symptoms. A quality of life questionnaire related to vision and the Beck Depression Inventory-2 were used in the 210 patients in the study. According to the results, patients with watery eyes reported higher levels of depression and a markedly lower quality of life in everyday activities, when compared to the other groups. The impact of watery eyes on a large number of patients is highlighted in the study, along with the significance of prompt diagnosis and treatment to restore full visual function and quality of life (42).

## External dacryocystorhinostomy – technique

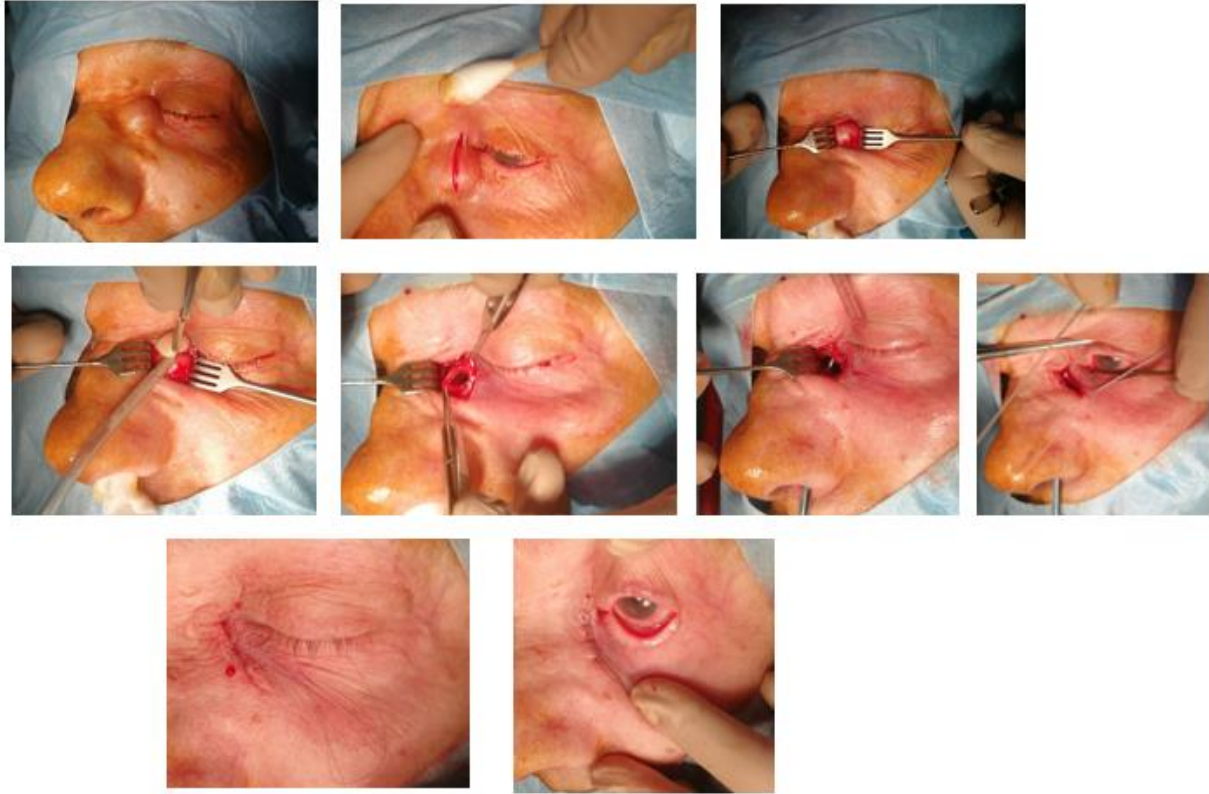As previously mentioned in detail, the most common reason of watering eye is an obstruction of the tear drainage system so called PANDO, which prevents tears from draining normally into the nose. From the surgical technique of dacryocystorhinostomy (DCR), excessive tearing is relieved, and the normal flow of tears from the tear ducts to the nose is restored. The surgical methods can be divided into two main types' categories: endonasal versus external. Endonasal can be subdivided into non-laser endoscopic endonasal DCR procedures (EN-DCR), and endonasal laser-assisted DCR (LA-DCR). The external DCR (EX-DCR) approach will be covered in detail in this section of the review, and both advantages and disadvantages of each type will be listed at the end of this chapter. For the most part, EX-DCR continues to be the gold standard in oculoplastic surgery, mostly because the procedure's long-term success rates typically exceed 90 per cent (43–45). A synopsis before delving into the phases of the procedure: An incision in the skin is made to approach the lacrimal sac and nasal mucosa during this procedure. A large bony rhinostomy is done between the lacrimal sac and the nose. An anastomosis is made between the lacrimal sac and nasal mucosa by sutured flaps. The operation generally lasts up to 15-90 minutes, depending on the expertise and experience of the surgeon. Regarding the anaesthesia during EX-DCR. Mostly, is done by general anaesthesia in day case surgery. A throat pack or laryngeal mask is required. Inhalational agents like isoflurane or desflurane is provided for good haemostasis and lowering blood pressure, often with short-acting beta-blocker to reduce tachycardia. The patient position should be at reverse Trendelenberg, meaning head up to reduce hydrostatic blood pressure in head. Good nasal mucosal vasoconstriction is recommended, using a cocaine 4-10% solution. For elderly frail patients, who would be medically at risk if given a general anaesthesia and a longer operation, are candidate for local anaesthesia utilizing anterior ethmoidal block. In this case, is necessary to anaesthetize the ocular surface, medial eyelids, medial canthus and anterior lacrimal crest, as well as nasal mucosa. In addition, the nasal mucosa must also be decongested. In those kind of patients, it could be consider to switch to



endonasal approach. Assessment of patient before EX-DCR surgery includes, the short drug history or current medication prescription taken by the patient. Non-steroidal anti-inflammatory drugs (e.g. Ibuprofen or aspirin) and anticoagulants, will cause excess per-operative bleeding, especially for EX-DCR. Surgeon should advise the patient to stop aspirin-containing drugs two weeks before the scheduled surgery, and reduce warfarin so that the INR falls below 2.0, if the medical condition permits. The surgeon should consult hematologist or the patient's physician if in doubt. In cases when lowering anticoagulants is not advisable for the patient (e.g. prosthetic heart valve), as the risk exceed the patient benefit from this approach, the surgeon should consider LA-DCR which minimized the risk of excessive bleeding during operation (46), or to admit the patient for intravenous heparin therapy. Regarding the medical drug history, the patient may not be aware of taking aspirin, as many over-the-counter analgesics do contain aspirin. Approaching EX-DCR surgery with two primary objectives in mind: first, enlarge the rhinostomy to expose sufficient nasal mucosa anteriorly for good flaps, which are intended to enable the common canalicular opening to open freely into the nose. Second, no tissue (such as mucosa strands, residual ethmoid, or maxilla bone) should be present medial to the common canalicular opening as this could obstruct it (6).

The standard surgical steps for performing EX-DCR surgery are (Picture 4.):

- **Skin incision.**
- **expose ascending process of maxilla and lacrimal fossa.**
- **rhinostomy with optional anterior ethmoidectomy.**
- **create mucosal flaps and intubate.**
- **skin closure.**



Picture 4. Main steps of DCR Ab Externo from left to right, courtesy of Asst. Prof. Jelena Juri Mandić.

**Instruments for skin incision:**

1. Marker pen and caliper
2. No. 15-scalpel blade on Barde Parker handle or Colorado needle
3. St martin's toothed forceps
4. Westcott's curved scissors
5. Straight blunt scissors
6. Moorfield's non-toothed scissors
7. Silk traction sutures (cutting needle), e.g. Ethicon 4/0 Mersilk W606 or W501
8. Castroviejo needle holder
9. Five artery clips
10. Rollet's rugine

**Instruments to enter lacrimal fossa:**

1. Sucker
2. Rollet's rigne or Hill's periosteal elevator
3. Traquair's periosteal elevator

#### **Instruments for rhinostomy:**

1. Traquair's periosteal elevator
2. Kerrison bone punches – up-cut in small, medium and large sizes
3. Bone nibblers, e.g. Beyer punch
4. Optional: hammer, chisel and bone wax.

#### **Instruments to create flaps and intubate:**

1. Nettleship punctual dilator
2. Bowman probes size 0/00 and ½
3. No. 11 blade, or paracentesis knife
4. Werb right-angle sac scissors or Westcott scissors
5. Stallard's blunt lacrimal dissector
6. O'Donoghue silicone tubes on metal bodkins
7. St Martin's toothed forceps
8. Curved artery clip
9. 6.0 absorbable suture on half circle spatula needle, e.g. Ethicon 6/0 Vicryl W9566 or Davis and Geck 4567-13 Dexon 'S'
10. Barraquer needle holder
11. Optional for sucurring tubes: Ligaclips and applicator or Watzke sleeve.

#### **Skin incision**

There are two options for the skin incision: Straight side of the nose and the tear trough. The first option is, a vertical incision made 1 cm away from the medial canthal angle to prevent a bowed scar. The angular vein is safe if a skin flap incision is used. The alternative incision is, a curved incision in a relaxed skin tension line in the tear trough, over the infero-medial orbital rim, through the skin and orbicularis down the rim. It start 2 mm above the MCT and avoid as well the angular vein. It is best done with electrocautery, for example using the Colorado cutting needle. The position of the

needle is critical, as too high above the rim could result in division of the NLD during surgery. For re-do DCR, its useful to avoid the original side of nose incision, or if there has been other medial canthal surgery or radiotherapy. The scar is barely perceptible if the skin is sutured properly (9).

### **Steps:**

- Mark the vertical skin incision with a pen. Use a calliper to measure distances if necessary. The incision is placed 10 mm from the medial canthal angle and extends approximately 2 mm above and 10 mm below the horizontal inter-canthal line. Its length is 12-15 mm in adults and 6-8 mm in children. Use the blade or Colorado needle to incise the skin only.
- Raise the skin flap by dissecting between the skin and vein/orbicularis, in a natural tissue plane. Use curved scissors to separate the orbicularis/skin attachments. Use straight, blunt scissors to divide the pretarsal and preseptal orbicularis fibres at the ALC. Reflect the lateral skin flap laterally on two traction sutures secured firmly to the draped.
- Identify the superficial MCT and divide all or lower two-thirds with a blade or Rollet's rugine. Place the lateral cut end on a small marker suture.
- Use the Rollet's rugine to divide the periosteum along the ALC. Lift the periosteum anterior off the ascending process of the maxilla – aim for the bridge of the nose. This should be at least 10 mm anteriorly in order to create a good-sized rhinostomy, and hence good-sized nasal mucosal flaps.
- Place three 4.0 black silk traction sutures around the medial orbicularis/vein/skin and secure them tightly to the drapes. The lowest traction suture is called the 'white nose' or 'break nose' suture, as it is secured very tightly over the nose, leaving a temporary indent. Bend the needle with artery clip in order to take a short deep bite of orbicularis.
- The suture of Notha (emissary vein) is anterior to the ALC and may bleed, in that case use the sucker or apply bone wax.

## **Exposure of ascending process of maxilla and lacrimal fossa**

The goal of this procedure is, to expose as much bone anterior to the ALC as possible, by using the traction sutures and a squint hook to reflect the orbicularis anterior off the bone, while using the sucker in non-dominant hand throughout to aspirate blood and reflect tissue (9).

### **Steps:**

- Reflect the periosteum and orbicularis laterally and identify the lacrimal sac. It is sometimes useful to put a marker suture on the edge of the reflected periosteum for later orientation.
- Enter the lacrimal fossa with Rollet's rugine – there is a natural plane between the sac and the bony fossa. Be careful not to penetrate the thin lacrimal bone in the lacrimal fossa yet, or damage the lacrimal sac. Use the sucker to reflect the sac and upper part of the NLD gently and laterally.
- Identify the vertical bone suture in the lacrimal fossa using the Traquair's periosteal elevator and penetrate the thin lacrimal bone superiorly, posterior to the suture. Always use the short end of the periosteal elevator if they are different sizes. Initially hold the Traquair's handle vertically so that the tip enters at right angles through the bone, and once it is in swing the handle laterally 90 degrees so that the tip is behind and parallel to the bone and cannot damage the nasal mucosa.

## **Rhinostomy**

In this part of the surgery, the procedure starts by making an initial C-shaped rhinostomy, which enables easy removal of the thickest part of the maxilla inferiorly. Ethmoid air cells between the lacrimal fossa and nasal mucosa are removed. The rhinostomy should be large enough to accommodate a large finger or thumb (9).

## **Steps:**

- Use the Traquair's periosteal elevator to separate the nasal mucosa and bone by running it superior and inferior in the bony suture, and gently pushing the mucosa away. Never have anything in the nose (nasal pack or instrument) that could push the mucosa towards the bone whilst doing the rhinostomy.
- Enlarge the initial lacrimal bone fracture to make an adequately large space to insert the bone punch. Pull the Traquairs toward you to outfracture little fragments of lacrimal bone. Use the sucker in the non-dominant hand to reflect the sac laterally and aspirate blood.
- Use the rongeurs to make the C-shaped rhinostomy anteriorly into the maxilla, starting superiorly. Initially go anteriorly towards the bridge of the nose, then inferiorly, and finally posteriorly. The thickest bone is inferior – if this is weakened it become easy to remove with rongeur or bone clipper. The rhinostomy should extend from the fundus of the sac superiorly and the PLC posteriorly. It should go at least 10 mm anteriorly towards the bridge of the nose, and inferiorly including the upper part of the medial nasolacrimal canal and the hamular process. The round-shaped rhinostomy should measure 10-18 mm in diameter. The assistant retract the medial orbicularis with a squint hook to help expose the maxilla for removal.
- Excise anterior ethmoid mucosa and thin ethmoid bone fragments. Ensure that the nasal mucosa is also free of all small fragments of bone, using Moorfield's forceps to feel for small bone fragments and remove them. The rhinostomy will expose the undersurface of the nasal mucosa, seen as grey mucosal sheet.

## **Additional tips for rhinostomy:**

- Keep elevating the nasal mucosa off the bone by alternate use of rongeur and periosteal elevator in order to keep the nasal mucosa intact. The assistant or nurse cleans the rongeur of entrapped bone after each bite, using a damp gauze square, and holds the Traquair's periosteal elevator for exchange.
- Differentiate between ethmoid and nasal mucosa. Nasal mucosa is grey and thick. Anterior ethmoid mucosa is pink/white, thin, and more prone to bleeding.

- Do not confuse entering the ethmoid for entering the nose. If in doubt, place Stallard instrument in the nasal space, directed up towards the rhinostomy – it should be seen indenting the nasal mucosa. Alternatively, use a cotton bud. Do not use the sucker. Placing an instrument in the nasal space will also show whether nasal mucosa has been inadvertently lost during the rhinostomy.

### **Mucosal flaps**

In this procedure, make the lacrimal flaps first, then the nasal mucosal flaps, because once they cut, they tend to bleed. Aim to suture both posterior and anterior flaps. Sometimes it is not possible to suture the posterior flaps, because of bleeding or mucosal loss, in either case a large anterior flap is effective (9).

### **Steps:**

- Dilate the lower punctum with the Nettleship dilator and then insert the Bowman probe size 1 along the inferior canaliculus into the sac, tenting up its medial wall.
- Incise the medial sac wall vertically using a paracentesis knife or no. 11 blade. Extend the superior and inferior ends of the incisions anteriorly and posteriorly to create the flaps. Ensure that the full thickness of the lacrimal wall has been incised, and not just the overlying thin adventitia, by directly inspecting the Bowman probe inside the sac. Place 6.0 absorbable sutures on the two corners of the anterior flap and reflect it laterally.
- Look inside the sac for folds, diverticulae, dacryoliths, polyps and other pathologies. If there is a membrane or fibrous mucosal folds over the common opening that held up passage of the probe, do a membrectomy with Vannas' scissors. Use the microscope or endoscope for better view.

### **Relative sizes of anterior and posterior lacrimal flaps:**

1. If the lacrimal sac is of a normal size, the anterior flaps are made the same size as the posterior flaps, 1 : 1, anterior : posterior.
2. If the lacrimal sac is very small, aim for a good sized anterior flaps, 2 : 1 in anterior : posterior.

3. If there is little remaining nasal mucosa, first try and find some anteriorly by enlarging the rhinostomy. If there is still inadequate nasal mucosa, the lacrimal sac mucosa will form the entire anterior flap, therefore 3 : 1 or 4 : 1 anterior : posterior. The posterior flap is omitted.
  4. If there is a large lacrimal sac (e.g. mucocele or diverticulum is present), it is sometimes necessary to excise part of the lacrimal mucosa so that the sutured flap does not flop back inwards and obstruct the common opening. The anterior flap will still be larger than the posterior because sac enlargement occurs anteriorly.
  5. If the lacrimal mucosa is badly damaged during incision, excise loose fragments and aim for a large flap derived from anterior or posterior nasal mucosa.
- If intubation is planned, insert the O'Donoghue silicone tubes now and use the tubes clipped back laterally onto the drapes, to reflect the sac mucosa open and provide greater access to the nasal mucosa. Retrograding intubation may be required if there is proximal or mid-canalicular obstruction.
  - Regarding **nasal flaps**, aim to make both anterior and posterior nasal flaps. The greater the area of nasal mucosa exposed, the more likely it is that you will be able to fashion two flaps.

**Relative sizes of anterior and posterior nasal flaps:**

1. The anterior flap is the same or larger than the posterior flap, 1 : 1 or 2 : 1, anterior : posterior.
  2. If there is only a very small amount of nasal mucosa, either as a result of trauma or a very low agger nasi, create a single anterior nasal flap.
  3. If the nasal mucosa has been damaged anteriorly, only a posterior flap will be possible. The anterior flap will therefore be made from the lacrimal sac mucosa only.
- Insert Stallard's instrument into the nose medially to the exposed nasal mucosa and repeat the incision. Cut down onto the Stallard with a paracentesis knife or



no. 11 or 15 blade. If using a long blade, avoid in advertently cutting the skin with the upper part of the blade. Use Werb's angled or Westcott's curved scissors for the horizontal cuts. If a single anterior flap of nasal mucosa is planned, incise the nasal mucosa more posteriorly.

- At this point the **posterior flap are usually sutured** together with interrupted or continuous 6.0 absorbable suture.

### **Silicon intubation**

The tubes are often inserted before creating the nasal flaps.

#### **Steps:**

- Dilate the punctum with the Nettleship dilator.
- Bend the metal bodkin and insert it gently through the canaliculus. Grasp it within the wound with a curved artery clip and bring it out.
- Repeat with the second bodkin.
- Cut off both bodkins and leave the ends long.
- Tie the silicone tubes together with several knots, Ligaclips or a Watzke sleeve, or a combination of these. Ensure that the tie is not going to lie close to the rhinostomy site (and risk later impaction) by tying the tubes outside the wound and level with the bridge of the nose, over an instrument.
- Pass the tubes down into the nose by holding the two ends together with forceps within the wound. Place a curved artery clip up through the nostril into the deep part of the wound to catch the ends and pull them down back through the nose and out of the nostril.

### **Suture the anterior flaps**

- Suture together the anterior flaps as for the posterior, using either interrupted or continuous 6.0 absorbable suture. If interrupted sutures, start by pre-placing the suture at each corner of the anterior nasal flap and one on the anterior lacrimal flap. Understand that the lacrimal sac and nasal mucosal flaps are not always exactly adjacent horizontally, but are often at different heights, with the nasal mucosal flap being lower.

## **Skin closure**

- Avoid orbicularis suture. Repair the MCT with one 6.0 absorbable suture, or leave it if there is no displacement. The muscle layer is self-sealing if the skin flap incision was used; simply reposition the orbicularis over the anterior mucosal flaps.
- Cut the tubes to the correct length in the vestibule of the nose, whilst on slight stretch, making sure that the tube is not too tight at the medial canthus. Optional: pack the nose with a dry sponge nasal pack coated with chloramphenicol ointment.
- Orbicularis oculi is approximated with interrupted 6-0 Vicryl.
- Skin is closed with interrupted 7-0 nylon.

## **Is external DCR any better than endonasal DCR?**

They are different operations, with similar but different success rates. It is important to explain the patients the pros and cons of each different type of DCR surgery and their relative surgical success rate. As a guideline, EX-DCR has a 90-95 per cent success rate, EN-DCR 80-85 per cent, and LA-DCR 70-80 per cent.

### **Advantages of external DCR:**

- The lacrimal sac is fully exposed. Intra-sac pathology identified and the valve of Rosenmüller clearly seen. Membranectomy of the common canalicular opening is possible, as is retrograde intubation.
- The rhinostomy is large (at least 10 mm), with all the intervening bone and sinus adjacent to the common opening removed, therefore the healed rhinostomy is unlikely to close.
- Mucosal flaps are sutures and therefore silicone intubation is only used if indicated, as healing is rapid.
- In hands of experienced surgeon the procedure last up to 15 min.
- Great cost -benefit, no expensive instruments needed

### **Disadvantages of external DCR:**

- Controlled hypotensive general anaesthesia may be contraindicated in elderly frail patients. Local anaesthesia is not always a suitable alternative.
- Pre-operative haemorrhage may impede the view of the common opening and make suturing of the posterior flaps difficult.
- There is a risk of sump syndrome if the rhinostomy is placed too high in relation to the lacrimal sac. In the sump syndrome, the lacrimal system is patent to syringing but intermittent symptom of epiphora and stickiness persist, because the lacrimal sac cannot drain fully.
- The cutaneous scar is occasionally visible.

### **Advantages of endonasal DCR:**

- Rapid post-operative rehabilitation.
- There is good haemostasis.
- Surgery can be theoretically shorter depend on institution.
- There is no risk of sump syndrome, as the rhinostomy is always adjacent to the lower part of the lacrimal sac, but there is a risk of too small rhinostomy.
- Surgery is localized with very little collateral damage.
- It avoids skin incision and hence risk of a visible facial scar.

### **Disadvantages of endonasal DCR:**

- There is a very long learning curve, with new anatomy and instruments, for an ophthalmologist. It is best done in conjunction with an otolaryngologist colleague, who already has the appropriate expertise and instruments.
- The costs of endoscopes ,instruments and multidisciplinary collaboration .are very high, cost-benefit dubious
- The inside of the lacrimal sac and common opening is not always visualized.
- The delicate lacrimal mucosa may be damaged, with resultant scarring.
- There are lower success rates, due to granuloma and sub-mucosal fibrosis sometimes causing rhinostomy closure.

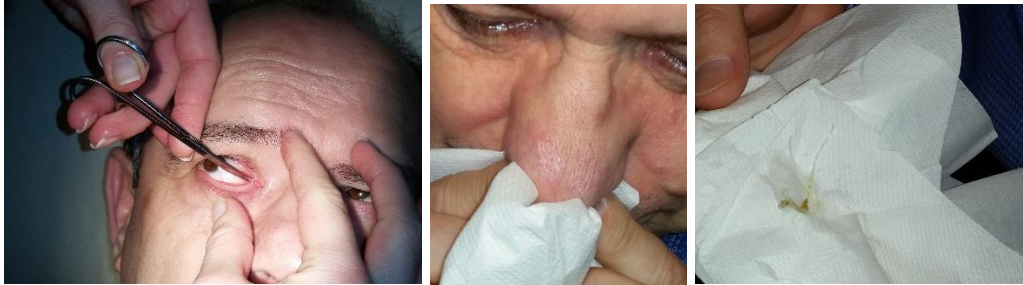At the end of the surgery, the surgeon can pad the eye/wound, the patient should sit up at 45 degrees as soon as possible to reduce bleeding. The patient should avoid nose-blowing for 4-7 days. The surgeon can prescribe broad-spectrum systematic antibiotics for 1 week, or give an antibiotic bolus per-operatively if a mucocoele or sinusitis is noted. The surgeon should give topical steroid and antibiotic eyedrops for 3 weeks. Post-operative instructions to the patient must be clear to prevent nasal haemorrhage and orbital emphysema (9).

## Surgical follow up

Post-operative management is divided into **early, intermediate and late**.

**Early management** start immediately at the end of the surgery, and the steps were mentioned and described in the last part above. They consist of padding the eye, sit up the patient, steroid and antibiotic prescription and instructions for the patient. The rest of the early follow up takes place in the setting of the outpatient clinic. 1 week, for removal of sutures, between 3 and 6 months for removal of tubes, and 6 months after surgery for the last checkup. Follow-up is more frequent if there are complications. At the 1 or 2 week post-operative visit, reassure the patient if there is still some watering, which may be due to the presence of the tubes or the persistence of crusting within the surgical rhinostomy. Encourage the patient to start blow the nose in order to clear out old blood clots and crust. In addition inspect the external wound for dehiscence or infection. Remove the skin sutures. Examine the nasal space after decongestion with guttae phenylephrine 2.5% or 10% on cotton buds, or co-phenylcaine nasal spray. Inspect tube movement on blinking, and their position in relation to the rhinostomy. Remove crusts with forceps as necessary, and divide early synechia when needed. Start broad-spectrum antibiotics if excessive mucous discharge is seen across the rhinostomy from chronic rhinosinus disease. There is rapid mucosal healing by primary intention, where the mucosal edges are sutured, and secondary intention healing, where the mucosal edges remain un-sutured superiorly and inferiorly. Epithelial continuity is usually complete within 2 weeks of surgery. Early synechia between the lateral nasal wall and septum, or between the middle turbinate and lateral nasal wall, are easily divided and

removed whilst they are soft, 1 week after surgery. Crusts lying within the rhinostomy are removed with Blakesley forceps. Crusts can be annoying to the patient and extra visit may be required. **Intermediate management (up to 3 months)** consist of removal of the tubes after surgery, depending on the indication for their placement (Picture 5.).



Picture 5. Removal of the tubes after surgery, courtesy of Asst. Prof. Jelena Juri Mandić.

Before cutting the tubes at the medial canthus, inspect the nasal space endoscopically to detect pathology, and inspect the healed rhinostomy and tubes. Nasal mucosa vasoconstriction is recommended, but topical anaesthesia is not usually required, either on the eye or in the nose. Cut the tubes at the medial canthus, and then either ask the patient to lean forward and blow the nose to blow the tubes out, or to gently retrieve them under direct endoscopic visualization. This should be atraumatic and quick for the patient. After the tubes are removed, syringe the lacrimal system to wash through any mucus and confirm patency. Perform a functional endoscopic dye test (FEDT), and inspect the healed rhinostomy. Regarding **late management (6 months after surgery)** the surgeon should evaluate the success of the surgery subjectively and objectively.

### **Subjective results**

Ask if the epiphora and stickiness has improved or been cured. The patient should estimate how much improvement there is (100 per cent is maximum) compared to before the surgery.

### **Objective results**

Syringe the lacrimal system, and do a final endonasal examination to observe the functional endoscopic dye test. Anatomical and functional success is defined as

improvement of symptoms, patent syringing and positive FEDT, which define when dye placed in the conjunctival sac rapidly emerges from the common opening and drains down the lateral nasal wall. Some patients with previous nasolacrimal duct obstruction have improvement of the symptoms and patent syringing but negative FEDT, they exhibit an alternative drainage route, probably via the ethmoid or maxilla sinuses.

Regarding long term follow up (years), in one Turkish study, 387 patients' external dacryocystorhinostomy (Ex-DCR) success rates were evaluated over a mean follow-up of 5.9 years. After reoperations, the initial success rate of 91.5% rise to 98.4%. The amount of time of the obstruction, the age of the patient, and the length of the postoperative follow-up were found to be correlated with success rates. Even after a long period of follow-up, the authors came to the conclusion that Ex-DCR is still a highly successful and cost-effective procedure (44).

## Complications intra/post-operative

As with any surgical procedure, there are risks and complications associated with external DCR surgery. Some of the potential complications includes **intraoperative** ones, either related to the anesthesia itself, or to the surgery steps mentioned above. In addition, there are **postoperative** complications, which can divided into early (1-4 weeks), intermediate (1-3 months) and late complications (6 months).

### **Intraoperative complications:**

As for anesthesia, one study from teaching and research hospital in Izmir, Turkey compare outcomes of External DCR under General and Local Anesthetics. They collect data from a total of 106 eyes from 82 patients. Results showed that external DCR with both general and local anesthesia is effective for treating nasolacrimal duct obstruction. Additionally, local anesthesia may be considered due to less bleeding, shorter discharge time, cost-effectiveness, and to avoid systemic complications for high-risk patients (47).

The intraoperative complications from surgery itself, can be: Excessive bleeding during the operation, which is the most common one. Cerebrospinal fluid leakage, due to penetration of the cribriform plate. Injury to the orbital contents. Injury to the canaliculi from improper probing. Shredding of the lateral nasal mucosa due to improper bone removal. Avoiding excessive bleeding was already explained in the section above. Regarding canaliculi injury, the surgeon should gently pass the probes and tubes as well as direct the blades away from the CC when creating the lacrimal sac flaps.

### **Postoperative complications:**

**Early (1-4 weeks)** complications includes, wound infections, fistula or dehiscence. Tube lateral displacement. Medial corneal erosion from tubes at medial canthus. Excessive rhinostomy crusting, as well as intranasal synechia. **Intermediate (1-3 months)** complications includes, synechia and fibrosis. Granulomas at rhinostomy. Tube lateral displacement and corneal erosions. Punctal cheesewiring and punctal or canalicular pyogenic granuloma. Tube tie impaction in ostium. Prominent facial scar. Medial canthal distortion and persistent fistula to the skin. From failed DCR. **Late (6 months and later)** complications includes, rhinostomy fibrosis, delayed mucosal healing or webbed facial scar. Also persistent synechia, medial canthal distortion and chronic fistula can be rare late complications (9). One case report highlights the rare occurrence of paranasal sinus mucocele (48).

Although some surgeons use systemic antibiotics as prophylaxis against postoperative infection, one study from Birmingham and Midland Eye Centre, UK, found that postoperative infection after external DCR without systemic antibiotics is rare. Out of 82 cases, only one (1.2%) had a superficial wound infection, which was successfully treated with oral antibiotics. The study suggests that, routine use of systemic antibiotic prophylaxis in external DCR may not be necessary (49). Regarding neurological complication, one retrospective observational study of 16 patients who developed postoperative orbicularis oculi muscle weakness after external DCR was done. Damage to the peripheral fibers of the zygomatic and buccal branches of the facial nerve as they pass course the medial canthal area and innervate the orbicularis oculi muscle, which controls the upper eyelid

was noted. Such an injury could be the cause of lagophthalmos and postoperative abnormal eyelid closure caused by weakness in the orbicularis oculi muscle. The findings were temporary and typically resolved in several months (50). Although the risks of complications such as bleeding EX-DCR are higher than the other approaches, it can be said that external dacryocystorhinostomy is a highly successful long-term solution for nasolacrimal duct obstruction. One study from University of California San Francisco involved 128 patients and 150 procedures over a 14-year period was done. The results showed, a 93% overall success rate at an average follow-up of 2.7 years, with a predicted success rate of 90% beyond 4 years according to Kaplan-Meier analysis. The study also revealed that, most surgical failures were identified within the first 2 years. Additionally, postoperative complications were rare, and the surgical scar was not a significant concern for most patients. The results of this study demonstrate that EX-DCR is a very effective, low-morbidity long-term treatment for nasolacrimal duct obstruction (45).

## Conclusion

In conclusion, external DCR surgery is a well-established technique in ophthalmology that offers distinct advantages over other methods. The external approach provides direct access to the nasolacrimal system, enabling the surgeon to achieve optimal results through comprehensive visualization and unobstructed access to nasal structures. While, as any surgery, external DCR surgery carries potential risks and complications, thorough preoperative evaluation and patient selection, as well as meticulous surgical technique, can minimize these risks and ensure highly successful outcomes.



## References

1. Bartley GB. Acquired lacrimal drainage obstruction: an etiologic classification system, case reports, and a review of the literature. Part 1. *Ophthal Plast Reconstr Surg.* 1992;8(4):237–42.
2. Tarbet KJ, Custer PL. External dacryocystorhinostomy. Surgical success, patient satisfaction, and economic cost. *Ophthalmology.* 1995 Jul;102(7):1065–70.
3. Chandler PA. Dacryocystorhinostomy. *Trans Am Ophthalmol Soc.* 1936;34:240–63.
4. Girgis IH. Dacryocystorhinostomy. *J Laryngol Otol.* 1968 Feb;82(2):149–52.
5. Yakopson VS, Flanagan JC, Ahn D, Luo BP. Dacryocystorhinostomy: History, evolution and future directions. *Saudi J Ophthalmol Off J Saudi Ophthalmol Soc.* 2011 Jan;25(1):37–49.
6. Dupuy-Dutemps L, Bourguet M. Procédé plastique de dacryocystorhinostomie et ses résultats. *Ann Ocul.* 1921;158:241–61.
7. Toti A. Nuovo metodo conservatore di cura radicale delle suppurazioni croniche del sacco lacrimale (dacriocistorinostomia). *Clin. Mod. Firenze.* 1904;10:385–387. [Google Scholar].
8. Kanski's Clinical Ophthalmology: A Systematic Approach (8th edition). Brad Bowling. Elsevier.
9. Olver J. Colour atlas of lacrimal surgery. Oxford: Butterworth-Heinemann; 2002. 207 p.
10. Amboss. "Lacrimal Gland." AMBOSS, [https://next.amboss.com/us/search?q=lacrimal+gland&v=overview&m=j5Y\\_Pp](https://next.amboss.com/us/search?q=lacrimal+gland&v=overview&m=j5Y_Pp). Accessed 27 August 2021.
11. Dartt DA. Neural regulation of lacrimal gland secretory processes: relevance in dry eye diseases. *Prog Retin Eye Res.* 2009 May;28(3):155–77.
12. Jones LT. An anatomical approach to problems of the eyelids and lacrimal apparatus. *Arch Ophthalmol.*, 66, 137-50.
13. Horner WE. Description of a small muscle at the internal commissure of the eyelid. *JMed Phys.* 1823;8:70–80.
14. Schaeffer JP. The genesis and development of the nasolacrimal passages in man. *Am J Anat.* 1912;13:1–24.

15. Tucker NA, Tucker SM, Linberg JV. The anatomy of the common canaliculus. *Arch Ophthalmol Chic Ill* 1960. 1996 Oct;114(10):1231–4.
16. Patton JM. Patton JasM. IV. Regional Anatomy of the Tear Sac. *Annals of Otolology, Rhinology & Laryngology*. 1923;32(1):58-65.  
doi:10.1177/000348942303200104.
17. Whitnall SE. The relations of the lacrimal fossa to the ethmoid air cells. *Ophthal Rev*. 30, 321-5.
18. Blaylock WK, Moore CA, Linberg JV. Anterior ethmoid anatomy facilitates dacryocystorhinostomy. *Arch Ophthalmol Chic Ill* 1960. 1990 Dec;108(12):1774–7.
19. Groessl SA, Sires BS, Lemke BN. An anatomical basis for primary acquired nasolacrimal duct obstruction. *Arch Ophthalmol Chic Ill* 1960. 1997 Jan;115(1):71–4.
20. Botelho SY. TEARS AND THE LACRIMAL GLAND. *Sci Am*. 1964 Oct;211:78–86.
21. Mishima S. SOME PHYSIOLOGICAL ASPECTS OF THE PRECORNEAL TEAR FILM. *Arch Ophthalmol Chic Ill* 1960. 1965 Feb;73:233–41.
22. Maurice DM. The dynamics and drainage of tears. *Int Ophthalmol Clin*. 1973;13(1):103–16.
23. Becker BB. Tricompartiment model of the lacrimal pump mechanism. *Ophthalmology*. 1992 Jul;99(7):1139–45.
24. Doane MG. Blinking and the mechanics of the lacrimal drainage system. *Ophthalmology*. 1981 Aug;88(8):844–51.
25. Thale A, Paulsen F, Rochels R, Tillmann B. Functional anatomy of the human efferent tear ducts: a new theory of tear outflow mechanism. *Graefes Arch Clin Exp Ophthalmol Albrecht Von Graefes Arch Klin Exp Ophthalmol*. 1998 Sep;236(9):674–8.
26. Kushner BJ. Congenital nasolacrimal system obstruction. *Arch Ophthalmol Chic Ill* 1960. 1982 Apr;100(4):597–600.
27. MacEwen CJ, Young JD. Epiphora during the first year of life. *Eye Lond Engl*. 1991;5 ( Pt 5):596–600.
28. Mannor GE, Rose GE, Frimpong-Ansah K, Ezra E. Factors affecting the success of nasolacrimal duct probing for congenital nasolacrimal duct obstruction. *Am J Ophthalmol*. 1999 May;127(5):616–7.

29. Aggarwal RK, Misson GP, Donaldson I, Willshaw HE. The role of nasolacrimal intubation in the management of childhood epiphora. *Eye Lond Engl*. 1993;7 ( Pt 6):760–2.
30. Hakin KN, Sullivan TJ, Sharma A, Welham RA. Paediatric dacryocystorhinostomy. *Aust N Z J Ophthalmol*. 1994 Nov;22(4):231–5.
31. Lyons CJ, Rosser PM, Welham RA. The management of punctal agenesis. *Ophthalmology*. 1993 Dec;100(12):1851–5.
32. Linberg JV, McCormick SA. Primary acquired nasolacrimal duct obstruction. A clinicopathologic report and biopsy technique. *Ophthalmology*. 1986 Aug;93(8):1055–63.
33. Nemet AY, Vinker S. Associated morbidity of nasolacrimal duct obstruction--a large community based case-control study. *Graefes Arch Clin Exp Ophthalmol Albrecht Von Graefes Arch Klin Exp Ophthalmol*. 2014 Jan;252(1):125–30.
34. Ali MJ, Joshi SD, Naik MN, Honavar SG. Clinical profile and management outcome of acute dacryocystitis: two decades of experience in a tertiary eye care center. *Semin Ophthalmol*. 2015 Mar;30(2):118–23.
35. Nascimento SB do, Rodrigues AB, Jurity TPM, Sá JC de, Castelo Branco AN de O. Lacrimal sac mucocele. *Braz J Otorhinolaryngol*. 2014;80(6):540–1.
36. Hawes MJ. The dacryolithiasis syndrome. *Ophthal Plast Reconstr Surg*. 1988;4(2):87–90.
37. Ali MJ, Paulsen F. Etiopathogenesis of Primary Acquired Nasolacrimal Duct Obstruction: What We Know and What We Need to Know. *Ophthal Plast Reconstr Surg*. 2019;35(5):426–33.
38. Savar A, Kirsztrot J, Rubin PAD. Canalicular involvement in dog bite related eyelid lacerations. *Ophthal Plast Reconstr Surg*. 2008;24(4):296–8.
39. Unger JM. Fractures of the nasolacrimal fossa and canal: a CT study of appearance, associated injuries, and significance in 25 patients. *AJR Am J Roentgenol*. 1992 Jun;158(6):1321–4.
40. Bartley GB. Acquired lacrimal drainage obstruction: an etiologic classification system, case reports, and a review of the literature. Part 2. *Ophthal Plast Reconstr Surg*. 1992;8(4):243–9.
41. Bartley GB. Acquired lacrimal drainage obstruction: an etiologic classification system, case reports, and a review of the literature. Part 3. *Ophthal Plast Reconstr Surg*. 1993;9(1):11–26.

42. Juri Mandić J, Ivkić PK, Mandić K, Lešin D, Jukić T, Petrović Jurčević J. Quality of Life and Depression Level in Patients with Watery Eye. *Psychiatr Danub*. 2018 Dec;30(4):471–7.
43. Leong SC, Macewen CJ, White PS. A systematic review of outcomes after dacryocystorhinostomy in adults. *Am J Rhinol Allergy*. 2010;24(1):81–90.
44. Erdöl H, Akyol N, Imamoglu HI, Sözen E. Long-term follow-up of external dacryocystorhinostomy and the factors affecting its success. *Orbit Amst Neth*. 2005 Jun;24(2):99–102.
45. Warren JF, Seiff SR, Kavanagh MC. Long-term results of external dacryocystorhinostomy. *Ophthalmic Surg Lasers Imaging Off J Int Soc Imaging Eye*. 2005;36(6):446–50.
46. Panda BB, Nayak B, Mohapatra S, Thakur S, Vishwanath S. Success and complications of endoscopic laser dacryocystorhinostomy vs. external dacryocystorhinostomy: A systematic review and meta-analysis. *Indian J Ophthalmol*. 2023 Oct;71(10):3290–8.
47. Aytogan H, Doran MA, Ayintap E. Outcomes of External Dacryocystorhinostomy under General and Local Anesthetics in a Tertiary Clinic. *Beyoglu Eye J*. 2022;7(1):25–9.
48. DeParis SW, Goldberg AN, Indaram M, Grumbine FL, Kersten RC, Vagefi MR. Paranasal Sinus Mucocele as a Late Complication of Dacryocystorhinostomy. *Ophthal Plast Reconstr Surg*. 2017;33(3S Suppl 1):S23–4.
49. Dulku S, Akinmade A, Durrani OM. Postoperative infection rate after dacryocystorhinostomy without the use of systemic antibiotic prophylaxis. *Orbit Amst Neth*. 2012 Feb;31(1):44–7.
50. Vagefi MR, Winn BJ, Lin CC, Sires BS, LauKaitis SJ, Anderson RL, et al. Facial nerve injury during external dacryocystorhinostomy. *Ophthalmology*. 2009 Mar;116(3):585–90.