

Glibenclamide - Induced Photoallergic Reaction

Rupert Gostiša, Eva; Jurakić Tončić, Ružica; Caccavale, Stefano; Čeović, Romana

Source / Izvornik: **Dermatology Practical & Conceptual, 2024, 14**

Journal article, Published version

Rad u časopisu, Objavljena verzija rada (izdavačev PDF)

<https://doi.org/10.5826/dpc.1402a114>

Permanent link / Trajna poveznica: <https://um.nsk.hr/um:nbn:hr:105:436778>

Rights / Prava: [Attribution-NonCommercial 4.0 International/Imenovanje-Nekomercijalno 4.0 međunarodna](#)

Download date / Datum preuzimanja: **2025-02-27**



Repository / Repozitorij:

[Dr Med - University of Zagreb School of Medicine Digital Repository](#)



Glibenclamide-induced Photoallergic Reaction

Eva Rupert Gostiša¹, Ružica Jurakić Tončić¹, Stefano Caccavale², Romana Čeović¹

¹ Department of Dermatology and Venereology, University Hospital Centre Zagreb, School of Medicine, University of Zagreb, Zagreb, Croatia

² Dermatology Unit, University of Campania Luigi Vanvitelli, Naples, Italy

Citation: Rupert Gostiša E, Jurakić Tončić R, Caccavale S, Čeović R. Glibenclamide - Induced Photoallergic Reaction. *Dermatol Pract Concept*. 2024;14(2):e2024114. DOI: <https://doi.org/10.5826/dpc.1402a114>

Accepted: November 14, 2023; **Published:** April 2024

Copyright: ©2024 Rupert Gostiša et al. This is an open-access article distributed under the terms of the Creative Commons Attribution-NonCommercial License (BY-NC-4.0), <https://creativecommons.org/licenses/by-nc/4.0/>, which permits unrestricted noncommercial use, distribution, and reproduction in any medium, provided the original authors and source are credited.

Funding: None.

Competing Interests: None.

Authorship: All authors have contributed significantly to this publication.

Corresponding Author: Professor Romana Čeović, MD, PhD, Department of Dermatology and Venereology, University Hospital Centre Zagreb, School of Medicine, University of Zagreb, Kišpatičeva 12, 10000 Zagreb, Croatia. E-mail: romana.ceovic@gmail.com

Case Presentation

A 78-year-old female with psoriasis came to our department due to PUVA phototherapy. Following five PUVA sessions (each exposure of 5 J/cm²), a reaction occurred presenting as intense erythema, followed by lamellar desquamation. According to the data, she had been exposed to the sun every summer during the last 20 years and had had several previous PUVA treatments for psoriasis but had not experienced any kind of skin reaction or sun intolerance. The only medication she had been taking was glibenclamide for the past 20 years. When the reaction occurred, she was treated with parenteral dexamethasone of 8 mg for three consecutive days, followed by oral prednisone 30 mg for five days, 20 mg for five days, and 10 mg for five days as well with topical corticosteroids. She was advised to stop taking glibenclamide and to avoid all other types of sulfonylurea drugs. Avoidance of sunlight, protective clothing, and application of broadband sunscreen with UVA filters were recommended. Patch test and photopatch test to glibenclamide with exposure to 5 J of UVA were done. Despite negative results, glibenclamide was substituted with metformin, and symptoms gradually diminished

within the following few weeks, without post-inflammatory hyperpigmentation.

Teaching Point

Photoallergic reaction is a cell-mediated type IV hypersensitivity that occurs due to interaction between the chemical photosensitizer and subsequent exposure to UV radiation, mostly UVA. The reaction is dose-independent, requires prior sensitization, and usually develops days/months after the exposure, sometimes even years [1]. Drugs constitute a major group of photosensitizers. Glibenclamide is a sulfonylurea hypoglycemic drug used for the treatment of type II diabetes [2]. Even though in our patient's photopatch test to glibenclamide was negative, symptoms disappeared within a short time after glibenclamide withdrawal and avoidance of UV radiation. This identified glibenclamide as the culprit drug and suggested the diagnosis of photoallergic reaction. Physicians should be aware that glibenclamide-induced photoallergic reaction can develop many years after starting the medication; taking detailed medical history of a patient is therefore very important.

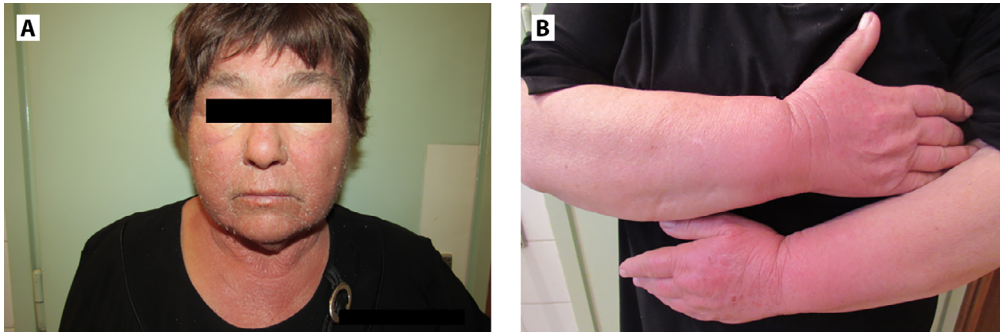


Figure 1. (A, B) Development of intense erythema with lamellar desquamation on the face, neck, and upper extremities after long-term glibenclamide use and subsequent exposure to phototherapy.

References

1. Singal A, Bhattacharya S N, Baruah M C. Glibenclamide induced photosensitivity. *Indian J Dermatol Venereol Leprol* 2002; 68:240-241.
2. Gayathri A, Anand R Kanaki, Patil BV, Ashok Binjawadgi, Basavambika V Anandi. "A case of sulfonylurea induced phototoxicity in an elderly subject - a rare case report". *Journal of Evolution of Medical and Dental Sciences* 2013; Vol2, Issue 39, September 30; Page: 7472-7474.