

# Causes of elevated troponin in patients with normal coronary angiography

---

**Reschner, Ana**

**Master's thesis / Diplomski rad**

**2016**

*Degree Grantor / Ustanova koja je dodijelila akademski / stručni stupanj:* **University of Zagreb, School of Medicine / Sveučilište u Zagrebu, Medicinski fakultet**

*Permanent link / Trajna poveznica:* <https://um.nsk.hr/um:nbn:hr:105:616515>

*Rights / Prava:* [In copyright](#)/[Zaštićeno autorskim pravom.](#)

*Download date / Datum preuzimanja:* **2024-08-31**



*Repository / Repozitorij:*

[Dr Med - University of Zagreb School of Medicine Digital Repository](#)



**UNIVERSITY OF ZAGREB**

**SCHOOL OF MEDICINE**

**Ana Reschner**

**Causes of Elevated Troponin in Patients  
with Normal Coronary Angiography**

**GRADUATE THESIS**



**Zagreb, 2016**

UNIVERSITY OF ZAGREB

SCHOOL OF MEDICINE

Ana Reschner

**Causes of Elevated Troponin in Patients  
With Normal Coronary Angiography**

GRADUATE THESIS

Zagreb, 2016

This graduate thesis was written under the supervision and mentoring of Prof. dr. sc. Maja Strozzi Chair for Congenital and Valvular diseases, Cardiology department at KBC Zagreb - Rebro, the University Hospital Center. The thesis was submitted for evaluation in 2015/2016.

## Abbreviations

ACC/AHA - American College of Cardiology/American Heart Association

ACE - Angiotensin Converting Enzyme

ACS - Acute Coronary Syndrome

AF - Atrial Fibrillation

AS - Aortic Stenosis

ASD - Atrial Septal Defect

BPM - Beats per minute

CABG - Coronary Artery Bypass Graft

CAD - Coronary Artery Disease

CHF - Congestive Heart Failure

COPD - Chronic Obstructive Pulmonary Disease

cTnC - Cardiac troponin C

cTnT - Cardiac troponin T

cTnI - Cardiac troponin I

CTO - Chronic Total Occlusion (of coronary artery)

CVI - Cerebrovascular Insult

DM2 - Diabetes Mellitus Type 2

ECG - Electrocardiogram

HOCM - Hypertrophic Obstructive Cardiomyopathy

KBC - Klinički Bolnički Centar

LCX – Left Circumflex Artery

LV - Left Ventricle

NSTEMI - Non ST-elevation Myocardial Infarction

PTSMA - Percutaneous Transluminal Septal Myocardial Ablation

PCI - Percutaneous Coronary Intervention

RA - Rheumatoid Arthritis

RBBB - Right Bundle Branch Block

RV - Right Ventricle

SPECT - Single-Photon Emission Computed Tomography

STEMI - ST-elevation Myocardial Infarction

SVT - Supraventricular Tachycardia

TAVI - Transcatheter Aortic Heart Valve

VT - Ventricular Tachycardia

**Contents:**

- 1. INTRODUCTION ..... 1
- 2. METHODS..... 3
  - 2.1 Data assessment ..... 3
  - 2.2 Exclusion criteria ..... 3
  - 2.3. Evaluation of patients ..... 3
  - 2.4 Diagnostic criteria..... 4
    - 2.4.1. Takotsubo syndrome ..... 4
    - 2.4.2. Shock ..... 4
    - 2.4.3. Pulmonary embolism ..... 4
    - 2.4.4. Hypertensive heart disease ..... 5
    - 2.4.5 Tachycardia ..... 5
    - 2.4.6. Malignant disease progression ..... 5
    - 2.4.7. Hypertensive crisis ..... 5
    - 2.4.8. Pulmonary hypertension ..... 5
    - 2.4.9. Atrial fibrillation ..... 5
- 3. RESULTS ..... 6
  - 3.1. Coronary angiography in KBC Zagreb ..... 6
  - 3.2. Laboratory results ..... 8
  - 3.3 Clinical presentation ..... 8
  - 3.4. Comorbidities and risk factors ..... 9
  - 3.5. Etiology of myonecrosis with normal coronary arteries ..... 10
  - 3.6. ECG findings ..... 10
  - Patient 1 ..... 11
  - Patient 2..... 13
  - Patient 3..... 13
- 4. DISCUSSION ..... 14
- 5. CONCLUSION..... 16
- 6. ACKNOWLEDGMENT..... 17
- 7. REFERENCES ..... 18
- 8. BIOGRAPHY ..... 23

## Summary

Title: Causes of elevated Troponin in Patients with Normal Coronary Angiography

Keywords: Cardiac troponin, Angiographic coronary artery disease, Myocardial cell injury

Author: Ana Reschner

Troponin rise indicates myocardial cell injury. However, elevated values of troponin are not always consequence of infarction or ischemia.

In this paper, aim was to elucidate diverse etiologies of elevated troponin in patients with normal coronary angiography.

At KBC Zagreb in 2014 there was 976 patients identified from catheterization database who underwent coronary angiography due to suspicion of acute coronary syndrome (ACS). We identified 30 (3.1%) patients who had alternative cause for myocyte injury other than coronary artery disease (CAD), meaning that there was less than 30 % coronary arterial luminal stenosis.

The elevation of cardiac troponin T (cTnT) in patients with normal coronary angiography was attributed to diverse etiologies, including hypertensive crisis, Takotsubo syndrome, severe aortic stenosis, atrial fibrillation (AF), chronic obstructive pulmonary disease (COPD) exacerbation, advanced heart failure, hypertensive cardiomyopathy, acute pulmonary embolism, malignant disease progression, and cardiogenic shock.

Apart from ACS, cTnT could be elevated in a number of different conditions, which should be considered according to clinical presentation, different diagnostic procedure, and still could reflect myonecrosis, even in the absence of significant angiographic CAD.



## 1. INTRODUCTION

Troponin is a complex which consists of three proteins: cTnC, cTnI and cTnT, which control skeletal and cardiac muscle contraction in response to intracellular calcium. Around 6-8% of cTnT and 2.8 – 8.3 % of cTnI are found free in the cytosol (1). Most commonly they are released as a result of proteolytic degradation. Initially Troponin is released from the cytoplasmic pool, following more release from quantities bound to deteriorating myofilaments (2).

The measurement of serum cTnI and cTnT is superior in comparison to the measurement of cTnC in the identification of cardiac muscle damage in terms of sensitivity and specificity to cardiac muscle enzyme measurements (1).

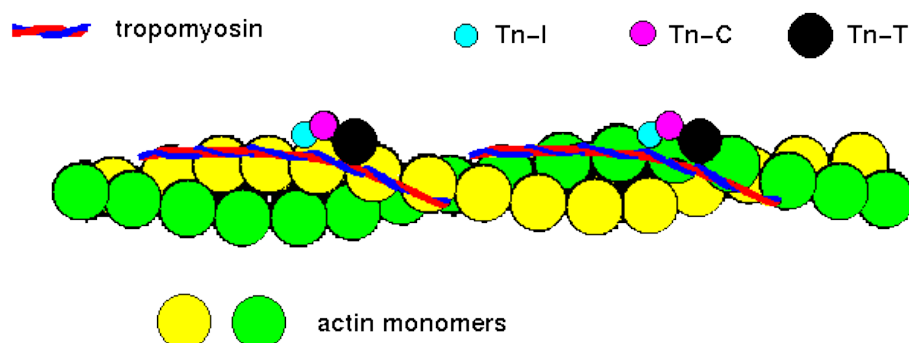
In peripheral blood, it takes 3-4 hours for cTnT to begin to rise after the onset of myocardial injury and remains increased for 10–14 days (3).

Troponins are markers, which indicate presence of myocardial cell injury and necrosis but they do not indicate the mechanism causing it (4-7). Furthermore, ACC/AHA guidelines also indicate that the troponin elevation signifies myocardial necrosis but this troponin increase is not necessarily due to atherosclerotic coronary artery disease (8). Therefore, myocardial infarction should be diagnosed in conjunction with other supportive evidence.

Myonecrosis can be a result of a number of other clinical situations with cardiac and non-cardiac etiologies (10-12). respectively named in Table 1 but they will be commented later.

In this paper three patients with “non- ischemic” causes of elevated troponin will be discussed. Thus, with absent angiographically significant coronary artery disease.

**Figure 1. Troponin**



**Table 1.** Possible etiologies of elevated troponin in patients with normal coronary angiography

<b>Direct damage to myocardium</b>	<b>Diminished oxygen supply to myocardium</b>	<b>Increased oxygen demand</b>	<b>Increased demand and diminished supply</b>	<b>Other causes</b>
Inflammation (either myocarditis or pericarditis)	Coronary embolus	Left ventricular hypertrophy	Tachycardia and severe AS	Infiltrative disease of myocardium
Electrical discharge	shock	cardiomyopathy	Tachycardia associated with bleeding	Renal failure
Mechanical damage	GI bleeding	COPD	sepsis	hypothyroidism
Chemical damage	Anemia	Valvular lesion	Severe CHF	False positive troponin (RA, cirrhosis)
	Coronary spasm	SVT		Diabetic ketoacidosis
	Hypercoagulable state	Extreme endurance exercise		Scorpion toxin
	Aortic dissection	Increased sympathetic activity		
	Coronary dissection	ASD failure associated with RV dilation		

(13-20)

## **2. METHODS**

### 2.1 Data assessment

Data was assessed retrospectively from medical files and databases collected in 2014 at KBC Zagreb. Patients who were considered for this study were patients who underwent coronary angiography in 2014 at KBC Zagreb due to suspicion of ACS, and patients who had troponin-positive “chest pain”. This involved a total of 976 patients who underwent cardiac catheterization within 48h of admission in the aforementioned year.

### 2.2 Exclusion criteria

Exclusion criteria was coronary arterial luminal stenosis greater than 30%, and missing medical data.

### 2.3. Evaluation of patients

Upon arrival, Troponin T was determined immediately and at 8, and 12 h after the onset of pain, but peak Troponin T values were used for the purpose of this research. The high-sensitive cTnT (hs-cTnT) assay was used to detect the presence of troponin in serum. This assay is a modification of the fourth-generation cTnT assay and is significantly improved (21). This new type of cTnT assay further reduces the susceptibility for false “positive” troponin.

Troponin T increase was defined as  $>0.014$  ng/mL (14 ng/L) (cut off value).

Within 24 h from admission, routine CRP was measured. Concentration  $>5$  ng/ml was considered elevated.

Creatinine is determined by enzymatic colorimetric assay. Cut-off value for male was 105  $\mu\text{mol/l}$ , and for females 85 $\mu\text{mol/l}$ .

Serum value of Creatinine Kinase was measured using an enzymatic rate method of foregoing reaction catalyzed by Creatinine Kinase. Normal reference range is 0-177 u/L.

Creatinine Kinase activities are greatest in skeletal muscles, followed by the heart, brain, and other tissue (22).

Chest pain unit protocol was used to evaluate patients (23).

It consisted of the clinical history (also to establish risk factors for atherosclerotic CAD), physical examination, ECG, echocardiography and coronary angiography.

## 2.4 Diagnostic criteria

### 2.4.1. Takotsubo syndrome

The diagnosis of Takotsubo syndrome, stress cardiomyopathy, was diagnosed based on presence of all defined criteria:

1. *Transient hypokinesis, akinesis, or dyskinesis in the left ventricular mid segments with or without apical involvement; regional wall motion abnormalities that extend beyond a single epicardial vascular distribution; and a stressful trigger*
2. *the absence of obstructive coronary disease or angiographic evidence of acute plaque rupture*
3. *new ECG abnormalities (ST-segment elevation and/or T-wave inversion) or modest elevation in cardiac troponin*
4. *the absence of pheochromocytoma and myocarditis (24).*

### 2.4.2. Shock

Shock was established when despite pharmacologic and mechanical support systolic blood pressure remained below 80mmHg or cardiac index was below 2 l/min/m<sup>2</sup>.

### 2.4.3. Pulmonary embolism

Pulmonary embolism was established when there was dyspnea or pleuritic chest pain present and ECG changes (S1Q3T3).

#### 2.4.4. Hypertensive heart disease

Hypertensive heart disease was diagnosed based on clinical picture, and ventricular hypertrophy and diastolic dysfunction based on echocardiography (25).

#### 2.4.5 Tachycardia

A ventricular response greater than 100/bpm was defined as tachycardia.

#### 2.4.6. Malignant disease progression

Diagnosis of severe critical illness was documented in this paper as progressed gastric carcinoma.

#### 2.4.7. Hypertensive crisis

Hypertensive crisis was diagnosed when there was a systolic pressure greater than 180mmHg and/or diastolic pressure greater than 110mmHg, with associated acute end-organ damage (26).

#### 2.4.8. Pulmonary hypertension

Pulmonary hypertension was defined when mean pulmonary arterial pressure  $\geq 25$  mmHg at rest confirmed by right heart catheterization.

#### 2.4.9. Atrial fibrillation

Atrial fibrillation was defined when ECG findings included oscillatory or fibrillatory waves of different sizes replacing normal consistent P waves, with rapid ventricular response, greater than 90 beats per minute.

### 3. RESULTS

#### 3.1. Coronary angiography in KBC Zagreb

Total of 2530 patients in 2014 at KBC Zagreb underwent coronary angiography due to different indications, which are respectively named in Table 2.

976 (38.6%) patients had troponin positive “chest pain” and consequently had suspicion for ACS. Of the total 976 patients with suspicion of ACS, 30 (3.1%) had potential alternative cause for myocyte injury.

The average of serum troponin T in patients without ACS or any other significant CAD was 0.41 ng/l. The lowest measured value was 0.016ng/l, and the highest measured troponin value in patients with normal coronary angiography was 2.28 ng/l. Average Troponin T concentration obtained in serum was 0.90 ng/l.

Furthermore, patients who were diagnosed with STEMI and NSTEMI had significantly higher values of troponin in serum.

**Table 2.** Indications for coronary angiography in 2014 in KBC Zagreb

<b>Indication</b>	<b>% of patients (n=2530)</b>
Stable angina	22.94
ACS with ST-elevation and increased troponin	14.93
ACS without ST-elevation and increased troponin	11.70
Unstable angina	10.93
Post-transplant evaluation	6.62
ACS with ST-elevation and normal troponin	6.51
Ischemic heart disease screening	4.66
Elective PCI	4.20
PCI control	4.00
Pre-operative evaluation	3.96
Valvular heart disease evaluation	3.85
Cardiomyopathy	3.27
Cardiac arrest	0.89
Rhythm abnormality	0.89

Subacute STEMI	0.77
Post-operative evaluation	0.69
Pre transplantation evaluation	0.65
Post CABG evaluation	0.65
ACS without ST- elevation and normal troponin	0.62
VT	0.50
HOCM	0.46
Atypical chest pain	0.42
Congenital heart disease	0.38
Temporary pacemaker	0.35
TAVI assessment	0.31
Cardiogenic shock	0.31
Positive stress test	0.31
CABG assessment	0.27
Aortic aneurysm	0.27
Positive SPECT	0.27
Heart failure	0.23
Pericarditis	0.23
PTSMA	0.19
In-stent restenosis	0.19
CTO	0.19
Recent myocardial infarction	0.15
Myocarditis	0.15
Endocarditis	0.12
Subchronic STEMI	0.12
Chest pain	0.12
Stent thrombosis	0.12
Diascopy	0.08
Fibrinolyzed chronic myocardial infarction	0.04
CVI	0.04

### 3.2. Laboratory results

Of the total 976 patients with suspicion of ACS, 30 (3.1%) patients had alternative causes for myocyte injury. CRP was measured in all 30 patients, and in 15 (50%) was found to be raised. The lowest «positive» detected concentration was 6.9 mg/L, and highest measured CRP value was 73,7 mg/L.

Creatinine Kinase was found to be raised in 12 patients (40%) with normal coronary angiography. The average was 228.7 U/L, with lowest value being 31 U/L and the highest 859 U/L.

Creatinine lowest measured value was 39 µmol/L and highest measured value was 124 µmol/L. The average was 72 µmol/L.

### 3.3 Clinical presentation

The most common complaint found among these patients was chest pain. Classification of chest pain described in those patients is given in Table 3.

**Table 3.** *Types of chest pain in patients with elevated troponin and normal coronary angiography*

Type of chest pain	% of patients (n=30)
Typical	43.3
Atypical	30.0
Non-anginal pain	26.7

*Typical features include:*

- 1. Retrosternal location of discomfort (in whole or in part)*
- 2. Provocation by activity or stress*
- 3. Relief by rest or nitroglycerin*

*If all three features are present the chest pain or discomfort is classified as **TYPICAL ANGINAL PAIN**. If two of three features are present the chest discomfort is classified as **ATYPICAL ANGINAL PAIN**. If only one of three features are present, the chest discomfort is classified as **NON ANGINAL CHEST PAIN** (9, 23).*



Other clinical presentations found in patients with troponin-positive “chest pain” are given in Table 4.

**Table 4.** *Clinical presentations of patients with elevated troponin and normal coronary angiography*

<b>Other clinical presentations</b>	<b>% patients (n=30)</b>
Dyspnea	33.3
Nausea	13.3
Tingling in arms or hands	13.3
Night sweats	10.0
Palpitations	10.0
Dry cough	6.7
Vertigo	6.7
General weakness	3.3
dysphagia	3.3

#### 3.4. Comorbidities and risk factors

The majority of patients with troponin positive “chest pain” have history of risk factors and comorbidities, which increase risk for further cardiovascular events (table 5).

**Table 5.** *Comorbidities and risk factors*

<b>Comorbidity</b>	<b>% of patients (n=30)</b>
Hypertension	70
Hypercholesterolemia	53
Smoking	30
History of ACS	23
DM 2	23
CHF	23
COPD	13

### 3.5. Etiology of myonecrosis with normal coronary arteries

The most common cause identified was hypertensive crisis, followed by Takotsubo syndrome. Others causes include pulmonary embolism, AF, cardiogenic shock, COPD exacerbation, malignant disease progression, severe aortic stenosis, persistent ventricular tachycardia, pulmonary hypertension, severe aortic stenosis, advanced heart failure, and in two patients no precipitants for increased troponin were identified (Table 6).

**Table 6.** *The causes of elevated Troponin in observed patients*

<b>Dx</b>	<b>% of patients (n=30)</b>
Hypertensive crisis or urgency	20.00
Takotsubo syndrome	16.67
AF	10.0
COPD exacerbation	10.0
Inconclusive	10.0
Moderate to severe AS	6.67
Advanced heart failure	6.67
Pulmonary hypertension	3.33
Hypertensive cardiomyopathy	3.33
Acute pulmonary embolism	3.33
Malignant disease progression	3.33
Cardiogenic Shock	3.33
VT	3.33

### 3.6. ECG findings

All of electrocardiogram findings are given in Table 7. ST elevations were common in patients diagnosed with Takotsubo syndrome negative T waves were most commonly seen with hypertensive crisis (Table 7).

**Table 7. ECG findings**

<b>ECG findings</b>	<b>% Patients (n=30)</b>
T inversion	23.3
ST-elevation (more than 0.05 mV)	20.0
No changes	16.7
AF	13.3
RBBB	13.3
P pulmonale	10.0
S1Q3T3	3.3

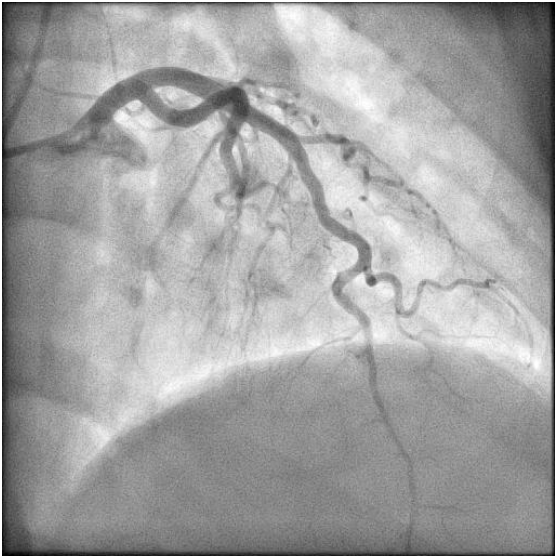
### Patient 1

A 44 year old nonsmoker, with negative family history of ischemic heart disease was admitted to KBC Zagreb from Opća bolnica Bjelovar due to suspicion of STEMI. Her other comorbidities are arterial hypertension (controlled), hypercholesterolemia (well controlled), obesity and depression. Her 12-lead ECG showed ST elevations (around 1mm) in inferolateral leads. Her RR was 140/75 mmHG. Troponin T levels were raised at 1.36 µg/L, CRP was 6.9mg/l, CK MB 433 U/L, and creatinine was 75µmol/l.

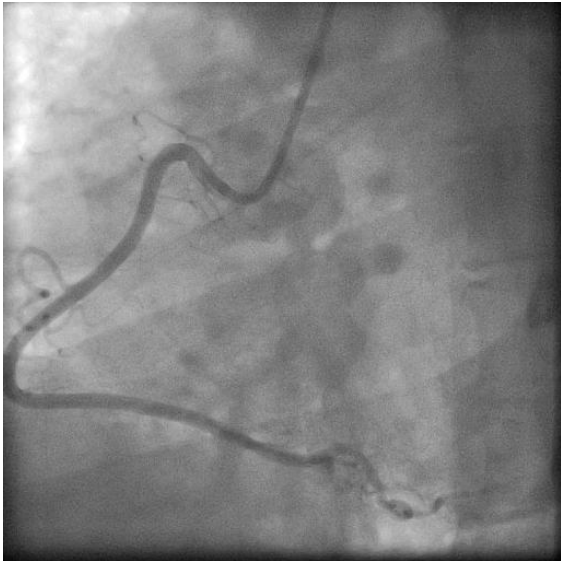Patient underwent examination with echocardiography were ballonings and akinetic apex were seen. EF was measured 50% by Teicholz method.

The patient underwent coronary angiography. Figure 2.a and 2.b illustrate the normal appearance of right and left coronary arteries, but on ventriculogram an anteroapical akinesia of LV was obtained suggesting that the cause of raised troponin is stress cardiomyopathy – Takotsubo syndrome (Figure 3). Patient was discharged with beta blockers, statins and advised to follow a strictly diet.

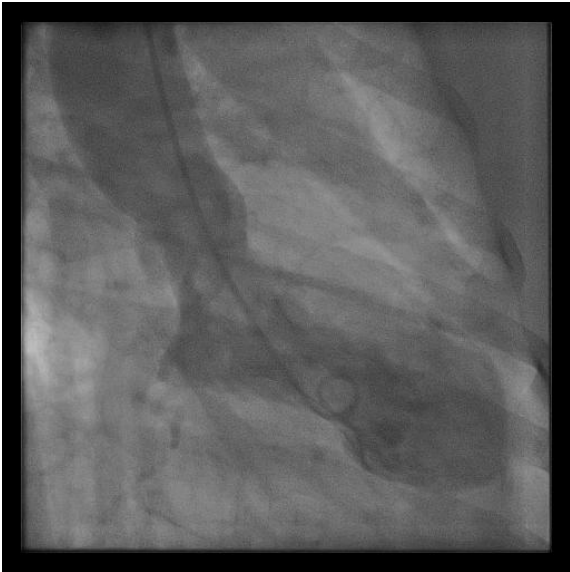**Figure 2.a** Coronarogram of LAD



**Figure 2.b** Coronarogram of RCA



**Figure 3.** Ventriculogram



## Patient 2

A 73-year-old smoker, hypercholesterolemic, and hypertensive (180/110mmHg) came to the emergency department with a chief complaint of typical chest pain and accompanied feeling of shortness of breath. In 2013 she was diagnosed with 50% stenosis of internal carotid artery. Peak troponin T measured during her hospital stay was 0.065 µg/L, CRP was 0.4 mg/L, CK 119 U/l, and creatinine at 84 µmol/L. Her 12-lead ECG showed negative T waves in lead aVL.

The angiogram did not show any significant coronary artery stenosis, only torturous coronary arteries. On echocardiography moderate to severe AS was confirmed. Patient got conservative therapy and antihypertensive medication, which ease her symptoms and signs. She was diagnosed with hypertensive urgency and moderate to severe AS. She was discharged with beta blockers, Aspirin, diuretics, antihypertensive medication, and statins.

## Patient 3

A 57-years old heavy smoker, dyslipidemic with elevated blood pressure (170/110 mmHg) came to emergency department in KBC Zagreb with a chief complaint of persistent typical chest pain. Other complaints were blurred vision, epistaxis, and severe headache. In the history there were no other comorbidities identified. Peak troponin T measured was 0.902 µg /l, CRP was 2.9 mg/L, CK 859 U/L, creatinine was 88 µmol/L. His 12- lead ECG did not show any changes.

Cardiac catheterization did not show any significant CAD, only less than 30% stenosis of LCX. Echocardiogram showed that there was minor to moderate septal hypertrophy, with normal systolic function. He was diagnosed with hypertrophic cardiomyopathy. The patient was given Nitrate, but he claimed that the intensity of his chest pain did not change. After 3 days the patient was released with a diagnosis of hypertensive heart disease with diastolic dysfunction. He was released with a therapy including statins, ACE inhibitors, anti aggregation therapy, Aspirin and also was advised to follow a strict diet to control his lipid levels. He was advised to see his cardiologist in 6 months and to repeat all diagnostic procedures.

#### 4. DISCUSSION

In this paper, 30 (3.1%) patients in 2014 in KBC Zagreb with troponin-positive chest pain and suspicion of ACS, were considered not to be related to angiographically significant coronary artery disease.

Values of troponin increase were not so useful in diagnosing ACS, and cardiac diagnostic procedure, echocardiography was frequently abnormal in patients without ACS or significant coronary artery disease.

Various cardiac and non-cardiac conditions have been described to cause the increase of troponin, in the absence of criteria to diagnose ACS (5-7,12-20, 24-25).

Mechanisms causing elevation of troponin, whether it is due to ACS or some other mechanism is of major therapeutic importance. Unnecessary coronary angiograms may not be appropriate in some of these patients. Increased troponin and absence of typical presentation of ACS, presents a diagnostic challenge. Patients who were reviewed in this paper, all had alternative etiology causing elevation of troponin, although the mechanism causing it in some cases was unclear.

Troponin may arise as a result of mismatch between myocardial oxygen supply and demand, as a result of direct damage, and also irreversible myocyte injury can cause an initial release of cytosolic troponin, in contrast to reversible injury which causes release of factors which lead to increased permeability of the membrane and leakage of degraded free troponin without myocyte necrosis (27).

Some cases involved true myocyte necrosis, which was related to increased oxygen demand in the absence of an appropriate supply (10). Furthermore, epicardial luminal stenosis is more likely to cause such a mismatch. In addition, some studies describe it in patients without evidence of coronary impairment (5, 10).

A good example of mismatch is hypertensive crisis, which was observed in most of the patients reviewed (28).

Strenuous exercise, catecholamine release and stress-related neuropeptides (last two most commonly seen in Takotsubo syndrome) are also documented causes (24, 29).

Tachycardia can also result in increase of troponin because there is a decreased time available for diastolic coronary perfusion (31). Alteration in the ST segment during episodes of tachycardia are not necessary indications for the presence of ischemia (32). Troponin elevation and the rate and duration of tachycardia, however shown no connections in between them (31, 32).

Toxic cytokines, ongoing apoptosis, chronic ischemia, and loss of cell membrane integrity can all cause elevation of troponin in patients with heart failure (33, 34). In addition, ongoing loss of viable cardiac myocytes, which is characteristic for progressive heart failure explains elevation of troponin (35).

In patients with moderate-to-large pulmonary embolism or massive pulmonary embolism elevation of troponin has been observed. It can be a result of increase in right ventricular myocardial oxygen demand, which may lead to right ventricular dilation and ischemia (36).

Exaggerated inflammatory response, as it is seen in patients with COPD exacerbation can also predispose for myocardial injury (37). In those patients elevated troponin is a strong predictor of in-hospital death in patients who are admitted for COPD exacerbation (38).

Ischemia can also be result of impaired coronary flow reserve caused by combination of the ventricular hypertrophy, tachycardia, and lower perfusion pressure, all which can occur in critical aortic stenosis (39)

Other conditions causing troponin release in the absence of ACS or significant coronary artery disease include conditions that affect myocardial cell metabolism, mechanisms that are still unknown, and also it was observed in patients with malignant disease progression.

To conclude everything that has been learnt doing research for this paper is that an elevated troponin can be a prognostic value in certain non-ischemic causes.

## **5. CONCLUSION**

Absence of angiographically significant coronary disease, excludes ACS as a cause of elevated troponin.

This small group of observed patients with elevated troponin due to diverse etiology requires further investigation of the mechanism, which causes an elevation of troponin and risk stratification.

Biochemical investigation with use of Troponin T as a screening method in patients with etiology other than ACS should be discouraged.

Troponin is not so useful to “rule in” ACS due to lack of its specificity, but it is a sensitive biomarker to “rule out” non-ST-segment elevation myocardial infarction.

Inappropriate therapy and delays in definitive diagnosis and treatment may be observed in such a patients because of misleading positive troponin.



## 6. ACKNOWLEDGMENT

Foremost, I would like to express my sincere gratitude to my mentor prof. dr. sc Maja Strozzi, dr.med. for the inspiration to pursue my study of causes for elevated troponin in patients with normal coronary angiography. Her personal experience and expertise, motivation, guidance and teaching inspired me to choose this exciting subject as the topic of my graduate thesis.

I would also like to give my thanks and appreciation to Zoran Mioviski, dr.med. for his effort and precious help in guiding and directing myself throughout this paper

Besides my mentor, I would like to thank the rest of my graduate thesis committee: doc. Dr. sc. Joško Bulum, dr.med and doc. dr.sc. \_\_\_\_\_, dr.med.

I would especially like to thank my family for supporting me throughout my studies and always encouraging me to do my best. I would also like to thank all my mentors and teachers throughout my medical career who have passionately shared their knowledge and experience with me and given me this opportunity to use this skills in the service of mankind.

## 7. REFERENCES

1. Collinson P, Boa F, Gaze D. Measurement of cardiac troponins. *Annals of Clinical Biochemistry*. 2001;38(5):423-449.
2. Antman E. Decision Making with Cardiac Troponin Tests. *New England Journal of Medicine*. 2002;346(26):2079-2082.
3. Christenson R. National Academy of Clinical Biochemistry Laboratory Medicine Practice Guidelines for Utilization of Biochemical Markers in Acute Coronary Syndromes and Heart Failure. *Clinical Chemistry*. 2007;53(4):545-546.
4. Zimmerman J, Fromm R, Meyer D, Boudreaux A, Wun C, Smalling R et al. Diagnostic Marker Cooperative Study for the Diagnosis of Myocardial Infarction. *Circulation*. 1999;99(13):1671-1677.
5. Mahajan N, Mehta Y, Rose M, Shani J, Lichstein E. ELEVATED TROPONIN LEVEL IS NOT SYNONYMOUS WITH MYOCARDIAL INFARCTION. *Chest*. 2005;128(4\_MeetingAbstracts).
6. Nageh T, Sherwood R, Wainwright R, Shah A, Thomas M. The clinical relevance of raised cardiac troponin I in the absence of significant angiographic coronary artery disease. *International Journal of Cardiology*. 2005;100(2):325-330.
7. Lai H. Causes of Increased Cardiac Troponin I Levels in Hospitalized Patients Without Coronary Artery Disease. *CHEST Journal*. 2011;140(4\_MeetingAbstracts):985A.
8. 2014 AHA/ACC Guideline for the Management of Patients With Non-ST-Elevation Acute Coronary Syndrome [Internet]. [Content.onlinejacc.org](http://content.onlinejacc.org). 2014 [cited 29 May 2016]. Available from: <http://content.onlinejacc.org/article.aspx?articleid=1910086>
9. Gibbons R, Chatterjee K, Daley J, Douglas J, Fihn S, Gardin J et al. ACC/AHA/ACP ASIM Guidelines for the Management of Patients With Chronic

Stable Angina: Executive Summary and Recommendations : A Report of the American College of Cardiology/American Heart Association Task Force on Practice Guidelines (Committee on Management of Patients With Chronic Stable Angina). *Circulation*. 1999;99(21):2829-2848.

10. Ammann P, Maggiorini M, Bertel O. Troponin as a risk factor for mortality in critically ill patients without acute coronary syndromes. *ACC Current Journal Review*. 2003;12(5):17.

11. Burness C. Pitfalls and problems of relying on serum troponin. *QJM*. 2005;98(5):365-371.

12. Jeremias A. Narrative Review: Alternative Causes for Elevated Cardiac Troponin Levels when Acute Coronary Syndromes Are Excluded. *Annals of Internal Medicine*. 2005;142(9):786.

13. Sybrandy K. Diagnosing cardiac contusion: old wisdom and new insights. *Heart*. 2003;89(5):485-489.

14. Hein S, Scheffold T, Schaper J. Ischemia induces early changes to cytoskeletal and contractile proteins in diseased human myocardium. *The Journal of Thoracic and Cardiovascular Surgery*. 1995;110(1):89-98.

15. Horwich T. Cardiac Troponin I Is Associated With Impaired Hemodynamics, Progressive Left Ventricular Dysfunction, and Increased Mortality Rates in Advanced Heart Failure. *Circulation*. 2003;108(7):833-838.

16. Logeart D, Beyne P, Cusson C, Tokmakova M, Leban M, Guiti C et al. Evidence of cardiac myolysis in severe nonischemic heart failure and the potential role of increased wall strain. *American Heart Journal*. 2001;141(2):247-253.

17. Ben Yedder N, Roux J, Paredes F. Troponin Elevation in Supraventricular Tachycardia: Primary Dependence on Heart Rate. *Canadian Journal of Cardiology*. 2011;27(1):105-109.
18. CARLSSON J. P-458 Elevation of cardiac troponin after sustained tachycardia is a frequent finding in patients without evidence of acute coronary disease. *Europace*. 2003;4:B174.
19. Lum G, Solarz D, Farney L. False Positive Cardiac Troponin Results in Patients Without Acute Myocardial Infarction. *Lab Med*. 2006;37(9):546-550.
20. Lauer M. Cardiac Troponins and Renal Failure: The Evolution of a Clinical Test. *Circulation*. 2005;112(20):3036-3037.
21. 12. Giannitsis E, Kurz K, Hallermayer K, Jarausch J, Jaffe A, Katus H. Analytical Validation of a High-Sensitivity Cardiac Troponin T Assay. *Clinical Chemistry*. 2009;56(2):254-261.
22. Glynn M, Drake W, Hutchison R. *Hutchison's clinical methods*. Edinburgh: Elsevier; 2012.
23. Borg G, Lindblad I, Holmgren A. QUANTITATIVE EVALUATION OF CHEST PAIN. *Acta Medica Scandinavica*. 2009;209(S644):43-45.
24. Akashi Y, Goldstein D, Barbaro G, Ueyama T. Takotsubo Cardiomyopathy: A New Form of Acute, Reversible Heart Failure. *Circulation*. 2008;118(25):2754-2762.
25. Alegría-Ezquerria E, González-Juanatey J, González-Maqueda I. Hypertensive Heart Disease: a Proposed Clinical Classification. *Revista Española de Cardiología (English Edition)*. 2006;59(4):398-399.
26. Vidt D. Hypertensive Crises: Emergencies and Urgencies. *The Journal of Clinical Hypertension*. 2004;6(9):520-525.

27. 14. Ammann P, Fehr T, Minder E, Günter C, Bertel O. Elevation of troponin I in sepsis and septic shock. *Intensive Care Med.* 2001;27(6):965-969.
28. Afonso L, Bandaru H, Rathod A, Badheka A, Ali Kizilbash M, Zmily H et al. Prevalence, Determinants, and Clinical Significance of Cardiac Troponin-I Elevation in Individuals Admitted for a Hypertensive Emergency. *The Journal of Clinical Hypertension.* 2011;13(8):551-556.
29. Troponin release following endurance exercise: is inflammation the cause? a cardiovascular magnetic resonance study. *BioMed Central Ltd;* 2010.
30. Schneider H. Elevated troponin in the absence of acute coronary syndrome – impact of troponin assay. *Pathology.* 2011;43:S18.
31. Xue F, Jiang T, Jiang B, Cheng X, He Y, Li X et al. Cardiac troponin I elevation with supraventricular tachycardia: two case reports and review of the literature. *BMC Research Notes.* 2014;7(1):136.
32. Coppola G, Carità P, Corrado E, Borrelli A, Rotolo A, Guglielmo M et al. ST segment elevations: Always a marker of acute myocardial infarction?. *Indian Heart Journal.* 2013;65(4):412-423.
33. Wencker D, Chandra M, Nguyen K, Miao W, Garantziotis S, Factor S et al. A mechanistic role for cardiac myocyte apoptosis in heart failure. *Journal of Clinical Investigation.* 2003;111(10):1497-1504.
34. Foo R, Mani K, Kitsis R. Death begets failure in the heart. *Journal of Clinical Investigation.* 2005;115(3):565-571.
35. Davies C, Harding S, Poole-Wilson P. Cellular mechanisms of contractile dysfunction in human heart failure. *European Heart Journal.* 1996;17(2):189-198.
36. Irwin Rippe J. *Irwin and Rippe's intensive care medicine.* Philadelphia: Wolters Kluwer Health/Lippincott Williams & Wilkins; 2012.

37. Soyseth V, Bhatnagar R, Holmedahl N, Neukamm A, Hoiseth A, Hagve T et al. Acute exacerbation of COPD is associated with fourfold elevation of cardiac troponin T. *Heart*. 2012;99(2):122-126.
38. Noorain S. Prognostic value of cardiac troponin I during acute exacerbation of chronic obstructive pulmonary disease: A prospective study. *Lung India*. 2016;33(1):53.
39. Nunes J. Elevated Troponin and Aortic Valve Disease. *Journal of the American College of Cardiology*. 2013;61(13):1467.

## 8. BIOGRAPHY

Ana Reschner was born on January 15th 1990 in Ljubljana, Slovenia. Originally she is Croatian as both her parents are. She finished her high school education at "Gymnasium Bežigrad", also in Ljubljana. She was enrolled in the University of Zagreb School of Medicine, in the academic year 2009/2010 where she is currently in her final year of study.

During her studies, Ana was involved in many extracurricular activities. She worked as a student demonstrator in the course propaedeutics in the internal intensive care unit at KBC Zagreb-Rebro under the mentorship of doc.dr.sc.Ivan Gornik. Furthermore, during her study years, she participated on congresses and workshops in Croatia and Slovenia.

In Summer 2015, Ana went to Houston as a visiting student trainee at Memorial Hermann Hospital at Heart and Vascular Institute on cardiology department, as she also volunteered during summer 2014 in Splošna Bolšnišnica Izola on gastroenterology department.

During her final year of study, Ana completed two-month rotation in internal medicine and surgery at the Ljubljana University Medical Center, in the internal intensive care unit, under mentorship of prof. dr. sc. Marko Noč, and at traumatology department, under mentorship of prof. dr.sc. Matej Cimerman.

Ana is fluent in Croatian, Slovenian and English.