

# Localization of language cortices by functional magnetic resonance

---

Škarić, Andrija Božo

Master's thesis / Diplomski rad

2016

Degree Grantor / Ustanova koja je dodijelila akademski / stručni stupanj: **University of Zagreb, School of Medicine / Sveučilište u Zagrebu, Medicinski fakultet**

Permanent link / Trajna poveznica: <https://um.nsk.hr/um:nbn:hr:105:560852>

Rights / Prava: [In copyright](#)

Download date / Datum preuzimanja: **2022-01-17**



Repository / Repozitorij:

[Dr Med - University of Zagreb School of Medicine Digital Repository](#)



UNIVERSITY OF ZAGREB  
SCHOOL OF MEDICINE

**Andrija Škarić**

**Localization of Language Cortices by  
Functional Magnetic Resonance**

**GRADUATE THESIS**



Zagreb, 2016

This graduation paper was made at the Croatian Institute for Brain Research under supervision of prof.dr.sc Milan Radoš and it was submitted for evaluation in the academic year 2015/2016.

Mentor: prof.dr.sc Milan Radoš

# Table of Contents

	<b>Abbreviations</b> .....	4
	<b>Summary</b> .....	5
<b>1</b>	<b>Introduction</b> .....	6
<b>2</b>	<b>Functional magnetic resonance imaging</b> .....	8
<b>3</b>	<b>Speech Comprehension</b> .....	10
<b>3.1</b>	Prelexical phonemic processing.....	10
<b>3.2</b>	Semantic processing of spoken words.....	12
<b>3.3</b>	Sentence comprehension.....	13
<b>3.4</b>	Semantic constraints in sentence comprehension.....	14
<b>3.5</b>	Syntactic constraints.....	15
<b>3.6</b>	Subvocal articulation during speech comprehension.....	16
<b>3.7</b>	The role of prosody in speech comprehension.....	17
<b>4</b>	<b>Speech Production</b> .....	18
<b>4.1</b>	Conceptual processing in speech production.....	18
<b>4.2</b>	Word retrieval.....	19
<b>4.3</b>	Articulation.....	19
<b>5</b>	<b>Cerebral Lateralization of language</b> .....	21
<b>6</b>	<b>The protocol and basis for preoperative assessment of language lateralization</b> .....	23
<b>6.1</b>	The Wada Test.....	23
<b>6.2</b>	Task fMRI.....	24
<b>6.3</b>	Resting-State fMRI.....	26
<b>7</b>	<b>Clinical application of fMRI in pre-surgical mapping of language in tumor patient</b> .....	28
<b>8</b>	<b>Conclusion</b> .....	29
<b>9</b>	<b>Acknowledgements</b> .....	31
<b>10</b>	<b>References</b> .....	32
<b>11</b>	<b>Biography</b> .....	39

## Abbreviations

<b>BOLD:</b>	<b>Blood-Oxygen-Level-Dependent</b>
<b>aMTg/pMTg:</b>	<b>anterior and posterior middle temporal gyrus</b>
<b>aMTc/pMTc:</b>	<b>anterior and posterior middle temporal cortex</b>
<b>aST/pST:</b>	<b>anterior and posterior superior temporal gyrus</b>
<b>PTPc/TPc:</b>	<b>posterior temporal parietal cortices</b>
<b>PostCP/IP:</b>	<b>post central and inferior parietal gyrus</b>
<b>IPs:</b>	<b>Intraparietal sulcus</b>
<b>ExSc:</b>	<b>Extra striate cortex</b>
<b>ITg:</b>	<b>Inferior temporal gyrus</b>
<b>T. pole:</b>	<b>Temporal pole</b>
<b>HG:</b>	<b>Heschl's gyrus</b>
<b>STg:</b>	<b>superior temporal gyrus</b>
<b>ASTs/pSTs:</b>	<b>anterior and posterior superior temporal sulcus</b>
<b>pPT:</b>	<b>planum temporale, posterior to HG</b>
<b>vSMg/dSMg:</b>	<b>ventral and dorsal supramarginal gyrus</b>
<b>ANG:</b>	<b>angular gyrus</b>
<b>da/m/pCIN:</b>	<b>dorsal anterior cingulate, middle cingulate, and posterior cingulate</b>
<b>pCen:</b>	<b>precentral gyrus</b>
<b>SMA:</b>	<b>supplementary motor cortex</b>
<b>SFg:</b>	<b>superior frontal gyrus</b>
<b>IFs:</b>	<b>inferior frontal sulcus</b>
<b>MFg/ MFc:</b>	<b>middle frontal gyrus and middle frontal cortex</b>
<b>pOr:</b>	<b>pars orbitalis</b>
<b>pTr:</b>	<b>pars triangularis</b>
<b>aINS/INS:</b>	<b>anterior insula and insula</b>
<b>vpOp/dpOp:</b>	<b>ventral and dorsal pars opercularis</b>
<b>aFUS/FUS:</b>	<b>anterior fusiform and fusiform</b>
<b>HC:</b>	<b>hippocampus</b>
<b>ParaHCg:</b>	<b>parahippocampal gyri</b>
<b>d/preMc:</b>	<b>dorsal premotor cortex and premotor cortex</b>
<b>Mc:</b>	<b>motor cortex</b>
<b>PREC:</b>	<b>precuneus</b>
<b>aPUT/ PUT:</b>	<b>anterior putamen and putamen</b>
<b>AMGD:</b>	<b>amygdala</b>
<b>preCg:</b>	<b>precentral gyrus</b>
<b>rolOr:</b>	<b>rolandic operculum</b>
<b>VGT:</b>	<b>verb generation task</b>
<b>VFT:</b>	<b>verb fluency task</b>
<b>SG:</b>	<b>sentence generation</b>
<b>WG:</b>	<b>word generation</b>

## Summary

Title: Localization of Speech Cortices by Functional Magnetic Resonance  
Author: Andrija Skaric

Speech cortices are an extensively researched topic. Here is presented a review of articles that illustrate areas of activation for speech comprehension and speech production through fMRI. Activation is reported for: prelexical speech processing in Heschl's gyrus, temporal poles and pars opercularis; word speech comprehension in bilateral superior temporal lobes and left angular gyrus; sentence speech comprehension the middle temporal gyrus, bilateral anterior temporal poles, left angular gyrus, and the posterior cingulate and preceuneus; for semantic constraint, syntax and prosody in left pars orbitalis, the right inferior frontal, the amygdala and cingulate cortex. Speech production activates the same set of regions as speech comprehension but in addition, activation is reported for: left middle frontal cortex, the left anterior insula, the left putamen, pre-SMA, SMA, and the motor cortex. fMRI is also a non-invasive method for pre-operative assessment of language lateralization and localization.

Keywords: speech, fMRI, language

# 1. Introduction

Language is a system of communication based on the symbolic representation and manipulation of information. Communication typically requires neural systems that process auditory or visual sensory information, hold this information in a short-term store, direct attention to specific features or aspects of the information, perform comparisons and other general operations on the information, select a response based on such operations, and carry out the response. fMRI is a specialized machine which measures the change of blood flows within the brain. Using specialized tests through the fMRI, localization of the speech cortices may be determined with modest accuracy. By splitting up the fundamentals of speech, the activation of each area is determined and its use within the understanding and production of speech. Speech is a complex integrated system of processing centers. Each center operates at a distinct level and on distinct types of information. To analyze speech, a review of studies will present areas of elucidation for subcategories of speech. It is primarily split into two sections, one being speech comprehension and the other being speech production. For speech comprehension it will be subcategorized into, (1) Prelexical phonemic processing, the processes serving recognition of speech sounds, (2) Semantic processing of spoken words, (3) Sentence comprehension, (4) Semantic constraints in sentence comprehension, (5) Syntactic constraints, (6) Subvocal articulation during speech comprehension, (7) The role of prosody in speech comprehension. For speech production, it will be subcategorized into (1) Conceptual processing in speech production, (2) Word retrieval, (3) Articulation. Language is unique in a way where the neural connections are formed differently in each human being. Dominance of a cerebral function such as language can take place on either hemisphere or bilaterally. fMRI can show the localization and

lateralization of language centers of an individual. This method of lateralization of language is being used for preoperative assessment of patients with neural lesions that have to undergo surgery.



## 2. Functional Magnetic Resonance Imaging

Functional magnetic resonance imaging (fMRI) is a functional neuroimaging procedure that measures brain activity by detecting change associated with blood flow.

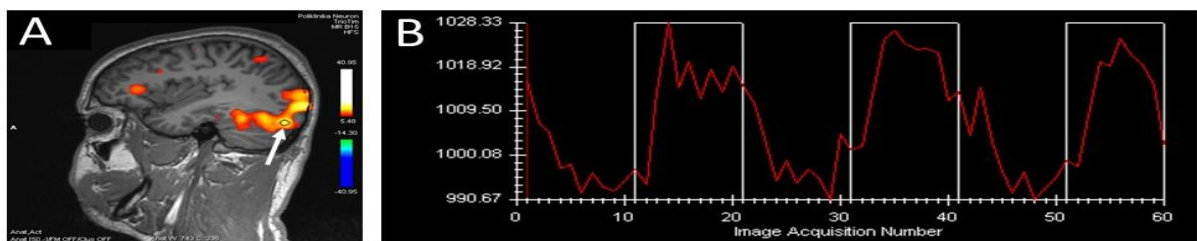
It has been shown that different parts of the brain are involved in different mental processes. When some mental process is performed there is increased neural activity of brain areas specific for that mental process. Increased neural activity lead to increased perfusion which is of crucial importance for fMRI. Namely, during increased perfusion of specific brain regions ratio of oxyhaemoglobin/deoxyhaemoglobin will increase which has direct impact to T2 relaxation time and intensity of MR signal. In other words, increased neural activity could be visualised as increased signal intensity on fMRI. For this reason fMRI signal is commonly referred to as the Blood-Oxygen-Level-Dependent (BOLD) signal (Ogawa and colleagues, 1990). Limitation of this technique is that neural activity is not directly measured (as for example in electroencephalography-EEG) but it is indirectly estimated through haemodynamic response. In spite of this limitation there is excellent correlation of activation zones obtained with fMRI and by other direct functional mapping technique (direct cortical stimulation, magnetoencephalography).

In order to visualize specific mental processes by fMRI two types of stimulation protocols are usually applied: block-design and event-related protocols. In block-design protocol there is regular alternation of relaxation and stimulation periods. During stimulation period participant is exposed to specific stimulus which elicit specific mental process. During relaxation period there is no specific stimulus. Analysis of brain scans obtained during both stimulation and relaxation periods will show in which regions MR

signal intensity is correlated with protocol of stimulation (Figure 1.). These regions are considered to be involved in specific mental process elicited by stimulation.

In event-related period there is occasional appearance of stimulus in irregular time intervals. Analysis is performed by comparison of fMRI scans obtained during irregular stimulation with the rest of the fMRI scans when stimulus was not present. In scientific research both types of fMRI stimulation protocols are accustomed, but in clinical practice block-design protocols are more often used, mainly due to the more simple analysis and calculation of activation zones.

The different tasks gives insight into the functionality of the brain. In the following sections, fMRI will be used to compare different specific tasks that should allow for some reasonable conclusions to be made about the localization and to some extent functionality of speech cortices. Also, clinical usefulness of fMRI in preoperative evaluation of language lateralization will be discussed.



**Figure 1.** (A) Example of increased MR signal intensity in occipital, frontal and parietal lobes elicited by object-naming fMRI protocol used for lateralization of language. (B) Changes of MR signal intensity in occipital lobe during fMRI protocol. Lower signal intensity during relaxation (absence of visual stimulation) alternate with higher signal intensity during stimulation (presentation of different images). (All images from archive of Polyclinic Neuron at Croatian Institute for Brain Research)

## **3. Review of Speech Comprehension**

### **3. 1 Prelexical Phonemic Processing Phoneme perception**

Prelexical phonemic processing refers to the differentiation of the auditory signals that are converted from energy into meaning. How the incoming signals are categorized depends on the characteristics of the acoustic energy. The type of signal depending on integrity and quality are sent to different regions of the brain. Fmri is task dependent, different tasks have different patterns of complexity, which show to activate different areas of the brain, depending on the task.

A review of evidence found that auditory inputs start at Heschl's gyrus (HG) and are processed along an antero-lateral gradient, which progressed in the anterior direction toward the temporal pole (T. pole) (Rauschecker and Scott, 2009). The anteriorly and laterally direction of the auditory information is said to process this information that is increasingly complex and intelligible. This is supported by multiple claims. The first being a study which compares the hearing of familiar vowels versus single formants and tones. The difference between them being that formants and tones where less acoustically complex due to the lack of stop bursts that vowels possess. The study found that vowel stimuli increased activation in lateral left Heschl's gyrus (HG), anteriorly and posteriorly (Leff and colleagues, 2009). Concurrent activation was also observed in the right superior temporal sulcus (STs). Another study also identified activation in lateral and anterior Heschl's gyrus (HG) for hearing vowels versus tones (Britton and colleagues, 2009).

To seek out the extent of these speech selective responses, a mismatch paradigm technique where the same stimulus was repeated for a few trails followed by a new stimulus in the same category was tested. The change in stimulus would bring about activation related to the area that processes the differences between the new stimulus and

the prior stimuli. The results revealed a left-lateralized activation in the anterior superior temporal lobe (aST) only when the vowel changed; the effect was not observed for formant or tone changes (Leff and colleagues, 2009).

Another study also used a mismatch paradigm. In the study they repeated a phonemic stimulus, but changed the acoustics of the sound. Left dorsal pars opercularis (dpOp) activation was found when the new stimulus arose after the repetition of the same predecessors (Myers and colleagues, 2009). The unmet expectation lead to this activation where higher cognitive processes take place. There, top-down expectations are used from prior experience to explain the prediction error for the failure to predict bottom-up inputs.

A final study in this section for speech selective responses confirmed speech selective responses in the posterior and ventral processing directions. The study manipulated acoustic complexity within category by using a sound morphing technique. White noise was gradually changed into either prelexical speech or music. What was observed was a bilateral activation in the anterior-superior sulci irrespective of whether speech or music emerged (Specht and colleagues, 2009). However left lateralized speech selective responses were identified more posteriorly and ventrally. Another report were activation was seen in the posterior and ventral processing directions was a study on the effect of phonological priming (Vaden and colleagues, 2009).

### **3.2 Semantic processing of spoken words**

Semantic processing of spoken words is an extensively computing task. Auditory sounds are differentiated based on certain qualities of the sound. The brain then interprets the sounds to what is known about its meaning. What areas that are activated depends on the level of focus, the amount of associations the sound has, the emotional attachment and

the auditory memory and more. Three main methods were used to probe the areas of activation associated with semantic processing of spoken words. The first was to examine participants that listened to spoken sentences relative to spectrally rotated speech. Bilateral mid-to-anterior superior temporal (aST) activation (Friederici and colleagues, 2009) along with left angular gyrus (ANG) (Oleser and Kotz, 2009) were activated. The next set of studies required more attention from the participants. Here attention was directed to the meaning of single words versus either spectrally rotated speech or pseudowords. When it came to the meaning of single words versus the acoustic properties of spectrally rotated speech, activation was observed in a left-lateralized network including regions in the inferior temporal gyrus (ITg), anterior fusiform (aFUS), hippocampus (HC), angular gyrus (ANG), pars orbitalis (pOr), superior and middle frontal gyri (SFg, MFg) and the right cerebellum (CER) (Sharp and colleagues). The comparison of spoken words to pseudowords (Davis and Gaskell) showed activation distributed in bilateral anterior middle temporal cortices (AMTc), posterior temporal parietal cortices (PTPc), and the precuneus (PREC), with left-lateralized activation in the temporal pole (T. pole), posterior middle temporal cortex (pMTc), anterior fusiform (aFUS), pars orbitalis (pOr), middle frontal cortex (MFC), anterior cingulate (aCIN) and putamen (PUT), and the right precentral gyrus (preCg). For pseudowords relative to words, superior temporal areas (ST) of activation as seen with prelexical processing (Davis and Gaskell, 2009). This suggests that real words increase activation in semantic areas whereas pseudowords increase the demands in prelexical processing areas. In a final study a video game was used as an alternative approach for identifying semantic recognition of auditory stimuli. Here, the video game trained participants to associate novel acoustically complex, artificial nonlinguistic sounds to visually presented aliens. After training, left

posterior superior temporal (pST) activation increased with how well the auditory categories representing each alien had been learnt (Leech and colleagues, 2009).

### **3.3 Sentence Comprehension**

Speech comprehension at the sentence level is measured through the comparison of grammatically correct sentences with plausible versus implausible meanings. The studies also have to account for phonological and lexical familiarity, syntactic processing, and working memory that must be controlled. Activation in four key region has been reported: anterior and posterior parts of the left middle temporal gyrus (aMTg, pMTg), bilateral anterior temporal poles (aT. pole), left angular gyrus (ANG), and the posterior cingulate (pCIN) / preceuneus (PREC).

Firstly shown is the activation of the left anterior middle temporal (aMT) locus, where activation has been reported for semantically plausible more than implausible sentences (Mashal and colleagues, 2009). Also for sentences with meanings that were difficult versus easy to predict (Obleser and Kotz, 2009) and when spoken speech was accompanied by beat gestures (Hubbard and colleagues, 2009) that enhance semantic meaning by providing intonation. Activation was also seen for written sentences compared to unrelated word sequences (Snijers and colleagues, 2009). This shows that sentence level comprehension effects are not limited to auditory words. Just as seen, left posterior middle temporal (pMT) activation has been seen for semantically plausible versus implausible sentences (Mashal and colleagues, 2009). It was also reported to activate when certain aids where accompanied by the auditory sentences. Such as when auditory sentences are accompanied by visual observation of the speaker's body movements that aided to the meaning of the sentence versus hearing the speech only (Holle and colleagues, 2009). Also

when participants viewed the face and emotional expression of a person speaking sentences versus hearing the sentence or viewing the face alone (Robins and colleagues, 2009). Bilateral temporal poles (T. pole) were activated in sentence processing relative to unrelated lists of words (Rogalsky and Hickok, 2009) as well as for written sentences compared to unrelated word sequences (Sijders and colleagues, 2009). Left angular gyrus (ANG) activation is not consistently reported, however it seems to have a role in facilitation of sentence comprehension via top-down activation of semantic concepts. Angular gyrus (ANG) activation was noted during reading relative to object naming (Carreiras and colleagues, 2009) as well as for comparison of heard sentences to unintelligible spectrally rotated speech (Oblesser and Kotz, 2009). Lastly, right precuneus (PREC) and bilateral posterior/middle cingulate cortices (p/m CINc) were noted to be activated for narrative language comprehension (Whitney and colleagues, 2009).

### **3.4 Semantic constraints in sentence comprehension**

This section is focused on the assumption that when the meaning of a sentence becomes difficult, either through it being implausible, ambiguous or unconstrained, certain areas of the brain will become activated in order to figure out the presented problem. Here studies are comparing sentences with implausible versus plausible meanings. What is seen is activation in the left pars opercularis (pOp), the left pars orbitalis (pOr) and the right inferior frontal (IF). Activation for the left pars opercularis (pOp) was reported active for grammatically correct sentences with implausible versus plausible meanings (Ye and Zhou). Also for a list of other similar cases, such as for sentences with ambiguous versus unambiguous meanings (Bilenko and colleagues, 2009) or sentences with novel metaphoric versus literal meanings (Mashal and colleagues, 2009). It was seen also when speech was

presented with incongruent relative to congruent gestures or pantomimes (Willems and colleagues, 2009) and when participants listened to sentences with abstract versus visual or motoric meanings (Desai and colleagues, 2010). Left pars orbitalis (pOr) activation is seen for semantic constraints in sentence comprehension. It was activated for reading irregularly spelled words relative to pseudowords (Nosarti and colleagues, 2009), for semantic relative to syntactic processing in written speech comprehension (Schafer and Constable) and when the written words right or left are incongruent with the direction of an arrow (Aats and colleagues, 2010). Finally, right inferior frontal (IF) activation has been reported where there was a conflict in the context of semantic information as seen above. Therefore, activation was seen when the meanings of a series of sentences conflicted with one another (Peele and colleagues, 2009). Also for when participants listened to and watched a story teller using hand movements that were semantically incongruent relative to congruent with the spoken speech.

### **3.5 Syntactic constraints**

Every language has its own set of grammatical rules; sentence structure, word placement and word associations are all considered when comprehending speech. Syntactic processing is the hierarchical sequencing of words and their meanings with the expected order of words depending on the language spoken. Syntactic processing is tested by comparing sentences with grammatical errors to sentences without grammatical errors and for sentences with more versus less syntactically complex structures. Left ventral and dorsal pars opercularis (vpOP/dpOp), planum temporale (pPT) and the supplementary motor cortex (SMA) were reported to be active.

Left ventral pars opercularis (vpOp) activation has been reported when sentences had syntactic errors (Friederici and colleagues, 2009) and when there were violations in



verb-argument structure (Raettig and colleagues, 2009). Dorsal pars opercularis (dpOp) activation was found to be significantly higher when sequences of nonlinguistic visual symbols could be predicted on the basis of nonadjacent word dependencies compared to adjacent word dependencies (Bahlmann and colleagues, 2009). It was also seen to be active for when participants learnt the nonrigid dependencies of items within a sequence of unfamiliar colored shapes (Tettamanti and colleagues). The third activation was seen with planum temporale ( pPT) and the supplementary motor cortex (SMA). The reported activations were for sentences with grammatical errors (Raettig and colleagues, 2009), for syntactically complex versus less complex sentences (Friederici and colleagues, 2009) and for sentences where the meaning depends on the order of the subject and object versus sentences where the subject and object are not reversible (Richardson and colleagues, 2009).

### **3.6 Subvocal articulation during speech comprehension**

Subvocal articulation has been shown to be activated inconsistently for the motor cortex, planum temporale (pPT) and the supplementary motor cortex (SMA). It has been observed that when speech stimuli are degraded or minimal these areas of the brain may be recruited to aid speech comprehension, when speech perception is challenging (Devlin and Aydelott, 2009). Another study also concluded that motor activation might facilitate speech perception in difficult listening conditions (Scott and colleagues, 2009). They further go on to suggest that motor activation during speech perception allows people to coordinate their speech with others, both in terms of turn taking and also in terms of idiosyncratic characteristics of pronunciation and the use of conceptual and syntactic structures.

### **3.7 The role of prosody in speech comprehension**

Prosody in speech refers to the emotional and nonverbal information that is conveyed in speech through intonation and patterns of stress in speech, facial expressions or demeanor. This information helps with the understanding of the message or situation. The amygdala (AMGD), right superior temporal gyrus and sulcus and dorsal anterior cingulate cortex were shown to be activated. Emotional prosody increased activation in the amygdala (AMGD) (Wiethoff and colleagues, 2009). Right superior temporal gyrus and sulcus (STg/STs) and dorsal anterior cingulate cortex (daCINc) were shown to be activated when the emotional prosody in heard sentences was incongruous with semantic content (Wittfoth and colleagues, 2010). A recent study has also demonstrated a functional subdivision of the superior temporal lobes (ST). They found maximum voice sensitivity in the trunk of the superior temporal lobe (ST) and maximum face sensitivity in the posterior terminal ascending branch (Kreifelts and colleagues, 2009). The last study of this section attempted to dissociate activation for five prosodic categories (anger, sadness, neutral, relief, and joy) through usage of pseudowords spoken with each type of emotion. The results demonstrated that each emotion had a specific spatial signature in the auditory cortex that generalized across speakers (Etofer and colleagues, 2009).

## 4. Review of speech production

### 4.1 Conceptual processing in speech production

Conceptualization is the formulating of objects, emotions, observations and themes, relevant or irrelevant, which leads to an idea that you wish to withdraw and present. All of the regions associated with single word speech comprehension were also shown to be for conceptual processing in speech production. These areas are as follows: inferior frontal gyrus (IFg), middle temporal gyrus, fusiform (FUS), parahippocampal gyri (paraHCg), and the posterior cingulate gyrus (pCIN) (Binder and colleagues, 2009). Along with the ventral and dorsal medial prefrontal cortex (dmPreFc), posterior inferior parietal lobe (pIP).

Their contribution to speech production depends on the task and the type of semantic information that needs to be retrieved. The lexico-semantic processing during speech production is distributed across brain regions participating in sensorimotor processing. The retrieval of words belonging to visual categories activated extra striate cortex (ExSc); retrieval of words belonging to motor categories activated the intraparietal sulcus (IPs) and posterior middle temporal cortex (pMTc); and retrieval of words belonging to somato-sensory categories activated postcentral and inferior parietal (postCP/IP) regions (Hwang and colleagues, 2009). The type of words that are being retrieved also has an effect on what region will be activated. Bilateral hippocampal (HC) activation was noted when pictures to be named were blocked in terms of their semantic category and bilateral anterior medial temporal activations for when the objects to be named were blocked according to similar visual features (Hocking and colleagues, 2009).

## **4.2 Word retrieval**

Word retrieval is the searching for the word that will fit accurately within the context of what is to be expressed. In two studies word generation tasks compared to reading highlighted activation in the left inferior and middle frontal gyri (IFg/MFg), spanning both the pars opercularis (pOp), the pars triangularis (pTr), and the inferior frontal sulcus (IFs) (Whitney and colleagues, 2009; Jeon and colleagues, 2009). Another study also showed left middle frontal (MF) region activation for generating words that were either semantically or phonologically related to a word (Heim and colleagues, 2009). A second region that is consistently activated in word retrieval tasks is the left dorsal pars opercularis (dpOp). This was also seen in the speech comprehension section. Left dorsal pars opercularis (dpOp) activation was reported for word generation more than reading (Jeon and colleagues, 2009) and for imitating or observing a speaker producing nonsense syllables (Fridriksson and colleagues, 2009). A final region that is consistently activated in word retrieval tasks is the left ventral pars opercularis (vpOp). This area was also seen in the speech comprehension section for predicting semantic or articulatory sequences. This region was perorated for articulating versus listening to the word “ted” (Zheng and colleagues, 2009) and for the repetition and subvocal rehearsal of pseudowords with low versus high sublexical frequency (Papoutsi and colleagues, 2009).

## **4.3 Articulation**

Articulation is the act of transmuting what was conceptualized into auditory form. This requires certain areas of the brain responsible for different tasks. Firstly noted was increases bilaterally in motor and premotor cortex (preMc, Mc), the cerebellum (CER), the supplementary motor area (SMA), the superior temporal gyri (STg), the temporo-parietal cortices (TPc), and the anterior insula (aINS), with left-lateralized activation in the putamen

(PUT) (Brown and colleagues, 2009). These regions were reported activated in the production of non-speech sounds from orofacial and vocal tract gestures that have no phonemic content as well as for speech. Therefore they are not solely dedicated to speech (Chang and colleagues, 2009). Two areas that are found to activate for speech more than vocal tract gestures were the anterior cingulate cortex (aCINc) and bilateral caudate (CAUD). Their activation has been associated with suppression of inappropriate responses (Aarts and colleagues, 2009; Ali and colleagues, 2009; Kircher and colleagues, 2009). The reasoning being that there is greater demands on response selection for accurate choices in word selection than needed for non-speech sounds. The anterior cingulate cortex is also subdivided into many sub regions that may each have their own function during speech production. Anterior insula (aINS) is speculated to be involved in generalize orofacial functions, including lip movement, tongue movement, and vocalization (Brown and colleagues). It was reported to be activated for syllable singing, oral reading as well as for rehearsal of verbal information (Koelsch and colleagues, 2009). With respect to the function of the premotor cortex (preMc), there are three functionally distinct areas. The rolandic operculum (rolOp) is responsible for larynx motor and tongue movement controls (Brown and colleagues, 2009). The dorsal premotor (dpreM) region plays a role in action selection and planning within the context of arbitrary stimulus-response mapping tasks and the most dorsal part of the premotor cortex, is activated by finger tapping as well as articulating (Meister and colleagues, 2009). Also interesting to note is that there is more activation throughout the speech production system for the repetition of pseudowords with four syllables versus two syllables (Papotsi and colleagues, 2009).

## 5. Cerebral lateralization of language

Brain lateralization refers to the unevenness of cognitive or neural functions across the hemispheres. Even though, both hemispheres are almost identical by appearance, the different composition of the neural networks in each hemisphere allows for specialized functions; where one hemisphere can be dominant in a certain neural function. The difference amongst people also leads to variability of neural network arrangement, leading to a unique lateralization seen on the individual level. One functionality of the brain that is dominantly lateralized is language. Language is seen most commonly dominant in the human population on the left hemisphere. There is also correspondence of which hemisphere will be more dominant according to handedness. So a right-handed person will usually present with left hemisphere dominance for language. In the past, lateralization of language was examined invasively via the Wada test or electrical stimulation testing. Since the advent of the fMRI, language lateralization can be determined in a non-invasive way. Language lateralization can have either left-sided, right-sided or bilateral dominance (Figure 2). A study of 100 healthy volunteers, consisting of 50 left-handed subjects and 50 right-handed subjects, were studied by fMRI to determine the cerebral lateralization of language. Each group consisted of 25 women and 25 men, all without any neurological, psychiatric or relevant medical disease. The results showed 94% of right-handed subjects showed fMRI changes lateralized to the left hemisphere and 4% showed bilateral activation patterns. In left-handed subjects, 76% showed fMRI activation in the left hemisphere, 14% bilateral activation and 10% in the right hemisphere (Pujol and colleagues, 1999). The importance of knowing the lateralization of language is in its relevance in the pre-surgical assessment of the brain. Knowing the eloquent areas of the brain is shown to reduce post-surgical complications.

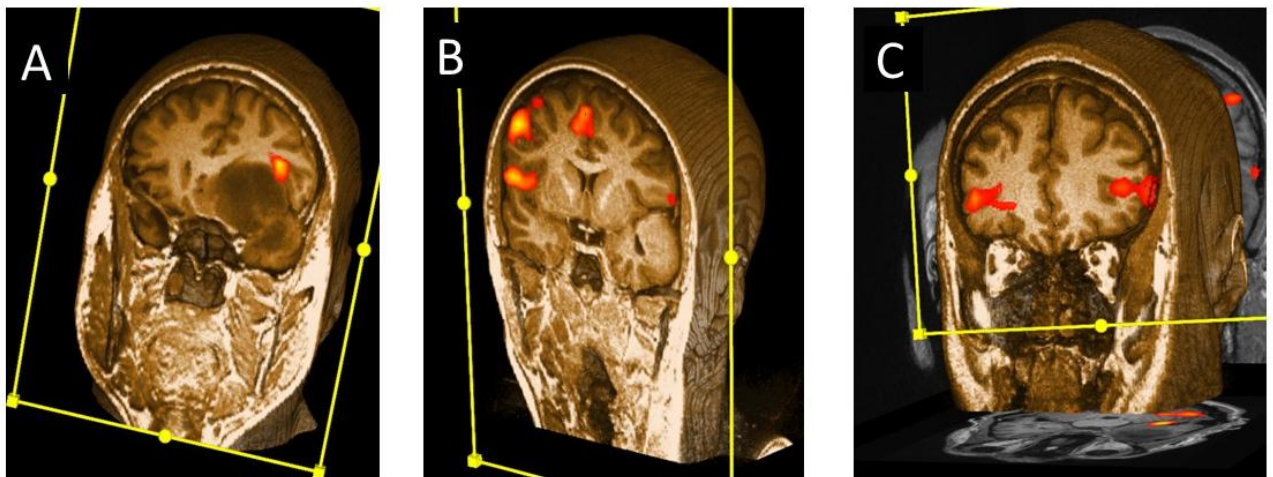


Figure 2. fMRI lateralization of language. (A) Example of left hemisphere language lateralization in patient with expansive process of left frontal and temporal lobe. (B) Rare variant of right hemisphere language lateralization. (C) Bilateral localization of language cortices. (All images from archive of Polyclinic Neuron at Croatian Institute for Brain Research)

## **6. The protocol and basis for preoperative assessment of language lateralization**

### **6. 1 The Wada test**

The Wada test is an invasive procedure that localizes the lateralization of language cortices in the dominant hemisphere. This was considered the gold standard for preoperative assessment of lateralisation of language and memory function before the advent of fMRI (Rutten and colleagues, 2006). The test consists of an amobarbital injection in the internal carotid artery. This causes functional disruption of the ipsilateral cerebral hemisphere for 3 to 5 minutes. While the functionality is disturbed, the patient is asked to perform language tasks. If the patient can do this without problems, then probably language is located on the contralateral side. If the patient becomes aphasic, it is then presumed that language is considered to be lateralised to the injected hemisphere. In one study it was found that out of 504 patients, 81% of patients were correctly classified as having left or right language dominance or mixed language representation (Bauer and colleagues, 2014). Although the sensitivity of the test is high, there are several drawbacks for this test that are not seen with fMRI. Firstly, due to the invasiveness of the procedure, angiography within a vascular compromised population comes with a complication rate of 1.3%-11%, of which about 0.6% are permanent (Wilinsky and colleagues, 2003). Clinical symptoms that can appear during and shortly after testing amobarbital may include somnolence, agitation and confusion, which may lead to obscure test results due to a distressing patient (Meador and colleagues, 1999). Also, amobarbital has a short duration of effect of 3 to 5 minutes. Lastly, it can give unreliable results that may be due to anatomical variations in the brain vascularisation (Hietala and colleagues, 1990).



fMRI when compared to Wada test, is non-invasive, rather rapidly conducted; and due to its non-invasiveness the possibility to conduct a retest is less distressing for the patient. It also costs a third of the Wada test (Medina and colleagues, 2004). However, Wada test may still be considered the choice for patients with a pacemaker or ferromagnetic material, in patients with severe obesity and macrocephaly, in patients that deal with claustrophobia, attention problems or are mentally challenged (Swanson and colleagues, 2007).

When compared to effectiveness of localizing language centers, fMRI correctly classifies 94% of patients shown to have typical language lateralisation by the Wada test. Therefore, it is not viewed that for patients with a clear left lateralisation result on fMRI, Wada test would be unnecessary for further language testing. Nevertheless, in cases where there is no clear lateralisation or atypical language lateralisation seen on fMRI, further testing would be warranted. When there is a discrepancy between fMRI and the Wada test, fMRI shows atypical language representation in more than 75% of the cases (Bauer and colleagues, 2014).

## **6.2 Task fMRI**

The rationale for any preoperative assessment in a neurosurgical resection is to avoid postoperative deficits, in which language functions are of critical value. The ideal mechanism would be one of which that can assess accurately the localization and functionality of language while providing the patient with as much comfort and with as little complications as possible. This is why fMRI is so alluring. fMRI is a non-invasive technique, which provides relevant information by mapping cognitive functions in eloquent areas (Adcock and colleagues, 2003). The earlier of the two techniques of how fMRI is conducted

is through the task method. Here the patient is tested through generally two paradigms; the verb generation task (VGT) and the verb fluency task (VFT). Another two techniques are the sentence generation (SG) task and word generation (WG) task. It is usually considered to use different paradigms simultaneously in order to obtain a better mapping of language functions (Ramsey and colleagues, 2001).

The verb generation task (VGT) consists in the generation of a verb that is semantically related to a presented noun (Bensen and colleagues, 1999; Fitzgerald and colleagues, 2007). An example would be the noun, spoon and the associate verb, to eat. Activation for this typically produces left-sided activation in the inferior and middle frontal gyri (IFg, MFg) (Bensen and colleagues, 1999). In the verb fluency task (VFT), subjects are required to silently generate different words starting with a particular letter (Hertz-Pannier and colleagues, 1997). An example of this could be the letter, F and the following words would be flower, fox, and fire. Activations for this task include the inferior, middle and superior frontal gyri (IFg, MFg, SFg), as well as the supplementary motor area (SMA) and the thalamus (Lehericy and colleagues, 2006).

The sentence generation (SG) task is the generation of a sentence through visualization of comic-like pictures, each of which coded for a standardized simple sentence. An example would be a picture of a clown and the corresponding sentence is, the clown is funny. The word generation (WG) task is the generation of words by hearing generic terms of categories. An example of this would be hearing the word, car and the patient would list names of cars, such as Jaguar, Toyota, and Ford. Both these tasks cause activation in inferior frontal gyrus, (IFg) (Broca area) the superior temporal (ST), supramarginal (SM), and angular gyri (ANG) (Wernicke area) (Stippich and colleagues 2006).

For all types of tasks, the similar protocols exist. Before entering the scanner, participants practice their task overtly. The participants when inside the scanner are instructed to respond silently. The stimuli are presented aurally via earphones or visually via specialized glasses. The task consists of a certain amount of blocks of alternating control/rest and activation conditions. There is an initial fixation period before the task is ready. During the activation part, the participants have a certain amount of time to answer as well as possibly the task at hand. During the control part, the participants are asked to either focus on a visual stimulus or repeat a word over and over depending. Depending on the task these may vary considerable (Stippich and colleagues, 2006; Sanjuán and colleague, 2010).

### **6.3 Resting-State fMRI**

Resting-State fMRI refers to a patient undergoing Functional magnetic resonance images while participants are not performing any task. Resting-State fMRI shows low frequency ( $<0.1\text{Hz}$ ) BOLD signal changes in several spatially distinct brain networks (Damoiseaux and colleagues, 2006; Fox and Raichle, 2007; Fox and Greicius, 2010). It is able to identify the language network amongst other brain networks. (Mitchell and colleagues, 2013; Tie and colleagues, 2014; Zhu and colleagues, 2014). There are major advantages of using Resting-State fMRI over task-fMRI. First there is a three times higher signal-to noise ratio than task-related signals. (Fox and Greicius, 2010). Another key advantage is that since the technique does not require a task and most patients that require this procedure are associated with a brain lesion, it is a viable option where task fMRI may not be (Lee and colleagues, 1999; Price and colleagues, 2006). Lastly, a resting state examination is more time-efficient than a task-based one. This is due to an imaging protocol that is typically

faster (Lang and colleagues, 2014). In terms of effectiveness, the resting state paradigm was able to provide similar results to those done by task-execution. Resting-state networks were shown to be as sensitive as task-based maps, however had an even higher specificity (Branco and colleagues, 2016). Therefore resting-state protocols are an effective technique to map language regions in patients with brain lesions.

## **7. Clinical application of fMRI in pre-surgical mapping of language in tumor patients**

Neurosurgical interventions in patients with brain tumors located in or close to language areas can cause intraoperative neuronal damage. This can lead to language deficits and thus to a further reduction in quality of life. Therefore, in patients with frontal and temporal lobe tumors, neurosurgery should be carefully considered (Stippich and colleagues, 2006). With functional MR imaging, it is possible to determine the language-dominant hemisphere (Binder and colleagues, 1996) and the spatial relationships between brain tumors and language areas before surgery (Rutten and colleagues, 1999). A study where pre-surgical functional magnetic resonance imaging was performed in 81 patients; 70 of which had left sided tumors and the other 11 with right sided tumors, shows the successfulness of fMRI in localization of language cortices. The protocol that the patient underwent where the sentence generation (SG) and word generation (WG). Of the 70 patients with left sided tumors, 60 were right handed, seven were left handed, and three were ambidextrous. Of the 11 patients with right sided tumors, seven were left-handed and four were right handed. The results showed that for the sentence generation (SG) and word generation (WG) paradigms, the patients successfully completed by all (100%) and 70 (86%) patients respectively. Success rates in localizing and lateralizing language were 96% for the Broca and Wernicke areas with the sentence generation (SG) paradigm, 81% for the Broca area and 80% for the Wernicke area with the word generation (WG) paradigm, and 98% for both areas when the sentence generation (SG) and word generation (WG) paradigms were used in combination (Stippich and colleagues, 2006).

## 8. Conclusion

In regard to speech comprehension, the auditory information is received by the Heschl's gyrus. There it is processed in two directions. Primary it progresses in the anterior direction towards the temporal pole and up to the pars opercularis. It also progresses into the posterior ventral direction to reach the superior temporal sulci. Once word comprehension comes into play, the signal expands throughout the brain, primarily to the bilateral superior temporal lobes along with left angular gyrus. Other areas that are involved extend to the inferior temporal gyrus, temporal pole, posterior middle temporal cortex, posterior temporal parietal cortices, anterior fusiform, hippocampus, angular gyrus, pars orbitalis, superior and middle frontal gyri, and the right cerebellum. When the meanings of the words compile to form a sentence, four areas have been shown to be activated for sentence comprehension. The anterior and posterior parts of the left middle temporal gyrus, bilateral anterior temporal poles, left angular gyrus, and the posterior cingulate/preceuneus. When the meaning becomes more difficult to interpret or understand the left pars orbitalis and the right inferior frontal regions become activated. When the speech itself is difficult to hear, then reiteration of the speech occurs in a form of subvocal articulation. Here the motor cortex, planum temporale and the supplementary cortex are activated. Lastly, the amygdala, right superior temporal gyrus and sulcus and dorsal anterior cingulate cortex are shown active for the emotional intonation and inclination of sight and speech in communication.

In regards to speech production, formulation and conceptualization of what is desired to be said, takes place within the same spread regions of the brain as occurs with word speech comprehension along with the ventral and dorsal medial prefrontal cortex, posterior inferior parietal lobe. Once the idea is conceptualized, word retrieval takes place

within the left inferior and middle frontal gyri, spanning both the pars opercularis, the pars triangularis, and the inferior sulcus. Now, finally the utterance of speech begins with articulatory centers being active. Bilaterally in motor and premotor cortex, the cerebellum, the supplementary motor area, the superior temporal gyri, the temporal parietal cortices, and the anterior insula, with left lateralized activation in the putamen.

In regards to language lateralization and its clinical relevance as an alternative and prominent option in pre-surgical assessment. Task fMRI and resting-state fMRI are shown to be good non-invasive alternatives that yield effective results in lateralization of language centers. This allows the surgeon to plan accordingly how to perform the surgery to lower post-surgical complications of language deficits.

## **9. Acknowledgments**

I would like to thank all the researches who published their articles for free. I would also like to thank the participants who underwent all these studies. My mentor, prof.dr.sc Milan Radoš was of great assistance in completing this paper. This paper could not have been written without the help of many individuals whom largely provide their assistance without even knowing.



## 10. References

1. Ogawa, S., Lee, T.M., Kay, A.R., Tank, D.W. 1990. Brain magnetic resonance imaging with contrast dependent on blood oxygenation. *Proc Natl Acad Sci.* 87(24):9868-72.
2. Rauschecker, J.P. & S.K. Scott. 2009. Maps and streams in the auditory cortex: nonhuman primates illuminate human speech processing. *Nat. Neurosci.* 12: 718–724.
3. Leff, A. P., P. Iverson, T. M. Schofield, et al. 2009. Vowel specific mismatch responses in the anterior superior temporal gyrus: an fMRI study. *Cortex* 45: 517–526.
4. Britton, B., S.E. Blumstein, E.B. Myers & C. Grindrod. 2009. The role of spectral and durational properties on hemispheric asymmetries in vowel perception. *Neuropsychologia* 47: 1096–1106.
5. Myers, E.B., S.E. Blumstein, E. Walsh & J. Eliassen. 2009. Inferior frontal regions underlie the perception of phonetic category invariance. *Psychol. Sci.* 20: 895–903
6. Specht, K., B. Osnes & K. Hugdahl. 2009. Detection of differential speech-specific processes in the temporal lobe using fMRI and a dynamic “sound morphing” technique. *Hum. Brain Mapp.* 30: 3436–3444.
7. Vaden, K. I. Jr., L. T. Muftuler & G. Hickok. 2009. Phonological repetition-suppression in bilateral superior temporal sulci. *Neuroimage* 49: 1018–1023.
8. Obleser, J. & S.A. Kotz. 2009. Expectancy constraints in degraded speech modulate the language comprehension network. *Cereb. Cortex.* doi: 10.1093/cercor/bhp128. 10.
9. Friederici, A.D., S.A. Kotz, S.K. Scott & J. Obleser. 2009. Disentangling syntax and intelligibility in auditory language comprehension. *Hum. Brain Mapp.* doi: 10.1002/hbm.20878.
10. Sharp, D. J., J. E. Warren, M. Awad, et al. 2009. The neural response to changing semantic and perceptual complexity during language processing. *Hum. Brain Mapp.* doi: 10.1002/hbm.20871.
11. Davis, M.H. & M.G. Gaskell. 2009. A complementary systems account of word learning: neural and behavioural evidence. *Phil. Trans. R. Soc. B.* 364: 3773–3800.
12. Leech, R., L.L. Holt, J.T. Devlin & F. Dick. 2009. Expertise with artificial non speech sounds recruits speech sensitive cortical regions. *J. Neurosci.* 29: 5234–5239.
13. Mashal, N., M. Faust, T. Hendler & M. Jung-Beeman. 2009. An fMRI study of processing novel metaphoric sentences. *Laterality* 14: 30–54.

14. Snijders, T.M., T. Vosse, G. Kempen, et al. 2009. Retrieval and unification of syntactic structure in sentence comprehension: an fMRI study using word-category ambiguity. *Cereb. Cortex* 19: 1493–1503.
15. Holle, H., J. Obleser, S. A. Rueschemeyer & T. C. Gunter. 2009. Integration of iconic gestures and speech in left superior temporal areas boosts speech comprehension under adverse listening conditions. *Neuroimage* 49: 875–884.
16. Rogalsky, C. & G. Hickok. 2009. Selective attention to semantic and syntactic features modulates sentence processing networks in anterior temporal cortex. *Cereb. Cortex* 19: 786–796.
17. Carreiras, M., M.L. Seghier, S. Baquero, et al. 2009. An anatomical signature for literacy. *Nature* 461: 983– 986.
18. Whitney, C., W. Huber, J. Klann, et al. 2009. Neural correlates of narrative shifts during auditory story comprehension. *Neuroimage* 47: 360–366.
19. Ye, Z. & X. Zhou. 2009. Conflict control during sentence comprehension: fMRI evidence. *Neuroimage* 48: 280– 290.
20. Bilenko, N. Y., C. M. Grindrod, E. B. Myers & S .E. Blumstein. 2009. Neural correlates of semantic competition during processing of ambiguous words. *J. Cogn. Neurosci.* 21: 960–975.
21. Willems, R.M., A. Ozyurek & P. Hagoort. 2009. Differential roles for left inferior frontal and superior temporal cortex in multimodal integration of action and language. *Neuroimage* 47: 1992–2004.
22. Desai, R. H., J. R. Binder, L. L. Conant & M. S. Seidenberg. 2010. Activation of sensory-motor areas in sentence comprehension. *Cereb. Cortex.* 20: 468–478.
23. Nosarti, C., A. Mechelli, D. W. Green & C. J. Price. 2010. The impact of second language learning on semantic and nonsemantic first language reading. *Cereb. Cortex* 20: 315–327.
24. Aarts, E., A. Roelofs & M. van Turennout. 2009. Attentional control of task and response in lateral and medial frontal cortex: brain activity and reaction time distributions. *Neuropsychologia* 47: 2089–2099
25. Peelle, J.E., V. Troiani & M. Grossman. 2009. Interaction between process and content in semantic memory: an fMRI study of noun feature knowledge. *Neuropsychologia* 47: 995–1003.

26. Raettig, T., S. Frisch, A.D. Friederici & S.A. Kotz. 2009. Neural correlates of morphosyntactic and verb argument structure processing: an fMRI study. *Cortex*. doi: 10.1016/j.cortex.2009.06.003.
27. Bahlmann, J., R.I. Schubotz, J.L. Mueller, et al. 2009. Neural circuits of hierarchical visuo-spatial sequence processing. *Brain Res.* 1298: 161–170.
28. Tettamanti, M., I. Rotondi, D. Perani, et al. 2009. Syntax without language: neurobiological evidence for cross-domain syntactic computations. *Cortex* 45: 825–838.
29. Friederici, A.D., M. Makuuchi & J. Bahlmann. 2009. The role of the posterior superior temporal cortex in sentence comprehension. *Neuroreport* 20: 563–568.
30. Devlin, J. T. & J. Aydelott. 2009. Speech perception: motoric contributions versus the motor theory. *Curr Biol.* 19: R198–R200
31. Scott, S.K., C. McGettigan & F. Eisner. 2009. A little more conversation, a little less action: candidate roles for motor cortex in speech perception. *Nature Rev. Neurosci.* 10: 295–302.
32. Wiethoff, S., D. Wildgruber, W. Grodd & T. Ethofer. 2009. Response and habituation of the amygdala during processing of emotional prosody. *Neuroreport* 20: 1356–1360.
33. Wittfoth, M., C. Schroder, D. M. Schardt, et al. 2010. On emotional conflict: interference resolution of happy and angry prosody reveals valence-specific effects. *Cereb. Cortex.* 20: 383–392
34. Kreifelts, B., T. Ethofer, T. Shiozawa, et al. 2009. Cerebral representation of non-verbal emotional perception: fMRI reveals audiovisual integration area between voice- and face-sensitive regions in the superior temporal sulcus. *Neuropsychologia.* 47: 3059–3066.
35. Ethofer, T., D. VanDeVille, K. Scherer & P. Vuilleumier. 2009. Decoding of emotional information in voice sensitive cortices. *Curr. Biol.* 19: 1028–1033
36. Binder, J.R., R.H. Desai, W.W. Graves & L.L. Conant. 2009. Where is the semantic system? A critical review and meta-analysis of 120 functional neuroimaging studies. *Cereb. Cortex.* 19: 2767–2796.
37. Hwang, K., E. D. Palmer, S. Basho, et al. 2009. Category specific activations during word generation reflect experiential sensorimotor modalities. *Neuroimage* 48: 717–725.

38. Hocking, J., K.L. McMahon & G.I. de Zubicaray. 2009. Semantic context and visual feature effects in object naming: an fMRI study using arterial spin labeling. *J. Cogn. Neurosci.* 21: 1571–1583.
39. Whitney, C., S. Weis, T. Krings, et al. 2009. Task dependent modulations of prefrontal and hippocampal activity during intrinsic word production. *J. Cogn. Neurosci.* 21: 697–712.
40. Jeon, H.A., K.M. Lee, Y.B. Kim & Z.H. Cho. 2009. Neural substrates of semantic relationships: common and distinct left-frontal activities for generation of synonyms vs. antonyms. *Neuroimage* 48: 449–457
41. Fridriksson, J., D. Moser, J. Ryalls, et al. 2009. Modulation of frontal lobe speech areas associated with the production and perception of speech movements. *J. Speech Lang. Hear Res.* 52: 812–819.
42. Zheng, Z.Z., K.G. Munhall & I.S. Johnsrude. 2009. Functional overlap between regions involved in speech perception and in monitoring one's own voice during speech production. *J. Cogn. Neurosci.* doi: 10.1162/jocn.2009.21324.
43. Brown, S., A.R. Laird, P. Q. Pfordresher, et al. 2009. The somatotopy of speech: phonation and articulation in the human motor cortex. *Brain Cogn.* 70: 31–41.
44. Chang, S.E., M.K. Kenney, T.M. Loucks, et al. 2009. Common neural substrates support speech and nonspeech vocal tract gestures. *Neuroimage* 47: 314–325
45. Ali, N., D.W. Green, F. Kherif, et al. 2009. Role of the left caudate in suppressing irrelevant words. *J. Cogn. Neurosci.* doi:10.1162/jocn.2009.21352.
46. Kircher, T., B. Straube, D. Leube, et al. 2009 Neural interaction of speech and gesture: differential activations of metaphoric co-verbal gestures. *Neuropsychologia* 47: 169–179.
47. Meister, I.G., D. Buelte, M. Staedtgen, et al. 2009. The dorsal premotor cortex orchestrates concurrent speech and fingertapping movements. *Eur. J. Neurosci.* 29: 2074–2082.
48. Jesús Pujol, Joan Deus, Josep M. Losilla and Antoni Capdevila. 1999. Cerebral lateralization of language in normal left-handed people studied by functional MRI. *Neurology* 52: 1038-1043
49. Rutten GJM, Ramsey NF. 2010. The role of functional magnetic resonance imaging in brain surgery. *Neurosurg Focus*; 28:E4.

50. Bauer PR, Reitsma JB, Houweling BM, et al. 2014. Can fMRI safely replace the Wada test for preoperative assessment of language lateralisation? A meta-analysis and systematic review *J Neurol Neurosurg Psychiatry*;85: 581–588.
51. Wilinsky RA, Taylor SM, TerBrugge K, et al. 2003. Neurologic complications of cerebral angiography: a prospective analysis of 2899 procedures and review of the literature. *Radiology*; 227: 522–528.
52. Meador KJ, Loring DW. 1999. The Wada test. Controversies, concerns and insights. Editorial. *Neurology*; 52: 1535.
53. Hietala SO, Silfvenius AJ, Olivecrona M, et al. *Brain*. 1990. Perfusion with intracarotid injection of 99mTc-HM-PAO in partial epilepsy during amobarbital testing. *Nucl Med*; 16: 683–687.
54. Medina LS, Aguirre E, Bernal B, et al. 2004. Functional MR Imaging versus Wada test for evaluation of language lateralization: cost analysis. *Radiology*; 230: 49–54.
55. Swanson SJ, Sabsevitz DS, Hammeke TA, et al. 2007. Functional magnetic resonance imaging of language in epilepsy. *Neuropsychol Rev*; 17: 491–504.
56. Adcock JE, Wise RG, Oxbury JM et al. 2003 Quantitative fMRI assessment of the differences in lateralization of language-related brain activation in patients with temporal lobe epilepsy. *Neuroimage* 18(2): 423–438.
57. Ramsey NF, Sommer IE, Rutten GJ et al. 2001. Combined analysis of language tasks in fMRI improves assessment of hemispheric dominance for language functions in individual subjects. *Neuroimage* 13(4): 719–733.
58. Benson RR, FitzGerald DB, LeSueur LL et al. 1999. Language dominance determined by whole brain functional MRI in patients with brain lesions. *Neurology* 52(4): 798–809.
59. FitzGerald DB, Cosgrove GR, Ronner S et al. 1997. Location of language in the cortex: a comparison between functional MR imaging and electrocortical stimulation. *Am J Neuroradiol* 18 (8): 1529–1539.
60. Hertz-Pannier L, Gaillard WD, Mott SH et al. 1997 Noninvasive assessment of language dominance in children and adolescents with functional MRI: a preliminary study. *Neurology* 48(4): 1003–1012.
61. Lehericy S, Cohen L, Bazin B et al. 2000. Functional MR evaluation of temporal and frontal language dominance compared with the Wada test. *Neurology* 54:1625–1633.

62. Stippich C, Rapps N et al. 2006. Localizing and Lateralizing Language in Patients with Brain Tumors: Feasibility of Routine Preoperative Functional MR Imaging in 81 Consecutive Patients. *Radiology*: 243(3): 828-836.
63. Sanjuán J, C. Martínez et al. 2010. Comparison of two fMRI tasks for the evaluation of the expressive language function. *Neuroradiology* 52:407–415.
64. Damoiseaux, J. S., Rombouts, S. A., Barkhof, F., Scheltens, P., Stam, C. J., Smith, S. M., et al. 2006. Consistent resting-state networks across healthy subjects. *Proc. Natl. Acad. Sci. U.S.A.* 103, 13848–13853.
65. Fox, M. D., and Raichle, M. E. 2007. Spontaneous fluctuations in brain activity observed with functional magnetic resonance imaging. *Nat. Rev. Neurosci.* 8, 700–711.
66. Fox, M. D., and Greicius, M. 2010. Clinical applications of resting state functional connectivity. *Front. Syst. Neurosci.* 4:19. doi: 10.3389/fnsys.2010.00019
67. Mitchell, T. J., Hacker, C. D., Breshears, J. D., Szrama, N. P., Sharma, M., Bundy, D. T., et al. 2013. A novel data-driven approach to preoperative mapping of functional cortex using resting-state functional magnetic resonance imaging. *Neurosurgery*73: 969–983.
68. Tie, Y., Rigolo, L., Norton, I. H., Huang, R.Y., Wu, W., Orringer, O., et al. 2014. Defining language networks from resting-state fMRI for surgical planning – a feasibility study. *Hum. Brain Mapp.* 35, 1018–1030.
69. Zhu, L., Fan, Y., Zou, Q., Wang, J., Gao, J. H., and Niu, Z. 2014. Temporal reliability and lateralization of the resting-state language network. *PLoS ONE* 9: e85880. doi:10.1371/journal.pone.0085880
70. Lee, C. C., Ward, H.A., Sharbrough, F. W., Meyer, F. B., Marsh, W. R., Raffel, C., et al. 1999. Assessment of functional MR imaging in neurosurgical planning. *Am. J. Neuroradiol.* 20: 1511–1519.
71. Price, C. J., Crinion, J., and Friston, K. J. 2006. Design and analysis off MRI studies with neurologically impaired patients. *J. Magn. Reson. Imaging* 23: 816–826
72. Lang, S., Duncan, N., and Northoff, G. 2014. Resting-state functional magnetic resonance imaging: review of neurosurgical applications. *Neurosurgery* 74: 453–464.
73. Branco, P. Seixas, D. Deprez, S. et al. 2016. Resting-State functional Magnetic Resonance Imaging for Language Preoperative Planning. *Front. Hum. Neurosci.* 10:11 doi: 10.3389/fnhum.2016.00011

74. Binder JR, Swanson SJ, Hammeke TA, et al. 1996. Determination of language dominance using functional MRI: a comparison with the Wada test. *Neurology* 46:978–984.
75. Rutten GJ, van Rijen PC, van Veelen CW, Ramsey NF. 1999. Language area localization with three-dimensional functional magnetic resonance imaging matches intrasulcal electrostimulation in Broca's area. *Ann Neurol*; 46: 405–408.

## **11. Biography**

I, Andrija Skaric was born on the 18<sup>th</sup> of January 1990, in Toronto Canada. I currently lived in Zagreb, Croatia, attending the University of Zagreb, School of Medicine. As a child I completed my elementary education at Divine Mercy Catholic School in Vaughan, Toronto. I attended high school both in Canada at Saint Elizabeth's Catholic high school and in Croatia at the 15<sup>th</sup> Gimnazija. In the academic year of 2009/2010, I enrolled at the University of Zagreb, School of Medicine.