

Anatomsko - radiološka studija pneumatizacije kriste gali

Antunović, Romano

Master's thesis / Diplomski rad

2017

Degree Grantor / Ustanova koja je dodijelila akademski / stručni stupanj: **University of Zagreb, School of Medicine / Sveučilište u Zagrebu, Medicinski fakultet**

Permanent link / Trajna poveznica: <https://um.nsk.hr/um:nbn:hr:105:009207>

Rights / Prava: [In copyright](#)/[Zaštićeno autorskim pravom.](#)

Download date / Datum preuzimanja: **2024-07-10**



Repository / Repozitorij:

[Dr Med - University of Zagreb School of Medicine Digital Repository](#)



An anatomical study of pneumatized crista galli

Ranko Mladina¹ · Romano Antunović² · Cemal Cingi³ · Nuray Bayar Muluk⁴ · Neven Skitarelčić^{5,6} · Mislav Malić⁷

Received: 13 October 2016 / Revised: 13 November 2016 / Accepted: 30 January 2017
© Springer-Verlag Berlin Heidelberg 2017

Abstract The literature data on the incidence of pneumatization of the crista galli based on patients' computed tomography (CT) scans ranges from 3 to 37.5%. This study investigated for the first time the incidence of crista galli pneumatization based on CT scans of human skulls. The study examined 102 randomly selected human skulls (≥ 20 years of age; 76 males, 26 females). Skulls were scanned in a fixed position using cone beam computed tomography (CBCT) with a field of view of 145×130 mm and an isotropic voxel size of 0.25 mm. The scans were recorded in Digital Images and Communications in Medicine format. The CBCT images were analyzed using OnDemand3DTM software. A 2-mm contiguous slice thickness was used in the axial and coronal planes. The width, length, and height (cranial-caudal dimension) of the pneumatized space within the crista galli were measured. The crista galli was found to be pneumatized in even 68 (66.6%) of the 102 skulls. Two types of

pneumatized crista galli (PCG) were identified: PCG alone (surrounded by bony walls) and PCG + spongiosis (surrounded by spongy bone). Of the 68 pneumatized skulls, 31 were PCG alone (45.58%) and 37 were PCG + spongiosis (54.42%). The pneumatized regions had a width of 0.9–6.6 mm, length of 2.8–12.9 mm, and height of 3.6–17.1 mm. No statistically significant differences have been found regarding the sex and age. Regarding the proportions of pneumatization, the three types of crista galli have been determined resulting in new, practical classification: type S (small), type M (moderate), and type L (large). The crista galli is not always a compact bone; in some cases, it is filled with spongy bone or pneumatized. In respect of proportions of pneumatization, there are three types of pneumatized crista galli: small, moderate, and large. Pneumatized crista galli can play an important role in clinical work, both as an inflamed sinus or other pathologies (sinusitis cristae galli, mucocoele) or as a morphologic barrier in neurosurgical approaches to some tumors of the anterior skull base.

✉ Nuray Bayar Muluk
nuray.bayar@yahoo.com; nurayb@hotmail.com

Keywords Human skull · Crista galli · Pneumatization · Sinus cristae galli · Proportions · Classification

- ¹ The Board of Surgical Sciences, Croatian Academy of Medical Sciences, Subićeva 19, 10000 Zagreb, Croatia
- ² Institute of Anatomy, School of Medicine, University of Zagreb, Šalata 11, 10000 Zagreb, Croatia
- ³ ENT Head and Neck Surgery Department, Faculty of Medicine, Eskisehir Osmangazi University, Eskisehir, Turkey
- ⁴ ENT Head and Neck Surgery Department, Faculty of Medicine, Kirikkale University, Kirikkale, Turkey
- ⁵ Department of Health Studies, University of Zadar, Zadar, Croatia
- ⁶ Faculty of Medicine, University of Rijeka, Rijeka, Croatia
- ⁷ ENT Head and Neck Surgery Department, Clinical Hospital Center Zagreb, Zagreb, Croatia

Introduction

The crista galli is an anatomical structure located in the midline above the cribriform plate. It has a thin and slightly curved posterior border, to which the falx cerebri are attached, and a much thicker and shorter anterior border, attached to the frontal bone by two small alae; it forms the foramen cecum [1]. Embryologically, it is derived from the ethmoid bone. It is formed together with the central structures of the anterior skull base and the perpendicular plate of the ethmoid bone during the second fetal month, by the mesethmoidal cartilage.

In some individuals, the crista galli is a compact bone, but it can also be pneumatized. Several theories have been proposed to explain the pneumatization of the crista galli, and two are widely accepted. The first advocates pneumatization from the ethmoid sinus and other advocates crista galli pneumatization from the frontal sinus [2]. Communication between the pneumatized crista galli (PCG) and adjacent paranasal structures usually occurs through an opening similar to other sinus ostia, opening into the frontal sinus in most cases. In case of ostial blockage, an inflammatory/infectious response similar to rhinosinusitis can occur. Socher et al. [3] reported three cases in which a chronic headache was attributed to inflammatory processes within the PCG. They succeeded in removing the inflamed mucosa from within the PCG endoscopically, with excellent outcomes in all three patients.

The reported incidence of PCG ranges from 3 to 37.5% [2–7]. However, all such reports have been based on computed tomography (CT) studies of ENT and neurosurgical patients. To the best of our knowledge, our study is the first to analyze the incidence of pneumatization of the crista galli by means of CT, but in human skulls. The width, length, and height of the PCG were measured. The distribution of all crista galli in our material was systematized according to both Hajjiannou [8] and Keros classification [9]. Particular analysis has been performed in the same sense for the pneumatized crista galli.

The question of crista galli pneumatization has been mostly neglected until the last decade. Nowadays, the interest for this phenomenon grows rapidly both because possible clinical implications in rhinosinusology (chronic sinusitis or mucopyocoeleae cristae galli, for instance) and because of the neurosurgical approaches to some tumors located in the anterior skull base region like giant meningiomas, etc.

Materials and methods

This anatomical study was conducted at the University of Zagreb, School of Medicine, Zagreb, Croatia, from 2015 to 2016 and adhered to the tenets of the Declaration of Helsinki. As the skull collection was used, there was no need to obtain ethical approval.

Subjects

A total of 102 skulls (Caucasians of European descent) were randomly selected from the skull collection at the “Drago Perović” Institute of Anatomy, University of Zagreb, School of Medicine.

Methods

The skulls were scanned in a fixed position using cone beam computed tomography (CBCT) (SCANORA® 3D; SOREDEX, Finland) with a field of view of 145 × 130 mm and an isotropic voxel size of 0.25 mm; these were recorded in Digital Images and Communications in Medicine format. The CBCT images were analyzed using OnDemand3DTM software (Cybermed, Korea). Contiguous, slices 2 mm thick (Hewaidi and Omami, 2008) in the axial and coronal plane images were studied.

The maximum length, width, and height of pneumatization of the space within the crista galli were determined. The height was measured in the coronal plane (Figs. 1 and 2), while length and width were measured in the axial plane (Fig. 3).

PCG slides were reclassified as PCG alone or PCG + spongiosis. The measurements were compared in males and females separately. The general position of the crista galli in our material as well as the position of all pneumatized crista galli have been analyzed according to Keros classification [8] (regarding the height of the lateral lamella of the cribriform plate (types A, B, and C) and Hajjiannou’s classification [9] (crista galli position regarding the level of the cribriform plate (types 1, 2, and 3). Besides, we have classified pneumatized crista galli in respect of their proportions in three types: type S (small), type M (moderate), and type L (large).

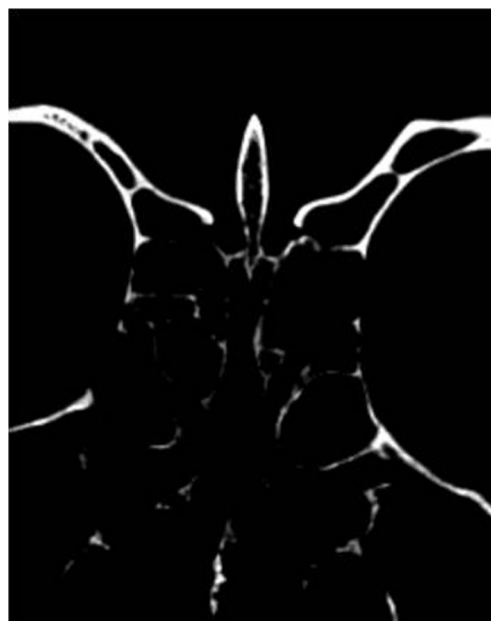

Fig. 1 Coronal CT scan of the human skull showing a large cavity within the crista galli. Maximall width and hight could be measured in this projection. This type of pneumatization corresponds well to Keros type B, Hajjiannou’s type 1 and proportion type M



Fig. 2 A huge pneumatized crista galli. Keros type C; Hajjiannou type 2; proportion type L

Statistical analysis

Statistical analyses were performed using SPSS ver. 16.0 with the independent samples *t* test, Mann–Whitney *U* test, and Spearman’s correlation. A *p* value <0.05 was considered to indicate statistical significance.

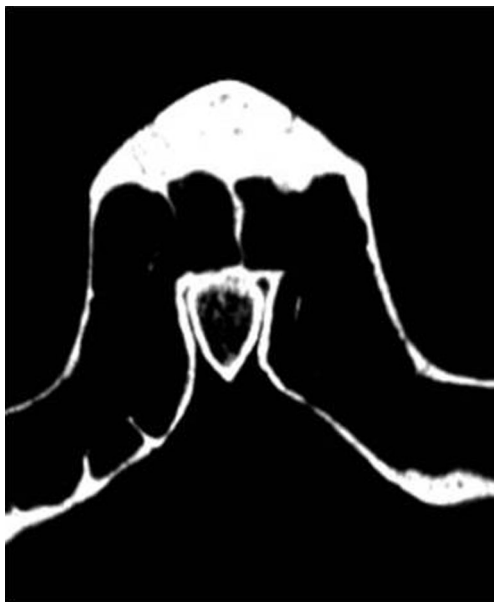

Fig. 3 Axial CT scan of the human skull showing a large cavity within the crista galli. Maximal width and length could be easily and precisely measured in this projection

Table 1 The values of the width of the pneumatized crista galli

Width of the pneumatized crista galli (mm)	Number	Percent
0.9–2.9	34	50.0
3.0–5.0	31	45.58
5.1–7.1	3	4.42

Results

Sex and general incidence

Of the 102 skulls, 76 (74.5%) were male and 26 (25.5%) were female. Sixty-eight skulls (66.6%) had PCG: 51 (75%) were male and 17 (25%) were female. PCG alone was detected in 31 skulls and PCG + spongiosis was found in 37 skulls. The dimensions of the pneumatized spaces within the crista galli are summarized below.

Width

The width ranged from 0.9 to 6.6 mm and was 0.9–2.9 mm in 34 cases (50.0%), 3.0–5.0 mm in 31 skulls (45.58%), and 5.1–7.1 mm in 3 (4.41%) (Table 1). Overall, the mean CG width was 3.0 ± 1.2 mm (Table 2). The mean width was 2.9 ± 1.3 mm in the PCG group and 3.1 ± 1.1 mm in the PCG + spongiosis group ($p = 0.460$) (Table 3). There were no significant differences between males and females in PCG and PCG + spongiosis groups and also in either group ($p > 0.05$) (Table 4).

Length

The mean lengths of the 68 skulls ranged from 2.8 to 12.9 mm (Table 3) and was 2.8–4.8 mm in 15 skulls (22.5%), 4.9–6.9 mm in 18 skulls (26.47%), 7.0–9.0 mm in 24 skulls (35.29%), 9.1–11.1 mm in 5 skulls (7.35%), and 11.2–13.2 in 6 skulls (8.82%) (Table 5). Overall, the CG length was 7.1 ± 2.5 mm (Table 2); it was 7.5 ± 2.8 mm in the PCG group and 6.7 ± 2.1 mm in the PCG + spongiosis group ($p = 0.170$) (Table 3). There were no significant differences between

Table 2 Measurement values in all PCG and PCG + spongiosis group ($n = 68$)

	Mean	Standard dev.	Minimum	Maximum
Width (mm)	3.0	1.2	0.9	6.6
Length (mm)	7.1	2.5	2.8	12.9
Height (mm)	10.1	3.0	3.6	17.1

Table 3 Measurement values in each of the PCG and PCG + spongiosis group

	PCG group (<i>n</i> = 31)				PCG + spongiosis group (<i>n</i> = 37)				<i>p</i> *
	Mean	Standard dev.	Minimum	Maximum	Mean	Standard dev.	Minimum	Maximum	
Width (mm)	2.9	1.3	1.0	6.6	3.1	1.1	0.9	5.7	0.460
Length (mm)	7.5	2.8	2.8	12.9	6.7	2.1	3.0	11.4	0.170
Height (mm)	10.2	3.1	4.3	17.1	9.9	2.8	3.6	13.9	0.752

**p* value shows the results of Independent samples *t* test

males and females in PCG and PCG + spongiosis groups and also in either group ($p > 0.05$) (Table 4).

Height

The height ranged from 3.6 to 17.1 mm (Table 2): 3.6–5.6 mm in 6 skulls (13.23%), 5.7–7.7 mm in 9 skulls (13.23%), 7.8–9.8 mm in 19 skulls (27.94%), 9.9–11.9 mm in 16 skulls (23.52%), 12–14 mm in 15 skulls (22.05%), 14.1–16.1 mm in 1 skull (1.47%), and 16.2 to 18.2 mm in 2 skulls (2.94%). The most frequent height range was 7.8–14.0 mm (Table 6). Overall, the mean CG height was 10.1 ± 3.0 mm (Table 2); it was 10.2 ± 3.1 mm in the PCG group and 9.9 ± 2.8 mm in the PCG + spongiosis group ($p = 0.752$) (Table 3). There were no significant differences between males and females in the PCG and PCG + spongiosis groups ($p > 0.05$) (Table 4). In the PCG group, the height was significantly higher in females (median 14.2 mm) than in males (median 9.5) ($p = 0.013$) (Table 4).

Spearman's correlation results

The width, length, and height of the crista galli were all positively correlated with each other in both the PCG and PCG + spongiosis groups ($p < 0.05$). Sex showed no significant

correlation with the width, length, or height of the crista galli ($p > 0.05$).

The obvious connections between the pneumatized crista galli and adjacent sinuses have been seen extremely rarely. It concerned to the communication with the frontal sinus only and was seen in two cases.

Keros classification

The distribution of pneumatized crista galli regarding the Keros classification [8] was as follows: type A has been seen in 29 cases (42.64%) (Fig. 4), type B has been found in 38 cases (55.88%) (Fig. 2), and type C in only one case (1.47%) (Fig. 2).

Hajjioannou's classification

The distribution of the position of pneumatized crista galli regarding their position as related to the level of the cribriform plate according to Hajjioannou's classification [9] was as follows: type 1 has been seen in 31 cases (45.58%) (Figs. 1 and 2) and type 2 in 37 cases (54.42%) (Fig. 4). Hajjioannou's type 3 has not been registered in our material.

Table 4 Measurement values of males and females in each of the PCG and PCG + spongiosis group

		PCG group (<i>n</i> = 31) (27 males, 4 females)				PCG + spongiosis group (<i>n</i> = 37) (27 males, 10 females)				<i>p</i> *
		Median	Minimum	Maximum	Mean rank	Median	Minimum	Maximum	Mean rank	
Width (mm)	Male	2.8	1.0	6.6	15.41	3.5	0.90	5.7	18.20	0.286
	Female	3.1	2.1	5.9	20.00	3.0	2.10	4.7	21.15	
	<i>p</i> *		0.345				0.460			
Length (mm)	Male	7.4	2.8	12.2	15.83	6.5	3.60	10.6	17.72	0.191
	Female	7.5	3.7	12.9	17.13	8.2	3.00	11.4	22.45	
	<i>p</i> *		0.791				0.238			
Height (mm)	Male	9.5	4.3	17.10	14.44	9.5	3.60	13.9	18.61	0.598
	Female	14.2	11.8	16.30	26.50	11.6	4.70	13.7	20.05	
	<i>p</i> *		0.013				0.719			

**p* value shows the results of Mann–Whitney *U* test

Table 5 The values of the length of the pneumatized crista galli

Length of the pneumatized crista galli (mm)	Number	Percent
2.8–4.8	15	22.50
4.9–6.9	18	26.47
7.0–9.0	24	35.29
9.1–11.1	5	7.35
11.2–13.2	6	8.82

Classification regarding the crista galli proportions

We classified here the degree of the crista galli pneumatization according to the proportions, i.e., the width, length, and height. We divided all pneumatized crista galli in three types: type S (small), M (moderate), and L (large). The dimensions expressed in decimal numbers for the practical reasons have been simplified and transferred to the nearest whole numbers. The final result is the following classification:

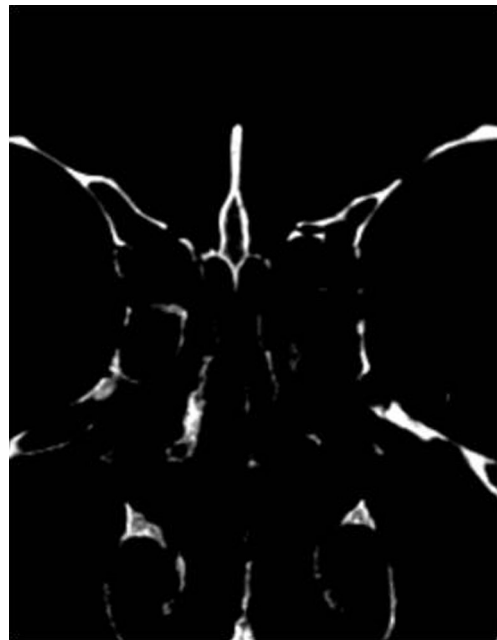- Type S: the width from 1 to 3 mm, the length from 3 to 7 mm and the height from 3 to 8 mm.
- Type M: the width from 3 to 5 mm, the length from 7 to 11 mm and the height from 8 to 12 mm (Figs. 1 and 4).
- Type L: the width from 5 to 7 mm, the length from 11 to 13 mm and the height from 12 to 18 mm (Fig. 2).

Discussion

To the best of our knowledge, this is the first CT-scanning study of the pneumatization of crista galli using human skulls. We found an obvious discrepancy between the incidence of pneumatization of the crista galli based on CT analysis of human skulls and CT analysis of ENT or neurosurgical patients. The overall incidence of PCG in a previous study we performed on ENT patients was 37.5% [6], much higher than in previous studies. For instance, Basic et al. [1] found an incidence of only 2.4% in five patients. Som et al. [2] reported

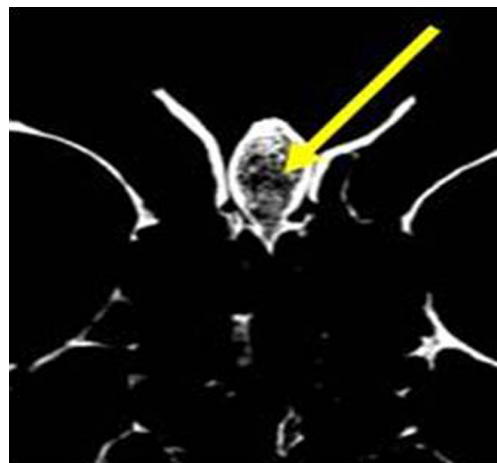
Table 6 The values of the height of the pneumatized crista galli

Height of the pneumatized crista galli (mm)	Number	Percent
3.6–5.6	6	8.82
5.7–7.7	9	13.23
7.8–9.8	19	27.94
9.9–11.9	16	23.52
12.0–14.0	15	22.05
14.1–16.1	1	1.47
16.2–18.2	2	2.94

**Fig. 4** Keros type A has been found in our material in even 42.64% of cases. Here, it goes also for Hajjioannou's type 1 and proportion type S

a rate of 13%. Other authors have obtained similar results. Kim et al. [4] found an incidence of 12.2% in 818 patients, but their group included children. After analyzing the results of two age groups separately, the incidence was only 2.7% in subjects aged 7 to 18 years, and 13.2% in the remainder. Other authors have found higher incidences, with Al Qudah [5] reporting 28% pneumatization. Contrary to these results obtained by analysis of the CT scans of the patients, our rate based on human skulls showed to be very high, even 66.6%.

The question arises here on what could be the reason for such a great difference? Of the PCGs in the human skulls examined, 37 (54.4%) contained spongy bone (Figs. 5 and 6). Perhaps CT is not able to differentiate between small

**Fig. 5** Coronal CT scan showing spongy bone within crista galli. Yellow arrow indicates a small space of true pneumatization in the middle of the spongy bone area

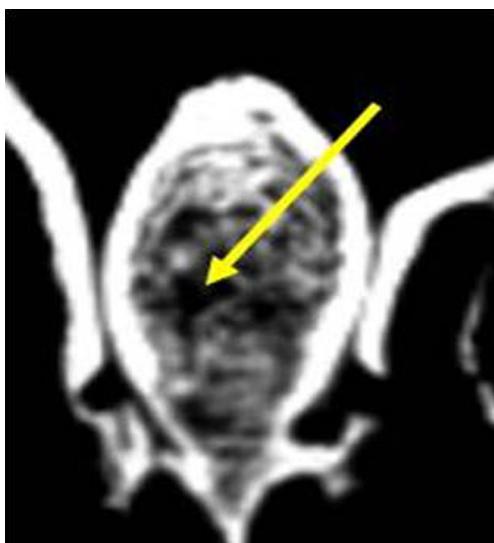


Fig. 6 Magnified detail of the crista galli from the Fig. 3. The spongy bone surrounds a small aerized space (yellow arrow)

pneumatized spaces and the surrounding spongy bone, which hides the real cavity within the crista galli. The spicules of the spongy bone form a lattice and the interstices are not empty spaces, but rather are filled with bone marrow, nerves, and blood vessels. Consequently, the evaluable elements, such as the maximum height, width, and length of the cavity within the bony borders of the crista galli, when observed using CT, depend on the subjective evaluation of the observer, unless special techniques have not been used, such as analyses of the tomographic coefficient of tissue density based on the Hounsfield unit (HU) scale [7]. In comparison, it was easier to judge the degree of pneumatization in the human skulls because spongy bone is clearly visible and identifiable because the spaces between spicules are not filled with tissues as they are in vivo. In skulls, the tissues are replaced with air during the process of skull preparation.

To know more about the real incidence of the crista galli pneumatization could be essential for ENT surgeons because of possible, usually unrecognized inflammatory process within the pneumatized crista galli (Fig. 1) dealing with the endoscopic endonasal approaches to the anterior skull base and the back parts of the frontal sinus. Shidanshid et al. published about the successful endoscopic resection of a mucocele of the crista galli [10]. Even very rare clinical entities like mucopycoelae of the paranasal sinuses can occur in pneumatized crista galli, like it was the case in 18-month-old boy who has been in otorhinolaryngological treatment three times before coming to our hospital owing to recurrent inflammatory abscess-like lumps in the region of the nasal root. There were also signs of cutaneous fistula in the middle line of the upper third of the external nose. The CT scanning clearly showed a mass in the crista galli with a tunnel-like progression to the face. In this very case, an external approach has been employed (Figs. 7, 8, and 9).

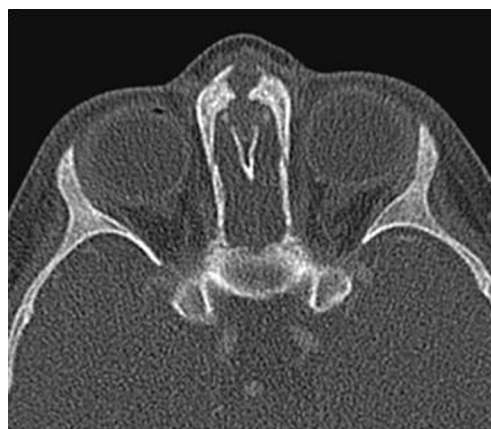

Fig. 7 Tunnel-like progression of the pathological process within the crista galli towards the root of the nose

The main parameters regarding the pneumatized crista galli are (a) the height of the lateral lamella of the cribriform plate (Keros classification [8]) which in fact defines the depth of the olfactory groove and (b) the position of the crista galli regarding the level of the cribriform plate (Hajjioannou's classification [9]), but in our opinion, the proportions of the particular pneumatized CG should be also taken into consideration, particularly in respect of the neurosurgical approaches to some tumors located at the very anterior skull base. That is why we offered here our own classification. Keros found that the depth of the olfactory groove, i.e., the height of the lateral lamella of the cribriform plate varies from 1 to 16 mm, and has divided this variations in three classes: type A (1–3 mm, found in 26.3% of the population), type B (4–7 mm, found in 73.3% of the population), and type C (8–16 mm, very rare morphological entity found in 0.5% of the population only). As to the Hajjioannou's classification, he also found three variations which are as follows: type 1 in which the base of the crista

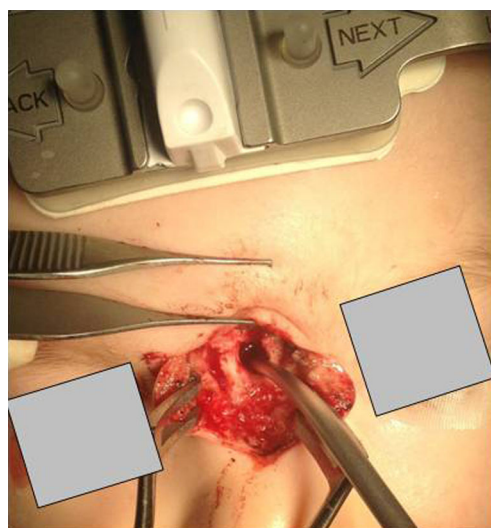


Fig. 8 An external approach following the fistular canal. The tip of the neuronavigational system probe is inserted in the deepest point of the operating field. Its position could be seen on the Fig. 9

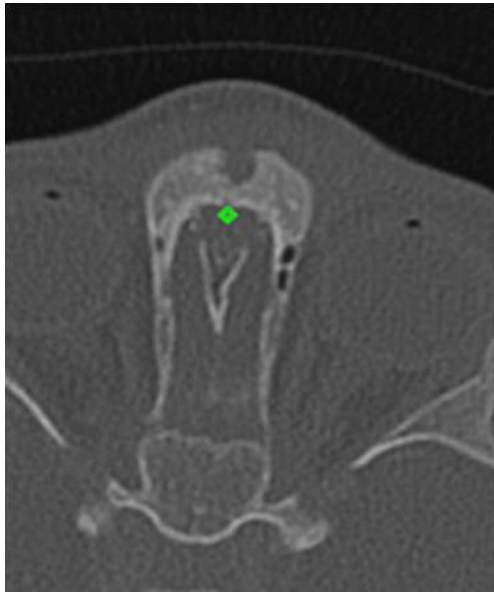


Fig. 9 The *green point* shows the position of the tip of the neuronavigational system probe which in this very moment confirmed that we were at the right position for the removal of the pathological process from the pneumatized crista galli

galli does not extend below the level of the cribriform plate (28.3%), type 2 in which crista galli extend less than 50% of its height below the cribriform plate (63.6%), and type 3 in which crista galli extends more than 50% of its height below the cribriform plate (8.1%). The comparison of our results to original Keros classification showed obvious similarity: it also showed the dominance of the type B (55.88%), type A was a little less frequent as well (42.64%), whereas type C showed to be very rare (1.47%) as it is in original Keros results. Regarding Hajjioannou's classification, despite the fact that the number of the investigated subjects was a little lower than 100 in both Hajjioannou's and our research (our sample 68, Hajjioannou's 99), our results are a little different: Hajjioannou has found type 1 in 28.3%, type 2 in 66.3%, and type 3 in 8.1% of his cases. We found Hajjioannou's type 1 in 31 cases (45.58%) and type 2 in 37 cases (54.42%). However, Hajjioannou's type 3 has not been registered in our material.

To know more about the real incidence of the crista galli pneumatization could be essential for the neurosurgeons when approaching the tumors of the olfactory groove region and most anterior parts of the skull base, or, more specifically in the context of meningioma surgery. Olfactory groove meningiomas originate from the dura of the cribriform plate and are rare lesions, accounting for 5–10% of intracranial meningiomas. As shown by Pallini R et al. [11] in one of the largest case series on olfactory groove meningiomas, the tumor at diagnosis was larger than 6 cm in more than half of the cases. These usually large and highly vascularized meningiomas are supplied by branches of the anterior and

posterior ethmoidal arteries, which enter the skull through small cribroethmoidal foramina at both sides of the GC, which are not amenable to preoperative endovascular occlusion. For these reasons, surgical devascularization of such tumors prior to operative removal is vitally important which is illustrated by Wei CP et al. [12].

In the case of olfactory groove meningiomas, most neurosurgeons prefer a unilateral, pterional/subfrontal approach for smaller lesions and a bifrontal/subfrontal approach with or without orbital rim osteotomies for larger lesions. Depending on the size and morphology of the GC and cribriform plate, the anterior ethmoidal arteries might be immediately adjacent to the GC. If tumor vessel ligation in this case is performed by means of a high speed drill, the parts of the GC may be drilled off to improve vessel exposure and hemostasis. Furthermore, it might be beneficial to expose and ligate the contralateral ethmoidal vessels in case of a unilateral subfrontal approach, which in some cases also requires reduction of the GC using a high speed drill. It seems that our findings suggest that meticulous sealing after drilling of the GC in the context of operative devascularization of anterior cranial base meningiomas is necessary in all patients because of the high incidence of pneumatized GC variants.

All above mentioned practical reasons suggest the extreme importance of knowing more about crista galli as an anatomical entity, not only from the aspect of endonasal, endoscopic ENT surgeons dealing with the anterior skull base pathology but also and particularly for the neurosurgeons operating in this region, be it by means of the unilateral, pterional/subfrontal approach for smaller lesions or by bifrontal/subfrontal approach with or without orbital rim osteotomies for larger lesions.

We do believe that our classification of three types of pneumatized crista galli, based on its proportions, together with Hajjioannou's and Keros classification will give an excellent preoperative input for planning the surgery itself.

Conclusions

The crista galli is not always compact bone; in some cases, it is filled with spongy bone or is pneumatized. The reported incidence of pneumatization ranges from 2.4 to 37.5%. However, in the present study on human skulls, the incidence of pneumatization was much higher, at 66.6%. This big difference might be attributable to the fact that the spaces within the spongy bone of crista galli are filled with tissue, mimicking compact bone with no crista galli pneumatization. PCGs seem to belong to the paranasal sinus system and can be called sinus cristae galli. The most frequent type of pneumatized crista galli according to Hajjioannou's classification in our material was type 2 (54.42%). Type 3 has not been seen at all. The most frequent Keros type was type B (55.88%).

There are three types of pneumatized crista galli regarding its proportions: type S (small), type M (moderate), and type L (large). Neurosurgeons and rhinologists dealing with both external as well as endonasal endoscopic approaches to the anterior skull base should consider this in their everyday practice. They should teach also the radiologist to pay attention to these entities and to regularly describe them in their radiological findings.

Acknowledgments The authors wish to cordially thank to Dr. Lovorka Grgurević and Dr. Nikola Štoković from the Laboratory for Mineralized Tissues, Center for Translational and Clinical Research, School of Medicine, University of Zagreb, Šalata 11, 10000 Zagreb, Croatia, as well as Dr. Tomislav Lauc from the Department of Anthropology, Faculty of Social Sciences and Humanities, University of Zagreb, Lucićeva 3, 10000 Zagreb, Croatia, for their great help in writing this paper.

With exception of data collection, preparation of this paper including design and planning was supported by Continuous Education and Scientific Research Association. There is no financial support. There is only scientific support.

Author contributions Ranko Mladina: planning, designing, literature survey, writing

Romano Antunović: planning, designing, data collection, literature survey

Cemal Cingi: planning, designing, literature survey

Nuray Bayar Muluk: planning, designing, literature survey, statistical analysis, writing

Neven Skitarelić: planning, designing, literature survey

Mislav Malić: planning, designing, literature survey

Compliance with ethical standards There are no financial disclosures of the authors.

Ethical approval As the skull collection was used, there was no need to take Ethical approval.

Informed consent As the skull collection was used, there was no need to take informed consent.

Conflict of interest The authors declare that they have no conflict of interest.

References

1. Basic N, Basic V, Jukic T et al (1999) Computed tomographic imaging to determine the frequency of anatomical variations in pneumatization of the ethmoid bone. *Eur Arch Otorhinolaryngol* 265:269–271
2. Som PM, Park EE, Naidich TP, Lawson V (2009) Crista galli pneumatization is an extension of the adjacent frontal sinuses. *Am J Neuroradiol* 30:31–33
3. Socher JA, Santos PG, Correa VC, de Barros e Silva LC (2013) Endoscopic surgery in the treatment of crista galli pneumatization evolving with localized frontal headaches. *Int Arch Otorhinolaryngol* 17(3):246–250
4. Kim JJ, Cho JH, Choi JW, Lim HW, Somng YJ, Choi SJ, Yeo NK (2012) Morphologic analysis of crista galli using computed tomography. *J Rhinol* 19(2):91–95
5. Al Quadah MS (2010) Anatomical variations in sino-nasal region: a computer tomography (CT) study. *J Med J* 44(3):290–297
6. Poje G, Mladina R, Skitarelic N, Marjanovic KM (2014) Some radiological and clinical aspects of the sinus cristae galli. *Romanian Journal of Rhinology* 13(4):31–36
7. Manea C, Mladina R (2016) Crista galli sinusitis—a radiological impression or a real clinical entity. *Romanian Journal of Rhinology* 23(6):167–117
8. Keros P (1962) On the practical value of differences in the level of the lamina cribrosa of the ethmoid. *Z Laryngol Rhinol Otol* 41:809–813
9. Hajjioannou J, Owens D, Whittet HB (2010) Evaluation of anatomical variation of the crista galli using computed tomography. *Clin Anat* 23(4):370–373. doi:10.1002/ca.20957
10. Shidanshid M, Taghi AS, Kuchai R, Saleh HA (2015) Endoscopic resection of a mucocele of the crista galli. *Ear Nose Throat J* 94(9):E23–E25
11. Pallini R, Fernandez E, Lauretti L et al (2015) Olfactory groove meningioma: report of 99 cases surgically treated at the Catholic University School of Medicine, Rome. *World neurosurgery* 83:219–231–e211–213
12. Wei CP, Wang AD, Tsai MD (2002) Resection of giant olfactory groove meningioma with extradural devascularization. *Skull Base* 12(1):27–31