

Diagnostic procedures in anisocoria

Golod, Steven

Master's thesis / Diplomski rad

2018

Degree Grantor / Ustanova koja je dodijelila akademski / stručni stupanj: **University of Zagreb, School of Medicine / Sveučilište u Zagrebu, Medicinski fakultet**

Permanent link / Trajna poveznica: <https://um.nsk.hr/um:nbn:hr:105:755935>

Rights / Prava: [In copyright](#)/[Zaštićeno autorskim pravom.](#)

Download date / Datum preuzimanja: **2024-10-10**



Repository / Repozitorij:

[Dr Med - University of Zagreb School of Medicine Digital Repository](#)



**UNIVERSITY OF ZAGREB
SCHOOL OF MEDICINE**

Steven Golod

Diagnostic Procedures in Anisocoria

GRADUATE THESIS



Zagreb, 2018.

This graduate thesis was made at the Department of Ophatalmology, Clinical Hospital Center Rebro, Zagreb, mentored by Professor Tomislav Vidović, MD, PhD. and was submitted for evaluation during the academic year 2017/2018.

ABBREVIATIONS:

ANS: Autonomic Nervous System

APD Afferent Pupillary Defect

AR: Argyll Robertson

CN: Cranial Nerve

EWN: Edinger-Westphal nucleus

TABLE OF CONTENTS:

Abstract	1
Sažetak	2
Introduction	3
Relevant Anatomy	4
Examination of the Pupil	7
Anisocoria	8
Afferent Pupillary Defect	9
Horner's Syndrome	11
Third Cranial Nerve Palsy	14
Tonic Pupil	16
Mechanical Causes	18
Pharmacological Causes	18
Other Causes	19
Pupillography	20
Discussion.....	21
Acknowledgments	23
References	24
Biography	28

ABSTRACT

Diagnostic Procedures in Anisocoria

Steven Golod

This paper is a narrative review of the literature regarding diagnostic procedures in anisocoria. Due to the many technological and pharmacological advances made in modern day medicine, an accurate diagnosis is sine qua non. Patients displaying acute pupil irregularities are an increased risk for life threatening conditions. Workup of acute anisocoria frequently involves costly and/or invasive procedures, which has resulted in much debate over practical guidelines on how to handle abnormal pupillary findings. Nonetheless, there is a body of evidence suggesting that a thorough eye examination results in better overall patient outcomes. Currently, there is a consensus that a clinically guided history and examination is the first step in establishing a diagnosis. Laboratory studies, imaging studies and other diagnostic procedures depend entirely upon the underlying cause of anisocoria. In the hospital setting, physicians are required to rule out life-threatening causes. Conversely, in an outpatient setting an underlying etiology must be determined. Anisocoria may be the cause of variable patient morbidity thus reinforcing the value of a prompt diagnosis, effective communication and proper follow up in such patients.

Keywords: Anisocoria, Pupil, Horner Syndrome, Tonic Pupil, CN III Palsy, Afferent Pupillary Defect

SAŽETAK

Dijagnostički Postupci u Anizokoriji

Steven Golod

Ovaj rad je narativni pregled literature o dijagnostičkim postupcima u anizokoriji. Zbog napredka do kojeg je došlo u tehnologiji i farmakologiji u modernoj medicini, točna dijagnoza je sine qua non. Pacijenti koji pokazuju akutne neispravnosti pupile su u povećanom riziku od po život opasnih stanja. Praktične smjernice o kako pregledati pupilu i kako postupiti u abnormalnim nalazima pupila su tema rasprave u literaturi zbog toga što dijagnostika akutne anizokorije često uključuje skupe i/ili invazivne procedure. Međutim, postoji dokaz koji jamči da detaljno ispitivanje rezultira boljim ishodima. Trenutno postoji konsenzus da je klinički vođena povijest bolesti i pregled, prvi korak u uspostavljanju dijagnoze. Laboratorijska istraživanja, studije snimanja i ostale dijagnostičke procedure ovise u potpunosti o temeljnom uzroku anizokorije. U bolničkom okruženju, liječnici su potrebni isključiti po život opasna stanja. Obrnuto, u ambulantnom okruženju temeljni uzrok mora biti utvrđen. Anizokorija može biti uzrok različitih stupnjeva morbidnosti pacijenta, čime se pojačava vrijednost brzine dijagnoze, efektivne komunikacije i pravilno praćenje u takvih pacijenata.

Ključne riječi: Anizokorija, Pupila, Hornerov Sindrom, Tonička Zjenica, Paraliza Trećeg Moždnog Živca , Aferentni Pupilarni Defekt

INTRODUCTION

Anisocoria is a relatively common condition characterized by unequal pupil sizes. Its causes are numerous and varied, ranging from benign physiologic anisocoria to life-threatening emergencies. Anisocoria patients present with diverse sets of symptoms that help to serve as a clue to the underlying pathology involved. Much of the success in making an appropriate diagnosis is dependent on a thorough clinical evaluation.

All physicians must be mindful of recognizing anisocoria, as it is not limited to ophthalmologic patients. Patients may range from healthy patients, without any comorbidity, to patients who are hospitalized on the general medicine ward, surgical ward or palliative care ward. The principle proportion of patients requiring attention is those displaying symptoms. The importance of early recognition of anisocoria cannot be overstated as there is a strong association between early recognition and overall adverse outcomes such as mortality, morbidity, infections, and length of hospital stay. Complications and mortality can be significantly reduced with early diagnosis (1).

Testing pupillary function is an essential part of a thorough neuroophthalmological examination, and it is important to proceed logically, in order to avoid steps, which do not provide any useful information. A thorough eye examination, when combined with an accurate and detailed history, will often lead to a diagnosis (2). Anisocoria is a complicated condition, which requires a good understanding of the underlying pathophysiology involved in different age groups and amongst different comorbidities. The diagnostic procedures involved are often specific for each etiology and must be used in accordance with the physician's knowledge.

Despite recent clinical successes in reaching a diagnosis, there is still a lack for fully formulated practical guidelines on how to examine the pupils and how to handle abnormal pupillary findings. Moreover, the developments of different diagnostic procedures have given impetus to a varied approach in the evaluation of anisocoria. In this review, a brief discussion of the anatomy and physiological processes, connected to pupil size, will provide context for the various diagnostic approaches to anisocoria and provide rationale for their use in a structured manner.

RELEVANT ANATOMY

PUPILS

The pupil is a hole, located slightly nasally and inferiorly of the iris of the eye, allowing light to strike the retina. Normally, both eyes have round, equally sized pupils.

The greatest pupil size is evident during the teenage years. From then on, pupil size decreases with age (3). Two muscles are responsible for controlling the size of the pupil; an iris sphincter muscle, which works to make the pupil smaller, and the iris dilator muscle that works to make the pupil larger. The iris sphincter can shorten up to 87% of its length, facilitating the normal degree of maximal mydriasis and miosis (10 mm and 1 mm respectively) (4). Pupils constrict to light and will also constrict during accommodation, independent of the illumination. The constriction during accommodation is part of the near triad: accommodation, miosis and convergence.

A healthy iris is always moving, even when light and accommodation are constant.

The oscillating movement of the pupil is called hippus, which is normal, but was once thought to be a sign of neurologic disease (5).

AUTONOMIC NERVOUS SYSTEM

(ANS)

The autonomic nervous system controls the body systems unconsciously, through a series of complex reflex actions.

Control of the pupil size, referred to as the pupillary light reflex, is one of these reflexes. The autonomic nervous system has two divisions that are responsible for dictating the physiologic control of pupillary function; the sympathetic system and parasympathetic system. These divisions operate opposing and simultaneous to one another in attempt to

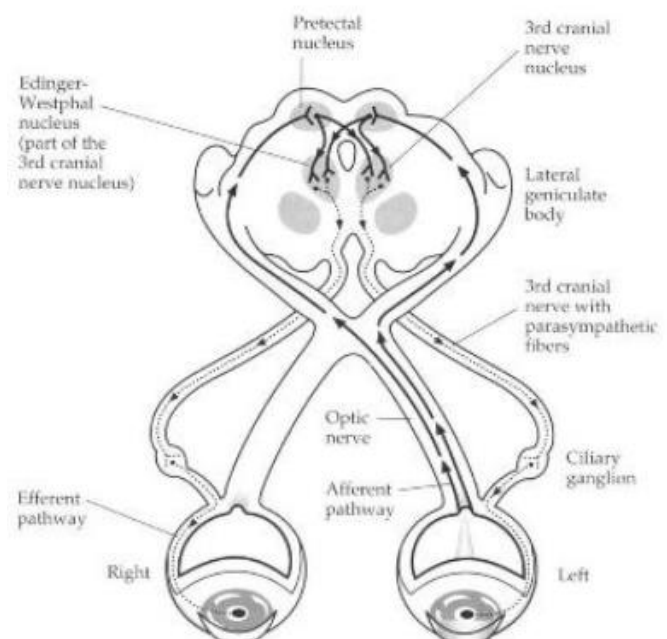


Fig.1 Autonomic Nervous System pathway (7)

maintain a balance. The size of the pupil is the result of which system is dominating at any given moment. The sympathetic pathway is a three-order neuron pathway that mediates pupillary dilation. The parasympathetic pathway is a four-order neuron pathway that controls pupillary constriction and accommodation (6). These pathways will be discussed in further detail together with their relevant diagnostic measures.

Pupillary function occurs involuntarily in response to light stimulation and adrenergic tone (4, 6). Afferent light stimuli are picked up by retinal ganglion cells whose axons travel down the optic nerve, optic chiasm and optic tract (7). Typically, bright light causes the sphincter contraction to make the pupil smaller (miosis), while dim light causes the sphincter relaxation, as well as the dilator contraction, to make the pupil larger (mydriasis). Innervation to these important muscles is under the control of the autonomic nervous system, which is also simultaneously responsible for changes in adrenergic tone. The main control of the autonomic nervous system is the hypothalamus (8).

PARASYMPATHETIC PATHWAY

The pupil response occurs by virtue of a reflex loop. Light stimulates the retina, the retinal ganglion cells transmit a signal along the afferent optic nerve fibers to the brain, from where the pupil response returns to the eye via the efferent oculomotor nerve fibers (6). The optic nerve contains both visual and pupillary fibers, which travel different routes. Pupil fibers branch off toward the pretectal nucleus, located in the dorsal midbrain, with some axons crossing over to the opposite side at the optic chiasm. Prior to the chiasm, the optic nerve carries axons from only one eye, whereas post-chiasm, there are fibers from both eyes (8). Consequently, light stimuli to the midbrain are divided equally to both eyes. This is the basis of the consensual light reflex. Intercalated neurons connect the afferent and efferent sides of the system. These axons continue the reflex loop traversing from the pretectal nucleus to the Edinger-Westphal nucleus. Pupil fibers from the Edinger-Westphal nucleus return to the iris, in unison with nerve fibers controlling the eye muscles (9). Together they compose the Oculomotor Nerve (CN III). Within the orbit, the pupil fibers split off from CN III to enter and synapse in the ciliary ganglion. From here, the fibers travel within short ciliary nerves to the

sphincter (8, 9). To summarize the pupil reflex loop, a signal is transmitted from the retina to the pretectal nucleus where it synapses. Intercalated neurons transfer this signal to the Edinger-Westphal nucleus via both third cranial nerves. Another synapse occurs at the ciliary ganglion just prior to the iris and sphincter. From the retina to the Edinger-Westphal nucleus is the afferent part of the system, whereas from the Edinger-Westphal nucleus to the sphincter is the efferent part of the system. This is the parasympathetic side of the story.

SYMPATHETIC PATHWAY

The sympathetic system is responsible for output to the dilator muscle by virtue of a sympathetic reflex loop. It is a three-order neuron pathway, which travels from the brainstem, through the spinal cord, over the apex (top) of the lung, along the carotid artery, through the cavernous sinus, to the eye (7). This chain also includes nerve fibers that control sweating function to the face. The first neuron, commonly referred to as the central neuron, originates in the hypothalamus. It travels through the brainstem and cervical (neck) spinal cord, and ends at the ciliospinal center, where it synapses. The second neuron, also called the preganglionic neuron, originates at the ciliospinal center and traverses through the stellate ganglion at the top of the lung to the common carotid artery and eventually to the superior cervical ganglion, where it synapses (7, 9).

The superior cervical ganglion is located at the bifurcation of the internal & external carotid arteries. The third neuron, also known as the postganglionic neuron, begins at the superior cervical ganglion, travels with the internal carotid artery, then through the cavernous sinus and joins with the trigeminal nerve (CN V, sensation to the eye). A subset of fibers diverges from the trigeminal to join the long ciliary nerves and travel through the choroid to the iris dilator muscle. The remaining fibers, from the trigeminal nerve, branch off before the ciliary nerves and travel to Mueller's muscle of the eyelid. Mueller's muscle is responsible for helping to raise the eyelid (10). To summarize, when the sympathetic system is stimulated, the pupils dilate, and the eyes open wider.

EXAMINATION OF THE PUPIL

Detection of pupil irregularities, and possible anisocoria, is often first noticed at the primary care level (11). The routine pupil examination begins with observation. The first step is external examination of the eyes, noting eyelid position, any ptosis or blepharochalasis, measurement of palpebral apertures. Next, transillumination of the eyelid allows is used to check the relationship of the eyelid margin to the corneal light reflex. Once completed, external factors may be excluded (11, 12).

Pupil response must carefully be tested to direct and consensual stimuli. Both pupils must be tested by ensuring not to illuminate one eye more than the other. For each eye, the pupillary response should be equal, in both speed and magnitude, to both types of stimuli (13).

In checking for anisocoria, it is useful to distinguish between anisocoria that is greater in the dark in contrast to anisocoria that is greater in the light (12). To do so, pupil size is examined twice, first with room lights on, then in dim light (normal size difference is less than 0.4 mm). Using a distance fixation target and a transilluminator to light the face from below helps to achieve consistent findings (14). Anisocoria that is greater in the dark suggests a lesion in the sympathetic pathway, which results in an abnormal pupil that is smaller or unable to dilate in response to removal of a light stimulus. Anisocoria that is greater in dim light is associated with mechanical or pharmacological disturbances, as well as with Horner's syndrome. Conversely, anisocoria that is greater in the light suggests a parasympathetic defect, resulting in an abnormal pupil that is larger or unable to constrict in response to a light stimulus (15). Anisocoria that is greater in bright light may be due to a third cranial nerve palsy or a tonic pupil. No difference in anisocoria, under dim and bright light, indicates that there relative function of the pupillary sphincter and dilator muscles, and this is consistent with simple anisocoria (16).

A swinging flashlight test, described in greater detail below, should be performed to check for an afferent pupillary defect (17). It is important to remember that the pupils will

appear equally sized in ambient light, and that the difference between the two eyes will only be revealed by the comparison of the light response (11, 17).

If all results are normal, normal pupillary function is recorded. The appearance of normal pupils is usually recorded as PERRLA: Pupils Equal Round Responsive to Light and Accommodation (14). In the case that any irregularities are observed, a series of pharmacologic tests must be performed to determine the exact etiology of the problem. The slit-lamp examination can provide additional information for associated or coexisting ocular conditions. Further diagnostic procedures that help deduce an exact etiology are described in conjunction with each disorder.

ANISOCORIA

The word anisocoria is derived from the Greek language, meaning disease of unequal pupil size. A difference in pupil size up to 0.4 mm is normal (18). However, when a greater difference in pupil size is present, and persists, an underlying pathology is likely to be causing it.

Anisocoria is a common condition. Although no overall prevalence statistics are available, it is estimated that in dim light, approximately 25% of the normal population has anisocoria of 0.4 mm or more at the moment of examination. In room light, this number drops to roughly 10%. The incidence and prevalence data for anisocoria depend on the specific pathophysiology and population (18). Mortality and morbidity rates associated with anisocoria also depend on the underlying pathology.

Simple anisocoria, also referred to as physiological anisocoria, is a normal finding that cannot be attributed to pathologic pupils, intraocular drugs, ocular injury, or ocular inflammation (19). The difference in pupil size in simple anisocoria rarely exceeds 1 mm (18, 19). Simple anisocoria is present in less than half of people at any given moment and may change its characteristics over time. Anisocoria is a constant finding in up to 3% of persons and it normally it is the same eye that will display the pupil irregularity (18).

Pathological anisocoria has a wide spectrum of underlying causes. Commonly, anisocoria is caused by a problem with input to either the pupillary sphincter or the dilator muscles (18). The ANS is responsible for controlling these muscles, thereby regulating pupil size. Denervation of the sympathetic or parasympathetic divisions of the ANS will result in anisocoria. Anisocoria may also be the result of mechanical or pharmacological disruptions. Mechanical causes of anisocoria can be broadly grouped as inflammatory, surgical or traumatic. Pharmacological causes are classified according to the agents responsible. Anticholinergic agents, cholinergic agonists or adrenergic agonists are the usual suspects (20).

The characteristics of physiologic anisocoria have been studied in great depth in effort to aid eye care professionals to distinguish between benign from pathologic findings (21). The diagnostic procedures involved in ascertaining a specific cause will be discussed in conjunction with their relevant conditions.

AFFERENT PUPILLARY DEFECT

An APD, also referred to as an Afferent Pupillary Defect or Marcus-Gunn pupil, occurs when there is a problem with light information travelling in the afferent part of the system (22). The afferent side of the pupil reflex loop is the part that is bringing information to the brain, the Edinger-Westphal nucleus in the midbrain to be precise. The brain receives and analyzes this information, and in turn returns its response through the efferent side of the loop (22).

The afferent pathway refers to the pre-chiasmal portion of the optic nerve. The pre-chiasmal optic nerve is the portion where there are only fibers from one eye. Consequently, when there is a defect in this part of the pathway, the pupil on the affected (ipsilateral) side will not constrict as well as the pupil on the healthy (contralateral) side (22). Reduced input results in reduced output.

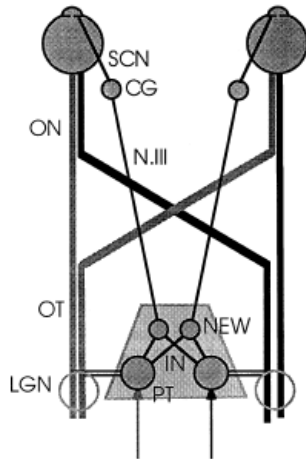


Fig.2 Schematic drawing of the pupillary light reflex pathway. (ON optic nerve, OT optic tract, LGN lateral geniculate nucleus, PT pretectal area, IN intercalated neurons, NEW nucleus Edinger-Westphal, N.III oculomotor nerve, CG ciliary ganglion, SCN short ciliary nerves)(8)

An APD is commonly defined as the difference between the direct and consensual reaction of the same eye. This is tested classically by the swinging flashlight test, which aims to demonstrate a difference between eyes in response to direct light reactions. The test is performed using a transilluminator, such as an indirect ophthalmoscope, to shine a light into one pupil, wait for

a brief interval, typically two to four seconds, and then quickly shine the light into the other eye (23). Naturally, when light is shone into the eye, the pupil should initially show constriction, followed by a slightly re-dilation (22,23). Best results are obtained with a pupil not constricting below four millimeters.

The absence of initial constriction indicates an abnormal finding. If one optic nerve is damaged, it will not send a strong signal back to the Edinger-Westphal nucleus.

The EWN will interpret a weak signal as less light, and its return response will not be as strong as in the other eye (24). In other words, a weak signal leads to a weak response, which leads to less pupillary constriction.

Damage to the retina or optic nerve of one eye may cause an APD (22). Typically, the vision and visual field correlate with the APD. The greater the damage to the retina or optic nerve, the worse the vision and visual fields will be. As a result, the APD will be more pronounced. A blind eye will always present with an APD and the pupil will not constrict to light at all (22, 24).

HORNER'S SYNDROME

Horner's syndrome is classically characterized by a triad consisting of ptosis, miosis, and anhidrosis, although the full triad is rarely present (26). It is the result of a disruption within the sympathetic system. Normally, the sympathetic reflex loop is responsible for enlarging the pupil larger and raising the eyelid. Moreover, sudomotor fibers for the face participate in the loop as well (7). It follows that damage to the sympathetic system will result in decreased output to the dilator muscle, and an unopposed sphincter, causing a miotic pupil. Depending on the site of the lesion, interruption of the ipsilateral sympathetic innervation may also cause ptosis on the same side as the affected pupil. The degree of ptosis will not be as great as when the levator muscle is malfunctioning, however a slight ptosis in Horner's syndrome will inevitably be apparent (26). The patient may use their frontalis muscle of the forehead to help lift the eyelid. A small subset of sympathetic fibers, responsible for controlling sweating in the area of the forehead, will also cease to function, resulting in anhidrosis (7). The difficulty with diagnosis is that a long and complicated sympathetic pathway is often involved on each level.

Responsible lesions that can affect the sympathetic pathway are diverse and differ depending on the portion of the sympathetic reflex loop they affect. The causes responsible for disruption of the first-order neuron include tumors, stroke, and multiple sclerosis. The second-order neuron is often upset by lung disease, lung tumor, trauma, and aortic aneurysm, due to its anatomical proximity to the aforementioned structures. The third-order neuron may be damaged by trauma, aneurysm or dissection of the internal carotid artery (27). Depending on the cause, early recognition and intervention can be lifesaving (28). Localization of the lesion greatly assists in the evaluation of Horner's Syndrome.

In rare instance, Horner's Syndrome may occur congenitally. During the developmental period, the iris requires sympathetic input for full pigmentation of the iris stroma to occur. Birth injury to the spinal cord, or any other disruption of the sympathetic innervation, will result in Horner's syndrome with heterochromia iris. Observing old photographs may help to identify how long a patient has had Horner's syndrome. In

approximately 60% of patients with Horner's syndrome, a cause cannot be identified (26).

In order to avoid over diagnosing, as well as, to minimize the risk of missing severe underlying disorders a rational handling of diagnostic procedures is necessary (28). The first examination is aimed to detect a dilation deficit of the smaller pupil. Both pupils are measured in bright and dim light. In a darkened room, a dim light shine is then shone from below, tangentially on to both eyes, in order to be able to observe the pupils without constricting them (29). Anisocoria will be more noticeable in dim light, when the dilator is supposed to be working. The patient is then instructed to fixate on a distant target. A stronger light is switched on and off and the dilation of the pupils is observed. Normal pupils will dilate in dim light within 4 to 5 seconds, and at equal speed. In case of Horner's syndrome the involved pupil will exhibit dilation lag, catching up after 15 to 20 seconds (26, 28). The biggest difference will be observed after 4 seconds. Additionally, the Horner's pupil will remain smaller than the normal pupil in dim light (26). If the smaller pupil shows dilation, Horner's syndrome has to be suspected, but the diagnosis cannot be established until further testing is done

Cocaine test

Cocaine, an indirect sympathomimetic agent, prevents reuptake re-uptake into the presynaptic sympathetic neuron, thus revealing the spontaneous activity of the sympathetic pathway to the eye. When norepinephrine remains attached to its target receptors, in this case the dilator muscle, it continues to work to dilate the pupil (29).

To perform the cocaine test, one drop of 5% cocaine solution is placed in each eye, followed by a period of watchful waiting for up to one hour. Ideally, photos are taken before instilling the drops, and again at 30 and 60

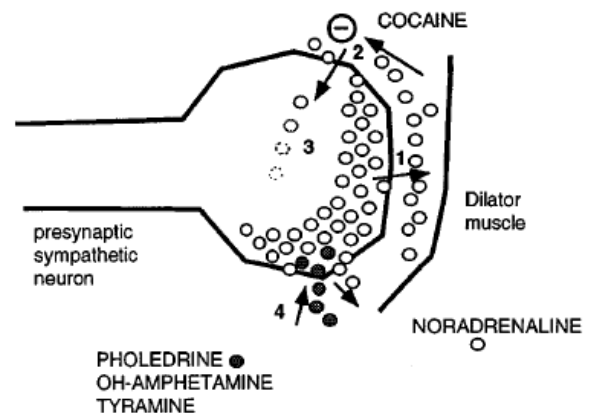


Fig 3. Pharmacological testing in Horner's syndrome Noradrenaline is released spontaneously (1) and eliminated by re-uptake (2) and intracellular decomposition (3). Cocaine inhibits the noradrenaline re-uptake. Pholedrine, OH-amphetamine and tyramine are taken up and exchanged for noradrenaline (4) (29)

minutes after instillation (30). Administration of cocaine to a healthy eye will cause the dilator muscle to remain switched on and result in mydriasis. In Horner's syndrome, no dilation occurs because there is no release of norepinephrine (26, 29). Consequently, no transmitter is available to keep the dilator muscle active. In summary, a normal pupil will dilate; Horner's syndrome will not dilate.

The cocaine test confirms that no signal is being received by iris, and on that account, the diagnosis of Horner's syndrome (29). However, testing with cocaine has limitations. The cocaine test does not allow for determination of which part of the three-order neuron sympathetic pathway is affected (29, 30). Moreover, the control pupil (contralateral eye) may not dilate due to the relatively weak dilating effect of cocaine. There is also the risk of a false-positive result if the affected pupil is incapable of dilating for another reason (31). When Horner's syndrome is proven or highly suspected, a second test is recommended in order to confirm the diagnosis and help to localize the site of the lesion.

Apraclonidine test

The use of apraclonidine to diagnose Horner's syndrome is a fairly new concept. The apraclonidine test works on the principle of denervation hypersensitivity, which states that when a nerve is damaged its receptors cease to receive regular amount of neurotransmitter, and consequently, they become extra-sensitive to the neurotransmitter (32). Apraclonidine is an adrenergic drug with a weak agonist action on α -1 receptors and a strong agonist action on α -2 receptors. In Horner's syndrome, there is an upregulation of α -1 receptors in response to the loss of sympathetic innervation (26, 32). This results in a hypersensitivity of the affected pupil, such that it dilates in response to apraclonidine. In contrast, a normal pupil will either show no change in size or may constrict due to α -2 activity. The current criterion for diagnosis of Horner's syndrome is a reversal of the anisocoria after bilateral administration of topical apraclonidine (31).

The apraclonidine test is performed in the same manner as the cocaine test. Similarly, it can help to diagnose Horner’s syndrome, but does not help to localize the site of the lesion. Unlike cocaine, a positive test depends on the development of sympathetic hypersensitivity at the end organ. The time interval required for the development of sufficient hypersensitivity is not known (33). This has led to debate over utility of apraclonidine in the acute setting. Another confounding factor is the response of a pupil with incomplete disruption to its sympathetic supply. Any blockade of sympathetic firing will result in hypersensitivity and thus a positive response to apraclonidine testing. While the usefulness of apraclonidine in acute and chronic Horner’s Syndrome has been clearly demonstrated, a larger study is necessary to provide more data on the viability of this test (34).

Table 1. Pharmacological Testing Summary

	Mode of action	Abnormal pupil	Normal pupil
Pilocarpine 0.125% cholinergic agonist	denervation hypersensitivity	Adies = will constrict	will not constrict
Cocaine 10.0 % adrenergic agonist	prevents neurotransmitter reuptake	Horners = will not dilate	dilates
Apraclonidine 0.5% adrenergic agonist – weak	denervation hypersensitivity	Horners = dilates	will not dilate

THIRD CRANIAL NERVE PALSY

The parasympathetic fibers innervating the pupil sphincter travel together with the oculomotor nerve. The third cranial nerve is composed of fibers from the Edinger-Westphal nucleus and fibers from the oculomotor nucleus (7). The oculomotor nucleus controls the majority of extraocular muscles, as well as, the levator palpebrae superioris muscle. The Edinger-Westphal nucleus is responsible for innervation of the iris sphincter muscle and the ciliary muscle (6). Naturally it follows that, as a general rule, palsies of the third cranial nerve do not cause isolated mydriasis. Symptoms of third

nerve palsy include ptosis, diplopia and mydriasis. The pupil may be spared or involved, which serves as a useful clue to the underlying pathology (35). An affected pupil signals that the parasympathetic fibers to the sphincter are not functioning properly.

The pupillary fibers travelling within CN III to the iris sphincter are located close to the nerve's surface (6). Consequently, they are susceptible to compression. Pathological changes to surrounding structures may cause a third nerve palsy. For example, an aneurysm, tumor, cavernous sinus thrombosis or hemorrhage can compress CN III, leading to development of palsy and a dilated pupil (35). Ptosis may also occur because the levator muscle is not functioning.

A spared pupil suggests that only fibers from the oculomotor nucleus are involved. CN III obtains its blood supply from small vessels, called vasa nervosa, located centrally (35). Diabetes or infarction, typically result in pathology of small blood vessels. Such changes tend to selectively affect somatic fibers over parasympathetic fibers (36). As a result, the functions of the muscles under control of CN III are absent or reduced, while the remaining extraocular muscles are not opposed. This causes the eye to be positioned inferior and lateral to its normal position. The degree of the gaze misalignment may vary depending on which fibers are damaged. When gaze misalignment is present without anisocoria it is referred to as a pupil-sparing CN III palsy (35).

The diagnosis of third nerve palsy may be considered following a clinical exam revealing ptosis, extraocular muscle weakness or pupil enlargement (37). Pupil involvement in addition to ptosis and eye muscle weakness is a medical emergency. Such patients must immediately undergo neuro-imaging to inspect for the presence of an aneurysm. In the acute setting, computed tomographic angiography is more sensitive than magnetic resonance angiography in detecting aneurysms that cause oculomotor palsy (35, 37). With the contemporary possibilities of angiography, the rule of spared or involved pupils should be applied only to patients older than 60 years with ischaemic risk factors and paralysis of the external ocular muscles but otherwise normal pupil (37). Otherwise, in cases of a pupil-sparing CN III palsy, frequent re-examinations, in combination with, laboratory studies, cytological studies and other examinations in

search of an underlying etiology, such as neurotropic viral infection, diffuse peripheral neuropathy or neurosyphilis, should be performed.

TONIC PUPIL

The tonic pupil, sometimes called an Adie's pupil, is the term used to denote a pupil that is larger than normal, and responds to both light and near stimuli with extremely slow constriction and re-dilation (36). As a rule, accommodation is better preserved. Initially larger, the pupil tends to become smaller than its normal fellow as the condition progresses (36, 38). The tonic pupil is unilateral in approximately 90% of cases, but may become bilateral at a rate of 4% per year. It has a prevalence of approximately two cases per 1000 population and is the most common condition among those mentioned so far. Tonic pupils can be found at any age and in both sexes, however it is predominately found in females, with roughly 70% of cases occurring in females between the ages of 20 and 50 years old (39). The vast majority of these patients will also have reduced deep tendon reflexes. If associated with hyporeflexia, the condition is termed Adie's syndrome. Ross's syndrome is an eponym for a tonic pupil in conjunction with hypohidrosis and other vegetative insufficiencies. In most cases, no cause can be identified; however a viral etiology is often presumed (40). Clinically, the pupil does not respond well to light, but does constrict to accommodation or attempted accommodation, which help to explain the presenting symptoms. The loss of accommodation results in abrupt onset of near blur and a dilated pupil may cause photophobia (36, 38).

The tonic pupil is a benign neuropathy of the cholinergic autonomic synapses. It is a result of damage to the parasympathetic ciliary ganglion (36). The parasympathetic innervation to the iris and ciliary body travels with the third cranial nerve and synapses in the ciliary ganglion. Interruption of the pupillary reflex loop anywhere along its route results in incomplete parasympathetic innervation, which leads to pupillary dilation, decreased speed and amplitude of constriction and decreased speed and amplitude of accommodation (7). Moreover, damage to the ciliary ganglion or postganglionic short ciliary nerves produces a better near reaction than light reaction, which is referred to as light-near dissociation (40). In response, up-regulation of the post-synaptic receptors

fibers causes the pupil to become hypersensitive to stimuli. Unlike light - near dissociation, which often requires months to develop, hypersensitivity can be observed within a few days (38). Additionally, fibers formerly destined for the ciliary body travel to the pupil instead. This process, known as aberrant regeneration, explains why the tonic pupil becomes smaller over the course of time (36, 38). The re-established connections are less efficient, further contributing to the latency and slow pupillary constriction.

The first step in proper diagnosis, as with other types of anisocoria, is to determine if the cause is benign and physiologic, or acquired and pathologic, which may be done by using methods already discussed above. Next, pupillary response to direct and consensual light stimuli must be compared, as well as the amount of constriction accompanying accommodative effort. The pupillary constriction that accompanies accommodation is slow and after the near effort is relaxed, re-dilation may take minutes to hours (38). The use of pharmacological testing, with dilute pilocarpine (0.125%) or methacholine (2.5%), to demonstrate denervation hypersensitivity, may be performed to help in the diagnosis. These agents will cause constriction in the majority of patients (80%) with a tonic pupil, whereas normal, healthy pupils would not respond. One drop of 0.125% pilocarpine should be instilled into the inferior fornix of both eyes and the pupil diameters re-evaluated 45 minutes later. If denervation hypersensitivity is present, the involved pupil will constrict more than 0.5 mm relative to the fellow eye (36, 38). It is important to note that hypersensitivity is not limited to post-ganglionic lesions of the ciliary ganglion and may also occur in both pre and postganglionic lesions of the third nerve.

The diagnosis of tonic pupil can be confirmed via slit lamp biomicrography. A slit lamp exam is the gold standard for observation of the iris (36). It is best viewed with a wide beam aimed at a 60° angle (16). When tonic pupils are present large sectors of the iris will not constrict to light as the lamp is switched on and off. This is as a result of non-functional segments of the iris being pulled by healthy neighbouring segments. This phenomenon, referred to as stromal streaming, is created by sectoral palsy of the sphincter muscle. The sphincter muscle is interwoven with the stroma; therefore it is possible to have a sector of the pupil not functioning and other sections functioning

normally. In such instances, pupil movement is described as vermiform, as part of the iris moves while part does not (9). Additionally, the pupil may be observed to not be round, with sections of the pupil margin appearing straight. It is important that the observation of pupil diameter is made while fixation is directed at distance to eliminate contribution the near synkinetic response, as often times, the synkinetic pupil movement is mistaken for a restored near response (38).

MECHANICAL CAUSES

Mechanical causes of anisocoria occur as a result of damage to the iris. Inflammation, surgical injury, and trauma may all interfere with the function of either the dilator or sphincter and result in an irregular pupil shape. The most common cause of mechanical anisocoria is trauma of the eye, which results in tearing of the sphincter (39). Rapid compression of the eye from front-to-back causes it to expand across the equator. Such sudden outward movement can tear the sphincter, resulting in a dilated pupil on the affected side. The ciliary nerves may also be damaged in trauma, so that nerve input to the iris is impaired. Other mechanical causes may include, but are not limited to, posterior synechia, anterior chamber lens implants, and trauma to the iris from phakoemulsification during cataract extraction. Inflammatory conditions, such as uveitis and angle closure glaucoma, can also precipitate pupil irregularities (41). Mechanical causes often affect the iris, which is best examined using a slit lamp and it follows that every case of anisocoria should be checked carefully using this method (16).

PHARMACOLOGICAL CAUSES

Pharmacological causes are classified according to the agents that are responsible for causing the anisocoria. Drugs that act on the ANS, such as anticholinergic agents, cholinergic agonists and adrenergic agonists, will affect pupil size (41). Patients often accidentally rub these substances in their eyes causing acute anisocoria. When a patient presents with an acutely dilated pupil, an accurate and detailed history should always be taken, to help reveal any possible pharmacological causes. Frequently, contact lens users require vasoconstrictor drops, which can dilate their pupils. Children may come in contact with certain species of plants that contain substances causing

mydriasis, or particular fertilizers or insecticides that cause miosis (12). When a pharmacological cause of anisocoria is suspected, the diagnosis can be confirmed using one drop of 0.5% pilocarpine, which will constrict a normal pupil, but will not constrict a pharmacologically dilated pupil (16). It is important to remember that 0.5% pilocarpine will also constrict a pupil dilated due to damage to the parasympathetic system; therefore an event suggesting a pharmacological cause must always be present in conjunction with using this test.

OTHER CAUSES

A myriad of pathologies, the scope of which is too broad for review here, may lead to pupil irregularities. An important select few will be briefly discussed to highlight their importance in the differential diagnosis. Congenital anomalies, such as coloboma, migraines and various other syndromes that require careful, specialist review, often present with pupil irregularities (41). Argyll Robertson pupils, is an eponym for pupils that are miotic, and are characterized by light – near dissociation. Diagnostic features that suggest the presence of AR pupils are an absent light reflex, an intact near reflex and pupils that are difficult to dilate with mydriatic drops (40). They are caused by disease in the midbrain, and the classic cause is syphilis. Other causes can include tumors, encephalitis, demyelinating disorders, diabetes and alcoholic neuropathy. If a patient's history and physical examination suggests Argyll Robertson pupils, testing should include a serum fluorescent treponemal antibody blood test for syphilis. Furthermore, it is important to distinguish them from true light-near dissociation, which occurs when the pupillary constriction to an accommodative target is greater than the constriction to bright light (40). Near and accommodative fibers are different in their anatomic location, and may be damaged separately (6). To test for a true light – near dissociation, the patient should be introduced to a moderate ambient room light, instructed to look at a distance target and pupil size measured using a bright light. Next, the patient must look at an accommodative target. If the patient is presbyopic, they may be asked to converge to a target, or point to a target to elicit the near triad. A true light – near dissociation is present if the near response exceeds the best constriction that

bright light can produce (40, 41). It is common that patients present with various comorbidities and the cause of anisocoria are often multifactorial.

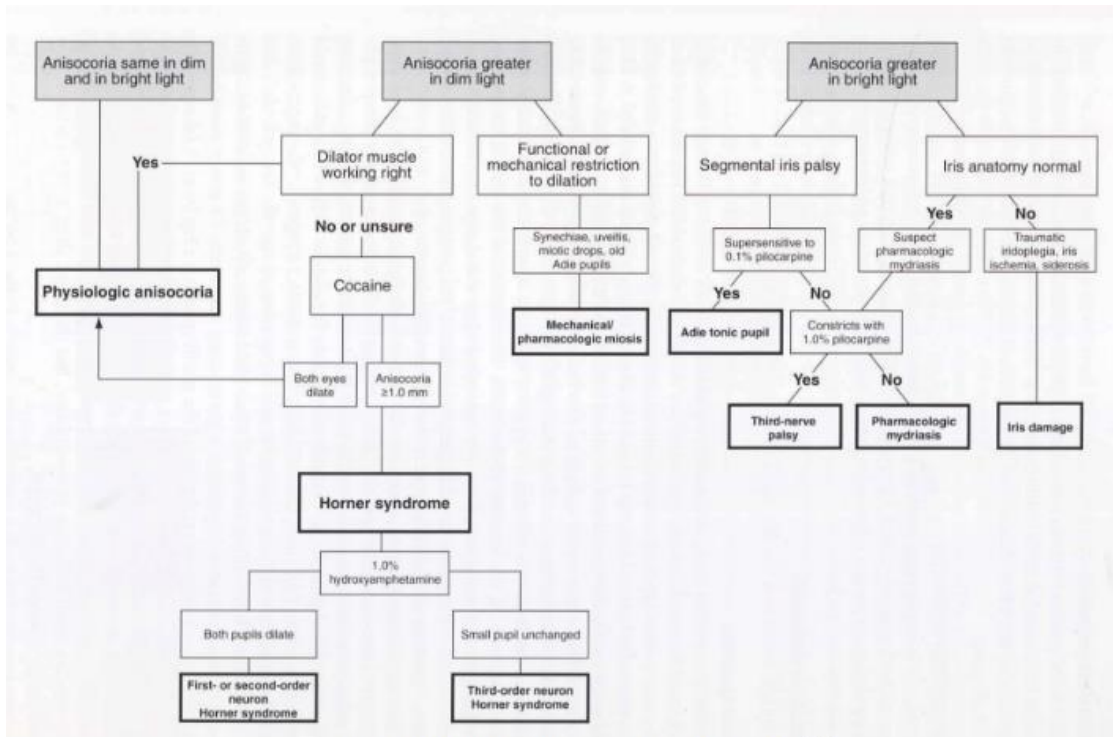


Fig. 4 Flowchart for the evaluation of anisocoria(15)

PUPILLOGRAPHY

Pupillography is a method of recording pupillary movements and allows for measurement of these movements to be made. It may be implemented as a technique for studying changes and reactions to light (42). Recordings of pupillary reactions have been carried out since the turn of the century. Formerly, pupillography has predominately been applied in research. Novel advances in technology have allowed for infrared video pupillography, to be applied in a clinical setting, to evaluate pupillary disorders and dysfunctions of the afferent visual system. Nowadays, pupilometers are relatively inexpensive and serve as a reliable tool in psychological and pharmacological research clinical application of pupillography (43). It will be a challenge for future clinical research to offer pupillography its place in modern neurological and ophthalmological diagnostics. There is certainly promising potential for pioneering revolutionary diagnostic procedures with this technology.

DISCUSSION

The implications of attaining a diagnosis of anisocoria are great and far-reaching. These patients may be susceptible to greater health risks, as well as life-threatening conditions, which must be managed appropriately in order to prevent further morbidity and mortality. A structured clinical approach is required to ascertain the underlying cause involved in each case. The importance of an accurate and detailed history cannot be overstated. On the whole, in the evaluation of anisocoria it is important to understand the underlying pathology varies between mechanical, pharmacological and neurological causes. Diagnostic procedures involved in distinguishing mechanical and pharmacological causes are relatively straight forward and well established. Neurological causes must be further subdivided according to which part of the nervous system is affected, as the etiology may vary, depending on if the brain, the autonomic nervous system or peripheral nerves are affected. In cases resulting from an autonomic nervous system dysfunction, it is essential to recognize which division of the ANS is affected, as well as if the disturbance lies in the afferent or efferent part of the pathway. The most important question, to help differentiate whether the sympathetic or parasympathetic division is affected, is whether both pupils are normally reactive to light. When both pupils are reactive to light, the lesion is likely in the sympathetic pathway and the smaller pupil is defective. This is because pupillary constriction, which is dependent on the parasympathetic pathway, is intact. It follows that when one pupil is non-reactive, the lesion is likely in the parasympathetic pathway and the larger pupil is abnormal. Although no gold standard diagnostic approach has yet to be developed, the various individual diagnostic procedures are indispensable when combined with the knowledge of a skilled physician. Moreover, the advent of new diagnostic tools is facilitating opportunities for a establishing a concrete diagnostic protocol. Unnecessary evaluation of benign disorders may produce morbidity inadvertently; however exclusion of serious conditions is vital. Upon discharge of patients, proper communication is imperative to ensure these patients follow their treatment regimens and properly and understand the details and importance of their follow up appointments.

ACKNOWLEDGMENTS

I would like to thank Professor Tomislav Vidović, Department of Endocrinology, Clinical Hospital Center Rebro, for his time and mentorship throughout this endeavour.

Additionally, I would like to thank M.Sc. Zdravko Beljan, Veleučilište Velika Gorica, for his guidance. Lastly, I would like to thank my family and friends for all of their love and support throughout my medical studies and in the writing of this thesis.

REFERENCES

1. Scott IU, Schein OD, West S, et al. Functional status and quality of life measurement among ophthalmic patients. *Arch Ophthalmology* 1994; 329-35
2. Grosvenor T. The role and scope of the primary care optometrist. In: *Primary care optometry*, 4th ed. Boston: Butterworth-Heinemann, 2002:543-49
3. Morgan MW. Normal Age Related Vision Changes. In: Rosenbloom AA, Morgan M, *Vision and aging*, 2nd ed. Boston: Butterworth-Heinemann, 1993:178-99
4. Parker S. *The Eye and Seeing*, New York: Franklin Watts, 1989:4
5. Kleinstein RN. *Vision Disorders*. 2nd ed. Boston: Butterworths, 1990:109-26
6. Freddo, Thomas F. *Anatomy of the Eye and Orbit: The Clinical Essentials*. Wolters Kluwer Health, 20170517. VitalBook file
7. Pintor J. Autonomic Nervous System: Ophthalmic Control. In: Squire LR, ed. *Encyclopedia of Neuroscience*. Oxford, UK: Academic Press; 2009:967–974
8. Grosvenor T. Pupillary Innervation. In: *Primary Care Optometry*, 4th Ed. Boston: Butterworth-Heinemann, 2002; 163-221
9. Catania LJ. Control of Pupil Size. In: Newcomb RD, Marshall EC, eds. *Optometry Essentials*, 2nd Ed. Boston: Butterworths, 1990:295-310
10. Corsino L, Dhatariya K, Umpierrez G. The Sympathetic Innervation of the Pupil: Important New Insights. *Endotext* [Internet]. 2000; 1–24. Available from: <http://www.ncbi.nlm.nih.gov/pubmed/25905323>
11. Grosvenor TP. The Preliminary Examination. In: *Primary Care Optometry*, 4th ed. Boston: Butterworth-Heinemann, 2002:133-162
12. Townsend JC. Patient Observation and External Assessment. In: Eskridge JB, Amos JF, Bartlett JD, *Clinical Procedures in Optometry*. Philadelphia: JB Lippincott, 1991:30-5
13. Carlson NB. Entrance Tests. In: Carlson NB, Kurtz D. *Clinical Procedures for Ocular Examination*, 3rd Ed. New York: McGraw-Hill, 2004:9-70
14. Goetzinger GJ, Wingert TA, McAlister WH. Routine optometric care: a retrospective study 2006; 73:243-6

15. Eskridge JB. Decision Making in Patient Care. In: Eskridge JB, Amos JF, Bartlett JD. Clinical Procedures in Optometry. Philadelphia: JB Lippincott, 1991:777-9
16. Kurtz D. Refraction. In: Carlson NB, Kurtz D. Clinical Procedures for Ocular Examination, 3rd Ed. New York: McGraw-Hill, 2004:71-159
17. Carlson NB. Functional Tests: Carlson NB, Kurtz D. Clinical Procedures for Ocular Examination, 3rd Ed. New York: McGraw-Hill, 2004:162-218
18. Lam BL. Thompson HS. Corbett JJ. The Prevalence of Simple Anisocoria. Ophthalmol. 1987
19. Congdon N, O'Colmain B, Klaver CC, et al. Causes and Prevalence of Visual Impairment Among Adults in the United States. Arch Ophthalmology 2004; 122:477-85
20. Capone RC. Systemic Health Screening. In: Carlson NB, Kurtz D. Clinical Procedures for Ocular Examination, 3rd Ed. New York: McGraw-Hill, 2004:395-422
21. Kurtz D. Ocular Health Assessment. In: Carlson NB, Kurtz D. Clinical Procedures for Ocular Examination, 3rd Ed. New York: McGraw-Hill, 2004:219-320
22. Gebremedhin E, Behrendt CE, Nakamura R, Parker P, Salehian B. Afferent Pupillary Defect and Other Disturbances in the Afferent Pathway [Internet]. 2013 Feb;36(1):177–85. Available from: <http://www.ncbi.nlm.nih.gov/pmc/articles/PMC3543586/>
23. Eskridge JB. Decision making in patient care. In: Eskridge JB, Amos JF, Bartlett JD. Clinical procedures in optometry. Philadelphia: JB Lippincott, 1991:777-779
24. Al-Azem H, Khan A., Farias JM, Tinetti M, Khoury M, Umpierrez GE, et al. Clinical Practice Guidelines for Anisocoria in Adults: Co-sponsored by American Association of Ophthalmology. [Internet]. 2014;99(2):3430–5. Available from: <http://dx.doi.org/10.4065/mcp.2010.0099%5Cnhttp://dx.doi.org/10.1016/j.ecl.2009.01.007%5Cnhttp://www.ncbi.nlm.nih.gov/pubmed/24276452%5Cnhttp://dx.doi.org/10.1016/j.beem.2010.02.001%5Cnhttp://www.ncbi.nlm.nih.gov/pubmed/24763327%5Cnhttp://www.sciencedirect>

25. Winn B, Whitaker D, Elliott DB, et al. Factors affecting light-adapted pupil size in normal human subjects. *Invest Ophthalmology Sci.* 1994; 35(3):1132–1137
26. Beynat J, Soichot P, Bidot S, et al. Acquired Horner's Syndrome. *J Fr Ophtalmol.* 2007;30
27. Whitmer L. To see or not to see: routine pupillary dilation. *J Am Optom Assoc* 1989; 496-500
28. Classé JG, Thal LS. Risk management. In: Classé JG, Hisaka C, Lakin DH, Rounds RS, Thal LS eds. *Business Aspects of Optometry.* Boston: Butterworth-Heninemann, 1997;315-29
29. Kardoll RH, Denison Brown CK, Thompson HS. Critical evaluation of the cocaine test in the diagnosis of Horner's syndrome. *Arch Ophthalmol.* 1990; 08(12):384-387
30. Thomas RK, Melton NR. Pupillary Dilation: A View from the Trenches. *J Am Optom Assoc* 1993; 64:612
31. Maloney WF, Younge BR, Moyer NJ. Evaluation of the causes and accuracy of pharmacologic localization of Horner's syndrome. 1980; 394-402
32. Morales J, Brown SM, Abdulim AS, Crosson. Ocular Effects of Apraclonidine in Horner syndrome. *Arch* 2000
33. Thompson BM, Corbett JJ, Kline LB, Thompson HS. Pseudo-Horner's syndrome. *Arch Neurol.*1982; 39-42
34. Cremer SA, Thompson HS, Digrc KB, Kardoll RH. Pharmacological Mydriasis in Horner's Syndrome. *Am J Ophthalmol.* 1990; 17-21
35. Finfer S, Chittock DR, Su SY-S, Blair D, Foster D, Dhingra V, et al. Third Cranial Nerve Palsy vs. the Tonic Pupil [Internet]. 2009; 360(13):1283–97. Available from: <http://www.ncbi.nlm.nih.gov/pubmed/19318384>
36. Potter JW. The Big Pupil. *J Am Optom Assoc* 1993; 64:610
37. Casser L, Fingeret M, Woodcome HT. Etiology and Management of 3rd Cranial Nerve Palsy. In: *Atlas of Primary Eyecare Procedures, 2ed.* Stamford, CT: Appleton & Lange, 1997: 2-3

38. Korytkowski MT, Salata RJ, Koerbel GL, Selzer F, Karslioglu E, Idriss AM, et al. Approach to the Tonic Pupil: A randomized controlled clinical trial. [Internet]. 2009 Apr 4;32(4):594–6. Available from:
<http://www.ncbi.nlm.nih.gov/pmc/articles/PMC26604235/>
39. The Eye Diseases Prevalence Research Group: Causes and Prevalence of Visual Impairment Among Adults in the United States. *Arch Ophthalmology* 122:477-485, 2004
40. Kavanagh B, McCowen K. True Light-near Dissociation. *New England Journal of Medicine* [Internet]. 2011 Mar 30;364(13):1280–1. Available from:
<http://dx.doi.org/10.1056/NEJMc1100357>
41. Zoungas, S., Patel, A., Chalmers, J., de Galen, B.E., Li, Q., Billot, L., Woodward, M., Ninomiya, T., Neal, B., MacMahon, S., Grobbee, D.E., Kengne, A.P., Marre, M., Heller S *Nejm*. Anisocoria: Eye Symptoms & Signs: The Eyes Have It. 2010;363:1410–8.
42. Zuckschewerd Verlag W. Pupillography: Principles and Methods of Application. Kuhlmann, Jochen. 1988;9(2):116–122
43. Marshall EC. Economic and Professional Aspects of Disease Prevention and Health Promotion. *J Am Optom Assoc*. 2015; 56:692-7

BIOGRAPHY

Steven Golod is currently a sixth-year medical student, at the University of Zagreb, who was born on February 2, 1988, in Sverdlovsk, Russia. He obtained his H.B.Sc. in Life Sciences at McMaster University, with a minor in Psychology. Aspiring to become a medical doctor, he moved to Zagreb to attend the Medical Studies in English program. He enjoys playing sports, chess and hiking with his English Bulldog, Mirko.