

# Breast reconstruction methods

---

**Bortone, Riccardo**

**Master's thesis / Diplomski rad**

**2018**

*Degree Grantor / Ustanova koja je dodijelila akademski / stručni stupanj:* **University of Zagreb, School of Medicine / Sveučilište u Zagrebu, Medicinski fakultet**

*Permanent link / Trajna poveznica:* <https://um.nsk.hr/um:nbn:hr:105:623820>

*Rights / Prava:* [In copyright](#)/[Zaštićeno autorskim pravom.](#)

*Download date / Datum preuzimanja:* **2024-07-24**



*Repository / Repozitorij:*

[Dr Med - University of Zagreb School of Medicine Digital Repository](#)



UNIVERSITY OF ZAGREB  
SCHOOL OF MEDICINE

**Riccardo Bortone**

**Breast reconstruction methods**

**GRADUATE THESIS**



Zagreb, 2018

This graduation paper was made at the Department of Plastic-Reconstructive Surgery and Breast Surgery, University Hospital Centre Zagreb, University of Zagreb, School of Medicine, under supervision of Prof. Dr. sc. Davor Mijatović, MD, Ph.D. and it was submitted for evaluation in the academic year 2017/2018.

Mentor: Prof. Dr. sc. Davor Mijatović, MD, Ph.D.

## LIST OF FIGURES

**Figure 1:** Preoperative marking before performing a skin sparing mastectomy. *(Courtesy of Department of Plastic-Reconstructive Surgery and Breast Surgery, University Hospital Centre Zagreb, University of Zagreb-School of Medicine, Zagreb).*

**Figure 2:** LD flap breast immediate-delayed breast reconstruction. *(Courtesy of Department of Plastic-Reconstructive Surgery and Breast Surgery, University Hospital Centre Zagreb, University of Zagreb-School of Medicine, Zagreb).*

**Figure 3:** DIEP flap immediate breast reconstruction. *(Courtesy of Department of Plastic-Reconstructive Surgery and Breast Surgery, University Hospital Centre Zagreb, University of Zagreb-School of Medicine, Zagreb).*

## **LIST OF ABBREVIATIONS**

ADM - Acellular dermal matrix

BCS - Breast-conserving surgery

DBR - Delayed breast reconstruction

DIEA - Deep inferior epigastric artery

DIEP - Deep inferior epigastric perforator

DTI - Direct to implant

FDA - Food and Drug Administration

fTRAM - Free transverse rectus abdominis myocutaneous

IBR - Immediate breast reconstruction

IGAP - Inferior gluteal artery perforator

LD - Latissimus dorsi

MsfTRAM - Muscle-sparing free transverse rectus abdominis myocutaneous

PMRT - Postmastectomy radiation therapy

pTRAM - Pedicled transverse rectus abdominis myocutaneous

SGAP - Superior gluteal artery perforator

SIEA - Superficial inferior epigastric artery

SIEAP - Superficial inferior epigastric artery perforator

TDAP - Thoracodorsal artery perforator

TRAM - Transverse rectus abdominis myocutaneous

TUG - Transverse upper gracilis

# TABLE OF CONTENTS

|       |  |    |
|-------|--|----|
| 1     | SUMMARY.....   | 7  |
| 2     | SAŽETAK.....   | 8  |
| 3     | INTRODUCTION .....                                     | 9  |
| 4     | HISTORY OF BREAST RECONSTRUCTION .....                 | 10 |
| 4.1   | Autogenous Breast Reconstruction .....                 | 10 |
| 4.1.1 | The Latissimus Dorsi Flap.....                         | 11 |
| 4.1.2 | Abdominal Flaps .....                                  | 11 |
| 4.1.3 | Free Tissue Transfer .....                             | 12 |
| 4.1.4 | Nipple Areola Reconstruction.....                      | 14 |
| 4.2   | Implant-Based Reconstruction.....                      | 14 |
| 5     | INDICATIONS FOR BREAST RECONSTRUCTION .....            | 16 |
| 5.1   | Breast Cancer Surgery .....                            | 16 |
| 5.2   | Congenital Anomalies Of The Breast.....                | 16 |
| 5.3   | Acquired Deformities Of The Breast.....                | 17 |
| 6     | BREAST RECONSTRUCTION METHODS .....                    | 18 |
| 6.1   | Preoperative Considerations .....                      | 18 |
| 6.2   | Immediate Versus Delayed Reconstruction.....           | 18 |
| 6.3   | Implant Versus Autogenous Reconstruction.....          | 19 |
| 6.4   | Implant-Based Reconstruction.....                      | 20 |
| 6.4.1 | Single-stage reconstruction.....                       | 21 |
| 6.4.2 | Two-stage tissue expander-implant reconstruction ..... | 22 |
| 6.5   | Autologous Tissue Reconstruction .....                 | 23 |
| 6.5.1 | Latissimus Dorsi Flap.....                             | 24 |
| 6.5.2 | Abdominal Flaps .....                                  | 25 |
| 6.5.3 | Other Donor Sites .....                                | 29 |
| 6.6   | Nipple Areola Reconstruction .....                     | 29 |
| 7     | DISCUSSION.....  | 31 |
| 8     | CONCLUSION .....                                       | 33 |
| 9     | ACKNOWLEDGMENTS .....                                  | 34 |
| 10    | REFERENCES .....                                       | 35 |
| 11    | BIOGRAPHY .....  | 42 |

# 1 SUMMARY

**Title:** Breast reconstruction methods

**Author:** Riccardo Bortone

## **Summary:**

Breast reconstruction has become a significant component of the management of breast cancer. It can also be carried out to resolve some congenital and acquired conditions that may affect the breast. The timing and the methods of reconstruction are selected by the plastic surgeon after performing a scrupulous examination of the patient, taking into account health status, body habitus and expectations of the candidate.

Breast reconstruction can be executed immediately after mastectomy or can be delayed according to patient's needs. The surgery entails the use of implants or the patient's autologous tissue. The former includes saline and silicone implants, sometimes supported by tissue expanders. The latter comprises an extensive range of flaps deriving from the back, abdominal, gluteal and inner thigh region. Nipple areola reconstruction completes the reconstructive surgery.

The goal of the reconstructive procedure is to restore a close to normal appearance of the breast and to deliver psychological benefit to the patient.

**Keywords:** breast reconstruction, breast cancer, mastectomy, immediate-delayed reconstruction, saline implants, silicone implants, latissimus dorsi (LD) flap, transverse abdominal muscle (TRAM) flap, deep inferior epigastric perforator (DIEP) flap, gluteal flaps, transverse upper gracilis (TUG) flap, nipple areola reconstruction.



## 2 SAŽETAK

**Naslov:** Metode rekonstrukcije dojke

**Autor:** Riccardo Bortone

### **Sažetak:**

Rekonstrukcija dojke postala je važan dio liječenja oboljelih od raka dojke. Rekonstrukcija može biti rješenje za određene kongenitalne i stečene bolesti koje zahvaćaju dojku. Točno vrijeme i metode rekonstrukcije su određene od strane kirurga koji obavlja detaljan pregled pacijenta, uzimajući u obzir status, navike i očekivanja kandidata za rekonstrukciju. Rekonstrukcija dojke može se obaviti odmah nakon mastektomije ili može biti odgođena prema potrebama pacijenta. Operacija uključuje implantante punjene fiziološkom otopinom ili silikonskim gelom, a ponekad uključuje potporu dodatnim tkivom koje obuhvaća širok spektar režnjeva s leđa, abdomena, gluteusa i unutrašnjosti bedara. Rekonstrukcijom areole bradavice dovršava se rekonstrukcija dojke. Cilj rekonstrukcije jest postići normalan izgled dojke i ujedno pomoći psihi pacijenta.

**Ključne riječi:** rekonstrukcija dojke, karcinom dojke, mastektomija, neposredna-odgođena rekonstrukcija, implantanti punjeni fiziološkom otopinom, implantanti punjeni silikonskim gelom, latissimus dorsi režanj (LD), režanj mišića transversus abdominis (TRAM), TUG režanj, DIEP režanj, rekonstrukcija areole bradavice.

### **3 INTRODUCTION**

Breasts are superficial anatomic structures located in the anterior part of the trunk. In females, they serve as the mammary glands, whose main function is to produce and secrete milk for the nourishment of the newborn.

Beside this main physiologic role, breasts also have an important function in a woman's perception of her body image, sexuality, and self-esteem (1). In the world of medicine, the breast has been at the center of the attention for centuries; it has been the object of the study of multidisciplinary teams because it is the site where the most common cancer occurs in women. Breast cancer is the leading cause of cancer death among women worldwide with near 1.7 million new diagnoses and 521.900 deaths in 2012 (2).

Breast cancer management depends mainly on the stage at which the cancer is diagnosed. Early stage breast cancer is treated by surgery—mastectomy or breast-conserving surgery (BCS), and radiotherapy. Advanced breast cancer requires chemotherapy, hormonal therapy, and targeted therapy.

As reported by different studies, the removal of a woman's breast or part of it represents a traumatic event that accounts for her physical and emotional distress (3). Reconstruction of the operated breast may deliver psychological benefits and improve the quality of life of the patient. It can be carried out either immediately after mastectomy or BCS or delayed, usually several months after on completion of adjuvant treatment if required (1). According to patients needs and surgeon decision, the breast can be reconstructed by using implants or autologous tissue (the patient's own tissue).

This thesis will discuss the breast reconstruction methods starting from historical background till the contemporary techniques, hoping to be an informative tool for those interested in plastic surgery, from medical students to attending physicians.

## **4 HISTORY OF BREAST RECONSTRUCTION**

The history of breast reconstruction, which started more than 100 years ago, was made by many different pioneering plastic surgeons who invented their model of breast reconstruction. Initially, the use of breast reconstruction after mastectomy was forbidden. This was due to Halsted's beliefs regarding a possible recurrence of cancer at the mastectomy site (4). Once passed this prohibition, plastic surgeons were allowed to spread their knowledge about breast reconstruction and in this time there was a gradual improvement of the techniques all aimed to maintain a natural appearance and symmetry of the reconstructed breast. Furthermore, particular attention was given to make the procedure less invasive. Patient satisfaction, problem analysis, and technical challenge have driven breast reconstruction to become a legitimate field within plastic surgery (5).

### **4.1 Autogenous Breast Reconstruction**

Autogenous breast reconstruction involves the manipulation of the operated breast by using a patient's own tissue. The first to attempt this procedure was the Italian surgeon Iginio Tansini, in 1896. In his publication *Nuovo processo per l'amputazione della mammella*, he described the use of a latissimus dorsi (LD) myocutaneous flap to reconstruct the breast after mastectomy (6).

In 1906, Ombrédanne was the first surgeon to use a muscle flap to reconstruct a breast immediately after mastectomy (7). Years later he described the axilloabdominal flap. Much of attention was dedicated to the new methods proposed by Gilles and Holdsworth that used tubed pedicle flap, from the contralateral breast and part of the abdomen, to recreate a breast mound in several stages (8,9). The latter led to many significant scars at the donor site and because of this, the technique was dismissed.

#### **4.1.1 The Latissimus Dorsi Flap**

As described above, the LD flap was invented by Tansini at the end of the 19<sup>th</sup> century. Because of Halsted's influence, it did not get the popularity it deserved. In 1976, Neven Olivary reconsidered the use of the LD flap to cover large defects of the anterior chest wall (10). This idea was after applied to reconstruct the breast. In 1977, Schneider, Hill, and Brown proposed their ideal breast reconstruction method. According to them "it should: be a one-stage procedure; restore deficient skin; replace the contour of the absent pectoralis major muscle; restore lost breast volume; replace the absent nipple-areolar complex, and match in a symmetrical and pleasing way the contour of the remaining breast. This could be accomplished by using a myocutaneous flap incorporating the LD muscle" (11). The main disadvantages related to this flap were the need to combine it with an implant in case its volume was not enough to achieve the reconstruction and the formation of the seroma at the donor site (38).

#### **4.1.2 Abdominal Flaps**

Abdominal flaps were initially experimented by Gilles in the form of tubed pedicle flap, but they were dismissed because of the elevated morbidity at the donor site (8). In 1977, Mathes and Bostwick published a case report in which they described the management of an abdominal wall defect by using a rectus abdominis myocutaneous flap (12). This method became the starting point to involve the use of the abdominal flaps to reconstruct the breast.

In 1982, Carl Hartrampf published the article *Breast Reconstruction With A Transverse Abdominal Island Flap* where he described the use of the transverse rectus abdominis myocutaneous (TRAM) flap for reconstruction of the female breast following mastectomy (13). In his article, he stated: "The technique utilizes an abdominal island flap composed of

an ellipse of skin and fat based on one rectus abdominis muscle isolated on its vascular pedicle". The pedicled TRAM (pTRAM) flap was well-vascularized, had a large arc of rotation, and contained excess abdominal fat with which to reconstruct an aesthetic breast mound (5,13). According to Hartrampf, risk factors that could complicate the operation were obesity, hypertension, diabetes, cardiovascular disease, chronic heavy smoking, poor motivation on the part of the patient, emotional and psychological problems, and a poorly prepared surgeon (14).

The pTRAM flap procedure had two major disadvantages: morbidity at the donor site and the reduced blood supply of the flap (15,16). This fostered surgeons' research toward more refined techniques.

#### **4.1.3 Free Tissue Transfer**

Free tissue transfer procedures, based on microsurgery principles, were developed in order to improve the blood supply of the flap and limit the harvest of the rectus muscle to reduce abdominal wall morbidity. In 1975, Toyomi Fujino published a case report in which he described for the first time the use of a free tissue transfer for postmastectomy breast reconstruction. To achieve his goal, he used a "microvascular transfer of a large dermal-fat-muscle flap from the buttock of the patient" (17).

In 1979, Holmstrom reported the first free microvascular abdominal flap to reconstruct the breast. The flap was designed on the area between the umbilicus, the pubic region and the anterior superior iliac spine is based on the inferior epigastric vessels on one side only (18).

The free TRAM (fTRAM) flap was introduced by James Grotting and his colleagues. He performed different studies aimed to compare the conventional TRAM flap versus microsurgical fTRAM flap for immediate breast reconstruction (IBR). In the comparison,

the fTRAM flap showed: decreased morbidity at the donor site; improved blood supply of the flap; the better aesthetic result (19). Because of these advantages, the fTRAM flap became the most used method for breast reconstruction for several decades.

In 1983, Anatomic studies showed that the rectus abdominis receives the most amount of blood supply from the deep inferior epigastric artery (DIEA) compared to the superior epigastric artery (20). The DIEA originates from the external iliac artery and once it enters the muscle it takes a variety of branching patterns with an average of five perforators supplying the skin (21). Thanks to these improvements, Allen and Treece developed the deep inferior epigastric perforator (DIEP) flap for breast reconstruction. It included skin and subcutaneous fat with the perforators. Sparing of the rectus abdominus musculature differentiates this procedure from other autogenous modalities such as the pedicled and fTRAM flap (22). The main advantage was a significant reduction of abdominal wall morbidity compared to TRAM flap based procedures. Nevertheless, technical challenges and variable anatomy limited its application (5).

Others free tissue transfer modalities were the superficial inferior epigastric artery perforator (SIEAP) and gluteal flaps. In 1999, Arnez and his team reported the use of SIEAP for breast reconstruction (23). Its use was limited to a small percentage of patients because of the considerable variation in the superficial venous anatomy of the abdominal wall that may have profound implications for success in SIEAP transfer (24).

The first free gluteal flap for postmastectomy breast reconstruction was introduced by Fujuno in 1975 (17).

The superior gluteal artery perforator (SGAP) flap and inferior gluteal artery perforator (IGAP) flap for breast reconstruction were described by Allen and colleagues (25). In his case report, he stated: "We feel that the buttock is a reliable soft tissue source for breast reconstruction. The evolution of surgical technique from the superior gluteal artery perforator to the in-the-crease inferior gluteal artery perforator flap now allows an

aesthetically superior result to be obtained for both the reconstructed breast and the donor site in the vast majority of patients” (25).

#### **4.1.4 Nipple Areola Reconstruction**

Nipple areola reconstruction is the last stage of the breast reconstruction procedure. It is meant to lend a natural appearance of the breast in order to get a better body image.

In 1949, Adams reported a case in which he took the skin of the labium minor as a free composite graft to transplant to a breast to recreate the nipple (26). In 1977, Brent proposed nipple-areolar complex reconstruction with auricular tissues from the contralateral breast (27).

Another way to achieve nipple-areolar reconstruction was nipple tattooing. It was first experimented by Hilton Becker in 1986. He proposed a simple intradermal tattoo for improved nipple-areola color match following breast reconstruction (28). This technique is currently the most recommended.

#### **4.2 Implant-Based Reconstruction**

In 1895, Vincent Czerny, famous plastic surgeon from Heidelberg, published a case in which he reported the story of a 41 years old woman whose breast was removed because of an adenofibroma (29). In order to reconstruct the breast and give it a proper symmetry to the contralateral one, he transplanted a lipoma from the right lumbar region of the patient. This is accredited as the first attempt of breast reconstruction by using an implant.

In 1963, Cronin and Gerow introduced the use of silicone gel breast implant for breast reconstruction (30). After their initial prototype failed, they proposed a second generation of implants under the supervision of Dow Chemical Company.

However, even the new model reported disappointing results. The main complications of these implants were the silicone leakage that led to capsular contracture and painful deformities. Another main concern was the potential of silicone in causing cancer and autoimmune diseases (5). Because of this, the Food and Drug Administration (FDA) banned the use of silicone implants and in the following years, saline-filled implants became the only accepted modality used for breast reconstruction (31).

By the end of the 1990s, the topic regarding the side effects of silicone implants was revisited and several meta-analysis studies showed no correlation between silicone and cancer or connective tissue diseases (32).

After a thorough examination of the data in 2006, the FDA reintroduced the use of silicone-based implants for breast reconstruction (33). The current, fifth-generation implants have a strong, thick and low bleed shell, smooth surface, variable anatomical shape, and tightly cross-linked gel. Safe and natural feeling, they gained wide consent by surgeons and patients.

Another modality used for breast reconstruction is the use of tissue expansion. In 1976 Radovan described the use of tissue expanders for breast reconstruction after mastectomy. He designated a technique that permitted a gradual expansion of the skin to a larger than desirable size by a temporary expander that could be subsequently replaced by a permanent implant (34).

In 1984, Becker criticized Radovan's procedure because it required a second operative procedure in order to remove the expander and replace it with another breast implant. Because of this, he invented a dual-chamber breast implant made by an inner inflatable lumen containing saline and an outer lumen of silicone gel (35). In this technique the reservoir of saline initially permitted the tissue expansion; once deflated, the silicone component remained in position as a definitive implant.



## **5 INDICATIONS FOR BREAST RECONSTRUCTION**

### **5.1 Breast Cancer Surgery**

As already mentioned, mastectomy is a component of the treatment for the early stage breast cancer. There are different options for performing it: simple mastectomy, modified radical mastectomy, radical mastectomy, subcutaneous or "nipple-sparing" mastectomy, skin-sparing mastectomy, and partial mastectomy, also known as lumpectomy or BCS. Women may also request mastectomy as a preventative measure if they carry a mutation of the *BRCA1* or *BRCA2* genes, or if they have a significant family history of breast cancer. In any case, breast reconstruction has become an accessible possibility for those who undergo a mastectomy. It can occur immediately after mastectomy or the patient can schedule it at the desired time (1).

### **5.2 Congenital Anomalies Of The Breast**

Breast reconstruction is also an available option for the treatment of the following congenital conditions of the breast: Poland syndrome, tuberous breast anomaly, pectus excavatum, breast hypoplasia, polymastia, and amastia. The clinical presentation of these diseases varies extensively. It ranges from the absent or hypoplastic pectoralis muscle to the under or overdevelopment of breast tissue. Consequently, reconstructive procedures have to be adjusted to correct the deformity, varying from chest wall balance or augmentation, dynamic muscle transfer, nipple and areola repositioning, and breast augmentation using implants or autologous tissue. The reconstruction should be carried out after puberty when the breast achieves the full development. Augmentation with implants provides a proper symmetry in those patients having rudimental breast tissue on the affected side and a small and non-ptotic contralateral healthy one. Autogenous

reconstruction is used in case the breast is totally missing or to obtain a better symmetry and progressive natural ptosis if the contralateral is present (36).

### **5.3 Acquired Deformities Of The Breast**

Acquired abnormalities of the breast usually have an iatrogenic origin. Acquired amastia may develop as a consequence of an imprudent biopsy of an evolving breast in pubertal age. The excision of part of the breast bud may lead to deformity of the developing breast. Additionally, radiation therapy for hemangioma of the breast or an intrathoracic illness of a prepubertal girl may result in amastia. Reconstructive surgery, in these cases, should be performed after the growth of the normal breast is completed, using the same techniques described above.

Breast deformity may also result from a traumatic injury to the breast. For instance, a severe burn localized to the chest, followed by contracture, can also lead to deformity. Because of this, patients may undergo breast reconstruction surgery to repair the unpleasant aesthetic appearance of the breast (37).

## **6 BREAST RECONSTRUCTION METHODS**

A patient who chooses to receive breast reconstruction must first discuss with a qualified plastic surgeon about several aspects related to the procedure. These include preoperative considerations, time to initiate the surgery and the choice between implant versus autogenous reconstruction.

### **6.1 Preoperative Considerations**

The most common setting to perform breast reconstruction is after mastectomy or BCS as a component of breast cancer surgery. The kind of reconstruction that is going to be planned is reliant on a number of factors including oncologic concerns, patient wishes and expectations, body habitus, and surgical risk factors. Generally, there are no absolute contraindications for candidate patients. On the other hand, the majority of surgeons consider inflammatory breast cancer, requiring massive skin resection that may increase the risk of medical complications, as a relative contraindication (38).

### **6.2 Immediate Versus Delayed Reconstruction**

Reconstruction can be carried out immediately after mastectomy or BCS or it can be postponed accordingly to patient's needs or once adjuvant therapy is completed. Most patients are eligible for IBR because this procedure entails the following advantages: improved aesthetic outcome by preserving the breast shape; minor scar formation and contracture; lastly, because this procedure spares the patient from an additional surgery, it is associated with considerable patient satisfaction and psychological benefit (1,38).

The choice to perform IBR led to the idea that it could delay the start of adjuvant therapy. Systematic studies of the current literature showed that IBR does not necessarily delay the start of adjuvant treatment to a clinically relevant extent (39).

Delayed breast reconstruction (DBR) is performed according to patient's desire and also taking into account a possible postmastectomy radiation therapy (PMRT) that may complicate an IBR by using implants because the risk to cause capsular contracture (40).

### **6.3 Implant Versus Autogenous Reconstruction**

Breast reconstruction can be achieved either by using an implant or by means of the patient's own tissue. Both methods are valid options for patients that are the candidate to undergo reconstruction. The choice between the two procedures comes after the plastic surgeon performs a detailed history and physical examination of the patient. The advantages and disadvantages of each technique are discussed below.

Implant-based breast reconstruction is simpler to accomplish than the autologous one and it is associated with a lower operative morbidity, shorter hospital stay and faster recovery time. Because of these benefits, it became the most used method in the world. A commonly reported disadvantage was implant leakage and subsequent infection. Since their introduction, implants have been progressively ameliorated during the years and currently, the rate of failure is significantly lower. Anyway, implants do not last lifetime; they have a lifespan of approximately ten years, so at some point, they should be replaced (5). Another drawback is that the implants do not feel like natural and because they do not age as the patient becomes older, they may cause contralateral asymmetry.

Capsular contracture is considered the most unpleasant disadvantage of this method. Implants are foreign material introduced in the human body and they are made of a covering fibrous capsule that may elicit an immune response against it. Furthermore, PMRT may also cause capsular contracture. The latter is characterized by capsule thickening and tightening that can be painful and upsetting, and could compromise the aesthetic result of the surgery. It can be quantified using the Baker scale, ranging from

grade I (normal appearing of the breast) to grade IV where the breast is hard, painful and abnormal looking. In order to solve the problem, the patient must obtain the removal and replacement of the implant. A way to prevent capsular contracture is the use of the acellular dermal matrix (ADM) as support to the implant (38,41).

Autologous tissue breast reconstruction involves the transfer of the patient's own tissue to the breast location. The most common donor sites are the back, the abdomen, the gluteal region, and the inner thigh. Autogenous reconstruction is indicated to those patients who desire to avoid implants and are not the good candidate for implant-based reconstruction. For example, a patient that underwent mastectomy and irradiation may have poor skin residual to sustain an implant reconstruction. The advantages of autologous reconstruction are a normal and softer appearance of the breast, maintained symmetry since the transferred tissue ages as the patient age, and the absence of capsular contracture. The main drawbacks are longer hospital stay and recovery time, and significant donor site morbidity (38).

#### **6.4 Implant-Based Reconstruction**

The ideal candidate to undergo implant-based reconstruction is a thin patient, lacking the required subcutaneous fat to perform an autologous reconstruction. This method is also suitable for older patients and those having some medical issue that prevents them to undergo more complex reconstructive surgeries. Moreover, the patient should have a moderate-size breast, with minimal ptosis and definite breast shape. If the breast is too small or very large, implant reconstruction becomes a challenge for the surgeon who, in order to achieve a proper symmetry, must operate the contralateral breast as well (38,42). Severe tissue deficiency following mastectomy or irradiation is considered an absolute contraindication to implant reconstruction. In extreme cases, the surgeon may harvest

additional tissue from a donor site and uses it to cover the underlying implant. Relative contraindications include obesity, smoking and connective tissue diseases (38,42).

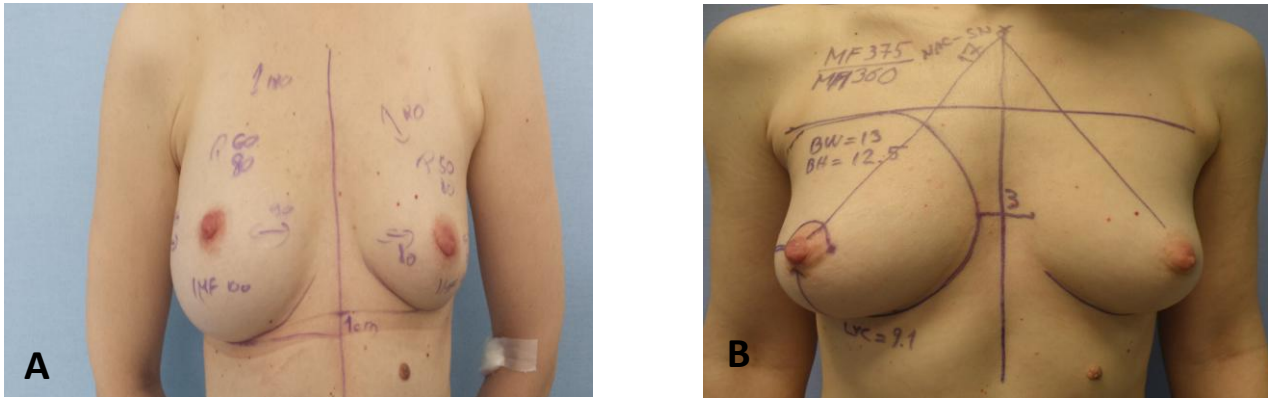
IBR by using implants is preferred over the delayed procedure because it is associated with a rapid reconstructive result and lesser psychological stress. Furthermore, as reported in the literature, immediate implant reconstruction does not increase the incidence of a possible locoregional recurrence of cancer, neither hinders its presence (38,39).

Implant-based reconstruction can be accomplished by two different ways: single-stage reconstruction and two-stage tissue expander-implant reconstruction.

#### **6.4.1 Single-stage reconstruction**

This technique also called direct to implant (DTI) reconstruction is suitable for those healthy and non-smoker patients having sufficient mastectomy skin and small to moderate breast size. The implant is located underneath the pectoralis muscle. Initially, DTI reported pectoralis muscle retraction, implant malposition, and capsular contracture. The invention of ADMs helped the surgeons to solve these problems and thus ADMs are now a component of the current DTI procedures (41,43).

Preoperatively, the surgeons “marks” the patient focusing on the relation of the inframammary fold (IMF) on one side and the contralateral one and also on the lateral borders of the breast (Figure 1). The patient also receives a muscle relaxant to facilitate pectoralis muscle dissection. When the muscle is lifted, the plastic surgeon makes a pocket; the upper part of the pocket is where the implant will be positioned. ADM will be stitched to the chest wall making the lower part of the pocket. The position of the ADM allows the creation of the preferred IMF. Suction drains are installed and a surgical bra is given to the patient to wear before the discharge from the hospital. The patient is followed for weeks until the removal of the drains (43).



**Figure 1 A,B:** Preoperative marking before performing a skin sparing mastectomy. (Courtesy of Department of Plastic-Reconstructive Surgery and Breast Surgery, University Hospital Centre Zagreb, University of Zagreb-School of Medicine, Zagreb).

#### 6.4.2 Two-stage tissue expander-implant reconstruction

This method is the most common implant-based reconstruction that is currently adopted. It is indicated to those patients that present with a poor mastectomy skin inadequate to perform a DTI. Moreover, it is chosen if the patient has to undergo PMRT.

The first stage of the surgery consists in the creation of the subpectoral pocket where the expander is positioned. The device is held in place by using absorbable sutures placed along the inframammary fold. The periprosthetic space is profusely irrigated with an antibiotic solution and the implant is then covered with the pectoralis muscle. Closed suction drains are also inserted (44).

The expander has a valve on its anterior part, readily accessible to perform the postoperative expansion. The latter is usually started 2 weeks after surgery when the mastectomy skin flap and the scars are healed and there is no sign of infection. The expansions are carried out once or twice per week, according to the patient's tolerance. The process may last several months, taking into account the duration of a possible PMRT (42).

The second stage involves the exchange of the expander for the permanent implant. After the removal of the tissue expander, a capsulotomy may be required in order to create better room to allow the proper position of the permanent implant (44).

Patients can choose between saline and silicone gel implants. The former entails a more visible and palpable rippling. In case of leaking, saline solution can be easily absorbed by the body but the implant needs to be replaced anyway. Silicone gel implants are felt more soft and natural than the saline ones. If leaking occurs, silicone is not absorbed and because of this, in the past, silicone implants have been withdrawn by the FDA. Concerns were about the potential risk of causing cancer or autoimmune diseases. In 2006 the ban was reversed and silicone implants are now accepted as safety devices for medical use. Advances in technology led to the introduction of new silicone implants, the so-called "gummy implants" with very low rates of leaking (5,33,38,42).

Implant-based reconstruction is considered a safe procedure with a low rate of complications. The most commonly reported are mastectomy skin flap necrosis, infections, hematoma, seroma, implant leaking and capsular contracture. A very rare complication is the association of implants and anaplastic large cell lymphoma. It may occur several years after the surgery, thus the patients must be informed about this rare complication as well (38,45).

## **6.5 Autologous Tissue Reconstruction**

Autologous breast reconstruction is performed according to patient preference, plastic surgeon's skills and the physical characteristics of the patient. A fundamental requirement is the presence of adequate donor tissue. This method is appropriate for those patients who are not the candidate for an implant reconstruction, like obese women. Indeed, they might have a large ptotic contralateral breast that makes it very hard to match a proper



symmetry by using an implant. In addition, patients who underwent PMRT may lack the necessary skin on the chest wall for an implant reconstruction, therefore the autologous method becomes a valid option for this group of patients. Because tissue reconstruction is associated with a natural feeling of the breast, the absence of capsular contracture and increased patient satisfaction, it is considered the gold standard procedure for aesthetic reconstruction (38,46).

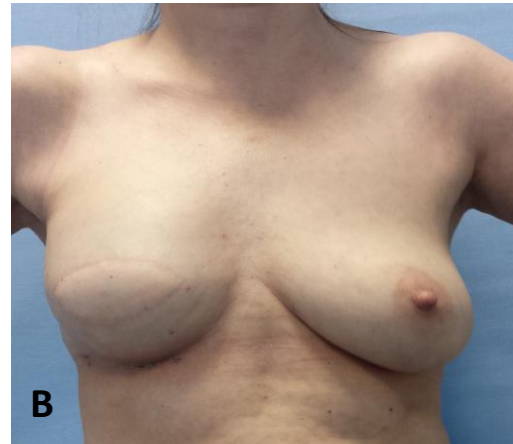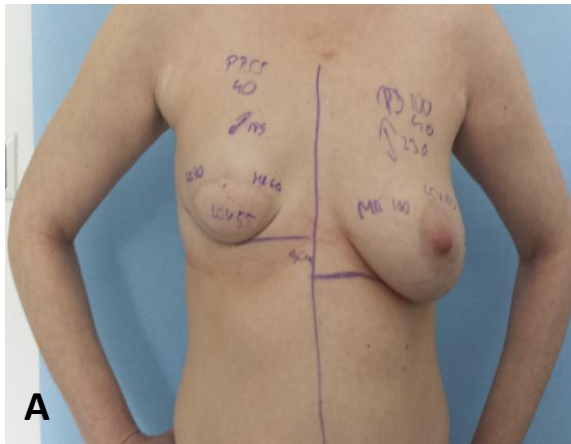
### **6.5.1 Latissimus Dorsi Flap**

Candidate patients for LD myocutaneous flap are those who present with some contraindications for an abdominal flap reconstruction, such as skinny patients, the presence of previous surgery at the anterior abdominal wall and the unavailability of microsurgical techniques. Moreover, patients who desire to become pregnant are more suitable for LD flap reconstruction as well (47).

During the surgery, the LD muscle is incised and the myocutaneous flap is then harvested as thoracodorsal pedicle maintaining the serratus branch and the humeral attachment. The flap is subsequently moved to the chest wall to recreate the breast. Thin patients may benefit from the placement of an implant below the LD flap (Figure 2). The entire tissue is secured to the pectoralis fascia by means of Vicryl sutures (47).

In order to maximize the volume of the reconstructed breast, besides implants, also fat-grafting is carried out with brilliant results (48).

LD flap procedure reported a significant level of satisfaction among patients in terms of natural feeling and symmetry of the breast. Drawbacks of this procedure are the risk of wound rupture, decreased shoulder motion and seroma formation in the donor area. Interestingly, the use of fat-grafting volume augmentation has considerably reduced the occurrence of seroma (47,48).



**Figure 2** LD flap breast immediate-delayed breast reconstruction. **A:** IBR with a LD flap. **B:** Patient has undergone a second operation to place an implant below the LD flap in order to achieve a better symmetry to the contralateral breast. (*Courtesy of Department of Plastic-Reconstructive Surgery and Breast Surgery, University Hospital Centre Zagreb, University of Zagreb-School of Medicine, Zagreb*).

The thoracodorsal artery perforator (TDAP) flap represents as a valid alternative in order to decrease the complications arising from the LD flaps. It entails the harvesting of the same amount of skin and fat as in the LD flap, but the muscle is spared. It showed to significantly reduce the seroma development at the donor area and minimize the shoulder range of motion issue. The most common disadvantages are steatonecrosis and distal tissue necrosis (49).

### 6.5.2 Abdominal Flaps

In 1982, Carl Hartrampf introduced the use of the abdominal flaps for breast reconstruction. He proposed the TRAM flap having a consistent amount of skin, subcutaneous tissue and muscle that remained completely viable during the transfer (13). During the time his technique has been ameliorated leading to a decreased donor site morbidity, natural looking of the breast, and improvement in the blood supply of the tissues. The candidate patient that undergoes to TRAM flap reconstruction should have an

adequate amount of abdominal tissue to create the breast mound and sufficient skin looseness to suture and secure the donor site. Absolute contraindication to this procedure is a history of abdominal surgeries that may compromise the blood circulation of the anterior abdominal wall. This may lead to the risk of necrosis of the harvested flap. Relative contraindications include smoking, PMRT, medical comorbidities and pregnancy planning (38).

The blood supply of the TRAM flap comes from two different sources: the superior epigastric artery and the inferior epigastric artery. Based on this anatomy notions, TRAM flaps exists as pTRAM flap and fTRAM flap, respectively.

In the pTRAM flap method, plastic surgeons identify the flap to be harvested at the level of the lower abdomen. Color Doppler ultrasonography is used perioperatively to ascertain the position of the perforators. During the surgery, skin, subcutaneous tissue and a variable portion of the rectus muscle are tunneled through the chest wall toward the breast site. Postoperatively, the patient is followed at different time intervals to assess the circulation of the flap (49).

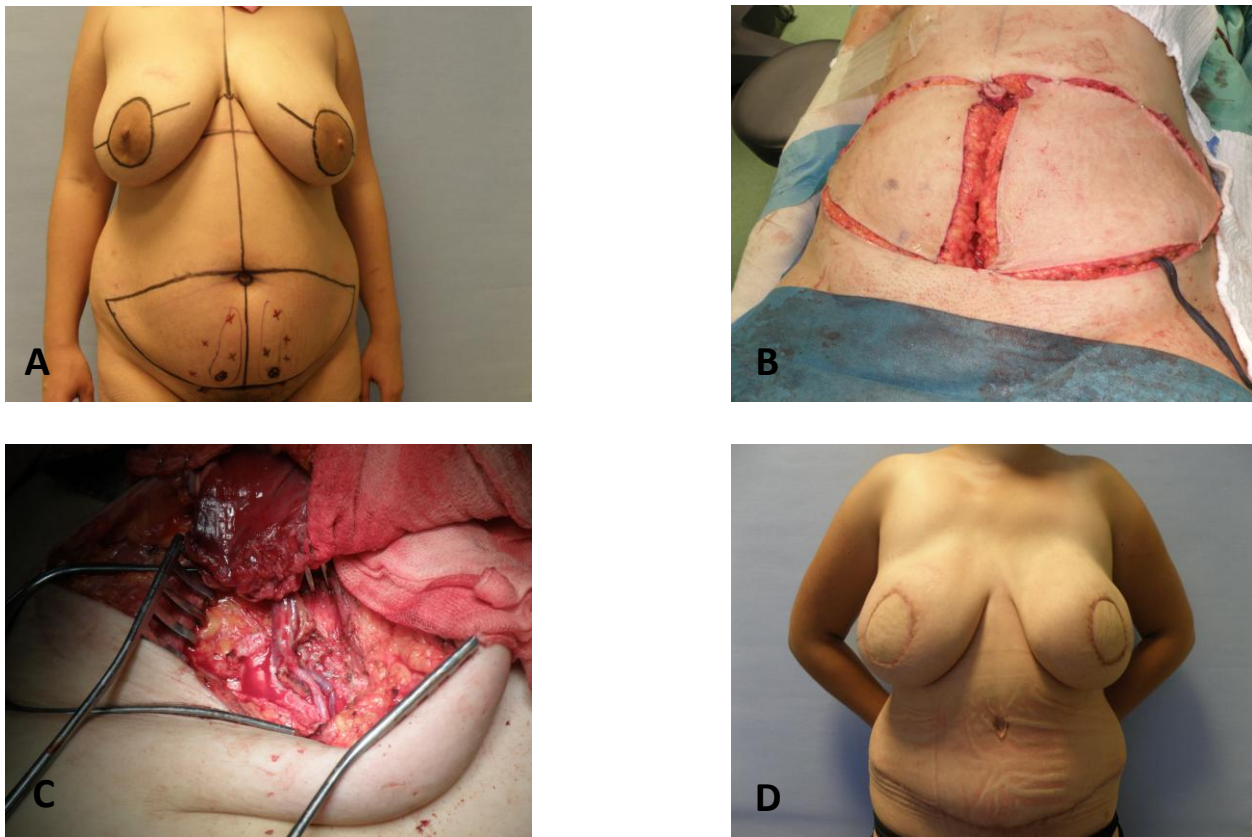
The most commonly reported complications of pTRAM flap reconstruction include: total flap loss, fat necrosis, abdominal hernia, seroma formation and wound infection. One solution adopted to control the complications at the donor site is the use of prolene mesh during the suturing of the abdominal defect (50).

Anatomy studies have been shown that the dominant blood supply to the rectus muscle comes from the inferior epigastric vessels. The need to limit the donor site morbidity and the rate of flap necrosis led to the introduction of the microsurgical flaps, known as fTRAM flap, muscle-sparing free TRAM (MsfTRAM), DIEP and SIEAP flap (51).

The fTRAM flap entails the transfer of the skin, fat and the muscle without the pedicle. The flap is harvested together with the inferior epigastric vessels that are anastomosed at the level of the breast (38,49).

When the surgeon performs a breast reconstruction by using a MsfTRAM, different parts of the rectus muscle can be preserved. These can be the central, the lateral or the medial part, according to the amount of flap that needs to be harvested (51).

The DIEP flap is harvested considering the perforating vessels from the deep inferior epigastric artery and vein. It includes skin and subcutaneous fat with the perforators with a complete sparing of the rectus abdominis muscle and anterior rectus fascia (51) (Figure 3).



**Figure 3** DIEP flap IBR. **A:** Preoperative marking. **B:** Elliptical abdominal incisions to harvest the flap. **C:** Blood vessels anastomosis. **D:** Postoperative result. (Courtesy of Department of Plastic-Reconstructive Surgery and Breast Surgery, University Hospital Centre Zagreb, University of Zagreb-School of Medicine, Zagreb).

The SIEAP flap reported the advantage of causing the lowest morbidity rate to the abdominal wall because the surgeon may completely preserve the abdominal fascia due to the superficial location of the blood vessels belonging to the SIEAP flap. Anyway, because

of the significant different anatomy of the superficial epigastric vessels, this technique is not often used (52).

A common characteristic of the microsurgical-based reconstructed methods is that all adopt as common recipient the internal mammary artery and vein or the thoracodorsal artery and vein. The harvested flap is anastomosed to those recipient vessels by a skilled plastic surgeon, in order to reestablish the circulation (49,51). The blood supply of the flap must be controlled postoperatively to prevent the risk of flap necrosis. The most critical period is the first three days after the operation. The patient must receive a detailed physical examination where capillary refill time, skin color, tissue turgor, temperature and needle pricks are performed to evaluate the color and appearance of eventual bleeding from the flap. Moreover, an objective analysis needs to be carried out as well. This includes Doppler ultrasound or implantable and near-infrared spectroscopy for oxygen saturation (49,53).

Patients can return to perform normal daily activities after six to eight weeks. The most common recommendations include the use of a surgical light bra and an abdominal support during the first weeks (38).

Overall, postreconstructive complications after abdominal flaps can be divided into major and minor complications. The former includes complete flap loss, fat necrosis, and abdominal hernias; the latter consists of wound dehiscence, infection at the donor or recipient site, postoperative hematoma and seroma (50).

As reported by a recent study, patients that underwent breast reconstruction by means of DIEP flap stated a higher general level of satisfaction compared to those who received TRAM flap-based reconstruction. Furthermore, donor site morbidity was higher in TRAM patients while DIEP patients had more flap perfusion-related issues (54).

### **6.5.3 Other Donor Sites**

Breast reconstruction can also be achieved by harvesting tissue from the gluteal region or from the thigh. In the first case, SGAP and IGAP flaps are used to reconstruct the breast mound. In addition, transverse upper gracilis (TUG) flap are collected from the thigh area. Gluteal flaps are indicated for thin patients or those having abdominal scars that preclude any tissue harvesting. SGAP and IGAP flaps are based on the superior and inferior gluteal artery and vein, respectively. Furthermore, they can be carried out as free or pedicled flap. In both cases, only skin and subcutaneous tissue are harvested while the muscle is spared. Preoperatively, the perforators are mapped by Doppler ultrasound. When the flap is positioned at the breast level, its blood vessels are anastomosed with the internal mammary and vein. Gluteal flaps are considered to be a second choice flap for breast reconstruction when a DIEP flap is contraindicated. The most commonly reported complications are gluteal lesions such as seroma, hematoma, infections and possible flap fat necrosis (56,57).

The TUG flap-based breast reconstruction is not routinely performed by plastic surgeons unless a severe abdominoplasty prevents the use of the DIEP flap. TUG flap is based on the medial circumflex artery and it is collected from the inner part of the thigh. The main advantages of the TUG flap are a reduced donor site morbidity and a limited influence on the range of motion of the leg. Possible disadvantages are disturbances in the sensation of the limb and lymphedema (58).

## **6.6 Nipple Areola Reconstruction**

Nipple and areola reconstruction represents the last stage of breast reconstruction. It helps to give a natural look of the breast and to mask the wounds of the surgery. Importantly, it is associated with a profound patient satisfaction.

The reconstruction of the nipple-areolar complex can be performed as outpatient treatment and under local anesthesia. The plastic surgeon must focus on symmetry in position, size, shape, texture, and pigmentation and permanent projection (59).

Nipple reconstruction can occur by different techniques. One of these is the composite nipple graft where part of the contralateral nipple is used to recreate the missing one. The disadvantages of this procedure are donor site morbidity and decreased sensation on the contralateral nipple. Another way is by local flaps, such as the well-known star flap. The latter entails a good cosmetic result but the poor projection of the nipple represents the most experienced disadvantage (59,60).

Flaps with autologous, alloplastic and allograft augmentation are also used. Particularly, the C-V flap technique is one of the most popular and related with a high satisfaction level of the patient. Potential drawbacks are infection, bruising and eventually total or partial nipple loss (59,61).

Areola reconstruction can be performed by means of skin graft or tattooing. Skin grafting of the areola is more invasive than drawing a tattoo but it lends a more natural appearance of the breast. Usually, the graft is taken from darker areas of the body like the inner groin or eventually from an extensive contralateral areola. Donor site complications are rare (38,59).

Tattooing the areola is simpler to carry out and can also be done at the same time with a skin graft. It is sometimes difficult to match the color of the contralateral areola and fading is a common problem. In order to prevent the onset of infections, the use of a sterile needle is mandatory (38,59).

## 7 DISCUSSION

Breast reconstruction represents a key component of the treatment of breast cancer. It is directed to recreate the operated breast following mastectomy or BCS. Moreover, it is an available option for the treatment of other conditions that can affect the breast. These range from congenital anomalies, such as Poland syndrome, tuberous breast anomaly, and pectus excavatum, to acquired abnormalities, which may have an iatrogenic cause or are due to a severe traumatic injury, burns being the most common instance.

Before to perform the surgical reconstruction of the breast, the plastic surgeon and the candidate patient must consider several preoperative features. These include oncologic concerns, patient wishes and expectations, body habitus, and surgical risk factors (38). This is of vital importance because it establishes the timing, the method of reconstruction and quality of the outcome.

Regarding the timing, breast reconstruction can be carried out as IBR or DBR. The former is executed at the time of mastectomy, thus avoiding an additional surgery and it entails considerable patient satisfaction and psychological benefit (1). The latter is performed according to patient's desire or treatment protocol, especially in case PMRT has to take place and it may complicate an IBR (40).

The methods to perform breast reconstruction include the use of implants and autogenous tissue.

The choice between the two procedures comes after the plastic surgeon performs a thorough history and physical examination of the patient. Implant-based reconstruction fits for thin patients having moderate-size breast with minimal ptosis and definite breast shape. It can be done in a single or two stage by using an implant or a tissue expander followed by the implant, respectively. Silicone gel implants are the most preferred because they are felt more soft and natural than the saline ones. Implant-based reconstruction is simple to perform and it is associated with a lower operative morbidity, shorter hospital



stay and faster recovery time. The most common drawbacks are infections, seroma, implant leaking and capsular contracture, the latter being significantly reduced by the use of ADMs (5,38,41).

Autologous tissue reconstruction is suitable for those patients having adequate donor tissue, or obese patients having a large ptotic contralateral breast hard to match by using an implant. Furthermore, patients who underwent PMRT may lack the necessary skin on the chest wall for an implant reconstruction. In general, tissue reconstruction is associated with a natural feeling of the breast, the absence of capsular contracture and increased patient satisfaction. Because of this, it is considered the gold standard procedure for aesthetic reconstruction (38,46).

Autogenous reconstruction entails the use of LD, TDAP, pTRAM, fTRAM, MsfTRAM, DIEP, SIEAP, SGAP, IGAP and TUG flaps. The choice among this wide range of flaps must take into account patient's wishes and doctor's skills. For instance, if the patient is planning to be pregnant the selection of LD flap versus an abdominal one is more appropriate. Microsurgical techniques, like DIEP and MsfTRAM flap-based reconstruction, require a high level of experience and knowledge from the plastic surgeon. Since they spare the muscle at the donor site, they are associated with a decreased donor site morbidity and thus they report a high general level of satisfaction among the patients (54).

Nipple and areola reconstruction is the final stage of the reconstructive surgery of the breast. It gives a natural look to the breast and makes the scars less visible. Additionally, it is associated with a profound patient satisfaction.

## **8 CONCLUSION**

Breast reconstruction has become an essential component of the management of breast cancer. It can also be executed to resolve some congenital and acquired conditions that may affect the breast.

The doctor-patient relationship is fundamental to achieve the best reconstructive outcome. The plastic surgeon should consider patient's health conditions, wishes, body habitus and accomplish a detailed anamnesis and physical examination in order to select the best reconstructive method that is appropriate for the patient.

## **9 ACKNOWLEDGMENTS**

I would like to express my gratitude to Prof. Dr. Sc. Davor Mijatović, MD, Ph.D. and Dr. med. Anto Dujmović for their proficiency, gentleness, and guidance to complete my thesis.

I would like to thank my parents Giacomo and Nicoletta, my sister Federica, my brother Massimiliano, my sister-in-law Antonella, and my little nephew Lorenzo for their continuous support and for believing in me. Thanks also to my flatmates Sanja, Darijo and Lara for their kindness and for the good times we spent together.

In conclusion, I am thankful to all my friends for making my stay in Zagreb such a memorable and unique experience.

## 10 REFERENCES

1. Guyomard V, Leinster S, Wilkinson M. Systematic review of studies of patients' satisfaction with breast reconstruction after mastectomy. *Breast*. 2007 Dec;16(6):547-67. Epub 2007 Nov 19.
2. Torre LA, Bray F, Siegel RL, Ferlay J, Lortet-Tieulent J, Jemal A. Global cancer statistics 2012. *CA Cancer J Clin*. 2015 Mar;65(2):87-108. doi:10.3322/caac.21262 Epub 2015 Feb 4.
3. Rowland JH, Holland JC, Chaglassian T, Kinne D. Psychological response to breast reconstruction. Expectations for and impact on postmastectomy functioning. *Psychosomatics*. 1993 May-Jun;34(3):241-50.
4. Halsted WS. The Results of Operations for the Cure of Cancer of the Breast Performed at the Johns Hopkins Hospital from June, 1889, to January, 1894. *Ann Surg*. 1984 Nov;20(5):497-555. doi: 10.1097/00000658-189407000-00075.
5. Champaneria MC, Wong WW, Hill ME, Gupta SC. The evolution of breast reconstruction: a historical perspective. *World J Surg*. 2012 Apr;36 (4):730-742.
6. Tansini I. Nuovo processo per l'amputazione della mammella per cacre. *Reforma Med*. 1896;12:3.
7. Teimourian B, Adham MN. Louis Ombredanne and the origin of muscle flap use for immediate breast mound reconstruction. *Plast Reconstr Surg*. 1983 Dec;72(6):905-10.
8. Gillies H. Surgical replacement of the breast. *Proc R Soc Med*. 1959 Aug;52:597-602.
9. Holdsworth WG. A method of reconstructing the breast. *Br J Plast Surg*. 1956;9:161-162.
10. Olivari N. The latissimus flap. *Br J Plast Surg*. 1976 Apr;29(2):126-8.

11. Schneider WJ, Hill HL, Brown RG. Latissimus dorsi myocutaneous flap for breast reconstruction. *Br J Plast Surg.* 1977 Oct;30(4):277-81.
12. Mathes SJ, Bostwick J 3<sup>rd</sup>. A rectus abdominis myocutaneous flap to reconstruct abdominal wall defects. *Br J Plast Surg.* 1977 Oct;30(4):282-3.
13. Hartrampf CR, Scheflan M, Black PW. Breast reconstruction with a transverse abdominal island flap. *Plast Reconstr Surg.* 1982 Feb;69(2):216-25.
14. Hartrampf CR Jr. Breast reconstruction with a transverse abdominal island flap. A retrospective evaluation of 335 patients. *Perspect Plast Surg.* 1987;1:123-128.
15. Rietjens M, De Lorenzi F, Andrea M, et al. Technique for minimizing donor-site morbidity after pedicled TRAM-flap breast reconstruction: outcomes by a single surgeon's experience. *Plast Reconstr Surg Glob Open.* 2015 Aug 3;3(8):e476. doi: 10.1097/GOX.0000000000000451. eCollection 2015 Aug.
16. Elliot IF. Options for donor sites for autogenous tissue breast reconstruction. *Clin. Plast. Surg.* 1994;21:177-89.
17. Fujino T, Harashina T, Enomoto K. Primary breast reconstruction after a standard radical mastectomy by a free flap transfer. Case report. *Plast Reconstr Surg.* 1976;58:371-374.
18. Holmstrom H. The free abdominoplasty flap and its use in breast reconstruction. An experimental study and clinical case report. *Scand J Plast Reconstr Surg.* 1979;13(3):423-27.
19. Grotting JC, Urist MM, Maddox WA et al. Conventional TRAM flap versus free microsurgical TRAM flap for immediate breast reconstruction. *Plast Reconstr Surg.* 1989;83:828-841 Discussion 842-844.
20. Scheflan M, Dinner MI. The transverse lower rectus abdominis operation for breast reconstruction. *Plast Reconstr Surg.* 1983;72:819-825.

21. Hamdi M, Rebecca A. The Deep Inferior Epigastric Artery Perforator Flap (DIEAP) in Breast Reconstruction. *Semin Plast Surg.* 2006 May; 20(2):95-102. doi: 10.1055/s-2006-941716.
22. Allen RJ, Treece P. Deep inferior epigastric perforator flap for breast reconstruction. *Ann Plast Surg.* 1994 Jan;32(1):32-8.
23. Arnez ZM, Khan U, Pogorelec D, Planinsek F. Rational selection of flaps from the abdomen in breast reconstruction to reduce donor site morbidity. *Br J Plast Surg.* 1999 Jul;52(5):351-4.
24. Rozen WM, Chubb D, Whitaker IS, et al. The importance of the superficial venous anatomy of the abdominal wall in planning a superficial inferior epigastric artery (SIEA) flap: case report and clinical study. *Microsurgery.* 2011 Sep;31(6):454-7. doi: 10.1002/micr.20896. Epub 2011 Apr 18.
25. Allen RJ, Levine JL, Granzow JW. The in-the-crease inferior gluteal artery perforator flap for breast reconstruction. *Plast Reconstr Surg.* 2006 Aug;118(2):333-9.
26. Adams WM. Labial transplant for correction of loss of the nipple. *Plast Reconstr Surg.* 1949 May;4(3):295-8.
27. Brent B, Bostwick J. Nipple-areola reconstruction with auricular tissues. *Plast Reconstr Surg.* 1977;60:353-361.
28. Becker H. The use of intradermal tattoo to enhance the final result of nipple-areola reconstruction. *Plast Reconstr Surg.* 1986;77:673-676.
29. Czerny V. Plastischer ersatz der brustdruse durch ein lipom. *Zentralbl Chir.* 1895 27:72.
30. Cronin TD, Gerow FJ. Augmentation mammoplasty: a new "natural feel" prosthesis. In: *Transactions of the Third International Congress of Plastic and Reconstructive*

- Surgery. October 13-18, 1963. Amsterdam, Excerpta Medica Foundation, 1963;41-9.
31. Schnur P, Hait P. The History of Plastic Surgery, Arlington Heights, IL. American Society of Plastic Surgeons/ Plastic Surgery Educational Foundation; 2009.
  32. Janowsky EC, Kupper LL, Hulka BS. Meta-analyses of the relation between silicone breast implants and the risk of connective-tissue diseases. *N Engl J Med*. 2000 Mar 16;342(11):781-90.
  33. Cunningham B. The mentor core study on silicone MemoryGel breast implants. *Plast Reconstr Surg*. 2007 Dec;120(7 Suppl 1):19S-29S; discussion 30S-32S.
  34. Radovan C. Breast reconstruction after mastectomy using the temporary expander. *Plast Reconstr Surg*. 1982 Feb;69(2):195-208.
  35. Becker H. Breast reconstruction using an inflatable breast implant with detachable reservoir. *Plast Reconstr Surg*. 1984 Apr;73(4):678-83.
  36. Caouette-Laberge L, Borsuk D. Congenital anomalies of the breast. *Semin Plast Surg*. 2013 Feb; 27(1): 36-41.
  37. Michael P. Osborne, Susan K. Boolbol. Breast anatomy and development. In: Jonathan W Pine Jr, Julie Goolsby, Emilie Moyer. *Diseases of the breast: Fifth edition*. USA , Wolters Kluwer Health Adis (ESP); 2014. p. 3-14.
  38. Babak J. Mehrara, Alice Y Ho. Breast Reconstruction. In: Jonathan W Pine Jr, Julie Goolsby, Emilie Moyer. *Diseases of the breast: Fifth edition*. USA, Wolters Kluwer Health Adis (ESP); 2014. p. 536-552.
  39. Xavier Harmeling J, Kouwenberg CA, Bijlard E, Burger KN, Jager A, Mureau MA. The effect of immediate breast reconstruction on the timing of adjuvant chemotherapy: a systematic review. *Breast cancer research and treatment*. 2015 Sep;153(2):241-51. doi: 10.1007/s10549-015-3539-4. Epub 2015 Aug 19.

40. Otte M, Nestle-Krämling C, Fertsch S, et al. Conservative mastectomies and Immediate-DElayed AutoLogous (IDEAL) breast reconstruction: the DIEP flap. *Gland Surg.* 2016 Feb; 5(1): 24-31. doi: 10.3978/j.issn.2227-684X.2015.05.15.
41. Salzberg CA, Ashikari AY, Berry C, Hunsicker LM. Acellular dermal matrix-assisted direct-to-implant breast reconstruction and capsular contracture: a 13-year experience. *Plast Reconstr Surg.* 2016 Aug;138(2):329-37. doi: 10.1097/PRS.0000000000002331.
42. Mesbahi AN, McCarthy CM, Disa JJ. Breast reconstruction with prosthetic implants. *Cancer J* 2008 Jul-Aug;14(4):230-5. doi: 10.1097/PPO.0b013e31817fb7c3.
43. Colwell AS. Direct-to-implant breast reconstruction. *Gland Surg.* 2012 Nov;1(3):139-41. doi: 10.3978/j.issn.2227-684X.2012.10.04.
44. Nahabedian MY. Implant-based breast reconstruction following conservative mastectomy: one-stage vs. two-stage approach. *Gland Surg* 2016 Feb;5(1):47-54. doi: 10.3978/j.issn.2227-684X.2015.06.08.
45. Clemens MW, Horwitz SM. NCCN Consensus Guidelines for the Diagnosis and Management of Breast Implant-Associated Anaplastic Large Cell Lymphoma. *Aesthet Surg J.* 2017 Mar 1;37(3):285-289. doi: 10.1093/asj/sjw259.
46. Murphy BD, Kerrebijn I, Farhadi J, Masia J, Hofer SOP. Indications and Controversies for Abdominally-Based Complete Autologous Tissue Breast Reconstruction. *Clin Plast Surg.* 2018 Jan;45(1):83-91. doi: 10.1016/j.cps.2017.08.007. Epub 2017 Sep 19.
47. Mushin OP, Myers PL, Langstein HN. Indications and Controversies for Complete and Implant-Enhanced Latissimus Dorsi Breast Reconstructions. *Clin Plast Surg.* 2018 Jan;45(1):75-81 doi: 10.1016/j.cps.2017.08.006. Epub 2017 Sep 23.



48. Zhu L, Mohan AT, Vijayasekaran A, Hou C, Sur YJ, Morsy M, et al. Maximizing the Volume of Latissimus Dorsi Flap in Autologous Breast Reconstruction with Simultaneous Multisite Fat Grafting. *Aesthet Surg J*. 2016 Feb;36(2):169-78 doi: 10.1093/asj/sjv173. Epub 2015 Nov 6.
49. Angrigiani C, Rancati A, Escudero E, Artero G. Extended thoracodorsal artery perforator flap for breast reconstruction. *Gland Surg*. 2015 Dec; 4(6): 519-527. doi: 10.3978/j.issn.2227-684X.2015.04.20.
50. McNally R, Rimler J, Laurence V, Z Paydar K, A Wirth G. Comparative Perfusion Analysis of Free Muscle-Sparing Versus Pedicle Transverse Rectus Abdominis Myocutaneous (TRAM) Flaps in Vivo in the Peri-Operative and Late Post-Operative Periods. *World J Plast Surg*. 2017 May;6(2):144-151.
51. Tan S, Lim J, Yek J, et al. The deep inferior epigastric perforator and pedicled transverse rectus abdominis myocutaneous flap in breast reconstruction: a comparative study. *Arch Plast Surg*. 2013 May; 40(3): 187-191. doi: 10.5999/aps.2013.40.3.187.
52. Butler PD, Wu LC. Abdominal perforator vs. muscle sparing flaps for breast reconstruction. *Gland Surgery*. 2015;4(3):212-221. doi: 10.3978/j.issn.2227-684X.2015.03.08.
53. Rozen WM, Chubb D, Whitaker IS, et al. The importance of the superficial venous anatomy of the abdominal wall in planning a superficial inferior epigastric artery (SIEA) flap: case report and clinical study. *Microsurgery*. 2011 Sep;31(6):454-7. doi: 10.1002/micr.20896. Epub 2011 Apr 18.
54. Lohman RF, Langevin CJ, Bozkurt M, et al. A prospective analysis of free flap monitoring techniques: physical examination, external Doppler, implantable Doppler, and tissue oximetry. *J Reconstr Microsurg*. 2013 Jan;29(1):51-6. doi: 10.1055/s-0032-1326741. Epub 2012 Nov 12.

55. Momoh AO, Colakoglu S, Westvik TS, et al. Analysis of complications and patient satisfaction in pedicled transverse rectus abdominis myocutaneous and deep inferior epigastric perforator flap breast reconstruction. *Ann Plast Surg.* 2012 Jul;69(1):19-23. doi: 10.1097/SAP.0b013e318221b578.
56. Gagnon AR, Blondeel PN. Superior Gluteal Artery Perforator Flap. *Semin in Plast Surg.* 2006 May;20(2):79-88. doi: 10.1055/s-2006-941714.
57. Satake T, Muto M, Ogawa M, et al. Unilateral Breast Reconstruction Using Bilateral Inferior Gluteal Artery Perforator Flaps. *Plast Reconstr Surg Glob Open.* 2015 Mar; 3(3): e314. Published online 2015 Apr 7. doi: 10.1097/GOX.0000000000000287.
58. Buchel EW, Dalke KR, Hayakawa TE. The transverse upper gracilis flap: Efficiencies and design tips. *Can J Plast Surg.* 2013 Autumn; 21(3): 162-166.
59. Nimboriboonporn A, Chuthapisith S. Nipple-areola complex reconstruction. *Gland Surg.* 2014 Feb;3(1):35-42 doi: 10.3978/j.issn.2227-684X.2014.02.06.
60. Alfano C, Tenna S, Caggiati A, et al. Nipple reconstruction by local flaps: a long-term comparative study between star and skate techniques. *Acta Chir Plast.* 2004;46(4):127-31.
61. Jalini L, Lund J, Kurup V. Nipple Reconstruction Using the C-V Flap Technique: Long-Term Outcomes and Patient Satisfaction. *World J Plast Surg.* 2017 Jan;6(1): 68-73.

## **11 BIOGRAPHY**

I was born on 25.04.1986 in Poggiardo, Italy. I have graduated from University of Ferrara, Italy with a master degree in biology in 2012. Successively, I enrolled at the University of Zagreb, School of Medicine. During my studies, I received the Dean's Commendation for distinguished academic success, the best student of Medical Studies in English Program in the academic year 2015/2016. I have also been a member of Faculty of Medicine swimming pool team, football team, and students' surgical association. I participated in the documentary film on HRT1 for the 100<sup>th</sup> Anniversary of Faculty of Medicine of the University of Zagreb in 2017, as a demonstrator of Advanced Life Support-manual defibrillator.

During the summer of 2017, I worked as student teaching assistant at the department of cardiology, oncology, neurology, and pediatrics at the Hospital Cardinale Giovanni Panico in Tricase, Italy.

I will carry out a surgical rotation at the Department of Plastic, Aesthetic and Reconstructive Surgery at the Ospedale Regionale di Lugano, Switzerland in May and June 2018.

I will graduate in July 2018.