

A Case Report of Solitary Extramedullary Plasmacytoma of the Cricoid Cartilage Diagnosed After Total Thyroidectomy

Čunović, Nikolina; Košec, Andro; Stevanović, Siniša; Bedeković, Vladimir

Source / Izvornik: **Ear, Nose & Throat Journal, 2020, 99, 130 - 131**

Journal article, Published version

Rad u časopisu, Objavljena verzija rada (izdavačev PDF)

<https://doi.org/10.1177/0145561319839634>

Permanent link / Trajna poveznica: <https://um.nsk.hr/um:nbn:hr:105:528568>

Rights / Prava: [In copyright](#)

Download date / Datum preuzimanja: **2021-12-02**



Repository / Repozitorij:

[Dr Med - University of Zagreb School of Medicine
Digital Repository](#)



A Case Report of Solitary Extramedullary Plasmacytoma of the Cricoid Cartilage Diagnosed After Total Thyroidectomy

Nikolina Čunović, MD¹, Andro Košec, MD, PhD, FEBORL-HNS¹, Siniša Stevanović, MD, PhD¹, and Vladimir Bedeković, MD, PhD²

Ear, Nose & Throat Journal
2020, Vol. 99(2) 130–131
© The Author(s) 2019
Article reuse guidelines:
sagepub.com/journals-permissions
DOI: 10.1177/0145561319839634
journals.sagepub.com/home/ear
SAGE

Laryngology ENT Clinic Case

The patient is a 68-year-old man who was admitted to a tertiary referral center for an elective total thyroidectomy after being diagnosed with thyroid papillary carcinoma. A total thyroidectomy and selective neck dissection of region VI was performed, and the early postoperative period was uneventful. Serum calcium levels were normal after the surgery. On the fourth postoperative day, the patient developed hoarseness, dyspnea, and a mild inspiratory stridor. Fiberoptic laryngoscopy revealed full vocal fold mobility and a normal appearance of mucosal surfaces. However, a subglottic submucosal mass was observed, causing significant airway stenosis (Figure 1). After parenteral administration of 120 mg of methylprednisolone, dyspnea and inspiratory stridor were relieved; intubation and tracheotomy were avoided. A computed tomography (CT) scan showed a mass in the cricoid cartilage measuring 2.4 cm in its craniocaudal diameter and 1.6 cm in its anteroposterior diameter. Destruction of cartilage was apparent, with edema causing airway stenosis reducing the airway (Figure 2). Ultrasound-guided core biopsy revealed an extramedullary plasmacytoma of the cricoid cartilage. Serum protein analysis and immunohistological tissue staining showed κ -immunoglobulin light-chain restriction, abundant monoclonal infiltrate of plasma cells with eccentrically situated nuclei alongside nuclear polymorphisms (Figure 3, Hematoxyline Eosine $\times 200$). Skeletal radiograph and total body scintigraphy did not reveal bone lesions. Subsequent evaluation for multiple myeloma, including bone marrow biopsy, was negative. There were no signs of hypercalcemia, renal failure, or anemia. The patient was treated with radiotherapy (total dose of 40 Gy), and significant local improvement with complete lesion regression was noted with 12 months of follow-up.

Discussion

Tumors of plasma cells can present as a single lesion (solitary plasmacytoma) or as multiple lesions (multiple myeloma). Solitary plasmacytoma may be divided into 2 groups: solitary bone plasmacytoma and extramedullary plasmacytoma. Extramedullary plasmacytomas have been reported to involve the larynx in 6% to 18% of head and neck cases, most commonly affecting the

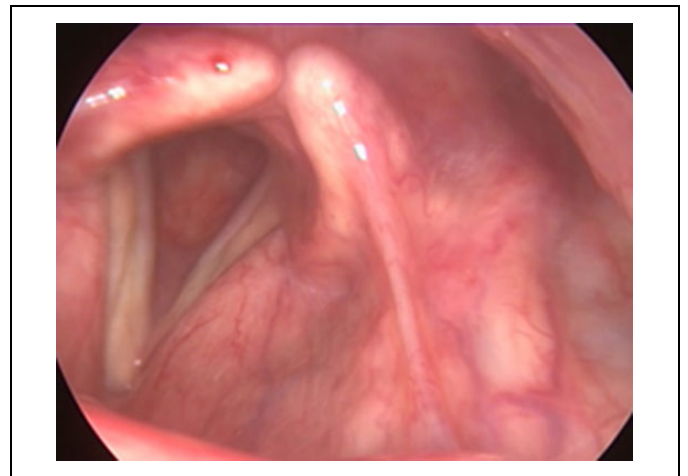


Figure 1. A submucosal mass situated in the subglottic area, with edema and significant airway stenosis.

epiglottis and the ventricle of Morgagni, followed in by the true vocal folds, the false vocal folds, the aryepiglottic folds, the arytenoids, and the subglottis.^{1,2} Only 4 cases have been described occurring in the cricoid cartilage to date.³⁻⁷ The median age of patients is 60 years, and 75% of patients are men.³ Approximately one-third of them disseminate to multiple myeloma within 2 years from presentation. Extramedullary plasmacytomas represent less than 1% of head and neck malignancies making diagnosis difficult. Symptoms with tumors affecting the cricoid include hoarseness, stridor, dyspnea, hemoptysis, and dysphagia, depending on tumor size and position at

¹ Department of Otorhinolaryngology and Head and Neck Surgery, University Hospital Center Sestre Milosrdnice, Zagreb, Croatia

² School of Medicine, University of Zagreb, Zagreb, Croatia

Received: February 26, 2019; revised: March 02, 2019; accepted: March 04, 2019

Corresponding Author:

Andro Košec, MD, PhD, FEBORL-HNS, Department of Otorhinolaryngology and Head and Neck Surgery, Clinical Hospital Center Sestre Milosrdnice, Vinogradska cesta 29, Zagreb, Croatia.

Email: andro.kosec@yahoo.com

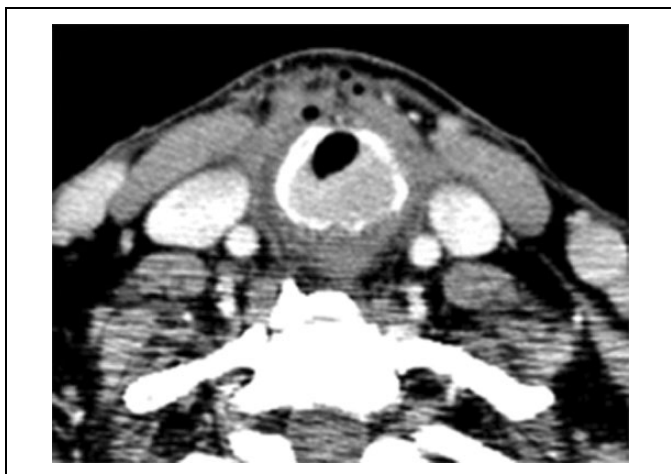

Figure 2. Computed tomography (CT) scan showed a cricoid cartilage mass 2.4×1.6 cm with destruction of cartilage, causing significant airway stenosis.

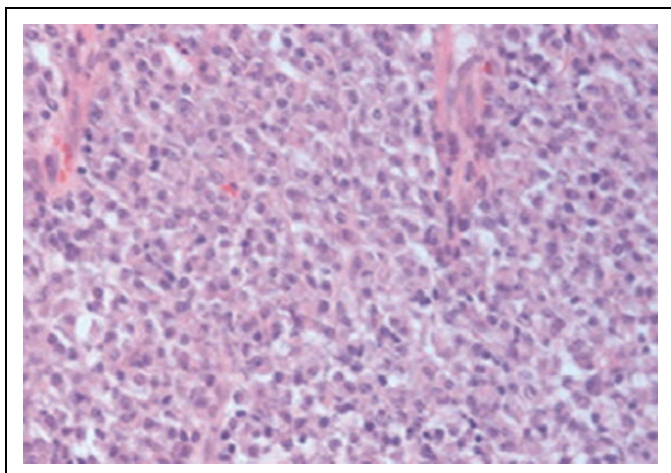


Figure 3. Histological staining showed abundant monoclonal infiltrate of plasma cells with eccentrically situated nuclei alongside nuclear polymorphisms (Hematoxyline Eosine $\times 200$).

presentation.⁴⁻⁸ Submucosal growth leads to early preservation of superficial mucosa (with late ulceration), which may cause the mass to go unnoticed during initial laryngoscopy.⁶ The differential diagnosis of these lesions includes chondromas, chondrosarcomas, squamous cell carcinomas, adenoid cystic carcinomas, pleomorphic adenomas, and cavernous hemangiomas. Solitary extramedullary plasmacytomas of the head and neck carry a more favorable prognosis than other forms of the disease, with an overall 5-year survival rate of 31% to 82%, depending on progression to multiple myeloma.⁵ Currently advocated imaging methods for exclusion of multiple myeloma include whole-body low-dose CT, magnetic resonance imaging, and positron emission tomography/computed tomography with fluoro-2-deoxy-D-glucose imaging.⁵ The etiology of the disease is unknown, with Epstein-Barr virus and chronic inhalatory irritation proposed as possible causes. In contrast to multiple myeloma, no specific chromosomal abnormalities have been isolated.⁵

This case report presents a rare entity. Moreover, the site of presentation and the time of presentation following thyroid surgery further complicated diagnostics and treatment. Head and neck extramedullary plasmacytomas are well managed by local therapy, either surgery or irradiation with a minimum dose of 40 Gy, followed by a 50% to 80% survival rate after 10 years.⁸ Surgery is preferred in patients with large tumors and extensive local tissue destruction.⁹ Prolonged follow-up is required due to the tendency of extramedullary plasmacytomas to disseminate to multiple myeloma.

Authors' Note

This case presentation was approved by the University Hospital Centre Sestre Milosrdnice, Zagreb, Bioethical Board adhering to the Helsinki Declaration of 1983. Full written informed consent was obtained from the patient in using images of tissue samples and radiologic imaging after discussing the details of the case report contents. All of the authors have read and approved the manuscript, and all authorship contributions have been verified to adhere to ICMJE guidelines.

Declaration of Conflicting Interests

The author(s) declared no potential conflicts of interest with respect to the research, authorship, and/or publication of this article.

Funding

The author(s) received no financial support for the research, authorship, and/or publication of this article.

References

1. Wax MK, Yun KJ, Omar RA: Extramedullary plasmacytoma of the head and neck. *Otolaryngol Head Neck Surg.* 1993;109(5): 877-885.
2. Wein OW, Topf P, Sham RL. Subglottic plasmocytoma: a case report and review of the literature. *Am J Otolaryngol.* 2002; 23(2):112-118.
3. Dimopoulos MA, Kiamouris C, Mouloupoulos LA. Solitary plasmacytoma of bone and extramedullary plasmacytoma. *Hematol Oncol Clin North Am.* 1999;13(6):1249-1257.
4. Wang M, DU J, Zou J, Liu S. Extramedullary plasmacytoma of the cricoid cartilage progressing to multiple myeloma: a case report. *Oncol Lett.* 2015;9(4):1764-1766.
5. Krebs S, Ganly I, Ghossein R, Yang J, Yahalom J, Schöder H. Solitary extramedullary plasmacytoma of the cricoid cartilage-case report. *Front Oncol.* 2017;7:284.
6. Pichi B, Terenzi V, Covello R, Spriano G. Cricoid-based extramedullary plasmocytoma. *J Craniofac Surg.* 2011;22(6):2361-2363.
7. Haser GC, Su HK, Pitman MJ, Khorsandi AS. Extramedullary plasmacytoma of the cricoid cartilage with solitary plasmacytoma of the rib. *Am J Otolaryngol.* 2015;36(4):598-600.
8. Lewis K, Thomas R, Grace R, Moffat C, Manjaly G, Howlett DC. Extramedullary plasmocytomas of the larynx and parapharyngeal space: imaging and pathologic features. *Ear Nose Throat J.* 2007; 86(9):567-569.
9. Creach KM, Foote RL, Neben-Wittich MA, Kyle RA. Radiotherapy for extramedullary plasmocytoma of the head and neck. *Int J Radiat Oncol Biol Phys.* 2009;73(3):789-794.