

Coombs-positive refractory acquired thrombotic thrombocytopenic purpura in a patient with chronic myelomonocytic leukemia successfully treated with rituximab

Krečak, Ivan; Medić Grgić, Marijana; Gverić-Krečak, Velka; Rončević, Pavle; Bašić Kinda, Sandra; Babel, Jakska; Radonić, Radovan

Source / Izvornik: *Acta Clinica Belgica*, 2020, 75, 357 - 361

Journal article, Accepted version

Rad u časopisu, Završna verzija rukopisa prihvaćena za objavljivanje (postprint)

<https://doi.org/10.1080/17843286.2019.1608395>

Permanent link / Trajna poveznica: <https://um.nsk.hr/um:nbn:hr:105:253954>

Rights / Prava: [In copyright](#) / [Zaštićeno autorskim pravom](#).

Download date / Datum preuzimanja: **2024-07-29**



Repository / Repozitorij:

[Dr Med - University of Zagreb School of Medicine Digital Repository](#)



Coombs positive refractory acquired thrombotic thrombocytopenic purpura in a patient with chronic myelomonocytic leukemia successfully treated with rituximab

Authors: Ivan Krecak^{1*}, Marijana Grgic Medic², Velka Gveric–Krecak¹, Pavle Roncevic³, Sandra Basic - Kinda³, Jaksa Babel², Radovan Radonic^{2,4}

¹Department of Internal Medicine, General Hospital of Sibenik - Knin County, Sibenik, Croatia

²Intensive Care Unit, Department of Internal Medicine, University Hospital Centre Zagreb, Zagreb, Croatia

³Division of Hematology, Department of Internal Medicine, University Hospital Centre Zagreb, Zagreb, Croatia

⁴School of Medicine, University of Zagreb, Zagreb, Croatia

***Corresponding author:** Ivan Krecak, MD

Address: Department of Internal Medicine, General Hospital of Sibenik – Knin County, Stjepana Radica 83, 22000 Sibenik, Croatia; telephone number +38522641432, e – mail: krecak.ivan@gmail.com

Running title: Acquired TTP in CMML treated with rituximab

Case report

Abstract: Acquired thrombotic thrombocytopenic purpura (aTTP) is a rare autoimmune disorder characterized by auto-antibodies to Willebrand factor (vWF) cleaving enzyme (ADAMTS13), resulting in unusually large vWF multimers that lead to platelet aggregation, microthrombi formation and microangiopathic hemolytic anemia. Hemolysis in aTTP is mechanical, thus direct antiglobulin test (Coombs test) is usually negative. Multiple autoimmune conditions and various auto-antibodies have been described in the context of chronic myelomonocytic leukemia (CMML). In this paper, we describe a first case of CMML with auto-antibodies to ADAMTS13, presenting initially as plasmapheresis refractory Coombs positive aTTP, which we successfully treated with rituximab.

Keywords: Thrombotic thrombocytopenic purpura; Chronic myelomonocytic leukemia; Rituximab

Conflict of interest: The authors report no conflict of interest.

Funding: None.

Ethics: The patient presented in this paper signed the informed consent for this publication. General Hospital of Sibenik-Knin County does not require ethical approval for reporting individual cases or case series.

Introduction: Chronic myelomonocytic leukemia (CMML) is a clonal hematopoietic stem cell disorder with overlapping features of myelodysplastic and myeloproliferative neoplasms. CMML is characterized by the presence of sustained (> 3 months) peripheral blood monocytosis ($\geq 1 \times 10^9/L$; monocytes 10% of white blood cell count) along with dysplastic features in the bone marrow (BM) [1,2]. Approximately 30% of CMML patients can present with antecedent or concomitant autoimmune diseases and poorly defined systemic inflammatory syndromes [3-7].

The term thrombotic microangiopathy (TMA) describes an etiologically very heterogeneous group of diseases, which in the presence of endothelial damage can lead to thrombosis of small and micro vessels, both arterial and venous. TMA's are usually characterized by fever, microangiopathic hemolytic anemia, thrombocytopenia, renal failure and neurological manifestations. Acquired thrombotic thrombocytopenic purpura (aTTP) is a rare life-threatening autoimmune syndrome characterized by microangiopathic hemolytic anemia and thrombocytopenia. aTTP is usually caused by auto-antibodies to Willebrand factor (vWF) cleaving enzyme (ADAMTS13), resulting in unusually large vWF multimers that lead to platelet aggregation and subsequent thrombocytopenia and microthrombi. Hemolysis in aTTP is mechanical and non-immune mediated, thus direct antiglobulin test (Coombs test) is usually negative. First-line therapy is plasma exchange (PEX) and corticosteroids [8]. In recent years, rituximab (RTX) has been increasingly used in refractory cases [9-11]. In this paper, we present a case of CMML with auto-antibodies to ADAMTS13, presenting initially as PEX refractory Coombs positive aTTP, which we successfully treated with RTX.

Case presentation: A 53-year-old Caucasian woman was admitted to hospital due to fever and confusion. She had fever for two days and became confused and agitated on the day of admission. She was not recently exposed to any known drug that could cause aTTP, such as quinine, chemotherapeutic agents or cyclosporin. The body temperature was 38°C on admission and her blood pressure was 130/80 mmHg. Physical examination revealed small ecchymoses on her legs. There was no focal neurological deficit. No lymphadenopathy was noticed. Her spleen was palpable 3 cm below the left costal margin. Meningeal signs were negative. Key laboratory findings included: platelet count 13 (normal range 100–400x10⁹/L); hemoglobin 99 (normal range 120–150 g/L); leukocyte count 9.3x10⁹/L (myelocytes 9%; metamyelocytes 10%; granulocytes 42%; lymphocytes 15%; monocytes 24%); reticulocytes 1.5% (normal range 0.5–1.5%); lactate dehydrogenase (LDH) 455 (normal range 100–235 IU/L); total bilirubin 22 (normal range 3–20 µmol/L); and direct bilirubin 6 (normal range 0.24–7.1 µmol/L); C-reactive protein 37.7 (normal range 0-5 mg/L); prothrombin time 0.95 (normal > 0.7 sec); acquired partial thromboplastin time 23.6 (normal 22 – 33 sec); fibrinogen 4.1 (normal 1.8 – 4.0 g/L). Peripheral blood smear revealed increased number (33%) of „atypical“ monocytes but no fragmented red blood cells (schistocytes). Direct Coombs test was positive for IgG, but not for C3d. Electrocardiogram and X-ray were normal. A computed tomography (CT) scan of the brain, neck, thorax, abdomen and pelvis showed mild splenomegaly (15 cm) and no lymphadenopathy. Magnetic resonance imaging of the brain was unremarkable.

Differential diagnosis included acute monocytic leukemia with central nervous system (CNS) involvement, meningoencephalitis, Evans syndrome (ES), immune thrombocytopenia (ITP), systemic lupus (SLE) with catastrophic antiphospholipid syndrome and sepsis. Lumbar puncture at admission revealed no pleocytosis and the potential diagnosis of CNS leukemia was dismissed. She was started on intravenous aciclovir, ceftriaxone and vancomycin. Given the evidence of immune-mediated hemolysis with thrombocytopenia, methylprednisolone (125

mg/day) and intravenous immunoglobulins (IVIg's) (40 g/day) were started. The next day patient drastically improved; she was conscious, lucid but still severely thrombocytopenic ($13 \times 10^9/L$) and anemic (Hgb 80 g/L). Bilirubin was normal (17.5 $\mu\text{mol/L}$) and LDH was elevated (513 IU/L). Reticulocytes were slightly elevated (3%). Again, there was no schistocytes in the peripheral blood smear. Blood cultures and spinal fluid were sterile. Due to quick clinical recovery and the absence of pleocytosis in the spinal fluid, the diagnosis of meningoencephalitis was excluded, so antiviral and antimicrobial therapy was omitted. Serologic testing for human immuno-deficiency virus, cytomegalovirus, hepatitis B and C virus, and Epstein-Barr virus was all negative. Rheumatoid factor, antinuclear and anti-double stranded DNA antibodies were also negative. Lupus anticoagulans was absent. Anticardiolipin and anti-beta2 glycoprotein antibodies were in the reference range. Testing for auto-antibodies to platelet glycoproteins IIb/IIIa and Ib/IX/V returned negative. BM smear was hypercellular with granulocytic hyperplasia and dysplasia. There were 40% monocytes in the bone marrow and there was no myeloblasts or lymphoblasts. Chromosome analysis revealed normal karyotype (46, XX) with no Philadelphia-chromosome. JAK2-V617F mutation was negative. A diagnosis of possible CMML with ES was made. Therapy with methylprednisolone and IVIg's was continued.

On the third day patient presented abruptly with confusion, right-sided hemiplegia and motor aphasia. Peripheral blood smear revealed 2% schistocytes.

A suspicion of thrombotic microangiopathy (TMA) was made. She was placed on therapeutic PEX (1.5x plasma volume exchange per day) and corticosteroids were continued. Further workup revealed she had 0% of ADAMTS13 enzyme activity and auto-antibodies to ADAMTS13 were present in high titer. After two days of PEX, patient clinically deteriorated and lost consciousness. CT scan of the brain was again unremarkable. The electroencephalogram (EEG) was focally abnormal. She was diagnosed with nonconvulsive

epileptic status and received continuous intravenous infusion of levatiracetam. She regained consciousness the next day. In the next three days her right-sided hemiplegia and motor aphasia slowly recovered. However, after seven days of continuous PEX her platelets were $77 \text{ (x10}^9\text{/L)}$ and LDH 400 (IU/L). She was considered refractory to treatment so RTX was administered (375 mg/m^2 weekly for four doses). Daily PEX and corticosteroids were continued. Complete remission [8] was achieved after four cycles of RTX and 27 PEX procedures. Monocytosis remained stable during the treatment (Figure 1.). In good health she was dismissed from the hospital. Six months later, her ADAMTS13 activity was $< 10\%$. However, blood cell recovery was sustained; platelet counts were continuously $> 150 \text{ (x10}^9\text{/L)}$ and hemoglobin levels $> 120 \text{ (g/L)}$. Coombs retesting was negative. Monocytosis was still prominent, but stable; leukocyte counts were in the range of $6\text{-}12 \text{ (x10}^9\text{/L)}$, with 32-56% of monocytes. A substantial increase in spleen length was noticed (10 cm below the left costal margin). Flow cytometry showed increased ($>94\%$) fraction of CD14+/CD16- monocytes in the peripheral blood [12]. A definite diagnosis of CMML was made according to WHO 2016 criteria [1]. Bone marrow reexamination did not show signs of transformation to acute leukemia. Allogeneic bone marrow transplantation from a HLA-matched unrelated donor is being considered. The patient is currently under pre-transplant evaluation.

Discussion: Retrospective studies suggest that the prevalence of autoimmune disorders, which can be diagnosed concomitantly or shortly before or after CMML, is increased. The most common autoimmune disorders reported are vasculitis, psoriasis, pyoderma gangrenosum, rheumatoid arthritis and immune thrombocytopenia [3-7]. Various autoimmune antibodies (rheumatoid factor, anti-nuclear antibodies, anti-cyclic citrullinate peptide and antineutrophil cytoplasmic antibodies) can appear in up to 30% of CMML patients [3]. However, it is still unknown if the chronic inflammatory state is the ground for CMML or CMML predisposes to immune dysregulation [13]. To the best of our knowledge, this is the first paper to describe a

case of CMML with auto-antibodies to ADAMTS13, presenting initially as PEX refractory aTTP.

Acute episodes of aTTP are associated with severe ADAMTS13 deficiency, commonly defined as <10%. Serum auto-antibodies to ADAMTS13 are present in the majority of aTTP patients. These auto-antibodies cause profound loss of VWF-cleaving function with subsequent platelet aggregation, microthrombi formation and microangiopathic hemolytic anemia. We found only one report, which described a case of relapsing aTTP in a CMML patient, that highlighted the possible connection between these two disorders [14]. However, in that case plasmatic ADAMTS13 activity was normal. As hypothesized by the authors, CMML is often accompanied by vasculitis that causes direct damage to endothelium which could also cause a rapid and substantial increase in vWF in the circulation beyond the clearing capacity of ADAMTS13. This endothelial damage has been described to cause TMA, especially in patients with advanced cancer. In these patients, treatment of the underlying cause should be the first-line therapy, as the efficacy of PEX is arguable [15]. Interestingly, although the ADAMTS13 levels were normal in that case, PEX and corticosteroids were effective. Possibly, some other auto-antibodies or cytotoxins against endothelial cells might have caused TMA, with a good clinical response to PEX. On the other hand, low plasmatic ADAMTS13 activity and the presence of auto-antibodies to ADAMTS13, as found in our CMML patient, indicate a different underlying pathophysiological process and clearly demonstrate the autoimmune nature of aTTP. aTTP has high morbidity and mortality up to 90% if left untreated. PEX plus corticosteroids as standard therapy reduces the mortality of aTTP to approximately 10–15%. PEX provides new source of ADAMTS13 and corticosteroids are used to target the autoimmune component of the disease. However, the recurrence rate of aTTP is 50–60% by standard treatment. In case of PEX-refractory aTTP, current guidelines advise to add RTX [8,16]. RTX rapidly depletes circulating B lymphocytes, resulting in a reduction of the auto-antibodies. In several studies,

RTX has been shown to reduce the volume of PEX for acute procedures and to reduce the recurrence rate [9-11]. In our case, aTTP was refractory to first-line treatment with PEX and corticosteroids but was eventually successfully treated with RTX. Interestingly, CMML is by definition a myelodysplastic/myeloproliferative neoplasm, however, due to the autoimmune nature of aTTP, targeting the B cells with RTX in our patient has proven to be effective. Although our patient was not treated for CMML, a complete remission of her refractory aTTP was achieved with RTX. Extended follow up of our patient will provide further information regarding the duration of response in this clinical context.

aTTP associated with a positive direct Coombs test is also a rare entity. Very few cases of aTTP with a positive Coombs test have been reported and most of them were associated with SLE [17]. A false-positive direct Coombs test is also possible with drugs such as penicillin, cephalosporins, methyldopa and after blood transfusion but our patient had received none of them. ES is also an uncommon disorder caused by auto-antibodies directed against self red blood cells (RBC) and platelets. The pathophysiology of disease involves phagocytosis of auto-antibody-coated RBCs and platelets in the spleen and complement-mediated hemolysis. Positive direct Coombs test is considered to be the hallmark of the disease. Mild splenomegaly is a frequent finding. ES can be idiopathic or secondary, due to lymphoproliferative, rheumatic, and chronic inflammatory disorders (i.e. SLE) [18]. Workup for all this disorders in our case returned negative.

Interestingly, although severe thrombocytopenia was present at the time of diagnosis, no schistocytes were found in the blood smear. This observation might have several explanations. As our patient was Coombs positive, an immune-mediated mechanism could also be responsible for severe thrombocytopenia at disease presentation. ITP has been recognized as a frequent complication in CMML [4-7]. As many as 60% to 70% of patients with ITP have platelet-specific immunoglobulin G antibodies. These antibodies are generally directed at the

most abundant platelet surface glycoproteins, GPIIb/IIIa and GP1b/IX/V. In our case, auto-antibodies against these platelet glycoproteins returned negative. However, a large number of patients with ITP do not have antiplatelet antibodies. In these patients abnormal T cells can result in platelet destruction. These cells accumulate in the bone marrow and are able to directly lyse platelets and impair their production. In addition, evidence suggests that platelet production is impaired in many ITP patients. The megakaryocytes of patients with ITP are not normal, show abnormal apoptosis and impaired megakaryocyte growth [19,20]. As CMML is a hematological neoplasm with a strong inflammatory milieu and a diseased bone marrow, it is possible that severe thrombocytopenia at disease presentation was partly mediated through similar mechanism. On the other hand, absent plasmatic ADAMTS13 activity, along with the presence of auto-antibodies to ADAMTS13, confirmed the diagnosis of aTTP. We hypothesize that bone marrow dysplasia, impaired hematopoiesis and abnormal T cell activation in concert with microthrombi formation and subsequent platelet sequestration, could have been responsible for severe thrombocytopenia at initial disease presentation. In addition, appearance of schistocytes in TMA can occasionally be delayed for several days, and current recommendations advise that screening for schistocytes should be repeated daily [21].

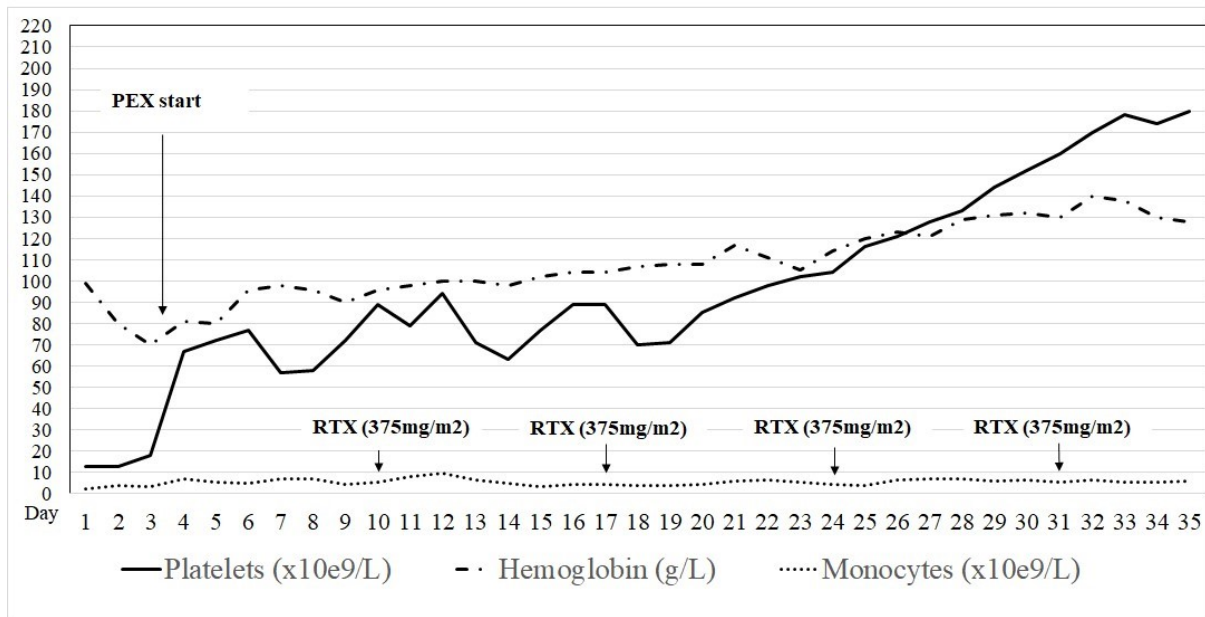
Although aTTP often involves fever, thrombocytopenia, Coombs-negative microangiopathic hemolytic anemia, neurological symptoms and renal insufficiency, many patients do not exhibit the full pentad of findings [8]. Our patient at admission had fever, confusion, mild splenomegaly, Coombs-positive anemia and thrombocytopenia. As there were no schistocytes in the peripheral blood smear she was treated for possible meningoencephalitis and ES. A positive Coombs test in this clinical context was misleading and might further indicate dysregulated systemic inflammatory response in CMML with overproduction of auto-antibodies.

Clinical behavior of CMML can be heterogeneous, with some patients having an indolent form of the disease, whereas others experience an aggressive course with decreased survival. About 30-40% of CMML patients eventually transform to acute leukemia. In the inflammatory CMML setting, first-line treatment consists mostly of steroids, with about 85% of responses. Hypomethylating agents, which have immunomodulatory functions, have been shown to be efficient and decrease steroid amounts and steroid dependence [2,5,22,23]. It is still unclear how auto-immune manifestations impact CMML overall survival and the only curative option still remains allogeneic stem cell transplantation. In our patient, an immune-mediated life-threatening disease complication was present at the time of CMML diagnosis, and the risk of aTTP recurrence still exists, as underlying CMML is present. Monocytosis showed indolent behaviour during the follow-up, however, a substantial increase in spleen length was noticed. Furthermore, ADAMTS13 activity remained low ($< 10\%$) after the treatment with PEX and RTX. Although there are uncertainties surrounding the measurement of ADAMTS13 activity during remission, including how often should it be monitored, and the level of ADAMTS13 activity that would prompt the use of preemptive rituximab or another immune suppressive agent, decreased ADAMTS13 activity after PEX and RTX treatment has been recognized as a risk factor for aTTP relapse [24]. To address this issue, an allogeneic bone marrow transplantation from a HLA-matched unrelated donor is being considered.

In conclusion, we propose that aTTP should be in the differential diagnosis of CMML patients with thrombocytopenia and anemia (Coombs positive or not) who develop signs of TMA. Blood smear screening for schistocytes should be repeated daily, as the appearance of schistocytes can occasionally be delayed for several days. Although confirming severely decreased ADAMTS13 activity and the presence of ADAMTS13 auto-antibodies helps establish the aTTP diagnosis, plasma exchange should be started empirically, even before test

results are available. Further studies are much needed to decipher the immune-mediated processes in CMML.

Figure 1. Hemoglobin level, platelet and monocyte count dynamics during the treatment. Plasmapheresis (PEX) was administered daily. Rituximab (RTX) was delivered in four weekly doses ($375\text{mg}/\text{m}^2$). Complete remission was achieved after four cycles of RTX and 27 PEX procedures. Monocytosis remained stable during the treatment.



References:

1. Arber DA, Orazi A, Hasserjian R, et al. The 2016 revision to the World Health Organization classification of myeloid neoplasms and acute leukemia. *Blood*. 2016;127(20):2391–2405.
2. Patnaik MM, Tefferi A. Chronic myelomonocytic leukemia: 2018 update on diagnosis, risk stratification and management. *Am J Hematol*. 2018;93(6):824-840.
3. Swedeh A, Patnaik M, Alfakara D, et al. Autoimmunity in Patients (pts) with Chronic Myelomonocytic Leukemia (CMML): A Frequent Finding. *Blood* 2012;120:4930.
4. Peker D, Padron D, Horna P, et al. A Close Association of History of Autoimmunity with Chronic Myelomonocytic Leukemia (CMML) in Contrast to Chronic Myelogenous Leukemia (CML). *Blood* 2012;120:1712.
5. Peker D, Padron E, Bennett JM, et al. A close association of autoimmune-mediated processes and autoimmune disorders with chronic myelomonocytic leukemia: observation from a single institution. *Acta Haematol*. 2015;133(2):249-256.
6. Grignano E, Mekinian A, Braun T, et al. Autoimmune and inflammatory diseases associated with chronic myelomonocytic leukemia: A series of 26 cases and literature review. *Leuk Res*. 2016;47:136-141.
7. Zahid MF, Barraco D, Lasho TL, et al. Spectrum of autoimmune diseases and systemic inflammatory syndromes in patients with chronic myelomonocytic leukemia. *Leuk Lymphoma*. 2017;58(6):1488-1493.
8. Joly BS, Coppo P, Veyradier A. Thrombotic thrombocytopenic purpura. *Blood*. 2017;129(21):2836-2846.
9. Jasti S, Coyle T, Gentile T, et al. Rituximab as an adjunct to plasma exchange in TTP: a report of 12 cases and review of literature. *J Clin Apher*. 2008;23(5):151-156.

10. Ling HT, Field JJ, Blinder MA. Sustained response with rituximab in patients with thrombotic thrombocytopenic purpura: a report of 13 cases and review of the literature. *Am J Hematol.* 2009;84(7):418-421.
11. Page EE, Kremer Hovinga JA, Terrell DR, et al. Rituximab reduces risk for relapse in patients with thrombotic thrombocytopenic purpura. *Blood.* 2016; 127(24):3092-309.
12. Selimoglu-Buet D, Wagner-Ballon O, Saada V, et al. Characteristic repartition of monocyte subsets as a diagnostic signature of chronic myelomonocytic leukemia. *Blood.* 2015;125(23): 3618–3626.
13. Elbæk MV, Sørensen AL, Hasselbalch HC. Chronic inflammation and autoimmunity as risk factors for the development of chronic myelomonocytic leukemia? *Leuk Lymphoma.* 2016;57(8):1793-9.
14. Cai Y, Teng R, Lin Z, et al. Chronic myelomonocytic leukemia presenting as relapsing thrombotic thrombocytopenic purpura. *Aging Clin Exp Res.* 2013;25(3):349-350.
15. Lechner K, Obermeier HL. Cancer-related microangiopathic hemolytic anemia: clinical and laboratory features in 168 reported cases. *Medicine (Baltimore).* 2012;91(4):195-205.
16. Scully M, Hunt BJ, Benjamin S, et al. Guidelines on the diagnosis and management of thrombotic thrombocytopenic purpura and other thrombotic microangiopathies. *Br J Haematol.* 2012;158(3):323-335.
17. Aleem A, Al-Sugair . Thrombotic thrombocytopenic purpura associated with systemic lupus erythematosus. *Acta Haematol.* 2006;115(1-2):68-73.
18. Michel M, Chanet V, Dechartres A, et al. The spectrum of Evans syndrome in adults: new insight into the disease based on the analysis of 68 cases. *Blood* 2009;114:3167-3172.
19. Lambert MP, Gernsheimer TB. Clinical updates in adult immune thrombocytopenia. *Blood.* 2017;25;129(21):2829-2835.

20. Audia S, Mahévas M, Samson M, Godeau B, Bonnotte B. Pathogenesis of immune thrombocytopenia. *Autoimmun Rev.* 2017;16(6):620-632
21. Zini G, d'Onofrio G, Briggs C, et al. ICSH recommendations for identification, diagnostic value, and quantitation of schistocytes. *Int J Lab Hematol.* 2012;34(2):107-116.
22. Solary E, Itzykson R. How I treat chronic myelomonocytic leukemia. *Blood.* 2017;13;130(2):126-136.
23. Fraison JB, Mekinian A, Grignano E, et al. Efficacy of Azacitidine in autoimmune and inflammatory disorders associated with myelodysplastic syndromes and chronic myelomonocytic leukemia. *Leuk Res.* 2016;43:13-17.
24. Masias C, Cataland SR. The role of ADAMTS13 testing in the diagnosis and management of thrombotic microangiopathies and thrombosis. *Blood.* 2018;132(9):903-910.