

# Overlap of the Pitt-Hopkins and Lennox-Gastaut syndromes

---

Šulentić, Vlatko; Petelin Gadže, Željka; Đapić Ivančić, Biljana; Mrak, Goran; Borovečki, Fran

Source / Izvornik: *Acta Neurologica Belgica*, 2020, 120, 399 - 401

Journal article, Accepted version

Rad u časopisu, Završna verzija rukopisa prihvaćena za objavljivanje (postprint)

<https://doi.org/10.1007/s13760-018-1045-2>

Permanent link / Trajna poveznica: <https://urn.nsk.hr/urn:nbn:hr:105:331982>

Rights / Prava: [In copyright](#) / [Zaštićeno autorskim pravom](#).

Download date / Datum preuzimanja: **2024-07-16**



Repository / Repozitorij:

[Dr Med - University of Zagreb School of Medicine  
Digital Repository](#)



## OVERLAP OF THE PITT – HOPKINS AND LENNOX-GASTAUT SYNDROMES

Vlatko Sulentic, Zeljka Petelin Gadze, Biljana Dapic Ivancic<sup>1</sup>, Goran Mrak<sup>2</sup>, Fran Borovecki<sup>3</sup>

Department of Neurology, University Hospital Centre Zagreb, School of Medicine, University of Zagreb, Referral Centre of the Ministry of Health of the Republic of Croatia for Epilepsy, Kispaticева 12, 10000 Zagreb, Croatia

<sup>1</sup>Division for Neurology, General Hospital Zadar, B. Pericica 5, 23 000 Zadar, Croatia

<sup>2</sup> Department of Neurosurgery, University Hospital Centre Zagreb, School of Medicine, University of Zagreb, Kispaticева 12, 10000 Zagreb, Croatia

<sup>3</sup> Department for Functional Genomics, Centre for Translational and Clinical Sciences, School of Medicine, University of Zagreb, Salata 3, 10 000 Zagreb, Croatia; Department of Neurology, University Hospital Centre Zagreb, School of Medicine, University of Zagreb, Kispaticева 12, 10000 Zagreb, Croatia

### Introduction:

Pitt-Hopkins syndrome (PTHS) is a condition characterized by intellectual disability and developmental delay, breathing problems, recurrent seizures and distinctive facial features. Other features may include constipation, microcephaly, myopia, strabismus, short stature, and minor brain abnormalities. Affected individuals may also have small hands and feet, a single crease across the palms of the hands, flat feet (pes planus), or unusually fleshy pads at the tips of the fingers and toes. (1,2). It is thought to be a very rare condition, with approximately 500 affected reported individuals worldwide. PTHS is an autosomal dominant disorder caused by mutations in the TCF4 gene. This gene encodes a protein that binds to specific regions of DNA to help control the activity of many other genes. The TCF4 protein plays a role in cell differentiation and maturation, as well as apoptosis (1,2). Considering the fact that this is a rare genetic disorder, differentiation from other diseases with psychomotor disability and epilepsy represents a diagnostic challenge. Given a small number of cases, this brings up the question about the type, frequency and treatment of epileptic seizures in this syndrome.

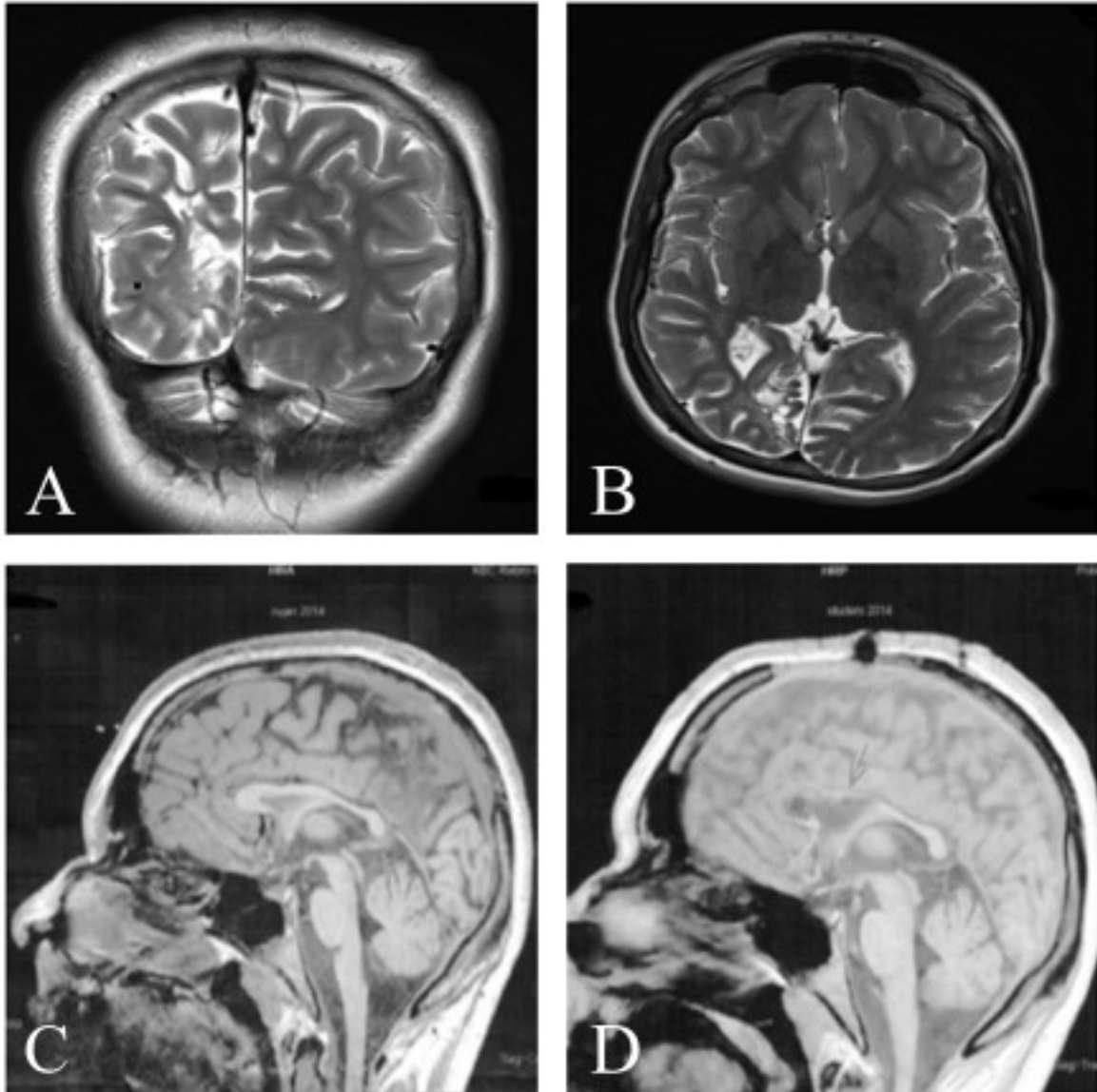
### Case report:

We present a patient at the age of 24, with the history of epileptic seizures (generalised tonic, atypical absence, atonic and generalised myoclonic seizures) from the age of 4. Early psychomotor development was accompanied by milder speech disturbances, but since the fourth year of his life, when epileptic seizures have occurred, a marked psychomotor impairment has begun. Epileptic seizures showed to be pharmaco-resistant and during time, under neuropediatrician and later under neurological supervision, patient changed various of antiepileptic drugs in different combinations phenobarbital, valproic acid, ethosuximide, carbamazepine, lamotrigine, vigabatrin, levetiracetam, clonazepam, rufinamide, oxcarbazepine as well as ketogenic diet. Magnetic resonance imaging (MRI) of the brain showed post-ischemic porencephalic changes in the morphology of right occipital cortex (Figure1. A, B). Electroencephalography (EEG) revealed slow spike-and-wave complexes with diffusely slowed background activity, characteristic for Lennox-Gastaut syndrome (LGS) (Figure2). Considering semiology of epileptic seizures, psychomotor impairment, and

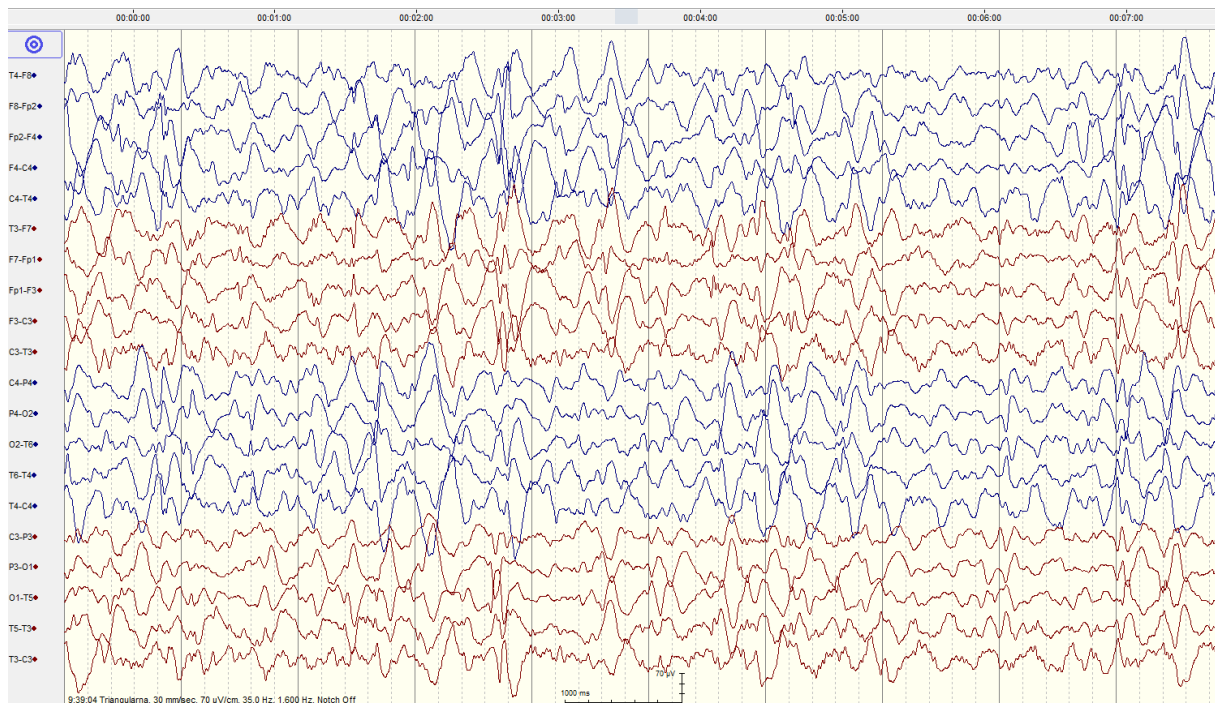
changes described on the brain MRI, patient was diagnosed with Lennox Gastaut syndrome. From early childhood patient has also had distinctive facial features (microcephaly, facial dysmorphism, epicanthus, orbital hypertelorism, concave dorsum of the nose, poorly shaped helix and antehelix), feet equinovarus deformity and scoliosis. Due to pharmacoresistant epilepsy vagal nerve stimulator (VNS) was implanted in 2009, and because of end of battery life reimplanted in 2017 (end of battery life). In the meantime, because of predominance of atonic seizures, in 2014 anterior two-third corpus callosotomy was also performed (Figure 1. C, D). Following neurosurgical treatments as well as continuous combined antiepileptic therapy (levetiracetam, clonazepam, oxcarbazepine, valproic acid), the ratio of epileptic seizures was decreased (primary atonic seizures, as well as generalised tonic seizures). In 2016 next-generation sequencing analysis involving 142 genes related to epilepsy was performed which revealed a heterozygotic missense variant in the TCF4 gene, a mutation previously linked to Pitt – Hopkins syndrome.

### **Discussion and conclusion:**

There are not enough case reports in literature about type and frequency of epileptic seizures in patients with diagnosed PTHS. It is considered that most common are generalised tonic seizures and absence seizures as well as focal epileptic seizures. Seizures are described as hard to control and EEG has no specific pattern characteristic for this syndrome even though there are case reports that describe patients without epilepsy (1,3). According to the most recent American Academy of Neurology and Child Neurology Society practice guidelines, routine cytogenetic testing is recommended in the evaluation of a child with global developmental delay that is nonprogressive with pharmacoresistant epilepsy and lacks a clear etiology (4). The pharmacoresistant epilepsy in this case report is probably the result of overlap with LGS. Genetic testing in patients with diagnosed LGS can discover possible etiology of the disorder. However, they may indicate the existence of overlap with other genetic syndromes, as can be seen in this case report. Genetic analysis is also essential for the differential diagnosis of Pitt Hopkins syndrome from some other genetic disorders such as Angelman syndrome, Rett syndrome and Marfan syndrome. It is also important to mention that genetic testing in patients with epilepsy reduced the percentage of so called idiopathic epilepsy (3,4). The palliative neurosurgical methods performed in this case report (VNS and corpus callosotomy) have led to a reduction of epileptic seizures, confirming their efficacy primarily on a particular type of epileptic seizures, unrelated to the etiology of epilepsy and even in the case of genetic disorders. Reading through available literature, this is the only described case report where patient with diagnosed PTHS was treated with palliative neurosurgical methods. Certainly, more case reports are necessary to confirm the possible benefits of palliative neurosurgical methods in patients with pharmacoresistant epilepsy and genetically-conditioned syndromes. However, in certain cases with diagnosed LCS we need to ask ourselves is this really typical LGS, or we need to search for overlap with some other possible rare genetic syndromes, that can be proven by genetic testing. Considering the importance of counselling and further therapeutic algorithm, genetic counselling should be performed early in the course of the disease.



**Figure 1.** Brain MRI 3T (April, 2014) shows post-ischemic porencephalic changes in the morphology of right occipital cortex: A) Coronal T2 - weighted image, B) Transverse T2 - weighted image. C) Brain MRI (Sagittal T1 sequence) before corpus callosotomy (September 2014.), D) Brain MRI (Sagittal T1 image) after corpus callosotomy (November 2014.).



**Figure 2.** EEG showing slow spike-and-wave complexes with diffusely slowed background activity.

**Acknowledgements:** Authors are very grateful to Prof. Sanja Hajnšek, M.D., Ph.D., for her help in treating patients presented in this paper, as well as to our other colleagues Sibila Nankovic M.D., Andreja Bujan Kovač M.D., Prof. Milan Rados M.D., Ph.D, Kristina Gotovac Ph.D, Natasa Pejanovic Skobic M.D.

**Declarations of interest:** The authors declare that they have no conflict of interest.

**Ethical approval:** This article does not contain research including human participants or animals performed by any of the authors.

**Informed consent:** Informed consent was obtained from the patient included in the study.

## References:

- [1] Marangi G, Zollino MJ. Pitt-Hopkins Syndrome and Differential Diagnosis: A Molecular and Clinical Challenge. *J Pediatr Genet* 2015;4(3):168-76. doi: 10.1055/s-0035-1564570.
- [2] Goodspeed K, Newsom C, Morris MA, Powell C, Evans P, Golla S. Pitt-Hopkins Syndrome: A Review of Current Literature, Clinical Approach, and 23-Patient Case Series. *J Child Neurol* 2018;33(3):233-44. doi: 10.1177/0883073817750490.
- [3] Inati A, Abbas HA, Korjian S, Daaboul Y, Harajely M, Saab R. A case of Pitt-Hopkins syndrome with absence of hyperventilation. *J Child Neurol* 2013;28(12):1698-701. doi: 10.1177/0883073812468054.
- [4] Asadi-Pooya AA. Lennox-Gastaut syndrome: a comprehensive review. *Neurol Sci* 2018;39(3):403-14. doi: 10.1007/s10072-017-3188-y.