

# Emergent Rescue Extracranial-Intracranial Bypass for Acute Carotid Stent Thrombosis Report

---

Toljan, Karlo; Jovanović, Ivan; Nemir, Jakob; Ozretić, David; Poljaković, Zdravka; Stambolija, Vasilije; Mrak, Goran

Source / Izvornik: **World Neurosurgery, 2019, 129, 242 - 244**

Journal article, Accepted version

Rad u časopisu, Završna verzija rukopisa prihvaćena za objavljivanje (postprint)

<https://doi.org/10.1016/j.wneu.2019.06.052>

Permanent link / Trajna poveznica: <https://urn.nsk.hr/urn:nbn:hr:105:505876>

Rights / Prava: [In copyright](#)/[Zaštićeno autorskim pravom.](#)

Download date / Datum preuzimanja: **2025-03-11**



Repository / Repozitorij:

[Dr Med - University of Zagreb School of Medicine  
Digital Repository](#)



Title: Emergent rescue extracranial-intracranial bypass for acute carotid stent thrombosis– case report

## Abstract

Background: Acute stent thrombosis is a rare adverse event following endovascular treatment of carotid artery. Experience on the topic is scarce making the therapeutic approach a clinical challenge. In cases of intraprocedural acute carotid stent thrombosis, thromboaspiration, thrombectomy, and thrombolysis have been used as successful modalities for achieving recanalization.

Case presentation: We describe a case of carotid artery dissection treated endovascularly and complicated by intraprocedural stent thrombosis which was ultimately managed by emergent extracranial-intracranial bypass with radial artery graft connecting the external carotid artery to ipsilateral middle cerebral artery.

Conclusions: Neurosurgical management may represent a rescue option for otherwise unmanageable acute carotid stent thrombosis.

Keywords: Carotid Artery Thrombosis; Extracranial-Intracranial Arterial Bypass; Internal Carotid Artery Dissection; Stent.

## Introduction

Acute carotid stent thrombosis is a rare event following carotid artery stenting (CAS) procedures, with 14 reports describing it as an intraprocedural complication.<sup>1-3</sup> Risk factors include vessel injury such as dissection, embolic protection device thrombosis, and hypercoagulability. In a review summarizing 26 acute carotid stent thrombosis cases, an algorithm for managing those

occurring intraprocedurally suggests thrombectomy, thromboaspiration, or thrombolysis.<sup>2</sup> This case report demonstrates how neurosurgical management could be considered as another valid modality, especially in cases of failed endovascular treatment.

## Case Report

A 47 y/o male patient reported to the hospital emergency with symptoms of progressive motor dysphasia that had started two days prior. Initial head multi-slice computerized tomography (MSCT) scan showed a hypodense left superior frontal brain area implying subacute ischemia. The patient's history was notable for occipital headache with neck pain and for smoking 30-40 cigarettes daily. Other than dysphasia, his neurologic exam was unremarkable (National Institutes of Health Stroke Scale - NIHSS 2), and he was admitted to a standard neurology ward and given 300 mg aspirin loading dose which was continued thereafter. On the third day of hospitalization he acutely developed right-sided hemiparesis and worsening dysphasia (NIHSS 12). An urgent MSCT angiography demonstrated left internal carotid artery (ICA) occlusion. He was immediately prepared for a digital subtraction angiography (DSA) and CAS. Platelet reactivity for aspirin checked with VerifyNow Aspirin Test showed him to be in therapeutic range and he received 180 mg ticagrelor preprocedurally.

The DSA showed tapering of the left internal carotid artery distal to carotid bulb with "flame" shaped occlusion that was typical for ICA dissection (Figure 1A). Supraclinoid segment of left ICA was reconstituted dominantly by retrograde flow in the ophthalmic artery. A microcatheter (Prowler Select +) was advanced past the occlusion to the flow-preserved supraclinoid segment and 4 stents (Enterprise) reaching the level of carotid bulb were placed (Figure 1C). Control angiography runs showed antegrade flow through narrowed ophthalmic and cavernous segments. Imaging of the right common carotid artery (CCA) showed partial arterial crossflow through

anterior communicating artery (ACoA) with left anterior (ACA) and left medial cerebral artery (MCA) filling. Left vertebral artery (VA) catheterization demonstrated pial collaterals from posterior cerebral artery filling parts of left ACA and left MCA vascular territories. A delayed control angiographic run of left CCA demonstrated left ICA occlusion (Figure 1D). Balloon angioplasty of the previously stenosed ophthalmic segment was unsuccessfully attempted, flow was not restored, and a forming thrombus in left ICA bulb was noted. Aspiration of thrombus was partial and the procedure was ended with the occlusion still present. Prompt neurosurgical consult indicated an immediate extracranial-intracranial (EC-IC) bypass operation.

During preoperative assessment, it was decided to bypass the occlusion with right radial artery (RA) graft. The RA was uneventfully harvested and the left CCA bifurcation exposed, while left Sylvian fissure dissection followed ipsilateral frontal osteoplastic craniotomy. After preparing the RA graft with the distension technique using heparin solution, termino-lateral anastomoses of the distal graft end to left MCA M2 frontal segment and the proximal graft end to left external carotid artery (ECA) were done respectively. Indocyanine green fluorescent angiography and micro-Doppler sonography demonstrated adequate bypass patency. Time from decision to bypass completion was 6 hours. The operation was ended in a routine manner without any direct postoperative complications. Next day DSA demonstrated distal third bypass narrowing indicating moderate vasospasm, but without flow delay (Figure 1E). Left MCA M1 segment was still noted to receive ACoA crossflow. The patient received symptomatic supportive care at the neurosurgical intensive care unit including daily 300 mg aspirin and anti-Xa activity-monitored enoxaparin, while ticagrelor was not continued. He exhibited minimal neurological recovery and intermittently required endotracheal intubation. On the 9<sup>th</sup> postoperative day, a control DSA demonstrated

complete vasospasm resolution and an increase in bypass flow which now dominantly filled the left MCA M1 segment (Figure 1F).

The patient was transferred from the neuroanesthesiological to neurological ward on the 17<sup>th</sup> postoperative day. He was stuporous, with head and eye deviation to the right, severe motor dysphasia, right hand hemiplegia, right leg hemiparesis, and responding to pain with eye opening (NIHSS 12, modified Rankin Score - mRS 5). A brain magnetic resonance imaging (MRI) scan with Time-of-Flight (TOF) angiography on the 22<sup>nd</sup> postoperative day showed bypass patency with left ICA occlusion. It also showed areas of late subacute ischemia frontotemporally in the left hemisphere corresponding to MCA vascular territory, including the semioval center and callosal genu and body. With a mild improvement in neurocognitive status, he was discharged to acute rehabilitation facility on the 29<sup>th</sup> postoperative day. At 90 days, some improvement was noted, but motor dysphasia and right sided hemiparesis were present (mRS 4). The patient was able to understand commands, sit up with assistance, and perform activities with the unaffected hand.

## Discussion

There are reports of successful early EC-IC bypass, utilizing low-flow vessels exclusively, in cases of acute stroke where patients were ineligible for or due to failed endovascular treatment, as first-line approach.<sup>4</sup> Large studies on neurosurgical treatment of symptomatic stenocclusive cerebrovascular diseases including the extra- and intracranial ICA have not shown the expected benefit and the indications remain narrow.<sup>5</sup> It seems patient selection remains a salient step determining outcomes. In cases of emergent EC-IC bypass, a preoperative perfusion/diffusion mismatch (PDM) MRI has been shown to aid in ascertaining proper indication.<sup>4</sup>

The experience on EC-IC bypass in cases of acute carotid stent thrombosis is practically non-existent. For such a specific and rare adverse effect, every report on the topic provides valuable insight for clinical practice. The etiology of intraprocedural stent thrombosis in the presented case may pertain to dissection as the initial mechanism of vessel occlusion. An early hyporesponse to loading dose ticagrelor could also be considered, though a 24 h-post loading dose ticagrelor laboratory aggregometry with 5 $\mu$ mol adenosine-diphosphate indicated 49% inhibition despite the fact the drug was taken at that one time only. The primary limitation of this case report is that a preoperative PDM MRI was not done, which hinders determining the operation effectiveness regarding salvaging brain tissue. Beyond relying solely on the patient's clinical status, cerebral hemodynamics was successfully re-established per repeated DSA.

#### Conclusion

This report represents the first application of an EC-IC bypass, using the RA graft connecting ECA to MCA, as a rescue method in case of acute carotid stent thrombosis.

Acknowledgements: None.

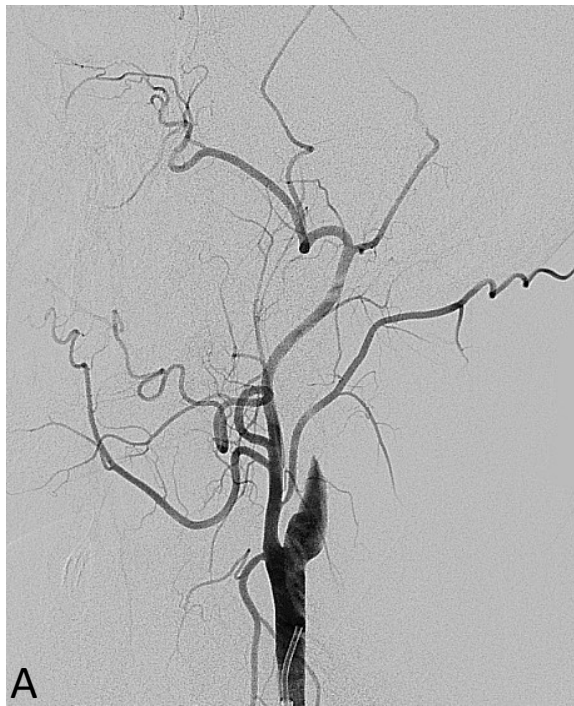#### References

1. Sorkin GC, Dumont TM, Mokin M, et al. Hyperacute Carotid Stent Thrombosis During Emergent Revascularization Treated with Intraarterial Eptifibatide After Systemic Administration of Recombinant Tissue Plasminogen Activator. *J Vasc Interv Neurol*. 2015;8(3):50-55. <http://www.ncbi.nlm.nih.gov/pubmed/26301032>.
2. Moulakakis KG, Mylonas SN, Lazaris A, et al. Acute Carotid Stent Thrombosis: A Comprehensive Review. *Vasc Endovascular Surg*. 2016;50(7):511-521. doi:10.1177/1538574416665986

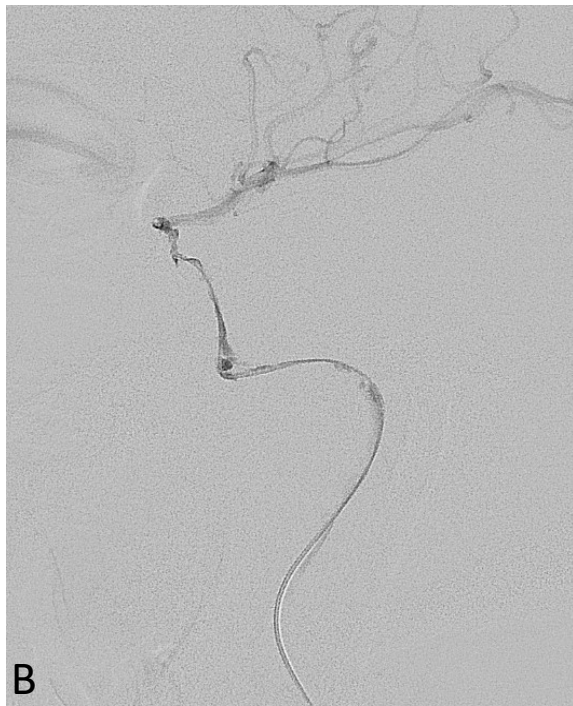3. Hu W, Wang L, Wang G. Acute In-Stent Thrombosis after Carotid Angioplasty and Stenting : A Case Report and Literature Review. *Interv Neurol.* 2018;7:265-270.  
doi:10.1159/000486247
4. Burkhardt JK, Winklhofer S, Fierstra J, et al. Emergency Extracranial-Intracranial Bypass to Revascularize Salvageable Brain Tissue in Acute Ischemic Stroke Patients. *World Neurosurg.* 2018;109:e476-e485. doi:10.1016/j.wneu.2017.10.005
5. Reynolds MR, Derdeyn CP, Grubb RL, Powers WJ, Zipfel GJ. Extracranial-intracranial bypass for ischemic cerebrovascular disease: what have we learned from the Carotid Occlusion Surgery Study? *Neurosurg Focus.* 2014;36(1):E9.  
doi:10.3171/2013.10.FOCUS13427

## Figures

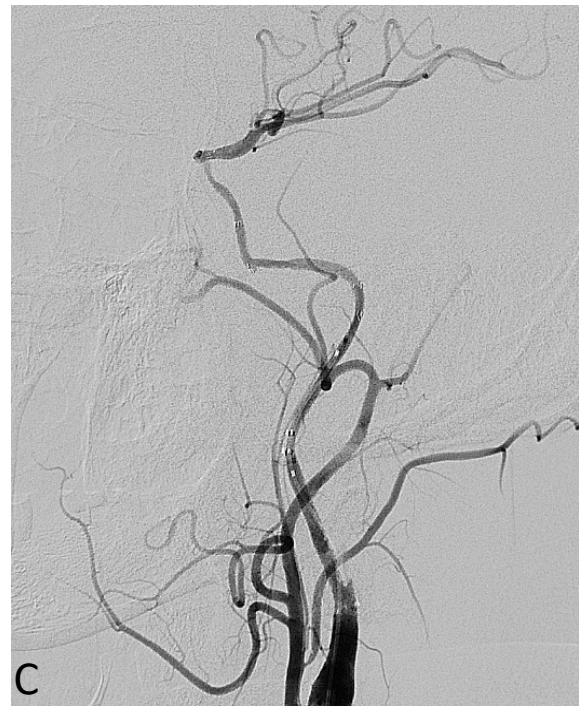Figure 1. A, DSA showed „flame” shaped occlusion of the left ICA, typical for carotid artery dissection. B, Angiography run through a microcatheter placed in the supraclinoid segment of the left ICA confirmed catheter location in the true lumen and showed no signs of emboli in left MCA. C, Left ICA was reconstructed using four Enterprise self-expanding stent implantation. D, Delayed postprocedural angiography run of left CCA demonstrated left ICA occlusion. E, DSA performed on 1st postoperative day demonstrated distal third bypass narrowing indicating moderate vasospasm (←), but without flow delay. F, Control DSA performed 9th postoperative day showed complete vasospasm resolution and increase in bypass flow.



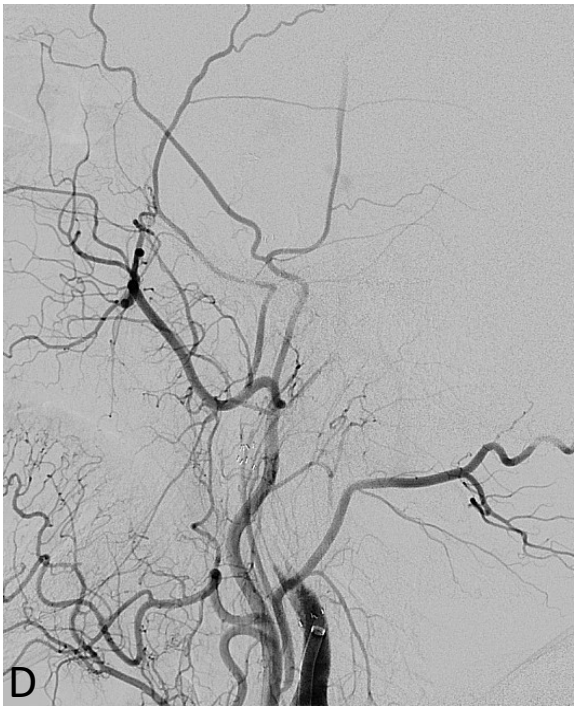A



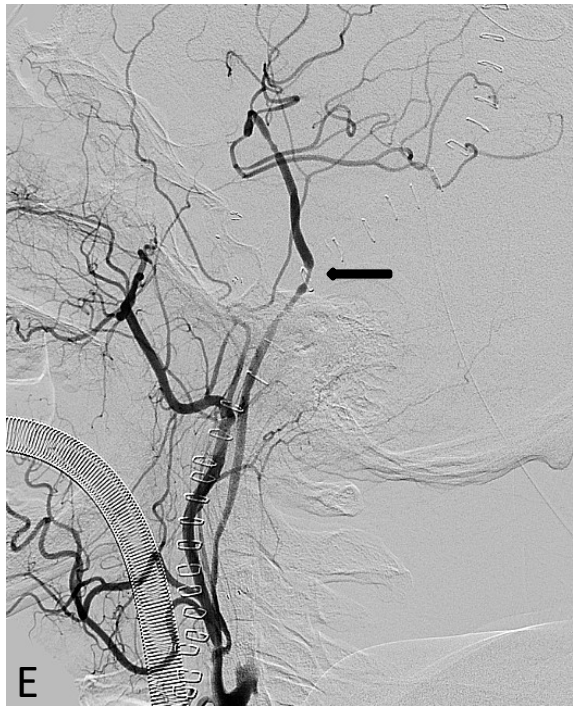
B



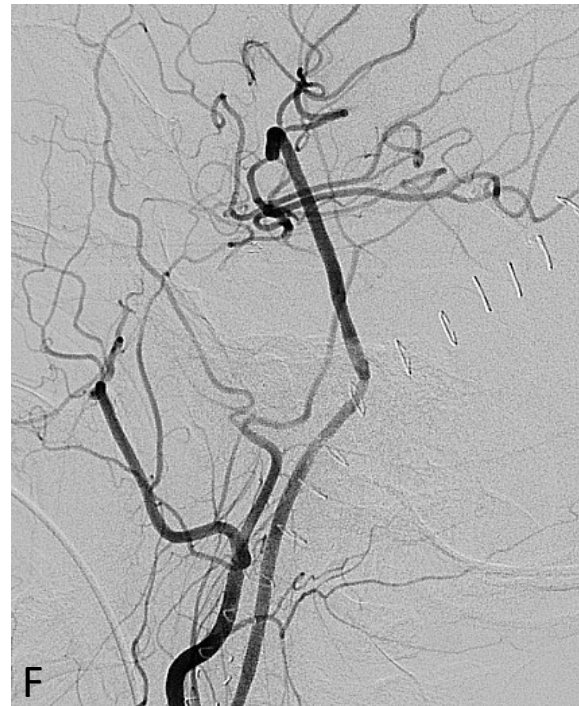C



D



E



F