

Spontaneous Resolution of Fourth Branchial Fistula Following Thyroid Surgery: Case Report

Bumber, Boris; Hodžić-Redžić, Selma; Prgomet, Drago; Bura, Miljenko; Marjanović Kavanagh, Marcel

Source / Izvornik: **Indian Journal of Otolaryngology and Head & Neck Surgery, 2019, 71, 879 - 882**

Journal article, Published version

Rad u časopisu, Objavljena verzija rada (izdavačev PDF)

<https://doi.org/10.1007/s12070-019-01588-z>

Permanent link / Trajna poveznica: <https://urn.nsk.hr/urn:nbn:hr:105:381084>

Rights / Prava: [In copyright](#) / [Zaštićeno autorskim pravom.](#)

Download date / Datum preuzimanja: **2024-11-25**



Repository / Repozitorij:

[Dr Med - University of Zagreb School of Medicine Digital Repository](#)



Spontaneous Resolution of Fourth Branchial Fistula Following Thyroid Surgery: Case Report

Boris Bumber¹ · Selma Hodzic-Redzic¹ · Drago Prgomet¹ · Miljenko Bura¹ · Marcel Marjanovic Kavanagh¹

Received: 27 November 2018 / Accepted: 8 January 2019 / Published online: 19 January 2019
© Association of Otolaryngologists of India 2019

Abstract Fourth branchial pouch anomalies represent one of the rarest types of all branchial apparatus anomalies. They appear in the first lifedecade in a form of recurrent left-sided neck masses which demands surgical treatment. Accidental finding, appearance later in life and spontaneous resolving are really rare. We present a case of a 43-year-old man with accidental finding of asymptomatic fourth pouch cyst and fistula following follicular thyroid cancer surgery. The day after the surgery, suction bottle was filled with little white crumbs and the wound started to suppurate. Barium swallow revealed the presence of a fistulous canal that arose from the left pyriform sinus. Meanwhile, the pathologist confirmed the presence of a lateral neck cyst within this thyroid lobe. The patient was operated on but fistulous canal was not visualized. In the meantime, wound discharge ceased spontaneously. At 1-year follow up, the patient was still well and free from any symptoms. These anomalies may manifest not only in childhood but may stay asymptomatic for a long time. It seems that the fistula can resolve spontaneously and that

conservative approach is an alternative to multiple surgical procedures.

Keywords Pyriform sinus · Cysts · Thyroid cancer · Follicular · Neck · Barium

Introduction

Human branchial apparatus has a vital role in the development of head and neck structures [1]. It is comprised of six paired mesodermal arches that appear in the fourth week of embryonic life and are separated by endodermal and ectodermal invaginations known as pouches and clefts [2]. Each branchial arch is covered externally by ectoderm and internally by endoderm, and the main body consists of mesenchyme. During development, the fifth arch disappears and the sixth arch becomes rudimentary. Branchial anomalies are classified into first, second, third and fourth anomalies depending on anatomic location [1]. Almost 95% of all congenital branchial apparatus anomalies are 2nd branchial arch, pouch or cleft anomalies, and the remaining 5% are from the 1st and 3rd arches [3]. Fourth branchial pouch anomalies are rare and they make the rarest type of all branchial apparatus anomalies. They may be presented as a fistula, sinus, or cyst. A fistula is composed of remnants of both pouch and cleft, with rupture of the interposed branchial plate; sinus is a tract that is open to either gut or skin and is composed of remnants of cleft or pouches, while cyst is a closed structure that presents entrapped remnants of branchial cleft or sinuses [1]. Derivatives of the fourth pouch include the laryngeal cartilages, laryngeal and pharyngeal constrictor muscles, superior laryngeal nerve, left thoracic aorta, right proximal subclavian artery, ultimobranchial body of the superior

✉ Selma Hodzic-Redzic
sellhodzic@gmail.com

Boris Bumber
borisbumber@yahoo.com

Drago Prgomet
dprgomet2@gmail.com

Miljenko Bura
miljenko.bura@zg.t-com.hr

Marcel Marjanovic Kavanagh
mmarjano@kbc-zagreb.hr

¹ University Department of ENT, Head and Neck Surgery, Zagreb University Hospital Center, Kišpatićeva 12, 10000 Zagreb, Croatia

parathyroid gland [2, 4, 5]. Typical fourth branchial pouch anomalies present in children, in the first decade of life, and almost always include recurrent left-sided neck masses refractory to treatment [3]. Acute suppurative thyroiditis and thyroid abscesses are also common presentations of this pathology (45%) [6]. Other presentations include cellulitis, hoarseness, odynophagia, abscess, and stridor [1]. We present a case of spontaneous resolution of fourth pouch fistula following accidental findings after thyroid surgery. Our intention is to note that these anomalies need not necessarily be surgically treated and that they may manifest not only in childhood but may stay asymptomatic for a long time.

Case Report

A 43-year-old man was admitted to the Department of ENT, Head and Neck Surgery because of planned left thyroid lobectomy following right lobectomy of the thyroid gland due to follicular thyroid carcinoma.

The day after the surgery, suction bottle was filled with little white crumbs and the wound started to suppurate. Laboratory inflammation parameters began to rise. A wound swab was obtained and empirical antibiotic therapy was introduced. The bacteria found in the wound swab were *Staphylococcus aureus* and *Streptococcus viridians*, both sensitive to the antibiotic administered. While the wound was suppurating, wound cleaning with hydrogen peroxide was performed daily. The patient complained of the cleaning agent entering his mouth, which raised suspicion of esophagus perforation and the patient underwent barium swallow X-ray. Food intake by mouth was excluded immediately. Barium swallow revealed the presence of a fistulous canal that arose from the left pyriform sinus and was 1 mm in diameter and 1 cm long (Fig. 1).

In the meantime, histopathologic examination was completed, indicating the presence of a cyst located in the posterior part of the thyroid lobe, which was lined with stratified epithelium and filled with fluid and a lot of neutrophils (Fig. 2). The pathologist confirmed it to be a lateral neck cyst within the left thyroid lobe.

Based on all these findings, we concluded that the patient had fistula of the fourth branchial arch that was connected to the cyst in the left thyroid lobe. Interestingly, the patient was completely asymptomatic throughout his life and he had never experienced any kind of neck swelling or infections. He had arterial hypertension, otherwise was healthy.

Our plan was to re-operate the patient with the aim of exploring the neck and hypopharynx and closing the fistula. Combined external and endoscopic approaches were planned. We accessed the hypopharynx through the

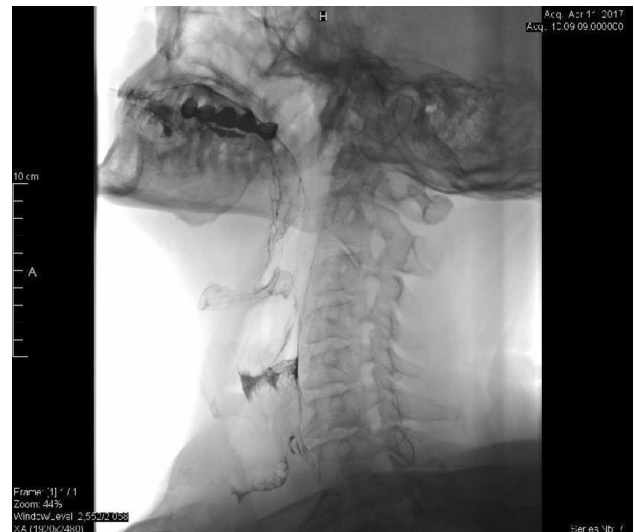

Fig. 1 The fistula in the lower third of the neck; Barium X-ray Swallow

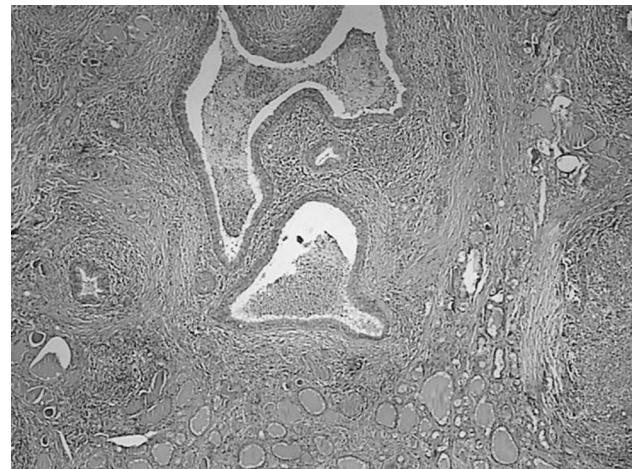


Fig. 2 Lateral neck cyst; HE (magnification $\times 200$)

existing wound on the neck. Direct hypopharyngoscopy was performed but the internal opening in the left pyriform sinus was not visualized. Thus, methylene blue stain was injected into the left pyriform sinus because barium swallow suggested it to be the site of fistula opening. The neck and the hypopharynx were explored but blue lining did not appear and the fistula was not visualized. The wound was closed in layers and the nasogastric feeding tube was inserted.

Wound discharge persisted for the next 2 weeks, thus radical reoperation, i.e. lateral pharyngotomy was planned. One day before the planned operation, wound suppuration ceased spontaneously. The wound stayed dry for the next 2 weeks, the nasogastric feeding tube was removed, and the patient swallowed without problems. As the patient was free from any symptoms, there was no need for additional

surgical procedures. At 1-year followup, the patient was still well and free from any symptoms.

Discussion

Congenital fourth branchial arch anomalies are uncommon entities. They primarily occur in childhood, in the first decade of life, while their occurrence in older age is uncommon. Typical presentation includes a cervical inflammatory process, mostly in the form of acute suppurative thyroiditis. However, our patient was in his early forties and was completely asymptomatic. He had never had any kind of neck swelling or infections. He suffered from arterial hypertension, otherwise was healthy. He had no symptoms associated with thyroid gland. There are few cases of later appearance of these anomalies described in the literature. Hallak et al. presented a 20-year-old woman with inflammatory left-side cervical swelling. She had an excision of a left-side cervical cyst 6 years before with initial diagnosis of a fourth branchial arch anomaly. Analysis showed a cyst in the left thyroid lobe and fistula arising from the left pyriform sinus. The patient was operated on with fistula excision and left thyroid lobectomy, and later was without any symptoms [6]. Patel and Hinni presented a 42-year-old male with recurrent neck infections and a draining cutaneous pit. He also had a history of multiple procedures on his neck starting 1 year before and was therefore thought to have recurrent deep neck infection. Barium swallow confirmed the presence of a sinus tract coming off the apex of the left pyriform sinus, consistent with a fourth branchial cleft anomaly. Complete surgical excision of the sinus tract resulted in resolution of the process with no further recurrences in 10-year period [2]. The only difference between these patients and our patient was that our patient was asymptomatic but probably in the future could suffer from recurrent thyroiditis or recurrent neck infections.

Fourth branchial arch anomalies are usually found on the left side, in 94% of cases according to literature [5]. This case presentation was not the exception. This may be due to the more complex and extended pathway of the fourth branchial tract on the left side, or it might be because of the absence or involution of the ultimobranchial body on the right side [6]. Fourth branchial cleft anomalies are usually found in the first decade of life. They can also be present at birth, as reported by Yoo et al. A full-term male newborn was presented with a mass on his left anterior neck, which increased in size during the first week, and was later diagnosed as a fourth branchial cleft cyst [7]. There are sporadic cases where these anomalies were presented later in life [2, 3]. These patients were symptomatic, whereas in our patient the anomaly was found accidentally.

Barium swallow and direct laryngoscopy have been the most useful diagnostic tools but computed tomography and magnetic resonance imaging are the modalities of choice for displaying both the location and extent of pyriform sinus anomalies, as well as thyroid involvement [8, 9]. Our patient was examined by barium esophagogram, and considering that thyroid gland had already been removed, there was no need for additional diagnostic workup.

The recommended treatment for fourth branchial anomalies is complete surgical excision of the anomaly, regardless of the clinical presentation [9]. Two main surgical approaches include the external and endoscopic approach. The external approach is most common but lately, endoscopic approach is more often used and includes endoscopic cauterization of fistula arising from the pyriform sinus. There are reported cases of fistula sclerotherapy with OK-432 [10]. In our study, a combined external and endoscopic approach was used. To date, we did not find any case of fourth branchial fistula that resolved spontaneously, although there is the possibility of unrecognized anomalies that resolved spontaneously after some surgical procedures, as in the case presented. Also, our patient was treated with thyroid lobectomy due to primary illness, and this surgical procedure could also be the reason for spontaneous resolution of the symptoms, although there is always a possibility of recurrent neck infections in the future.

In conclusion, the fourth branchial anomalies can be found later in life, since these patients can long stay asymptomatic. Symptoms can be induced by some procedures, as in our case by thyroid surgery. It also seems that the fistula can resolve spontaneously and that conservative approach can be an alternative to multiple surgical procedures.

Compliance with Ethical Standards

Conflict of interest We declare that we have no conflict of interest.

Ethical Approval All procedures performed in studies involving human participants were in accordance with the ethical standards of the institutional and/or national research committee and with the 1964 Helsinki declaration and its later amendments or comparable ethical standards.

Informed Consent Informed consent was obtained from the patient included in the study.

References

1. Prasad SC et al (2014) Branchial anomalies: diagnosis and management. *Int J Otolaryngol* 2014:237015
2. Patel AB, Hinni ML (2011) The fourth branchial complex anomaly: a rare clinical entity. *Case Rep Otolaryngol* 2011:958652

3. Pal I et al (2009) Fourth branchial pouch sinus: an unusually late initial presentation. *Indian J Otolaryngol Head Neck Surg* 61(1):72–75
4. Nicoucar K et al (2010) Management of congenital third branchial arch anomalies: a systematic review. *Otolaryngol Head Neck Surg* 142(1):21e2–28e2
5. Nicoucar K et al (2009) Management of congenital fourth branchial arch anomalies: a review and analysis of published cases. *J Pediatr Surg* 44(7):1432–1439
6. Hallak B et al (2014) Residual fistula of fourth branchial arch anomalies and recurrent left-side cervical abscess: clinical case and review of the literature. *Case Rep Otolaryngol* 2014:931279
7. Yoo TK et al (2014) Fourth branchial anomaly presenting with a lateral neck mass in a neonate. *J Neonatal Surg* 3(3):34
8. Cases JA et al (2000) Recurrent acute suppurative thyroiditis in an adult due to a fourth branchial pouch fistula. *J Clin Endocrinol Metab* 85(3):953–956
9. Liberman M et al (2002) Ten years of experience with third and fourth branchial remnants. *J Pediatr Surg* 37(5):685–690
10. Arunachalam P, Vaidyanathan V, Sengottan P (2015) Open and endoscopic management of fourth branchial pouch sinus: our experience. *Int Arch Otorhinolaryngol* 19(4):309–313

Publisher's Note Springer Nature remains neutral with regard to jurisdictional claims in published maps and institutional affiliations.