

Nonprescription acne vulgaris treatments: Their role in our treatment armamentarium - an international panel discussion

Dréno, Brigitte; Araviiskaia, Elena; Kerob, Delphine; Andriessen, Anneke; Anfilova, Maryna; Arenbergerova, Monika; Forero Barrios, Olga L.; Bukvić Mokos, Zrinka; Haedersdal, Merete; Hofmann, Maja A.; ...

Source / Izvornik: **Journal of Cosmetic Dermatology, 2020, 19, 2201 - 2211**

Journal article, Published version

Rad u časopisu, Objavljena verzija rada (izdavačev PDF)

<https://doi.org/10.1111/jocd.13497>

Permanent link / Trajna poveznica: <https://um.nsk.hr/um:nbn:hr:105:364927>

Rights / Prava: [Attribution 4.0 International](#) / [Imenovanje 4.0 međunarodna](#)

Download date / Datum preuzimanja: **2024-07-29**



Repository / Repozitorij:

[Dr Med - University of Zagreb School of Medicine Digital Repository](#)



Nonprescription acne vulgaris treatments: Their role in our treatment armamentarium—An international panel discussion

Brigitte Dréno MD, PhD¹  | Elena Araviiskaia MD²  | Delphine Kerob MD³  |
 Anneke Andriessen PhD⁴  | Maryna Anfilova MD, PhD⁵  |
 Monika Arenbergerova MD, PhD⁶  | Olga L. Forero Barrios MD⁷  |
 Zrinka Bukvić Mokos MD, PhD⁸  | Merete Haedersdal MD, PhD, DMSc⁹  |
 Maja A. Hofmann MD¹⁰  | Ziad Khamaysi MD¹¹  | Marita Kosmadaki MD, PhD¹²  |
 Aleksandra Lesiak MD¹³  | Elia Roó MD¹⁴  | Anca Zbranca-Toporas MD, PhD¹⁵  |
 Marni C. Wiseman MD, FRCPC¹⁶  | Sameer Zimmo MD¹⁷  | Lucie Guerin PharmD¹⁸  |
 Gabriella Fabbrocini MD¹⁹ 

¹Cell Therapy and Gene Therapy Unit, Department of Dermato-Oncology, The Faculty of Medicine, University of Nantes, Nantes, France

²Department of Dermatology & Venereology, First Pavlov State Medical University of Saint Petersburg, Saint Petersburg, Russia

³International Medical Relations, Laboratoire Vichy, Chevilly-Larue, France

⁴Nijmegen and Andriessen Consultants, Radboud UMC, Malden, The Netherlands

⁵Department of Skin and Venereal Diseases, National Pirogov Memorial Medical University, Vinnytsya, Ukraine

⁶Department of Dermato-Venereology, Third Faculty of Medicine, Charles University and University Hospital of Kralovske Vinohrady, Prague, Czech Republic

⁷Centro de Dermatologia, Porto Alegre, Brazil

⁸Department of Dermatology and Venereology, School of Medicine University of Zagreb, University Hospital Center Zagreb, Zagreb, Croatia

⁹Bispebjerg Hospital, University of Copenhagen, Copenhagen, Denmark

¹⁰Department of Dermatology, Venereology, and Allergy, Charité-Universitätsmedizin, Berlin, Germany

¹¹Department of Dermatology, Rambam Medical Center and Ruth & Bruce Rappaport Faculty of Medicine, Technion, Haifa, Israel

Abstract

Background: Acne vulgaris (acne), a common inflammatory skin disorder, has its peak incidence between 14 and 19 years of age, with girls frequently developing acne earlier than boys. Over recent years, persistent acne is becoming more prevalent in adult women.

Objectives: This review and panel discussion addresses challenges in acne management, particularly in adult women. The role which nonprescription acne treatment can play is explored when used as monotherapy or as an adjunctive treatment for acne of all severity.

Methods: The best available evidence on nonprescription acne treatment was coupled with the opinion of an international expert panel of dermatologists to adopt statements and recommendations discussed in this review.

Results: All severity of acne has a significant burden on patients. Addressing environmental factors that are important for the individual with acne may help to educate, prevent, effectively manage, and maintain acne, as per the panel. They agreed that the adult female acne population has unique needs because of their aging skin and social environment. Nonprescription acne treatment products may help to balance the efficacy and tolerability of prescription acne treatment. Currently, there are no specific guidelines for how to use nonprescription acne treatment products in these patients.

Conclusion: The panel agreed that guidelines including nonprescription acne treatment either as monotherapy for mild acne or in combination with prescription treatments for more severe acne would address a significant unmet need.

This is an open access article under the terms of the Creative Commons Attribution-NonCommercial License, which permits use, distribution and reproduction in any medium, provided the original work is properly cited and is not used for commercial purposes.

© 2020 The Authors. *Journal of Cosmetic Dermatology* published by Wiley Periodicals LLC

¹²Boston University, Boston, MA, USA

¹³Dermatology and Venereology Clinic, Medical University, Łódź, Poland

¹⁴Clíder-Clínica Dermatológica, Madrid, Spain

¹⁵Department of Biomedical Sciences, Faculty of Bioengineering, University of Medicine and Pharmacy Grigore T.Popa, Iasi, Romania

¹⁶Departments of Medicine and Dermatology, University of Manitoba, Winnipeg, MB, Canada

¹⁷King Abdulaziz University, Jeddah, Saudi Arabia

¹⁸L'Oréal Research and Innovation, Chevilly-Larue, France

¹⁹Department of Clinical Medicine and Surgery, Dermatology, Section of Dermatology, University of Naples Federico II, Naples, Italy

Correspondence

Anneke Andriessen, Zwenkgras 25, 6581 RK Malden, The Netherlands.

Tel: +31243587086, Email: anneke.a@tiscali.nl

Funding information

Vichy Laboratoires, France

KEYWORDS

acne in adult women, acne vulgaris, adjunctive treatment, dermocosmetics, monotherapy

1 | BACKGROUND

Acne vulgaris is the most common dermatological disorder globally in the world, with an estimated prevalence of 650 million adolescents and adults affected.¹⁻⁴ The Global Burden of Disease Project estimates the prevalence of acne at 9.4%, ranking it as the eight most prevalent disease worldwide.² Of the adolescents, the peak incidence of acne is at 14 and 17 years old for girls and 16 and 19 years old for boys.^{3,4} Although acne vulgaris is considered a typical chronic adolescent inflammatory skin disorder, it is becoming more prevalent in adulthood, especially in women.^{4,5} Over the past several years, acne in the adult female has become one of the reasons for the increase in dermatologic consultations.⁶ Based on the time of acne onset, two subtypes of female acne are recognized: persistent acne, representing a continuation or a relapse from adolescence, and late-onset acne, which appears for de novo in adulthood (25 years or more).⁶ The main complications of acne are acne scarring and PIH, which are frequent and can impact on the quality of life (QOL).⁷⁻¹¹ Various studies have indeed reported on psychological and emotional distress due to acne, including poor self-esteem, social anxiety, depression, and suicidal ideation.^{12,13}

The pathophysiology of acne is complex and multifactorial.^{14,15} comprising a peripheral hormonal factor and chronic stimulation of the innate immunity by commensal bacteria (*C acnes* and *S epidermidis*) of the microbiome with a loss of diversity, as well as other internal factors such as genetic predispositions.

The classic view on acne pathogenesis regards inflammation as the endpoint following seborrhea, hyperkeratosis, and bacterial hyperproliferation.¹⁴ Current insights have identified acne as primarily an inflammatory disease, with micro-inflammation being the root cause of the acne cycle.¹⁴⁻¹⁸ The pattern of innate inflammation, leading to acne lesions, is triggered by direct and indirect multifactorial, complex, and interrelated mechanisms.²¹ In acne-affected skin, pro-inflammatory factors are upregulated, such as toll-like receptors (TLR), interleukin-1 (IL), and IL-8, human β -defensin-4 (hBD), and matrix metalloproteases (MMPs), all of which stimulate inflammatory mediators.¹⁸

Hormonal changes are the driving mechanism triggering elevated sebum formation with an abnormal constitution and *Cutibacterium acnes* (*C acnes*), thereby decreasing skin microbial diversity.¹⁴⁻¹⁸ The contribution of *C acnes* to acne is not completely elucidated.¹⁶

Cutibacterium acnes can alter its local environment as it contains numerous biosynthetic gene clusters and lipases that contribute to the production and release of antimicrobial and immunomodulatory molecules.¹⁵⁻¹⁸ Acne vulgaris can be characterized by the dominance of distinct strains of *C acnes* as well as elevated *S epidermidis* abundance. In acne-affected skin, there is a loss of the diversity of *C acnes* phylotypes with the predominance of 1A1.^{16,25,26} In acne-prone and acne-affected skin, it has, therefore, become crucial to maintaining the balance of the cutaneous microbiome within its follicles and on the surface of the skin.^{16,25,26} Testosterone and dihydrotestosterone (DHT) are more selective to sebocytes of the face and are crucial for regulating sebum production.²⁶

External factors that contribute to acne include cosmetics, stress, tobacco, or exposure to ultraviolet. These factors are called acne exposome factors. The acne exposome represents a total of factors that influence the occurrence, duration, and severity of acne beyond genetics.¹⁶ An international survey recently described the most common factors related to acne as nutrition, pollution, stress, and harsh skincare.¹⁷

Frequently in acne-affected skin, the barrier function is compromised, changing functional properties, such as elevated sebum excretion, enlarged sebaceous glands, and subclinical inflammation.¹⁴⁻¹⁸

Current acne treatment recommendations are dependent on the severity of the condition identified by different gradings.¹⁹ Systemic and topical medications, such as retinoids, topical antibiotics, and benzoyl peroxide, are associated with skin barrier alteration, and may be associated with skin dryness and irritation in some patients.^{20,21} These side effects can reduce adherence to treatment and thus negatively impact therapeutic outcomes.²⁰

Nonprescription acne treatments and skincare, such as non-comedogenic cleansers, and moisturizers have been successfully used to reduce skin irritation.¹⁴ Adult women with facial acne frequently have dry skin, which is prone to irritation. They may benefit from specifically designed nonprescription acne treatment, including cleansers and moisturizers that cater to their condition. More recently, the role of nonprescription acne treatment, either as monotherapy or in combination with prescription agents, has become a topic of interest to physicians treating patients with acne.^{22,23} Treating acne taking into account the complete portfolio of measures available, including skincare, may improve adherence to treatment, reducing skin irritation, and improving patient outcomes.

2 | AIM

This international expert panel discussion explores challenges in addressing acne, particularly acne in adult women, and examines to what extent nonprescription acne treatment used as an adjunctive or as monotherapy can improve patient outcomes, including prevention, treatment, and maintenance of acne. For this purpose, the best available evidence, coupled with experts' opinion, was used to create statements that are discussed in this paper.

3 | METHODS

3.1 | Literature searches

Before the international panel meeting, a literature review was conducted, which included clinical acne guidelines, clinical studies, and review articles on acne prevention, treatment, and maintenance, specifically targeting nonprescription regimens for adult females affected by acne. For this purpose, searches were made in PubMed and on Google Scholar, on July 10-12, 2019, for English-language literature (2010-2019) using the following terms:

Acne vulgaris, acne pathogenesis, adult female acne, skin microbiome and acne, acne exposome, acne therapy with OTC regimens, non-prescription acne treatment, active cosmetics for acne, sebostatics, keratinization, salicylic acid (SA), niacinamide/nicotinamide, retinoids, benzoyl peroxide (BPO), isotretinoin, lipo-hydroxy acid (LHA), alpha-hydroxy acids (AHAs), linoleic acid (LA), P acnes and zinc salts, acne guidelines or algorithms for adult females with acne.

Exclusion criteria were as follows: no original data (unless a review article was deemed relevant), not dealing with the management of acne in adult females, and publication language other than English. Two authors (BD and AA) manually reviewed the selected publications for additional resources, yielding seventy-six papers deemed clinically relevant to adult female acne and the use of non-prescription acne regimens. After the exclusion of duplicates, sixty articles were included.

3.2 | Role of the panel

The international expert panel of dermatologists convened for a meeting (October 11, 2019; Madrid, Spain). Prior to this meeting, statements were prepared based on the selected information from the literature searches. During the meeting, the panel worked in small groups to define and adopt statements on adult female acne and its treatment approaches using nonprescription acne regimens. The panel then reconvened into a plenary group to define and order statements, coupled with expert opinion and experience of the panel.²⁴

4 | STATEMENTS AND DISCUSSION

Statement 1: The acne exposome model may be used for educational purposes to enhance awareness of the variety of causes of acne and provide holistic acne management

The term exposome was used for the first time by Wild in 2005 to describe the sum of environmental exposures to which an individual is subjected from conception to death.

In 2014, Miller and Jones refined this term as "the cumulative measure of environmental influences and the associated biological responses throughout the lifespan, including exposures from the environment, diet, behavior, and endogenous processes."^{16,27}

The acne exposome is defined as the sum of all environmental factors influencing the occurrence, duration, and severity of acne.¹⁶ Acne exposome factors impacting the development of acne include nutrition, medication, occupational factors, pollutants, climatic factors, and psychosocial factors, including lifestyle (Figure 1).¹⁶ Daily consumption of dairy products, especially skim milk, and the regular consumption of high-glycemic index foods may stimulate the proliferation of sebocytes and keratinocytes.¹⁶ There is some evidence indicating a link at a transcriptional level between insulin-like growth factor 1 (IGF-1), leptin and liponectin, and high-glycemic index through the activation of mammalian target of rapamycin (mTOR)

and forkhead box protein P1 (FOXP1) pathways.^{28,29} Interestingly, acne is not observed in native non-Westernized populations consuming low-glycemic index foods or in those that do not consume refined sugars, grains, milk, and dairy products.²⁸ However, conclusive evidence on the influence of a dairy containing diet on acne flares is lacking.

Leucine, a whey protein that stimulates the production of IGF-1, is frequently used in supplements used by athletes. Such supplements may trigger or worsen acne flares.

Another exposome factor that may trigger acne is air pollution causing oxidative damage that aggravates dysseborrhea, which can lead to microcomedones. Studies found a correlation between the concentration of NO₂ and the number of acne consultations.²⁸⁻³⁰ Recently, an international survey found that pollution, stress, and harsh skincare, as well as climate and sun exposure, may be considered as important factors related to acne development.¹⁷

The panel recommends that checking these exposome factors at the acne patient's first visit to the clinic may be beneficial to identify the specific issues triggering acne in this patient (Table 1).¹³ The exposome model may be particularly helpful for adult females with acne, as the information is also helpful for the prevention of photoaging damage.³²

Statement 2: Adult acne, particularly in women, is increasingly a reason for dermatologic consultation

The panel agreed that the proportion of adult female patients with persistent mild-to-moderate acne seen in consultation has significantly increased over the past years. These patients often report worsening of acne during their premenstrual period.

Various studies have demonstrated that the incidence of adult female acne is increasing and frequently leading to scarring.^{3,4} In the majority of females, acne persisted after adolescence; however, there are reports on late onset at over 25 years of age.³³

It is not clear whether there is a real increase in acne incidence in the adult female population or whether access to information

encourages women to visit a dermatologist for their acne, resulting in more clinic visits.³³

The panel members agreed that late-onset acne in females is often associated with polycystic ovary syndrome or the use of contraceptives.³⁴ The pathogenesis of acne is usually related to the intracrine synthesis of active androgens in the skin. Sebaceous glands and hair follicles act as independent endocrine organs and respond to the different levels of androgens.^{14,33,34} Hormonal tests may be indicated in patients with acne resistant to treatment, patients with hirsutism, and patients with menstrual disorders.³³ In this case, the following hormonal tests that can be prescribed upon clinical examination are follitropin (FSH), lutropin (LH), total testosterone (T), sex hormone-binding globulin (SHBG), dehydroepiandrosterone sulfate (DHEAS), 17OH-progesterone, thyrotropin (TSH), and prolactin (PRL).³³

In adult women, a positive correlation has been described between DHT, DHEAS levels, and the severity of the inflammatory lesion, with blood levels of the insulin-like growth factor 1 (IGF-1).³³ Hyperinsulinemia influences both the IGF-1 concentration in the blood and the insulin-like growth factor-binding protein 3 (IGFBP-3) that acts directly on keratinocytes elevating proliferation resulting in continuous sebum production.³³

External hormones through the use of pro-androgen progestins present in specific oral, injectable, or intrauterine device contraceptives may also trigger or aggravate acne.³⁴

The use of epidermal growth factor receptor (EGFR) inhibitors, such as the monoclonal antibody cetuximab and the tyrosine kinase inhibitor erlotinib, for the treatment of solid tumors, is increasing. These treatments may cause skin toxicities such as an acneiform eruption, xerosis, eczema, and changes in the hair and nails.

Statement 3: Burden of acne can increase in the case of sequelae such as acne scarring or postinflammatory hyperpigmentation

A study by Rocha et al showed that adult female acne has a high negative impact on the patients' QoL, even for the mild-to-moderate acne sufferers.³⁵

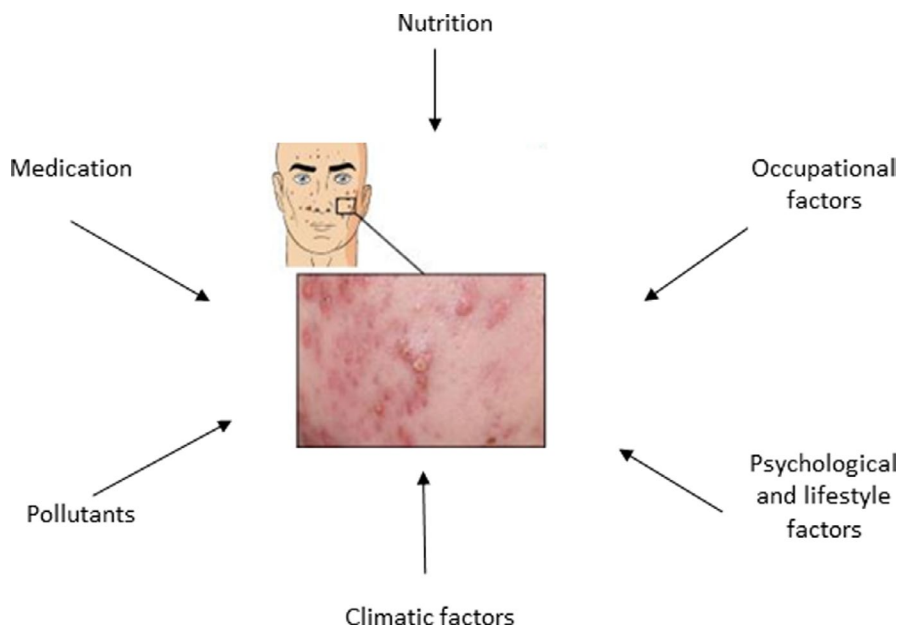


FIGURE 1 Exposome factors triggering acne

TABLE 1 Exposome factors to be checked at the first visit

Exposome factors	Details
Nutrition	Dairy products such as skim milk Rapidly assimilated saccharides, snacks Nutritional supplements containing whey proteins/leucine 1
Medication	Contraception: Combined contraception may be beneficial in the treatment of acne; progestin-only contraception may not help or even worsen acne. ²⁰ Use of anabolic steroids, testosterone
Occupation	Cosmetics Mechanical factors
Pollutants	Air and industrial pollutants ³² Tobacco and cannabis consumption
Climate	Heat, humidity, ultraviolet radiation
Psychosocial factors like modern lifestyle	Stress, emotions, sleep deprivation Socioeconomic pressures Excessive light exposure from digital devices (tablets, smartphones, computers)

Note: Adapted from Dréno B et al.⁷

The panel members reported that their patients found visible acne lesions to be troublesome to camouflage and that they have concerns about acne marks, including scarring and postinflammatory hyperpigmentation (PIH). PIH is an inflammatory response of the skin, developing more commonly in darker skin.³⁶ Asian patients from Pacific rim countries, including Japan, Taiwan, and China, seem to be more susceptible to developing PIH.³¹ PIH is considered if a history of a preceding pathologic process such as an inflammatory event (acne) or injury to the affected area of hyperpigmentation is present.³⁶ PIH is caused by one of two mechanisms that result in either epidermal or dermal melanosis. The epidermal inflammatory response results in the release and subsequent oxidation of arachidonic acid to prostaglandins, leukotrienes, and other products, which alter the activity of both immune cells and melanocytes.³⁶ Specifically, these inflammatory cells stimulate epidermal melanocytes, causing the elevated synthesis of melanin and subsequently elevated transfer of pigment to surrounding keratinocytes. Such increased stimulation and transfer of melanin granules result in epidermal hypermelanosis. The distribution of the hypermelanotic lesions depends on the location of the acne lesions. The lesions range from light brown to black, with a lighter brown appearance if the pigment is within the epidermis and a darker gray to bluish appearance if lesions contain dermal melanin (Figure 2A,B).³⁶

Differences exist in the presentation of and therapy in teenagers with a skin of color, largely due to the increased risk for PIH, scarring, and keloid formation. Additionally, there are differences in skincare-related exacerbating factors.^{37,38} The primary goal of acne therapy, especially in those with a skin of color, is the prevention of long-term sequelae such as atrophic or hypertrophic scars.^{37,38} Daily use of a broad-spectrum sunscreen (SPF > 15) is an essential part of any therapeutic acne regimen.^{37,38}

Statement 4: When managing acne, it is important to target the four main pathogenesis, such as follicular hyperkeratosis,

inflammation, sebum production, and the skin microbiome, while maintaining an intact skin barrier.

According to the panel, an understanding of new insights into acne pathophysiology is required to improve treatment outcomes. Treatment recommendations for mild acne may start with nonprescription acne treatment, topical benzoyl peroxide (BPO), or a topical retinoid.^{14,15,20} A nonprescription acne regime, including skincare, could be recommended as monotherapy for mild acne or in combination with prescription topical or orals for more severe acne or in the maintenance of acne.

The use of a topical retinoid may have additional advantages, such as addressing signs of facial skin aging. Other options are topical fixed combination products such as BPO plus antibiotic, BPO plus retinoid, or a combination of BPO, antibiotic, and retinoid.^{14,15,20} Topical dapson may be a further option, which may be given as monotherapy (Table 2).^{14,15,20}

Treatment recommendations for moderate acne may begin with topical fixed combination therapy, as described for mild acne.^{14,15,20} Other options, such as an oral antibiotic combined with topical retinoid plus BPO, can be considered, and if the response to therapy is inadequate, the type and or formulation of the topical treatment may be changed. For females, hormonal therapy may be considered or oral isotretinoin combined with nonprescription acne treatment.^{14,15,20} For moderate-to-severe acne, nonprescription acne treatment may be used as an adjunctive to systemic treatments.

Topical therapies typically used for acne are, in principle, suitable for adult females; however, care should be taken when using washes and scrubs as these may irritate the skin, especially in individuals with skin prone to irritation.^{21,23} Moreover, many of the topical medications, such as retinoids, antibiotics, and BPO, are associated with skin barrier alteration, causing irritation and dry skin conditions, possibly reducing adherence to treatment and therapeutic outcomes.^{21,23} Strategies to improve tolerance and compliance have been described, such as alternate regimens of topical retinoids, and

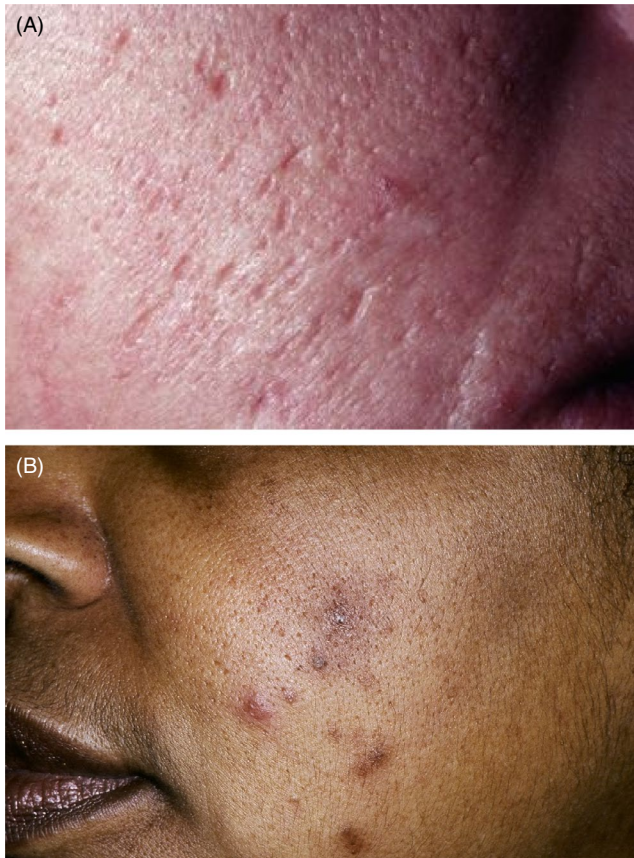


FIGURE 2 Inflammatory acne may result in postinflammatory hyperpigmentation. A, Icepick scar: tiny ice pick punctures. B, Female with a skin of color and acne-related postinflammatory hyperpigmentation

progressive and adaptive increase of systemic retinoids, with the association of nonprescription acne treatment.³⁹ Alterations in skin barrier function and integrity have been reported in acne-affected skin^{18,21,40}; however, it is unclear whether these alterations are sequelae of the disease process or a predisposition to acne itself.⁴⁰ The structural and functional integrity of the stratum corneum (SC) is dependent on adequate water in the skin barrier.²¹ Acne-affected skin has a much lower water retention rate and therefore has a much faster water decay.²¹

Statement 5: The role of nonprescription acne treatment in acne management is 4-fold: management of mild acne, maintenance therapy, synergistic effect, and management of side effects.

Nonprescription acne treatment may play a role in acne prevention, treatment, and maintenance regimens. The panel members agreed that nonprescription acne treatment plays a significant role in the management of mild acne, as maintenance therapy, or in combination with acne prescription medications to enhance efficacy or to improve tolerability.⁴¹ Nonprescription acne treatment, cleansers, and moisturizer use may prevent the appearance of new lesions, reduce inflammation, and improve skin barrier function.⁴¹ The composition of moisturizers and cleansers should have a pH close to a physiological skin surface pH ranging from 4 to 6 to prevent an increase of moisture vapor water loss and a change of protease-activated receptor 2 (PAR₂) affecting skin barrier integrity and elevating inflammation.³⁹

A randomized, investigator/evaluator-blinded, split-face comparison in subjects with healthy skin over four weeks showed more subjects without symptoms of dry or irritated skin or mild symptoms in the moisturizer and tretinoin cream group versus the tretinoin cream alone group (17.1% vs 14.3% and 60% vs 25.7%, respectively; Figure 4).⁴⁰

A review on the use of nonprescription acne treatment explored the use of salicylic acid (SA), niacinamide/nicotinamide, benzoyl peroxide (BPO), lipohydroxy acid (LHA), alpha-hydroxy acids (AHAs), retinoid, linoleic acid (LA), and zinc salts used in dermocosmetic formulations.⁴¹ The authors reported several of these topical formulations, such as vitamin C and niacinamide, and demonstrated a sebo-suppressive effect as well as a topical antioxidant effect in small clinical studies.⁴¹ Glycolic acid peels may be used to open comedones and to unroof pustules; however, the panel agreed that these peels should not be classified as nonprescription acne treatment and should be applied by professionals.

SA is reported to have comedolytic properties and is moderately effective in the treatment of acne, although it is less potent than topical retinoids.⁴¹ SA may be used in combination with other treatments. A comparative study of oral isotretinoin vs oral isotretinoin with a 20% SA peel in 60 patients with active acne demonstrated the combination treatment was more effective than isotretinoin alone (a reduction of 93% in lesion number, compared with 73%).⁴²

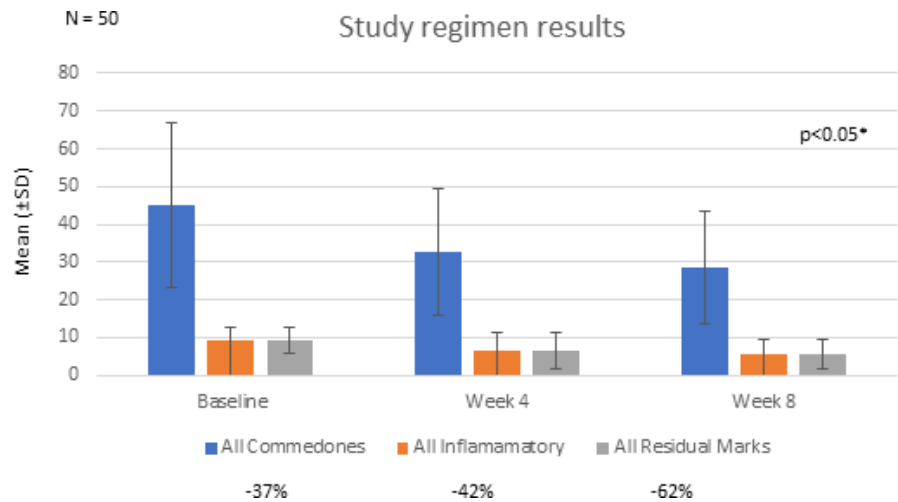
An SA containing product showed similar efficacy and tolerability when used in patients with mild-to-moderate acne compared to a gel containing clindamycin and BPO.⁴³

The panel agreed that maintaining an intact skin barrier is important to successful acne treatment outcomes and considered skincare, including a cleanser and moisturizer, to be an important

Innate immune response	Hyperkeratinization	PMN chemotaxis/phagocytosis	<i>Cutibacterium acnes</i>
Retinoids	Retinoids	Retinoids	BPO
Clindamycin	BPO	BPO	AB
Dapsone	Hydroxy acids	Clindamycin	Dapsone
		Dapsone	

TABLE 2 Topical treatment options

FIGURE 3 NP treatment regimen study results. Significant reduction ($P < .05$) comparing the mean (\pm SD) number of comedones (-37%), inflammatory lesions (-42%), and acne marks (-62%) at baseline vs 8-wk assessment



factor. Cleansers and moisturizers support epidermal barrier repair in acne-affected skin.^{22,23,37,38,41,43-45} Studies have shown normalizing the skin surface pH reduces the inflammatory TH2 response and enhances barrier function recovery, thereby preventing epidermal hyperproliferation.^{40-42,46-48} Another study showed adjuvant skincare improved adherence to topical retinoid treatment, significantly reducing acne severity.⁴³ When using oral isotretinoin, combining it with SA peels seems to be an attractive option.⁴⁹

Studies on the use of a skin cleanser and moisturizer in patients with mild acne and dry skin demonstrated a reduction in acne, an improvement in dry skin, and increased levels of endogenous ceramides in the SC.^{44,46,47}

A recent study has been conducted with a nonprescription acne regimen (Normaderm Phytosolution, Vichy (NP)) which targets the acne pathogenesis due to SA 2%, phyco-saccharide 2%, and vitamin CG as well as ingredients that enable regeneration of the disrupted skin barrier in acne-affected skin, such as mineralizing water 60%, Bifida ferment lysate 1%, and HA 0.2% in adult females with acne. Salicylic acid promotes individual corneocyte desquamation close to natural exfoliation, phyco-saccharide reduces sebum production, and vitamin CG has demonstrated anti-inflammatory action.^{14,18,50} The study included fifty women with acne-prone skin having at least five inflammatory acne lesions and ten noninflammatory lesions as well as a dull and uneven complexion. The study evaluated skin condition, sebum tape, and pH measurements, and subjective assessment of the skin complexion radiance, homogeneity, and patient satisfaction with the treatment. The women used the NP regimen twice daily for eight weeks and had a significant ($P < .05$) reduction of the number of inflammatory lesions (papules and pustules), noninflammatory lesions (open and closed comedones), erythematous macules, and pigmentation evaluated by a dermatologist (Figure 3 and Table 3). Patients reported a high degree of satisfaction with the treatment. Another unpublished study evaluated the quality-of-life aspects of 232 women from different ethnic groups, African (24.8%), Asian (24.8%), Caucasian (25.6%), and Hispanic participants (24.8%). The

women with oily and acne-prone skin rated psychological attributes after daily use of mineralizing water 60%, Bifida ferment lysate 1%, and HA 0.2% containing skincare regimen for 8 weeks. The study demonstrated a significant positive improvement in their skin condition, behavioral aspects, and emotional status (Figure 4). These results were consistent for all the four ethnic groups.

Statement 6: There are unmet needs for adult females with acne who may benefit from specifically designed acne treatment, skincare, and cleanser formulations, which can be recommended to manage acne either as monotherapy or in combination with acne medications.

The panel agreed that there are limited guidelines available regarding the role of nonprescription acne regimens. They suggested that these nonprescription regimens offer patients the ability to better tolerate topical prescription treatment and play a large role in maintenance therapy.^{45,46,51} The panel further agreed that almost all of their patients were interested in maintenance measures and skincare that improved their facial skin condition long-term and recognized that available regimes are not always suited for this purpose. The panel further agreed that topical formulations do not frequently address rhytide development, skin texture, and moisturization, issues that are important to the adult female population with acne. The panel shared what they considered important unmet needs for nonprescription acne regimes (Table 4). Most frequently mentioned are nonprescription acne regimen for maintenance after retinoid treatment, monotherapy for very mild acne, and topical retinoid combined with BPO suitable for the aging skin.

Additionally, a nonprescription acne treatment that approaches pharmacologic acne treatment is recommended by doctors. Such formulations should be a safe option for acne-prone young children and pregnant women. The panel members noted that nonprescription treatment for aging skin and acne is a welcome addition. Finally, the panel members stated that dermatologists are ideally positioned to combine prescription treatment with nonprescription acne treatment. Evidence- and guideline-based medicine is important, but

insufficient. Nonprescription acne treatment is required to improve therapeutic compliance and patient quality of life.⁵¹

5 | CONCLUSIONS

Acne is primarily an inflammatory disease that can have a significant burden on patients, regardless of severity. Therefore, prevention,

early treatment, and maintenance approaches are needed. The acne exposome addresses environmental factors that play a role in the development, duration, and severity of acne. This concept may be a useful educational tool and can be used upon the first visit to the clinic to highlight specific factors that are important for the individual with acne. The panel agreed that although data are lacking, adult female acne is an increasing issue. This population has unique needs because of their aging skin and social environment. An acne

TABLE 3 Treatment regimen study results

Acne lesions N = 50	Baseline	Week 4	Baseline vs week 4	Week 8	Baseline vs week 8
Open comedones					
Mean (SD±)	38.62 (± 19.37)	27.46 (± 14.44)	-11.16 (± 9.37)	24.34 (± 13.46)	-14.28 (± 11.96)
P-value			<.001		<.001
% improvement			-28.90%		-37.00%
Closed comedones					
Mean (SD±)	6.46 (± 7.43)	5.12 (± 6.03)	-1.34 (± 4.32)	4.04 (± 4.73)	-2.34 (± 5.07)
P-value			.051		<.001
% improvement					-37.50%
All comedones					
Mean (SD±)	45.08 (±21.64)	32.58 (±16.62)	-12.50 (±10.51)	28.46 (±14.79)	-16.62 (±13.20)
P-value			<.001		<.001
% improvement			-27.70%		-36.90%
Papules					
Mean (SD±)	6.74 (± 3.09)	5.26 (± 4.10)	-1.48 (±3.02)	4.58 (± 3.37)	-2.16 (±3.36)
P-value			.003		.003
% improvement			-22%		-22%
Pustules					
Mean (SD±)	2.64 (± 2.33)	1.34 (± 1.91)	-1.30 (±2.5)	0.90 ± (1.23)	-1.74 ± 2.41
P-value			<.001		
% Improvement			-49.20%		
All inflammatory lesions					
Mean (SD±)	9.38 (±3.51)	6.60 (±4.87)	-2.78 (±4.08)	5.48 (±4.00)	-3.90 (±3.91)
P-value			<.05		<.05
% Improvement			-29.60%		-41.60%
Erythematous macules					
Mean (SD±)	8.44 (± 6.15)	5.98 ± 6.72	-2.46 ± 6.63	4.16 ± 4.56	-4.18 ± 5.15
P-value			<.001		<.05
% Improvement			-29.10%		-41.60%
Colored marks					
Mean (SD±)	5.70 (± 9.56)	3.74 (± 6.27)	-1.96 (± 4.75)	1.06 (± 2.75)	-4.58 (± 8.40)
P-value			.143		<.001
% Improvement					-81.40%
All residual marks					
Mean (SD±)	9.38 (±3.51)	6.60 (±4.87)	-2.78 (±4.08)	5.48 (±4.00)	-3.90 (±3.91)
P-value			<.001		<.001
% Improvement			-31.30%		-62%

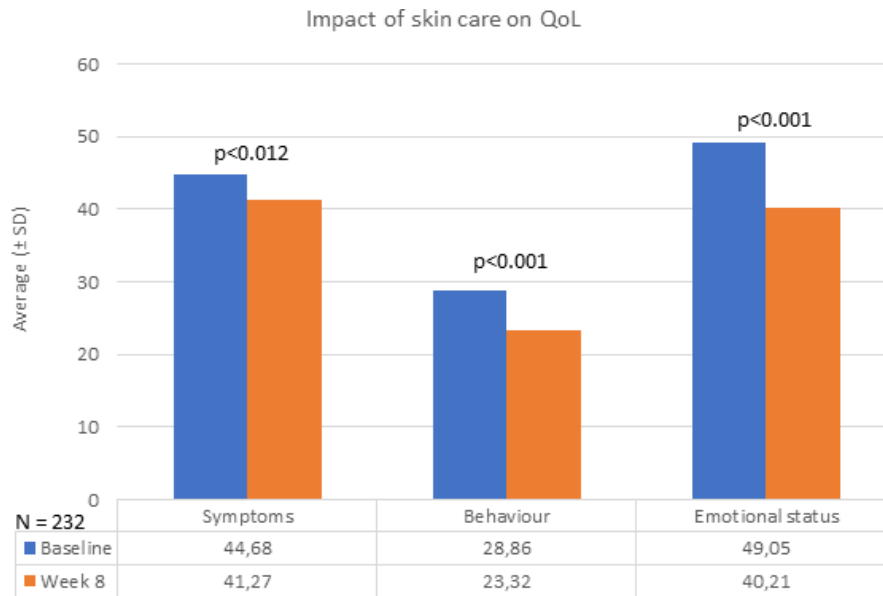


FIGURE 4 Impact on quality of life of the study regimen. The score was obtained from 0% (well-being) to 100% (bad being). A low score represents a good quality of life (QoL), and a high score shows a degradation of the domain. *Symptoms included:* My skin gives me a feeling of discomfort; I have sensitive skin; my skin is irritated. *Behavior included:* My skin condition affects my social life; I tend to stay at home because of the appearance of my skin; my condition affects my contacts with relatives; the appearance of my skin affects my relations with others; I try to keep my skin out of peoples' sight. *Emotional status included:* My skin is not pretty; my skin makes me feel depressed; I don't take pleasure in looking at my skin; I don't take pleasure in touching my skin; I am not happy about my skin; I am hung up about my skin condition; I am obsessed by my skin; my skin problem is stressful; my skin problem makes me unattractive.

TABLE 4 Unmet needs

No	Unmet needs
1	Dermocosmetic formulation for maintenance after retinoid treatment
2	Monotherapy for very mild acne as well as maintenance treatment in adult females
3	Although numerous products help with hydration, there is a need for a topical dermocosmetic formulation that is close to pharmacologic acne treatment—recommended by doctors and obtained
4	A topical product that can safely be given to acne-prone young children and pregnant women
5	Topical acne formulation for preteens and children. Parents do not always agree with off-label use of topical retinoids
6	There is a lack of dermocosmetics for aging skin and acne
7	A topical retinoid combined with BPO suitable for adult females affected by acne
8	A formulation with two main ingredients, to be used as acne maintenance, treatment, and for very mild acne in adult women, targeting the science of aging, that is, corrective acne treatment for adult women
9	There is a need for adjunctive and maintenance treatment for adult women with acne such as products that combine retinoid treatment with dermocosmetics

treatment regimen such as NP may offer a suitable option for adult females with acne either as a monotherapy for the milder acne or in combination with prescription treatments. A combined prescription and non-prescription approach may provide clinical outcomes with more satisfactory results while improving patient QoL. The panel members agreed that there is a role for nonprescription acne products that balance efficacy with tolerability. Finally, they agreed that guidelines for nonprescription acne treatment and

acne prevention, treatment, and maintenance would fill an important unmet need.

5.1 | Limitations

There is a lack of robust evidence on nonprescription acne treatment used for all severity of acne. Moreover, the observation of

the international panel of dermatologists that the incidence of acne among adult women is increasing needs to be supported by evidence.

ORCID

Brigitte Dréno  <https://orcid.org/0000-0001-5574-5825>
 Elena Araviiskaia  <https://orcid.org/0000-0002-6378-8582>
 Delphine Kerob  <https://orcid.org/0000-0003-2816-4261>
 Anneke Andriessen  <https://orcid.org/0000-0001-5930-4162>
 Maryna Anfilova  <https://orcid.org/0000-0001-5609-7399>
 Monika Arenbergerova  <https://orcid.org/0000-0002-7919-9619>
 Olga L. Forero Barrios  <https://orcid.org/0000-0001-9652-2783>
 Zrinka Bukvić Mokos  <https://orcid.org/0000-0002-1180-9759>
 Merete Haedersdal  <https://orcid.org/0000-0003-1250-2035>
 Maja A. Hofmann  <https://orcid.org/0000-0003-3859-234X>
 Ziad Khamaysi  <https://orcid.org/0000-0001-9586-2807>
 Marita Kosmadaki  <https://orcid.org/0000-0003-1723-5036>
 Aleksandra Lesiak  <https://orcid.org/0000-0003-3318-729X>
 Elia Roó  <https://orcid.org/0000-0002-7745-2924>
 Anca Zbranca-Toporas  <https://orcid.org/0000-0002-5474-4182>
 Marni C. Wiseman  <https://orcid.org/0000-0001-9634-3750>
 Sameer Zimmo  <https://orcid.org/0000-0002-0796-7586>
 Lucie Guerin  <https://orcid.org/0000-0001-6978-9933>
 Gabriella Fabbrocini  <https://orcid.org/0000-0002-0064-1874>

REFERENCES

- Bhate K, Williams HC. Epidemiology of acne vulgaris. *Br J Dermatol*. 2013;168(3):474-485.
- Vos T, Flaxman AD, Naghavi M, et al. Years lived with disability (YLDs) for 1160 sequelae of 289 diseases and injuries 1990–2010: a systematic analysis for the Global Burden of Disease study 2010. *Lancet*. 2012;380:2163-2196.
- Tan JK, Bhate K. A global perspective on the epidemiology of acne. *Br J Dermatol*. 2015;172(Suppl 1):3-12.
- Rocha MA, Bagatin E. Adult-onset acne: prevalence, impact, and management challenges. *Clin Cosmet Investig Dermatol*. 2018;11:59-69.
- Hay RJ, Johns NE, Williams HC, et al. The global burden of skin disease in 2010: An analysis of the prevalence and impact of skin conditions. *J Invest Dermatol*. 2014;134(6):1527-1534.
- Auffret N, Claudel JP, Leccia MT, Poli F, Farhi D, Dreno B. AFAST – adult female scoring tool: an easy-to-use tool for scoring acne in adult females. *J Eur Acad Dermatol Venerol*. 2016;30(5):824-828.
- Bhargava S, Cunha PR, Lee J, Kroumpouzou G. Acne scarring management: systematic review and evaluation of the evidence. *Am J Clin Dermatol*. 2018;19(4):459-477.
- Shuah SY, Sheth N, Kurwa HA, Mallipeddi R. Photodynamic therapy followed by Mohs micrographic surgery compared to Mohs micrographic surgery alone for the treatment of basal cell carcinoma: Results of a pilot single-blinded randomised controlled trial. *J Cutan Aesthet Surg*. 2015;8(3):153-158.
- Connolly D, Hi V, Mariwalla K, Saedi N. Acne scarring-pathogenesis, evaluation and treatment options. *J Clin Aesthet Dermatol*. 2017;10(9):12-23.
- Abad-Casintahan F, Chow SK, Goh CL, et al. Frequency and characteristics of acne-related post-inflammatory hyperpigmentation. *J Dermatol*. 2016;43(7):826-828.
- Abanmi A, Al-Enezi M, Al Hammadi A, Galadari I, Kibbi AG, Zimmo S. Survey of acne-related post-inflammatory hyperpigmentation in the Middle East. *J Dermatol Treat*. 2019;30(6):578-581.
- Halvorsen JA, Stern RS, Dalgard F, Thoresen M, Bjertness E, Lien L. Suicidal ideation, mental health problems, and social impairment are increased in adolescents with acne: a population-based study. *J Invest Dermatol*. 2011;131(2):363-370.
- Sundström A, Alfredsson L, Sjölin-Forsberg G, Gerdén B, Bergman U, Jokinen J. Association of suicide attempts with acne and treatment with isotretinoin: a retrospective Swedish cohort study. *Br Med J*. 2010;341:c5812.
- Gollnick HPM. From new findings in acne pathogenesis to new approaches in treatment. *J Eur Acad Dermatol Venerol*. 2015;29(Suppl. 5):1-7.
- Dreno B, Pecastaings S, Corvec S, Veraldi S, Khammari A, Roques C. Cutibacterium acnes (*Propionibacterium acnes*) and acne vulgaris: a brief look at the latest updates. *J Euro Acad Dermatol Venerol*. 2018;32(Suppl 2):5-14.
- Dréno B, Bettoli V, Araviiskaia E, Sanchez Viera M, Boulouc A. The influence of the exposome on acne. *J Eur Acad Dermatol Venerol*. 2018;30:1-8.
- Dreno B, Shourick J, Kerob D, Boulouc A, Taieb C. The role of the exposome in acne: results from an international patient survey. *J Eur Acad Dermatol Venerol*. 2020;34:1057-1064. <https://doi.org/10.1111/jdv.16119>
- Dreno B. What is new in the pathophysiology of acne, an overview. *J Eur Acad Dermatol Venerol*. 2017;31(Suppl 5):8-12.
- Thiboutot DM, Dreno B, Abanmi A, et al. Practical management of acne for clinicians: an international consensus from the global alliance to improve outcomes in acne. *J Am Acad Dermatol*. 2018;78(2):S1-S23.e1
- Nast A, Dreno B, Bettoli V, et al. European evidence-based (S3) guideline for the treatment of acne – update 2016 – short version. *J Eur Acad Dermatol Venerol*. 2016;30(8):1261-1268.
- Thiboutot D, Del Rosso JQ. Acne vulgaris and the epidermal barrier: Is acne vulgaris associated with inherent epidermal abnormalities that cause impairment of barrier functions? Do any topical acne therapies alter the structural and/or functional integrity of the epidermal barrier? *J Clin Aesthet Dermatol*. 2013;6(2):18-24.
- Araviiskaia E, Dreno B. The role of dermocosmetics in acne vulgaris. *J Eur Acad Dermatol Venerol*. 2016;30:926-935.
- Lynde CW, Andriessen A, Barankin B, et al. Moisturizers and ceramide-containing moisturizers may offer concomitant therapy with benefits. *J Clin Aesthet Dermatol*. 2014;7(3):18-26.
- Brouwers MC, Kho ME, Browman GP, et al. AGREE II: advancing guideline development, reporting and evaluation in health care. *Canadian Medical Association Journal*. 2010;182(18):E839-E842.
- Kwon HH, Suh DH. Recent progress in the research about *Propionibacterium acnes* strain diversity and acne: pathogen or bystander? *Internat J Dermatol*. 2016;55(11):1196-1204.
- Qidwai A, Pandey M, Pathak S, Kumar R, Dikshit A. The emerging principles for acne biogenesis: a dermatological problem of puberty. *Human Microbiome J*. 2017;4:7-13.
- Krutmann J, Boulouc A, Sore G, Bernard BA, Passeron T. The skin aging exposome. *J Dermatol Sci*. 2017;85:152-161.
- Norstedt S, Lindberg M. Dietary regimes for treatment of acne vulgaris: a critical review of published clinical trials. *Acta Derm Venerol*. 2016;96:283-284.
- Agamia NF, Abdallah DM, Sorour O, Mourad B, Younan DN. Skin expression of mammalian target of rapamycin and forkhead box transcription factor O1, and serum insulin-like growth factor-1 in patients with acne vulgaris and their relationship with diet. *Br J Dermatol*. 2016;174:1299-1307.
- Cengiz FP, Cevirgen Cemil B, Emiroglu N, Gulsel Bahali A, Onsun N. Acne located on the trunk, whey protein supplementation: is there any association? *Health Promot Perspect*. 2017;7:106-108.
- Lefebvre MA, Pham DM, Boussouira B, Bernard D, Camus C, Nguyen QL. Evaluation of the impact of urban pollution on the

- quality of skin: a multicentre study in Mexico. *Int J Cosmet Sci.* 2015;37:329-338.
32. Lefebvre MA, Pham DM, Boussoira B, et al. Consequences of urban pollution upon skin status. A controlled study in Shanghai area. *Int J Cosmet Sci.* 2016;38:217-223.
33. Perkins AC, Maglione J, Hillebrand GG, Miyamoto K, Kimball AB. Acne vulgaris in women: prevalence across the life span. *J Womens Health.* 2012;21(2):223-230.
34. Tyler KH, Zirwas MJ. Contraception and the dermatologist. *J Am Acad Dermatol.* 2013;68:1022-1029.
35. Rocha M, Sanudo A, Bagatin E. The effect on acne quality of life of topical azelaic acid 15% gel versus a combined oral contraceptive in adult female acne: a randomized trial. *Dermatoendocrinol.* 2017;9(1):e1361572.
36. Cardinali G, Kovacs D, Picardo MI. Mechanisms underlying post-inflammatory hyperpigmentation. *Ann Dermatol Venereol.* 2012;139(Suppl 4):S148-S152.
37. Woolery-Lloyd HC, Kerri J, Doig S. Retinoids and azelaic acid to treat acne and hyperpigmentation in skin of color. *J Drugs Dermatol.* 2013;12(4):434-437.
38. Nestor MS, Bucay VW, Callender VD, Cohen JL, Sadick N, Waldorf H. *Polypodium leucotomos* as an adjunct treatment of pigmentary disorders. *J Clin Aesthet Dermatol.* 2014;7(3):13-17.
39. Tan J, Bissonnette R, Gratton D, et al. The safety and efficacy of four different fixed combination regimens of adapalene 0.1%/benzoyl peroxide 2.5% gel for the treatment of acne vulgaris: results from a randomised controlled study. *Eur J Dermatol.* 2018;28(4):502-508.
40. Fabbrocini G, Rossi AB, Thouvenin MD, et al. Fragility of epidermis: acne and post-procedure lesional skin. *J Eur Acad Dermatol Venereol.* 2017;31(Suppl 6):3-18.
41. Zeichner JA. Inflammatory acne treatment: review of current and new topical therapeutic options. *J Drugs Dermatol.* 2016;15(1 Suppl 1):s11-s16.
42. Jang H, Matsuda A, Jung K, et al. Skin pH is the master switch of kallikrein 5-mediated skin barrier destruction in a murine atopic dermatitis model. *J Invest Dermatol.* 2016;136(1):127-135.
43. Schorr ES, Sidou F, Kerrouche N. Adjunctive use of a facial moisturizer SPF 30 containing ceramide precursor improves the tolerability of topical tretinoin 0.05%: a randomized, investigator-blinded, split-face study. *J Drugs Dermatol.* 2012;11(9):1104-1107.
44. Kar BR, Tripathy S, Panda M. Comparative study of oral isotretinoin versus oral isotretinoin + 20% salicylic acid peel in the treatment of active acne. *J Cutan Aesthetic Surg.* 2013;6:204-208.
45. Baumann LS, Oresajo C, Yatskayer M, et al. Comparison of clindamycin 1% and benzoyl peroxide 5% gel to a novel composition containing salicylic acid, capryloyl salicylic acid, HEPES, glycolic acid, citric acid, and dioic acid in the treatment of acne vulgaris. *J Drugs Dermatol.* 2013;12:266-269.
46. de Lucas R, Moreno-Arias G, Perez-Lopez M, Vera-Casano A, Aladren S, Milani M. Adherence to drug treatments and adjuvant barrier repair therapies are key factors for clinical improvement in mild to moderate acne: the ACTUO observational prospective multicenter cohort trial in 643 patients. *Br Med Clin dermatology.* 2015;15:17.
47. Isoda K, Seki T, Inoue Y, et al. Efficacy of the combined use of a facial cleanser and moisturizers for the care of mild acne patients with sensitive skin. *J Dermatol.* 2015;42(2):181-188.
48. Decker A, Graber EM. Over-the-counter acne treatments: a review. *J Clin Aesth Dermatol.* 2012;5:32-40.
49. Salsberg J, Andriessen A, Abdulla S, et al. A review of protection against exposome factors impacting facial skin barrier function with 89% mineralizing thermal water. *J Cosmet Dermatol.* 2019;18(3):815-820.
50. Claudel JP, Auffret N, Leccia MT, Poli F, Corvec S, Dreno B. *Staphylococcus epidermidis*: a potential new player in the physiopathology of acne. *Dermatology.* 2019;235:287-294.
51. Decker A, Graber EM. Over-the-counter acne treatments: a review. *J Clin Aesth Dermatol.* 2012;5:32-40.

How to cite this article: Dréno B, Araviiskaia E, Kerob D, et al. Nonprescription acne vulgaris treatments: Their role in our treatment armamentarium—An international panel discussion. *J Cosmet Dermatol.* 2020;19:2201–2211. <https://doi.org/10.1111/jocd.13497>