

Plexiglas barrier box to improve ERCP safety during the COVID-19 pandemic

Ljubičić, Neven; Stojšavljević-Shapeski, Sanja; Virović-Jukić, Lucija; Nikolić, Marko

Source / Izvornik: **Gastrointestinal Endoscopy, 2020, 92, 428 - 429**

Journal article, Published version

Rad u časopisu, Objavljena verzija rada (izdavačev PDF)

<https://doi.org/10.1016/j.gie.2020.04.020>

Permanent link / Trajna poveznica: <https://urn.nsk.hr/urn:nbn:hr:105:778064>

Rights / Prava: [In copyright](#) / [Zaštićeno autorskim pravom.](#)

Download date / Datum preuzimanja: **2024-05-26**



Repository / Repozitorij:

[Dr Med - University of Zagreb School of Medicine
Digital Repository](#)



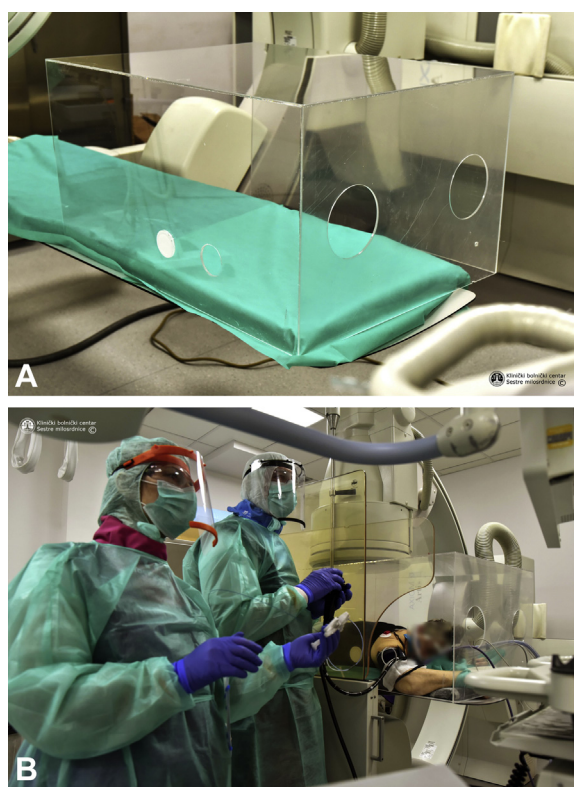
In this case, EUS-FNA was used to differentiate groove pancreatitis from malignancy. This is an interesting point, but in practice an experienced radiologist can usually distinguish between these 2 distinct clinical entities.

Douglas G. Adler, MD, FASGE
GIE Senior Associate Editor
University of Utah School of Medicine
Salt Lake City, Utah

Mohamed O. Othman, MD
Associate Editor for Focal Points



Plexiglas barrier box to improve ERCP safety during the COVID-19 pandemic



Since December 2019, more than 1.5 million cases of COVID-19 infection have been recorded worldwide, and the number of infected patients is rapidly increasing. Medical personnel are at great risk for acquiring COVID-19 infection because of their high exposure to patients' body fluids and the aerosol generated during GI endoscopic procedures. With the idea of minimizing the spread of aerosols during endoscopy, we are using a specially designed transparent Plexiglas box (length 90 cm, width 70

cm, height 60 cm) with a smaller opening on the side for the endoscope (diameter 60 mm) and 2 openings for the anesthesiologist's maneuvers and the passage of various equipment cables (each diameter 150 mm) (**A**). During ERCP, the patients are sedated in the prone position with both arms extended next to the head to facilitate the approach of the anesthesiologist (**B**). The Plexiglas box does not limit necessary access to the patient, the endoscopic procedure, or the quality of the fluoroscopic

view. We have not specifically tested our box model for limitation of aerosol spread, but our device seems to be similar to the device studied for endotracheal intubation recently published by Canelli et al in the *New England Journal of Medicine*.

DISCLOSURE

All authors disclosed no financial relationships.

Neven Ljubicic, MD, PhD, FACG, Department of Gastroenterology, Clinical Hospital Center "Sestre milosrdnice," School

of Medicine, School of Dental Medicine, University of Zagreb, **Sanja Stojasavljevic-Shapeski, MD**, Department of Gastroenterology, Clinical Hospital Center "Sestre milosrdnice," **Lucija Virovic-Jukic, MD, PhD**, Department of Gastroenterology, Clinical Hospital Center "Sestre milosrdnice," School of Medicine, University of Zagreb, **Marko Nikolic, MD, PhD**, Department of Gastroenterology, Clinical Hospital Center "Sestre milosrdnice," School of Dental Medicine, University of Zagreb, Zagreb, Croatia

<https://doi.org/10.1016/j.gie.2020.04.020>

Commentary

Necessity is the mother of invention. The COVID crisis of 2019 to 2020 has made it clear to all concerned that endoscopy in this setting needs to be performed safely, from the perspective of both patients and healthcare providers. The authors in this case have enclosed their patient's head in a clear Plexiglas box to reduce the spread of aerosolized GI secretions. In theory, this device (or a device like it) could be used for any upper or lower endoscopic procedure, including bronchoscopy.

The authors note that they have not tested the actual *ability* of this device to reduce the spread of disease, but perhaps this will come with time. It should be noted that the patient in this case is not intubated and that intubation in the context of general anesthesia is another highly effective way to reduce or nearly eliminate aerosolization of GI secretions (after the intubation procedure itself is complete, of course).

Douglas G. Adler, DMD, FASGE
GIE Senior Associate Editor
University of Utah School of Medicine
Salt Lake City, Utah

Mohamed O. Othman, MD
Associate Editor for Focal Points

Inspissated pill occluding a self-expanding biliary metal stent

