

Konferencijski zbornici - vrijedan izvor novih informacija ili ...?

Čavka, Mislav

Conference presentation / Izlaganje na skupu

Permanent link / Trajna poveznica: <https://um.nsk.hr/um:nbn:hr:105:359035>

Rights / Prava: [In copyright](#) / [Zaštićeno autorskim pravom](#).


Download date / Datum preuzimanja: **2025-01-14**



Repository / Repozitorij:

[Dr Med - University of Zagreb School of Medicine Digital Repository](#)





Konferencijski zbornici – vrijedan izvor novih informacija ili ...?


Paleoradiološki prikaz slučaja

doc. dr. sc. Mislav Čavka, dr. med.
Klinički zavod za dijagnostičku i intervencijsku radiologiju
Klinički bolnički centar “Zagreb”
Katedra za socijalnu medicinu i organizaciju zdravstvene zaštite
Medicinski fakultet Sveučilišta u Zagrebu

“Kako prepoznati lošeg znanstvenika?”

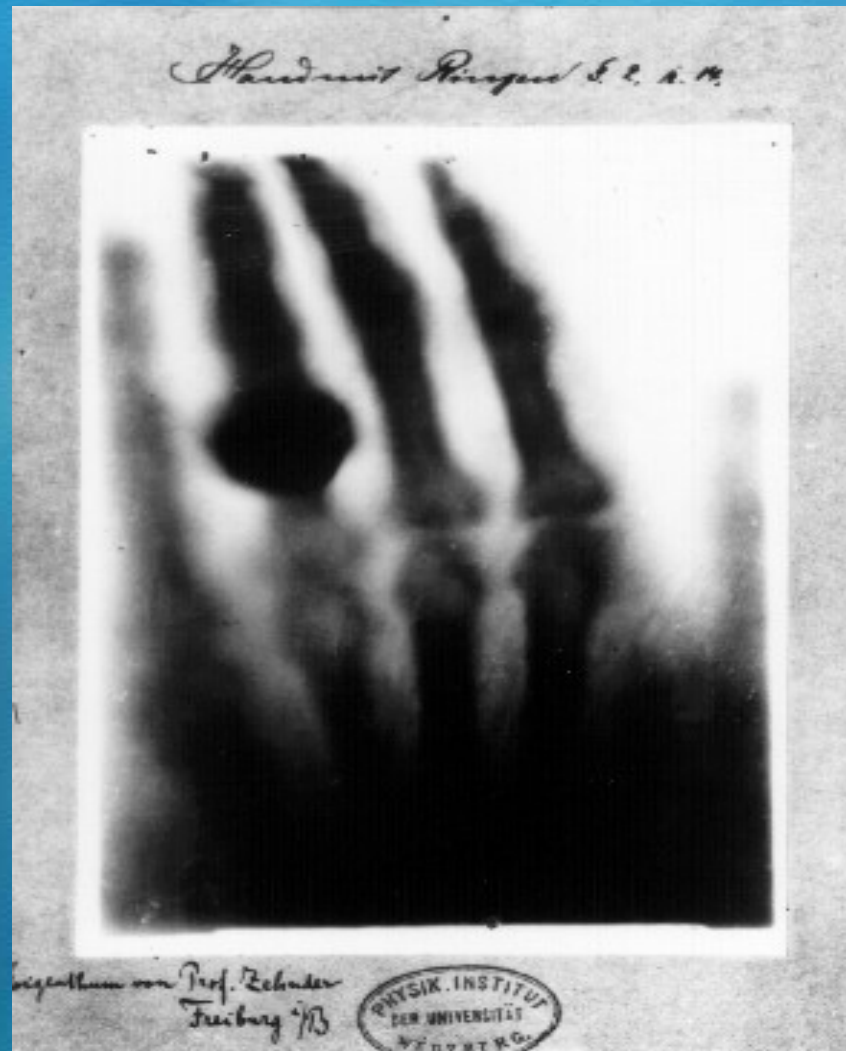Po velikom broju konferencijskih izlaganja??

- Kongresno priopćenje (sažeci) u CC časopisu (5)
- Kongresno priopćenje (sažeci) u ostalim časopisima (6)
- Drugi radovi u zbornicima skupova s recenzijom (2)
- Sažeci u zbornicima skupova (72)
- Neobjavljena sudjelovanja na skupovima (16)

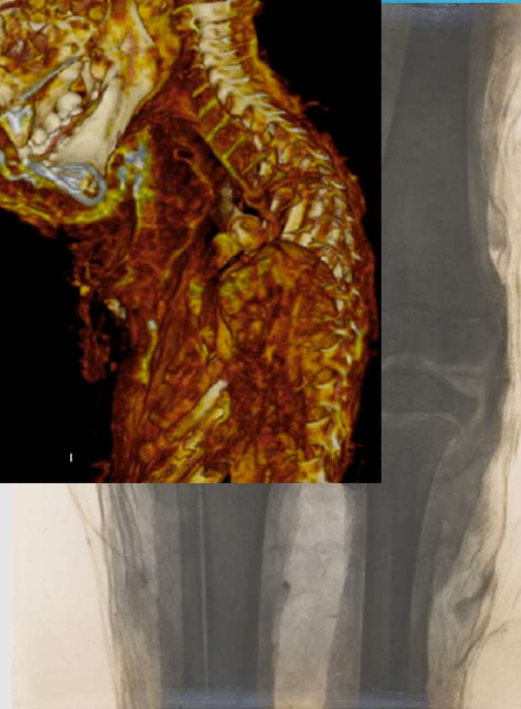
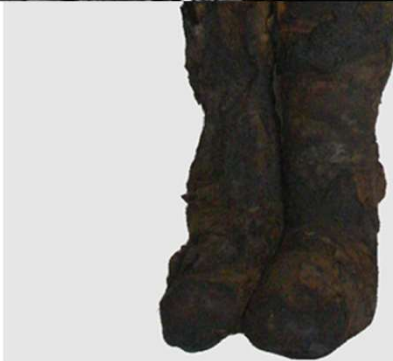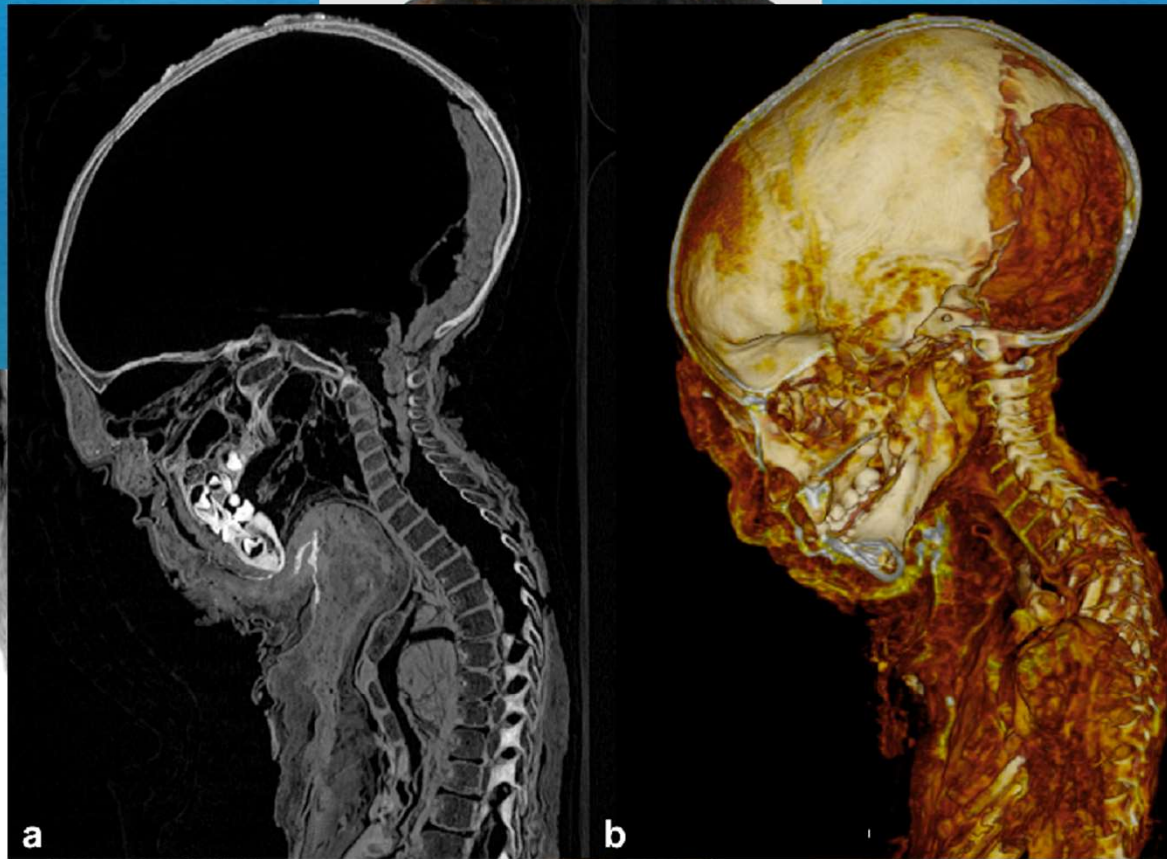
- 
- Veliki broj domaćih kongresa
 - Slabija recenzija
 - Sažetak
 - Visibility / impact?

- Kongresno priopćenje (sažetci) u CC časopisu
- Kongresno priopćenje (sažetci) u ostalim časopisima
- Sažetci u zbornicima skupova
- In extenso / poglavlje u knjizi

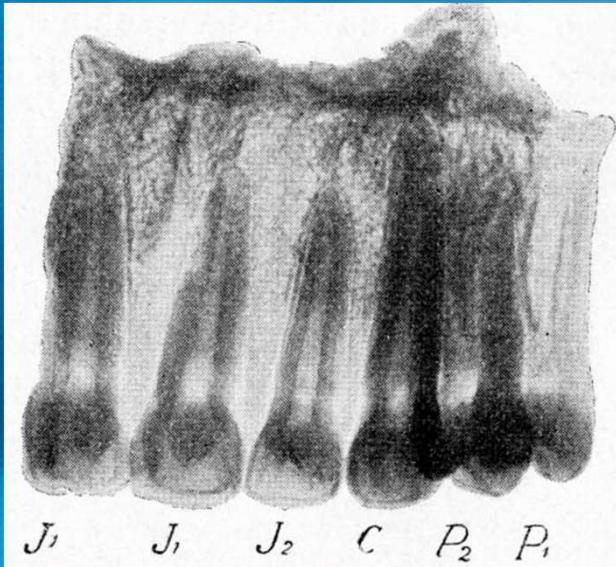
Radiologija



Paleoradiologija



Paleoradiologija



I. Zähne des Oberkiefers (Tafel II, Abb. 9; Tafel III, Abb. 7, 8, 9, 10, 13).
 a) *Incisivi* (Abb. 123). Bezüglich der Schneidezähne bemerke ich, dass ich davon 22 obere und 7 untere besitze. Ich werde hauptsächlich die oberen in Betracht ziehen, weil an ihnen die Schmelzfalten sehr gut ausgeprägt sind, und zwar an der inneren Zahnseite. Doch besteht auch zwischen den oberen Schneidezähnen bezüglich der Fältelung ein Unterschied: an den I_1 sind sie reichlicher, während sie bei den I_2 reduciert (was ihre Anzahl betrifft) auftreten. Die Schmelzfalte ist anfänglich, d. h. an der Kronenbasis stark entwickelt und wird bei den I_1 gegen die Zahnschneide zu durch drei bis vier Einschnitte in vier bis fünf Falten zerlegt, die sich gegen die Schneide zu verlieren. An den I_2 sieht man eine oder auch eine getheilte Längsfalte auftreten. Bei diesen letzteren Zähnen kann sich indessen die Schmelzfalte derartig stark entwickeln, dass sie sich von dem eigentlichen Zahn theilweise löst und eine Art Talon bildet, der beim Kauen mithalf. Den etwas beschädigten Zahn dieser Art habe ich auf Tafel III, Abb. 10, abgebildet und bemerke, dass ich zu dieser extremen Schmelzfaltenbildung Übergänge besitze.
 Ein längster I_2 misst 35·5 mm.

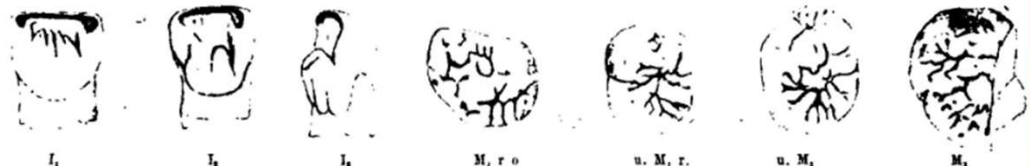

Abb. 123. Schmelzfalten an Incisiven erwachsener Individuen, in 2,1-facher Vergrößerung.

Abb. 124. Schmelzfalten an Molaren erwachsener Individuen in etwa 2,1-facher Vergrößerung.

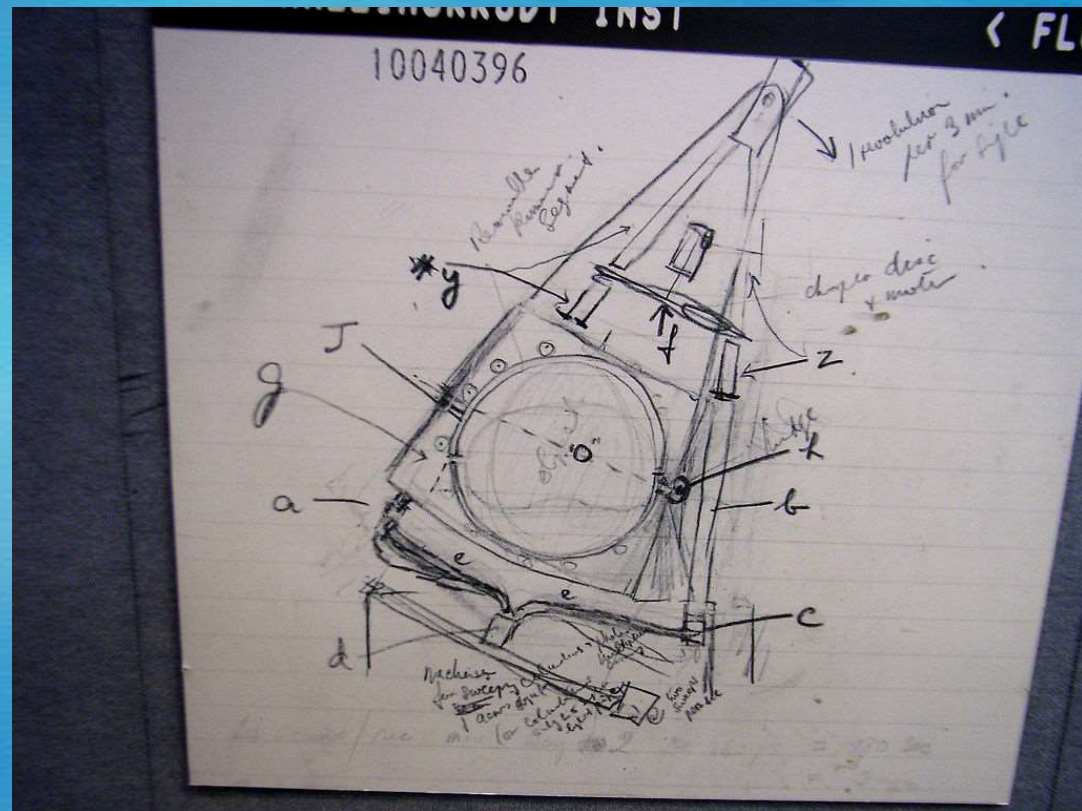

Gorjanovic-Kramberger K. Der palaeolithische Mensch und seine Zeitgenossen aus dem Diluvium von Krapina in Kroatien. Mittheilungen der Anthropologischen Gesellschaft in Wien 1901;31:164-97 (4 plates); 1902;32: 189-216 (4 plates).

Paleoradiologija

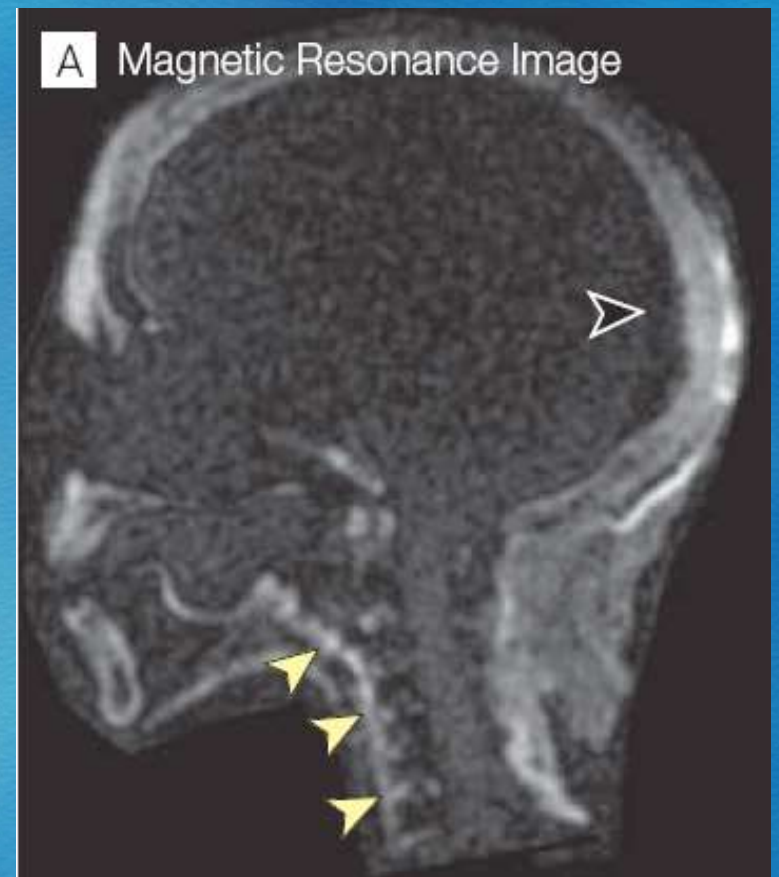
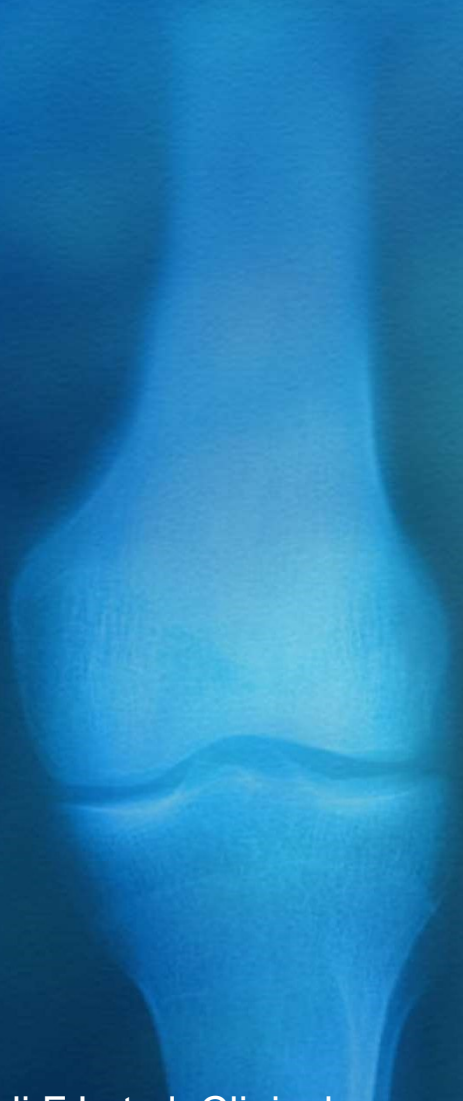EMI congratulates The Beatles
on winning 1964 grammy awards

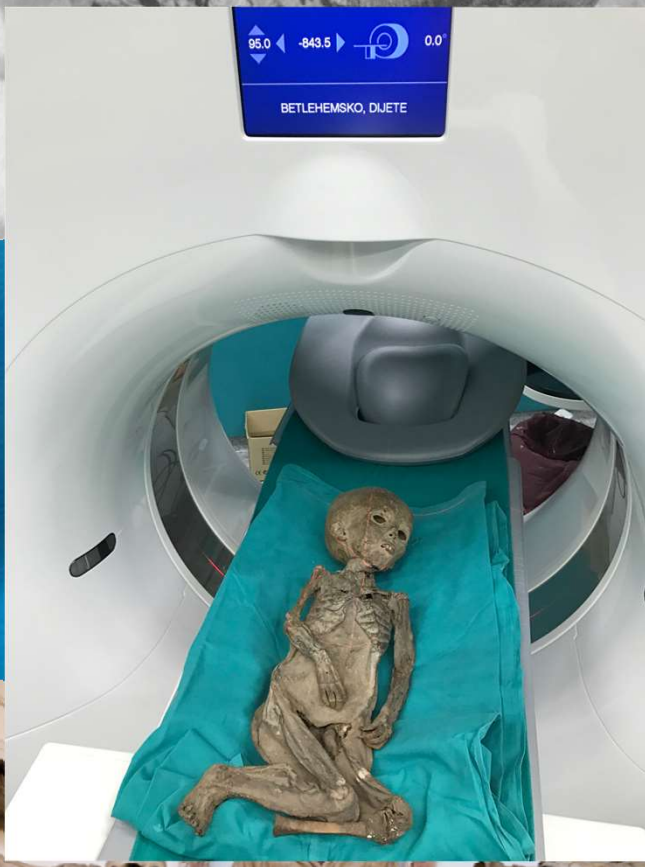
Best performance by a vocal group □□□□□□

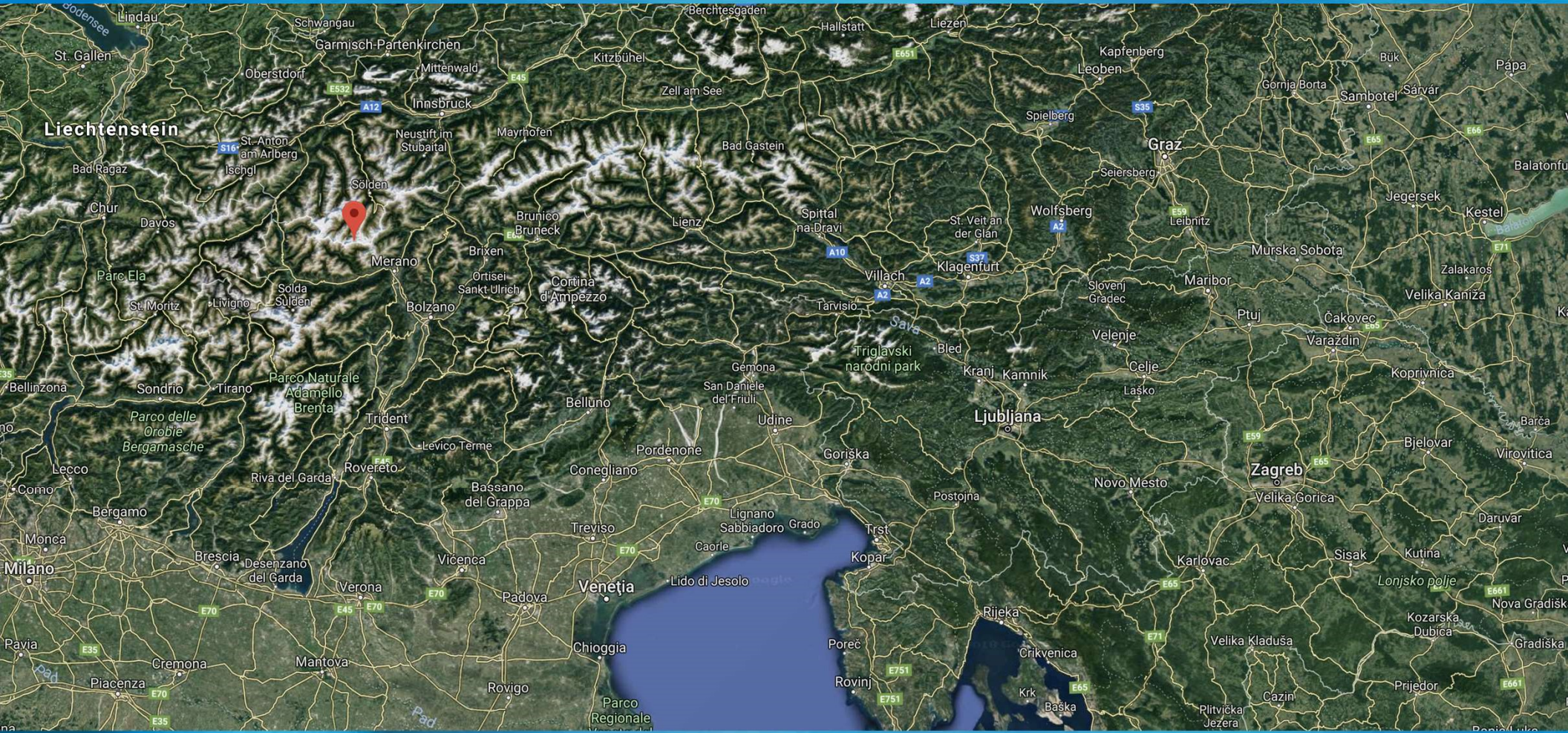● Best new artist of 1964 ●●●●●●●●



Magnetska rezonancija (MR)

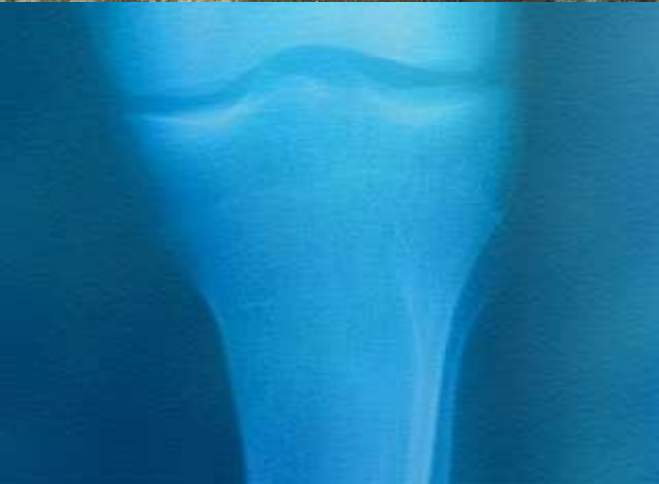




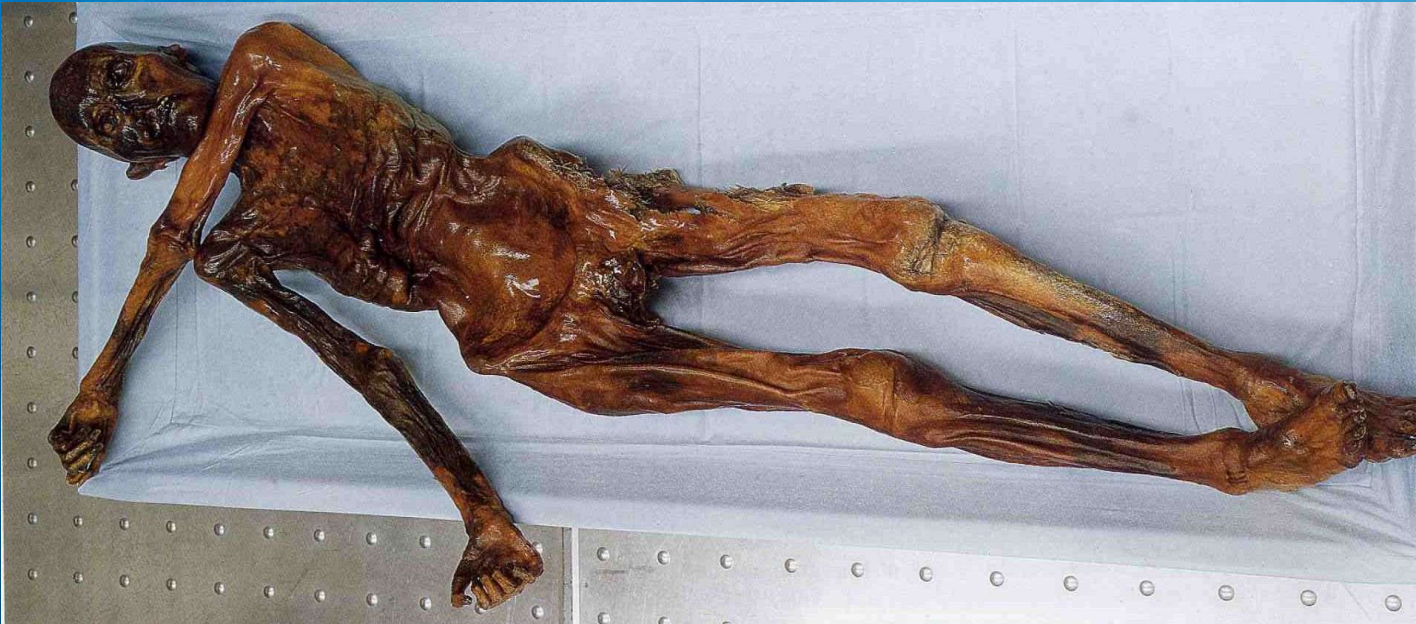


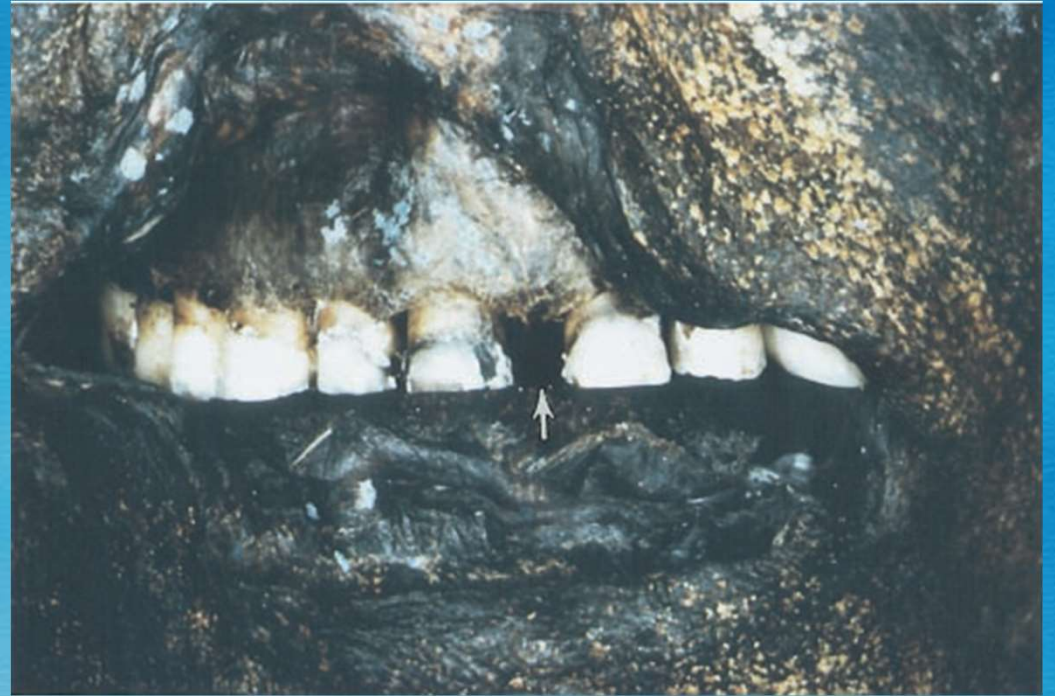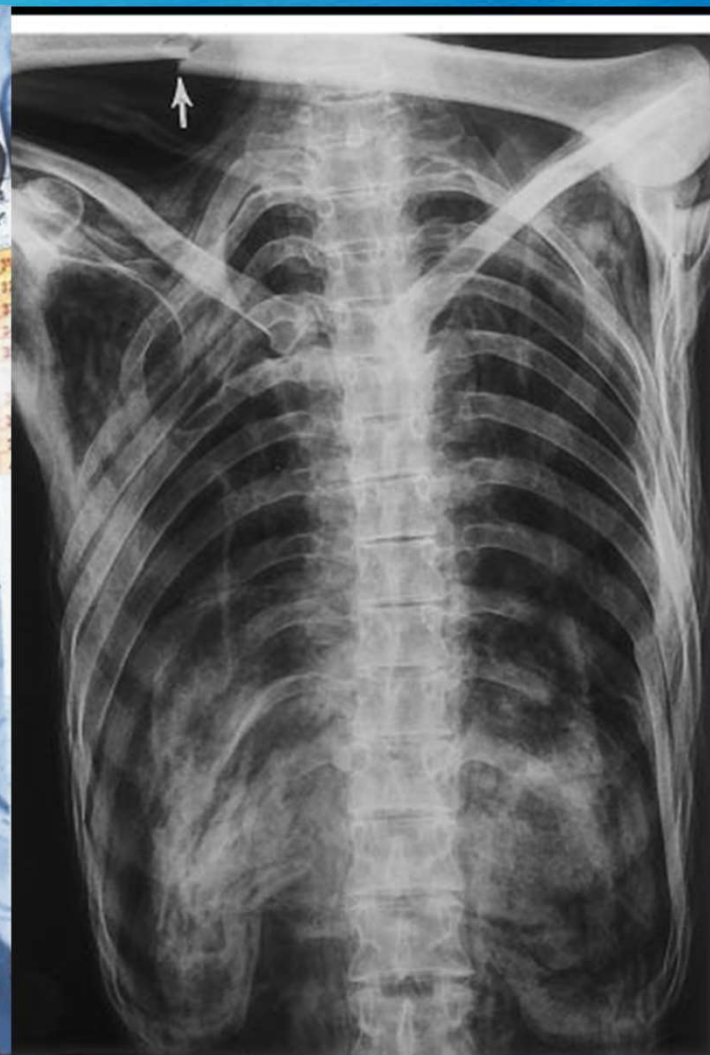



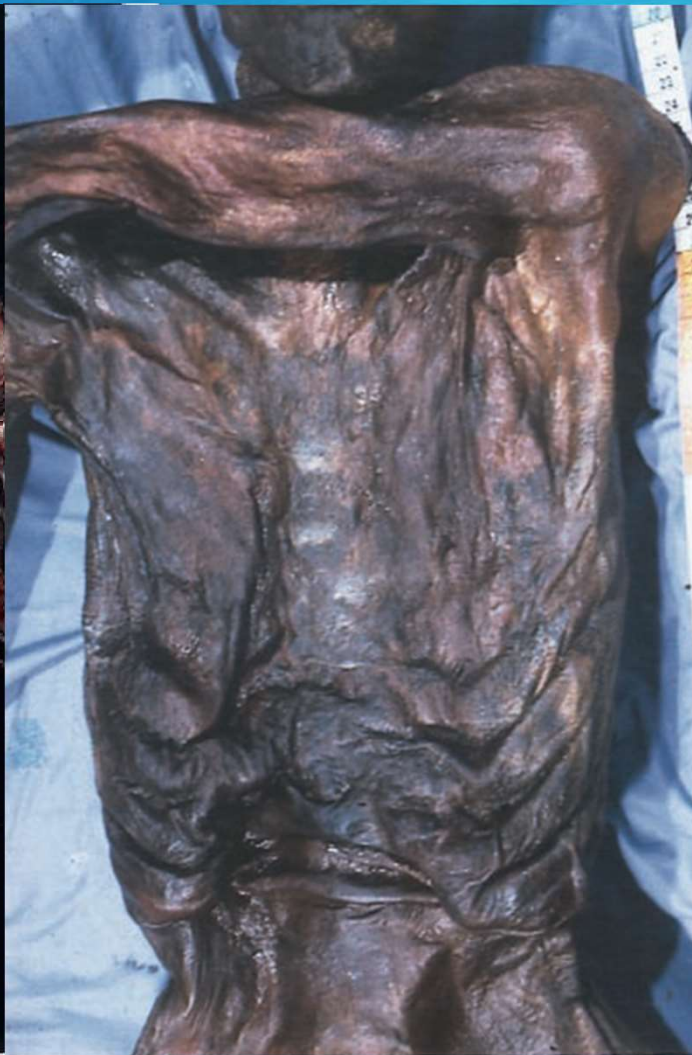
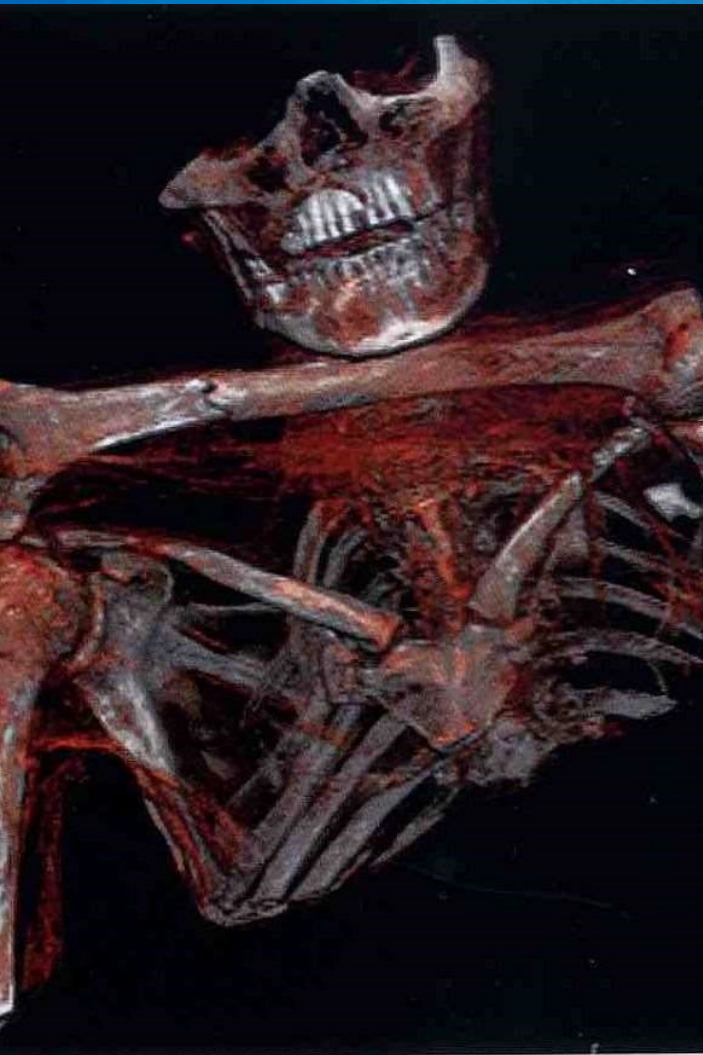

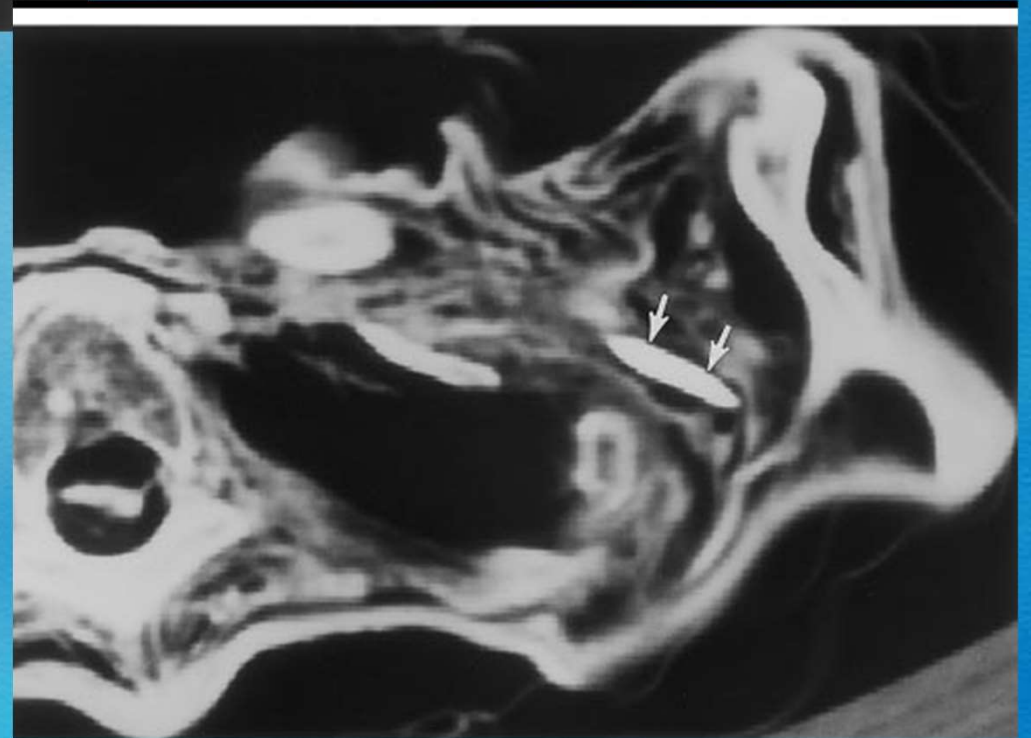





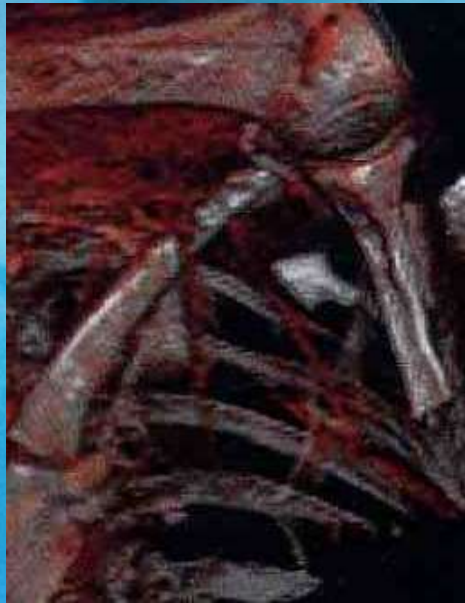
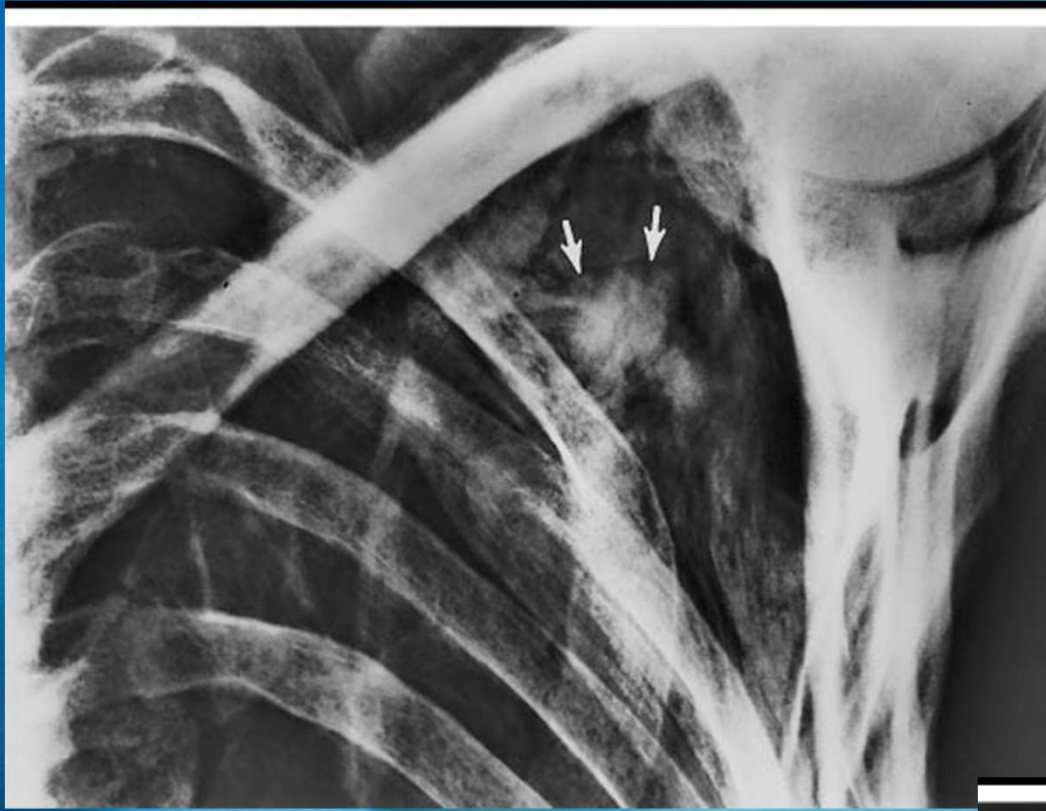Murphy WA Jr, Nedden Dz, Gostner P, Knapp R, Recheis W, Seidler H. The iceman: discovery and imaging. *Radiology*. 2003;226:614-29.

Kean WF, Tocchio S, Kean M, Rainsford KD. The musculoskeletal abnormalities of the Similaun Iceman ("ÖTZI"): clues to chronic pain and possible treatments. *Inflammopharmacology*. 2013;21:11-20.



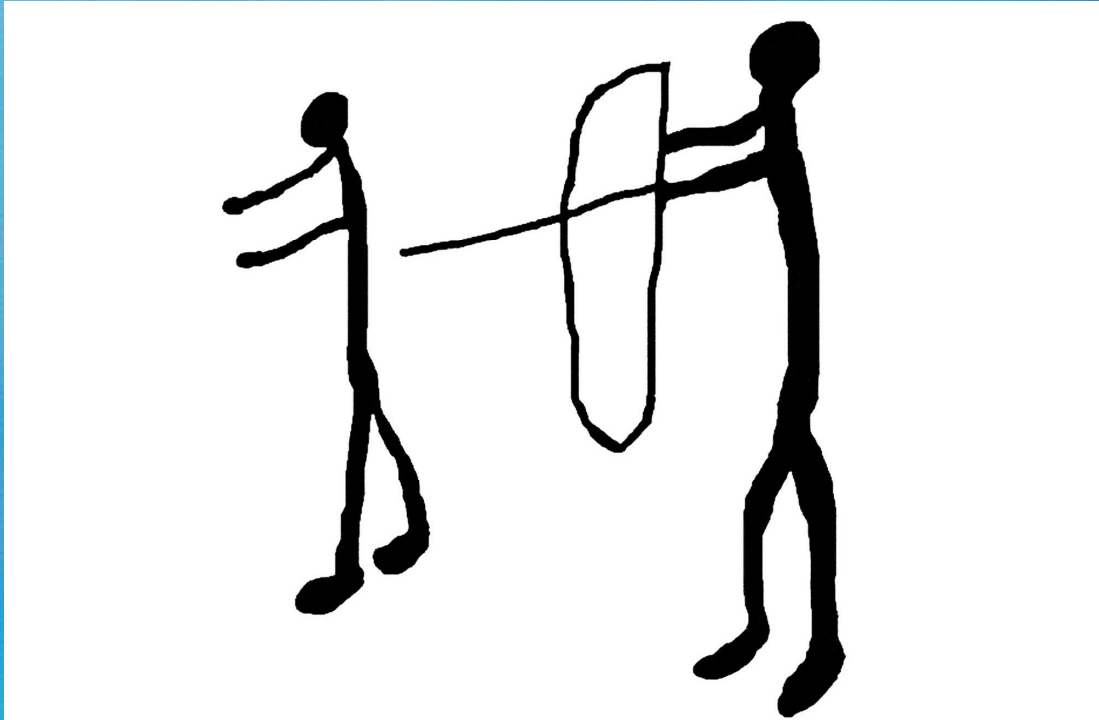


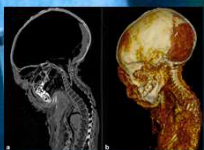
TABLE 1
Chronologic Record of Imaging Examinations

Date	Imaging Method	No. of Images Acquired	Anatomy Studied
September 25, 1991	CT, 4 mm thick	40	Head
	CT, 1 mm thick	47	Head
	CT, 5 mm thick	21	Maxilla, mandible
	CT, 5 mm thick	8	Mandible
	CT, 5 mm thick	26	Neck
	CT, 8 mm thick with 2D and 3D reconstructions	108	Chest, abdomen, pelvis, proximal thigh
	CT, 5 mm thick with 3D reconstructions	38	Head
September 26, 1991	CT, 4 mm thick	54	Midfemora to distal tibiae
	CT, 2 mm thick	44	Ankles
	Conventional radiography	9	Skull, spine, chest, pelvis, knees, ankles
May 25, 1993	Portable computed radiography	23	Skull, spine, chest, abdomen, extremities, hands, feet
April 14, 1994	Spiral CT, 1 mm thick with 2D and 3D reconstructions	222	Head, neck
May 3, 1994	Spiral CT, 5 mm thick with 2D reconstructions	178	Neck, chest, abdomen, pelvis
	Spiral CT, 5 mm thick with 2D reconstructions	196	Pelvis to midfemora
	Spiral CT, 5 mm thick with 2D and 3D reconstructions	298	Acetabulae to feet
March 3, 2001	Spiral CT, 4 mm thick with 2D reconstructions	134	Skull, maxilla, mandible
	Spiral CT, 4 mm thick with 3D reconstructions	104	Chest
	Spiral CT, 2 mm thick	164	Abdomen, pelvis, hips
	Spiral CT, 2 mm thick with 2D reconstructions	368	Midfemora to distal tibiae
	Spiral CT, 1 mm thick with 2D reconstructions	137	Ankles, feet
June 27, 2001	Digital radiography	6	Ribs

Note.—The iceman was imaged on seven separate occasions with a combination of CT and radiography. In all, the examinations generated approximately 2,190 CT and 38 radiographic source images. Many more images were derived from the spiral CT data sets. These images are not tabulated, but they include many two- and three-dimensional reconstructions, postprocessed images for measurement in Hounsfield units, and images optimized to emphasize certain anatomic features. 3D = three-dimensional, 2D = two-dimensional.

Paleoradiologija


1896.



Otkriće X-zraka

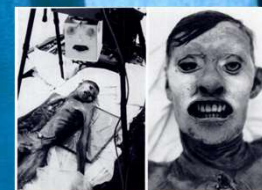Dragutin
Gorjanović
Kramberger

1972.



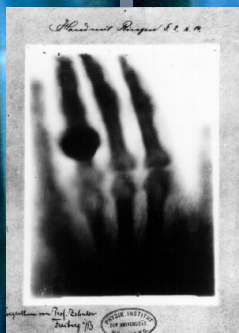Snimljen mozak
mumije CT-om u
Kanadi

1987.



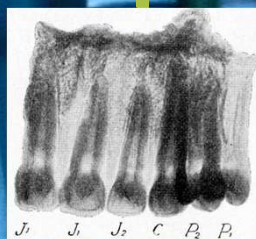
Prvi uspješni MR
mumije bez
rehidracije

Prvo snimanje
mumije RTG-om



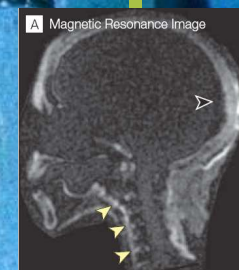
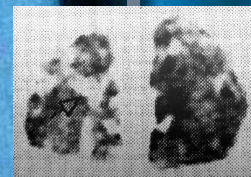
1895.

Izum
kompjuterizirane
tomografije



1901.

Naziv
paleoradiologija



2007.

(males) and 156 cm (females). However, relative femoral strength was high compared to our European Neolithics, and more similar to our European Mesolithics. The combined results indicate a population that was not particularly well nourished and that engaged in hard physical labor. Results are consistent with a scenario in which the later inhabitants of

tomio.

Coall and Chisholm (2003) suggest that differences in the fetal/placental weight (F/P) ratio may reflect variation in intrauterine parent-offspring conflict. Haig (1993) has hypothesized that faced with intrauterine resource restriction, which is likely to happen with an increase in litter size, fetuses may solicit placental resources

full-time or part-time at the time of the survey (n=546), 72% indicated that the need to return to work had a big/some impact on the length of time they breast-fed; 28% returned to work within 6 weeks after giving birth and an additional 49% of mothers returned to work between 7-12 weeks after giving birth. Only 29% of mothers who worked (prenatally and/or postnatally) (n=874) indicated that their

First ever multislice-CT and magnetic resonance imaging of the Iceman, ca. 3300 BC.

Authors FJ Ruhli, E Egarter-Vigl, P Gostner

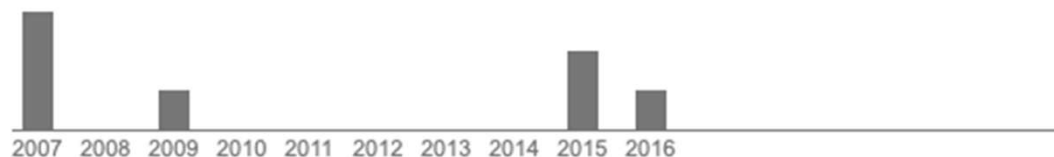
Publication date 2006/1/1

Conference AMERICAN JOURNAL OF PHYSICAL ANTHROPOLOGY

Pages 156-156

Publisher WILEY-LISS

Total citations [Cited by 7](#)



Scholar articles [First ever multislice-CT and magnetic resonance imaging of the Iceman, ca. 3300 BC.](#)
FJ Ruhli, E Egarter-Vigl, P Gostner - AMERICAN JOURNAL OF PHYSICAL ANTHROPOLOGY, 2006
[Cited by 7](#) [Related articles](#)

- Ruhli FJ, Egarter-Vigl E, Gostner P. First ever multislice-CT and magnetic resonance imaging of the Iceman, ca. 3300 BC. AMERICAN JOURNAL OF PHYSICAL ANTHROPOLOGY, 2006:S42;156-156.

Kongresna priopćenja

Comparison of UTE sequence and MSCT in 15 mummified specimens from Archeological Museum in Zagreb

[PDF] from researchgate.net

Authors M Cavka, G Ivanac, A Petaros, Z Sonicki, G Reiter, S Nielles-Vallespin, P Speier, B Brkljacic

Publication date 2012

Journal Poster presented to the European Society of Radiology

Volume 10

Description Purpose

Introduction: Only few months after the discovery of X-rays, first x-ray studies on mummies were performed. Therefore paleoradiology is as old as radiology. Later advances in radiology were applied almost simultaneously in paleoradiology. Mummies are dessicated and lack of unbound protons so magnetic resonance (MR) couldn't be applied without rehydration, which led to permanent destruction of specimens. In 2007 for the first time MR signal was obtained from a dessicated mummy.

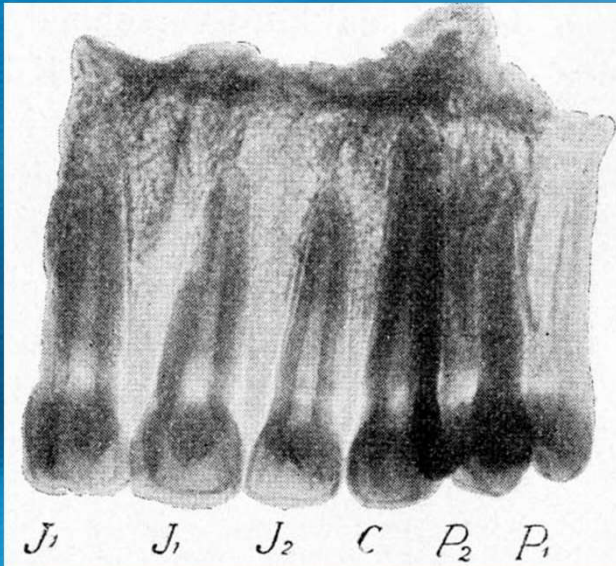
Purpose:

Total citations Cited by 2



2015

Kongresna priopćenja



I. Zähne des Oberkiefers (Tafel II, Abb. 9; Tafel III, Abb. 7, 8, 9, 10, 13).
α) *Incisivi* (Abb. 123). Bezüglich der Schneidezähne bemerke ich, dass ich davon 22 obere und 7 untere besitze. Ich werde hauptsächlich die oberen in Betracht ziehen, weil an ihnen die Schmelzfalten sehr gut ausgeprägt sind, und zwar an der inneren Zahnseite. Doch besteht auch zwischen den oberen Schneidezähnen bezüglich der Fältelung ein Unterschied: an den I₁ sind sie reichlicher, während sie bei den I₂ reduciert (was ihre Anzahl betrifft) auftreten. Die Schmelzfalte ist anfänglich, d. h. an der Kronenbasis stark entwickelt und wird bei den I₁ gegen die Zahnschneide zu durch drei bis vier Einschnitte in vier bis fünf Falten zerlegt, die sich gegen die Schneide zu verlieren. An den I₂ sieht man eine oder auch eine getheilte Längsfalte auftreten. Bei diesen letzteren Zähnen kann sich indessen die Schmelzfalte derartig stark entwickeln, dass sie sich von dem eigentlichen Zahn theilweise löst und eine Art Talon bildet, der beim Kauen mithalf. Den etwas beschädigten Zahn dieser Art habe ich auf Tafel III, Abb. 10, abgebildet und bemerke, dass ich zu dieser extremen Schmelzfaltenbildung Übergänge besitze.
Ein längster I₂ misst 35·5 mm.



Abb. 123. Schmelzfalten an Incisiven erwachsener Individuen, in $\frac{1}{2}$ facher Vergrößerung.

Abb. 124. Schmelzfalten an Molaren erwachsener Individuen in etwa $\frac{1}{2}$ facher Vergrößerung.

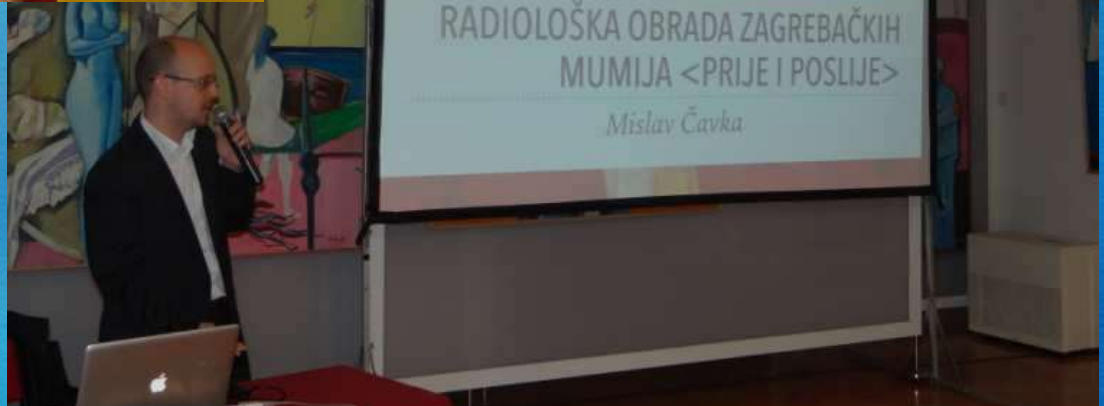Gorjanovic-Kramberger K. Der palaeolithische Mensch und seine Zeitgenossen aus dem Diluvium von Krapina in Kroatien. Mittheilungen der Anthropologischen Gesellschaft in Wien 1901;31:164-97 (4 plates); 1902;32: 189-216 (4 plates).

Kongresna priopćenja

- Brzina i jednostavnost objave
- Efektnija prezentacija rezultata
- Izravnija izmjena rezultata i iskustva



Frank Rühli, President of the Advisory Board for the Iceman



Konferencijski zbornici – vrijedan izvor novih informacija ili ...?

mislav.cavka@yahoo.com

doc. dr. sc. Mislav Čavka, dr. med.
Klinički zavod za dijagnostičku i intervencijsku radiologiju
Klinički bolnički centar “Zagreb”
Katedra za socijalnu medicinu i organizaciju zdravstvene zaštite
Medicinski fakultet Sveučilišta u Zagrebu