

# Transarterial chemoembolization of hepatocellular carcinoma

---

Cetinić, Ivan

Master's thesis / Diplomski rad

2014

Degree Grantor / Ustanova koja je dodijelila akademski / stručni stupanj: **University of Zagreb, School of Medicine / Sveučilište u Zagrebu, Medicinski fakultet**

Permanent link / Trajna poveznica: <https://um.nsk.hr/um:nbn:hr:105:677407>

Rights / Prava: [In copyright](#) / [Zaštićeno autorskim pravom.](#)

Download date / Datum preuzimanja: **2025-03-14**



Repository / Repozitorij:

[Dr Med - University of Zagreb School of Medicine Digital Repository](#)



**UNIVERSITY OF ZAGREB  
SCHOOL OF MEDICINE**

**Ivan Cetinić**

**Transarterial Chemoembolization of  
Hepatocellular Carcinoma**

**GRADUATION PAPER**

Zagreb, 2014

This graduation paper was made at University Hospital Dubrava at the Radiology Department under supervision of Prof. Dr. Sc Boris Brkljacic and it was submitted for evaluation in the academic year 2013/2014.

Abbreviations:

- HCC - Hepatocellular carcinoma
- EASL - European Association for the Study of the Liver
- AASLD - American Association for the Study of Liver Diseases
- AFP - Alpha feto protein
- CT - Computed tomography
- MRI - Magnetic Resonance Imaging
- MELD - Model for End-Stage Liver Disease
- INR - International Normalized Ratio
- CLIP - Cancer of the Liver Italian Program
- AJCC - American Joint Committee on Cancer
- JIS - Japan Integrated Stage
- LCSGJ - Liver Cancer Study Group of Japan
- CUPI - Chinese University Prognostic Index
- BCLC - Barcelona Clinic Liver Cancer
- PST - Performance Status Test
- PET - Positron Emission Tomography
- RFA - Radiofrequency Ablation
- PEI - Percutaneous Ethanol Injection
- TACE - Transarterial Chemoembolization
- TAE - Transarterial embolization
- US - Ultrasound
- SMANCS - Styrene Maleic Acid Neocarzinostatin
- DEB - Drug-Eluting beads
- HIFU - High-Intensity Frequency Ultrasound
- DNA - Deoxyribonucleic Acid
- MWA - Microwave Ablation
- HBV - Hepatitis B Virus
- HCV - Hepatitis C Virus

INTRODUCTION	1
Diagnosis, Indications & Treatment	2
Diagnosis	2
Staging Systems	3
Treatment strategy based on BCLC	8
Radiofrequency Ablation	9
Percutaneous Ethanol Injection	11
Transarterial Chemoembolization	13
High-Intensity Focused Ultrasound	17
Cryoablation	19
Microwave Ablation	21
Discussion	22
Conclusion	23
References	24

# INTRODUCTION

Liver cancer is the second most common cause of death from cancer in the world with an estimated 780,000 new cases and 742,000 deaths in 2012. It has a great geographic variation and is mainly prevalent in less developed regions, which are responsible for 83% of new cases. Out of all new HCC cases, China represents 50% of them. Liver cancer is more common in men with a male-to-female ratio of 2.4. Areas with highest incidence (>20 new cases per 100,000 male inhabitants) of liver cancer include regions such as Eastern Asia (31.9) & South-Eastern Asia (22.2). In more developed regions, such as Northern America & most of Europe, male incidence is much lower at 9.3 and 4.6, respectively. Lowest incidence can be found in Northern Europe (4.6) and South-Central Asia (3.7)<sup>1</sup>.

Since HCC is the predominant primary liver cancer in most countries, aforementioned geographical variations can be used as accurate reflections to the incidence of HCC<sup>1,2</sup>. HCC is the fifth most common cancer worldwide with an expected further increase in incidence the next following years<sup>2,4</sup>.

HCC is a complex disease with a quite well known natural history, except for its early stages<sup>4</sup>. Majority of hepatocellular carcinoma occurs secondarily to chronic liver disease, most commonly liver cirrhosis. Cirrhosis of the liver is characterized by irreversible injury to hepatocytes and diminishing regenerative capacity of the liver resulting in fibrosis of liver tissue and destruction of hepatocytes, eventually leading to development of neoplastic changes<sup>5</sup>. Known etiologies of cirrhosis & HCC include viral Hepatitis B, which is estimated to be responsible for at least 50% of cases worldwide, Hepatitis C for 25% and remaining part to be associated with other risk factors<sup>2,5,6</sup>. Such as alcoholic liver disease, intake of aflatoxin, nonalcoholic steatohepatitis, diabetes, obesity, high fructose intake, and hereditary hemochromatosis<sup>4,8,9</sup>.

Due to the complexity of HCC, selection of treatment depends on several factors, such as extent of the disease, location, underlying liver function and general condition of the patient. All important for establishing the development and prognosis of the disease. A multidisciplinary team comprising, but not restricted to, of hepatologists, surgeons, oncologists, radiologists (including interventional), transplant surgeons and pathologists are all important in order to evaluate a certain treatment plan for patients with HCC. (3)

Staging systems are essential to evaluate the prognostics of patients with HCC and to guide the therapeutic approach<sup>4,10,11</sup>.

Curative therapies include surgical removal of the tumor lesion, liver transplantation & certain percutaneous ablative treatments. These therapies are aimed at patients who were diagnosed at an early stage of HCC. Patients with more advanced HCC are treated with minimally invasive therapies, systemic drugs or conservatively, which are aimed at improving quality of life and life expectancy (8). Unfortunately, due to its complex pathological course and late diagnosis, HCC still has a very poor prognosis (overall ratio of mortality to incidence is 0.95)<sup>1</sup>.

In the last 30 years, much of the medical development and innovation in minimally invasive procedures that are used throughout the world today, are methods pioneered by interventional radiologists. The essential Seldinger technique introduced in year 1953<sup>7</sup>, first embolization therapy in 1966 and further additional advances that lead to development of new ideas and technologies to treat various types of conditions. Important benefits notable with minimally invasive methods compared to open surgery include reduced postoperative pain, reduced trauma, shorter hospital stay and lower risk of infection.

In this thesis we will explain various staging systems that are used to divide patients, cover treatment options that are available to patients with liver tumor, provide a detailed explanation of transarterial chemoembolization and other minimally invasive treatment modalities, and conclude with a discussion of the role of transarterial chemoembolization and other therapies in the battle of hepatocellular carcinoma & other liver tumors.

# Diagnosis, Indications & Treatment

It's very important to divide patients into groups in order to provide the best possible care. This is crucial since patients are at a different stage of their disease and at a different level of health. In the treatment of hepatocellular carcinoma and other liver tumors, several classifications and guidelines have been developed throughout years to easily separate the growing number of patients. Although surgical resection or liver transplantation are one of the currently available curative treatments, approximately only 20-30% of the patients are viable for undergoing such complex procedures<sup>13-15</sup>. This review paper will mainly cover non-invasive therapeutic modalities, which are suitable to the remaining patients.

## Diagnosis

Imaging plays a key role in the diagnosis, and cirrhotic patients should be put under regular surveillance since 80% of new HCC cases arise in the setting of cirrhosis<sup>10</sup>. Recommendations from the European Association for the Study of the Liver (EASL) is to enroll cirrhotic patients, who wish to be treated for HCC, into a biannual surveillance program which includes an abdominal ultrasound examination and a sample to measure serum alfa-fetoprotein (AFP). A similar program is recommended by the American Association of the Study of Liver Diseases (AASLD). Upon discovery of a mass on ultrasound in cirrhotic patients (Figure 1), EASL recommends nodules smaller than 1 cm to be closely followed up (3-4 months). If the mass is larger, between 1 and 2 cm, two samples of dynamic imaging techniques, such as contrast enhanced CT or MRI should be performed because they are able to detect a certain type of vascular pattern that is specific to hepatocellular carcinoma. This can be observed following rapid IV infusion of contrast. Computer tomography or MRI can detect differences in the uptake of contrast throughout liver tissue. Hepatocellular carcinoma is generally nourished by the hepatic artery and shows an increased uptake during the arterial phase (first 2-40 seconds), while the remaining normal liver parenchyma is enhanced during the venous phase (50-90 seconds after infusion)<sup>16</sup>. If imaging is unsuccessful or shows an atypical vascular pattern, a liver biopsy or cyto-histology needs to be performed. In cases of larger nodules (>2cm), one imaging technique with typical vascular presentation is sufficient, or an AFP level of >200 ng/ml (AASLD) or >400 ng/ml (EASL) to diagnose HCC<sup>15,16</sup>. However in many facilities and institutions, histological evidence of HCC is required before extensive treatment<sup>15</sup>. Angiography as a diagnostic tool has been limited due to its poor detection rate of small tumors. PET scan has also limited use, and is mainly aimed to detect extrahepatic spread<sup>16</sup>.

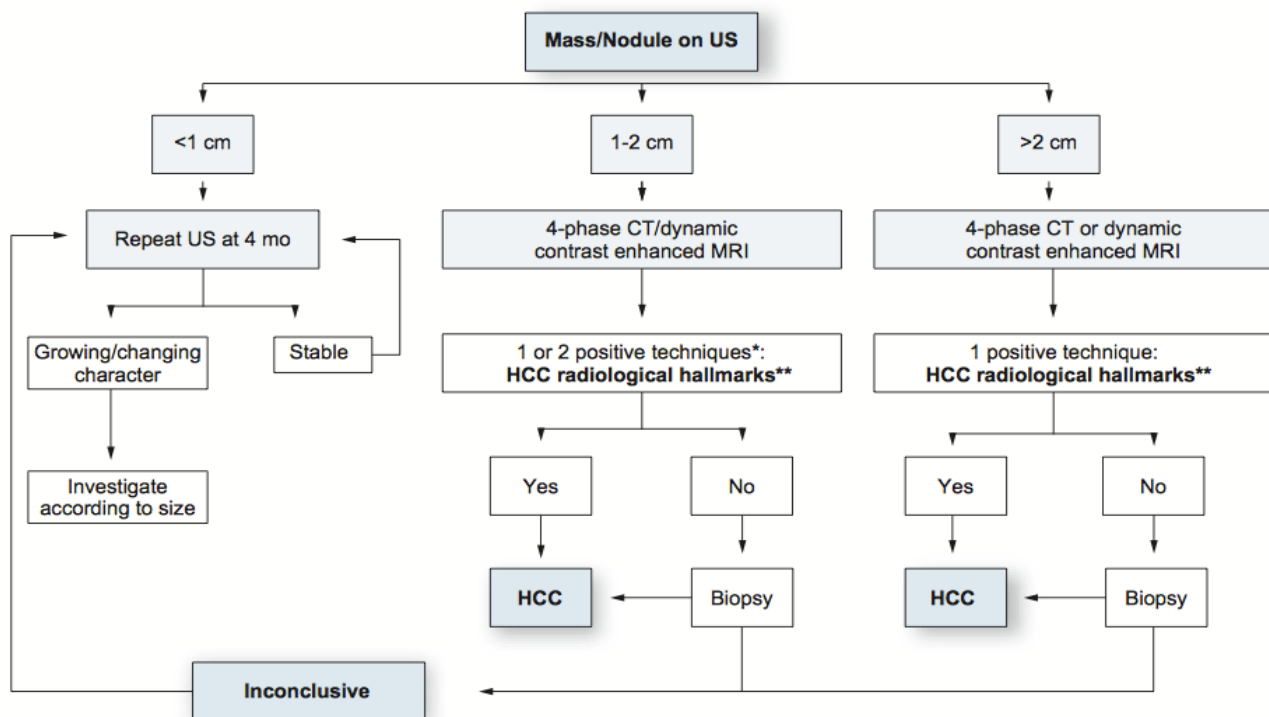


Figure 1. Diagnostic algorithm upon detection of liver mass in cirrhotic patient. Courtesy of European Association for the Study of the Liver<sup>23</sup>.

## Staging Systems

Staging systems are valuable tools to classify patients with cancer into groups. It's meant to determine prognostic outcome, guide therapeutic approach and exchange information among researchers. With hepatocellular carcinoma and liver tumors there have always been problems in standardizing classifications and therapies accordingly. In response to this, several staging systems have been produced worldwide to find a solution. As previously mentioned HCC usually occurs in association with chronic liver disease and cirrhosis. The first staging systems we will review are concerned about underlying liver function and its correlation with survival after surgery.

Table 1 Child-Pugh Score			
Measure	1 Point	2 Points	3 Points
Total Bilirubin (mg/dl)	<2	2-3	>3
Serum Albumin (g/dl)	>3.5	2.8-3.5	<2.8
PT INR	<1.7	1.71-2.30	>2.30
Ascites	None	Mild	>Moderate
H. Encephalopathy	None	Grade 1-2	Grade 3-4

*Child-Pugh score* (Table 1) is one of the oldest methods used to assess the severity of chronic liver disease and cirrhosis. It's a key component in many staging classifications today due to its simple and efficient grading system for liver function. Child-Pugh score is divided into Class A (5-6 points), B (7-9) and C (10-15). Class A is associated with 100% 1-year survival rate, and B and C with 80% & 45%, respectively. Only patients with Child-Pugh Score A are available for surgical resection (52).

Model for End Stage Liver Disease (MELD) was designed to predict short-term survival of patients undergoing liver transplantation. It takes into account the patients values for serum bilirubin, serum creatinine and the international normalized ratio for prothrombin time (INR) in the following formula:

$$\text{MELD Score} = (0.957 * \ln(\text{Serum Cr}) + 0.378 * \ln(\text{Serum Bilirubin}) + 1.120 * \ln(\text{INR}) + 0.643) * 10$$

(if patient is on hemodialysis, value for Creatinine is automatically set to 4.0)

The 3 month mortality rate in patients scored by MELD is 1.9% for a score of less than 9, 6% for 10-19, 19,6% for 20-29, 52.6% for 30-39% and 71.3% for a score higher than 40.

In order to assess the prognosis and possible curative treatment (surgical resection) for these patients, the Child-Pugh Score can be used in conjunction with MELD score.

The following staging classifications are focused on liver tumors.



### Okuda System

The Okuda classification system is one of the oldest systems focused on prognosis of HCC. It originates from 1985<sup>17</sup> and is based on four factors (Table 2). One parameter concerning the size of the tumor liver area involvement - more or less than 50%), and three related to liver status (ascites, albumin and bilirubin) (7). The classification is useful for end-stage patients due to its ability to stratify patients on advanced levels of HCC. Today with improved imaging and diagnostic technique, earlier diagnosis is more common and Okuda falls short in complete HCC staging due to its poor classification of early stage patients.

Table 2 Okuda Staging		
Factors associated with advanced disease -Albumin level <3g/dL -Ascites -Bilirubin <3g/dL Tumor size > 50% of liver		
Stage 1	No factors present	
Stage 2	1-2 factors	
Stage 3	3-4 factors	

### CLIP Score

The Cancer of The Italian Program (Table 3) score was developed in 1998 from a retrospective analysis of 435 patients with HCC between 1990-1995. This staging system takes into account Child-Pugh Class, AFP level, tumor morphology (whether it's unifocal & <50%, multifocal (<50%) or diffuse (>50%) and whether there is vascular invasion) and presence or absence of portal vein thrombosis. CLIP is designed mainly for advanced liver tumors, since it only discriminates tumor invasion of either more or less than half the liver. However CLIP was shown to be a good predictor of recurrence in hepatitis B patients with HCC who underwent curative resection<sup>10,18,19</sup>.

Table 3 Cancer of the Liver Italian Program				
Score	0		1	2
Child-Pugh Stage	A	B		
Tumor Morphology	uninodular & extension ≤ 50%	multinodular & extension ≤50%	multinodular & extension > 50%	
AFP (ng/dL)	<400	≥400		
Portal vein thrombosis	No	Yes		

### TNM Stage

The conventional TNM staging system, which has been endorsed by the American Joint Committee on Cancer (AJCC), measures the primary tumor features (T) (Table 4), regional lymph nodes (N) (Table 5) and presence of distant metastasis (M) (Table 6). It's main drawback was the lack of assessment of liver function, but newer revisions have included level of fibrosis and histological grade. In a review by S. Subramaniam et al from 2013<sup>18</sup>, they state that TNM staging for HCC is unable to properly assess liver function, offer guidance on resectability and prognostic value of patients in advanced liver diseases.

### Japan Integrated System

The Japan Integrated System (JIS) is a newer staging score system (Table 7), which was developed by the The Liver Cancer Study Group of Japan (LCSGJ) in 2003<sup>20</sup> to evaluate prognosis in patients of earlier stages

of HCC. This differs JIS from Okuda & CLIP, which are both unable to properly establish prognostic value in early-stage patients. JIS incorporates a modified LCSGJ-TNM staging system and Child-Pugh Score on a score based from 0-10. It has been validated in Asian populations and shown to better assess prognostic values for early-stage patients than CLIP, but has not been validated nor gathered traction in Western population<sup>18</sup>.

Table 4 Primary Tumor TNM, From American Joint Committee on Cancer (AJCC)	
Tx	Primary tumor can not be assessed.
T0	No evidence of primary tumor.
T1	Solitary tumor without vascular invasion.
T2	Solitary tumor with vascular invasion or multiple tumors none >5 cm.
T3a	Multiple tumors >5 cm.
T3b	Single tumor or multiple tumors of any size involving a major branch of the portal vein or hepatic vein.
T4	Tumor(s) with direct invasion of adjacent organs other than the gallbladder or with perforation of visceral peritoneum.

Table 5 Regional Lymph Nodes TNM Staging From AJCC	
NX	Regional lymph nodes cannot be assessed.
N0	No regional lymph node metastasis.
N1	Regional lymph node metastasis.

Table 6 Distant Metastasis TNM Staging. From AJCC	
M0	No distant metastasis.
M1	Distant metastasis

Table 7 Japan Integrated System				
Score	0	1	2	3
Child-Pugh Stage	A	B	C	
Stage by LCSGJ	1	2	3	IVA or IVB

### *CUPI*

The Chinese University Prognostic Index (Table 8) was announced in 2002 from a retrospective analysis of 929 patients, which were predominantly hepatitis B positive. It includes TNM staging, AFP level, Bilirubin level, Alkaline Phosphatase level, assessment of ascites and if patient was asymptomatic or not on disease presentation<sup>21</sup>. Comparison to CLIP & Okuda was made in the same study and concluded that CUPI showed better survival rate. However more recent studies<sup>10,18</sup> declare that CUPI shows questionable early prognostic values and wasn't fully compatible in Western populations, with predominantly Hepatitis C patients.

Table 8 Chinese University Prognostic Index	
TNM Stage	
1 & 2	-3
3a & 3b	-1
4a & 4b	0
Asymptomatic disease on presentation	-4
Ascites	3
AFP $\geq$ 500 ng/mL	2
Total Bilirubin (umol/L):	
< 34	0
34-51	3
$\geq$ 52	4
ALP $\geq$ 200 IU/L	3

*Barcelona Clinic Liver Cancer Staging System*

The last staging system we will cover is The Barcelona Clinic Liver Cancer Staging System (BCLC) which is considered the standard scoring system for HCC staging (Figure 2). It was developed from a single institution and based from results of cohort and randomized control trial studies<sup>15</sup>. BCLC has been endorsed by the American Association for the Study of Liver Disease (AASLD) & the European Association for the Study of Liver Disease (EASL)<sup>18</sup>. Several studies have shown it to be the most comprehensive & applicable staging system for hepatocellular carcinoma<sup>10, 18, 22, 23</sup>. BCLC staging system incorporates both prognostic and treatment indications, depending on what stage a patient is classified into. The 5 stages are divided into 0, A, B, C & D from a set of factors, including Okuda Stage, Child-Pugh Score, performance status test (PST), bilirubin, portal hypertension, tumor nodules, and presence of vascular invasion/extrahepatic spread. PST translates into presence of cancer-related symptoms.

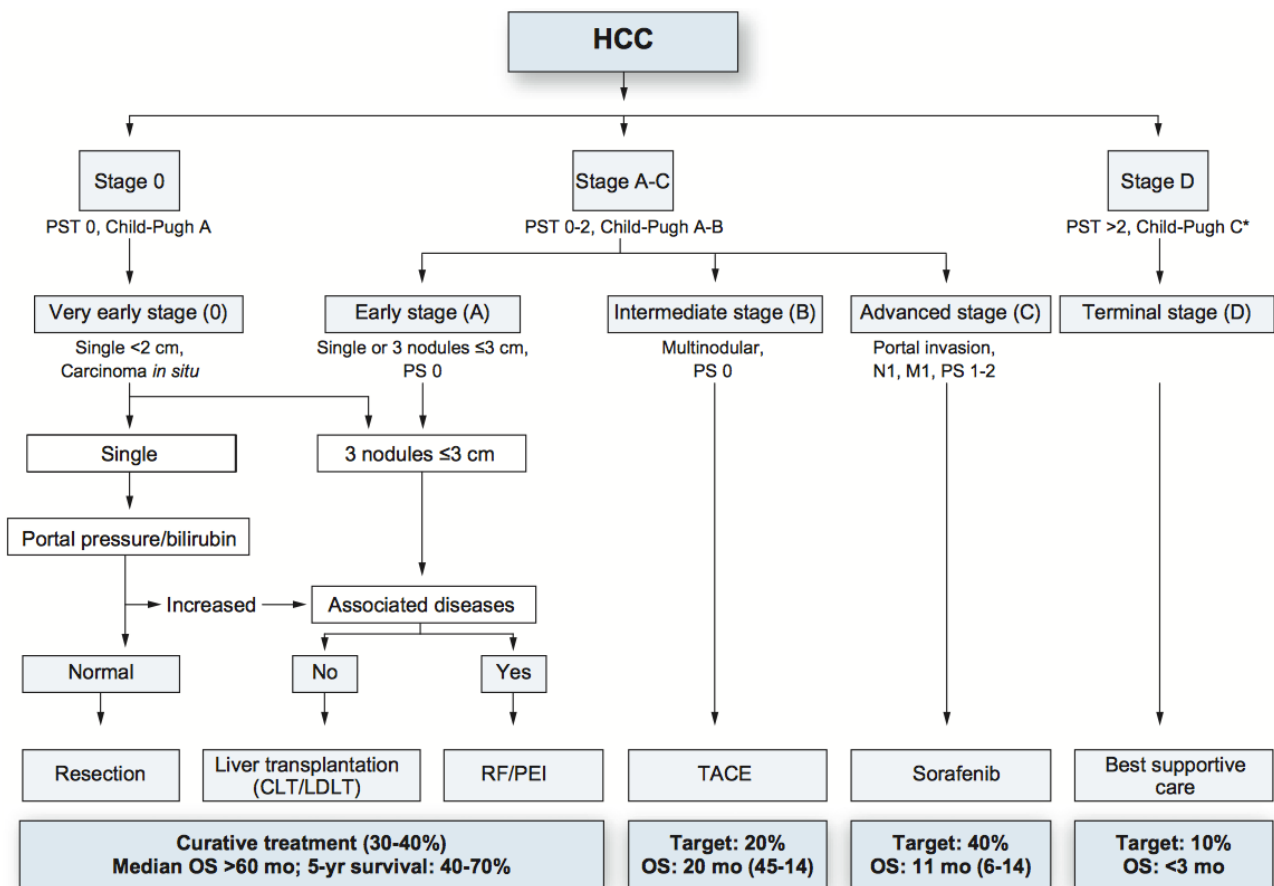


Figure 2. Overview of Barcelona Clinic Liver Cancer staging system. Courtesy of European Association for the Study of the Liver<sup>23</sup>.

## Treatment strategy based on BCLC

### **Very Early Stage (0) & Early Stage (A)**

Stage 0 is defined in asymptomatic patients with a small single solitary nodule lesion (less than 2 cm) and with preserved liver function. Approximately 5-10% of patients in Western population are diagnosed at this stage, the figure is 3-5 times higher in Japan due to widespread implementation of surveillance programs<sup>23</sup>. Best possible treatment for patients in the earliest stage is surgical resection with 5-year survival rates around 70%<sup>15,24</sup>. Situations that preclude resection are the presence of portal vein thrombosis reflecting extensive disease, lymph node metastases, extrahepatic localizations and intrahepatic multiple, diffuse disease. When HCC arises in non-cirrhotic liver it is often diagnosed when the tumor becomes large and symptomatic. In the absence of diffuse disease involving both lobes or metastases, aggressive surgical management of HCC is indicated in non-cirrhotic liver. In these patients resection of the tumor may be considered no matter its size, since they are usually in good general condition and surgical resection usually involves the tumor mass rather than the functional parenchyma.

Early Stage A group include patients with a single tumor lesion up to 5 cm or 3 nodules less than 3 cm each. They are also suitable for surgical resection as long as they have preserved liver function, but because cirrhosis affects majority of HCC patients and have a reduced liver function, liver transplantation is a more suitable option. Theoretically, the liver transplantation may cure the liver and cirrhosis at the same time. Studies show a 5 year survival rate of about 50% up to 70% in liver transplantation patients, unfortunately the biggest issue in this treatment modality is the prolonged waiting time<sup>10,12,23</sup>. Patients who are not candidates for surgical resection can undergo local ablation treatment such as radiofrequency ablation & percutaneous ethanol injection. Both are covered in more detail in the following chapters.

### **Intermediate Stage (B)**

Patients with compensated cirrhosis and HCC who do not fit the criteria of early stage, who have not yet presented cancer-related symptoms or vascular invasion or extrahepatic spread, correspond to the intermediate stage. Majority of this thesis will cover treatment options in this group and focus will be on transarterial chemoembolization.

### **Advanced Stage (C)**

Patients in stage C present with cancer-related symptoms (PST) and with either extrahepatic spread (such as metastases or spread to lymph nodes) or vascular invasion. They have for a long time not been suitable for any radical therapies. By 2006<sup>12</sup> there was no convenient therapy for these patients. Recent studies with Sorafenib, an agent targeting tyrosine-kinase pathways, has provided hope for patients in this group and showed to increase median survival from 6 months to up to 14,7 in these patients<sup>23</sup>.

### **Terminal Stage (D)**

The last stage in the Barcelona Clinic Liver Cancer staging system includes patients with Child-Pugh C & with poor physical health. They have a 1-year survival rate of around 10% and are candidates for supportive care<sup>15</sup>.

## Radiofrequency Ablation

The currently most used percutaneous thermoablative modality in the world is radiofrequency ablation (RFA). The last decade has seen a great expansion of this technique due to its impressive safety and efficacy.

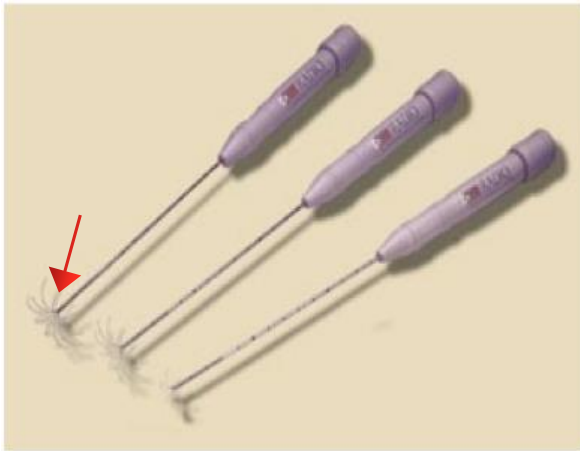

Figure 3. Shows deployed radiofrequency ablative probes. With image guided assistance, probes are introduced into the target tissue. Once the probe is in the place, the tip is deployed in an umbrella type fashion (red arrow). The probe is ready for ablation.

A radiofrequency ablation system consist of a set of probes and a generator. Older modalities included only monopolar probes and a grounding pad. Due to several drawbacks, including risk of electrical shock, skin marks, inability to ablate larger volumes and prolonged procedures, they were quickly replaced by newer and more advanced technologies (multipolar probes).

Multipolar probes have multiple electrodes on a single probe, enabling a closed-loop circuit, rendering the grounding pad obsolete.

RFA is a minimally invasive tool and as with other thermoablative methods, puts less stress on the patients, preserves more normal organ tissue and requires less hospital stay<sup>9,25</sup>.

Probes are introduced into the target tissue with surgical, laparoscopic or percutaneous access. Radiofrequency ablation has mainly seen its use in selective solid tumors, particularly in liver, kidney, lungs and the musculoskeletal system<sup>9,25</sup>.

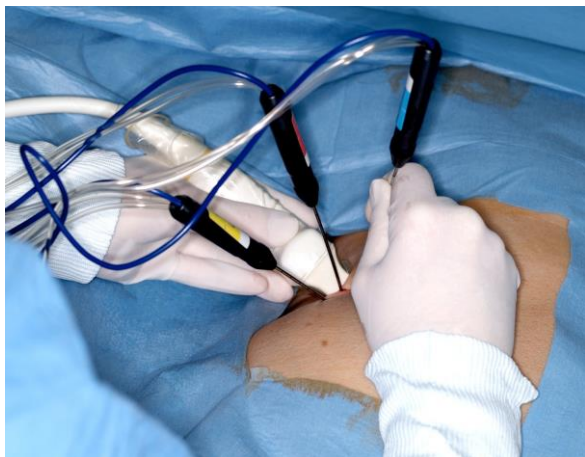


Figure 4. Careful application of RF probes with ultrasound guidance by Prof. B. Brkljacic at Radiology Dep. at University Hospital of Dubrava. Ultrasound allows precise placement of ablative probes and possibility to monitor therapeutical progress.

Indications for RFA ablation in liver tumors applies to patients who are not candidates for surgical procedures, or have decreased liver capacity (e.g from cirrhosis). This includes HCC nodules less than 4 cm in size or even greater than 5 cm if the patient was previously treated with transarterial chemoembolization. For liver metastases, ablation is considered in lesions up to 4 cm (if fewer than 3) or up to 3 cm (if up to 4 lesions). Bigger tumors can be treated for palliative reasons.

The procedure is performed in a sterile environment and the area of operation is surgically prepared. The patient is given general anesthesia or mild sedation. In mild sedation, the patient receives local anesthesia into the injection site for pain. When the equipment and staff are ready, the physician locates the tumor lesion with an imaging device, usually ultrasound, (Figure 4) and guides the probe inside the tumor tissue.

Once introduction and deployment of the probe (Figure 3) inside the target tissue is complete, heating is delivered to the tissues through high flow of alternating current (375-

500 kHz) passing through the circuit. The tissue heating leads to protein denaturation that results in cellular breakdown and irreversible damage. As in figure 4, ultrasound probes are generally used to monitor the treatment. Echogenicity of the tissues imply formation of tissue and water vapor bubbles from the heated tissue, and can be used as an estimation of the ablation size. The temperature at the tip of the electrode is limited to 100°C, since higher temperatures will produce charring of tissues and cells, which lead to an increased impedance (higher heat loss in peripheral tissues) within the target volume. Additionally, blood vessels near or within the target tissue are responsible for majority of the heat loss. This phenomena is labeled "heat-sink effect" and is responsible for poor ablation in peripheral regions of the target volume<sup>9,25,26</sup>. Application of multiple probes enable the physician to treat larger tissue volume and achieve a more uniform heating pattern across the tumor tissue.

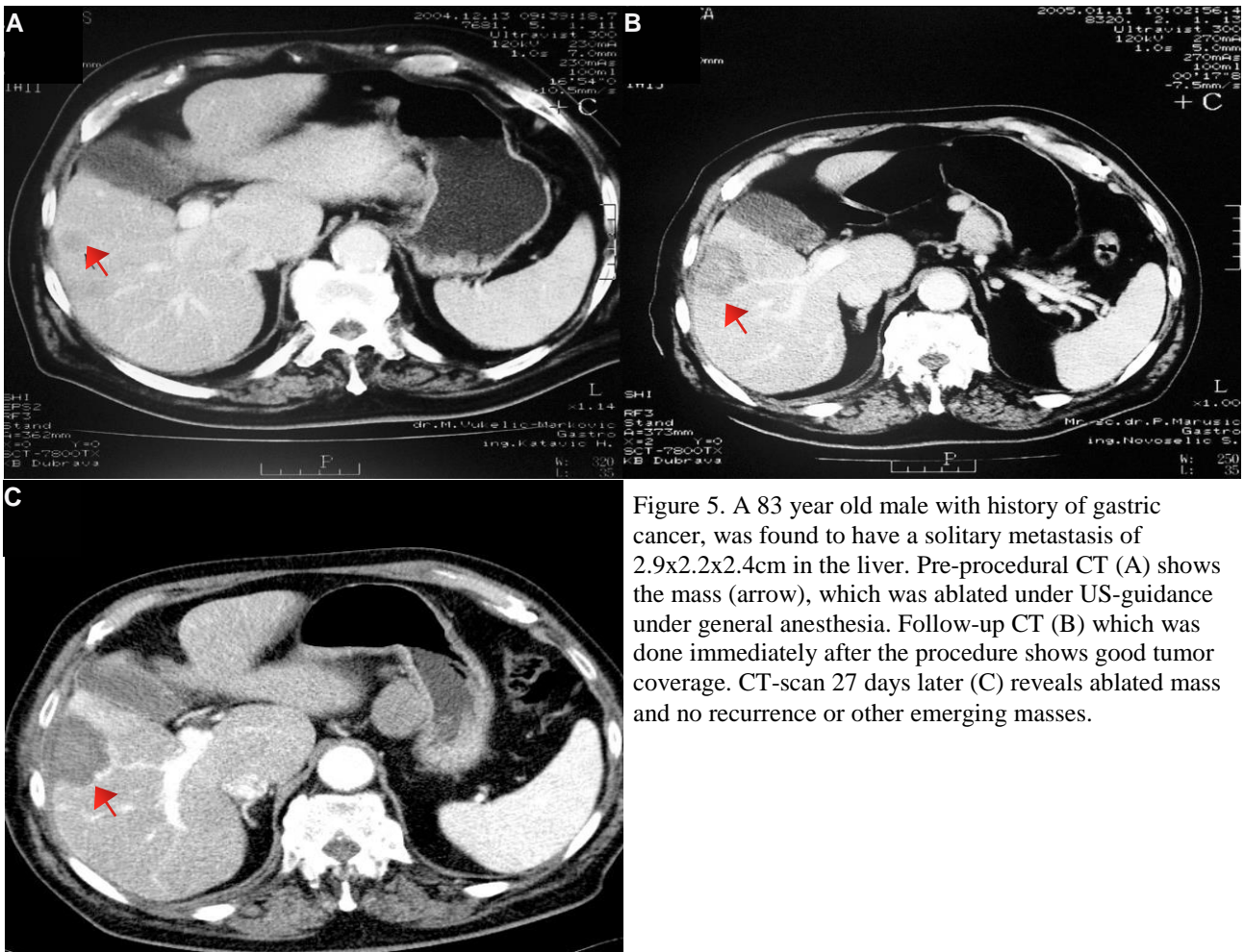


Figure 5. A 83 year old male with history of gastric cancer, was found to have a solitary metastasis of 2.9x2.2x2.4cm in the liver. Pre-procedural CT (A) shows the mass (arrow), which was ablated under US-guidance under general anesthesia. Follow-up CT (B) which was done immediately after the procedure shows good tumor coverage. CT-scan 27 days later (C) reveals ablated mass and no recurrence or other emerging masses.

Livraghi et al<sup>27</sup> showed that complications from radiofrequency ablation are uncommon, with major complications occurring at a rate of 3%. Most common are peritoneal hemorrhage, neoplastic seeding, intrahepatic seeding and intestinal perforation. Mortality rate at 0.3%.

In order to decrease intraprocedural complications, careful selection of appropriate patients is mandatory. Exophytic tumors should be avoided to reduce the risk of neoplastic seeding and post procedural bleeding. Instead a transhepatic route should be taken to battle peripheral tumors<sup>25</sup>. To avoid pneumothorax, puncture site should be as anterior and inferior as possible. And usage of prophylactic antibiotics to reduce the rate of intrahepatic abscesses in patients who are at a higher risk (biliary dilatations)<sup>25</sup>.

RFA is a well known technology to control HCC lesions and liver metastases (Figure 5). It's shown to be able to be used as a bridge therapy while waiting for transplantation<sup>28</sup> and improve survival in patients with colorectal liver metastases<sup>29</sup>. In treatment of HCC, recurrence rate of RFA-ablated lesions is usually low (<10%), but recurrence of the cancer in other areas of the liver occurs more frequently (approx. 50%)<sup>9</sup>. In a prospective study conducted in Netherlands<sup>30</sup> with 132 patients and 290 metastatic lesions ablated, median survival was 41 months, with a 3- and 5-year survival of 60% and 30.8%, respectively. More results are covered in the next section.

RFA is a young and effective type of ablation that has gained the greatest marketshare in the world of thermoablative techniques due to its cheap, safe and efficient technology. It's role in reducing cancer burden is already applied in several organs. With the advancements in imaging and use of adjuvant therapies (TACE, PEI etc), we will see an increase in indications and efficiency.

## Percutaneous Ethanol Injection

Percutaneous ethanol injection (PEI) is one of the oldest ablative techniques available on the market today. The principle of PEI is to enter the target tumor tissue through the skin with very thin needles (size 21-22 gauge) and release ethanol. Releasing 96% alcohol directly into the tumor is used to reduce the burden from the tumor lesion and prolong survival rate. It's been used widely for small HCC tumors because it's cheap, easy-to-use, efficient & repeatable<sup>31</sup>.

Patients indicated for percutaneous ethanol injection are not candidates for surgical resection or liver transplantation. They belong to stage A of BCLC staging system and have three or fewer than three tumor lesion, which are less than 3 cm in diameter and have well defined margins.

Contraindications for PEI are patients with poor hepatic reserve, extrahepatic metastases, refractory ascites, coagulopathy (PT activity <35%, thrombocytes < 40 x 10<sup>9</sup>/L), jaundice and portal vein tumor invasion. PEI has no restrictions on tumor location.

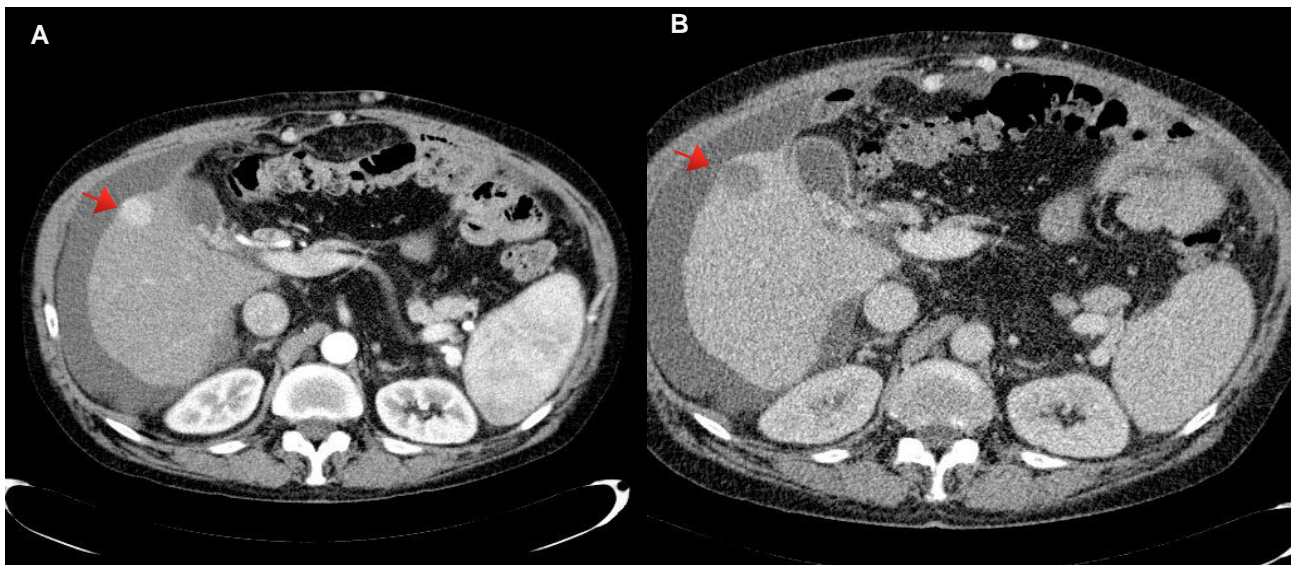


Figure 6. (A) A CT scan of a 67 year old male with cirrhotic liver show a hepatocellular carcinoma lesion (arrow). Dose of 30 ml ethanol was delivered in three injections to the tumor lesion over 8 days. (B) A control CT taken few days after the procedure shows tumor destruction. PEI can be repeated if viable tumor tissue is detected.

The procedure can be performed on an outpatient basis with normal surgical precautions and local anesthesia. Tumor location is determined and a thin needle is guided into the tumor tissue with either ultrasound or computed tomography assistance (Figure 6A). When the needle is in place, ethanol is injected. The volume required to inject depends on the size of the lesion. With the formula  $V = \frac{4}{3} \pi (r+0.5)^3$  a tumor of 3 cm would provide an injection volume of approximately 32 ml<sup>32</sup>. At the radiology department of University Hospital of Dubrava, we don't exceed injection volume of 15 ml per session. Main reason is to avoid major complications. Distribution of ethanol at absolute level (96%) within the tumor tissue leads to cellular dehydration and thrombosis of vascular beds resulting in destruction of tumor cells (Figure 6B). If performed well, one injection is sufficient to ablate the whole tumor volume. Usually PEI is performed twice a week for up to 4-6 weeks<sup>31</sup>.

S. Shiina et al<sup>32</sup> conducted a multivariate analysis study in 2012, spanning over 20 years, with 685 primary hepatocellular carcinoma patients. They showed that PEI is a safe procedure with low rate of complications (2%). Minor complications include pain (located to injection site or abdomen), fever, alcoholic intoxication and elevated transaminase<sup>31</sup>. More serious complications include peritoneal bleeding, hemothorax, hemobilia, liver abscess, hepatic infarction, seeding of malignant cells and pleural effusion. Mortality rate was 0,06%.

Recurrence of tumor lesions after PEI is a known issue. Approximately 50% reappear after 3 years, mostly within the liver<sup>31,32</sup>. Therefore it's important to enroll the patient into a follow-up schedule every 3-4 months with CT or US in order to discover new tumor lesions.



Survival rate in 5, 10 and 20 years after PEI procedure is 49.0%, 17.9% and 7.2% respectively<sup>32</sup>. Same study showed PEI to be comparable to surgical resection in survival rate, despite different indications between the treatments.

Radiofrequency ablation (RFA), which shares its patient indication regime with PEI<sup>12,23</sup>, has been shown by randomized control studies<sup>33</sup> to be superior to percutaneous ethanol injection irrespective of tumor size.

Studies showed that overall 5 year survival rate of patients in the RFA and PEI groups were 55% and 42%, respectively. RCT by S. Shiina et al in 2005<sup>34</sup> showed patients treated with RFA to have a 4-year survival rate of 74%, compared to 57% in patients that underwent PEI. Length of hospitalization stay, amount of treatment sessions and mortality rate was also shown to be advantageous in patients from the RFA group. Conclusions from these studies is that radiofrequency ablation is superior to ethanol injection.

Since the introduction of RFA, there has been a dramatic shift from PEI. Therefore PEI should only be performed in patients whom RFA can not be performed safely. This includes patients with enteric-biliary anastomosis (risk of developing liver abscess after RFA procedure), those which have adhesions between tumor lesion and GI tract (risk of RFA to produce GI perforation), or in cases in which RFA can't be performed safely due to technical difficulties.

## Transarterial Chemoembolization

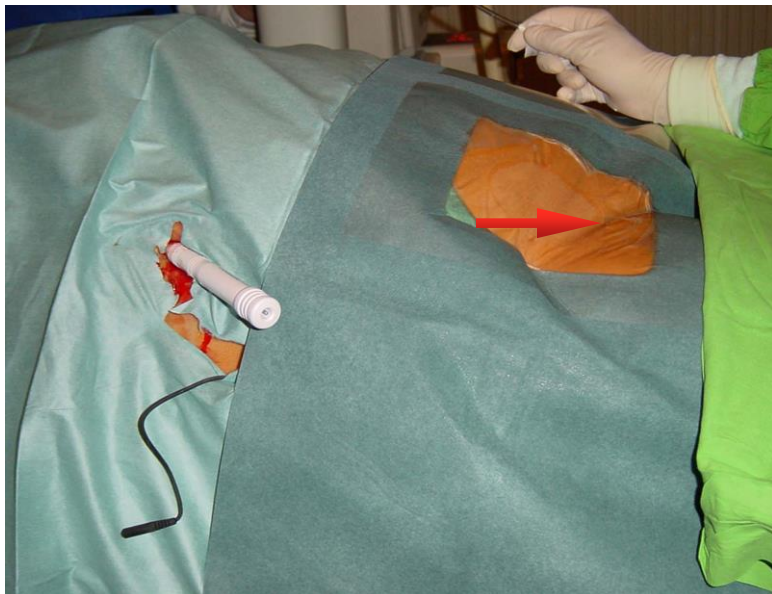


Figure 7. The right groin is exposed and thoroughly cleaned before procedural treatment. The right femoral artery (arrow) is the entrance point for introduction of the catheter and tools used in TACE. On the left, instruments for PEI are in place for combination therapy with TACE.

Transarterial chemoembolization (TACE) is a chemoablative therapy that has been used to treat unresectable HCC since the end of 1970s<sup>13</sup>. TACE is a percutaneous technique, which uses a coaxial catheter system to deliver several different types of anti-cancer and embolizing agents into the arterial network nourishing the tumor. TACE is based on the knowledge that the liver has a dual arterial blood supply, 75% provided by the portal vein and remaining 25% by the hepatic artery, and that primary and secondary liver tumors almost exclusively receive their nourishment from the hepatic artery<sup>12,13,14</sup>. A detailed anatomical knowledge of normal and variant arterial structure of the liver is very important in order to effectively deliver the treatment and to spare non-target tissue. Based on this, it is possible to deliver chemo-therapeutic agents that will result in destruction of tumor parenchyma, while relatively sparing normal liver parenchyma. TACE

is not deemed as a curative treatment for liver tumors, in fact it is used as palliative modality that has been shown to improve quality of life and prolong survival in patients<sup>13,14,35</sup>.

Ideal candidates for transarterial chemoembolization belong to stage B of BCLC. These patients are asymptomatic with intermediate stage of HCC and preserved liver function. TACE should be avoided in patients with advanced liver disease and poor hepatic reserve (Child-Pugh Class C). Other contraindications include poor clotting test results (platelet count  $50,000 \text{ mm}^3$  or prothrombin activity  $\leq 50\%$ ), renal or cardiac failure. If there is an insufficient or impaired collateral flow, in cases of hepatofugal flow, portosystemic shunt or portal vein thrombosis, patients should not be included because there will be a very high risk of necrosis of non-target tissue left without blood supply<sup>12,14,35</sup>.

Patients are given fluid, anti-emetics, painkillers and antibiotics before and after the procedure. Hydration is a key element to avoid development of nephrotoxicity from the iodine contrast, tumor lysis and chemotherapeutic agents. Metronidazole is provided to avoid bacterial colonization in necrotic tumor tissue. A thorough angiographic examination (CT or MRI) has to be done beforehand to supply the physician with a clear map of the arterial network in the liver and of vessels feeding the tumor tissue. This includes angiograms of the hepatic artery proper and superior mesenteric artery to avoid missing any arterial variations.

Patients are generally put under conscious sedation, and given local anesthesia into the right femoral area (Figure 7). With a coaxial catheter system, the right or left femoral artery is penetrated according to the Seldinger technique<sup>7</sup>, and a catheter is guided into the abdominal aorta, where iodine contrast is released to reveal the arterial network with fluoroscopic guidance (Figure 8B). Then, arteries associated with the tumor are selected, and intra-arterial injection of chemotherapeutic agents, usually enclosed within a carrier substance (lipiodol), and agents that obstruct hepatic artery blood flow is performed (Figure 8C). The idea is to deliver a very high local and concentrated dose of toxic agents into the blood flow, followed by embolization of tumor circulation in order to reduce washout of drugs, increase anti-tumor effect and to reduce the burden of systemic side effects<sup>13,14,35</sup>.

Depending on the state of the patient and tumor advancement, multiple procedural sessions can be repeated in order to achieve a better tumor response. The interval between two TACE sessions should be between 4-12 weeks<sup>36</sup>.

Patients are usually provided with further hydration, antiemetics, painkillers and antibiotics after the procedure to reduce complications. The most common complication after a TACE treatment is the post-embolization syndrome, it comprises of fever, nausea/vomiting and pain. Study by Lo et al in 2002<sup>37</sup> showed fever, pain and vomiting to be very common side-effects with an occurrence rate of 63%, 50% & 32%, respectively. In a risk factor analysis by Shi-Ying Wang et al from 2013<sup>38</sup>, nausea and vomiting had an occurrence rate of 38% and 21%, respectively. The rising of temperature is not due to an infection, but due to tumor necrosis and therefore doesn't indicate blood cultures to be taken. Post-embolisation syndrome starts to subside by 72 hours<sup>39</sup>. Major side effects are rare<sup>40</sup>, but include vascular complications, pulmonary embolization, severe infections, hepatic and renal failure.

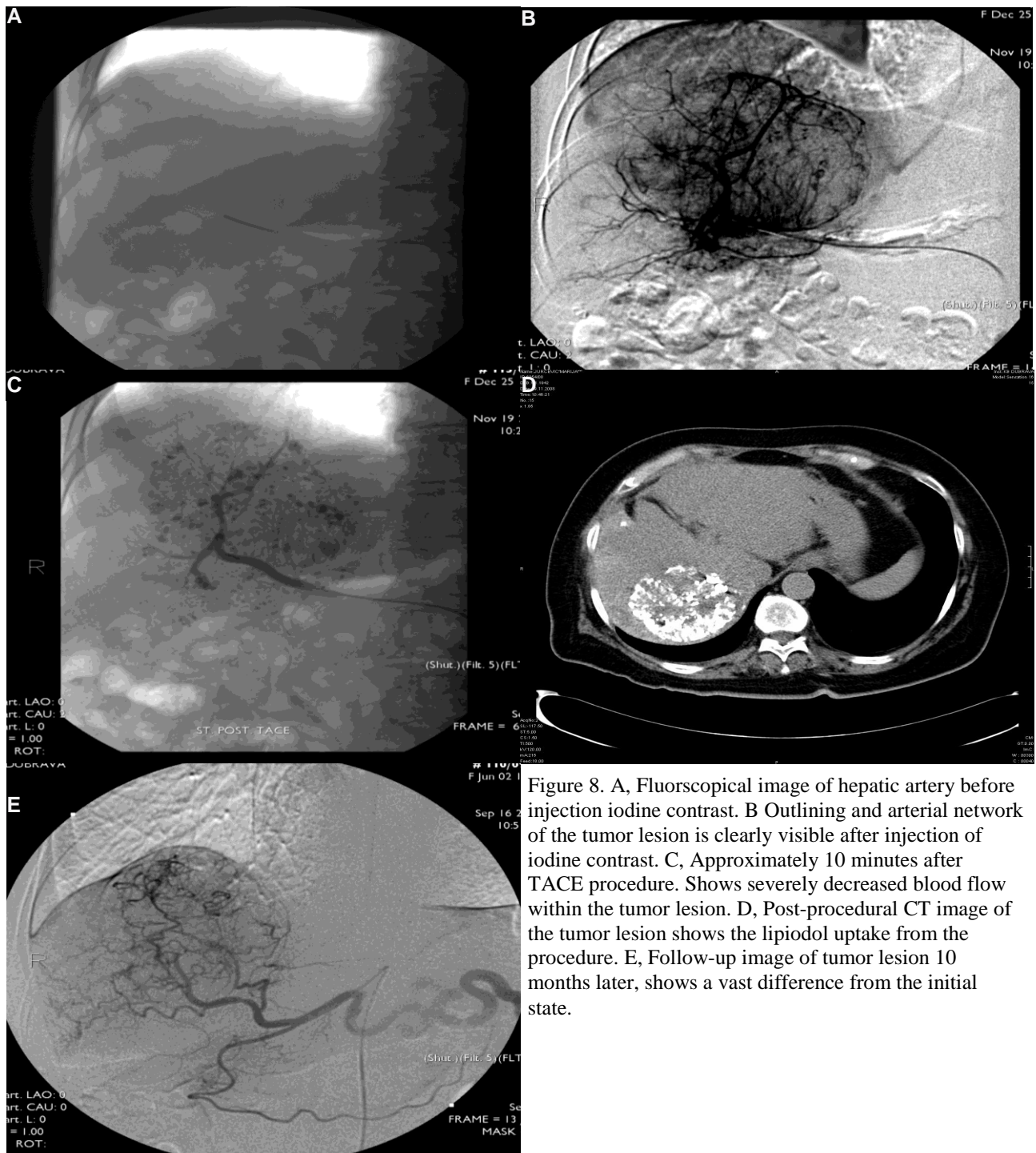


Figure 8. A, Fluoroscopic image of hepatic artery before injection iodine contrast. B Outlining and arterial network of the tumor lesion is clearly visible after injection of iodine contrast. C, Approximately 10 minutes after TACE procedure. Shows severely decreased blood flow within the tumor lesion. D, Post-procedural CT image of the tumor lesion shows the lipiodol uptake from the procedure. E, Follow-up image of tumor lesion 10 months later, shows a vast difference from the initial state.

## Agents used in TACE

As discussed above, transarterial chemoembolization involves the intra-arterial administration of chemotherapeutic drugs mixed with embolizing agents. A systematic review of 175 randomized and cohort studies regarding the current practice and administration of transarterial therapy for hepatocellular carcinoma was conducted in 2007 by Marelli et al<sup>36</sup>. It showed that several different chemotherapeutic agents are in use today, which of doxorubicin and cisplatin are the most common. Out of 61 chemoembolization studies, 36% used doxorubicin and 31% cisplatin. Other agents used as anticancer agents include epirubicin (12%), mitoxantrone (8%), mitomycin C (8%) and SMANCS (5%). SMANCS is a synthetic polymer of styrene maleic acid and neocarzinostatin<sup>36</sup>. Criteria to determine the dosages of anticancer agents seem to be variable and not standardized. Some authors refer to a fixed dose, others use the patients body surface area, weight, tumor size or bilirubin level<sup>36,41</sup>. Doses for the chemotherapeutic agents varied noticeably. A doxorubicin dose per session ranged from 25-50 mg, cisplatin 10-120 mg and epirubicin from 40 to 100 mg. Even though administration of a single anticancer agent was the most common form of administration (75%), there was no evidence that showed double (15%) or triple therapy (6%) to be any more beneficial. Most importantly, no single anticancer drug was proven to be superior to any other drug<sup>36</sup>.

Lipiodol is an ethiodized oil that is frequently mixed with anticancer agents before a TACE procedure. This oily contrast medium was shown to remain in tumor tissue for several weeks to over a year after injection into the hepatic artery<sup>42</sup>, due to hypervascularization and absence of Kupffer cells, which are essential for lipiodol clearance, in tumor cells<sup>43</sup>. Before the procedure, lipiodol is vigorously mixed with anticancer agents in order to prepare an emulsion. The idea of lipiodol is to carry and localize drugs into tumor tissue, where the drug would be slowly released from the emulsion and remain in high concentration within the tumor tissue for an extended amount of time. It is however unclear how stable water-based agents (anticancer agents) combined with lipiodol, which is oil-based, are to deliver drugs slowly over time. In fact, it's efficacy is unproven since there are no data that shows how slowly lipiodol is able to release anticancer agents into tumor tissue. Lipiodol can complicate the interpretation of residual vascularity of tumor tissue on post-procedural CT imaging<sup>36</sup>.

Embolizing agents are injected after administration of chemotherapeutic agents. There are several types which are used in transarterial chemoembolization, including gelatin sponge, polyvinyl alcohol, steel coils, degradable starch microspheres, autologous blood clots, embospheres and drug-eluting beads. The most commonly used is gelatin sponge, which produces a temporary arterial occlusion with recanalization occurring after 2 weeks<sup>36</sup>. It can be prepared in several different sizes and forms, such as gelatin sponge particles, pellets, cubes, powder, fragments and strips. They have different sizes and are designed to reach different levels of the arterial system. Gelatin sponge powder has been abandoned, since it's use has been shown to be harmful to extratumoral liver tissue, unlike other types, which have been shown to not be harmful to normal parenchyma<sup>36,41</sup>.

Steel coils are equivalent to surgical ligation and occlude small to medium sized arteries. Together with polyvinyl alcohol and microspheres they are regarded as permanent embolic agents.

Drug-eluting beads (DEB) is a drug-delivery system that can be used for TACE procedures. In fact, it combines the release of chemotherapy into target tissue with local embolization.

DBE are microspheres made of biocompatible polymers, such as polyvinyl alcohol hydrogel, with an ion exchange mechanisms that allows binding to chemotherapy, such as doxorubicin. The beads are designed to occlude vasculature, causing embolization, and later deliver chemotherapy in a slower fashion than what is seen in conventional TACE procedure. This increases the drug-tumor tissue interaction and lowers the systemic concentrations, leading to a reduced number of complications. Early studies<sup>44</sup> show promising results, but further investigation is essential in order to define its role in TACE procedures.

Lastly, embospheres are around 100-700 um in size and made of trisacryl gelatin microspheres. They have a smooth hydrophilic surface, which are able to penetrate deeper and embolize smaller and more peripheral vessels.

To summarize, Marelli et al (2007) states in her study that there is no conclusion on which is the most effective embolizing agent on the market right now. Theoretically, embolizing agents with a standardized size that can be delivered into smaller arteries and cause permanent thrombosis should be more effective than gelatin sponge agents

## Results of TACE

To date, there has been a big number of randomized and non-randomized clinical studies of TACE. In the biggest and most comprehensive review of transarterial therapy of HCC<sup>36</sup>, in which 175 articles were covered, the most important conclusion was that quality of life and survival rate in patients increased after TACE treatment compared to conservative therapy. Some study states how clinical studies performed before year 2000 showed lower survival rate than compared to more recent ones, after 2000. The results for studies before 2000 showed 1,3 and 5 year survival rate to be  $57 \pm 19\%$ ,  $29 \pm 16\%$  and  $23 \pm 19\%$ , and results after 2000 to be  $71 \pm 18\%$ ,  $34 \pm 13\%$  and  $14 \pm 10\%$ . This is likely to be a result of better procedural technique, better patient selection and better management of underlying liver disease. Eastern studies showed to have better 3 and 5 year survival rates (of  $33 \pm 22$  &  $24 \pm 14$ ) than the Western ones ( $27 \pm 9$  and  $7 \pm 10$ ). Additional studies from other authors present similar results. Another RCT with 79 patients<sup>37</sup>, divided into one control group of 39 patients and remaining 40 into a group with chemoembolization, survival rate was significantly better in the chemoembolization group. The survival rate of 1,2 and 3 year was 57%, 31%, and 26% for the chemoembolization group and 32%, 11%, and 3% for the control group. Study with 122 patients conducted by Llovet et al in 2006<sup>11</sup> showed that patients treated conservatively had a lower survival rate compared to patients treated with chemoembolization. The study presented a 1 and 2-year survival rate of 82% and 63%, respectively for chemoembolization, and 63% and 27% for control group. More recent study from 2012<sup>13</sup> showed similar results, with a 3-year survival rate of 30-55% for patients that underwent TACE. These results pin the importance of TACE as a therapy modality in patients with unresectable HCC. Prognostic factors that are associated with the outcome include liver function, stage of cancer (number of

Study	Arms	Patients n.	Gender (male)	Child-Pugh Class		Tumor size (mean±SD, cm)	Number of tumor (1/>2)	1-year survival	3-year survival
				(A/B/C)					
Zhao et al. [8]	TACE+3D-CRT	49	32	49/0/0		all<6	N.R.	82%	43%
	TACE	47	28	47/0/0				55%	15%
Liu et al. [9]	TACE+HIFU	43	67.9%	45/33/0		all > 5	40/38	74.4%	16.3%
	TACE	35						48.6%	0%
Bartolozzi et al. [10]	TACE+PEI	26	19	14/12/0		4.84±1.44	18/8	100%	72.2%
	TACE	27	22	11/16/0		5.09±1.36	14/13	92.6%	43.4%
Becker et al. [11]	TACE+PEI	27	20	17/10/0		n=17 > 5cm	13/14	61.5%	N.R.
	TACE	25	21	22/3/0		n=17 > 5cm	9/16	62.9%	N.R.
Xu et al. [12]	TACE+PEI	23	N.R.	23/0/0		all > 5cm	23/0	88%	21%
	TACE	22		22/0/0			22/0	59%	0%
Yamamoto et al. [13]	TACE+PEI	50	42	17/23/10		N.R.	22/28	95%	50%
	TACE	50	45	20/19/11			26/24	92.5%	20%
Yang et al. [14]	TACE+RFA	24	18	11/5/1		6.6±0.6	5/19	68.3%	N.R.
	TACE	11	8	10/5/0		6.4±1.0	7/4	53.2%	
Leng et al. [15]	TACE+RT	36	27	N.R.		9.7	34/2	74.8%	40.4%
	TACE	39	27			10.4	34/5	61.3%	19.8%
Wang et al. [16]	TACE+RT	20	18	N.R.		N.R.	N.R.	50%	N.R.
	TACE	20	19					33.3%	
Wang et al. [17]	TACE+RT	54	43	N. R.		n=19 > 5cm	49/5	76.5%	42.1%
	TACE	54	44			n=22 > 5cm	50/4	53.2%	18.6%

Table 9. Overview of survival rate from standalone TACE procedure and combination therapies with TACE. Table used from Liao M, Huang J, Zhang T, Wu H (2013)<sup>45</sup>

tumor, nodules), vascular invasion and extrahepatic spread<sup>11,13,40,41</sup>.

What's important to remember is that TACE is not always used as the single therapeutic model in patients with liver tumors. They can often be combined with other treatments of what we have covered above.

Common combination therapies include TACE with radiofrequency therapy, percutaneous ethanol injection, high-intensity frequency ultrasound, radiotherapy and three-dimensional conformal radiation therapy. In a meta-analysis performed by Liao M et al<sup>45</sup> covering 10 randomized trials and 18 observational studies (2497 patients), they concluded that TACE combined with local treatments could improve overall survival rate compared to patients receiving TACE therapy alone.

In a study with 71 patients from 2010<sup>46</sup>, in which 26 received conventional TACE therapy and remaining 45 underwent TACE with drug-eluting beads. Median survival from diagnosis of HCC in the group with TACE + DEB were 610 (351–868) and 284 days (4 – 563) for TACE only group. This underlines clearly that there is further space and potential in development and understanding in the utilization of transarterial chemoembolization with other therapy modalities.

## High-Intensity Focused Ultrasound

High-intensity focus ultrasound (HIFU) is the only non-invasive technology that we will cover in this paper. Unlike other interventional therapies used to treat tumors, such as radiofrequency ablation and chemoembolization, HIFU is regarded as a completely non-invasive technology, since it doesn't require any physical tools to be introduced into the patient in order to deliver energy.

Ultrasound modality in diagnostic setting work within ranges of sound waves that have no or minimal biological effect on the tissues<sup>47</sup>. As acoustic waves travel through tissue, some of their energy gets absorbed and converted into heat. HIFU works by sending several waves to a common focus inside tissues, resulting in physiological and biological effects<sup>48</sup>. The energy harvested from the collision of beams in the focus is capable of producing sufficient heat to produce tissue damage, such as the




Fig 10. Characteristic shape of a thermal lesion, resembling a cigar, from focused ultrasound therapy. Performed on a porcine liver specimen. Granted permission from KJR (16) for use of the figure.

therapy for another treatment or as a palliative option<sup>48</sup>. HIFU is a new technology and more research has to be conducted in order to gather more information on long term effects, complications and success rate.

High-intensity focused ultrasound treatment can be performed for inpatients, but also for outpatients. The patient is either put under general anesthesia or sedated with spinal anesthesia. Spinal anesthesia is recommended for patients undergoing treatment of prostate and uterine fibroids in order to remain comfortable and static throughout the procedure. Once the patient is in place, the transducer is placed properly to face the target tissue. It is introduced into the rectum in case of prostate cancer or applied directly on the skin when treating liver tumors. The US transducer is connected to a computer, which allows the physician to construct a treatment plan for the therapy. Depending on the tumor type, size and location, the procedure takes around 2-4 hours.

Tumors are treated by destroying as much as possible of the tumor tissue. In focused ultrasound therapy, tissue damage is accomplished by several mechanisms, including thermal, mechanical and chemical. Tissue heating occurs as a result of the absorbed energy that is applied onto the focal zone. The amount of energy delivered is a function of the temperature the tissue is heated to and on how long the tissue is exposed to the ultrasound beams. This results in destruction of tumor tissue from coagulation necrosis. Hemostasis occurs as an indirect effect of the thermal injury, since the high temperature induce vessel collapse and subsequent formation of fibrin plug<sup>48</sup>. Cavitations are produced in tissues from very high-intensity acoustic waves, which are able to grow and have a very high temperature inside. Eventually these cavitations can implode, releasing a strong shock wave throughout the tissue and cause mechanical injury.



Figure 9. Transrectal probe for HIFU therapy. Courtesy of Sonacare Medical.

characteristic "cigar-shape" in the focal zone (Figure 10). In the clinical setting, HIFU is available as an option in the treatment of tumors in prostate, uterus, breast, liver, pancreas and other. An important factor for efficient HIFU application is the distance between the target tissue and the ultrasound transducer (Figure 9).

In the case of treating prostate cancer, the treatment can be delivered from a transrectal probe, resulting in a relatively short distance from the target organ. Prostate cancer has seen the most use of HIFU and some studies have shown results to be approaching surgical options, but no randomized control studies have been performed to date. In tumors of other organs, such as of breast, pancreas and liver, HIFU is primarily used as a bridging

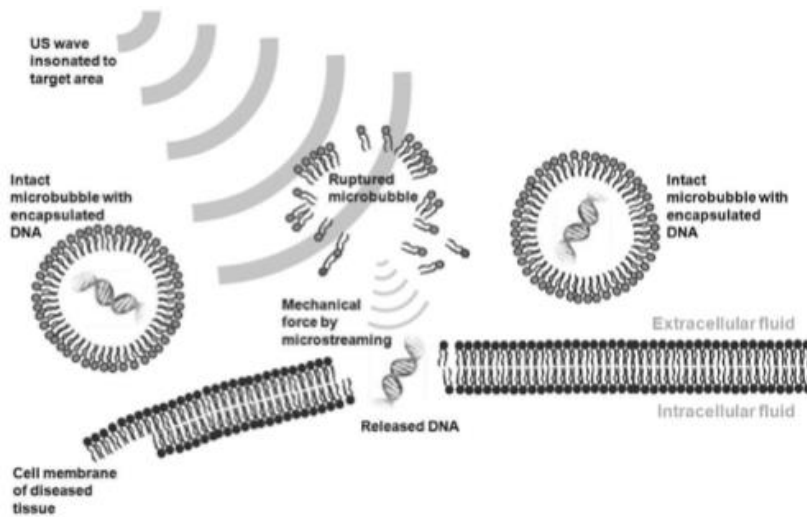


Figure 11. Schematic drawing of gene-delivery therapy. Sound waves of low intensity induces rupture of microbubbles, which lead to release of DNA. Granted permission from KJR (16) for use of the figure.

dose of therapy. This has an advantage over systemwide genetic therapy, because it only delivers therapy to the diseased area and subsequently reduces side-effects<sup>48,49</sup>.

Thrombolysis can be achieved and improved from ultrasound. By using low intensity acoustic waves, non-thermal mechanisms such as acoustic cavitation open up cell membranes and allow thrombolytic agents to have a greater bioavailability and effect, potentially resolving a thrombus.

Clearly HIFU has a big potential as a therapeutic modality for tumors and other diseases. Advantages include the non-invasiveness and low post-therapeutical pain for patients. Unfortunately with the current technology HIFU still comes with some limitations. Including difficulties operating on moving target organs, interference with gas in bowel or bony tissue, and the relatively high cost of technique in relation to its effectiveness. There's great potential for HIFU in the future and in the field of interventional oncology. In regards to liver cancer, no randomized control trials have been performed that shows HIFU singlehandedly to be a reliable treatment option, but HIFU in combination with transarterial chemoembolization has been proven to prolong survival of patients with advanced hepatocellular carcinoma<sup>50</sup>.

Additional methods to produce biological effects include targeted drug /gene delivery therapy and thrombolysis. Targeted drug therapy is a novel type of therapy that involves the application of certain "microbubbles" (Figure 11), that are loaded with drugs or plasmid-DNA. These are injected into the bloodstream and travel as vehicles. The walls of the microbubbles are designed to rupture once they receive a set of sound waves with the correct level of intensity. Theoretically, if the ultrasound transducer aims its beams to a vessel feeding the tumor, passing microbubbles would burst and release a highly concentrated and localized

## Cryoablation

Cryoablation is a type of percutaneous ablation technique that is used to treat tumors and other diseases. Special type of probes are penetrated through the skin and introduced into the target tissue with the guidance of imaging devices such as ultrasound, computer tomography (CT) or magnetic resonance imaging (MRI). Cryoablation, also called cryotherapy, as the name implies, delivers subzero temperatures to tissues in order

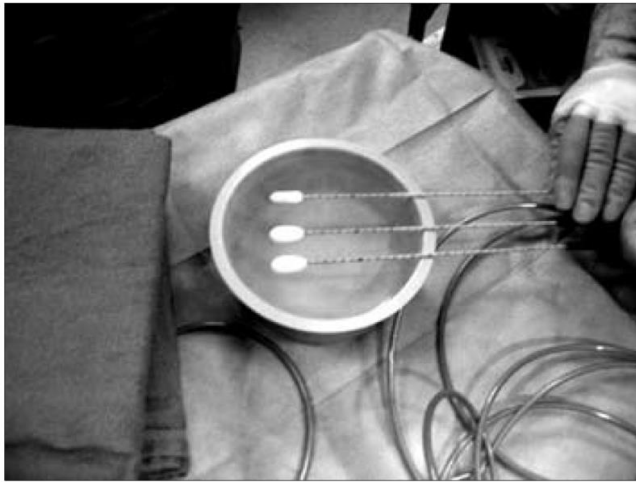


Figure 12. This picture shows activated cryoablative probes with an ice ball formation at the tip. Credit to author Servet Tatli et al <sup>51</sup> for the figure.

to cause local tissue ischemia. The freezing temperature is delivered to tissues through a set of small probes that are equipped with argon. When argon is exposed to very low pressure within the probes, it reaches temperatures of less than -100 celsius & produces an ice ball at the tip of the probe (Figure 12). Water molecules transform to solid state (ice) that results in cellular dehydration, which leads to rupture of cell membranes, vascular stasis and thrombosis. As a consequence, cells are destroyed and ravage of local tissue occurs. Previously, cryoablation, was only possible with laparoscopic or surgical access because older cryoablative tools were too large to penetrate the skin, but with advancements in probe technology & size, cryoablative procedures can be performed without surgical assistance<sup>51</sup>.

Candidates for cryotherapy are patients with advanced liver disease, including metastatic lesions.

They are not candidates for surgical resection, radiofrequency ablation or chemoembolization. Since cryotherapy is a new ablation technique, patients are generally enrolled into clinical studies that offer an alternative therapy. This includes patients with primary liver tumors, such as hepatocellular carcinoma, and liver metastases. Lesions larger than 5 cm are ideally avoided due to higher recurrence rate and decreased efficiency of therapy (18,19). Studies show that lesions below 3 cm are best treated. Main reason is believed to be due to absence of large vessels near the tumor tissue. One of the drawbacks of cryoablation is the possibility of local blood flow to prevent temperatures to reach lethal levels, so called "thermal-sink effect". This can lead to poor therapy outcome and increase the recurrence rate of tumor tissue<sup>51,52</sup>.

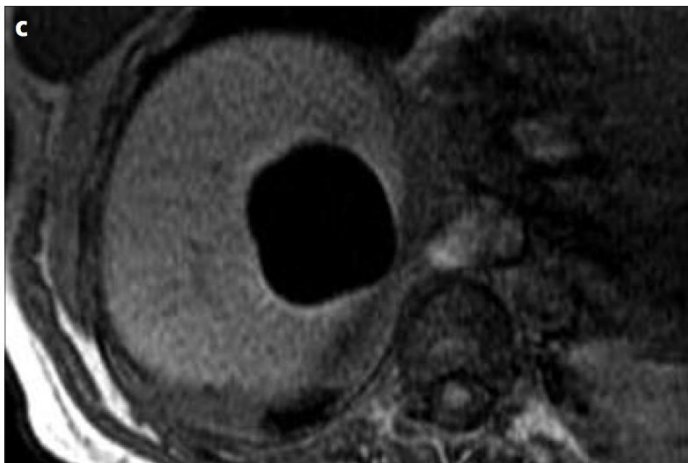


Figure 13. Observation of an ice ball formation that cover the liver lesion. This is taken intraprocedurally.

Patients are put under general anesthesia and undergo normal surgical preparation. Depending on the facility, US, CT or MRI can be used to guide the cryoablative probes into the target tissue. Procedure can start once the probe is deemed to be in place. A set of two 15-minute freezing periods separated by a 10 minute break, is sufficient to reach tissue temperature of -20 and -50 celsius that will result in complete tissue destruction<sup>51</sup>. Certain cells are differently sensitive to the freezing temperature. Important resistive cells include collagen and elastin fibers, which are important parts of connective tissue. This fact maintains a certain safety profile of the procedure, since healthy tissue suffers less to the damaging effects of treatment.



The freezing can be observed during the treatment by US, CT or MRI (Figure 13), but US is often avoided since posterior acoustic shadowing limits visualization<sup>51</sup>. This is an important difference from radiofrequency ablation which doesn't allow intraprocedural monitoring.

Complications that can occur within a cryotherapy procedure to liver lesions are rarely severe. Small intrahepatic hematomas can occur if tumor lesion is situated near any larger blood vessel. Postoperative pain is most often absent, but if present lasts around 1-2 hours. If a large volume of hepatic parenchyma is involved, possibility of severe myoglobinuria can occur, especially in a patient with poor renal function. Therefore it's common to undertake precautionary prophylactic measures by maintaining adequate urinary output.

#### Summary

To conclude cryoablation, it's an innovating technique that destroys tumor tissue by extremely low temperatures. Due to the application of probes into the organs, virtually any tumor shape can be targeted, and with individual control of pressure in probes, healthy tissue can be spared. This is a welcome addition as an alternative treatment for solid tumors that are not responding to systematic chemotherapy. Several clinical studies have been performed, but no randomized control trials are known to date<sup>23</sup>. Lastly, imaging techniques can be used intraprocedurally to maximize treatment of tumor and at the same time avoid serious complications.

## Microwave Ablation

Microwave ablation (MWA) is one of the latest developments in ablation techniques. Similar to previously percutaneous ablative techniques mentioned, it consists of a set of probes (Figure 14) that are introduced into the target tissue with either percutaneous, laparoscopic or surgical access. Microwave probes are equipped with multiple antennas along the probe that emit electromagnetic waves. The antennas are capable of delivering radio waves between 0,9 and 2,4Ghz. Water molecules are polar and will interact heavily with radio waves of such energy<sup>53</sup>. This interaction leads to severe agitation and movement of water molecules, which flip back and forth 2-5 billion times a second, resulting in an increase of temperature in the



Figure 14. The picture shows a microwave ablation probe. It's equipped with antennas, which are able to emit high frequency radio waves. Temperature control is built-in into the probe, allowing the physician to protect itself and non target tissue. Courtesy of Microsulis Medical Limited.

target tissue<sup>54</sup>. Eventually, the tissue will lead to cellular death and coagulation necrosis from excessive heating. Majority of patients with hepatocellular carcinoma are not candidates for surgical resection and are therefore candidates for ablative therapies. As with other thermoablative techniques, MWA aims to control the level of tumor growth in nonresectable lesions. Even though radiofrequency ablation is the most widely used thermoablative technique in the world, it still comes with some drawbacks. Major ones include heat sink effect from blood vessels, high local recurrence rate in lesions above 3 cm and difficulties in ultrasound imaging of ablated lesions. Microwave technology has been shown to offer many benefits of RFA, but also some advantages. Studies have shown microwave ablation to produce higher intratumoral temperatures that result in larger and faster tumor ablations<sup>54,55</sup>. In the clinical setting MWA has been undergoing clinical studies in treatment of both primary and secondary liver, lung, renal and bone tumors.

The patient undergoes routine surgical preparations with local anesthesia. Depending on the patients comorbidities and general condition, general anesthesia might be necessary. Unlike monopolar radiofrequency sets, microwave ablation does not require grounding pads. The lesion is located with imaging and the probe is inserted with surgical, laparoscopic or percutaneous access. Procedural steps of microwave ablation therapy is similar to radiofrequency ablation, saving the physician from a steep learning curve generally associated with new therapies. Lesions from MWA have been shown to have a much greater volume and be more effective around blood vessels than lesions by radiofrequency ablation in human (20) and porcine liver<sup>25</sup>. This results in a better clearance of unwanted tumor tissue and potentially better care for patients. In its current stage, microwave ablation is still in its infancy and far away from worldwide clinical application. It builds on microwave technology that is destined to improve some of RFA's drawbacks. Current studies show improvements, but the technology needs additional time and research to develop into an additional solution for patients with cancer.

## Discussion

It is clear to us now that interventional radiology is an important part of hepatocellular and liver tumor treatment. Advancements in technology and medicine has allowed new innovative treatments to take place and be part of the battle against horrible diseases. Hepatocellular carcinoma is one of the deadliest cancers in the world and due to its growing incidence, additional focus is necessary in order to save lives. We know that majority of HCC cases occur in patients with previous cirrhotic liver. It's therefore of utmost importance to prevent diseases that can progress to cirrhosis. As with any other diseases in medicine, prevention is the most preferred, affordable and efficient way of treatment. Preventative measures for HCC include reduction of HBV/HCV transmission, promotion of vaccination of HBV, lifestyle changes preventing obesity and alcohol abuse and controlling metabolic diseases, such as diabetes.

Fortunately there are several treatment options to patients with confirmed hepatocellular carcinoma or other liver tumors. Barcelona Clinic Liver Cancer staging system is the recommended tool for prognostic outcome and treatment allocation. In it, surgical resection and liver transplantation are deemed as potential curative treatments that are available to patients with solitary tumors and well preserved liver function. Studies have shown 5 year survival rate to be up to 70% and possibly even higher in certain clinics. Unfortunately, due to late diagnosis, this type of treatment only applies to approximately one fifth of patients with hepatocellular carcinoma. It was quite surprising to me that such a low number of patients are available for curative treatment. The low number can in some part be explained from the high incidence differences throughout the world. Majority of patients are from less developed regions with poor surveillance programs and primary health care. This is definitely a contributing factor that leads to a greater risk of missing patients with HCC in the early phase. Additionally, there is no simple and reliable tumor marker that can be used to scan massive populations for incidence; and HCC becomes only clinically difficult in advanced stages, resulting in patients searching for health care too late.

Patients with HCC & impaired liver function can undergo radiofrequency ablation and percutaneous ethanol injection. These are minimally invasive treatments that can potentially cure and increase the survival rate of patients with HCC. The focus of this thesis has been transarterial chemoembolization, which combines transcatheter delivery of chemotherapeutic agents emulsified with lipiodol, followed by vascular embolization. My expectations of TACE were much greater than the medical literature has proven. The combination of drug delivery and simultaneous blockage of blood flow sounds very powerful, but to translate the procedure into medical practice seems to be more difficult. It requires a great amount of knowledge and skill to be able to master coaxial catheter systems and select specific arteries during fluoroscopic imaging. In my opinion, this is regarded as a disadvantage to TACE, since only physicians with years of experience in the field of interventional radiology have skills enough to attempt such a procedure. Hopefully, improvements in imaging techniques and other technological advances will allow for an easier and more efficient operative procedure in the future. Despite this, a great amount of work from physicians throughout the world have overcome the technological barriers of TACE and developed it into a reliable and powerful tool for treatment of liver tumors. There are several advantages of TACE that have lead to its adoption in many hospitals and clinical centers. The minimally invasive approach to access and deliver agents is fully accessible from a single perforation of a medium sized artery, such as the femoral artery. Through this site, the procedure can be completely performed, allowing the patient to avoid general anesthesia and its complications. Certain patients, depending on their previous clinical history, may however require general anesthesia. This type of minimally invasive approach drastically reduces pain, operative complications and hospitalization stay. Additionally, the procedure includes local injection of chemotherapy, instead of systemic, reducing symptoms from these drugs. Due to this, transarterial chemoembolization has the capability to encompass patients that are not suitable for surgical resection. This includes majority of tumor-positive patients, since a great number of them have an expected poor surgical outcome, e.g due to poor liver function, difficult tumor location, poor physical condition and old age; or have metastatic lesions in the liver. As mentioned in the result section of TACE, the procedure is proven by several RCTs to increase the survival rate and quality of life in patients, who otherwise would not be suitable for curative treatments. Several questions remain to be answered in order to develop and improve the outcome of chemoembolization in patients. First, which is the best chemotherapeutic drug? As previously mentioned<sup>36</sup> no chemotherapeutic drug was proven to be more beneficial than any other. Doxorubicin is the most used drug worldwide, but in Japan epirubicin is predominant, mainly due to epirubicin being covered by the National Insurance System. My thoughts on the difficulties of the medical research to declare a single superior drug are multiple. Firstly, it seems to be unclear how much of the chemotherapy released into the bloodstream is

actually picked up and utilized within the tumor cells, leading to unexpected results. The difficulty of concentrating the agents within the tumor tissue is one of the disadvantages of TACE.

Secondly, the matter of which is the best treatment scheme for full TACE treatment, whether it should be undertaken at a fixed time or on disease progression after initial response. Finally, what is the actual role of chemotherapy in TACE? Marelli et al<sup>36</sup> showed in 2005 that patients receiving transarterial embolization (TACE without chemotherapy) or transarterial chemoembolization (TACE) presented with no difference in survival rate. Both presented with an improved survival rate and quality of life above conservative therapy, but failed to show any greater difference between each other. The study concluded that this statement could be changed in the future when a higher number of randomized control trials have been conducted. Fast-forwarding several years later, the EASL<sup>45</sup> guidelines from 2012 on treatment for HCC does not recommend bland embolization technique instead of TACE. My impression is that this question still remains unresolved, because multiple studies declare transarterial embolization to be more or less equivalent to TACE. I believe that a meta-analysis of great sample size is necessary to provide a definitive answer to this question.

In regards to the second step of TACE, which is the embolization of the arterial network feeding the tumor tissue, some points need to be cleared out. Even though the hepatic artery, in majority of cases, is the major nourishing vessel for a liver tumor, it's not the only one. There are collateral arteries in the surrounding liver parenchyma that deliver oxygenated blood to the tumor tissue. These smaller vessels, that are difficult to detect on imaging, are targets of embolizing agents that are delivered after injection of chemotherapy. Small particles, which have been designed to embolize arteries, are injected into the arterial network and travel in an emboli fashion in order to block blood flow. The behavior of the embolizing agents within the arterial network can not be controlled by the physician, leading to random dispersion of the agents. This uncertainty will carry a risk of certain tumor nourishing arteries to be left unblocked and subsequently spare tumor tissue. This is certainly one major reason to why there is a possibility of tumor recurrence after TACE treatment. More advanced tumors or metastatic lesions have a greater vascularity and produce a higher number of collateral arteries. Evidently recurrence rate is higher in these cases. On the positive note, TACE can be used to reduce and dampen the effect of larger tumor nodules in patients with very late stage of disease without putting to much restrain on the patient from the procedure.

Lastly, TACEs main advantage is its ability to be fused with other treatment modalities, which we have covered in this thesis. This solution is practically reasonable since ablative therapies such as RFA, PEI, MWA, Cryoablation & HIFU access the liver from the abdomen, unlike TACE which is performed from the groin area. Liao M published a meta-analysis study<sup>45</sup> with 2497 patients in 2013 that showed any treatment of the above combined with TACE to be more beneficial than taking TACE alone. Today, TACE +RFA or TACE+PEI combination are used most frequently as they have repeatedly been associated with improved survival rate than local therapies alone. The conclusion is reasonable, since the tumor lesion is locally attacked from two angles, primarily by toxicity and vascular deprivation from TACE and additionally from thermal ablation, which clears the remaining tumor tissue.

## Conclusion

Transarterial chemoembolization is a minimally invasive treatment modality in the field of interventional radiology that is primarily used to treat liver tumors such as hepatocellular carcinoma and metastases from other tumors. TACE has been categorized as a treatment for patients in the intermediate stage of BCLC, who are not suitable for more radical therapies such as surgical resection and radiofrequency ablation. The principle of TACE involves the local injection of chemotherapy followed by embolizing agents into the direct supplying artery of the involved tumor tissue. Multiple studies have shown the procedure to alleviate several symptoms from patients and simultaneously improve their survival rate and quality of life. Due to its minimally invasive nature, TACE is only associated with severe complications in very few cases. Finally, TACE has played an important role in preventing progression of liver disease in transplant candidates and increase their chances of receiving a new liver.

# References

1. Ferlay J, Shin HR, Bray F, Forman D, Mathers C, Parkin DM. GLOBOCAN 2008 v1.2, Cancer Incidence and Mortality Worldwide: IARC CancerBase No. 10 [Internet] Lyon, France: International Agency for Research on Cancer, 2012. Available from: <http://globocan.iarc.fr>. Accessed January 2014.
2. Venook AP, Papandreou C, Furuse J, de Guevara LL. The incidence and epidemiology of hepatocellular carcinoma: a global and regional perspective. *Oncologist*. 2010;15 Suppl 4:5-13.
3. <http://www.cancer.gov/cancertopics/pdq/treatment/adult-primary-liver/HealthProfessional/page4>
4. Llovet JM. Updated treatment approach to hepatocellular carcinoma. *J Gastroenterol* 2005;40:225-235
5. Sanyal AJ, Yoon SK, Lencioni R. The etiology of hepatocellular carcinoma and consequences for treatment. *Oncologist*. 2010;15 Suppl 4:14-22.
6. Timothy M Block et al. Molecular viral oncology of hepatocellular carcinoma. *Oncogene* (2003) 22, 5093–5107.
7. Seldinger SI (1953). "Catheter replacement of the needle in percutaneous arteriography; a new technique". *Acta radiologica* 39 (5): 368–76
8. Kumamoto et al.: Dietary fructose enhances the incidence of precancerous hepatocytes induced by administration of diethylnitrosamine in rat. *European Journal of Medical Research* 2013 18:54
9. Steven A. Curley, et al. Radiofrequency Ablation of Hepatocellular Cancer in 110 Patients With Cirrhosis. *Ann Surg*. 2000 September; 232(3): 381–391.
10. Pons F et al (2005), Staging systems in hepatocellular carcinoma. *HPB*, 7: 35–41.
11. Llovet JM et al. Arterial embolisation or chemoembolisation versus symptomatic treatment in patients with unresectable hepatocellular carcinoma: a randomised controlled trial. *Lancet*. 2002 May 18;359(9319):1734-9.
12. Alejandro Forner, Amelia J. Hessheimer, M. Isabel Real, Jordi Bruix, Treatment of hepatocellular carcinoma, *Critical Reviews in Oncology/Hematology*, Volume 60, Issue 2, November 2006, Pages 89-98, ISSN 1040-8428, <http://dx.doi.org/10.1016/j.critrevonc.2006.06.001>.
13. Kenichi Takayasu. Transarterial Chemoembolization for Hepatocellular Carcinoma over Three Decades: Current Progress and Perspective. *Jpn J Clin Oncol* 2012;42(4)
14. Shrimal A. et al. Interventional Radiological Treatment of Hepatocellular Carcinoma: An Update. *Indian J Surg* (January–February 2012) 74(1):91–99
15. Llovet et al. The Barcelona Approach: Diagnosis, Staging, and Treatment of Hepatocellular carcinoma. *Liver Transplantation*, Vol 10, No 2, Suppl 1 (February), 2004: pp S115–S120
16. E. S. Bialecki & A. M. Di Bisceglie. Diagnosis of hepatocellular carcinoma. *HPB*, 2005; 7: 26–34.
17. Okuda, K., Ohtsuki, T., Obata, H., Tomimatsu, M., Okazaki, N., Hasegawa, H., Nakajima, Y. and Ohnishi, K. (1985), Natural history of hepatocellular carcinoma and prognosis in relation to treatment study of 850 patients. *Cancer*, 56: 918–928. doi: 10.1002/1097-0142(19850815)56:4<918::AID-CNCR2820560437>3.0.CO;2-E
18. Subramaniam S, Kelley RK, Venook AP. A review of hepatocellular carcinoma (HCC) staging systems. *Chin Clin Oncol* 2013;2(4):33. doi: 10.3978/j.issn.2304-3865.2013.07.05.
19. Daniele, B., Annunziata, M., Barletta, E., Tinessa, V. and Di Maio, M. (2007), Cancer of the Liver Italian Program (CLIP) score for staging hepatocellular carcinoma. *Hepatology Research*, 37: S206–S209. doi: 10.1111/j.1872-034X.2007.00186.
20. Nanashima A et al. The Japanese integrated staging score using liver damage grade for hepatocellular carcinoma in patients after hepatectomy. *Eur J Surg Oncol*. 2004 Sep;30(7):765-70.
21. Leung, T. W. T., Tang, A. M. Y., Zee, B., Lau, W. Y., Lai, P. B. S., Leung, K. L., Lau, J. T. F., Yu, S. C. H. and Johnson, P. J. (2002), Construction of the Chinese University Prognostic Index for hepatocellular carcinoma and comparison with the TNM staging system, the Okuda staging system, and the Cancer of the Liver Italian Program staging system. *Cancer*, 94: 1760–1769. doi: 10.1002/cncr.10384
22. Marrero et al. Prognosis of Hepatocellular Carcinoma: Comparison of 7 Staging Systems in an American Cohort. *HEPATOLOGY* 2005;41:707–716. DOI 10.1002/hep.20636.
23. EASL–EORTC Clinical Practice Guidelines: Management of hepatocellular carcinoma. *Journal of Hepatology* 2012 vol. 56 j 908–943. [http://www.easl.eu/assets/application/files/d38c7689f123edf\\_file.pdf](http://www.easl.eu/assets/application/files/d38c7689f123edf_file.pdf) Accessed: 13-02-2014.
24. G. Marin-Hargreaves et al. Hepatocellular carcinoma: Surgical Indications and Results. *Critical Reviews in Oncology/Hematology* 47 (2003) 13-/27. doi:10.1016/S1040-8428(02)00213-5.
25. Servet Tati et al. Radiofrequency ablation: technique and clinical applications. *Diagn Interv Radiol* 2012; 18:508–516.
26. Axel Häcker Bipolar and Multipolar Radio Frequency Ablation With Resistance Controlled Power Output: Standardized Ex Vivo Kidney Tissue Evaluation. DOI:10.1016/S0022-5347(05)00316-2
27. Tito Livraghi et al. Treatment of Focal Liver Tumors with Percutaneous Radio-frequency Ablation: Complications Encountered in a Multicenter Study. *Radiology* 2003; 226:441–451.
28. Tateishi R, Shiina S, Teratani T, et al. Percutaneous radiofrequency ablation for hepatocellular carcinoma. An analysis of 1000 cases. *Cancer* 2005; 103:1201–1209.
29. Stang A, Fischbach R, Teichmann W, Bokemeyer C, Braumann D. A systematic review on the clinical benefit and role of radiofrequency ablation as

- treatment of colorectal liver metastases. *Eur J Cancer* 2009; 45:1748–1756.
30. Nielsen K, van Tilborg AA et al. Incidence and treatment of local site recurrences following RFA of colorectal liver metastases. *World J Surg.* 2013 Jun;37(6):1340-7. doi: 10.1007/s00268-013-1997-6.
  31. MN Islam et al. Percutaneous ethanol injection for ablation of hepatocellular carcinoma. *Bang Med J (Khulna)* 2010; 43 : 12-17
  32. Shiina S et al. Percutaneous ethanol injection for hepatocellular carcinoma: 20-year outcome and prognostic factors. *Liver International* 2012 ISSN 1478-3223.
  33. Lin Z-Z, Shau W-Y, Hsu C, Shao Y-Y, Yeh Y-C, et al. (2013) Radiofrequency Ablation Is Superior to Ethanol Injection in Early-Stage Hepatocellular Carcinoma Irrespective of Tumor Size. *PLoS ONE* 8(11): e80276. doi:10.1371/journal.pone.0080276
  34. Shiina S et al. A Randomized Controlled Trial of Radiofrequency Ablation With Ethanol Injection for Small Hepatocellular Carcinoma. *Gastroenterology* 1 July 2005 (volume 129 issue 1 Pages 122-130 DOI: 10.1053/j.gastro.2005.04.009).
  35. Thuong G, Van Ha. Transarterial Chemoembolization for Hepatocellular Carcinoma. *Semin Intervent Radiol* 2009;26:270–275
  36. L. Marelli et al 2007. Transarterial Therapy for Hepatocellular carcinoma: Which technique is more effective? A systematic review of cohort and randomized studies. *Cardiovasc Intervent Radiol* (2007) 30:6–25.
  37. Lo et al. Randomized Controlled Trial of Transarterial Lipiodol Chemoembolization for Unresectable Hepatocellular Carcinoma. *Hematology Vol. 35, No. 5, 2002*
  38. Shi-Ying Wang et al. Nausea and Vomiting after Transcatheter Arterial Chemoembolization for Hepatocellular Carcinoma: Incidence and Risk Factor Analysis. *Asian Pacific Journal of Cancer Prevention, Vol 14, 2013.*
  39. Kessel D, Robertson I. *Interventional radiology, a survival guide.* Churchill Livingstone. (2005) ISBN:0443100446.
  40. Clark T.W.I. Complications of Hepatic Chemoembolization. *Semin Intervent Radiol* 2006;23:119–125.
  41. Shin. S.W. The current practice of Transarterial Chemoembolization for the Treatment of Hepatocellular carcinoma.
  42. Nakakuma K, Tashiro S, Hiraoka T, Uemura K, Konno T, Miyauchi Y, et al. Studies on anticancer treatment with an oily anticancer drug injected into the ligated feeding hepatic artery for liver cancer. *Cancer* 1983;52:2193-2200.
  43. Kan Z, McCuskey PA, Wright KC, Wallace S. Role of Kupffer cells in iodized oil embolization. *Invest Radiol* 1994;29:990-993.
  44. Carter S, Martin Ii RC. Drug-eluting bead therapy in primary and metastatic disease of the liver. *HPB (Oxford).* 2009 Nov;11(7):541-50.
  45. Liao M, Huang J, Zhang T, Wu H (2013) Transarterial Chemoembolization in Combination with Local Therapies for Hepatocellular Carcinoma: A Meta-Analysis. *PLoS ONE* 8(7): e68453. doi:10.1371/journal.pone.0068453
  46. R.Dhanasekaran et al. Comparison of Conventional Transarterial Chemoembolization (TACE) and Chemoembolization With Doxorubicin Drug Eluting Beads (DEB) for Unresectable Hepatocellular Carcinoma (HCC). *Journal of Surgical Oncology* 2010;101:476–480.
  47. Wood RW, Loomis AL. The physical and biological effects of high frequency sound waves of great intensity. *Philos Mag* 1927;4:417
  48. Kim YS et al High-intensity focused ultrasound therapy: an overview for radiologists. *Korean J Radiol.* 2008 Aug;9(4):291-302. doi: 10.3348/kjr.2008.9.4.291.
  49. Tachibana K, Tachibana S. The use of ultrasound for drug delivery. *Echocardiography* 2001;18:323-328
  50. Wu F, Wang ZB, Chen WZ, Zou JZ, Bai J, Zhu H, et al. Advanced hepatocellular carcinoma: treatment with high- intensity focused ultrasound ablation combined with transcatheter arterial embolization. *Radiology* 2005;235:659- 667
  51. Servet Tatlı, Percutaneous cryoablation techniques and clinical applications *Diagn Interv Radiol* 2010; 16:90–95
  52. Silverman SG, Tuncali K, Adams DF, et al. MR imaging-guided percutaneous cryo- therapy of liver tumors: initial experience. *Radiology* 2000; 217:657–664.
  53. Christopher L. Brace, Microwave ablation technology: What every use should know. *Curr Probl Diagn Radiol.* 2009 Mar–Apr; 38(2): 61–67.
  54. Caroline J. Simon, MD, et al Microwave Ablation: Principles and Applications. *RadioGraphics* 2005;25:S69–S83
  55. Dr David A. Iannitti et al. Hepatic tumor ablation with clustered microwave antennae: the US Phase II Trial. *HPB (Oxford).* 2007; 9(2): 120–124.