

Endoscopic Removal of Medially Migrated Tympanostomy Tube

Malić, Mislav; Miličić, Borna; Gjurić, Mislav

Source / Izvornik: **Ear, Nose & Throat Journal, 2021, 100, NP191 - NP192**

Journal article, Published version

Rad u časopisu, Objavljena verzija rada (izdavačev PDF)

<https://doi.org/10.1177/0145561319869606>

Permanent link / Trajna poveznica: <https://urn.nsk.hr/urn:nbn:hr:105:117856>

Rights / Prava: [Attribution-NonCommercial 4.0 International/Imenovanje-Nekomercijalno 4.0 međunarodna](#)

Download date / Datum preuzimanja: **2024-09-15**



Repository / Repozitorij:

[Dr Med - University of Zagreb School of Medicine Digital Repository](#)



Endoscopic Removal of Medially Migrated Tympanostomy Tube

Ear, Nose & Throat Journal
2021, Vol. 100(4) NP191–NP192
© The Author(s) 2019
Article reuse guidelines:
sagepub.com/journals-permissions
DOI: 10.1177/0145561319869606
journals.sagepub.com/home/ear



Mislav Malic, MD¹ , Borna Milicic, MD¹, and Mislav Gjuric, MD, PhD¹

A 5-year-old male patient was referred to our clinic after an unsuccessful attempt of extraction of a tympanostomy tube, which migrated in the tympanic cavity, by a surgeon who initially inserted it 18 months ago in another institution. Audiometric examination was normal, and tube was in a correct position on the first 2 control examinations 1 and 3 months after the insertion. Next examination 16 months after the initial procedure revealed tube to be medial to an intact tympanic membrane. Due to position of the tube far anterior in the anterior superior quadrant of the tympanic cavity, surgeon was not able to remove it microscopically through ear speculum. On our initial examination 2 weeks after the aforementioned failed extraction attempt, a bluish shadow could be seen under the tympanic membrane anterior to manubrium of the malleus (Figure 1). We decided to perform an endoscopic exploration; 14-cm long and 3-mm wide 0° endoscope was used. Although the position of the tube was far anterior under the annulus, with an endoscope, we could easily approach tympanic membrane near the tube. In that way, we avoided the need to do a canal incision and tympanomeatal flap elevation. Typical myringotomy incision was made through which the tube was clearly seen and extracted with a small alligator forceps (Figures 2 and 3). The patient recovered well without postoperative complications.

Etiology of the medial migration of tympanostomy tube (MMTT) is not fully understood with 2 main theories proposed. First possibility is that an oversized incision during myringotomy leads to improper placement of a tube. The second theory is based on a primary variation of the tympanic cavity anatomy, such as abnormally deep hypotympanic cleft, leading to possible medial displacement of the correctly positioned tube, which would likely be our case. Groblewski and Harley proposed a classification based on those 2 theories in primary and secondary.¹ Another likely mechanism occurs in the process of epithelial immigration during cholesteatoma formation, during which squamous epithelium progresses from the margin of a tympanic perforation into the middle ear cleft.² Bezdjian et al in a review of literature on MMTT found only 10 reports with total of 29 cases. The authors concluded that removal of a migrated tube should be offered to the patients in light of the rare, yet potentially serious complications that could develop many years

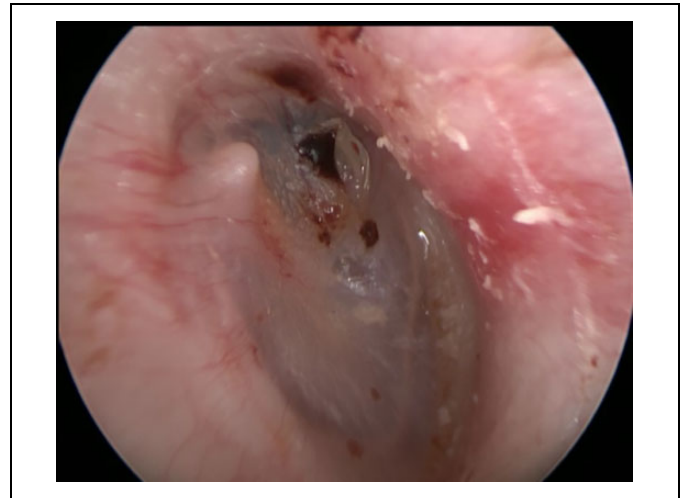


Figure 1. Oto endoscopic examination showing bluish shadow under healed tympanic membrane in anterior superior quadrant.

later, and pointed out the low morbidity associated with surgical removal.²

To the best of our knowledge, this is the first report of using an endoscope for managing this rare complication. Endoscopic ear surgery (EES) offers the possibility of minimally invasive surgery, where even more extensive disease can safely be surgically managed through the external ear canal.^{3,4} The authors who compared EES to microscopic ear surgery (MES) in myringotomy or myringoplasty as well as placing tympanostomy tubes reported results which are comparable if not better than MES.^{5,6} Endoscopic technique was also reported very effective in other procedures, such as ossiculoplasty, stapedotomy, or cholesteatoma surgery, allowing visualization of the middle ear

¹ Department of ENT and H&N Surgery, University Hospital Centre Zagreb, Zagreb, Croatia

Received: April 23, 2019; revised: June 24, 2019; accepted: July 19, 2019

Corresponding Author:

Mislav Malic, MD, Department of ENT & H&N Surgery, University Hospital Centre Zagreb, Kišpatičeva 12, 10000 Zagreb, Croatia.

Email: mislav.malic@gmail.com



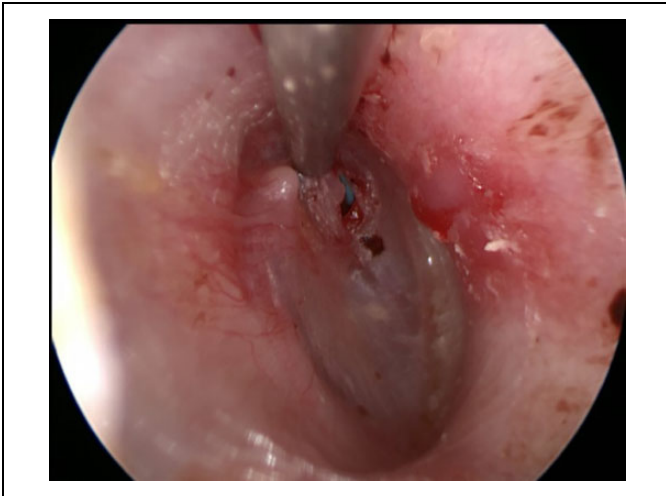


Figure 2. After the myringotomy incision with a sickle knife, tube is visualized in the tympanic cavity.

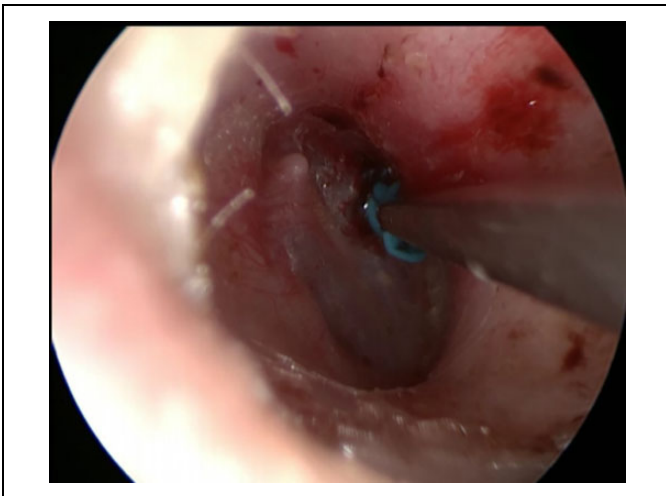


Figure 3. Tube extraction with a small alligator forceps.

structures from angles which couldn't be possible with MES, therefore lowering the recurrence rate. Endoscopic ear surgery can be a valuable tool in education, allowing demonstration of surgical steps and anatomical relationships of tympanic membrane and middle ear.⁷ Drawback of EES is that surgeon holds the endoscope with one hand and operates with other, meaning increased difficulty of managing the potential stronger bleeding, which is not likely due to lesser disruption of healthy tissue. However, in simple procedures like this, use of endoscope offers us clear view of the whole tympanic membrane even in the narrow canal, often seen in children, thus avoiding the need for tympanomeatal flap elevation and more extensive surgery.

In summary, we presented a rare complication of a very common surgical procedure, which allowed us to demonstrate the use of endoscope for extraction of the MMTT. Leaving a foreign object in the middle ear cleft can lead to potentially serious complications, such as conductive hearing loss, pain, chronic otitis media, or cholesteatoma, and therefore we propose endoscopic myringotomy and extraction as a method of choice for dealing with this complication.

Authors' Note

This case presentation was approved by the University Hospital Centre Zagreb, Zagreb, and Bioethical Board adhering to the Helsinki Declaration of 1983. Full written informed consent was obtained from the patient in using images of tissue samples and radiologic imaging after discussing the details of the case report contents. All of the authors have read and approved the manuscript, and all authorship contributions have been verified to adhere to ICMJE guidelines.


Declaration of Conflicting Interests

The author(s) declared no potential conflicts of interest with respect to the research, authorship, and/or publication of this article.

Funding

The author(s) received no financial support for the research, authorship, and/or publication of this article.

ORCID iD

Mislav Malic  <https://orcid.org/0000-0003-3260-5146>

References

1. Groblewski JC, Harley EH. Medial migration of tympanostomy tubes: an overlooked complication. *Int J Pediatr Otorhinolaryngol.* 2006;70(10):1707-1714. doi:10.1016/j.ijporl.2006.05.015.
2. Bezdjian A, Maby A, Daniel SJ. To remove or not to remove: review of cases of medial migration of tympanostomy tubes. *Int J Pediatr Otorhinolaryngol.* 2015;79(11):1793-1797. doi:10.1016/j.ijporl.2015.08.008.
3. Tarabichi M. Endoscopic middle ear surgery. *Ann Otol Rhinol Laryngol.* 1999;108(1):39-46. doi:10.1177/000348949910800106.
4. Tarabichi M. Endoscopic management of limited attic cholesteatoma. *Laryngoscope.* 2004;114(7):1157-1162. doi:10.1097/00005537-200407000-00005.
5. Martellucci S, Pagliuca G, de Vincentiis M, et al. Myringotomy and ventilation tube insertion with endoscopic or microscopic technique in adults: a pilot study. *Otolaryngol Neck Surg.* 2015;152(5):927-930. doi:10.1177/0194599815576906.
6. Han S-Y, Lee DY, Chung J, Kim YH. Comparison of endoscopic and microscopic ear surgery in pediatric patients: a meta-analysis. *Laryngoscope.* 2018;129(6):1444-1452. doi:10.1002/lary.27556.
7. Mohindra S, Panda NK. Ear surgery without microscope; is it possible. *Indian J Otolaryngol Head Neck Surg.* 2010;62(2):138. doi:10.1007/s12070-010-0033-5.