

A novel autologous bone graft substitute containing rhBMP6 in autologous blood coagulum with synthetic ceramics for reconstruction of a large humerus segmental gunshot defect in a dog: The first veter ...

Pećin, Marko; Štoković, Nikola; Ivanjko, Natalia; Smajlović, Ana; Kreszinger, Mario; Capak, Hrvoje; Vrbanac, Zoran; Oppermann, Hermann; Matičić, Dražen; Vukičević, Slobodan

Source / Izvornik: **Bone Reports, 2021, 14**

Journal article, Published version

Rad u časopisu, Objavljena verzija rada (izdavačev PDF)

<https://doi.org/10.1016/j.bonr.2021.100759>

Permanent link / Trajna poveznica: <https://um.nsk.hr/um:nbn:hr:105:778934>

Rights / Prava: [Attribution-NonCommercial-NoDerivatives 4.0 International/Imenovanje-Nekomercijalno-Bez prerada 4.0 međunarodna](#)

Download date / Datum preuzimanja: **2024-07-28**



Repository / Repozitorij:

[Dr Med - University of Zagreb School of Medicine Digital Repository](#)





Case Report

A novel autologous bone graft substitute containing rhBMP6 in autologous blood coagulum with synthetic ceramics for reconstruction of a large humerus segmental gunshot defect in a dog: The first veterinary patient to receive a novel osteoinductive therapy

Marko Pecin^a, Nikola Stokovic^b, Natalia Ivanjko^b, Ana Smajlovic^a, Mario Kreszinger^a, Hrvoje Capak^c, Zoran Vrbanac^c, Hermann Oppermann^d, Drazen Maticic^a, Slobodan Vukicevic^{b,*}

^a Clinics for Surgery, Orthopedics and Ophthalmology, Faculty of Veterinary Medicine, University of Zagreb, Zagreb, Croatia

^b Laboratory for Mineralized Tissues, Centre for Translational and Clinical Research, School of Medicine, University of Zagreb, Zagreb, Croatia

^c Department of Radiology, Ultrasound Diagnostics and Physical Therapy, Faculty of Veterinary Medicine, University of Zagreb, Zagreb, Croatia

^d Genera Research, Kalinovica, Rakov Potok, Croatia



ARTICLE INFO

Keywords:

Bone morphogenetic proteins
BMP
TCP
Bioceramics
Segmental defect
Tissue engineering

ABSTRACT

Background: Management of large segmental defects is one of the most challenging issues in bone repair biology. Autologous bone graft substitute (ABGS) containing rhBMP6 within autologous blood coagulum (ABC) with synthetic ceramics is a novel biocompatible therapeutic solution for bone regeneration.

Case presentation: A 2-year old dog was brought to the veterinary clinics due to pain and bleeding from the right front leg after being unintentionally hit by a gunshot. Radiological examination revealed a large, 3 cm long multisegmental defect of the humerus on the right front leg with a loss of anatomical structure in the distal portion of the bone. The defect was treated surgically and an external fixator was inserted to ensure immobilization. Complete lack of bone formation 3 months following surgery required a full reconstruction of the defect site with a novel ABGS (rhBMP6 in ABC with ceramic particles) to avoid front leg amputation. The healing was then followed for the next 16 months. The callus formation was observed on x-ray images 2 months following ABGS implantation. The bone segments progressively fused together leading to the defect rebridgment allowing removal of the external fixator by 4 months after the reconstruction surgery. At the end of the observation period, the function of the leg was almost fully restored while analyses of the humeral CT sections revealed restoration and cortices rebridgment with a renewal of uniform medullary canal including structural reconstruction of the distal humerus.

Conclusion: This large humeral gunshot segmental defect of the front leg in a dog was saved from amputation via inducing bone regeneration using a novel ABGS osteoinductive device containing BMP6 in ABC.

1. Introduction

Gunshot fractures are often severe, multifragmentary, and require stabilization and treatment. External fixation is regularly used with the promotion of “biologic” fracture repair strategies (Harasen, 2002). Large bone defects rarely heal spontaneously. Severe trauma that involves a complex fracture and/or loss of soft tissues often leads to limb amputation. In a retrospective study of gunshot injuries, 166 dogs treated in

our institution had a 20.5% fracture rate (Capak et al., 2016) while 65 cats with gunshot injuries had 39.9% fractures (Vnuk et al., 2016).

The repair of segmental long bones defects is one of the most challenging issues in bone biology because they do not heal spontaneously by the intrinsic repair capacity due to a biologically hampered environment (Dumic-Cule et al., 2015; Lammens et al., 2020). To achieve healing, four factors are required including osteoinductive growth factors, presence of osteogenic cells, osteoconductive scaffold, and

* Corresponding author at: Laboratory for Mineralized Tissues, Center for Translational and Clinical Research, University of Zagreb School of Medicine, Salata 11, 10000 Zagreb, Croatia.

E-mail address: slobodan.vukicevic@mef.hr (S. Vukicevic).

<https://doi.org/10.1016/j.bonr.2021.100759>

Received 10 November 2020; Received in revised form 1 February 2021; Accepted 22 February 2021

Available online 25 February 2021

2352-1872/© 2021 The Author(s). Published by Elsevier Inc. This is an open access article under the CC BY-NC-ND license

(<http://creativecommons.org/licenses/by-nc-nd/4.0/>).

mechanical stability, collectively called a “diamond concept” (Gianoudis et al., 2007).

Bone morphogenetic proteins (BMPs) are potent osteoinductive agents that recruit mesenchymal stem cells and promote their proliferation and differentiation into bone and cartilage during embryonic development (Sampath and Vukicevic, 2020; Vukicevic and Grgurevic, 2009). Autologous blood coagulum (ABC) is a novel physiological BMP carrier that supports tight BMP binding to plasma proteins within the fibrin meshwork, suppresses foreign body response, and allows a sustained *in vitro* release of rhBMP6 (Vukicevic et al., 2014; Grgurevic et al., 2019; Vukicevic et al., 2020a; Vukicevic et al., 2020b). To improve biomechanical properties of implants, compression resistant matrix (CRM) could be added to implants in selected indications (Vukicevic et al., 2020a). Therefore, different bone graft substitutes with various scaffolds and growth factor combinations have been tested with and without cells, but the efficacy of bone formation remained unpredictable (Wang and Yeung, 2017; Palombella et al., 2019; Ho-Shui-Ling et al., 2018; Vukicevic et al., 2019; Kuroiwa et al., 2019). Also, cell-based Advanced Therapy Medicinal Product (ATMPs) such as combinatorial implants comprised of periosteum-derived stem cells with dicalcium phosphate scaffold coated with BMP6 or BMP2 were recently proven efficacious in 4,5 cm long biologically compromised defects of the sheep tibia (Lammens et al., 2020).

We have recently demonstrated that an autologous bone graft substitute (ABGS) containing recombinant human bone morphogenetic protein 6 (rhBMP6) within ABC with and without allograft as a CRM was safe and efficacious in the rabbit ulnar segmental defect model (Grgurevic et al., 2019), rabbit and ovine posterolateral spinal fusion (PLF) and sheep anterior lumbar interbody fusion (ALIF) models (Vukicevic et al., 2020a; Grgurevic et al., 2020). In continuation, the ABGS was tested in Phase I clinical trials in patients with distal radial fracture (Durdevic et al., 2020), and Phase I/II trial in patients undergoing high tibial osteotomy (Chiari et al., 2020) and was proven safe and efficacious as compared to placebo and standard of care treated patients. ABGS with the addition of allograft as a CRM is currently used in a posterolateral lumbar interbody fusion (PLIF) clinical study in patients with lumbar back pain due to a degenerative disc disease (EudraCT number 2017-000860-14).

Since the use of allograft has several disadvantages including regulatory issues, immunogenicity, and viral transmission risk (Mroz et al., 2009), we recently tested ABGS with synthetic calcium phosphate ceramics (tricalcium phosphate (TCP), hydroxyapatite (HA), and biphasic ceramics containing TCP and HA in various ratios) as a CRM. Superior osteoinductive and osteoconductive properties of ABGS with synthetic ceramics were confirmed in a rat subcutaneous assay (Stokovic et al., 2020a; Stokovic et al., 2020b), and in a rabbit spine PLF model due to successful new bone integration with native transverse processes of lumbar vertebrae (Stokovic et al., 2020c).

Here, we report on the first veterinary patient treated with a novel ABGS osteoinductive device following an unsuccessful union of a humeral segmental defect. The overview of this case study is presented in Fig. 1A.

2. Case presentation – reconstruction of a segmental bone defect

A 2-year old dog (mixed breed, 5.4 kg) was brought to the Clinics for Surgery, Orthopedics, and Ophthalmology at the Faculty of Veterinary Medicine (University of Zagreb, Zagreb, Croatia) due to pain and bleeding from the right front leg after an unintended hit by a gunshot. Clinical and radiological examination revealed a large, segmental defect of the distal part of the right front leg humerus (Figs. 1B, 2A). Almost 1/3 of the total bone length was missing. Spherical metallic shots were present in the surrounding tissues of the defect (Fig. 1B). The dog was treated surgically and an external fixator (IMEX, 20 cm) (Fig. 1C3) was inserted to ensure immobilization of the leg. After a lateral approach to the fracture site an «open but do not touch» technique was used and some fragments of the bullet and dead bone were removed. In remnants of the distal diaphysis of the humerus a Schanz pin (4.0 mm, Centerface® Positive-profile ESF Full-pin, IMEX Veterinary, Inc.) was inserted through condyles and connected medially with a cranially inserted Schanz pin (4.0 mm, Interface® Standard thread ESF Half-pin, IMEX Veterinary, Inc.). The loss of bone tissue above the humeral condyles was about 3 cm. A distal part of the diaphysis was completely missing (Fig. 2A, red arrow). A transcondylar distal Schanz pin was laterally connected with the connecting bar to the proximal Schanz pin placed also from the lateral to the medial side to finally construct a biplanar

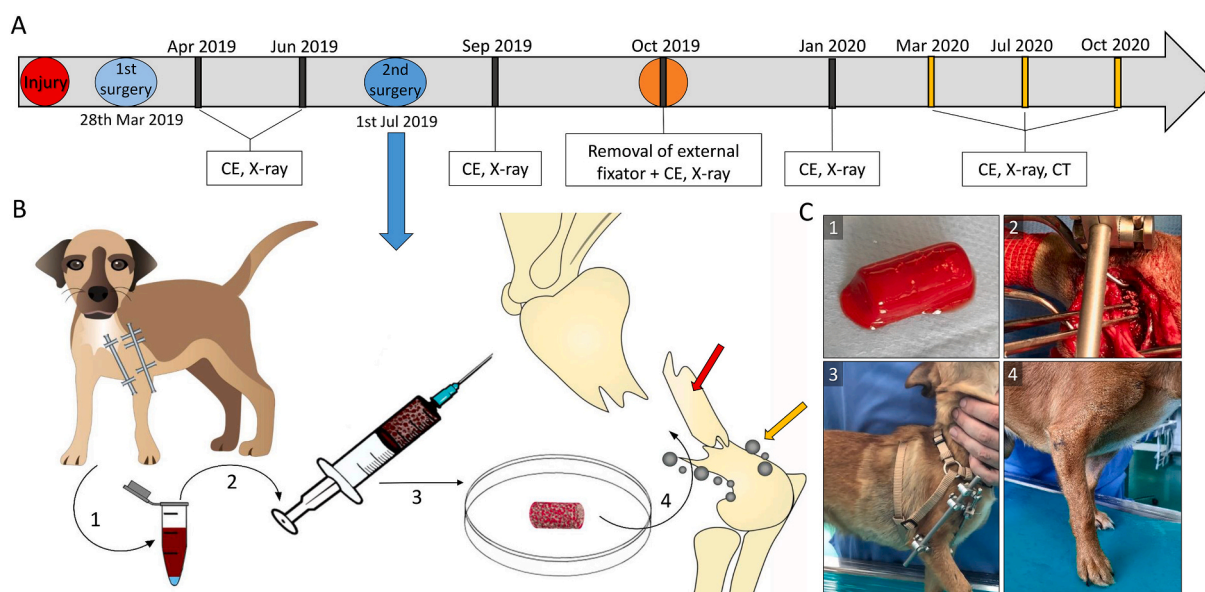


Fig. 1. (A) Timeline showing dates of gunshot injury, 1st and 2nd surgery, and monitoring including clinical examinations (CE), X-ray, and CT. (B) Implant preparation and implantation on the segmental defect site. (1) Blood was collected from the cephalic vein in a volume of 2,5 mL and mixed with rhBMP6 (250 µg), (2) whereupon it was withdrawn into a syringe containing CRM. (3) ABGS implant was left on the RT to coagulate. (4) Implantation into the gunshot injury area. The yellow arrow indicates gunshot pellet residuals, while the red arrow indicates a bone fragment. (C) (1) ABGS containing rhBMP6, ABC, and CRM. (2) Implantation of ABGS. (3) External fixator after surgery. (4) Restored full weight bearing of the leg on the last clinical examination.

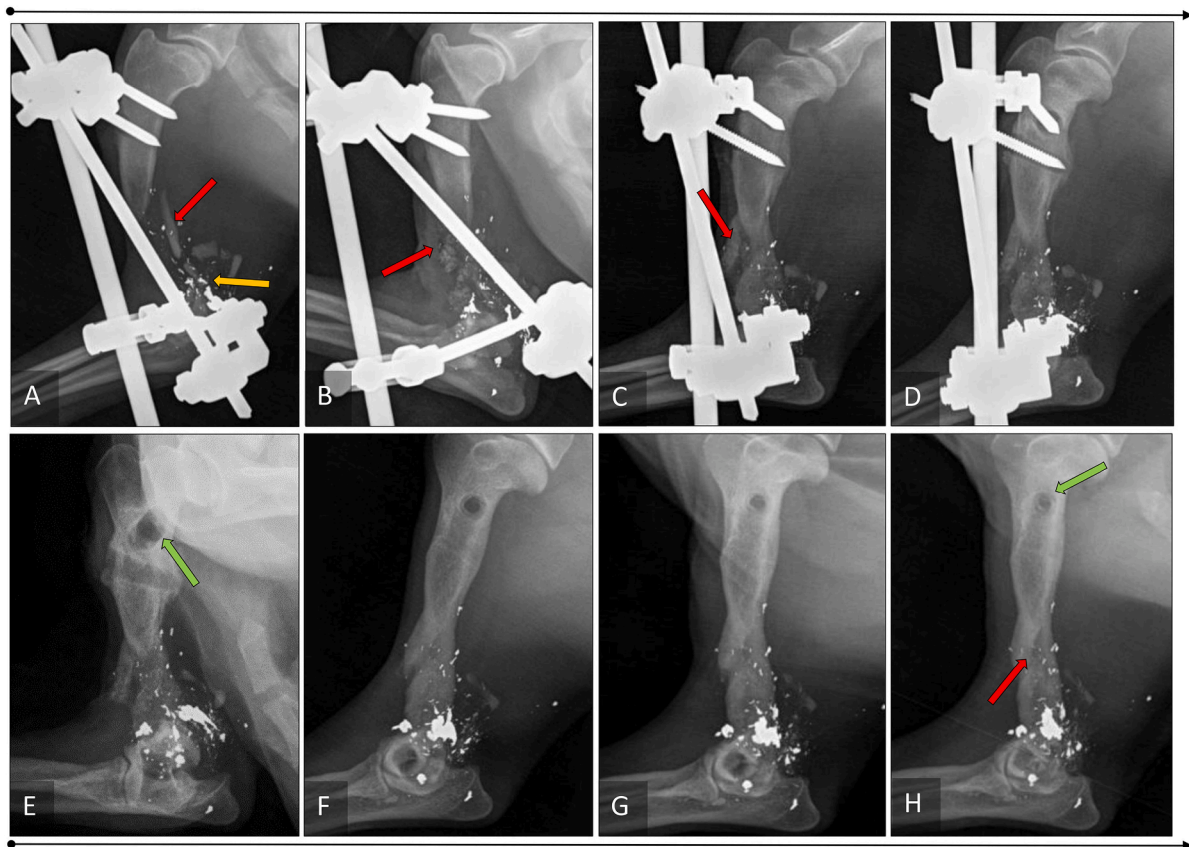


Fig. 2. X-ray images showing the progress of humeral segmental bone defect healing. (A) X-ray image taken before 2nd surgery (Jun 2019); red arrow indicates a bone fragment, while yellow arrow indicates gunshot pellet residuals. (B) X-ray image taken after the 2nd reconstruction surgery (Jul 2019) showing bone fragment placed on the site of fracture. (C,D) The continuous progress of healing with fusion of bone fragments. (E,F,G,H) X-ray images showing the continuation of healing following external fixator removal and successful integration of the misplaced bone fragment (red arrow). The green arrow indicates the progressive decrease of the external fixator pinholes.

bilateral (hybrid) external fixator. The stability of bone fragments was acceptable and post operative x-ray in standard projections revealed that the normal length of bone was achieved with aligned bone axes. Bone fragments were displaced and gun shots remained accumulated

around the distal humerus (Figs. 2A and 3A). The elbow range of motion was 30–40% preserved without full flexion and extension. The X-ray controls were performed monthly for the next three months (Fig. 2A). However, a complete lack of the defect rebridgment and absence of bone

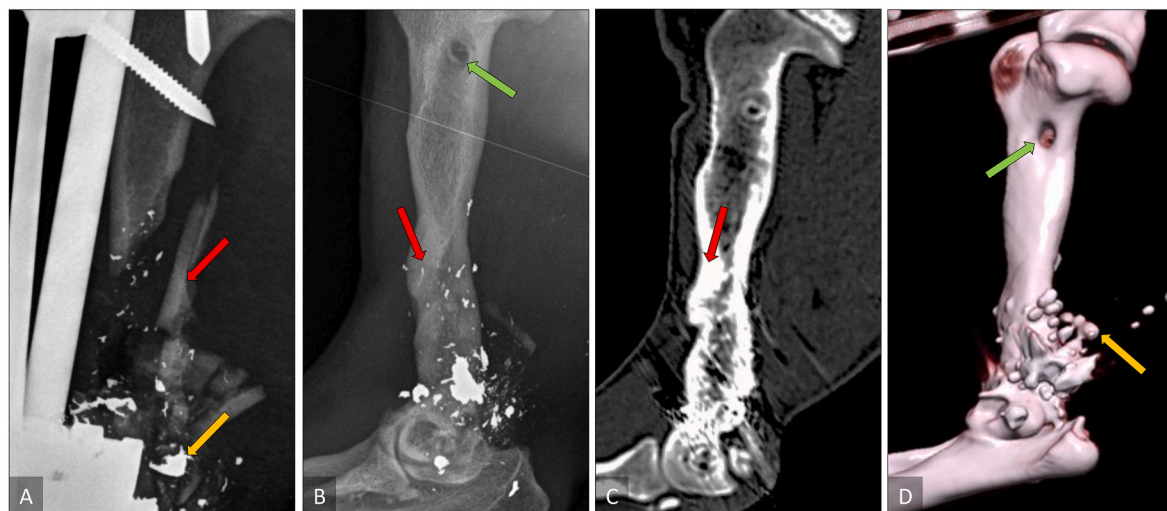

Fig. 3. (A) The X-ray image after the initial surgery using external fixator for the leg immobilization. The red arrow indicates a bone fragment, while the yellow arrow indicates gunshot pellet residuals. (B) X-ray image taken on the last clinical examination; red arrow indicates a bone fragment which was successfully integrated into the regenerated bone continuum, while green arrow indicates holes of removed external fixator pins. (C) CT section and (D) 3D reconstruction taken on the last visit confirming humeral segmental defect restoration.

formation was evident with distal fragments displaced more caudally due to bone atrophy (Fig. 2A), and the bone defect was greater than before (4 cm). The surgical revision (Fig. 1A, 2nd surgery) was performed without removing the external fixator (Fig. 1C2). The fracture site was approached laterally, the fibrous tissue was removed and fracture ends and the medullary bone canal were refreshed. The larger bone diaphysal fragment displaced laterally from the proximal humeral diaphysis was relocated medially, closer to the adjacent bone (Fig. 2B). To avoid the front leg amputation, a novel ABGS containing rhBMP6 in ABC with ceramic particles (Fig. 1C1) was used following approval of the Ethics Committee at the Faculty of Veterinary Medicine. The ABGS was prepared as follows: blood (2,5 mL) was withdrawn into a tube containing 250 µg of rhBMP6 and moved to a syringe (BD 5 mL) containing 500 mg of TCP particles (particle size 500–1700 µm) (Fig. 1B). Blood was mixed with TCP to achieve a uniform distribution of particles in the implant and left to coagulate for 60 min (Fig. 1B). ABGS was cut into several pieces and adapted to fill in the segmental defect (Fig. 1B, C2).

The dog was premedicated with methadone 0,2 mg/kg (Comfortan, Netherlands), midazolam 0,2 mg/kg (B. Braun, Germany), and ketamine 1 mg/kg (Ketamidol, Austria). After induction with propofol 2 mg/kg i. v. (B. Braun, Germany), and lidocaine in a dosage of 0,6 mg/kg i.v. (B. Braun, Germany), the animal was endotracheally intubated. During surgical procedures, anesthesia was maintained with isoflurane in combination with oxygen and air. Postoperatively analgesia was maintained with NSAID (Meloxidolor, Netherlands, 0,2 mg/kg i.v.) and fentanyl patch (Matrifan, Denmark, 12 µg/h).

The dog was then followed and examined at 2, 4, 6, 8, 12, and 16 months (Figs. 1A, 2B–H, 3B–D). The callus formation was observed on x-ray images at 2 months following ABGS implantation and fragments realignment (Fig. 2C–D). At four months following surgery, the defect was rebridged and the external fixator removed (Fig. 2E–H).

At 8, 12, and 16 months CT scans (SOMATOM go.Now, Siemens AG, Germany) revealed that both the cortical bone and the medullary cavity of newly formed bone established continuity with the proximal part of the humerus (Fig. 3C–D), while the distal end was restored via structurally competent newly formed bone, the fusion of the bone segments and their integration. A complete bone remodeling has begun and will continue until the replacement of the old bone.

3. Discussion

In this report of the first veterinary patient to receive a novel osteoinductive BMP6 in ABC based therapy, we reported a 2-year old dog with a large segmental defect of the distal part of humerus caused by a gunshot. A complete lack of the new bone formation following primary surgery prompted us to use the novel ABGS with synthetic ceramics as an experimental therapy in an attempt to prevent the front leg amputation. The efficacy and safety of this ABGS device for the treatment of critical size bone defects has been previously demonstrated in rabbits (Grgurevic et al., 2019). To improve the implant biomechanical properties, we supplemented ABGS with allograft as a compression resistant matrix (Vukicevic et al., 2020a). Next, we tested synthetic ceramics of various chemical compositions (TCP, HA, BCP) formulated either as particles (Stokovic et al., 2020a) or blocks (Stokovic et al., 2020b) and demonstrated superior osteoconductive properties to support bone formation by rhBMP6 in ABC. Here we demonstrate for the first time a successful use of ABGS with synthetic ceramic particles to achieve a full rebridgment and reconstitution of the segmental bone defect in a biologically hampered microenvironment without any sign of spontaneous healing following osteosynthetic stabilization. The function of the dog's front leg was restored and the external fixator removed 4 months following the ABGS reconstructive surgery. The therapeutic strategy used in the dog fulfilled the requirements of the "diamond" concept (Giannoudis et al., 2007). In this compromised microenvironment and potential initial infection at the site as a consequence of remaining shells around the

skeletal structures, ABGS with BMP6 in ABC and ceramics induced bone healing with a successful clinical outcome. The bone formation between displaced humeral fragments was evident within 2 months following implantation and the holes of external fixator pins were fully restored following removal of the external fixator. The healing of this "war-like" segmental bone injury suggests that BMP6 within ABC as a natural carrier supported regeneration of the dog's leg due to the high efficacy of ABGS components and an appropriate rhBMP6 dose. BMP6 is superior to BMP2 and BMP7 in stimulating bone formation both *in vitro* and *in vivo* (Song et al., 2010; Vukicevic and Grgurevic, 2009) because it acts *via* all BMP type I receptors. In addition, BMP6 is, unlike BMP2 and BMP7, resistant to Noggin which is the main BMP antagonist present in an increased amount in bone (Song et al., 2010) allowing the use of low BMP6 concentration per mL of ABC (Grgurevic et al., 2019; Sampath and Vukicevic, 2020; Grgurevic et al., 2020; Durdevic et al., 2020; Chiari et al., 2020). BMP2 with bovine collagen has been used previously in dogs with long bone non-unions; however, the follow-up period of mostly 5–8 weeks was not long enough to pronounce successful healing since large defects need at least 4–8 months to demonstrate the cortical rebridgment and biomechanical stability after osteosynthesis removal (Itoh et al., 1998; Milovancev et al., 2007; Peric et al., 2015). The use of this novel ABGS device in veterinary medicine will be considered, particularly in complex bone injuries when physiological healing mechanisms fail. It has been demonstrated that BMPs can act more efficiently than autologous bone grafts in a contaminated bone environment. For example, BMP6 regulated a gene expression repertoire reminiscent of type I interferon signaling by inducing upregulation of interferon (IFN) and by downregulating an inhibition of IFN signaling. However, BMP6 and activin A act also independently of IFN and can inhibit the replication of viruses, like chronic hepatitis C virus *via* SMAD1 signaling (Eddowes et al., 2019). BMP6 primarily induced the differentiation of local mesenchymal stem cells into chondrogenic and osteogenic lineages (Vukicevic and Grgurevic, 2009) with a subsequent formation of the endochondral bone required to rebridge the defect while TCP ceramic particles enhanced the implant's biomechanical properties, supported the bone formation and were resorbed over time. The external fixator provided initial mechanical stability but the bone healing following the first surgical intervention failed. Treatment of large bone defect is an unmet medical need and therefore many improvements including scaffold technology (Lammens et al., 2020; Roberts et al., 2011), increased survival and priming of implanted cells (De Bari et al., 2006; Stegen and Carmeliet, 2019; Bolander et al., 2017; Bolander et al., 2020), and optimization of growth factor dosing (Bouyer et al., 2016) will be tested in large animal models with compromised bone defects biology to better mimic the human situation and achieve unprotected weight-bearing. We aim to treat more veterinary patients with various bone injuries using this novel ABGS osteoinductive implant containing ABC with dispersed rhBMP6 and compression resistant matrix.

4. Conclusion

We reported a dog with a large gunshot segmental bone defect as the first veterinary patient whose leg was saved from amputation by inducing bone regeneration with a novel ABGS device. Successful use of ABGS to restore a critical size segmental defect suggests that this novel ABGS might become a therapeutic solution for segmental defects in clinical practice, and will be further evaluated in complex veterinary bone injuries requiring enhanced osteoinductive signaling in the reconstruction of the skeleton.

Declaration of competing interest

HO is an employee of Genera Research; SV and HO hold a patent WO2019076484A1 issued to Genera Research.

Acknowledgements

This program was funded by the FP7 Health Program (FP7/2007-2013) under grant agreement HEALTH-F4-2011-279239 (Osteogrow), H2020 Health GA 779340 (OSTEOPROSPINE), and European Regional Development Fund - Scientific Center of Excellence for Reproductive and Regenerative Medicine (project "Reproductive and regenerative medicine - exploration of new platforms and potentials," GA KK.01.1.1.01.0008 funded by the EU through the ERDF).

References

- Bolander, J., Ji, W., Leijten, J., Teixeira, L.M., Bloemen, V., Lambrechts, D., Chaklader, M., Luyten, F.P., 2017. Healing of a large long-bone defect through serum-free in vitro priming of human periosteum-derived cells. *Stem Cell Reports* 8 (3), 758–772.
- Bolander, J., Herpelinck, T., Chaklader, M., Gklava, C., Geris, L., Luyten, F.P., 2020. Single-cell characterization and metabolic profiling of in vitro cultured human skeletal progenitors with enhanced in vivo bone forming capacity. *Stem Cells Transl. Med.* 9 (3), 389–402.
- Bouyer, M., Guillot, R., Lavaud, J., Plettinx, C., Olivier, C., Curry, V., Boutonnat, J., Coll, J.L., Peyrin, F., Josserand, V., Bettega, G., Picart, C., 2016. Surface delivery of tunable doses of BMP-2 from an adaptable polymeric scaffold induces volumetric bone regeneration. *Biomaterials* 104, 168–181.
- Capak, H., Brkljaca Bottegaro, N., Manojlovic, A., Smolec, O., Vnuk, D., 2016. Review of 166 gunshot injury cases in dogs. *Top. Companion Anim. Med.* 31 (4), 146–151.
- Chiari, C., Grgurevic, L., Bordukalo-Niksic, T., Oppermann, H., Valentinitich, A., Nemecek, E., Staats, K., Schreiner, M., Trost, C., Kolb, A., Kainberger, F., Pehar, S., Milesevic, M., Martinovic, S., Peric, M., Sampath, T.K., Vukicevic, S., Windhager, R., 2020. Recombinant human BMP6 applied within autologous blood coagulum accelerates bone healing: randomized controlled trial in high Tibial osteotomy patients. *J. Bone Miner. Res.* 35 (10), 1893–1903.
- De Bari, C., Dell'Accio, F., Vanlauwe, J., Eyckmans, J., Khan, I.M., Archer, C.W., Jones, E. A., McGonagle, D., Mitsiadis, T.A., Pitzalis, C., Luyten, F.P., 2006. Mesenchymal multipotency of adult human periosteal cells demonstrated by single-cell lineage analysis. *Arthritis Rheum.* 54 (4), 1209–1221.
- Dumic-Cule, I., Pecina, M., Jelic, M., Jankolija, M., Popek, I., Grgurevic, L., Vukicevic, S., 2015. Biological aspects of segmental bone defects management. *Int. Orthop.* 39 (5), 1005–1011.
- Durdevic, D., Vlahovic, T., Pehar, S., Miklic, D., Oppermann, H., Bordukalo-Niksic, T., Gavrankapetanovic, I., Jamakosmanovic, M., Milesevic, M., Martinovic, S., Sampath, T.K., Peric, M., Grgurevic, L., Vukicevic, S., 2020. A novel autologous bone graft substitute comprised of rhBMP6 blood coagulum as carrier tested in a randomized and controlled phase I trial in patients with distal radial fractures. *Bone* 140, 115551.
- Eddows, L.A., Al-Hourani, K., Ramamurthy, N., Frankish, J., Baddock, H.T., Sandor, C., Ryan, J.D., Fusco, D.N., Arezes, J., Giannoulitou, E., Boninsegna, S., Chevaliez, S., Owens, B.M.J., Sun, C.C., Fabris, P., Giordani, M.T., Martines, D., Vukicevic, S., Crowe, J., Lin, H.Y., Rehwinkel, J., McHugh, P.J., Binder, M., Babitt, J.L., Chung, R. T., Lawless, M.W., Armitage, A.E., Webber, C., Klenerman, P., Drakesmith, H., 2019. Antiviral activity of bone morphogenetic proteins and activins. *Nat. Microbiol.* 4 (2), 339–351.
- Giannoudis, P., Tzioupis, C., Almalki, T., Buckley, R., 2007. Fracture healing in osteoporotic fractures: is it really different? A basic science perspective. *Injury* 38 (Suppl. 1), S90–S99.
- Grgurevic, L., Oppermann, H., Pecin, M., Erjavec, I., Capak, H., Pauk, M., Karlovic, S., Kufner, V., Lipar, M., Bubic Spoljar, J., Bordukalo-Niksic, T., Maticic, D., Peric, M., Windhager, R., Sampath, T.K., Vukicevic, S., 2019. Recombinant human bone morphogenetic protein 6 delivered within autologous blood coagulum restores size segmental defects of ulna in rabbits. *JBMR Plus* 3 (5), e10085.
- Grgurevic, L., Erjavec, I., Gupta, M., Pecin, M., Bordukalo-Niksic, T., Stokovic, N., Vnuk, D., Farkas, V., Capak, H., Milesevic, M., Spoljar, J.B., Peric, M., Vuckovic, M., Maticic, D., Windhager, R., Oppermann, H., Sampath, T.K., Vukicevic, S., 2020. Autologous blood coagulum containing rhBMP6 induces new bone formation to promote anterior lumbar interbody fusion (ALIF) and posterolateral lumbar fusion (PLF) of spine in sheep. *Bone* 138, 115448.
- Harasen, G., 2002. Biologic repair of fractures. *Can. Vet. J.* 43 (4), 299–301.
- Ho-Shui-Ling, A., Bolander, J., Rustom, L.E., Johnson, A.W., Luyten, F.P., Picart, C., 2018. Bone regeneration strategies: engineered scaffolds, bioactive molecules and stem cells current stage and future perspectives. *Biomaterials* 180, 143–162.
- Itoh, T., Mochizuki, M., Fuda, K., Nishimura, R., Matsunaga, S., Kadosawa, T., Sasaki, N., 1998. Femoral nonunion fracture treated with recombinant human bone morphogenetic protein-2 in a dog. *J. Vet. Med. Sci.* 60 (4), 535–538.
- Kuroiwa, Y., Niikura, T., Lee, S.Y., Oe, K., Iwakura, T., Fukui, T., Matsumoto, T., Matsushita, T., Nishida, K., Kuroda, R., 2019. Escherichia coli-derived BMP-2 absorbed beta-TCP granules induce bone regeneration in rabbit critical-sized femoral segmental defects. *Int. Orthop.* 43 (5), 1247–1253.
- Lammens, J., Marechal, M., Delpont, H., Geris, L., Oppermann, H., Vukicevic, S., Luyten, F.P., 2020. A cell-based combination product for the repair of large bone defects. *Bone* 138, 115511.
- Milovancev, M., Muir, P., Manley, P.A., Seeherman, H.J., Schaefer, S., 2007. Clinical application of recombinant human bone morphogenetic protein-2 in 4 dogs. *Vet. Surg.* 36 (2), 132–140.
- Mroz, T.E., Joyce, M.J., Lieberman, I.H., Steinmetz, M.P., Benzel, E.C., Wang, J.C., 2009. The use of allograft bone in spine surgery: is it safe? *Spine J.* 9 (4), 303–308.
- Palombella, S., Lopa, S., Gianola, S., Zagra, L., Moretti, M., Lovati, A.B., 2019. Bone marrow-derived cell therapies to heal long-bone nonunions: a systematic review and meta-analysis-which is the best available treatment? *Stem Cells Int.* 2019, 3715964.
- Peric, M., Dumic-Cule, I., Grcovic, D., Matijasic, M., Verbanac, D., Paul, R., Grgurevic, L., Trkulja, V., Bagi, C.M., Vukicevic, S., 2015. The rational use of animal models in the evaluation of novel bone regenerative therapies. *Bone* 70, 73–86.
- Roberts, S.J., Geris, L., Kerckhofs, G., Desmet, E., Schrooten, J., Luyten, F.P., 2011. The combined bone forming capacity of human periosteal derived cells and calcium phosphates. *Biomaterials* 32 (19), 4393–4405.
- Sampath, T.K., Vukicevic, S., 2020. Biology of bone morphogenetic protein in bone repair and regeneration: a role for autologous blood coagulum as carrier. *Bone* 141, 115602.
- Song, K., Krause, C., Shi, S., Patterson, M., Suto, R., Grgurevic, L., Vukicevic, S., van Dinther, M., Falb, D., Ten Dijke, P., Alaoui-Ismaïl, M.H., 2010. Identification of a key residue mediating bone morphogenetic protein (BMP)-6 resistance to noggin inhibition allows for engineered BMPs with superior agonist activity. *J. Biol. Chem.* 285 (16), 12169–12180.
- Stegen, S., Carmeliet, G., 2019. Hypoxia, hypoxia-inducible transcription factors and oxygen-sensing prolyl hydroxylases in bone development and homeostasis. *Curr. Opin. Nephrol. Hypertens.* 28 (4), 328–335.
- Stokovic, N., Ivanjko, N., Erjavec, I., Milesevic, M., Oppermann, H., Shimp, L., Sampath, K.T., Vukicevic, S., 2020a. Autologous bone graft substitute containing rhBMP6 within autologous blood coagulum and synthetic ceramics of different particle size determines the quantity and structural pattern of bone formed in a rat subcutaneous assay. *Bone* 141, 115654.
- Stokovic, N., Ivanjko, N., Milesevic, M., Matic Jelic, I., Bakic, K., Rumenovic, V., Oppermann, H., Shimp, L., Sampath, T.K., Pecina, M., Vukicevic, S., 2020b. Synthetic ceramic macroporous blocks as a scaffold in ectopic bone formation induced by recombinant human bone morphogenetic protein 6 within autologous blood coagulum in rats. *Int. Orthop.* <https://doi.org/10.1007/s00264-020-04847-9>.
- Stokovic, N., Ivanjko, N., Pecin, M., Erjavec, I., Karlovic, S., Smajlovic, A., Capak, H., Milesevic, M., Bubic Spoljar, J., Vnuk, D., Maticic, D., Oppermann, H., Sampath, T. K., Vukicevic, S., 2020c. Evaluation of synthetic ceramics as compression resistant matrix to promote osteogenesis of autologous blood coagulum containing recombinant human bone morphogenetic protein 6 in rabbit posterolateral lumbar fusion model. *Bone* 140, 115544.
- Vnuk, D., Capak, H., Gusak, V., Maticic, D., Popovic, M., Brkljaca Bottegaro, N., 2016. Metal projectile injuries in cats: review of 65 cases (2012-2014). *J. Feline Med. Surg.* 18 (8), 626–631.
- Vukicevic, S., Grgurevic, L., 2009. BMP-6 and mesenchymal stem cell differentiation. *Cytokine Growth Factor Rev.* 20 (5–6), 441–448.
- Vukicevic, S., Oppermann, H., Verbanac, D., Jankolija, M., Popek, I., Curak, J., Brkljacic, J., Pauk, M., Erjavec, I., Francetic, I., Dumic-Cule, I., Jelic, M., Durdevic, D., Vlahovic, T., Novak, R., Kufner, V., Bordukalo Niksic, T., Kozlovic, M., Banic Tomisic, Z., Bubic-Spoljar, J., Bastalic, I., Vikic-Topic, S., Peric, M., Pecina, M., Grgurevic, L., 2014. The clinical use of bone morphogenetic proteins revisited: a novel biocompatible carrier device OSTEOGROW for bone healing. *Int. Orthop.* 38 (3), 635–647.
- Vukicevic, S., Stokovic, N., Pecina, M., 2019. Is ceramics an appropriate bone morphogenetic protein delivery system for clinical use? *Int. Orthop.* 43 (5), 1275–1276.
- Vukicevic, S., Grgurevic, L., Erjavec, I., Pecin, M., Bordukalo-Niksic, T., Stokovic, N., Lipar, M., Capak, H., Maticic, D., Windhager, R., Sampath, T.K., Gupta, M., 2020a. Autologous blood coagulum is a physiological carrier for BMP6 to induce new bone formation and promote posterolateral lumbar spine fusion in rabbits. *J. Tissue Eng. Regen. Med.* 14 (1), 147–159.
- Vukicevic, S., Peric, M., Oppermann, H., Stokovic, N., Ivanjko, N., Erjavec, I., Kufner, V., Vnuk, D., Bubic Spoljar, J., Pecin, M., Novak, R., Matic Jelic, I., Bakic, K., Milesevic, M., Rumenovic, V., Popek, I., Pehar, S., Martinovic, S., Blazevic, V., Rogina, L., Vikic-Topic, S., Bozic, T., Verbanac, D., Bordukalo Niksic, T., Sampath, K., Pecina, M., Maticic, D., Grgurevic, L., 2020b. Bone morphogenetic proteins: from discovery to development of a novel autologous bone graft substitute consisting of recombinant human BMP6 delivered in autologous blood coagulum carrier. *Rad CASA - Medical Sciences* 544 (52–53), 26–41.
- Wang, W., Yeung, K.W.K., 2017. Bone grafts and biomaterials substitutes for bone defect repair: a review. *Bioact Mater* 2 (4), 224–247.