

# Heterophile antibodies, false-positive troponin, and acute coronary syndrome: a case report indicating a pitfall in clinical practice

---

Lakušić, Nenad; Sopek Merkaš, Ivana; Lučinger, Daren; Mahović, Darija

Source / Izvornik: **European Heart Journal - Case Reports, 2021, 5**

Journal article, Published version

Rad u časopisu, Objavljena verzija rada (izdavačev PDF)

<https://doi.org/10.1093/ehjcr/ytb018>

Permanent link / Trajna poveznica: <https://um.nsk.hr/um:nbn:hr:105:044878>

Rights / Prava: [Attribution-NonCommercial 4.0 International](#)/[Imenovanje-Nekomercijalno 4.0 međunarodna](#)

Download date / Datum preuzimanja: **2024-07-17**



Repository / Repozitorij:

[Dr Med - University of Zagreb School of Medicine  
Digital Repository](#)



# Heterophile antibodies, false-positive troponin, and acute coronary syndrome: a case report indicating a pitfall in clinical practice

Nenad Lakusic <sup>1,2,3</sup>, Ivana Sopek Merkas <sup>1\*</sup>, Daren Lucinger <sup>1</sup>, and Darija Mahovic <sup>4</sup>

<sup>1</sup>Department of Cardiology, Special Hospital for Medical Rehabilitation Krapinske Toplice, Croatia; <sup>2</sup>Department of Clinical Medicine, Faculty of Dental Medicine and Health Osijek, J. J. Strossmayer University of Osijek, Croatia; <sup>3</sup>Department of Internal Medicine, Family Medicine and History of Medicine, Faculty of Medicine Osijek, J. J. Strossmayer University of Osijek, Croatia; and <sup>4</sup>Department of Neurology, University Hospital Centre Zagreb, School of Medicine University of Zagreb, Croatia

Received 9 July 2020; first decision 7 October 2020; accepted 12 January 2021

## Background

Heterophile antibodies are one of the most common causes of false-positive troponin.

## Case summary

We report a case of a 53-year-old woman with false-positive troponin elevation and a clinical presentation understood and treated as non-ST-elevation acute coronary syndrome. Because of chronic basal elevation of troponin (at a 'plateau' level) and chest pain, the patient underwent several invasive coronary angiograms until false-positive increase of troponin due to heterophile antibodies was suspected. Borderline stenosis of a left circumflex coronary artery found on first coronary angiogram was a coincidental finding and heterophile antibodies in the patient's serum were confirmed.

## Discussion

This interesting case report aims to remind the clinicians about the possibility of false-positive troponin level due to laboratory analytical interference caused by heterophile antibodies. In this case, it is important to suspect false-positive troponin elevation, even when coronary artery disease is found. This rare and less mentioned and/or recognized cause of troponin elevation may lead to unnecessary invasive diagnostics and aggressive treatment of patients.

## Keywords

Heterophile antibodies • Troponin • False positive • Acute coronary syndrome • Case report

## Learning points

- Heterophile antibodies are an under-recognized cause of false-positive troponin elevation and may lead to unnecessary diagnostic testing and treatment.
- In patients presenting with persistently elevated troponins and low clinical suspicion of acute coronary syndrome, it is important for clinicians to suspect false-positive troponin elevation.

\* Corresponding author. Tel: + 385 49 383100, Email: [ivana.sopek92@gmail.com](mailto:ivana.sopek92@gmail.com)

Handling Editor: Nikolaos Bonaros

Peer-reviewers: Zain Ul Abideen Asad; Mariama Akodad

Compliance Editor: Daniel Tardo

Supplementary Material Editor: Aiste Monika Jakstaite

© The Author(s) 2021. Published by Oxford University Press on behalf of the European Society of Cardiology.

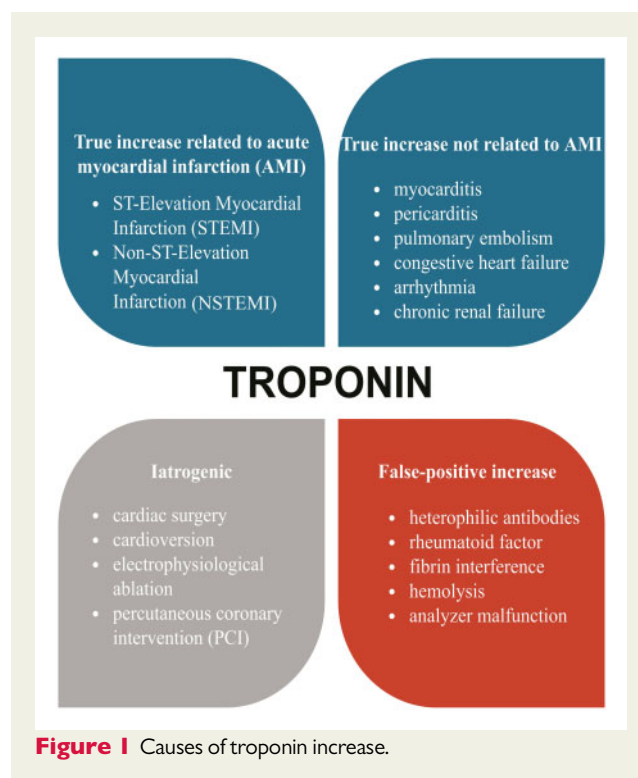
This is an Open Access article distributed under the terms of the Creative Commons Attribution Non-Commercial License (<http://creativecommons.org/licenses/by-nc/4.0/>), which permits non-commercial re-use, distribution, and reproduction in any medium, provided the original work is properly cited. For commercial re-use, please contact [journals.permissions@oup.com](mailto:journals.permissions@oup.com)

## Introduction

In patients presenting with clinical and electrocardiographic (ECG) signs of myocardial ischaemia, cardiac troponin concentration is the cornerstone in establishing a diagnosis of acute coronary syndrome (ACS).<sup>1</sup> An increased concentration of troponin is not only specific to acute coronary artery thrombotic occlusion but can also be seen in many other diseases. Mechanisms of such an increase of troponin can be categorized into three major groups: myocardial damage related to an imbalance between myocardial oxygen supply and demand (e.g. coronary vasospasm, arrhythmia, etc.), myocardial damage related to non-ischaemic causes (e.g. pericarditis, myocarditis) which includes direct trauma (e.g. cardiac surgery, cardioversion, etc.) and multifactorial myocardial injury (e.g. sepsis, stroke, chronic renal failure).<sup>2,3</sup> These potential categories may be overlapping or impossible to discriminate completely from each other. In addition to well-known causes of troponin elevation,<sup>2</sup> there are other rare and less recognized phenomena such as false-positive increase of troponin due to cross-reacting heterophile antibodies<sup>3</sup> (Figure 1).

## Timeline

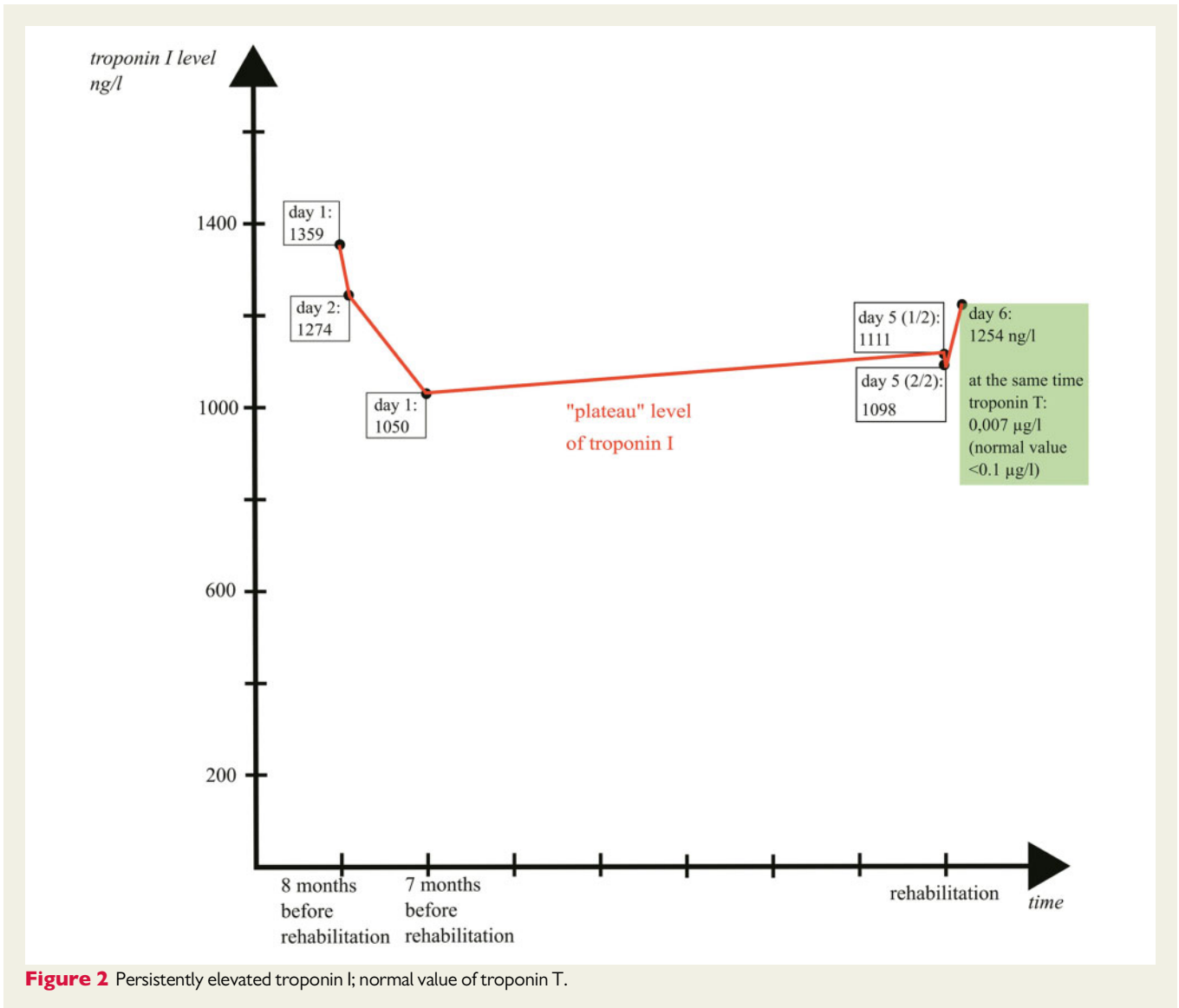
<b>8 months prior to rehabilitation</b>	Chest pain without any significant ST-T changes in electrocardiogram (ECG), elevated troponin I level. Misdiagnosis of non-ST-elevation myocardial infarction-acute coronary syndrome and percutaneous coronary intervention of LCx was done in the County hospital.
<b>7 months prior to rehabilitation</b>	Recurrence of chest pain with elevated troponin I, there was no in-stent thrombosis/re-stenosis on repeated coronary angiography in the County hospital.
<b>5th day of rehabilitation</b>	Chest pain accompanied by moderately elevated blood pressure, persistently elevated troponin like in previous hospitalization was measured ('plateau' level), ECG showed stable sinus rhythm without any significant ST-T changes. Applied therapy quickly normalized the blood pressure and complete regression of symptoms occurred.
<b>6th day of rehabilitation</b>	Troponin was again measured at a 'plateau' level and the existence of heterophile antibodies in the patient's serum that cause a chronic basal elevation of troponin was suspected.
<b>7th day of rehabilitation</b>	New blood sample was taken and the concentration of troponin I and simultaneously the concentration of troponin T at a collaborative laboratory in an external institution was tested. The concentration of troponin I was still at a 'plateau' level, while hs-troponin T from the same sample was within normal range.



## Case presentation

A 53-year-old female patient with hypertension, mild dyslipidaemia, chronic stress, nicotine use, and menopause was referred to the County hospital with suspected ACS. Physical examination revealed normal respiratory auscultation sounds, regular heart rate and rhythm, no murmurs or rubs, abdomen soft to palpation, and palpable peripheral pulses. There were no significant ST-T changes in repeated ECGs and no signs that would suggest coronary artery spasm and ischaemia. The patient had chest pain for 3 h before coming to the emergency room, which she characterized as chest discomfort, tightness and heaviness in rest, without radiation, with no progression in physical activity, that regressed gradually (did not respond to nitroglycerine spray), but the patient was hospitalized due to elevated troponin I of 1359 ng/L with a diagnosis of non-ST-elevation myocardial infarction (NSTEMI-ACS). There was no change in troponin concentration on the second day of treatment. Echocardiography showed normal left ventricular ejection fraction and no regional wall motion abnormalities.

Coronary angiography was then performed and verified left anterior descending (LAD) and right coronary artery (RCA) without stenosis, no signs of coronary artery spasm, but borderline 70% stenosis of the left circumflex artery (LCx) in the proximal segment. Percutaneous coronary intervention (PCI) of LCx with drug-eluting stent implantation was done. Patient was discharged on Day 7 with an uncomplicated hospital course. Three weeks later, she was hospitalized because of recurrent chest pain which had the same characteristics as the first time. There were no ischaemic changes on the ECG, but due to significant elevation of troponin I, urgent coronary angiography was performed. There was no in-stent thrombosis/



**Figure 2** Persistently elevated troponin I; normal value of troponin T.

restenosis in LCx and no stenosis of LAD and RCA. Troponins remained elevated throughout the hospitalization.

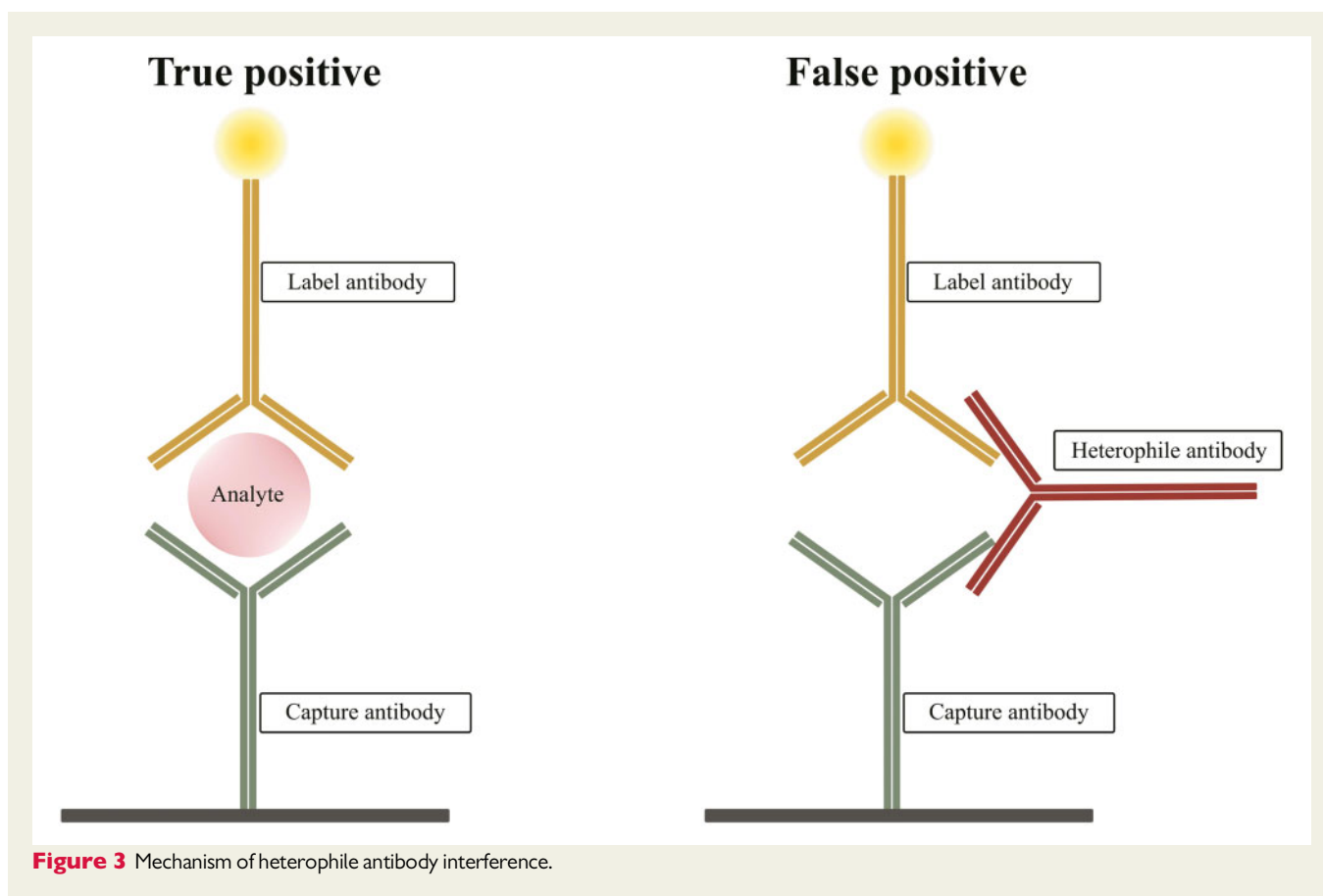
The patient was then referred for cardiac rehabilitation. On the fifth day of rehabilitation, after a disturbing telephone conversation with her family, the patient had chest pain similar to the previous hospitalizations (chest discomfort in rest, without progression in physical activity) accompanied by elevated blood pressure. Electrocardiogram showed sinus rhythm without significant ST-T changes. Applied therapy (diazepam 5 mg and amlodipine 10 mg) quickly normalized the blood pressure and symptoms resolved, but troponin I was significantly elevated (1111 ng/L). When measured again, three hours later and the next morning, troponin I was at a similar, 'plateau' elevated level. In view of this finding, the patient's stable clinical state, our previous experience<sup>4</sup> and the recent literature data,<sup>5</sup> we suspected the existence of heterophile antibodies in the patient's serum causing a chronic elevation of troponin.

The next day a new blood sample was taken, in which our laboratory tested the concentration of high-sensitivity (hs) troponin I and

simultaneously the collaborative laboratory at an external institution tested the concentration of troponin T. The concentration of hs-troponin I was 1254 ng/L while hs-troponin T from the same sample was within the normal range 0.007 µg/L (normal value <0.1 µg/L), [Figure 2](#). With such laboratory findings and the additional anamnestic data that patient breeds rabbits, there was no doubt that the sustained 'plateau' elevated level of hs-troponin I was caused by heterophile antibodies. The further course of rehabilitation went without complications, and the patient's discharge medical records emphasized the presence of chronically elevated troponin caused by heterophile antibodies which is extremely important for further monitoring and evaluation.

## Discussion

Heterophile antibodies are an under-recognized cause of false-positive troponin. These are weak antibodies produced against poorly defined antigens. Heterophile antibodies may be acquired



**Figure 3** Mechanism of heterophile antibody interference.

**Table 1** Methods that can be applied when heterophile antibody interference is suspected

<p>Blood sample can be analysed on a different manufacturers assay system.</p> <p>Using heterophile blocking reagents.</p> <p>Adding endogenous immunoglobulin free serum samples to the blood sample can remove endogenous immunoglobulin (i.e. normal animal sera blocking reagent).</p> <p>Measurement of dilutions of the sample using the manufacturers diluent containing non-immune globulin.</p> <p>Prior extraction of the analyte from the sample (e.g. chromatography).</p>
--

from iatrogenic and non-iatrogenic causes; these include the use of mouse monoclonal antibodies in therapeutic or diagnostic purposes, blood transfusion products, vaccinations, exposure to various animal antigens, and in autoimmune diseases (rheumatoid factor). The precise prevalence of heterophile antibodies is unknown, varying from <1 to almost 80%.<sup>6</sup> Immunoassays for troponin I often use two-site ('sandwich') reactions which contain two antibodies ('capture' and 'label') specific for the measured analyte.<sup>7</sup> The 'capture' antibody binds to any cardiac troponin I in the sample, and the 'label' antibody is then added and binds to any 'captured' cardiac troponin I, providing a detectable signal used to determine the cardiac troponin I concentration. Heterophile antibodies simultaneously create complexes with 'capture' and 'label' antibodies of the analyte—they 'bridge' them and give a false-positive result, [Figure 3](#). When the false-positive

value of troponin is suspected, the laboratory can launch a variety of approaches to address the issue; use of blocking antibodies which are routinely added by the manufacturers to most of the commercial assays, determination of both troponin T and I values from the same blood sample, ideally using assays from different manufacturers<sup>8</sup> ([Table 1](#)). When the approach of analysing blood samples on a different manufacturer's assay system is used (as in our case), both troponin I and T values can be determined. The use of different assays is essential. Prevalence of false-positive troponin I values vary between 0.17–3.1% due to multiple factors, including the presence of heterophile antibodies.<sup>7</sup>

Fortunately, the scenario involving the presence of heterophile antibodies and symptoms of angina pectoris rarely occurs. Our patient was misdiagnosed NSTEMI-ACS (no ischaemic ECG changes and

contractility abnormalities, no thrombus in coronary angiography, the normal value of troponin T<sup>2</sup> and the 70% stenosis of LCx was only an additional finding within her cardiovascular risk profile. After taking a detailed medical history, in our opinion, the chest pain that preceded both hospitalizations was caused by weeks of family problems with a consequent increase in blood pressure. Taking into consideration the patient's pronounced cardiovascular risk profile, chest pain and significantly elevated troponin I, for such patient the presumption of having NSTEMI-ACS followed by her admission to the hospital and undergoing invasive coronary angiography is not unusual.

If our patient did not have a significantly increased troponin, given the regression of symptoms and no dynamics in the series of ECGs, she would probably be discharged and recommended for further examination. If the exercise stress test would be inconclusive, multislice computed tomography (MSCT) coronary angiography and then single-photon emission computed tomography (SPECT) or cardiac magnetic resonance (CMR) for detection of ischaemia in regions perfused by LCx would be performed.<sup>9</sup> In the case of proven ischaemia, an elective PCI of LCx would be done. If there would be no evidence of reversible ischaemia and the lesion was assessed as insignificant, optimal medical therapy would be continued. Also, if the patient would be referred for classical coronary angiography after the exercise test, functional tests like instantaneous wave-free ratio (iFR) or fractional flow reserve (FFR) would be performed to estimate the significance of LCx lesion.<sup>9</sup> Only when the significance of the lesion is proven, the PCI would be done.

What happens with the troponin level during real ACS in presence of heterophile antibodies? Although there are no clear guidelines found in the available literature regarding those scenarios, in case of ACS, an additional increase in troponin over the basal 'plateau' level with obvious dynamics (increase and decrease) is expected. There is always an option of using a commercial assay in which basal troponin levels were previously proven normal in absence of ACS (in our case hs-troponin T) to determine troponin dynamics.

The purpose of this article is to remind the clinicians about the possibility of false-positive troponin due to laboratory analytical interference caused by heterophile antibodies. It is important to emphasize that there is no characteristic dynamics of troponin, as is in the ACS. Since heterophile antibodies are generally poorly mentioned or even not mentioned at all in cardiology guidelines, we wanted to remind the clinicians of the possibility of this scenario for purpose of avoiding unnecessary invasive procedures and overtreatment of these 'patients'.

## Lead author biography



Nenad Lakušić is a consultant cardiologist working in the biggest rehabilitation center in Croatia. He has a wide experience in the different fields; preventive and rehabilitation

cardiology, heart failure, acute and chronic coronary syndrome, cardiomyopathies, hypertension, clinical arrhythmology, etc. He has several publications in different respectable cardiology journals. He is a member of the Croatian Society of Cardiology and European Association of Preventive Cardiology (EAPC) – ESC.

## Supplementary material

Supplementary material is available at *European Heart Journal - Case Reports* online.

## Acknowledgements

Special thanks to Anita Klasić Med. Biochem., for providing troponin T measurement comparison at external laboratory.

**Slide sets:** A fully edited slide set detailing these cases and suitable for local presentation is available online as [Supplementary data](#).

**Consent:** The authors confirm that written consent for submission and publication of this case report including images and associated text has been obtained from the patient in line with COPE guidance.

**Conflict of interest:** None declared.

**Funding:** None declared.

## References

1. Wu AH, Apple FS, Gibler W, Jesse RL, Warshaw MM, Valdes R, Jr National Academy of Clinical Biochemistry Standards of Laboratory Practice: recommendations for the use of cardiac markers in coronary artery diseases. *Clin Chem* 1999; **45**:1104–1121.
2. Thygesen K, Alpert JS, Jaffe AS, Chaitman BR, Bax JJ, Morrow DA, et al.; ESC Scientific Document Group; the Executive Group on behalf of the Joint European Society of Cardiology (ESC)/American College of Cardiology (ACC)/American Heart Association (AHA)/World Heart Federation (WHF) Task Force for the Universal Definition of Myocardial Infarction. Fourth universal definition of myocardial infarction (2018). *Eur Heart J* 2019;**40**:237–269.
3. Mair J, Lindahl B, Müller C, Giannitsis E, Huber K, Möckel M et al. What to do when you question cardiac troponin values. *Eur Heart J Acute Cardiovasc Care* 2018;**7**:577–586.
4. Lakusic N, Klasic A, Dubroja RC, Halapir M, Cerovec D, Bernat R et al. Clinical relevance of false-positive troponin level. *Lijec Vjesn* 2011;**133**:292–293.
5. Santos LG, Carvalho RR, Montegro Sa F, Soares F, Pernencar S, Castro R et al. Circulating heterophile antibodies causing cardiac troponin elevation: an unusual differential diagnosis of myocardial disease. *J Am Coll Cardiol Case Rep* 2020;**2**:456–460.
6. Kricka L. Human anti-animal antibody interferences in immunological assays. *Clin Chem* 1999;**45**:942–956.
7. Lum G, Solarz DE, Farney L. False positive cardiac troponin results in patients without acute myocardial infarction. *Lab Med* 2006;**37**:546–550.
8. Kim WJ, Laterza OF, Hock KG, Pierson-Perry JF, Kaminski DM, Mesguich M et al. Performance of a revised cardiac troponin method that minimizes interferences from heterophile antibodies. *Clin Chem* 2002;**48**:1028–1034.
9. Nkutu J, Wijns W, Saraste A, Capodanno D, Barbato E, Funck-Brentano C, et al. ESC Scientific Document Group. 2019 ESC Guidelines for the diagnosis and management of chronic coronary syndromes. *Eur Heart J* 2020;**41**:407–477.