

Clinical spectrum of Alzheimer's disease

Mouselli, Caroline Lucie

Master's thesis / Diplomski rad

2014

Degree Grantor / Ustanova koja je dodijelila akademski / stručni stupanj: **University of Zagreb, School of Medicine / Sveučilište u Zagrebu, Medicinski fakultet**

Permanent link / Trajna poveznica: <https://um.nsk.hr/um:nbn:hr:105:028869>

Rights / Prava: [In copyright](#)/[Zaštićeno autorskim pravom.](#)

Download date / Datum preuzimanja: **2025-03-30**



Repository / Repozitorij:

[Dr Med - University of Zagreb School of Medicine Digital Repository](#)



**UNIVERSITY OF ZAGREB
SCHOOL OF MEDICINE**

**Caroline Lucie Mouselli
CLINICAL SPECTRUM OF ALZHEIMER'S DISEASE**

GRADUATION THESIS



Zagreb, 2014

This graduate thesis was made at the Department of Cognitive Neurology, University Hospital Center Zagreb, mentored by dr.sc. Marina Boban and was submitted for evaluation during academic year 2013/2014.

Abbreviations

AD: Alzheimer disease

VCI: Vascular Cognitive Impairment

LBD: Dementia with Lewy Bodies

FTLD: Fronto-temporal Lobar Degeneration

ADI: Alzheimer's Disease international

NINCDS: National Institute of Neurological and Communicative Disorders and Stroke

ADRDA: Alzheimer's Disease and Related Disorders Association

MCI: Mild Cognitive Impairment

NIA: National Institute on Aging

MMSE: Mini Mental Status Examination

NICE: The National Institute for Health and Clinical Excellence

TSH: Thyroid-Stimulating Hormone

CRP: C Reactive Protein

HIV: Human Immunodeficiency Virus

TPHA: Treponema Pallidum Hemagglutininations Assay

VDRL: Venereal Disease Research Laboratory

CSF: Cerebro-Spinal Fluid

CJD: Creutzfeldt-Jakob Disease

EEG: Electroencephalography

MRI: Magnetic Resonance Imaging

CT: Computerised Tomography

EOAD: Early-onset AD

LOAD: Late-onset AD

APP: Amyloid Precursor Protein

PSN1: Presenilin 1

PSN2: Presenilin 2

APOE: Apoprotein E

A β : Amyloid-beta Protein

FDG-PET: Positron Emission Tomography with [18F] Fluorodeoxyglucose

fMRI: functional MRI

SPECT: Single Photon Emission Computed Tomography

PiB : Pittsburgh compound B

VBM : Voxel-based volumetry

DBM : Deformation-based morphometry

PCA: Posterior cortical atrophy

PPA: Primary progressive aphasia

bvFTLD : Behavioural variant fronto-temporal lobar degeneration

PNFA: Progressive nonfluent aphasia

SD: Semantic dementia

LPA: Logopenic aphasia

CBD: Corticobasal degeneration

pTau : Phosphorylated Tau protein

CONTENTS

SUMMARY.....	6
INTRODUCTION.....	7
I. TYPICAL PRESENTATION OF AD.....	10
I. 1. Clinical features and diagnosis of dementia.....	10
I.1.1 History and clinical findings.....	10
I.1.2. Causes and differential diagnoses of dementia.....	11
I.1.3. Objective clinical assessment of dementia.....	12
I.1.4. Criteria for dementia.....	15
I.1.5. Investigations.....	16
I. 2. Clinical features and diagnosis of AD.....	17
I.2.1. Overview of the pathophysiology of AD.....	17
I.2.2. Clinical features of AD.....	19
I.2.3. Neurocognitive assessment in AD.....	20
I.2.4. Criteria for the diagnosis of AD.....	21
I.2.5. Clinical course of AD.....	22
I.2.6. Neuroimaging.....	23
I.2.7. Biomarkers of AD.....	25
I. 2.8. Classification of AD.....	28
II. ATYPICAL PRESENTATION OF AD.....	30
II. 1. Evidence of AD heterogeneity in the literature.....	30
II.1.1 Imaging evidence of Heterogeneity.....	31
II.1.2. CSF biomarkers as an evidence of heterogeneity.....	31
II.1.3. Neuropathological heterogeneity.....	32
II. 2. Factors contributing to AD heterogeneity.....	32
II.2.1. Age of Onset	33
II.2.2. Disease topography	33
II.2.3. Genetics	34

II. 3. AD subtypes.....	35
II.3.1. Posterior cortical atrophy (PCA).....	35
II.3.2. Primary Progressive aphasia (PPA).....	36
II.3.3. Behavioural variant (bvAD).....	37
III. PRECLINICAL STAGE OF AD AND MILD COGNITIVE IMPAIRMENT (MCI).....	39
III. 1. Preclinical stage of AD.....	39
III.1.1. The continuum of AD.....	39
III.1.2. AD pathophysiological cascade.....	41
III.1.3. Model of dynamic biomarkers of the Alzheimer’s pathological cascade.....	42
III. 2. Mild Cognitive Impairment (MCI).....	43
III.2.1. Definition and progression of MCI.....	43
III.2.2. Criteria for the clinical and cognitive syndrome.....	44
III.2.3. Objective clinical assessment of cognitive impairment: neuropsychological tests.....	46
III.2.4. MCI classification: Incorporating biomarkers in clinical practice	46
DISCUSSION.....	48
CONCLUSION.....	49
ACKNOWLEDGEMENT.....	50
REFERENCES.....	51
CURRICULUM VITAE.....	58

SUMMARY

Clinical spectrum of Alzheimer's disease

Caroline Lucie Mouselli

The incidence of Alzheimer's disease (AD) increases exponentially with age. Therefore, it becomes a major public health problem since the population is getting older, and the cost of caring increases. Cognitive deficits in AD appear and progress insidiously, but the rate of progression can vary. The average life expectancy has been reported to be between three and eight years. Clinical assessment and neuropsychological testing are necessary initial tools for the diagnosis of AD. Memory impairment, specifically loss of episodic memory (memory of recent events), is an essential feature of AD and is usually its first manifestation. Deficits in other cognitive domains may appear with or after the development of memory impairment. Language function and visuospatial skills tend to be affected relatively early, while deficits in executive function and behavioural symptoms often manifest later in the disease course. Neuropsychiatric and behavioural symptoms are common in middle and late stages of AD. Noncognitive neurologic deficits (pyramidal and extrapyramidal motor signs, myoclonus, and seizures) can occur in late stages of AD, but are uncommon in early and middle stages. Atypical presentations of AD may occur. These include a visual variant (posterior cortical atrophy), primary progressive aphasia (PPA) and behavioural variant AD (bvAD). AD progresses through three stages: an early, preclinical stage with no symptoms; a middle stage or mild cognitive impairment (MCI); and a final stage marked by symptoms of dementia (apparent AD). Diagnostic tests (basic laboratory tests and neuroimaging) are performed initially to exclude other (treatable) causes. Recently discovered biomarkers may help in early and differential diagnosis as well as prognosis of AD.

Keywords: Alzheimer's disease, atypical, Mild cognitive impairment, diagnosis, biomarkers.

INTRODUCTION

Dementia is a clinical syndrome characterised by a cluster of symptoms and signs manifested by difficulties in memory, disturbances in language, psychological and psychiatric changes, and impairments in activities of daily living.

Alzheimer disease (AD) is the most common cause of dementia. According to the Alzheimer's Association^[1], approximately 60 to 80% of cases of dementia among the elderly population are caused by AD which is to be differentiated from other forms of dementia, such as vascular cognitive impairment (VCI), dementia with Lewy bodies (DLB), frontotemporal lobar degeneration (FTLD) and dementia caused by Parkinson's disease among others.

AD is a specific disease that affects about 6% of the population aged over 65 and increases in incidence with age. It is progressive neurodegenerative disorder beginning with episodic memory impairment, but inevitably affecting all cognitive functions and leading to premature death.

With aging being the main risk factor of the disease, the probability of being affected doubles every 5 years after the age of 65. It becomes a major public health problem as the population ages, and the cost of caring increases. The World Alzheimer Report 2013^[2] estimated that over 35 million people worldwide currently live with this condition and this number is expected to double by 2030 and more than triple by 2050 to 115 million.

So, dementia is one of the biggest global public health challenges facing our generation. In the 2010 World Alzheimer Report^[3], Alzheimer's Disease International (ADI) estimated that the annual societal costs of dementia worldwide were US\$604 billion, or 1% of the aggregated worldwide Gross Domestic Product (GDP) and it predicted a near doubling in worldwide societal costs from US\$604 billion in 2010 to US\$1,117 billion by 2030. Moreover, from a patient perspective, this disease is leading to complete dependence for basic functions of daily life, and decrease tremendously their quality of life.

Additionally, patients with AD present diagnostic and management challenge. The benefits of early investigation and diagnosis of AD include early access to pharmacological symptomatic treatments, initiation of psychosocial support, and treatment of comorbid conditions.

This is why in 1984, a work group on the diagnosis of AD was established by the National Institute of Neurological and Communicative Disorders and Stroke (NINCDS) and the Alzheimer's Disease and Related Disorders Association (ADRDA)^[4]. The aim of the work group was to define clinical diagnostic criteria for AD to serve as a clinical basis for diagnosis of AD. They conceptualized AD as a dual clinical-pathological entity, which requires 1/ a clinical phenotype typically centred on the presence of a progressive dementia that includes episodic memory impairment as a defining feature and involvement of other cognitive domains or skills, and 2/ specific neuropathological changes that usually include intraneuronal (neurofibrillary tangles) and extracellular parenchymal lesions (senile plaques), which are often accompanied by synaptic loss and vascular amyloid deposits and can only be verified by post-mortem histological examination of brain tissue^[4]. They classified AD as definite (clinical diagnosis with histologic confirmation), probable (typical clinical syndrome without histologic confirmation), or possible (atypical clinical features, but no alternative diagnosis apparent and no histologic confirmation). These criteria have been reliable for the diagnosis of probable AD, and across more than a dozen clinical pathological studies have had a sensitivity of 81% and specificity of 70%^[5].

However, in the intervening 30 years tremendous progression has been made in the understanding of the AD pathological process. So in April, 2011, the diagnostic criteria for AD were revised to reflect a deeper understanding of the disease^[6]. The new guidelines differ from the 1984 diagnostic criteria in a few key ways. Three main points are highlighted:

- They reflect a better understanding of dementia and the distinctions and associations between typical Alzheimer and non-Alzheimer's dementias, as well as recognize the potential use of biomarkers as indicators of underlying brain disease to diagnose AD.
- They expand the criteria for Alzheimer's dementia beyond memory loss as the first or only major symptom: they recognize that there are several nonamnesic presentations of the pathophysiological process of AD, the most common ones being the syndrome of posterior cortical atrophy^[7] and the primary progressive aphasia^[8].

- They recognize that AD progresses on a spectrum with three stages: an early, preclinical stage with no symptoms; a middle stage of mild cognitive impairment (MCI); and a final stage marked by symptoms of dementia (apparent AD).

Each of these 3 points will be developed in the next 3 chapters of this review paper.

I. TYPICAL PRESENTATION OF AD

Important concepts about dementia will be developed in this chapter: the clinical evaluation of cognitive impairment with history taking and neuropsychological testing, the causes and differential diagnoses of dementia, and finally investigations to rule out reversible causes of dementia. Then specificities on AD will be explained: its clinical findings, clinical criteria and progression.

I. 1. Clinical features and diagnosis of dementia

I.1.1 History and clinical findings

The National Institute on Aging and the Alzheimer's Association clinical guidelines revised in April 2011 criteria for dementia^[6]. The diagnosis is made when there are cognitive or behavioural (neuropsychiatric) symptoms that disrupt daily function (work, usual activities) and represent a decline from previous levels of functioning and performing. The key to the reliable identification of cognitive impairment is to integrate three components:

- history taking from the patient and a collateral account from a carer,
- physical examination and observation of the patient,
- and assessment of cognition with standardised tests either a "bedside" mental status examination or neuropsychological testing.

The cognitive or behavioural impairment involves a minimum of two domains including memory, language, executive function, or visuospatial skills.

In the amnesic presentation there is impaired ability to acquire and remember new information. The patient with this presentation asks repetitive questions during conversation, misplaces personal belongings, forgets events or appointments, and gets lost on a familiar route.

Other cognitive area that can be involved is the executive function with presentation of impaired reasoning and handling of complex tasks, poor judgment if dysfunction is present: the patient presents with poor understanding of safety risks, inability to manage finances, poor decision-making ability, inability to plan complex or sequential activities.

Also, impaired visuospatial abilities may be found: the patient has poor ability to recognize faces or common objects or to find objects in direct view despite good acuity, to operate simple implements, or orient clothing to the body.

Additionally, language impairment can also be found: symptoms include difficulty of finding common words while speaking, hesitations; speech, spelling, and writing errors.

Finally, behaviour can change such as uncharacteristic mood fluctuations, agitation, impaired motivation and initiative, apathy, loss of drive, social withdrawal, decreased interest in previous activities, loss of empathy, compulsive or obsessive behaviours, socially unacceptable behaviours.

I.1.2. Causes and differential diagnoses of dementia

It is necessary to rule out other causes of dementia or other systemic or brain diseases that could account for the decline in cognition. The four main causes of dementia are AD, vascular cognitive impairment (VCI), frontotemporal lobar degeneration (FTLD) and dementia with Lewy bodies (DLB).

Core clinical features of DLB are fluctuating cognitive impairment (seen in 50-75% of patients), visual hallucinations, and parkinsonism (seen in 25-50% of patients at diagnosis)^[9]. Its supportive features are repeated falls, syncope, transient loss of consciousness, neuroleptic sensitivity, systematized delusion, hallucination of other modalities, rapid eye movement (REM) sleep behaviour disorder, and depression.

The clinical features of FTLD are described with the emphasis on prominent personality and behavioural changes with less prominent memory loss early in the course comparing to AD^[10]. Frequently, FTLD is misdiagnosed as personality disorders or late-onset psychiatric disorders. Common conduct disturbances are loss of personal awareness, inappropriate social behaviour, disinhibition, impulsivity, distractibility, hyperorality (excessive eating), social withdrawal, stereotyped or preservative behaviour, and speech output change (reduction of speech, stereotyped speech, and echolalia). The physical examination usually reveals early prominent primitive or frontal reflexes.

VCI is caused primarily by ischemic strokes. The most common form is due to small vessel cerebrovascular disease. Diagnosis is most specific if there is a stroke-like course of illness, neurologic signs of stroke on examination, and imaging

evidence of stroke. However, the course of illness may appear smoothly progressive, and there may be no elementary neurologic signs. The presentation of cognitive impairment in VCI may be quite distinct from AD, especially early in the disease course, with prominent deficits in executive dysfunction causing significant disability, even while memory impairment is quite mild and before the patient reaches criteria for dementia. There is considerable overlap between AD and VCI with regard to comorbidity as well as shared risk factors and even pathogenesis. The combination of pathologies may be more common than either in isolation (mixed dementia).

Also, it's important to rule out prion disease, neoplasm, or metabolic disorders that present with very rapid cognitive decline that occurs over weeks or months.

Two main differential diagnoses of dementia, delirium and depression, should be also ruled out.

Features of delirium include poor attention (distractibility or inability to focus), incoherent speech (hard to fully understand what the patient is trying to say), and altered level of alertness (sleepiness or agitation). The key is substantial change or fluctuation in mental status over hours or days: this is the cardinal feature of delirium. Drugs are a common cause of delirium in older people, and a medication review is therefore essential.

Features of depression include low mood, loss of interest and diminished capacity for enjoyment, poor self-care, and a negative outlook with feelings of hopelessness that can include suicidal thoughts. However, it is important to be aware that somatic symptoms such as reduced energy, poor appetite and insomnia are more prominent than depressed mood.

I.1.3. Objective clinical assessment of dementia

It is valuable to get a first impression of general cognitive functioning. Simple questions and tasks such as those of the mini mental state examination (MMSE) provide insight into the level and severity of cognitive functioning of a patient^[11]. It is the most widely used cognitive test for dementia in clinical practice. The examination takes approximately 7 minutes to complete. It tests a broad range of cognitive functions including orientation, recall, attention, calculation, language, and constructional praxis (figure I.1). The MMSE has a maximum score of 30. A MMSE

score between 20 and 26 is associated with mild functional dependence, such as difficulty managing finances. Moderate AD (MMSE score between 10 and 20) is associated with more immediate dependency, such as inability to drive, difficulty with hygiene and shopping, and remote memory impairment. Severe disease (MMSE score under 10) correlates with a state of total dependence and need for constant supervision. While proven reliable, its validity is less secure unless adjusted scoring methods are used to address the potential for educational and age bias^[12]. So with a high level of education and younger age, a higher score may already be suggestive of cognitive dysfunction. Another inconvenient is that the MMSE is relatively insensitive to early or mild forms of dementia.

The clock drawing test (figure 1.2) is a screen for visuospatial, constructional praxis and frontal/executive impairment. The patient is asked to draw a clock. Inability to correctly space the numbers around the circle can be due to a visuospatial impairment, neglect, or a planning deficit. He is then asked to set the time at 10 after 11 which tests the patients capacity to compute that the minute hand should be pointing to the number 2, rather than 10 (a frontal/executive function). The advantage is the relative independence from bias due to intellect, language or cultural factors.

Neuropsychological testing should be performed when the routine history and bedside mental status examination cannot provide a confident diagnosis.

The mini mental state examination

Orientation

Year, month, day, date. season _____/5
Country, county, town, hospital, ward (clinic) _____/5

Registration

Examiner names three objects (for example, apple, pen, and table)
Patient asked to repeat objects, one point for each. _____/3

Attention

Subtract 7 from 100 then repeat from result, stop after
five subtractions. (Answers: 93, 86, 79, 72, 65)
Alternatively if patient errs on subtraction get them to
spell world backwards: D L R O W
Score best performance on either task. _____/5

Recall

Ask for the names of the objects learned earlier. _____/3

Language

Name a pencil and a watch. _____/2
Repeat: 'No ifs, and or buts.' _____/1
Give a three stage command. Score one for each
stage (for example, 'Take this piece of paper in your right
hand, fold it in half and place it on the table.' _____/3
Ask patient to read and obey a written command
on a piece of paper stating: 'Close your eyes.' _____/1
Ask patient to write a sentence. Score correct if
it has a subject and a verb. _____/1

Copying

Ask patient to copy intersecting pentagons.
Score as correct if they overlap and each has five sides. _____/1

Total score: _____/30

Figure 1.1: The mini mental state examination (MMSE).

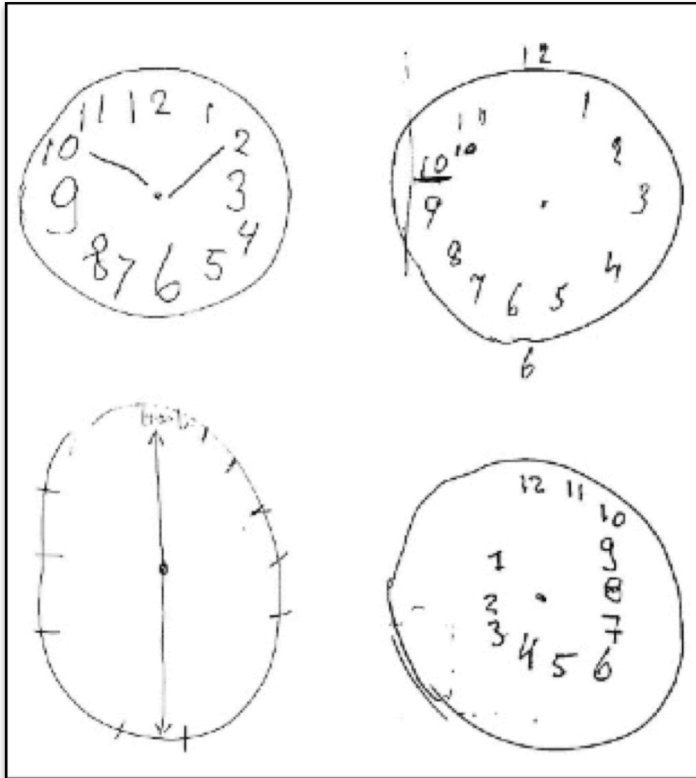


Figure 1.2: Clock drawings by patients with AD: the patient is asked to draw a clock and set the time at 10 after 11.

I.1.4. Criteria for dementia

Dementia is fundamentally a clinical diagnosis. Criteria for the diagnosis of dementia have been established by the National Institute on Aging and The Alzheimer's Association^[6]. They are defined by the following characteristics:

- interference with ability to function at work or at usual activities,
- a decline from a previous level of functioning and performing,
- cognitive impairment established by history-taking from the patient and a knowledgeable informant; and objective bedside mental status examination or neuropsychological testing,
- cognitive impairment involving a minimum of two of the following domains :
 - impaired ability to acquire and remember new information,
 - impaired reasoning and handling of complex tasks, poor judgment,

- impaired visuospatial abilities,
- impaired language functions,
- changes in personality, behaviour or comporment.

Moreover, these symptoms should not be explained by delirium or major psychiatric disorder.

I.1.5. Investigations

The aim of further investigations is to detect potentially reversible causes of cognitive impairment such as vitamin B12 deficiency, hypothyroidism or electrolytes abnormalities (e.g. hypercalcemia). The National Institute for Health and Clinical Excellence (NICE) dementia guidelines recommended performing the following blood tests for all patients at first presentation^[13]:

- a full blood count,
- T4 and thyroid stimulating hormone (TSH) blood levels,
- biochemical screen for electrolytes abnormalities,
- urea and creatinine plasma level,
- plasma glucose level,
- vitamin B12 and folate level,
- clotting factors and albumin level in the plasma,
- blood sedimentation rate and C reactive protein (CRP).

Routine chest X-ray and electrocardiogram should be performed as well.

Other possible blood tests, though not routinely requested in primary care, depend on the patient profile (young age, risk factors for sexually transmitted diseases such as having multiple partners or having a history of sexually transmitted infection) or on clinically identified causes on physical examination. They include:

- syphilis serology : TPHA-VDRL,
- human immunodeficiency virus (HIV) serology,
- caeruloplasmin for Wilson's disease.

Other possible specialist investigations include:

- cerebrospinal fluid (CSF) examination if Creutzfeldt-Jakob disease (CJD) or other forms of rapidly progressive dementia are suspected,
- electroencephalography (EEG) is not routinely indicated but should be considered in suspected delirium, FTLD or CJD or associated seizure disorder in those with dementia.

Structural imaging such as MRI or CT scan, are performed to exclude other cerebral pathologies and help establish the subtype of dementia. It may help to identify treatable causes such as subdural haematoma, normal pressure hydrocephalus, cerebral tumours etc. Finally, assessment of co-morbidities is essential for the diagnosis and management of dementia such as alcohol intoxication, cardiovascular risk factors (diabetes and dyslipidaemia), malnutrition, and age-related diseases (visual or auditory deficit, abnormal transit, mainly constipation and dehydration).

I. 2. Clinical features and diagnosis of AD

Now that criteria for dementia have been developed in the previous chapter, further clinical and nonclinical investigations should be done to make the final diagnosis of AD, the most common cause of dementia. To better understand the clinical features and the diagnosis of AD, the history of the discovery of dementia and its pathophysiology will be explained in the next chapter.

I.2.1. Overview of the pathophysiology of AD

The initial case reported by Aloïs Alzheimer, Auguste Deter (figure I.3), presented with behavioural disorders, psychosis and delusions in combination with dementia. These symptoms matched the definition of what was then called dementia, but she was very young to be displaying them, so he diagnosed her as having “presenile dementia”. When the patient died, Dr. Alzheimer sampled thin slices of this brain tissue, stained them with silver salts, and examined them under the microscope. He observed two types of abnormal deposits one outside the nerve

cells (in modern terminology, “amyloid plaques”), the other inside (now known as “neurofibrillary tangles”), which are the pathologic anomalies that now hallmark AD.




Figure 1.3: the case of Auguste Deter reported by Aloïs Alzheimer.

Nowadays, although the pathophysiology of AD still remains controversial, it has been clear that the pathological manifestations of AD include diffuse and neuritic extracellular amyloid plaques and intracellular neurofibrillary tangles^[14] accompanied by reactive microgliosis, dystrophic neurites, and loss of neurons and synapses^[15]. The regional evolution of AD pathology in terms of amyloid deposition and neurofibrillary tangles at several stages of the disease was described by Braak and Braak^[16], using post-mortem brain tissue. While these pathological lesions do not fully explain the clinical features of the disease, it has been hypothesized that alterations in the production and processing of amyloid beta (A β) protein may be the principal initiating factor^[17]. The underlying causes of these multifaceted changes remain unknown, but advancing age, genetic and nongenetic antecedent factors are thought to play important roles.

The genetic contribution to AD risk remains poorly understood despite major advances in the 1990's in the identification of three genes that cause early-onset AD (EOAD) and one significant genetic risk factor for late-onset AD (LOAD)^[18]. The first progress in understanding the genetic basis of AD resulted from studies of families displaying autosomal dominant inheritance of the disorder. In these families, affected individuals typically develop symptoms of AD between the ages of 30 and 60 years. Early studies^[19] in families with autosomal dominant AD identified causative mutations in the three genes: amyloid precursor protein (APP)^[20], presenilin 1 (PSN1)^[21] and presenilin 2 (PSN2)^[22]. The genetic basis of late-onset Alzheimer disease (LOAD) is more complex, with susceptibility conferred by a variety of more common but less penetrant genetic factors, likely interacting with environmental and epigenetic influences. To date, the only established genetic risk factor for late-onset disease is apoprotein E (*APOE*)^[23]. The *APOE* gene is located on chromosome 19 and exists in three alleles: epsilon 2, 3, and 4. *APOE* is a susceptibility gene, not a determinative gene. Patients homozygous for this allele are much more likely but not absolutely destined to develop dementia. In addition, almost 40% of patients with AD do not carry *APOE* ε4^[24].

I.2.2. Clinical features of AD

The amnesic presentation often prevails, but nonamnesic presentations can occur (see chapter II). The typical early cognitive impairment found in AD is memory involvement. It can be assessed by means of neuropsychological tests. In AD, declarative memory for facts and events, which depend on mesial temporal and neocortical structures are profoundly affected, while subcortical systems supporting procedural memory and motor learning are relatively spared until quite late in the disease. A subset of declarative memory, that of specific events and contexts (episodic memory) is more profoundly impaired in early AD, compared with memory for facts such as vocabulary and concepts (semantic memory), which often becomes impaired later. Semantic memory is encoded in neocortical (nonmesial) temporal regions. Within episodic memory, there is a distinction between immediate recall (mental rehearsal of a phone number), memory for recent events (which comes into play once material that has departed from consciousness must be recalled), and memory of more distant events. Memory for recent events, served by the

hippocampus, entorhinal cortex, and related structures in the mesial temporal lobe, is prominently impaired in early AD. In contrast, immediate memory (encoded in the sensory association and prefrontal cortices) is spared early on, as are memories that are consolidated for long periods of time (years), which can be recalled without hippocampal function. The early memory deficit in AD is most precisely described as anterograde long-term episodic amnesia. Memory deficits develop insidiously and progress slowly over time, evolving to include deficits of semantic memory and immediate recall. Impairments of procedural memory appear only in late stages of AD. There are numerous tests to assess memory and follow up its progression.

I.2.3. Neurocognitive assessment in AD

Testing orientation to time and place and asking the patient about events of the day are useful tools in the office or at the bedside to assess recent memory which involves the learning of new material. A more explicit test of recent memory, is asking patient to remember three to four words, having them repeat to ensure normal attention/immediate memory, and then ask them to recall the words after 5 to 10 minutes of distraction. For patients who are unable to recall the original words, category hints ("animal") or multiple-choice cues ("cow, horse, or dog") can be given to further assess the severity of the deficit. Longer lists of 8 to 10 words can also be used to increase the sensitivity of the test. Normal older adults should be able to remember three out of three words without cues and up to eight words with cues. Impaired ability to recall objects with selective cues (hints) represents a more severe deficit and one that may be particularly specific for AD in its early presentation.

The "three-words three-shapes" memory test is another test of recent memory that can be useful in the office setting^[25]. In this test, patients are asked to copy three words (eg, justice, courage, thirst) along with three abstract shapes. Delayed recall is tested in 5, 15, and 30 minutes with re-exposure to the stimuli as needed. If recall is faulty, multiple-choice recognition is tested.

Retrieval of remote memories can be tested by asking for the names of presidents from the country they are from in reverse order as far back as the patient can remember, or by asking about important historical events and dates as well as sporting events and popular television shows. The patient can also be asked about

details of personal life such as his or her birth date, the names and ages of children and grandchildren, and work history, assuming independent verification is available. Asking the patient the meanings of words, phrases, and symbols assesses semantic memory.

I.2.4. Criteria for the diagnosis of AD

Criteria for the diagnosis of probable AD dementia have been established by the National Institute on Aging and the Alzheimer's Association^[6].

To make the diagnosis of probable AD, the patient should present the criteria for dementia (see part I.1.4) associated with other core criteria that include:

- a insidious onset,
- a clear-cut history of worsening,
- with initial and most prominent cognitive deficits being one of the following :
 - amnesic presentation,
 - or nonamnesic presentations which include either :
 - a language presentation: prominent word-finding deficits,
 - a visuospatial presentation: visual cognitive deficits,
 - or a dysexecutive presentation: prominent impairment of reasoning, judgment and/or problem solving

Also, differential diagnoses have to be ruled out. There should be no evidence of substantial concomitant cerebrovascular disease, core features of DLB, prominent features of behavioural variant FTLD or prominent features of semantic or nonfluent variants of primary progressive aphasia, or evidence of another concurrent, active neurologic or non-neurologic disease or use of medication that could have a substantial effect on cognition.

Additionally, the National Institute on Aging and the Alzheimer's Association established criteria for possible AD dementia^[6]. Possible AD includes the following clinical features:

- atypical onset, presentation, or progression of dementia without known aetiology,

- presence of another potentially causative systemic or neurologic disorder that is not thought to be the aetiology of dementia in this case,
- progressive deterioration in a single cognitive domain in the absence of any other aetiology.

I.2.5. Clinical course of AD

AD progresses insidiously. The progress of the disease can be measured with mental status scales such as the MMSE. The clinical course is not necessarily linear, however, a number of studies have found that patients decline 3 to 3.5 points on average on the MMSE each year^[26]. A minority (<10%) of AD patient presents with a specific form of AD called rapidly progressive AD which is defined as having a decline of more than 6 points on annual MMSE^[27]. An older age of onset of AD (>80 years) may be associated with a slower rate of decline compared to younger patients^[28]. The MMSE has limitations for assessing progressive cognitive decline in individual patients over time. Small changes of 2 points or less in MMSE can be interpreted only with great uncertainty. They have a reasonable probability of being caused by measurement error, regression to the mean or practice^[29]. The reported median survival after diagnosis of AD is 4.2 years for men and 5.7 years for women with AD^[30]. Patients generally succumb to terminal-stage complications that relate to advanced debilitation, such as dehydration, malnutrition, and infection.

Deficits in other cognitive domains may appear with or after the development of memory impairment. Language function and visuospatial skills tend to be affected relatively early, while deficits in executive function often manifest later in the disease course. These deficits appear and progress insidiously.

The first manifestations of language dysfunction usually include word-finding difficulties, circumlocution, and reduced vocabulary in spontaneous speech and anomia on confrontational naming tests. This progresses to include agrammatism, paraphasic errors, impoverished speech content, and impaired comprehension.

Loss of visuospatial skills is an early feature of AD and manifests as misplacement of items and difficulty navigating in first unfamiliar then familiar terrain. Visual agnosia (inability to recognize objects) and prosopagnosia (inability to

recognize faces) are later features. Visuospatial skills may be tested by doing a clock drawing test (figure I.2).

Impairment in executive function may be subtle rather than frank; family members and coworkers may find them less motivated and engaged. In addition to poor insight, reduced ability for abstract reasoning may be elicited. As the disease progresses, a more manifest alteration of personality, poor judgment and planning, and an inability to complete tasks typically emerges.

I.2.6. Neuroimaging

Brain structural imaging, preferably with magnetic resonance imaging (MRI), is indicated in the evaluation of patients with suspected AD. On structural neuroimaging, both generalized and focal atrophy, as well as white matter lesions is noted. Also, medial temporal lobe atrophy, particularly the hippocampal formation and the amygdala have been shown to be reduced in AD (Figure I.4)^[31]. However, this finding is not specific for AD, as hippocampal atrophy also occurs in other common dementias such as VCI, DLB, and FTLD. Also, it is not clear that this finding adds to the accuracy of the diagnosis over the clinical assessment alone^[32]. Brain MRI can also document potential alternative diagnoses including cerebrovascular disease, other structural diseases (chronic subdural hematoma, cerebral neoplasm, normal pressure hydrocephalus), and regional brain atrophy suggesting FTLD.

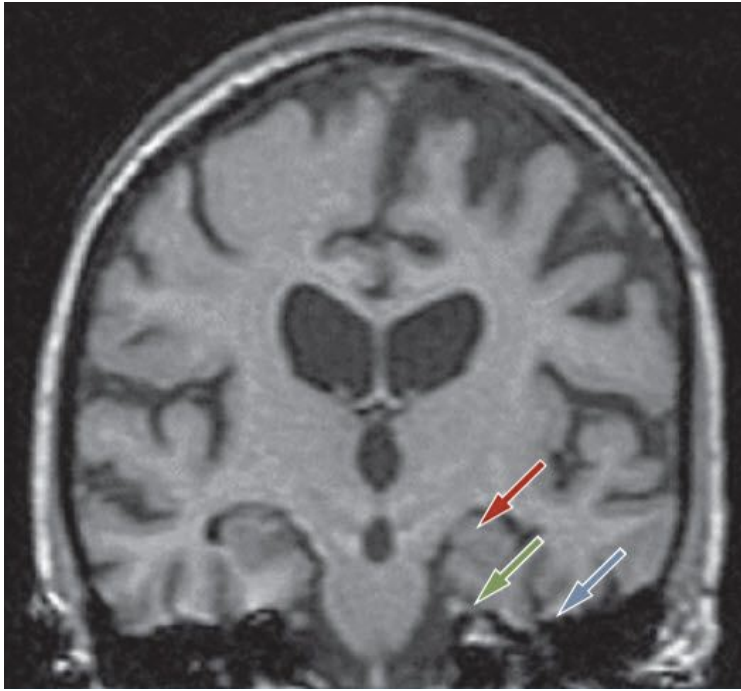


Figure 1.4 : T1-weighted MRI scan of a patient with AD. Generalized brain atrophy and loss of gray matter affecting the hippocampus (red arrow), entorhinal cortex (green arrow) and perirhinal cortex (blue arrow). Abbreviation: AD, Alzheimer disease.

Positron emission tomography with [18F] fluorodeoxyglucose (FDG-PET)^[33], functional MRI (fMRI)^[34], perfusion MRI, or perfusion single photon emission computed tomography (SPECT) reveals distinct regions of low metabolism and hypoperfusion in AD. These areas include the hippocampus, the precuneus (mesial parietal lobes) and the lateral parietotemporal cortex. Clinical studies suggest that FDG-PET may be useful in distinguishing AD from FTL^[35].

On SPECT scanning, reductions of blood flow and oxygen use can be found in the temporal and parietal neocortex in patients with AD, but it is not commonly used to assess AD.

On FDG-PET scanning, glucose hypometabolism is likely to be caused by a combination of neuronal cell loss and decreased synaptic activity in AD. Patients with AD have characteristic temporoparietal glucose hypometabolism, the degree of which is correlated with the severity of dementia^[36]. With disease progression, frontal involvement may be evident. The limited availability of PET in most medical centres is a current obstacle to widespread use.

The most significant advance in dementia imaging in recent years has been

the development of *in vivo* amyloid plaque labelling compounds. The most widely studied *in vivo* amyloid labelling tracer at this point is the PET ligand {N-methyl-¹¹C}2-(4'-methylaminophenyl)-6-hydroxybenzothiazole also known as Pittsburgh Compound B or PiB^[37]. PiB binds to fibrillar amyloid primarily in neuritic and diffuse plaques. *In vivo* PiB studies demonstrate a roughly two-fold increase in tracer retention in AD patients compared to most cognitively normal elderly subjects. Moreover, the topographic distribution of PiB retention matches that expected on the basis of autopsy studies of regional fibrillar plaque distribution^[38]. Greatest retention values are seen in prefrontal and lateral temporoparietal cortex, posterior cingulate/precuneus, and striatum^[39]. So PiB-PET is under investigation as an *in vivo* biomarker to positively diagnose AD: it can assess the level of certainty for AD (see chapter I.2.7), aid in prognosis, and differentiate AD from other causes of dementia.

It should be noted that the pathological features of other causes of dementia could exist in combination with AD (i.e. dementia with Lewy bodies, DLB and vascular cognitive impairment, VCI), particularly among individuals at an advanced age, which is particularly challenging from a diagnostic perspective^[51]. Because AD pathology frequently coexists with vascular pathology, particularly at older ages, both may contribute to cognitive dysfunction (mixed dementia). Thus, during life, it may be difficult to determine which pathological feature is the primary cause of the cognitive impairment.

I.2.7. Biomarkers of AD

Over the past years, the potential use of biomarkers has been recognized as a valuable tool for early and accurate diagnosis of AD^[40]. The major AD biomarkers that have been widely investigated at this time may be broken into two classes based on the biology which they measure. The first category is biomarkers of brain A β protein deposition. The two major biomarkers are low CSF A β 42 and a positive PiB-PET amyloid imaging^[41]. The second category is that of biomarkers of downstream neuronal degeneration or injury. The three major biomarkers in this category are elevated CSF tau, both total tau (t-tau) and phosphorylated tau (p-tau); decreased 18FDG uptake on PET in temporo-parietal cortex; and disproportionate atrophy on structural magnetic resonance imaging in medial temporal lobe, and

hippocampus by volumetric MRI measurements^[40]. Each of these five biomarkers is validated enough to be used in currently active therapeutic trials and large multicentered observational studies. Both CSF A β_{42} and amyloid PET imaging are biomarkers of brain A β plaque deposition. Excellent correspondence has been seen between Pittsburgh compound B (PiB) binding and fibrillar A β deposition in the brain (or cerebral vasculature) found on autopsy (figure 1.5)^[37].

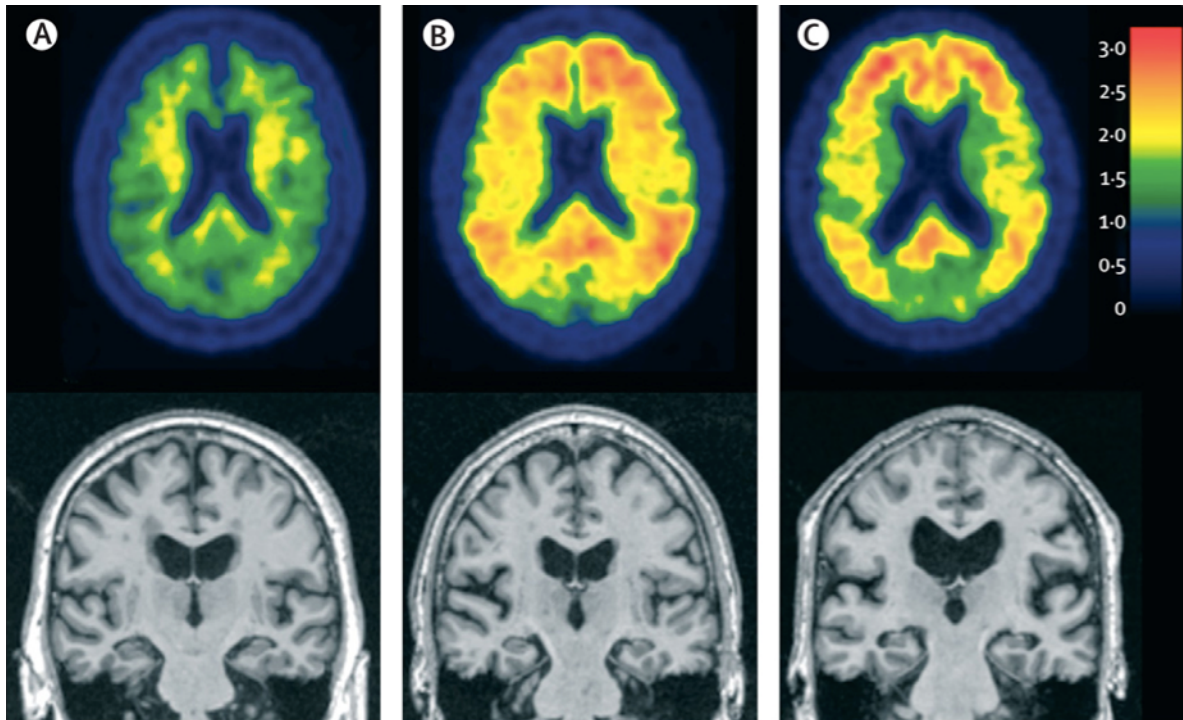


Figure 1.5: Axial PET amyloid imaging with Pittsburgh Compound B (PiB) (upper) and coronal structural MRI (lower) in three older patients. Regions of red and yellow indicate high Pittsburgh Compound B retention, indicating presence of amyloid deposition. (A) A cognitively normal individual with no evidence of A β on PET amyloid imaging with PiB and no evidence of atrophy on MRI. (B) A cognitively normal individual who has no evidence of neurodegenerative temporal atrophy on MRI, but has significant A β deposition on PET amyloid imaging. (C) An individual who has dementia and a clinical diagnosis of AD, a positive PET amyloid imaging study, and neurodegenerative atrophy of the temporal lobe on MRI.

Abbreviations: MRI, Magnetic resonance imaging; A β , amyloid-beta ; PiB, Pittsburgh compound B. Adapted from Jack et al., 2010^[42].

Low concentrations of CSF A β correlate with both the clinical diagnosis of AD and A β neuropathology at autopsy^[43]. CSF tau is an indicator of tau pathological changes and associated neuronal injury and concentrations of both p-tau and t-tau increase in AD^[44]. FDG-PET studies in patients with AD show a specific topographic pattern of decreased glucose uptake in a lateral temporoparietal (figure 1.6) and posterior cingulate, precuneus distribution^[45].

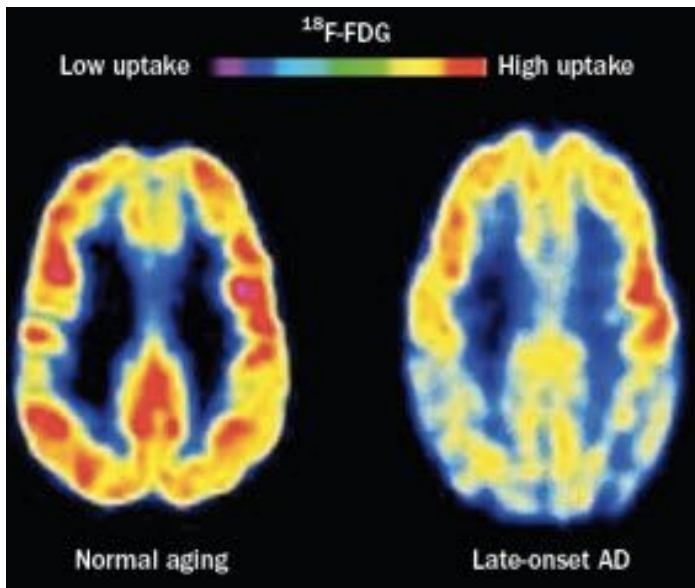


Figure 1.6. : Changes revealed by ¹⁸F-FDG-PET scanning in the brain, patterns characteristic of metabolic activity in cognitively normal individuals and patients with late-onset AD. In comparison with people aging normally (left), individuals with late-onset AD (right) show decreased bilateral glucose metabolism, particularly in the temporal and parietal regions. Abbreviations: AD, Alzheimer disease; FDG, 2-fluoro-2-deoxy-D-glucose; PIB, Pittsburgh compound B.

Finally, structural MRI can provide measures of cerebral atrophy, which is caused by dendritic pruning and loss of synapses and neurons^[46] which correlate with rates of cognitive decline^[47]. Manual hippocampal volumetry is currently the best-established biomarker for AD in the fields of structural imaging. Significant atrophy of the hippocampal formation can be demonstrated by MRI even in preclinical stages of AD and predict later conversion to AD^[48-49]. Automated data driven methods such as voxel-based volumetry (VBM), deformation-based morphometry (DBM) and the measurement of cortical thickness are currently being investigated to detect regional changes.

I.2.8 Classification of AD

In persons who meet the core clinical criteria for probable AD dementia, positive biomarker may increase the certainty that the basis of the clinical dementia syndrome is the AD pathophysiological process. Hence, the National Institute on Aging and The Alzheimer's Association included these biomarkers for the pathophysiological process of AD in the diagnostic criteria^[6].

Table I.1: Diagnostic Criteria for AD Dementia

Diagnosis	Likelihood of AD aetiology	A β (PET or CSF)	Neuronal injury (tau, FDG-PET, sMRI)
Probable AD dementia			
Clinical evidence only	Uninformative	Conflicting / Indeterminate / Unavailable	
With Biomarker evidence	Intermediate Intermediate High	Unknown Positive Positive	Positive Unknown Positive
Possible AD dementia			
Clinical evidence only	Uninformative	Conflicting / Indeterminate / Unavailable	
Atypical clinical presentation with biomarkers for AD	High	Positive	Positive
Dementia unlikely due to AD	Low	Negative	Negative

Abbreviations: AD, Alzheimer's disease; A β , amyloid-beta; PET, positron emission tomography; CSF, cerebrospinal fluid; FDG, ¹⁸fluorodeoxyglucose; sMRI, structural magnetic resonance imaging.

*Source : Adapted from McKhann GM, Knopman DS, Chertkow H, et al. The diagnosis of dementia due to Alzheimer's disease : recommendations from the National Institute on Aging-Alzheimer's Association workgroups on diagnostic guidelines for Alzheimer's disease. *Alzheimers Dement.* 2011;7(3):263-9^[6].*

As shown in table 1, a clinical diagnosis of probable AD based on only clinical criteria is of uninformative likelihood of AD pathology. The next level of certainty for a probable AD diagnosis is evidence of either amyloid deposition (detected on PET or in CSF) or neuronal injury (CSF tau levels, FDG-PET, or MRI atrophy patterns). This evidence increases the likelihood that the clinical syndrome of dementia is the result of underlying AD. The highest level of certainty is achieved when there is evidence of both amyloid deposition and neuronal injury in the presence of clinical evidence. There is also the category “possible AD,” with an atypical clinical course, but if both types of biomarkers (of amyloid deposition and neuronal injury) are positive, there is high likelihood of AD although it does not rule out second aetiology. Finally, with the wealth of available information on non-AD dementias, there is the category “unlikely due to AD,” which is appropriate if the person has clinical evidence, but accompanied by negative biomarkers for amyloid deposition and neuronal injury.

So biomarkers are considered to be a potential adjunct to diagnosis, primarily for research purposes, that would serve to increase the certainty of the aetiology of the clinical diagnosis of AD. However, incorporating these biomarkers in clinical practice is not yet widely established. Although work has begun in standardizing CSF assays, PET imaging, and volumetric MRI measurements, there are not yet well-validated, established normative values and calibration metrics for any of these biomarkers. Additional work remains to be done to standardize currently available biomarkers to enable optimal use in the clinical setting to develop more sensitive and specific biomarkers for early diagnosis, to track progression, and to monitor response to future disease-modifying therapy.

II. ATYPICAL PRESENTATION OF AD

II.1. Evidence of AD heterogeneity in the literature

Over the past years, there has been increasing awareness of slowly progressive focal cortical syndromes in which memory impairment is not a prominent feature and other symptoms predominate. Studies correlating clinical diagnosis and pathology in focal dementias have been few and have consisted mainly of either single case reports or relatively small series with particular cortical syndromes. A case series^[50] reported on 13 patients with atypical and typical presentations of AD from a total of 52 patients reaching autopsy. It showed that pathologically proven AD can present with a range of cognitive symptoms and identified 3 main patterns: posterior cortical atrophy (PCA), primary progressive aphasia (PPA) and behavioural variant AD (bvAD). PPA is further classified in three subtypes: progressive nonfluent aphasia (PNFA), semantic dementia (SD) and logopenic aphasia (LPA).

A large clinicopathological study^[7] of typical AD and focal cortical syndromes attempted to estimate the frequency at which such syndromes are due to AD versus other pathologies was performed. It showed that high proportion (just over a third) of focal cortical dementia syndromes is associated with AD pathology. The proportion of focal cortical syndromes associated to AD pathology was different according to their clinical presentations. 100% of PCA was found to be due to AD whereas 50% of corticobasal degeneration (CBD), 36% of PPA, 71% with mixed aphasia, 10% of SD and 7 % of bvAD were associated with AD pathologies. PPA is probably the commonest atypical presentation of AD with progressive nonfluent aphasia (PNFA) accounted for the majority of AD cases. Murray and his colleagues have shown by assessing the density and the distribution of neurofibrillary tangles on autopsy that atypical AD subtypes might account for about 25% of cases^[52].

Hence, there is a growing tendency in the literature suggesting a higher proportion of focal cortical presentations of AD pathology than previously recognized. These findings have implications for understanding the relationship between type of pathology and clinical dementia syndromes, as well as for early diagnosis and treatment. Several attempts have been made to better characterize those subtypes,

by neuropsychological profiles, biomarker profiles in the CSF and recently by neuroimaging.

II.1.1 Imaging evidence of Heterogeneity

In a comprehensive overview^[53] authors presented the knowledge about different phenotypes of AD. They showed corresponding abnormalities on functional imaging suggesting that variations in the distribution of the pathogenic changes in AD account for some of the observed clinical differences. Foster and his colleagues^[54] showed that patients with disproportionate failure of language function had markedly diminished metabolism in the left frontal, temporal, and parietal regions. Patients with predominant visuo-constructive dysfunction have shown evidenced a hypometabolic focus in the right parietal cortex. Patients with memory failure as the most apparent feature had no significant metabolic asymmetry in cortical regions. Verbal competency generally correlated with metabolic activity in the left frontal and temporal areas, while visuo-constructive test performance was linked to glucose utilization in the right parietal lobe. Pietrini et al.^[55] showed the involvement of parietal and occipital cortices (including primary visual cortex) on 18FDG-PET scan in patients with AD and visual disturbances at onset. Boxer and his colleagues^[56] demonstrated significant right cortical grey matter loss in MRI imaging in the visuoconstructively impaired group. They concluded that right inferotemporal atrophy may serve as a neuroimaging marker of visual constructive impairment in mild to moderate AD.

II.1.2. CSF biomarkers as an evidence of heterogeneity

Some studies postulated that subgroups of AD might be identified by the cerebrospinal fluid (CSF) levels of proteins associated with senile (neuritic) plaques and neurofibrillary tangles^[57]. The main biomarkers studied are t-tau, p-tau, and A β 42 in the CSF^[58]. However, current biomarkers do not account for all of the variance in AD; a more complete repertoire of biomarkers that more comprehensively assay the disease process is needed.

II.1.3. Neuropathological heterogeneity

From a pathological point of view, evidence has been found to support hypotheses of Alzheimer's heterogeneity. Neuropathological classification and scores exist such as the Braak's staging^[16], describing the distribution of neurofibrillary tangles (NFT), the CERAD staging (Consortium to Establish a Registry Of Alzheimer's disease) which describes the density of neuritic plaques^[59] and the National Institute on Aging and the Reagan Institute of the Alzheimer's Association (NIA-RIA) criteria, being a synthesis of CERAD and Braak's criteria^[60]. Regarding those criteria, neuropathological heterogeneity was observed: studies, which focused on neurofibrillar tangles (NFT) in AD revealed significantly different NFT densities in various areas of the cerebral cortex suggesting a possible existence of subgroups.

II.2. Factors contributing to AD heterogeneity

Factors, which might cause these clinical disparities, appear to be diverse. Three hypotheses have been proposed to explain neuropathological heterogeneity in AD: the presence of distinct subtypes of AD ("subtype hypothesis"), variation in the stage of the disease ("phase hypothesis") and variation in the origin and progression of the disease ("compensation hypothesis"). For instance, Wilkosz and his colleagues^[61] showed different cognitive impairment speeds and distinct trajectories of that deterioration speed may occur in different disease stages. Also the difference in cognitive reserve^[62], depending on patient intellectual quotient, educational and occupational attainment could account for phenotypical disparities. But furthermore, different biological causes or processes that converge on a common final pathophysiological pathway might evoke heterogeneity: Ritchie and Touchon^[63] showed that heterogeneity was due to the prevailing theory of the time, which held that clinical variation arose from observing the disease at different stages of progression ("phase hypothesis"), rather than truly distinct disease phenotypes ("subtype hypothesis"). In the same way, Armstrong and his colleagues examined 80 cases of patients with AD and found that neuropathological differences were rather continuously distributed in contrast to the subtype hypotheses. Heterogeneity in plaque and tangle distribution correlated more with disease stage (phase hypothesis) rather than being explained by the presence of AD subtypes^[64].

Many factors have been shown to contribute to this variability such as the age of onset, the topography of AD pathology, and genetics.

II.2.1. Age of Onset

Koedam and his colleagues studied 270 patients with EOAD and 90 patients with LOAD. EOAD accounted for 32% of atypical AD in contrast to only 6% of typical AD^[65]. In retrospect, this is consistent with earlier studies, wherein atypical subgroups of AD were significantly associated with younger age^[66]. Moreover, Van der Vlies et al. showed, by assessing the changes in MMSE per year, that the course of the disease in the EOAD has a more rapid progression than the LOAD: change in MMSE per year was a mean of 2,4 in EOAD versus 1,7 in LOAD^[67]. So these early-onset individuals evince a more aggressive disease course, in distinction from the more gradual progression of typical AD, and in contrast to the very slow decline of temporal variant AD. A rare type of EOAD called familial Alzheimer's disease (FAD), is caused by an autosomal dominant mutation in the amyloid precursor protein (APP), presenilin 1 (PSEN1), or presenilin 2 (PSEN2) genes^[18]. Despite that most cases of FAD have early-onset, mutation in APP, PSEN1 and PSEN2 still account for only a small percentage of all EOAD cases although this percentage increases in patients with very early onset AD (VEOAD) i.e. less than 45 years old.

II.2.2. Disease topography

The distribution of AD pathology and associated atrophy varies among individuals and may affect phenotype. Neurofibrillary pathology has a stereotypical progression in AD that is encapsulated in the Braak staging scheme^[16]. However, some AD cases are atypical and do not fit into this scheme. In a retrospective cohort, Murray et al. compared clinical and neuropathological features between typical and atypical AD cases: neurofibrillary tangle counts and senile plaque distribution showed that three pathologically distinct patterns of AD: hippocampal-sparing, limbic predominant, and 'typical' AD^[52]. Hippocampal-sparing AD occurred in younger individuals (mean age 72 years, versus 79 for typical and 86 for limbic-predominant AD), which is consistent with the association between atypicality and EOAD. Also

hippocampal-sparing cases were more likely to have an atypical, non-amnestic clinical onset (30% of cases) versus individuals with typical pathological distribution, where this occurred less frequently (17%). Hippocampal-sparing AD revealed the fastest rate of cognitive decline (-4.8 on MMSE per year, versus -2.8 for typical and -1.4 for limbic-predominant AD). Other studies showed that early onset AD has atypical topography. With FDG-PET scan, patients with EOAD had more severe and more widespread hypometabolism than patients with LOAD: in a study, there was significantly lower glucose metabolism in precuneus, posterior cingulate, temporo-parietal and occipital cortices^[68].

Structural MRI studies have shown that LOAD patients tend to have more prominent hippocampal volume loss than EOAD with more posterior areas more commonly affected in EOAD: precuneus, posterior cingulate and temporo-parietal areas^[69].

II.2.3. Genetics

Investigations for genetic predictors in AD have been significantly increased over the past years. In the autosomal dominant mutations causing FAD, mutations in PSEN1 and APP can both produce non-amnestic, atypical EOAD^[70-71]. PSEN1 has been described in one patient with PNFA in addition to more typical amnestic AD^[72]. A review reported cases with atypical findings associated with PSEN1 mutation^[73]: PSEN1 mutation was reported in patients with spastic paraparesis, frontotemporal dementia, myoclonus with generalized seizures, and psychiatric disorders. Prominent early behavioural symptoms have also been reported in association with several PSEN2 mutations^[74]. Extrapyrimal signs have been reported in association with several different PSEN1 mutations, particularly those causing very early onset disease and other neurological signs such as spastic paraparesis^[75].

Guyant-Marechal and his colleagues showed intrafamilial diversity of AD phenotype with APP duplication: one member of the family with APP mutation complained with bradykinesia and hallucinations, another showed memory and behavioural changes, whereas the third member presented with memory decline followed by intracerebral haemorrhage from cerebral amyloid angiopathy (CAA)^[76]. Rovelet-Lecrux and his colleagues also showed that APP can be associated with severe CAA presenting with haemorrhage and seizures along with memory decline^[77]. Brains from such

individuals with APP duplication showed abundant parenchymal and vascular deposits of A β peptides.

II. 3. AD subtypes

The 3 main focal cortical presentations of AD, posterior cortical atrophy, primary progressive aphasia and behavioural variant AD will be explained in the following chapters.

II.3.1. Posterior cortical atrophy (PCA)

PCA is now a well-recognized focal dementia syndrome which appears to be nearly always due to AD pathology^[50], but its regional distribution differs from typical AD. The immense majority of the patients with PCA do have AD with dementia with Lewy body, prion disease and tauopathies as major differential diagnosis^[78]. Patients with PCA present progressive visual or visuospatial impairment in the absence of ophthalmologic impairment. On examination there is evidence of complex visual disorder: elements of Balint's syndrome, visual agnosia, dressing apraxia or environmental disorientation. But there is proportionately less memory loss or reduced verbal fluency^[79]. PCA patients were further divided into two broad sub-groups^[80] :

- the biparietal syndrome with apraxia, visuospatial problems, agraphia, Balint's syndrome with preserved basic perceptual abilities, object recognition and reading (Figure II.1);
- the occipitotemporal syndrome with alexia, apperceptive agnosia and/or prosopagnosia.

Functional imaging shows biparieto-occipital hypoperfusion on SPECT scan^[55] or hypometabolism on PET scans^[81].

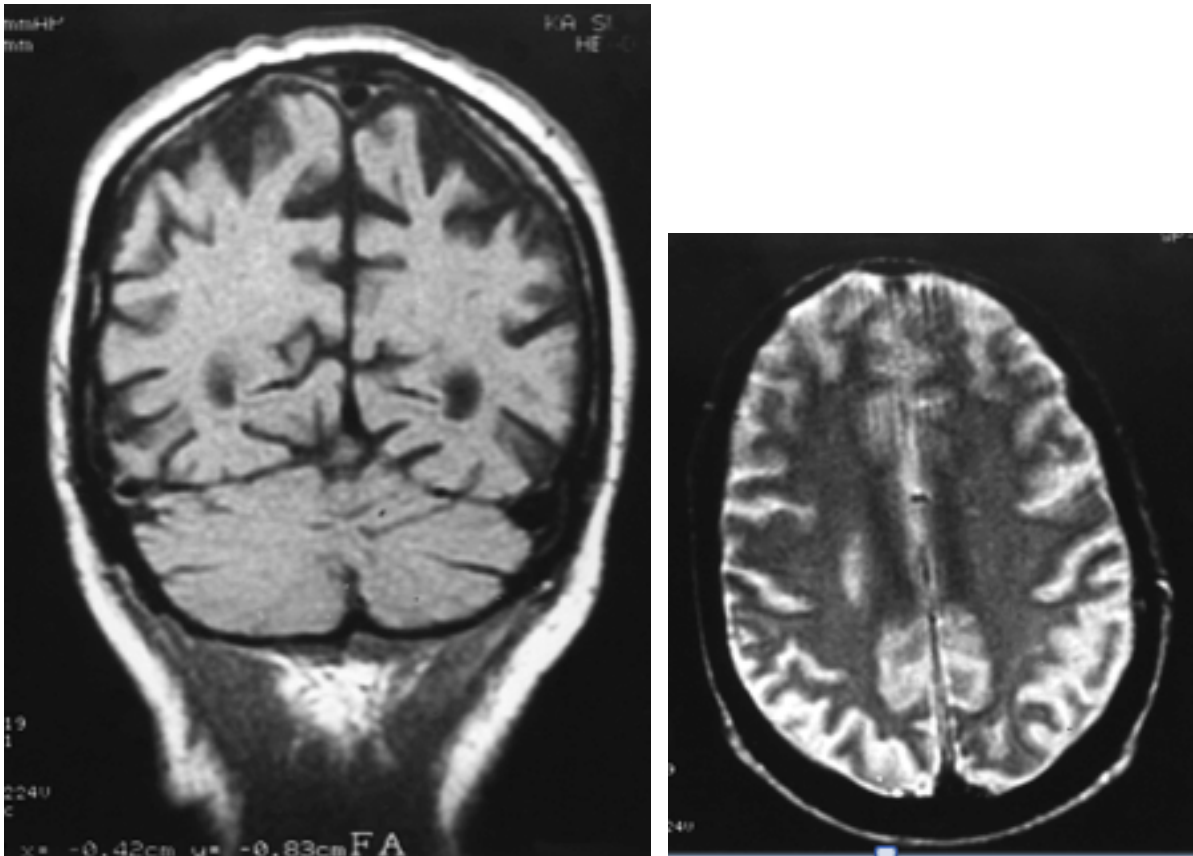


Figure II.1: Brain MRI of a patient with troubles in performing manual tasks and an inability to write. Coronal T1 (left) and axial T2 (right) with gross posterior cortical atrophy especially of the left parietal and temporal lobes. (Ross et al., 1996)^[80]

A third subtype is visual variant with primary visual failure and impairment of basic perceptual abilities. With only one previous pathologically proven case in the literature^[82], this pathology appears to be even rarer than the 2 other syndromes.

II.3.2. Primary Progressive aphasia (PPA)

PPA is a clinical syndrome defined by the insidious onset and progressive dissolution of language skills. PPA pathologically usually occurs with one of the frontotemporal lobar degeneration (FTLD) spectrum pathologies. However, it has long been recognized that PPA syndrome may also be associated with AD^{[50][7]}. Mesulam argued that PPA represents a distinct syndrome which can be distinguished from the aphasic presentation of AD by the clinical profile: preserved insight, social skills and episodic memory, visuospatial skills, reasoning, and comportment. In contrast to aphasia secondary to AD, which was associated with

early loss of insight and rapid deterioration in memory and other cognitive functions^[83]. Diagnostic criteria for PPA are an insidious onset and progressive language difficulty for at least two years without behavioural changes, memory or visuospatial impairments^[84]. In AD presenting as PPA, Galton et al.^[50] reported a disproportionately high burden of plaques and tangles in the left temporal and inferior parietal cortex (language areas) with sparing of the hippocampus. On imaging, left temporal hypoperfusion and left perisylvian atrophy was seen. PPA can be classified into three distinct clinical variants based on language profiles, progressive nonfluent aphasia (PNFA), semantic dementia (SD), and the recently characterized logopenic or phonological variant (LPA)^[85].

Patients with PNFA have nonfluent speech characterized by agrammatism (i.e. hesitancy and effortfulness attributable to impaired planning of articulation), phonemic paraphasias, and relative preservation of memory. In early disease MRI shows left inferior frontal and insula atrophy^[86].

In SD, speech fluency is preserved but there is a striking anomia, impaired word comprehension and deficits in non-verbal semantic association tasks such as sorting and grouping objects on basis of functional characteristics^[87]. MRI shows asymmetrical antero-inferior temporal lobe atrophy. LPA is commonly associated with AD pathology^[7].

Patients with LPA have word-finding pauses and anomia as well as impaired speech repetition, particularly sentences, but grammar and articulation are preserved^[88]. Verbal or phonological short-term memory is impaired^[89]. MRI shows left temporo-parietal atrophy.

II.3.3. Behavioural variant (bvAD)

Patient may present with prominent behavioural symptoms such as disinhibition, apathy and lack of empathy, poor self-care, alterations of food preference, stereotypic behaviour, as well as executive dysfunction. They also present executive dysfunction. bvAD is an extremely rare EOAD subtype. Johnson and colleagues, who found 3 cases among 63 individuals with pathologically confirmed AD, first described it. Likewise, Alladi and his colleagues identified only 2 instances among their 100 case series, of whom only one had a true dysexecutive syndrome, the other having only behavioural features^[7]. Analysis of brain tissue

samples demonstrated that, despite comparable entorhinal, temporal, and parietal NFT loads, the frontal AD group showed a significantly higher NFT load in the frontal cortex than the typical AD group^[91,92].

This demonstrates the wide spectrum of AD presentations and the recognition of atypical presentations of AD is important when attempting to make an early accurate pre-morbid diagnosis of neurodegenerative disease. Latest pharmacological trials implicated that different subtypes within AD may exhibit different susceptibilities to specific treatment^[93]. Hence, a superior characterization of the clinico-pathological heterogeneity and identification of predictive factors of disease progression should be able to improve our understanding of disease pathogenesis and allow better monitoring in therapeutic settings.

III. PRECLINICAL STAGE OF AD AND MILD COGNITIVE IMPAIRMENT (MCI)

While specific changes in cognition are frequently observed in normal aging, there is increasing evidence that some forms of cognitive impairment are recognizable as an early manifestation of dementia^[94]. The utility of this paradigm centers around the recognition that dementia is not a dichotomous state. Our understanding of transitional states between normal cognition and dementia will improve the understanding of cognitive decline, facilitate early diagnosis, and ultimately benefit patients.

III.1. Preclinical stage of AD

Over the past years, it had been critical to better define the preclinical stage of AD, to determine the factors that best predict the emergence of clinical impairment and progression to eventual AD dementia, and to reveal the biomarker profile that will identify individuals most likely to benefit from early intervention.

III.1.1. The continuum of AD

The concept of AD pathogenesis has evolved from a static, binary view discriminating cognitive normality from dementia, towards a dynamic view that considers AD pathology as a long-lasting morbid process that takes place progressively over years, or even decades, before the first symptoms become apparent, and thus operating in a continuum between the two aforementioned extreme states. AD was perceived for the first time more as a dynamic process than a stationary state in the late 1980s, and the idea that the pathological process begins long before clinical symptoms become apparent has gained increasing interest^[95]. The differences between normal aging and AD were clarified and formalized by Dubois and colleagues. They proposed a novel classification of AD^[96], which describe a model of the clinical trajectory of AD (see figure III.1). It distinguishes three stages of the disease: preclinical AD, MCI, and AD due to dementia.

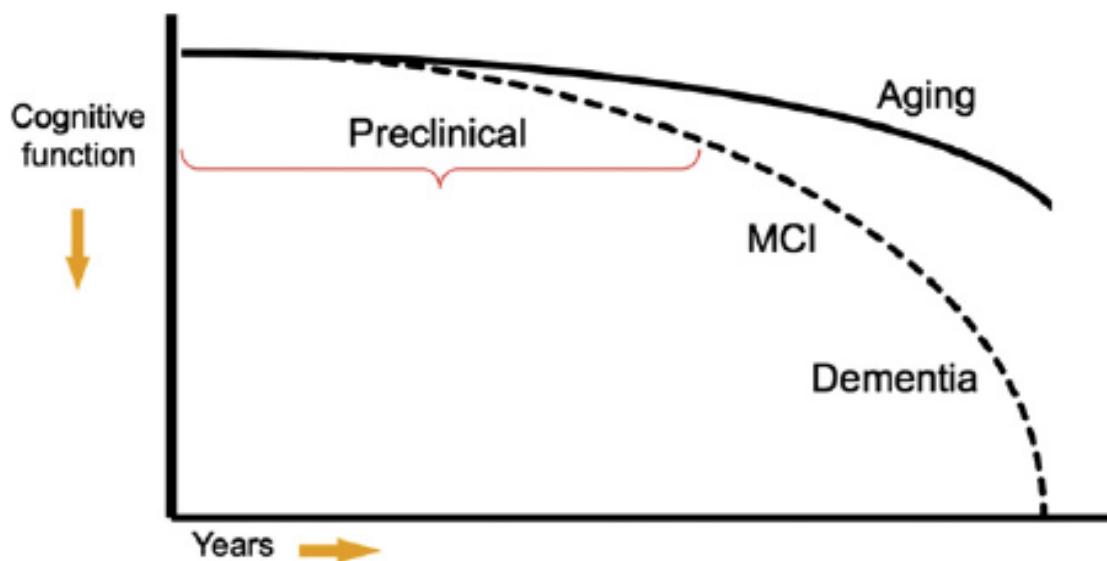


Figure III.1 : Model of the clinical trajectory of AD.

The stage of preclinical AD precedes mild cognitive impairment (MCI) and encompasses the spectrum of:

- presymptomatic autosomal dominant mutation carriers,
- asymptomatic biomarker-positive carriers of one or more apolipoprotein E (APOE) alleles,
- asymptomatic biomarker-positive older individuals at risk for progression to MCI due to AD and AD dementia,
- biomarker-positive individuals who have demonstrated subtle decline from their own baseline that exceeds that expected in typical aging, but would not yet meet criteria for MCI.

This diagram represents a hypothetical model for the pathological-clinical continuum of AD but does not imply that all individuals with biomarker evidence of AD-pathophysiological process will progress to the clinical phases of the illness.

Also, AD should be defined as encompassing the underlying pathophysiological disease process, as opposed to having “AD” connote only the clinical stages of the disease. So to disambiguate the term “AD,” it was referred to evidence of the underlying brain disease process as AD-pathophysiological process (abbreviated as AD-P) and the clinical phases of the illness as “AD-Clinical” (abbreviated as AD-C), which include not only AD dementia but also individuals with MCI due to AD-P.

III.1.2. AD pathophysiological cascade

AD-P is thought to begin years before the emergence of AD-C^[97]. The extent to which biomarkers of AD-P predict a cognitively normal individual's subsequent clinical course remains to be clarified. The difficulty in the field of AD is that it has not been established yet a firm link between the appearance of any specific biomarker in asymptomatic individuals and the subsequent emergence of clinical symptomatology. If however, it is possible to definitively determine the risk of developing AD dementia and the temporal course of clinical progression associated with AD-P in individuals without dementia or MCI, it will open a crucial window of opportunity to intervene with disease-modifying therapy. As an initial attempt to better understand the concept preclinical stage of AD, Sperling and colleagues proposed a theoretical model of the pathophysiological cascade of AD (Figure III.2)^[98].

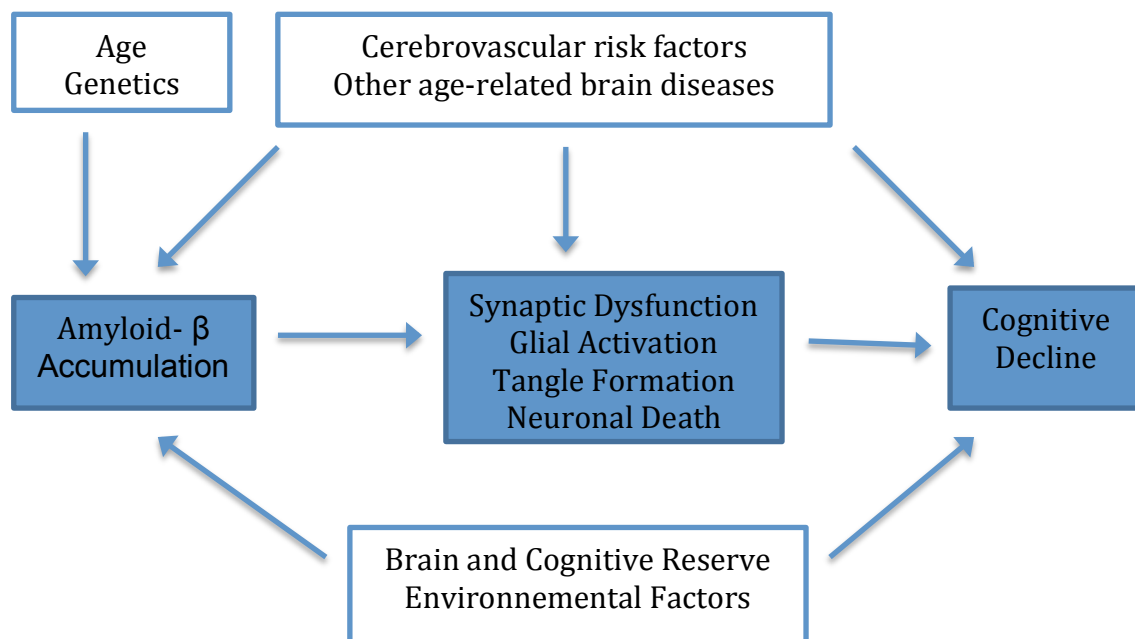


Figure III.2 : Hypothetical model of AD pathophysiological cascade

Adapted from Sperling et al., 2011^[98]

So far, it is well known that A β accumulation is necessary but not sufficient to produce the clinical manifestations of AD. A widely accepted assumption is that AD begins with abnormal processing of amyloid precursor protein (APP), which then

leads to excess production or reduced clearance of A β in the cortex^[99]. Genetic studies^[19] have identified mutations in *APP*, *PS1* and *PS2* genes which are involved in the cleavage of A β from APP to generate amyloidogenic A β peptides, see chapter I.2.1). These mutations cause rare, dominantly inherited familial AD. Also, genetic and cell biological studies show increased production of more amyloidogenic A β peptides associated with dominantly inherited familial AD-linked mutations, providing strong support for the amyloid hypothesis^[99], which postulate that A β peptides play a pivotal role in AD pathogenesis. Some investigators have also proposed that amyloid-independent mechanism may play an even earlier, or more central, role than A β peptides in the pathogenesis of AD such as synaptic, mitochondrial, metabolic, inflammatory, neuronal, cytoskeletal, and other age-related alterations^[100]. Evidence also suggests that additional factors, such as brain and cognitive reserve^[62], the presence of other age-related brain diseases, and genetic or environmental influence may modulate the relationship between AD-P and AD-C. Environmental factors^[101] such as cardiovascular risk factors (hypertension, hypercholesterolemia, diabetes)^[102], depression^[103], lack of engagement in cognitive^[104], physical and social activity and lower education and socioeconomic status have been associated to increased risk of cognitive decline.

III. 1.3. Model of dynamic biomarkers of the Alzheimer's pathological cascade

Jack and colleagues proposed a biomarker model^[42]. This model hypothesized a specific sequence of biomarker abnormalities that began before any evidence of clinical symptoms, and a series of sigmoid curves to characterize the temporal dynamics of these biomarkers (Figure III.3). Also it postulated that markers of amyloid accumulation typically become abnormal first but, importantly, suggested that amyloid might be necessary but not sufficient to result in AD dementia. Also in this model, biomarkers of A β deposition become abnormal early, before neurodegeneration and clinical symptoms occur. Biomarkers of neuronal injury, dysfunction, and neurodegeneration become abnormal later in the disease. Cognitive symptoms are directly related to biomarkers of neurodegeneration rather than biomarkers of A β deposition. Finally, as was said earlier, demographic factors might influence the temporal trajectory of these hypothetical curves, including age, genetics, socio-economic factors such as education, and other indicators of cognitive

reserve. The temporal relationships among the biomarkers and with clinical disease stage constitute an array of testable hypotheses.

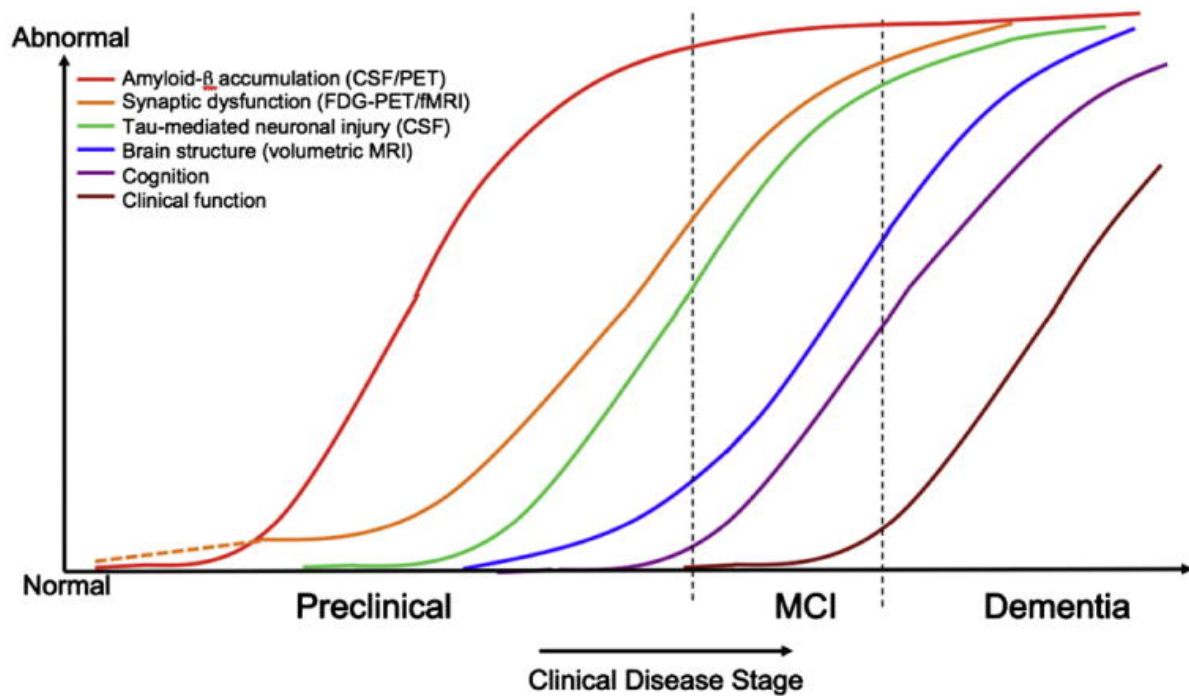


Figure III.3 : Dynamic biomarkers of the Alzheimer's pathological cascade.

Aβ is identified by CSF Aβ42 or PET amyloid imaging. Tau-mediated neuronal injury and dysfunction is identified by CSF tau or FDG-PET. Brain structure is measured by structural MRI. Adapted from Jack et al., 2010^[42]

Also, a staging framework based on biomarkers was proposed to characterize patients at increasing risk of progression toward MCI and dementia. Stage 1 is characterized as asymptomatic cerebral amyloidosis; stage 2 is amyloidosis plus neurodegeneration; and stage 3 is amyloidosis, neurodegeneration, and evidence of very subtle change in cognition or behaviour but is not sufficient to be diagnosed with MCI.

III.2. Mild Cognitive Impairment (MCI)

III.2.1. Definition and progression of MCI

Over the past three decades it has become abundantly clear that the cognitive deficits that accompany pathophysiological process of AD evolve gradually with

dementia representing the end stage of many years of pathology accumulation. When the cognitive impairment is sufficiently great, such that there is interference with daily function, the patient is diagnosed with AD dementia. As AD is a slow, progressive disorder, with no fixed events that define its onset, it is particularly challenging for clinicians to identify transition points for individual patients. Thus, the point at which an individual transition from the asymptomatic phase to the symptomatic MCI phase, or from the symptomatic MCI phase to dementia onset are difficult to identify.

The term MCI has arisen since the mid 1990's and stand for the symptomatic predemented phase of AD: the gradual impairments of cognitive function that precede the point where significant interference in daily activities occur^[105]. So MCI refers to the clinical condition between normal aging and AD in which persons experience memory loss to a greater extent than one would expect for age, yet they do not meet currently accepted criteria for clinically probable AD. Patients with MCI have a far higher rate of developing dementia than cognitively normal persons, but at the individual level, prognosis is variable: sometimes persons with MCI do not worsen and a few even revert back to cognitive normality. The variable prognosis in MCI is one reason why the term "MCI" has caught on: not only does it denote a sense of severity at the mildest level, it also conveys uncertainty of prognosis. Identification of the subset of patients with MCI at highest risk to progress to more severe cognitive impairment is a very important goal for research and future clinical care^[106]. Quantisation the degree of cognitive impairment by traditional history-taking, brief mental status testing, and more detailed neuropsychological assessment are necessary and informative first steps. Moreover, It is important that people with AD be identified as early as possible, so that they can benefit from treatments in development that slow down the progression of the disease.

III.2.2. Criteria for the clinical and cognitive syndrome

Largely informed by the advances in biomarker research discussed above and by increasing recognition of early stages of clinical impairment, a number of expert groups have worked over the past decade to develop new diagnostic criteria. The National Institute on Aging and the Alzheimer's Association convened a working group to revise the diagnostic criteria for MCI^[107]. The diagnosis of MCI is based

upon core clinical criteria that can be applied broadly, in any setting, without the need of highly specialized tests and/or procedures. These criteria are based on 3 main ideas:

- Concern from the family or physician regarding a change in cognition in comparison with the person's previous level or evidence of intraindividual change on serial evaluations.
- The patient present impairment in one or more cognitive domains that is greater than would be expected for the patient's age and educational background. This change can occur in a variety of cognitive domains, including memory, executive function, attention, language, and visuospatial skills. Impairment in episodic memory (the ability to learn and retain new information) is seen most commonly in MCI patients who subsequently progress to a diagnosis of AD dementia.
- Despite this cognitive impairment, there should be preservation of independence in functional abilities. Indeed, these cognitive changes should be sufficiently mild that there is no evidence of a significant impairment in social or occupational functioning.

Furthermore, evidence of progressive decline in cognition provides additional evidence that the individual has "MCI due to AD". Thus, it is important to obtain longitudinal assessments of cognition, whenever possible by serial evaluations of cognition but it may not be feasible in a particular circumstance. This is inherently a clinical judgment made by a skilled clinician on the basis of the individual circumstances of the patient and the description of daily affairs of the patient obtained from the patient and from a knowledgeable informant. Finally, as the similar strategy to that one that is use to diagnose AD-dementia, physicians must rule out other cerebrovascular disease that could account for the decline in cognition. So, the differentiation of dementia from MCI rests on whether there is substantial interference in the ability to function at work or in usual daily activities. This is a clinical judgment.

III.2.3. Objective clinical assessment of cognitive impairment: neuropsychological tests

Cognitive testing can assess objective evidence of impairment in one or more cognitive domains. Impairment in episodic memory is most commonly seen in MCI patients who subsequently progress to a diagnosis of AD dementia. There are a variety of episodic memory tests that are useful for identifying those MCI patients who have a high likelihood of progressing to AD dementia within a few years. Examples of such tests include the Free and Cued Selective Reminding Test, the Rey Auditory Verbal Learning Test, and the California Verbal Learning Test (CVLT). Other episodic memory measures include: immediate and delayed recall of a paragraph such as the Logical Memory I and II of the Wechsler Memory Scale Revised^[108] and immediate and delayed recall of nonverbal materials, such as the Visual Reproduction subtests of the Wechsler Memory Scale-Revised I and II. The Mini Mental State Examination^[11] is used as a general measurement of dementia.

Because other cognitive domains can be impaired among individuals with MCI, it is important to examine domains in addition to memory. Many validated clinical neuropsychological measures are available to assess these cognitive domains. These include:

- executive functions (set-shifting, reasoning, problem-solving, planning): Trail Making Test;
- language (naming, fluency, expressive speech, and comprehension) : the Boston Naming Test, letter and category fluency;
- visuospatial skills : figure copying;
- attentional control : digit span forward.

III.2.4. MCI Classification: Incorporating biomarkers in clinical practice

The National Institute on Aging and the Alzheimer's Association gave recommendations for MCI classification^[107]. As shown in Table III.1 the first level of diagnostic certainty for MCI involves having the clinical evidence alone. The next level of certainty requires positive evidence of either amyloid deposition or neuronal injury biomarkers. The highest level of confidence that MCI is caused by AD is

derived when the clinical syndrome is accompanied by positive evidence for both amyloid deposition and neuronal injury. As with dementia, the likelihood of a clinical syndrome not being caused by AD-P is low if the biomarkers are negative. At this point, only the diagnosis of MCI should be used in practice.

Table III.1 : Diagnostic Criteria for MCI

Diagnosis	Likelihood of AD aetiology	A β (PET or CSF)	Neuronal injury (tau, FDG-PET, sMRI)
MCI	Uninformative	Conflicting / Indeterminate / Untested	
MCI due to AD Intermediate likelihood	Intermediate	Positive	Untested
	Intermediate	Untested	Positive
MCI due to AD High likelihood	High	Positive	Positive
MCI Unlikely due to AD	Low	Negative	Negative

Abbreviations: MCI, Mild Cognitive Impairment; AD, Alzheimer's disease; A β , amyloid-beta; PET, positron emission tomography; CSF, cerebrospinal fluid; FDG, ¹⁸fluorodeoxyglucose; sMRI, structural magnetic resonance imaging.

Source : Adapted from Albert MS, DeKosky ST, Dickson D, et al. The diagnosis of mild cognitive impairment due to AD: recommendations from the National Institute on Aging-Alzheimer's Association workgroups on diagnostic guidelines for AD. Alzheimer Dement. 2011;7(3):270-9^[107]

However, nowadays biomarkers are deemed to be primarily for research use because several important issues about incorporating biomarkers into clinical practice exist, in particular, the need for standardization across centers. Although work has begun in standardizing CSF assays, PET imaging, and volumetric MRI measurements, there are not yet well-validated, established normative values and calibration metrics for any of the biomarkers. Additional work is required to make these biomarkers more easily interpretable to physicians in a variety of clinical settings.

DISCUSSION

The diagnosis of AD, and its neuropsychiatric sequelae, presents significant challenges for the clinicians because of the wide spectrum of the disease and its heterogeneous presentation. Indeed, it has been increasingly understood and recognized through several studies that AD has several atypical variants and can be identified in 3 main patterns: posterior cortical atrophy (PCA), primary progressive aphasia (PPA) and behavioural variant AD (bvAD). Moreover in the last decade, it has been shown that, during several years preceding the diagnosis of AD there is a gradual cognitive decline with a continuum in the disease and that the three stages exists: preclinical AD, MCI and dementia due to AD. This is why the new criteria issued in 2011 by the National Institute on Aging for diagnosing the AD spectrum were designed to help clinicians characterize individuals as early as possible in the course of the disease to allow for early intervention and prevention of subsequent neuronal damage. The criteria are also necessary for designing clinical trials for new therapies to prevent neuronal destruction.

Finally, recent studies assessed that biomarkers can be used to diagnose AD, its clinical variants, and its very early stage. It can also provide objective and reliable measures of disease progress. However, nowadays, the difficulty in the field of AD is that we have not yet established a firm link between the appearance of any specific biomarker in asymptomatic individuals and the subsequent emergence of clinical symptomatology. However, if we can definitively determine the risk of developing AD dementia and the temporal course of clinical progression associated with AD-P in individuals without dementia or MCI, we will open a crucial window of opportunity to intervene with disease-modifying therapy.

We should be open to the idea that, similar to cardiac disease and cancer treatment, AD can be diagnosed preclinically before significant cognitive impairment by the presence of biomarker evidence of AD pathologic change, and that this and other biomarkers may eventually guide therapy prior to the onset of symptoms. The overarching therapeutic objective of these preclinical studies would be to treat early pathological processes (e.g., lower A β burden or decrease neurofibrillary tangle pathology) to prevent subsequent neurodegeneration and eventual cognitive decline.

CONCLUSION

AD generally presents as a slowly progressive amnesic syndrome in later life, but there are several conditions that can mimic AD; conversely AD can mimic a range of other conditions. The high prior likelihood that an elderly individual with cognitive impairment has AD should not preclude consideration of other causes, and in particular it is always important to consider 'reversible' or treatable conditions, even if they are rare. Aside from endogenous variation in the AD phenotype, a further issue (particularly in older patients) is the real possibility of mixed pathology, eg, superadded vascular damage or Lewy body pathology, which may modify the AD phenotype. In many cases, careful history taking and bedside assessment can help to define atypical or unusual cases, but standard investigations, particularly MRI and neuropsychology, can be very useful in assessing the likelihood of AD versus other conditions.

AKNOWLEDGEMENTS

The contributions of many different people, in their different ways, have made this possible. I would like to extend my appreciation especially to the following.

First and foremost, I would like to express my sincere gratitude to my mentor doctor Marina Boban. I really appreciated her help in providing me with proper guidance and advice which has served me greatly.

I would also like to thank doc. dr. sc. Branko Malojčić and doc. dr. sc. Mario Habek for serving as members on my thesis committee.

I want to thank my parents for their love and support throughout my life. Thank you both for giving me strength to reach for the stars and chase my dreams.

To all my friends, thank you for your understanding and encouragement in my many, many moments of crisis. Your friendship makes my life a wonderful experience.

REFERENCES

1. http://www.alz.org/downloads/facts_figures_2011.pdf
2. <http://www.alz.co.uk/research/WorldAlzheimerReport2013ExecutiveSummary.pdf>
3. http://www.alz.org/documents/national/world_alzheimer_report_2010.pdf
4. McKhann G, McKhann G, Drachman D, Folstein M, Katzman R, Price D, Stadlan EM. "Clinical diagnosis of Alzheimer's disease: report of the NINCDS-ADRDA Work Group under the auspices of Department of Health and Human Services Task Force on Alzheimer's Disease." *Neurology* 1984; 34: 939-44.
5. Knopman DS, DeKosky ST, Cummings JL, Chuit H, Corey-Bloom J, Relkin N, et al. Practice parameter: diagnosis of dementia (an evidence-based review). *Neurology* 2001;56:1143-53.
6. McKhann GM, Knopman DS, Chertow H, et al. The diagnosis of dementia due to Alzheimer's disease: recommendations from the National Institute on Aging-Alzheimer's Association workgroups on diagnostic guidelines for Alzheimer's disease. *Alzheimers Dement* 2011;7(3):263-9.
7. Alladi S, Xuereb J, Bak T, Nestor P, Knibb J, Patterson K, et al. Focal cortical presentations of Alzheimer's disease. *Brain* 2007; 130:2636-45.
8. Rabinovici GD, Jagust WJ, Furst AJ, Ogar JM, Racine CA, Mormino EC, et al. Abeta amyloid and glucose metabolism in three variants of primary progressive aphasia. *Ann Neurol* 2008;64:388-401
9. McKeith I, Mintzer J, Aarsland D, et al. Dementia with Lewy bodies. *Lancet Neurol*. 2004;3:19-28.
10. Neary D, et al. Frontotemporal lobar degeneration: a consensus on clinical diagnostic criteria. *Neurology*. 1998;51(6):1546-54.
11. Folstein MF, Folstein SE, McHugh PR. 'Mini-mental state'. A practical method for grading the cognitive state of patients for the physician. *J Psychiatr Res* 1975;12:189-98.
12. Crum RM, Anthony JC, Bassett SS, Folstein MF. Population-based norms for the Mini-Mental State Examination by age and educational level. *JAMA* 1993; 269:2386.
13. National Institute for Health and Clinical Excellence (NICE). Delirium: diagnosis, prevention and management. (Clinical guideline 103.) 2010.
14. Davis DG, et al. Alzheimer neuropathologic alterations in aged cognitively normal subjects. *J Neuropathol Exp Neurol*. 1999;58(4):376-88.
15. Serrano-Pozo A, Frosch MP, Masliah E, Hyman BT. 2011. Neuropathological alterations in Alzheimer disease. *Cold Spring Harb Perspect Med* doi: 10.1101/cshperspect. a006189.
16. Braak H, Braak E. Neuropathological staging of Alzheimer-related changes. *Acta Neuropathol (Berl)* 1991;82:239-59
17. Hardy JA, Higgins GA. Alzheimer's disease: the amyloid cascade hypothesis. *Science*. 1992;256(5054):184-5.
18. Bertram L, Tanzi RE. Thirty years of Alzheimer's disease genetics: the implications of systematic meta-analyses. *Nat Rev Neurosci* 2008;9:768-78.
19. Price DL, Tanzi RE, Borchelt DR, Sisodia SS (1998) Alzheimer's disease: genetic studies and transgenic models. *Annu Rev Genet* 32:461-493.

20. Goate A, Chartier-Harlin MC, Mullan M, et al. Segregation of a missense mutation in the amyloid precursor protein gene with familial Alzheimer's disease. *Nature* 1991; 349:704
21. Sherrington R, Rogaev EI, Liang Y, et al. Cloning of a gene bearing missense mutations in early-onset familial Alzheimer's disease. *Nature* 1995; 375:754.
22. Renbaum P, Levy-Lahad E. Monogenic determinants of familial Alzheimer's disease: presenilin-2 mutations. *Cell Mol Life Sci* 1998; 54:910.
23. Corder EH, Saunders AM, Strittmatter WJ, et al. Gene dose of apolipoprotein E type 4 allele and the risk of Alzheimer's disease in late onset families. *Science* 1993; 261:921.
24. Myers RH, Schaefer EJ, Wilson PW, et al. Apolipoprotein E epsilon4 association with dementia in a population-based study: The Framingham study. *Neurology* 1996; 46:673.
25. Weintraub S, Peavy GM, O'Connor M, et al. Three words three shapes: A clinical test of memory. *J Clin Exp Neuropsychol* 2000; 22:267.
26. Clark CM, Sheppard L, Fillenbaum GG, et al. Variability in annual Mini-Mental State Examination score in patients with probable Alzheimer disease: a clinical perspective of data from the Consortium to Establish a Registry for Alzheimer's Disease. *Arch Neurol* 1999; 56:857.
27. Schmidt C, Wolff M, Weitz M, et al. Rapidly progressive Alzheimer disease. *Arch Neurol* 2011; 68:1124.
28. Bernick C, Cummings J, Raman R, et al. Age and rate of cognitive decline in Alzheimer disease: implications for clinical trials. *Arch Neurol* 2012; 69:901.
29. Hensel A, Angermeyer MC, Riedel-Heller SG. Measuring cognitive change in older adults: reliable change indices for the Mini-Mental State Examination. *J Neurol Neurosurg Psychiatry* 2007; 78:1298.
30. Larson EB, Shadlen MF, Wang L, et al. Survival after initial diagnosis of Alzheimer disease. *Ann Intern Med* 2004; 140:501.
31. Jack CRJ, Petersen RC, Xu YC, et al. Medial temporal atrophy on MRI in normal aging and very mild Alzheimer's disease. *Neurology* 1997; 49 :786–94.
32. Wahlund LO, Almkvist O, Blennow K, et al. Evidence-based evaluation of magnetic resonance imaging as a diagnostic tool in dementia workup. *Top Magn Reson Imaging* 2005; 16:427.
33. Minoshima S, Giordani B, Berent S, et al. Metabolic reduction in the posterior cingulate cortex in very early Alzheimer's disease. *Ann Neurol* 1997; 42:85.
34. O'Brien JL, O'Keefe KM, LaViolette PS, et al. Longitudinal fMRI in elderly reveals loss of hippocampal activation with clinical decline. *Neurology* 2010; 74:1969.
35. Foster NL, Heidebrink JL, Clark CM, et al. FDG-PET improves accuracy in distinguishing frontotemporal dementia and Alzheimer's disease. *Brain* 2007; 130:2616.
36. Salmon E. Functional brain imaging applications to differential diagnosis in the dementias. *Curr Opin Neurol*. Aug 2002;15(4):439-44.
37. Klunk WE, Engler H, Nordberg A, Wang Y, Blomqvist G, Holt DP, et al. Imaging brain amyloid in Alzheimer's disease with Pittsburgh Compound-B. *Ann Neurol*.2004;55:306–19.
38. Rowe, C. C., Ng, S., Ackermann, U., Gong, S. J., Pike, K., Savage, G., Villemagne, V. L. (2007). Imaging beta-amyloid burden in aging and dementia. *Neurology*, 68(20), 1718-1725. doi: 10.1212/01.wnl.0000261919.22630.ea

39. Edison P, Archer HA, Hinz R, Hammers A, Pavese N, Tai YF, et al. Amyloid, hypometabolism, and cognition in Alzheimer disease: An [11C]PIB and [18F]FDG-PET study. *Neurology* 2007;68:501–508.
40. Hampel H, Burger K, Teipel SJ, Bokde AL, Zetterberg H, Blennow K. Core candidate neurochemical and imaging biomarkers of Alzheimer's disease. *Alzheimers Dement* 2008;4:38–48.
41. Chetelat G, Villemagne VL, Bourgeat P, Pike KE, Jones G, Ames D, et al. Relationship between atrophy and beta-amyloid deposition in Alzheimer disease. *Ann Neurol* 2010;67:317–24.
42. Jack CR Jr, Knopman DS, Jagust WJ, Shaw LM, Aisen PS, Weiner MW, et al. Hypothetical model of dynamic biomarkers of the Alzheimer's pathological cascade. *Lancet Neurol* 2010;9:119–28.
43. Schoonenboom NS, van der Flier WM, Blankenstein MA, et al. CSF and MRI markers independently contribute to the diagnosis of Alzheimer's disease. *Neurobiol Aging*. 2008;29:669–675.
44. Buerger K, Ewers M, Pirttila T, et al. CSF phosphorylated tau protein correlates with neocortical neurofibrillary pathology in Alzheimer's disease. *Brain*. 2006;129:3035–3041.
45. Jagust W, Reed B, Mungas D, Ellis W, Decarli C. What does fluorodeoxyglucose PET imaging add to a clinical diagnosis of dementia? *Neurology*. 2007;69:871–877.
46. Bobinski M, de Leon MJ, Wegiel J, et al. The histological validation of post mortem magnetic resonance imaging-determined hippocampal volume in Alzheimer's disease. *Neuroscience*. 2000;95:721–725
47. Fox NC, Scahill RI, Crum WR, Rossor MN. Correlation between rates of brain atrophy and cognitive decline in AD. *Neurology*. 1999;52:1687–1689.
48. Jack CR Jr, Petersen RC, Xu YC, O'Brien PC, Smith GE, Ivnik RJ, et al. Prediction of AD with MRI-based hippocampal volume in mild cognitive impairment. *Neurology* 1999;52:1397–403.
49. Apostolova, L. G. et al. Conversion of mild cognitive impairment to Alzheimer disease predicted by hippocampal atrophy maps. *Arch. Neurol.* 63, 693-699 (2006).
50. Galton CJ, Patterson K, Xuereb JH, Hodges JR: Atypical and typical presentations of Alzheimer's disease: a clinical, neuropsychological, neuroimaging and pathological study of 13 cases. *Brain* 2000, 123:484-498.
51. Schneider JA, et al. Mixed brain pathologies account for most dementia cases in community-dwelling older persons. *Neurology*. 2007;69(24):2197–204.
52. Murray ME, Graff-Radford NR, Ross OA, Petersen RC, Duara R, Dickson DW: Neuropathologically defined subtypes of Alzheimer's disease with distinct clinical characteristics: a retrospective study. *Lancet Neurol* 2011, 10:785-796.
53. J. L. Cummings, 2000. Cognitive and behavioral heterogeneity in Alzheimer's disease: seeking the neurobiological basis. *Neurobiol Aging*, 21(6), 845 EOF 61 EOF.
54. Foster NL, Chase TN, Fedio P, Patronas NJ, Broks RA, Di Chiro G: Alzheimer's disease: focal cortical changes shown by positron emission tomography. *Neurology* 1983, 33:961-965.
55. Pietrini P, Furey ML, Graff-Radford N, Fieo U, Alexandre GE, et al.. (1996) Preferential metabolic involvement of visual cortical areas in a subtype of Alzheimer's disease: clinical implications. *American Journal of Psychiatry*, 153, 1261–1268.
56. A. L. Boxer, J. H. Kramer, A. Du, T. , N. Schuff, M. W. Weiner, B. L. Miller, et al., 2003. Focal right

- inferotemporal atrophy in AD with disproportionate visual constructive impairment. *Neurology*, 61(11), 1485-1491.
57. Iqbal, K., Alonso Adel, C., Chen, S., Chohan, M. O., El-Akkad, E., Gong, C. X., Grundke-Iqbal, I. (2005). Tau pathology in Alzheimer disease and other tauopathies. *Biochim Biophys Acta*, 1739(2-3), 198-210. doi: 10.1016/j.bbadis.2004.09.008
58. A. E. van der Vlies, N. A. Verwey, F. H. Bouwman, M. A. Blankenstein, M. Klein, P. Scheltens, et al. (2009b). CSF biomarkers in relationship to cognitive profiles in Alzheimer disease. *Neurology*, 72(12), 1056-1061.
59. Mirra, S. S., Heyman, A., McKeel, D., Sumi, S. M., Crain, B. J., Brownlee, L. M., Berg, L. (1991). The Consortium to Establish a Registry for Alzheimer's Disease (CERAD). Part II. Standardization of the neuropathologic assessment of Alzheimer's disease. *Neurology*, 41(4), 479-486.
60. Murayama, S., & Saito, Y. (2004). Neuropathological diagnostic criteria for Alzheimer's disease. *Neuropathology*, 24(3), 254-260.
61. Wilkosz, P. A., Seltman, H. J., Devlin, B., Weamer, E. A., Lopez, O. L., DeKosky, S. T., & Sweet, R. A. (2010). Trajectories of cognitive decline in Alzheimer's disease. *Int Psychogeriatr*, 22(2), 281-290. doi: 10.1017/S1041610209991001.
62. Stern, Y. (2006). Cognitive reserve and Alzheimer disease. *Alzheimer Dis Assoc Disord*, 20(2), 112-117. doi: 10.1097/01.wad.0000213815.20177.19.
63. Ritchie, K., & Touchon, J. (1992). Heterogeneity in senile dementia of the Alzheimer type: individual differences, progressive deterioration or clinical sub-types? *J Clin Epidemiol*, 45(12), 1391-1398.
64. Armstrong, R. A., Nochlin, D., & Bird, T. D. (2000). Neuropathological heterogeneity in Alzheimer's disease: a study of 80 cases using principal components analysis. *Neuropathology*, 20(1), 31-37.
65. Koedam, E. L., Lauffer, V., van der Vlies, A. E., van der Flier, W. M., Scheltens, P., & Pijnenburg, Y. A. (2010). Early-versus late-onset Alzheimer's disease: more than age alone. *J Alzheimers Dis*, 19(4), 1401-1408. doi: 10.3233/JAD-2010-1337.
66. Snowden, J. S., Stopford, C. L., Julien, C. L., Thompson, J. C., Davidson, Y., Gibbons, L., Mann, D. (2007). Cognitive phenotypes in Alzheimer's disease and genetic risk. *Cortex*, 43(7), 835-845.
67. A. E. van der Vlies, A.E., Koedam, E.L.G.E., Pijnenburg, Y.A.L., Twisk, J.W.R., Scheltens, P., van der Flier, W.M. (2009a) Most rapid cognitive decline in APOE epsilon4 negative Alzheimer's disease with early onset. *Psychol Med*, 39(11), 1907-1914.
68. Rabinovici, G. D., Furst, A. J., Alkalay, A., Racine, C. A., O'Neil, J. P., Janabi, M., Jagust, W. J. (2010). Increased metabolic vulnerability in early-onset Alzheimer's disease is not related to amyloid burden. *Brain*, 133(Pt 2), 512-528. doi:10.1093/brain/awp326
69. Frisoni, G. B., & Caroli, A. (2007). Neuroimaging outcomes for clinical trials. *J Nutr Health Aging*, 11(4), 348-352.
70. Ryan NS, Rossor MN: Correlating familial Alzheimer's disease gene mutations with clinical phenotype. *Biomark Med* 2010, 4:99-112.

71. Larner AJ, Doran M: Clinical phenotypic heterogeneity of Alzheimer's disease associated with mutations of the presenilin-1 gene. *J Neurol* 2006, 253:139-158.
72. Godbolt, A. K., Beck, J. A., Collinge, J., Garrard, P., Warren, J. D., Fox, N. C., & Rossor, M. N. (2004). A presenilin 1 R278I mutation presenting with language impairment. *Neurology*, 63(9), 1702-1704.
73. Menendez, M. (2004). Pathological and clinical heterogeneity of presenilin 1 gene mutations. *J Alzheimers Dis*, 6(5), 475-482.
74. Marcon G, Di Fede G, Giaccone G et al: A novel Italian presenilin 2 gene mutation with prevalent behavioral phenotype. *J Alzheimers.Dis* 16(3), 509-511 (2009).
75. Dintchov TL, Mehrabian S, Van den BM et al: Novel PSEN1 mutation in a bulgarian patient with very early-onset Alzheimer's disease, spastic paraparesis, and extrapyramidal signs. *Am J Alzheimers.Dis Other Demen.* 24(5), 404-407 (2009).
76. Guyant-Marechal I, Berger E, Laquerrière A, Rovelet-Lecrux A, Viennet G, Frebourg T, Rumbach L, Campion D, Hannequin D: Intrafamilial diversity of phenotype associated with app duplication. *Neurology* 2008, 71:1925-1926.
77. Rovelet-Lecrux A, Hannequin D, Raux G, Le Meur N, Laquerrière A, Vital A, Dumanchin C, Feuillet S, Brice A, Vercelletto M, Dubas F, Frebourg T, Campion D: APP locus duplication causes autosomal dominant earlyonset Alzheimer disease with cerebral amyloid angiopathy. *Nat Genet* 2006, 38:24-26.
78. Tang-Wai DF, Graff-Radford NR, Boeve BF, Dickson DW, Parisi JE, Crook R, Caselli RJ, Knopman DS, Petersen RC: Clinical, genetic, and neuropathologic characteristics of posterior cortical atrophy. *Neurology* 2004, 63:1168-1174
79. McMonagle, P., Deering, F., Berliner, Y., & Kertesz, A. (2006). The cognitive profile of posterior cortical atrophy. *Neurology*, 66(3), 331-338. doi:10.1212/01.wnl.0000196477.78548.db
80. Ross S, Graham N, Stuart-Green L, Prins M, Xuereb J, Patterson K, et al. Progressive biparietal atrophy: an atypical presentation of Alzheimer's disease. *J Neurol Neurosurg Psychiatry* 1996; 61: 388–95.
81. Freedman L, Selchen DH, Black SE, Kaplan R, Garnett ES, Nahmias C. Posterior cortical dementia with alexia: neurobehavioural, MRI, and PET findings. *J Neurol Neurosurg Psychiatry* 1991; 54: 443–8.
82. Levine DN, Lee JM, Fisher CM. The visual variant of Alzheimer's disease. *Neurology* 1993; 43: 305–13.
83. Mesulam MM. Primary progressive aphasia—differentiation from Alzheimer's disease [editorial]. [Review]. *Ann Neurol* 1987; 22: 533–4.
84. Mesulam MM. Primary progressive aphasia. *Ann Neurol* 2001;49:425-32.
85. Gorno-Tempini, M. L., Hillis, A. E., Weintraub, S., Kertesz, A., Mendez, M., Cappa, S. F., . . . Grossman, M. (2011). Classification of primary progressive aphasia and its variants. *Neurology*, 76(11), 1006-1014. doi: 10.1212/WNL.0b013e31821103e6
86. Knibb JA, Xuereb JH, Patterson K, Hodges JR. Clinical and pathological characterisation of progressive aphasia. *Ann Neurol* 2006;59:156-65.

87. Adlam A-LR, Patterson K, Rogers TT, Nestor PJ, Salmond CH, Acosta-Cabronero J, et al. Semantic dementia and fluent primary progressive aphasia: two sides of the same coin? *Brain* 2006;129:3066-80.
88. Gorno-Tempini ML, Dronkers NF, Rankin KP, Ogar JM, Phengrasamy L, Rosen HJ, et al. Cognition and anatomy in three variants of primary progressive aphasia. *Ann Neurol* 2004;55:335-46.
89. Gorno-Tempini ML, Brambati SM, Ginex V, Ogar J, Dronkers NF, Marcone A, Perani D, Garibotto V, Cappa SF, Miller BL: The logopenic/phonological variant of primary progressive aphasia. *Neurology* 2008, 71:1227-1234
90. Hodges JR, Patterson K. Nonfluent progressive aphasia and semantic dementia: a comparative neuropsychological study. *J Int Neuropsychol Soc* 1996; 2: 511–24
91. Johnson JK, Head E, Kim R, Starr A, Cotman CW. Clinical and pathological evidence for a frontal variant of Alzheimer disease. *Arch Neurol* 1999;56:1233-9
92. von Gunten A, Bouras C, Kovari E, Giannakopoulos P, Hof PR. Neural substrates of cognitive and behavioral deficits in atypical Alzheimer's disease. *Brain Res Rev* 2006;51:176-211.
93. A. K. Wallin, K. Blennow, H. Zetterberg, E. Londos, L. Minthon, O. Hansson, 2010CSF biomarkers predict a more malignant outcome in Alzheimer disease. *Neurology*, 74(19), 1531 EOF 1537 EOF
94. Bennett DA, Wilson RS, Schneider JA, et al. Natural history of mild cognitive impairment in older persons. *Neurology* 2002; 59:198.
95. Brayne C, Calloway P: Normal ageing, impaired cognitive function, and senile dementia of the Alzheimer's type: a continuum? *Lancet* 1988, 1:1265-1267.
96. Dubois B, Feldman HH, Jacova C, Dekosky ST, Barberger-Gateau P, Cummings J, Delacourte A, Galasko D, Gauthier S, Jicha G, Meguro K, O'Brien J, Pasquier F, Robert P, Rossor M, Salloway S, Stern Y, Visser PJ, Scheltens P: Research criteria for the diagnosis of Alzheimer's disease: revising the NINCDS-ADRDA criteria. *Lancet Neurol* 2007, 6:734-746.
97. Dubois B, Feldman HH, Jacova C, Cummings JL, Dekosky ST, Barberger- Gateau P, et al. Revising the definition of Alzheimer's disease: a new lexicon. *Lancet Neurol* 2010;9:1118–27.
98. Sperling, R. A., Aisen, P. S., Beckett, L. A., Bennett, D. A., Craft, S., Fagan, A. M., Phelps, C. H. (2011). Toward defining the preclinical stages of Alzheimer's disease: recommendations from the National Institute on Aging-Alzheimer's Association workgroups on diagnostic guidelines for Alzheimer's disease. *Alzheimers Dement*, 7(3), 280-292. doi: 10.1016/j.jalz.2011.03.003
99. Hardy J, Selkoe DJ (2002) The amyloid hypothesis of Alzheimer's disease: progress and problems on the road to therapeutics. *Science* 297:353–356.
100. Pimplikar SW, Nixon RA, Robakis NK, Shen J, Tsai LH. Amyloidindependent mechanisms in Alzheimer's disease pathogenesis. *J Neurosci* 2010;30:14946–54.
101. Yaffe K, Fiocco AJ, Lindquist K, Vittinghoff E, Simonsick EM, Newman AB, et al. Predictors of maintaining cognitive function in older adults: the Health ABC study. *Neurology* 2009; 72:2029–35.
102. Craft S. The role of metabolic disorders in Alzheimer disease and vascular dementia: two roads converged. *Arch Neurol* 2009;66:300–5.
103. Wilson RS, Arnold SE, Schneider JA, Kelly JF, Tang Y, Bennett DA. Chronic psychological distress and risk of Alzheimer's disease in old age. *Neuroepidemiology* 2006;27:143–53.

104. Wilson RS, Scherr PA, Schneider JA, Tang Y, Bennett DA. Relation of cognitive activity to risk of developing Alzheimer disease. *Neurology* 2007;69:1911–20.
105. Petersen RC, et al. Current concepts in mild cognitive impairment. *Arch Neurol.* 2001;58(12):1985–92.
106. Petersen RC, Stevens JC, Ganguli M, Tangalos EG, Cummings JL, DeKosky ST : Practice parameter: early detection of dementia: mild cognitive impairment (an evidence-based review). Report of the Quality Standards Subcommittee of the American Academy of Neurology. *Neurology.* 2001 May 8; 56(9):1133-42.
107. Albert, M. S., DeKosky, S. T., Dickson, D., Dubois, B., Feldman, H. H., Fox, N. C., Phelps, C. H. (2011). The diagnosis of mild cognitive impairment due to Alzheimer's disease: recommendations from the National Institute on Aging-Alzheimer's Association workgroups on diagnostic guidelines for Alzheimer's disease. *Alzheimers Dement*, 7(3), 270-279. doi: 10.1016/j.jalz.2011.03.008
108. Wechsler DA. Wechsler Memory Scale-Revised. San Antonio (TX): Psychological Corporation; 1987.

Curriculum Vitae

Caroline Mouselli

41, av Paul Doumer • 75116, Paris, France

Born in Paris le 26/12/1987

Phone: 0033647272949 • E-Mail: cmouselli@gmail.com

Education

- Medical Studies in English, Sixth Year 2008-2014
University of Zagreb, School of Medicine
- Premier Cycle des Etudes Médicales, PCEM1 2006-2008
Université Paris V René Descartes
- Scientific Baccalaureate, Physic speciality, with honours 2006
Institut de la Tour, 75116 Paris

Stages

- Department of Emergency Medicine September-November 2014
Hôpital Cochin, Paris 75006
- Department of Infectious Diseases July-August 2013
Hôpital Cochin, Paris 75006
- Departement of Internal medicine and rare diseases July-September 2012
Pr Guillevin
Hôpital Cochin, Paris 75006
- Department of Neurosurgery July 2011
Hôpital Sainte-Anne, Paris 75014
- *Department of Obstetrics and Gynecology* July 2005
Clinique Sainte-Thérèse, Paris 75017
- Department “Gueules Cassées” July 2004
Reconstructive surgery
Hôpital Saint-Joseph, Paris 75014

Languages: French, English, Spanish, Ancient Greek