

Brain MRI post-processing with MAP07 in the preoperative evaluation of patients with pharmaco-resistant epilepsy - Croatian single centre experience

Bujan Kovač, Andreja; Petelin Gadže, Željka; Radoš, Milan; Krbot Skorić, Magdalena; Mrak, Goran; Nemir, Jakob; Milošević, Milan; Hajnšek, Sanja

Source / Izvornik: *Clinical Neurology and Neurosurgery*, 2021, 201

Journal article, Accepted version

Rad u časopisu, Završna verzija rukopisa prihvaćena za objavljivanje (postprint)

<https://doi.org/10.1016/j.clineuro.2020.106426>

Permanent link / Trajna poveznica: <https://um.nsk.hr/um:nbn:hr:105:900886>

Rights / Prava: [In copyright](#) / [Zaštićeno autorskim pravom](#).

Download date / Datum preuzimanja: **2024-08-27**



Repository / Repozitorij:

[Dr Med - University of Zagreb School of Medicine Digital Repository](#)



Brain MRI post-processing with MAP07 in the preoperative evaluation of patients with pharmacoresistant epilepsy – Croatian single centre experience

Andreja Bujan Kovac¹, Zeljka Petelin Gadze¹, Milan Rados², Magdalena Krbot Skoric^{1,3}, Goran Mrak⁴, Jakob Nemir⁴, Milan Milosevic⁵, Sanja Hajnsek⁶

¹ Department of Neurology, University Hospital Centre Zagreb, School of Medicine, University of Zagreb, Referral Centre of the Ministry of Health of the Republic of Croatia for Epilepsy, Affiliated Partner of the ERN EpiCARE, Zagreb, Croatia

² Croatian Institute for Brain Research, School of Medicine, University of Zagreb, Zagreb, Croatia

³ University of Zagreb, Faculty of Electrical Engineering and Computing, Zagreb, Croatia

⁴ Department of Neurosurgery, University Hospital Centre Zagreb, School of Medicine, University of Zagreb, Affiliated partner of EUROCAN, Zagreb, Croatia

⁵ Andrija Stampar School of Public Health, Department for Environmental Health, Occupational and Sports Medicine, University of Zagreb, School of Medicine, Zagreb, Croatia

⁶ School of Medicine, University of Zagreb, Zagreb, Croatia - retired

Corresponding author:

Bujan Kovac Andreja, M.D., neurologist

E-mail address: abujankovac@gmail.com

Mailing address: Department of Neurology, University Hospital Centre Zagreb, School of Medicine, University of Zagreb, Referral Centre of the Ministry of Health of the Republic of Croatia for Epilepsy, Affiliated Partner of the ERN EpiCARE

Kispaticeva 12, 10000 Zagreb, Croatia

Telephone number: +38512388374

Orchid ID: 0000-0003-3729-8624

Abstract

Objective: This study aimed to determine the role of brain MRI post-processing method MAP07 (Morphometric Analysis Program) in detecting epileptogenic brain lesions in patients with pharmaco-resistant epilepsy (PE). MAP07 is a sophisticated diagnostic program that offers several morphometric maps and facilitates the detection and localization of hippocampal sclerosis (HS), focal cortical dysplasias (FCD), and other types of cortical malformations, which could be undetected by conventional visual MRI analysis (CVA).

Methods: 120 patients aged > 16 years with PE have been recruited. 3T MRI was performed according to epilepsy imaging protocol followed by image postprocessing with a fully automated MATLAB script, MAP07, by applying SPM5 algorithms. Statistical analysis was performed in IBM SPSS Statistics, version 25.0.

Results: Analysis in our patients showed a high sensitivity of MAP07 with low specificity and with a high proportion of false-positive patients. After MRI analysis, out of 120 patients, 32 were found to have no structural abnormalities by conventional visual analysis in whom after MAP07 in 5 patients structural lesions were found (in one HS, in one FCD, in two perinatal vascular lesions, and in one hippocampal hyperintensity). There was a quite high overall coincidence of the findings of MAP07 and MRI for the detection of FCD, HS, perinatal ischemia/chronic vascular lesions, heterotopias, and polymicrogyria (kappa coefficient above 0.700).

Conclusions: MAP07 analysis is a useful, additional, and automated method that may guide re-evaluation of MRI by highlighting suspicious cortical regions, as a complementary method to CVA, by enhancing the visualization of cortical malformations and lesions.

Key words: epilepsy, brain MRI postprocessing, hippocampal sclerosis, malformation of cortical development

1. Introduction

Epilepsy is a chronic disease of the central nervous system that affects 1% of the population [1–4]. 25-35% of patients have pharmaco-resistant epilepsy (PE) and are considered for epilepsy surgery [5–8]. Preoperative evaluation of patients with PE encompasses non-invasive and invasive methods, where MRI (Magnetic resonance imaging), especially 3T, is crucial in the delineation of structural lesions [9–12].

Complete removal of the MRI-detected structural lesion is the most important factor determining seizure freedom following surgery [9-10,13]. However, about 20-30% of patients with classic temporal lobe epilepsy do not have any MRI-defined abnormality [14-15]. Furthermore, about 10-30% of focal cortical dysplasias (FCD), especially subtle or located deep in the sulci, can be overseen on conventional visual MRI analysis (CVA) [16–18].

There is a need for postprocessing MRI tools for more accurate detection of structural epileptogenic lesions [19–21]. In the latest ILAE recommendations for the use of structural MRI in epilepsy patients, epilepsy protocols are discussed, and also several MRI postprocessing techniques are listed and encouraged, especially when evaluating patients with negative MRI [15, 22]. Another promising technique that can help improve preoperative patient evaluation is the post-processing of MRI images with MAP07 (Morphometric Analysis Program), a MATLAB program using an algorithm of the SPM software [23]. The program processes data gained by 1.5 or 3T MRI. MAP07 analysis is based on the principle of voxel-by-voxel comparison of the normalized individual 3D-T1 sequence with a normal database [18,23–27]. The processing results are presented in several post-processing MAP07 images which allow easier detection and localization of hippocampal sclerosis (HS), FCD, and other malformations of cortical development that were initially MRI negative and would in other case be difficult to detect with CVA [23–27].

2. Materials and methods

2.1. Participants

A prospective cross-sectional study was conducted at the Referral Centre of the Ministry of Health of the Republic of Croatia for Epilepsy and University Hospital Centre Zagreb in co-operation with the Croatian Institute for Brain Research and Polyclinic Neuron, for the purpose to differentiate the role of utilizing postprocessing MAP07 program in patients with PE.

120 patients with PE were enrolled, aged from 16 to 67 years (average 32.53 years), 51 men and 69 women. Most patients (63.33%, N=76) had epilepsy with focal to bilateral tonic-clonic seizures, 25% (N=30) had focal, and 2.5% (N=3) generalized epilepsy, 6.67% (N=8) had combined focal and generalized epilepsy, one patient had progressive myoclonic epilepsy, one had Lennox- Gastaut syndrome, and one was with unknown clinical phenotype.

In our research we aimed: A) to estimate the role of MAP07 in the detection of the structural epileptogenic lesions, B) to estimate differences in MAP07 analysis of our CVA + (conventional visual MRI analysis positive - with structural epileptogenic lesion) and CVA- patients (without structural epileptogenic lesion), C) to determine how many epilepsy patients who are CVA- have changes detectable with MAP07 (MAP+), D) to determine the proportion of “false” positive results detected with MAP07 (patients who are CVA-/MAP+), E) to estimate the percentage of patients that have had epilepsy surgery after a MAP+ result and F) to determine the advantages of certain MAP07 maps in detecting different malformations of cortical development (MCD).

2.2. MRI protocol

In all patients included in this study 3T MRI was performed on Magnetom TrioTim, Siemens, Erlangen, Germany. All MRIs consisted of high-resolution MPRAGE, T1 sequence - TR =1900 ms, TE=2.52 ms, voxel size 1x1x1 mm, “field of view” 250x250, matrix 246x256, and coronal and axial T2 and FLAIR sequences (TR=9400 ms, TE=87 ms, voxel size=1x1x3 mm, “field of view”=180x250 mm, matrix=256x184) as required by MAP07 program. The control database was created on the same scanner, with the same parameters, and consisted of 30 healthy age-matched volunteers with headache and normal MRI findings.

2.3. Morphometric analysis program

Morphometric MRI analysis was performed using a fully automated MATLAB script (version 7.11.0., R2010b, MathWorks, Natick, MA), by applying algorithms of SPM5 (Statistical Parametric Mapping, Wellcome Dept. of Imaging

Neuroscience Group, London, UK; <http://www.fil.ion.ucl.ac.uk/spm>) and additional simple computations to compare individual brain anatomy with a normal database in MAP07 program following previously established methods by Huppertz HJ et al. [23–25,27-28].

Analysis of each patient image data set results in the creation of three morphometric maps, each representing different radiological aspects of MCD, called the junction map (sensitive to the blurring of the gray-white matter junction), the extension map (sensitive to the abnormal gyration and extension of gray matter into the white matter) and the thickness map (sensitive to abnormal cortical thickness) [27]. These 3 maps represent z-score maps and highlight brain structures when deviating from a normal database. MAP07 also encompasses fully automated script for the detection of periventricular nodular heterotopias (PNH) [24], automated whole-brain FLAIR analysis [29,30], and automated quantitative hippocampal FLAIR intensity analysis [25].

Initial MRI images were examined by a neuroradiologist and labeled as CVA+ or CVA-. Thereafter MAP07 was performed and labeled as MAP+ or MAP- when showing deviation to the database. MAP07 was set to “medium sensitivity” with the following z-score thresholds for extension map (3.5 lower cutoff and 5 higher cutoff), junction map (2.5 lower cutoff and 4 higher cutoff), thickness map (2.5 lower cutoff and 4 higher cutoff), combined map (3.5 lower cutoff and 5 higher cutoff) and for automated whole-brain FLAIR analysis (lower cutoff 3 and higher cutoff 4). All MAP findings were re-evaluated by a neuroradiologist experienced in epilepsy imaging and epileptologist and finally marked as MRI+ when showing structural epileptogenic lesion or MRI- (without structural epileptogenic lesion), Figure 1.

2.4. Statistical analysis

All statistical data analyses were performed using IBM SPSS Statistics, version 25.0 (<https://www.ibm.com/analytics/spss-statistics-software>) and MedCalc for Windows, version 19.0.3 (MedCalc Statistical Software version 19.0.3 (MedCalc Software bvba, Ostend, Belgium; <https://www.medcalc.org;2019>). The Kolmogorov-Smirnov test analyzed the distribution of continuous numerical values and the corresponding nonparametric tests were applied according to the obtained data. The following statistical tests were performed: Fisher's exact test for contingency tables, the Mann-Whitney test for nonparametric two-sample analysis, the Kendall rank correlation coefficient (τ_b) for nonparametric test hypothesis, the Cohen's kappa coefficient (κ) for assessing the reliability of MRI and MAP07 findings and ROC analysis for the evaluation of z-score. $P < 0.05$ was statistically significant.

3. Results

120 patients (42.5% men, N=51, and 57.5% women, N=69) with PE according to ILAE definition were included [7,8]. The flowchart representing data acquisition and analysis is presented in Figure 1. CVA was positive in 88 patients, and negative in 32 patients, without statistically significant difference regarding gender.

Figure 1. Flowchart representing data acquisition and analysis

Data showing the difference in frequencies of different structural lesions on CVA, MAP07, and re-evaluated MRI positive findings of different lesions in our group of patients is shown in Figure 2. Among the CVA+ findings, the most prevalent were perinatal ischemia/chronic vascular changes with an overall frequency of 21.6%, as a cause of structural epilepsy in these patients, although they do not present a typical substrate for epilepsy surgery, followed by FCD, HS, heterotopias, etc.

Figure 2. The difference in frequencies of CVA, MAP07, and re-evaluated MRI positive findings of different lesions in our group of patients: Fisher-Friedman-Halton's exact test

There is a significant difference from the initial MRI finding ($P = 0.005$) meaning that 27 subjects who were MAP+ (84.4%) were initially CVA-. In 22/27 of these patients, after re-examining of MRI, it was still found negative (MRI-), but in 5/27 of patients who were initially CVA-, MAP07 was positive - one showing FCD, two perinatal ischemia/chronic vascular changes, one HS and one increased FLAIR intensity of hippocampus. MAP07 showed no changes in patients with pineal gland cyst (N=4), encephalocele (N=1), and lobar atrophy (N=1).

Surgery was performed in 34 patients, and patients who were MRI+ were more likely to undergo surgery ($p=0,006$). The most frequent procedure in MRI+ patients was selective amygdalohippocampectomy (N=11), followed by VNS implantation (N=8), FCD resection (N=5), operation of encephalocele (N=2), ablation of epilepsy-related tumors (LGG, N= 2), one selective amygdalohippocampectomy, and tumor resection due to dual pathology, one cavernoma ablation and in one patient anterior temporal lobe resection was performed. Most frequent PHD findings were HS (N=9) and FCD (N=11, 1/11 FCD1 and 1/11 FCD2a, 4/11 FCD2b, 4/11 FCD3a and 1/11 FCD3b) [31-32]. From 5 MAP07 new cases, only one patient with MAP07 finding of HS was operated, with histopathological correlation and good clinical outcome.

In our group of patients, MAP07 analysis showed high sensitivity (98.86%) with a rather low specificity (15.62%) and a high number of false positives. All MAP07 findings were reevaluated by an experienced neuroradiologist. The additional value of MAP07 was the finding of 5 patients who were CVA-.

When looking at individual changes, the overall coincidence of the findings is quite high (kappa coefficient above 0.700) for detection of FCD (κ coefficient 0.772, $p < 0.001$), HS (κ coefficient 0.843, $p < 0.001$), perinatal ischemia/chronic vascular lesions (κ coefficient 0.691, $p < 0.001$) and heterotopia (κ coefficient 0.829, $p < 0.001$). MAP07 verified all sites of polymicrogyria (5/5, κ coefficient 1.000, $p < 0.001$). The worst match findings are for hippocampal/amygdala hyperintensity (κ coefficient 0.299 with $p = 0.027$).

When analyzing detection rates of different structural lesions, higher z-score values on extension maps were significantly associated with the detection of heterotopia ($\tau_b = 0.375$; $P < 0.001$). Higher z-scores on PNH maps were associated with heterotopia detection and higher FLAIR z-scores with HS detection. Thickness and extension maps were associated with polymicrogyria detection. Neither map correlates significantly with FCD findings. Table 1 analyzes the correlation of measured values of individual maps with detected changes on MRI. According to our results, heterotopia was significantly better represented on the PNH map ($p = 0.001$), with z-scores from 6.6-34.9, while subcortical nodules were better detected by extension map with $p < 0.001$ and z- a score of 7.2-35.2.

Table 1. Relationship of certain maps available by MAP07 analysis in the detection of various malformations of cortical development and their localization: Kendall's Tau-b correlation coefficient

Lesions that are CVA+ had a significantly higher z-score: median (interquartile range) 8.20 (7.00-11.08) versus 6.90 (6.30-8.00); $P < 0.001$, as shown in Figure 3. When analyzing the ROC curve of the z-score ratio and the positive MRI findings for individual changes at values > 7.7 , there is the highest sensitivity (58.6%) and specificity (72.2%) with a significant area under the curve (AUC) of 0.711, $P < 0.001$.

Figure 3. Box and Whisker's Z-score plot of positive MRI findings in detecting individual changes

CVA showed FCD in 14 patients with concordant MAP07 analysis in 12/14 patients (overall FCD was suspected in 16 patients after MAP07), but in 4 patients additional FCD was found (Figure 2). After re-evaluation, 18 patients were MRI+ with FCD findings. Of this 4 additional FCD found on MAP07, one patient was initially CVA- but MAP07 showed FCD in the eloquent cortex. However, the patient denied further invasive monitoring. In the second patient, CVA showed HS and postencephalitic changes, but MAP07 showed FCD IIIA (FCD + HS). In the third patient, CVA showed polymicrogyria and MAP07 additional FCD. In the fourth patient CVA showed heterotopia, but after MAP07 it was reevaluated as FCD. None of these patients were operated, 2 were better after correction of antiepileptic drug therapy, and last patient was lost on further follow-up.

Heterotopia was found on CVA in 11 patients, and two had additional polymicrogyria (11/120, 12.5%). The MAP07 verified heterotopic sites in 8/11 patients. In one patient with multiple heterotopic nodules, MAP07 was partially positive and did not indicate one nodule. Surgery was performed in 4/11 patients. VNS was implanted in a patient with heterotopia and polymicrogyria (PMG) and in two patients with multiple heterotopic nodules. The last patient first underwent selective amygdalohippocampectomy due to HS followed by anterior temporal lobe resection due to an unsatisfactory clinical response (PHD - FCD IIIA). We also had 2 patients with tuberous sclerosis (TS), in whom multiple tubers were verified by MAP07. In one patient MAP07 indicated additional 3 tubers (6 tubers in total). In another patient who had 5 tubers in total on CVA, only 3 tubers were found on MAP07.

In 10/120 patients, CVA showed HS (11.4%, $p = 0.046$). Automated FLAIR analysis of the hippocampus indicated HS in 11 patients, with a kappa coefficient of concordance of 0.843 ($p < 0.001$), whereas in one out of eleven patients only a marginal increase in FLAIR signal was found after analysis of 25% voxels of the highest FLAIR intensities. In this patient after CVA left-sided HS was detected, followed by selective amygdalohippocampectomy, with PHD finding of FCD IIIA. In two patients with bilateral HS on CVA, automated FLAIR analysis of the hippocampus indicated unilateral HS with a matching finding of electrophysiological processing (in one patient after implantation of sphenoidal electrodes). In both patients selective amygdalohippocampectomy was performed. PHD in one patient showed HS type I (patient had postoperatively rare, isolated auras) and in the other FCD type IIIA (FCD + HS).

4. Discussion

According to the results of randomized clinical studies, resective surgery is a superior method of treatment than pharmacotherapy alone in patients with pharmacoresistant focal epilepsy and therefore represents a treatment choice method [13,21]. However, the absence of an MRI detectable epileptogenic lesion is associated with worse outcomes after surgery. Thus, MRI+ patients have a 2-fold better outcome after surgery for epilepsy than MRI- patients [31-32]. ILAE published a new recommendation for the use of structural MRI in epilepsy patients in 2019 that defines protocol with high-resolution 3D T1-weighted, high-resolution 3D FLAIR, and high in-plane resolution 2D coronal T2-weighted MRI images. In the case of a suspected tumor, vascular malformation, or infectious process T1 MRI with gadolinium should be performed with T2* sequences sensitive for hemorrhage or iron deposits and calcification [15, 22]. Also, ILAE recommendations encourage the use of postprocessing methods [15, 22]. For most available methods, studies show concordance with the CVA and also ability to detect prior CVA- epileptogenic lesions (from 5-10% even to 70% in selected groups of patients), but there is no level I evidence from clinical trials and no real head-to-head comparisons between different methods [38].

MAP was introduced by Huppertz and al. in 2005 to improve the detection of FCD by three complementary feature maps depicting different neuroradiological characteristics of FCD. The method was further developed in the following years to achieve a better presentation of different MCD. Before the implementation of MAP07 certain education of using the MAP07 interface and reading feature maps is required, and creating a local database of healthy controls specific for each MRI device is encouraged. [28]. This data, with additional research, showed that morphometric MRI analysis of T1 post-processed images in combination with CVA is more sensitive than CVA alone [18,32]. The significance of MAP analysis in the detection of FCD in 150 MRI negative patients was described by Wang I.Z. et al., where MAP07 after epilepsy surgery showed preoperative structural changes in 65 patients (45% positive findings), with a specificity of 0.9 and a sensitivity of 0.67 [32-33]. In our group of patients CVA verified FCD in 14 patients, with concordant MAP07 analysis in 12/14 patients, but in 4 patients additional FCD was found (in total 18 FCD – Figure 2). Also, our results did not indicate the statistical advantage of any map in the detection of FCD, although literature data show better specificity and sensitivity of the junction and extension map [18,28,34].

Following the research of Pascher B. et al, an additional algorithm was implemented in MAP to more accurately detect PNH, with a specificity of 91.5% and sensitivity of 92.5% [24]. In our study MAP07 showed heterotopia in 8/11 patients with a high kappa coefficient of coincidence on the PNH map (0.829, $p < 0.001$). Our data for the PNH map correspond to the literature data for the detection threshold (z-score 6.6), and we also found multiple heterotopic nodules in most patients [24].

Following similar histopathological and neuroradiological findings of FCD type IIb and cortical tubers in TS, House PM et al. in 2015 showed the effectiveness of cortical tubers detection with MAP using T1 and T2 junction map. Respectively, MAP verified additional 23% of tubers that weren't noticed on CVA [36]. Detection of additional tubers may have an influence on differential diagnosis to FCD but also can guide decisions in further treatment or SEEG implantation [37]. Our two patients with TS were not operated and treatment with everolimus is being considered [39].

An automated quantitative FLAIR analysis of the hippocampus is included within the MAP07 (described by Focke NK et al. and HJ. Huppertz et al.) which defined a 95% confidence interval for detection of HS and the specificity of 95.4% [25,29-30]. In 10 out of 120 patients CVA showed HS (11.4%) but after MAP07 in 11 patients HS was diagnosed.

MAP07 analysis in our 120 patients showed high sensitivity (98.86%) and low specificity (15.62%) with a high proportion of false-positive patients. After initial MRI analysis, 32/120 patients were labeled as CVA-, in whom after MAP07 analysis in 5 patient lesions were found, in one HS, in one FCD, in two perinatal vascular lesions, and one hippocampal hyperintensity.

Literature data indicate a z-score threshold for the detection of structural changes on the junction map > 4 , for the extension map > 6 , and the thickness > 4 [34]. Our results show that MRI+ changes have a significantly higher z-score: median (interquartile range) 8.20 (7.00-11.08) versus 6.90 (6.30-8.00); $p < 0.001$. Furthermore, in a group of patients with z-score > 7.7 , we found the highest sensitivity (58.6%) and specificity (72.2%) with a statistically significant area below curves (AUC) of 0.711, $p < 0.001$.

As for the disadvantages of MAP07 itself, it should be noted that certain data automated preparation procedures (e.g. image intensity correction due to registration inequalities and tissue segmentation) can significantly affect the final result and must therefore be analyzed in detail. MAP07, as well as other automated methods, has some false-positive findings, but on the other hand, in 3-35% of cases, CVA can detect lesions that are missed by post-processing [38]. There is no perfect postprocessing method. This disadvantage, as in our case, of a high number of false-positive findings, requires additional reevaluation by a neuroradiologist and is time-consuming.

In the last years, MAP07 was further developed to MAP18 to decrease false-positive findings. Probably, if reevaluating our patients with the updated program, this number of false-positive findings would be lower. Also, increasing the threshold of z-score would reduce the number of false-positives, but this can result in some missed cases. Furthermore, in the context of preoperative treatment and focus hypothesis, it is important to emphasize that MAP07 results highlight structural changes, that should be interpreted by clinical seizure semiology and electrophysiological findings (clinico-electrophysiological-radiological correlation). Different structural lesions included in our study, besides FCD, HS, and PHN (e.g. perinatal ischemia/vascular lesions, lobar atrophy, gliosis, etc.) are also important. Although they do not represent typical substrates for resective epilepsy surgery they can cause PE.

The main benefit of MAP is fully automated detection of FCD, HS, heterotopias, and other types of MCD. Preparation of data and analysis last for 45-60 minutes, with additional reevaluation performed by a neuroradiologist for 15 minutes.

The limitations of our research are a small sample for adequate analysis of certain subgroups of structural changes, and a small number of patients who ultimately underwent resective neurosurgery with PHD analysis. Thus, subtle changes found on CVA or MAP07 could not be confirmed as a true lesion without histopathological analysis. Some patients refused preoperative invasive evaluation, and some were not suitable candidates (e.g. lesion in eloquent cortex, multiple or dual pathology, additional neurological or psychiatric comorbidities.). Others achieved satisfactory seizure control with further correction of antiepileptic therapy. VNS was implanted in 10 patients and therefore we do not have a PHD diagnosis.

Furthermore, only one postprocessing method (MAP07) has been done in patients and we do not have a head-to-head comparison of MAP07 with other post-processing methods. Additional research is required to compare different postprocessing methods across a larger number of patients, or even comparing different modalities of imaging (functional MRI, PET) with EEG (electroencephalography) data. Although MAP07 represents a series of automated MATLAB scripts, re-analysis is ultimately a subjective process. This indicates the possibility of "re-reading" changes designated by MAP07, to find an adequate correlation between clinical imaging, neuroradiology, and electrophysiology processing. Thus, a multidisciplinary approach to epilepsy patient is required, which starts with epilepsy specific MRI protocol, followed by analysis from experienced neuroradiologist and, if necessary, additional image postprocessing, such as MAP07, can be performed.

5. Conclusion

MAP07 analysis is a useful method that may guide additional re-evaluation of MRI by highlighting suspicious cortical regions and may direct the "second" look of the neuroradiologist and thus increase the sensitivity of the MRI scan itself. MAP07 is a practical and useful tool, that uses images already acquired by MRI of patients with pharmaco-resistant epilepsy.

MRI postprocessing, using the MAP07 program, should be understood as a complementary method to conventional visual MRI analysis that enhances the visualization of malformation of cortical development. Additional analysis with larger groups of patients and comparison with other postprocessing methods are still required.

6. References:

1. Fisher RS, Acevedo C, Arzimanoglou A, Bogacz A, Cross JH, Elger CE, et al. ILAE OFFICIAL REPORT A practical clinical definition of epilepsy. 2014;475–82.
2. Berg AT, Berkovic SF, Brodie MJ, Buchhalter J, Cross JH, Van Emde Boas W, et al. Revised terminology and concepts for organization of seizures and epilepsies: Report of the ILAE Commission on Classification and Terminology, 2005-2009. *Epilepsia*. 2010;51(4):676–85.
3. Petelin Gadze Z, Poljakovic Z, Nankovic S, Sulentic V. *Epilepsija dijagnostički i terapijski pristup*. 2019th ed. Zagreb: Medicinska naklada; 2019. 1–326 p.
4. Bill F, Foundation MG. Global , regional , and national burden of epilepsy , 1990 – 2016 : a systematic analysis for the Global Burden of Disease Study 2016. 2019;
5. Fiest KM, Sauro KM, Wiebe S, Patten SB, Dykeman J, Pringsheim T, et al. Prevalence and incidence of epilepsy A systematic review and meta-analysis of international studies. 2017;
6. Stafstorm CE, Carmant L. Seizures and epilepsy: An overview. *Cold Spring Harb Perspect Med*. 2015;1–18.
7. Kwan P, Arzimanoglou A, Berg AT, Brodie MJ, Hauser WA, Mathern G, et al. Definition of drug resistant epilepsy: Consensus proposal by the ad hoc Task Force of the ILAE Commission on Therapeutic Strategies. *Epilepsia*. 2010;51(6):1069–77.
8. Janmohamed M, Brodie MJ, Kwan P. Pharmacoresistance – Epidemiology, mechanisms, and impact on epilepsy treatment. *Neuropharmacology*. 2019;
9. Rathore C, Radhakrishnan K. Seminar in epileptology: Concept of epilepsy surgery and presurgical evaluation. *Epileptic Disord*. 2015;17(1):19–31.
10. Ryvlin P, Rheims S. Epilepsy surgery: Eligibility criteria and presurgical evaluation. *Dialogues Clin Neurosci*. 2008;10(1):91–103.
11. Petelin Ž, Hajnšek S, Wellmer J, Mrak G, Radoš M, Paladino J. Smjernice u preoperativnoj dijagnostičkoj obradi bolesnika s farmakorezistentnom epilepsijom. *Neurol Croat*. 2010;59(1–2):23–34.
12. Jehi L. The epileptogenic zone: Concept and definition. *Epilepsy Curr*. 2018;18(1):12–6.
13. West S, Nolan S, Cotton J, Gandhi S, Weston J, Sudan A, et al. Surgery for epilepsy (Review). *Cochrane Database Syst Rev*. 2015;(3).
14. Radhakrishnan K, So EL, Silbert PL, Jack CR, Cascino GD, Sharbrough FW, et al. Predictors of outcome of anterior temporal lobectomy for intractable epilepsy: A multivariate study. *Neurology*. 1998;51(2):465–71.
15. Berkovic SF, Mc Intosh AM, Kalnins RM, Jackson GD, Fabinyi GCA, Brazenor GA, et al. Preoperative MRI predicts outcome of temporal lobectomy: An actuarial analysis. *Neurology*. 1995;45(7):1358–63.
16. Kim DW, Kim S, Park SH, Chung CK, Lee SK. Comparison of MRI features and surgical outcome among the

- subtypes of focal cortical dysplasia. *Seizure* [Internet]. 2012;21(10):789–94. Available from: <http://dx.doi.org/10.1016/j.seizure.2012.09.006>
17. Chassoux F, Landré E, Mellerio C, Turak B, Mann MW, Dumas-Duport C, et al. Type II focal cortical dysplasia: Electroclinical phenotype and surgical outcome related to imaging. *Epilepsia*. 2012;53(2):349–58.
 18. Wagner J, Weber B, Urbach H, Elger CE, Huppertz HJ. Morphometric MRI analysis improves detection of focal cortical dysplasia type II. *Brain*. 2011;134(10):2844–54.
 19. Von Oertzen J, Urbach H, Jungbluth S, Kurthen M, Reuber M, Fernández G, et al. Standard magnetic resonance imaging is inadequate for patients with refractory focal epilepsy. *J Neurol Neurosurg Psychiatry*. 2002;73(6):643–7.
 20. Winston GP, Micallef C, Kendell BE, Bartlett PA, Williams EJ, Burdett JL, et al. The value of repeat neuroimaging for epilepsy at a tertiary referral centre: 16 years of experience. *Epilepsy Res* [Internet]. 2013;105(3):349–55. Available from: <http://dx.doi.org/10.1016/j.eplepsyres.2013.02.022>
 21. West S, Nolan SJ, Newton R. Surgery for epilepsy: A systematic review of current evidence. *Epileptic Disord*. 2016;18(2):113–21.
 22. Bernasconi A, Cendes F, Theodore WH, Gill RS, Koepp MJ, Hogan RE, et al. Recommendations for the use of structural magnetic resonance imaging in the care of patients with epilepsy: A consensus report from the International League Against Epilepsy Neuroimaging Task Force. *Epilepsia*. 2019;60(6):1054–68.
 23. Huppertz HJ. Morphometric MRI Analysis. In: Urbach H, editor. *MRI in Epilepsy*. Berlin: Springer-Verlag; 2013. p. 73–84.
 24. Huppertz HJ, Wellmer J, Staack A, Altenmüller D, Urbach H, Kröll J. Voxel-based 3D MRI analysis helps to detect subtle forms of subcortical band heterotopia. *Epilepsia*. 2008;49(5):772–85.
 25. Pascher B, Kroell J, Mothersill I, Kraemer G, Huppertz HJ. Automated morphometric magnetic resonance imaging analysis for the detection of periventricular nodular heterotopia. *Epilepsia*. 2013;d(2):305–13.
 26. Huppertz HJ, Wagner J, Weber B, House P, Urbach H. Automated quantitative FLAIR analysis in hippocampal sclerosis. *Epilepsy Res*. 2011;97(1–2):146–56.
 27. Huppertz HJ, Kassubek J, Altenmüller DM, Breyer T, Fauser S. Automatic curvilinear reformatting of three-dimensional MRI data of the cerebral cortex. *Neuroimage*. 2008;39(1):80–6.
 28. Huppertz HJ, Grimm C, Fauser S, Kassubek J, Mader I, Hochmuth A, et al. Enhanced visualization of blurred gray-white matter junctions in focal cortical dysplasia by voxel-based 3D MRI analysis. *Epilepsy Res*. 2005;67(1–2):35–50.
 29. Focke NK, Symms MR, Burdett JL, Duncan JS. Voxel-based analysis of whole brain FLAIR at 3T detects focal cortical dysplasia. *Epilepsia*. 2008;49(5):786–93.

30. Focke NK, Bonelli SB, Yogarajah M, Scott C, Symms MR, Duncan JS. Automated normalized FLAIR imaging in MRI-negative patients with refractory focal epilepsy. *Epilepsia*. 2009;50(6):1484–90.
31. Blümcke I, Thom M, Aronica E, Armstrong DD, Vinters H V., Palmini A, et al. The clinicopathologic spectrum of focal cortical dysplasias: A consensus classification proposed by an ad hoc Task Force of the ILAE Diagnostic Methods Commission. *Epilepsia*. 2011;52(1):158–74.
32. Najm IM, Sarnat HB BI. Review: The international consensus classification of Focal Cortical Dysplasia - a critical update 2018. *Neuropathol Appl Neurobiol*. 2018;44(1):18–31.
33. Téllez-Zenteno JF, Ronquillo LH, Moien-Afshari F, Wiebe S. Surgical outcomes in lesional and non-lesional epilepsy: A systematic review and meta-analysis. *Epilepsy Res*. 2010;89(2–3):310–8.
34. Wang ZI, Jones SE, Jaisani Z, Najm IM, Prayson RA, Burgess RC, et al. Voxel-Based Morphometric Magnetic Resonance Imaging (MRI) Postprocessing in MRI-Negative Epilepsies. *Ann Neurol*. 2015;77(6):1060–75.
35. Wang ZI, Jones SE, Ristic AJ, Wong C, Kakisaka Y, Jin K, et al. Voxel-based morphometric MRI post-processing in MRI-negative focal cortical dysplasia followed by simultaneously recorded MEG and stereo-EEG. *Epilepsy Res [Internet]*. 2012;100(1–2):188–93. Available from: <http://dx.doi.org/10.1016/j.epilepsyres.2012.02.011>
36. House PM, Holst B, Lindenau M, Voges B, Kohl B, Martens T, et al. Morphometric MRI analysis enhances visualization of cortical tubers in tuberous sclerosis. *Epilepsy Res [Internet]*. 2015;117:29–34. Available from: <http://dx.doi.org/10.1016/j.epilepsyres.2015.08.002>
37. Gallagher A, Chu-Shore CJ, Montenegro MA, Major P, Costello DJ, Lyczkowski DA, et al. Associations between electroencephalographic and magnetic resonance imaging findings in tuberous sclerosis complex. *Epilepsy Res*. 2009;87(2–3):197–202.
- Martin P, Bender B, Focke NK. Post-processing of structural MRI for individualized diagnostics. *Quant Imaging Med Surg*. 2015;5(2):188-203. doi:10.3978/j.issn.2223-4292.2015.01.10
39. Franz DN, Lawson JA, Yapici Z, Ikeda H, Polster T, Nabbout R et al. Everolimus for treatment-refractory seizures in TSC Extension of a randomized controlled trial. *Neurol Clin Pract* 2018, 8 (5) 412-420; DOI: 10.1212/CPJ.0000000000000051

Declaration

CRedit author statement:

Andreja Bujan Kovač: Conceptualization; Data curation; Formal analysis; Investigation; Methodology; Project administration; Resources; Visualization; Writing - original draft; Writing - review & editing

Željka Petelin Gadže: Conceptualization; Methodology; Data curation; Project administration; Resources; Supervision; Validation; Visualization; Writing - original draft; Writing - review & editing

Milan Radoš: Data curation; Formal analysis; Investigation; Methodology; Project administration; Resources; Supervision; Visualization; Writing - original draft; Writing - review & editing

Magdalena Krbot Skorić: Data curation; Formal analysis; Investigation; Methodology; Resources; Software; Validation; Visualization; Writing - original draft; Writing - review & editing

Goran Mrak: Data curation; Resources; Formal analysis; Visualization; Writing - original draft; Writing - review & editing

Jakob Nemir: Data curation; Formal analysis; Resources; Visualization; Writing - original draft; Writing - review & editing

Milan Milosevic: Formal analysis; Software; Validation; Visualization; Writing - original draft; Writing - review & editing

Sanja Hajnšek: Conceptualization; Methodology; Project administration; Supervision; Writing - original draft; Writing - review & editing

All authors approved the final version of this paper for publication.

Conflict of interest

The authors state no conflict of interest.

Ethical approval

All procedures performed in studies involving human participants were in accordance with the ethical standards of the institutional and/or national research committee and approved by the Ethics Committee of the University Hospital Centre Zagreb, School of Medicine of the University of Zagreb and Croatian Institute for Brain Research and Polyclinic Neuron. Study was performed in accordance with the 1964 Helsinki declaration and its later amendments or comparable ethical standards.

Consent to participate

Informed consent was obtained from all individual participants included in the study.

Acknowledgements

The authors acknowledge Professor Hans-Jürgen Huppertz for his support in implementing the Morphometric Analysis Program (MAP07) in the Referral Centre of the Ministry of Health of the Republic of Croatia for Epilepsy and University Hospital Centre Zagreb.

The authors would also like to thank our colleagues Sibila Nankovic, Vlatko Sulentic, Ivana Cajic, Zdravka Poljakovic, Petra Nimac Kozina, Biljana Dapic Ivancic, Boris Radic, Marko Rados, David Ozretic, Ivan Jovanovic and Andrej Desnica for their help in treating epilepsy patients and data collection.

Highlights

- Some types of malformation of cortical development may not be easily detected by conventional visual MRI analysis (CVA)
- MAP07 program is a sophisticated diagnostic program that offers several morphometric maps and facilitates the detection and localization of hippocampal sclerosis, focal cortical dysplasias and other types of cortical malformations
- MAP07 program may be used as a complementary method to CVA and may guide additional re-evaluation of MRI by highlighting suspicious cortical regions and thus increase the sensitivity of the MRI scan itself

List of figures and tables

Figure 1. Flowchart representing data acquisition and analysis

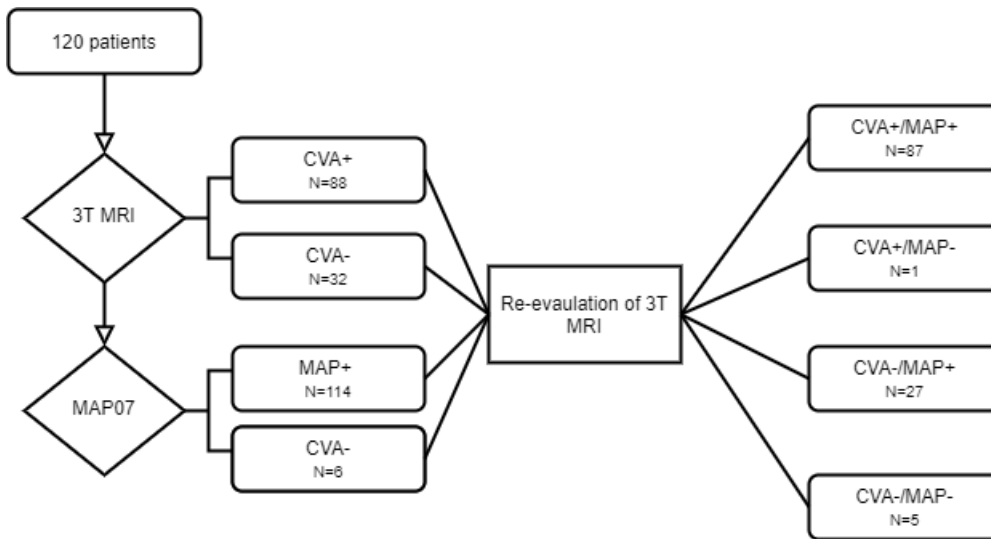
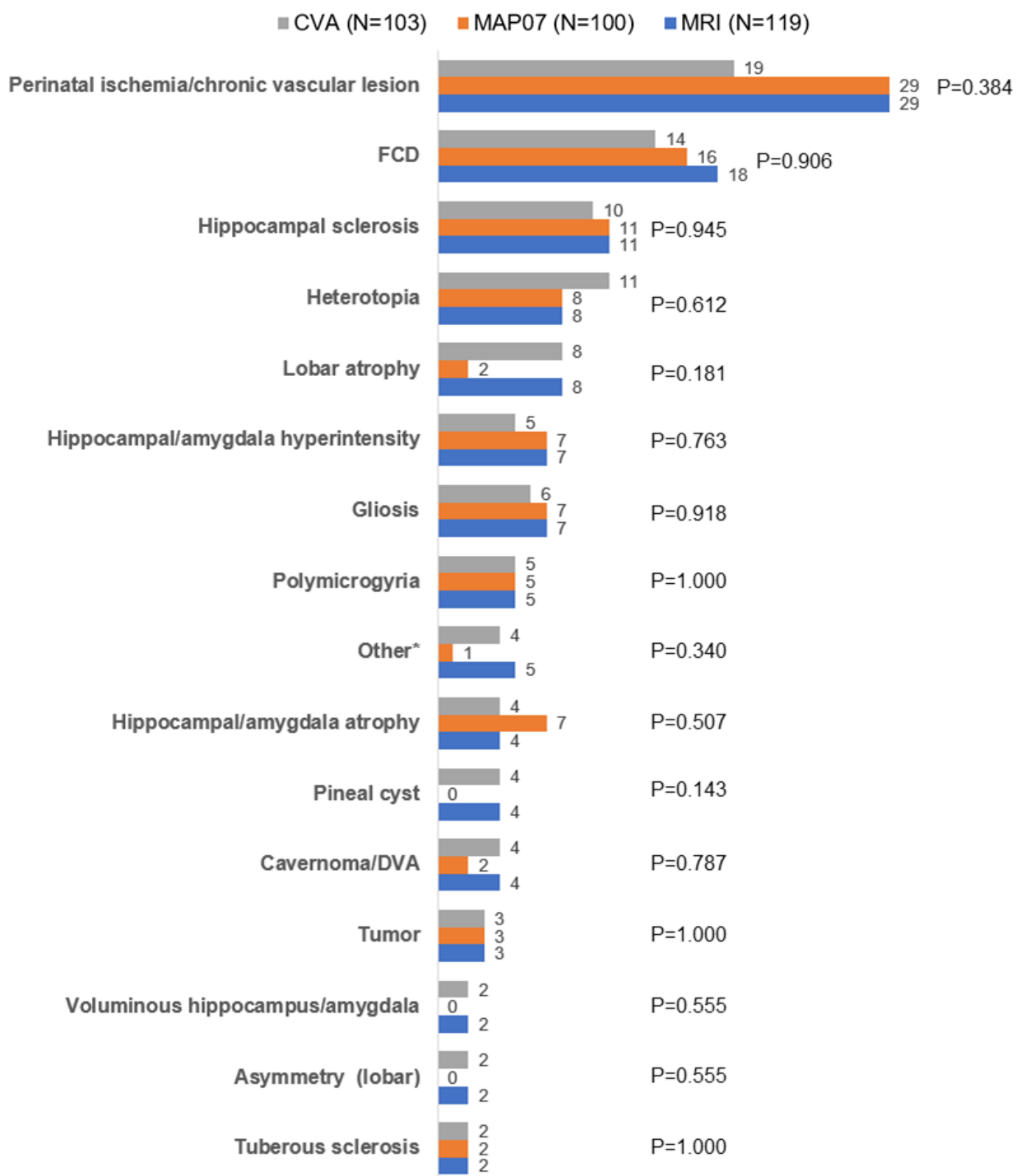


Figure 2. The difference in frequencies of CVA, MAP07 and re-evaluated MRI positive findings of different lesions in our group of patients: Fisher-Friedman-Halton's exact test



*Other: Hygroma, Postencephalitic changes, Encephalocela, Demyelination

FCD – focal cortical dysplasia, DVA – developmentat venous anomaly

Table 1. Relationship of certain maps available by MAP07 analysis in the detection of various malformations of cortical development and their localization on total number of 120 patients: Kendall's Tau-b correlation coefficient

		FCD	PMG	Perinatal ischemia/ chronic vascular lesion	Heterotopy	HS	Hippocampal/ amygdala hyperintensity
combined z score	Tau_b	0.013	0.057	0.167	0.027	-0.052	0.082
	P	0.875	0.472	0.036	0.740	0.516	0.302
	N	120	120	120	120	120	120
junction	Tau_b	0.043	0.103	0.158	0.121	0.011	0.032
	P	0.605	0.212	0.054	0.141	0.895	0.695
	N	120	120	120	120	120	120
thickness	Tau_b	0.017	0.258	-0.061	0.086	-0.090	-0.099
	P	0.845	0.004	0.493	0.331	0.308	0.263
	N	120	120	120	120	120	120
extension	Tau_b	0.135	0.217	-0.014	0.375	-0.035	-0.133
	P	0.125	0.013	0.871	<0.001	0.694	0.129
	N	120	120	120	120	120	120
FLAIR z score	Tau_b	0.039	0.071	-0.034	-0.055	0.213	0.118
	P	0.649	0.401	0.689	0.515	0.012	0.164
	N	120	120	120	120	120	120
PNH z score	Tau_b	-0.029	0.079	0.102	0.299	-0.094	-0.065
	P	0.744	0.379	0.260	0.001	0.297	0.471
	N	120	120	120	120	120	120

FCD - Focal cortical dysplasia; PMG – Polymicrogyria; HS: Hippocampal sclerosis

Figure 3. Box and Whisker's Z-score plot of positive MRI findings in detecting individual changes

