

Assessment of acute abdomen in the emergency department

Csenar, Mario Luka

Master's thesis / Diplomski rad

2015

Degree Grantor / Ustanova koja je dodijelila akademski / stručni stupanj: **University of Zagreb, School of Medicine / Sveučilište u Zagrebu, Medicinski fakultet**

Permanent link / Trajna poveznica: <https://um.nsk.hr/um:nbn:hr:105:916383>

Rights / Prava: [In copyright](#) / [Zaštićeno autorskim pravom.](#)

Download date / Datum preuzimanja: **2024-08-05**



Repository / Repozitorij:

[Dr Med - University of Zagreb School of Medicine Digital Repository](#)



**UNIVERSITY OF ZAGREB
SCHOOL OF MEDICINE**

Mario Luka Csenar

**Assessment of Acute Abdomen
in the Emergency Department**

GRADUATE THESIS



Zagreb, 2015

This graduate thesis was made at the Department of Internal Medicine,
Sisters of Charity University Hospital Centre, Zagreb, Croatia,
mentored by professor Vesna Degoricija, MD, PhD,
and was submitted for evaluation in academic year 2014/2015.

Abbreviations

ED – Emergency department

SAGES – Society of America

OPTIMA – Optimization of diagnostic imaging use in patients with acute abdominal pain

OMGE – World organization of gastroenterology

MRI – Magnetic resonance imaging

CT – Computed tomography

US – Ultrasonography

AXR – Abdominal X-ray

SOAP – subjective, objective, assessment, plan

AAA – Abdominal aortic aneurysm

VAS – visual analogue scale

CBC – Complete blood count

WBC – White blood cells

RBC – Red blood cells

CRP – C-reactive protein

BUN – Blood urea nitrogen

CVD – Cardiovascular disease

Contents

Summary

| | |
|---|----|
| 1. Introduction..... | 1 |
| 2. Definition | 2 |
| 3. Epidemiology and Aetiology | 2 |
| 4. Workflow | 5 |
| 5. Clinical evaluation | 7 |
| 5.1. Patient history | 7 |
| 5.2. Physical examination | 14 |
| 5.3. Digital rectal examination..... | 16 |
| 5.4. Special examination manœuvres..... | 17 |
| 6. Analgesia..... | 18 |
| 7. Investigative studies..... | 19 |
| 7.1. Laboratory tests..... | 19 |
| 7.2. Imaging | 22 |
| 7.2.1. X-ray..... | 22 |
| 7.2.2. Ultrasound | 23 |
| 7.2.3. CT | 23 |
| 7.2.4. CT-angiography..... | 24 |
| 7.2.5. Endoscopy | 24 |
| 7.2.6. MRI..... | 24 |
| 7.3. Choice of imaging modality..... | 25 |
| 8. Management..... | 26 |
| 8.1. Invasive diagnostics | 27 |
| 9. Conclusion | 28 |
| 10. References..... | 29 |
| 11. Biography..... | 32 |

Assessment of Acute Abdomen in the Emergency Department

Mario Luka Csenar

Summary:

Acute abdominal pain is one of the most commonly encountered leading symptoms in the emergency department. Although it is oftentimes held for a purely surgical problem, two thirds of patients do not require operative management. The causative pathologies of the acute abdomen range from intra-abdominal to extra-abdominal and metabolic diseases. Therefore a multi-disciplinary approach is imperative and early consultation is key in order not to unnecessarily delay treatment.

Clinical experience is equally as important as a sound knowledge of the anatomy and physiology of the abdominal cavity and an understanding of the pathophysiological processes at work. This knowledge should be applied whilst taking a history and performing the physical examination.

Investigative studies are indispensable in the evaluation of the acute abdomen, especially since at least one third of patients presents with atypical features. Thereby the age of the patient plays an important role. Elderly patients may present with signs and symptoms unimpressive to the untrained eye, yet harbouring a serious pathology. Laboratory tests by themselves are not enough to assess the patient, so radiological studies have to be a deeply rooted part of the patient evaluation.

With ultrasonography, plain abdominal films, computed tomography, CT-angiography and magnetic resonance imaging a broad array of imaging modalities, are at the ED physician's disposal. In choosing a modality the diagnostic yield of such a procedure should be weighed against the risk of radiation exposure.

The severity of aetiologies ranges from benign self-limiting to life-threatening. Hence the main focus of the ED physician should be to triage the patient accordingly and discern whether immediate or urgent surgical intervention is necessary. Thereby a priority- and problem oriented strategy should be pursued. In order to prevent diagnostic errors and improve patient care, diagnostic algorithms and patient evaluation forms should be used.

Key terms:

acute abdomen, acute abdominal pain, clinical algorithm, diagnostic modalities

1. Introduction

*who stands rigid and hard
hardly moving like a queen's guard
not even upon her tender loving touch
inasmuch as such would make him flinch
and thus move an inch*

Mario Csenar, 2014
Acute Peritonitis

Much as this little riddle, the assessment of the acute abdomen represents one of the most formidable diagnostic challenges encountered by the emergency department (ED) physician.

The clinician must work through a long list of differential diagnoses, ranging from benign self-limited to life-threatening conditions. Pressed for time, step by step, from triage to treatment, important choices have to be made.

- Is the patient's life at imminent danger?
- Does he/she require surgical or non-surgical treatment?
- Is there an indication for emergent or urgent surgery?
- Should the patient receive analgesic medication?
- Which diagnostic modality should be chosen?
- Is there a need for a consultation?

2. Definition

The acute abdominal pain is defined as a pain that arises suddenly and is of less than a week's and in most cases less than 48 hours' duration [1, 2]. The term acute abdomen defines a graver presentation of abdominal pain, accompanied by guarding and muscular rigidity, which essentially describes the clinical picture of peritonitis and usually calls for an emergency operation [3]. This led to the common misconception that the acute abdomen is synonymous with the surgical abdomen. However, not all cases of acute abdomen are best treated with surgery. In literature as well as in clinical practice the borders between the acute abdominal pain and acute abdomen overlap and are used interchangeably.

While in German medical literature, the term acute abdomen encompasses all cases of acute abdominal pain [3], in English medical literature it is vice versa, with the acute abdomen being subsumed under acute abdominal pain [4].

I would like to refer to *Cope's Early Diagnosis of the Acute Abdomen* (Silen 2010) saying that "... physicians are 'not impressed' by a patient's abdominal pain or physical findings. The failure to impress reflects the erroneous idea that an 'acute abdomen' is so catastrophic that the patient must complain of severe pain and have board-like rigidity of the abdomen." As for me, it would be necessary to norm these terms in order to eliminate confusion.

3. Epidemiology and Aetiology

The acute abdomen is with 5-10% one of the most common reasons for a visit to the emergency department [5, 6, 7]. It represents the most common surgical emergency, the most frequent cause for the consultation of a surgeon in the emergency department and the most common cause for non-trauma related hospital admissions [5]. The causative pathologies of the acute abdomen range from intra-abdominal to extra-abdominal and metabolic diseases (*see Table 1*). The most frequent diagnosis made is with 34% that of a non-specific or undifferentiated abdominal pain (*see Table 2*) [3, 5, 8, 9, 10]. Of the remaining 66% three-quarters are diagnosed as either acute appendicitis, small bowel obstruction or are ascribed to gynaecological causes [5, 9]. Age differences play a crucial role and are important to be considered when assessing the acute abdomen, seeing as with age not only the incidence of certain pathologies changes but also the clinical presentation varies

[10]. The World Organization of Gastroenterology's (OMGE) epidemiological survey [9], with a sample of more than 10000 patients the most representative epidemiological study on abdominal pain so far places 50 years of age as a threshold to differentiate younger from older patients with acute abdomen (*see Table 3*) [5, 8]. According to those results there is a significant increase in organic causes of acute abdominal pain in the older population [8]. Comparing the < 50 years and > 50 years age groups one finds that especially vascular and oncologic abdominal pain aetiologies increase in frequency and gain in significance. The older the patient, the more important it is to "think vascular" and to "think cancer" [8, 10]. Biliary tract disorders, like cholecystitis with 21% become the most frequent cause of acute abdomen in the older age group [8, 9, 10]. In the > 75 year olds the "leaderboard" is again headed by non-specific abdominal pain [9, 3, 8, 10]. Partly responsible for that might be that elderly patients present with nonspecific symptoms more often and the clinical assessment oftentimes poses a challenge for the physician due to altered mentation from fever, electrolyte abnormalities, dementia and other co-morbidities [10]. With that in mind, the job of the emergency physician, namely to rapidly identify whether the underlying cause requires an urgent or even immediate surgical or medical intervention [5] does not get any easier. Especially so, as the lethality of the acute abdomen increases with the age of the patient, lying at 10% in the > 80 year olds, meaning that there is less tolerance for initial diagnostic falsities [8].

Table 2: The 10 common aetiologies of acute abdominal pain. Modified according to de Dombal 1988 [9].

| OMGE-study (n=10 320) | Prevalence (%) |
|----------------------------|----------------|
| Nonspecific abdominal pain | 34,0 |
| Acute appendicitis | 28,1 |
| Acute cholecystitis | 9,7 |
| Bowel obstruction | 4,1 |
| Gynaecological pathologies | 4,0 |
| Acute pancreatitis | 2,9 |
| Renal colic | 2,9 |
| (perforated) peptic ulcer | 2,5 |
| Cancer | 1,5 |
| Diverticulitis | 1,5 |

Table 3: Age-dependent prevalence of acute abdominal pain aetiologies Modified according to de Dombal 1988 [9].

| Cause of acute abdomen | Prevalence (%) | |
|----------------------------|----------------|------------|
| | < 50 years | > 50 years |
| Nonspecific abdominal pain | 40 | 16 |
| Acute appendicitis | 32 | 15 |
| Acute cholecystitis | 6 | 21 |
| Bowel obstruction | 3 | 12 |
| Acute pancreatitis | 2 | 7 |
| Diverticulitis | < 0,1 | 6 |
| Cancer | < 0,1 | 4 |
| Hernia | < 0,1 | 3 |
| Vascular disease | < 0,1 | 2 |

Table 1: Causes of acute abdominal pain.

Modified according to Soybel et al. 2006 [1] and Lankisch et al. 2006 [8].

| Abdominal Causes: |
|---|
| <p><i>Inflammatory:</i></p> <ul style="list-style-type: none">• Peritoneal:<ul style="list-style-type: none">- Bacterial peritonitis: e.g. perforated hollow viscus, spontaneous bacterial peritonitis- Chemical and nonbacterial peritonitis: e.g. perforated peptic ulcer, pancreatitis, mittelschmerz• Hollow visceral: e.g. appendicitis, cholecystitis, diverticulitis, peptic ulcer, gastroenteritis• Solid visceral: e.g. pancreatitis, hepatitis, splenic abscess• Mesenteric: e.g. lymphadenitis• Pelvic: e.g. pelvic inflammatory disease, endometriosis <p><i>Mechanical (obstruction, acute distention):</i></p> <ul style="list-style-type: none">• Hollow visceral: e.g. acute intestinal obstruction, choledocholithiasis, (ureterolithiasis)• Solid visceral: e.g. acute splenomegaly, acute hepatomegaly)• (Ogilvie-syndrome) <p><i>Hemoperitoneum:</i> due to ruptured viscera – e.g. AAA, spleen, liver; ruptured graafian follicle, ruptured ectopic pregnancy</p> <p><i>Vascular:</i></p> <ul style="list-style-type: none">• Thrombosis or embolism• Dissecting aortic aneurysm• Sickle cell anaemia• Rectus sheath hematoma <p><i>Abdominal trauma</i></p> |
| Extra-abdominal Causes: |
| <ul style="list-style-type: none">• Cardiothoracic: e.g. pleuropneumonia, pulmonary embolism, myocardial infarction• Genitourinary: e.g. testicular torsion, cystitis, pyelonephritis, nephrolithiasis, dysmenorrhea• Neurogenic: e.g. herpes zoster |
| Metabolic Disorders: |
| <p><i>Exogenic Causes:</i> e.g. lead poisoning, mushroom poisoning</p> <p><i>Endogenic Causes:</i></p> <ul style="list-style-type: none">• Uremia• Diabetic ketoacidosis• Acute intermittent porphyria• Addisonian crisis• Hemolytic crises• Familial Mediterranean fever• Hyperparathyroidism (hypercalcemia) |

4. Workflow

Acute abdominal pain is one of the most diagnostically challenging presenting symptoms encountered by the ED physician. A long list of possible differential diagnoses which range from intra-abdominal to extra-abdominal as well as metabolic derangements must be taken into consideration and treated according to severity and urgency [8]. In order to improve the diagnostic accuracy and the triage of the patient into emergent, urgent and non-urgent, the use of standardized forms for the clinical evaluation and the use of work-up algorithms have proven worthwhile [1, 5]. The utilisation of these helping tools is aimed at improving patient care and decreasing diagnostic errors. One often employed, repeatedly cited and modified standardized form is the abdominal pain chart developed by the OMGE [1, 5]. Following work-up protocols enables an evidence-based problem and priority oriented approach to acute abdominal pain and allows for young yet inexperienced physicians to make sound and reproducible decisions regarding the diagnostic evaluation and treatment plan [5].

The patient work-up should follow the renowned SOAP (subjective - objective - assessment - plan) scheme and guide the physician through the patient evaluation and management.

An interdisciplinary approach is of great importance in the assessment of acute abdominal pain. Although the acute abdomen is oftentimes viewed as a surgical problem, a surgical intervention is needed only in 1/3 of cases [1, 5]. Nevertheless the need for a surgical consult or intervention should be evaluated early in the course of the patient assessment in order to prevent unnecessary delays.

Most clinical workflow algorithms available [3, 7, 1] concentrate on the logical sequence of individual decision-making processes but do not take into consideration the patient's general state when suggesting a management model [5]. Trentzsch et al. [5] created an algorithm with the goal in mind to provide a time-critical and multidisciplinary approach to the acute abdomen, not only distinguishing between medical and surgical treatment but also giving advice about the necessity to ask for urological or gynaecological consults (*see Figure 1*).

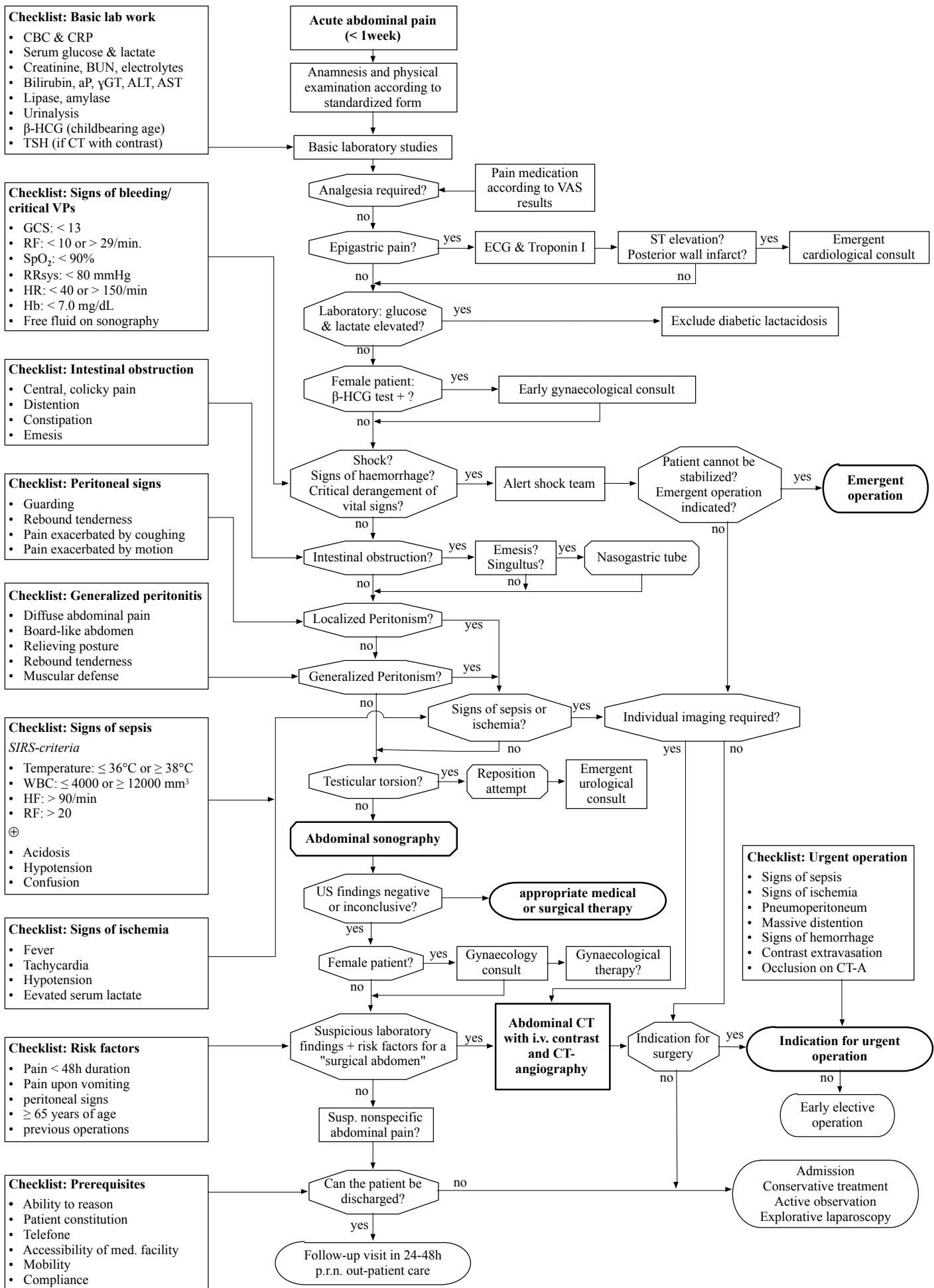


Figure 1: Clinical algorithm for the workflow in acute abdominal pain in adults. Modified according to Trentzsch et al. 2011 [5].

5. Clinical Evaluation

The most important tools aiding in the evaluation of the acute abdomen are a detailed patient history and an accurate physical examination [1, 5, 11]. In some circumstances, as in the case of a typical presentation of acute appendicitis or an incarcerated hernia, the diagnosis can be made even without the help of imaging modalities [1, 5, 11]. Solely by means of the clinical evaluation the correct diagnosis can be ascertained with a sensitivity of 88% and a specificity of 41% [5]. Although in most cases this is not enough to make a safe diagnosis, which makes further laboratory and imaging studies indispensable, the importance of this step in the assessment of the acute abdomen should not be underestimated. Patient history and physical examination findings should build on sufficient clinical experience and a detailed knowledge of the anatomy and physiology of the abdominal cavity and a clear conception of the pathological processes at work [5, 11]. Unfortunately though, when the ability of clinicians to take an organized and accurate history has been studied, the results have been rather disappointing, which is why the use of standardized history and physical examination forms has been recommended and yielded an improvement of the diagnostic accuracy by 20% [1, 5].

5.1. Patient history

The leading symptom of the acute abdomen is pain. It is imperative to inquire about the dimensions of pain, which are summarized under the mnemonic acronym SOCRATES, helping to ensure a thorough history. Much as its name giver's methods of questioning should the patient history be conducted, with systematicity and a critical mind.

- **Site:** Location of pain
- **Onset:** Exact time and mode of onset – sudden or gradual? Setting – what was the patient doing when the pain first started? Is it progressive or regressive?
- **Character:** Localized or diffuse? Dull or sharp?
- **Radiation or referral of pain?**
- **Associated Symptoms:** Jaundice? Anorexia, nausea and/or vomiting? Diarrhoea/Constipation? Pyrosis and/or singultus? Genitourinary symptoms – dysuria, pollakisuria, hematuria?
- **Time course:** Is the pain continuous or intermittent in nature? Does it follow a pattern?
- **Exacerbating/Relieving factors:** Are there palliating or provoking factors – breathing, coughing, food intake, defecation, vomiting?
- **Severity:** from 1-10 on the visual analogue scale (VAS)

Site: Pain location

Based on the type of afferent nerve innervation three basic patterns of pain perception can be differentiated: Visceral pain, somatic pain and referred pain [5].

- Visceral pain:

Visceral pain results from stretching or distention of the intestine or excessive contraction against resistance [1, 5, 11]. Touch or inflammation, as long as they do not irritate the parietal peritoneum do not lead to a pain perception [11]. Visceral nociceptive stimuli are conducted to the brain via C-fibres, which means that the pain elicited will generally be perceived as dull in character [5, 6, 8]. Due to the fact that the innervation of abdominal organs is arranged bilaterally, the pain is oftentimes referred to the midline, but is mostly of poor localization [5, 6, 8, 11]. The localization of visceral pain is predetermined by the embryological development of the gut. Pain from foregut structures (proximal to the ligament of Treitz), including the stomach, pancreas, hepatobiliary system and proximal duodenum, will be typically localized to the epigastrium. Pain arising from midgut structures (ligament of Treitz to the right colonic flexure), that receive the blood supply from the superior mesenteric artery – small bowel and proximal third of the colon including the appendix – is perceived in the periumbilical area. Hindgut structures (distal to the right colonic flexure) – bladder, distal two-thirds of the colon and pelvic genitourinary structures cause pain in the suprapubic region. Pain from retroperitoneal structures like the aorta or kidneys is usually referred to the back [6].

- Somatic (parietal) pain:

Somatic pain originates from irritation or inflammation of the peritoneum parietale, mesenterium, mesocolon or retroperitoneum and is of a sharp, stabbing character [8]. Patients can discern its localization much better than visceral pain, because in somatic pain the painful stimulus is conducted via A-delta-fibres, which are unilaterally arranged and can therefore be better lateralised by the patient [5].

Visceral pain, as demonstrated by the case of acute appendicitis can change over to somatic pain [8]. In acute appendicitis, typically the pain starts as a poorly localized periumbilical pain, which as the inflammation progresses, irritating the peritoneum, shifts to the right lower quadrant becoming increasingly better localized.

- Referred pain/Radiation:

Referred pain arises from a convergence of somatic and visceral afferent fibres. This type of pain is not perceived at the point of origin, but may be projected to a corresponding possibly far away lying dermatome. Examples of referred pain include the pain of a renal colic which radiates to the groin or the right subscapular pain felt in a biliary colic [1]. Generally the chance of perceiving referred pain is higher, the more severe the painful stimulus is [1].

All three types of pain perception may appear together, which has to be taken into account when assessing the patient [5]. On the basis of the pain localization a preliminary differential diagnosis can be formulated (*see Table 4*) [12].

Table 4: Differential diagnoses of the acute abdomen according to pain localization.
Adapted from Soybel et al. 2006 [1], Trentzsch et al. 2011 [5], Lankisch et al. 2006 [8].

| Upper right quadrant | Epigastric region | Upper left quadrant |
|--|---|---|
| <ul style="list-style-type: none"> - Peptic ulcer - Cholecystitis - Choledocholithiasis - Acute cholangitis - Acute pancreatitis - Hepatitis - Hepatic neoplasm - Liver abscess - Pneumonia - Subphrenic abscess - Pyelonephritis - Nephrolithiasis/ureterolithiasis - Myocardial ischemia - Herpes zoster | <ul style="list-style-type: none"> - Peptic ulcer - Gastritis - Duodenitis - Pancreatitis - Gastroenteritis - Mesenteric adenitis - Inflammatory bowel disease - Intestinal obstruction - Mesenteric thrombosis - Myocardial ischemia | <ul style="list-style-type: none"> - Peptic ulcer - Splenic infarction or rupture - Pancreatitis - Pancreatic neoplasm - Pleuropneumonia - Subphrenic abscess - Pyelonephritis - Nephrolithiasis/ureterolithiasis - Myocardial ischemia - Herpes zoster |
| | Periumbilical region | |
| | <ul style="list-style-type: none"> - Appendicitis - Small bowel obstruction - Gastroenteritis - Intestinal obstruction - Rupture of aortic aneurysm - Dissection of abdominal aorta - Mesenteric ischemia - Hernia | |
| Lower right quadrant | Hypogastric region | Lower left quadrant |
| <ul style="list-style-type: none"> - Acute appendicitis - Mesenteric lymphadenitis - Meckel diverticulitis - Inflammatory bowel disease - Caecal carcinoma - Perforated peptic ulcer - Ovarian cancer - Ovarian cyst/torsion - Salpingitis - Ectopic pregnancy - Hernia - Pyelonephritis - Nephrolithiasis/ureterolithiasis | <ul style="list-style-type: none"> - Acute cystitis - Prostatitis - Inflammatory bowel disease - Intestinal obstruction - Abdominal wall hematoma - Ovarian cancer - Ovarian cyst/torsion - Diverticulitis - Endometriosis - Proctocolitis - Ectopic pregnancy | <ul style="list-style-type: none"> - Diverticulitis - Inflammatory bowel disease - Ovarian cancer - Ovarian cyst/torsion - Salpingitis - Ectopic pregnancy - Hernia - Sigmoid colonic carcinoma - Pyelonephritis - Nephrolithiasis/ureterolithiasis |

Mode of onset and duration:

The mode of onset and the acuteness of abdominal pain give important clues about the severity of the underlying pathology [1, 8, 11]. Abdominal pain that sets in suddenly, particularly if severe, is suspicious of an intra-abdominal catastrophe of the likes of a ruptured abdominal aortic aneurysm (AAA) or perforated viscus [1, 8, 11]. In the case of such a sudden-onset pain it is useful to ask whether there was a concomitant loss or near loss of consciousness [1, 11]. According to *Cope's Early Diagnosis of the Acute Abdomen* [11], the perforation of a gastric or duodenal ulcer, acute pancreatitis, ruptured aortic aneurysm or a ruptured ectopic pregnancy are the only abdominal conditions likely to cause a person to faint in the setting of acute abdominal pain. Abdominal pain that awakens the patient from sleep should also be considered serious until proven otherwise [1, 6, 8, 11]. The duration of pain can be an early clue, whether surgical treatment is necessary or not. Acute abdominal pain that lasts 6 hours or longer is likely to be caused by pathologies requiring surgical intervention [1, 5].

Character:

The assessment of the character of pain helps giving further insight into the nature of the underlying condition [11]. Abdominal pain can be characterised as dull, burning, tearing, sharp stabbing, as well as localized or diffuse. Particular types of pain seem specific and characteristic for certain pathologies [1, 11]. The pain of a perforated gastric ulcer for example is of a burning character, the pain of a dissecting aneurysm tearing and that of a bowel obstruction gripping [1, 11]. In most cases the pain described by the patient does not fit these profiles [1], which makes a sound comprehensive approach even more important.

Associated symptoms:

The assessment of associated symptoms and their relation to the abdominal pain is of great significance. Besides gastrointestinal symptoms it is important to inquire about urinary symptoms and in female patients a full gynaecological and obstetric history should be taken [1, 5, 6].

- Vomiting:

Vomiting commonly accompanies acute abdominal pain and can be encountered in almost any abdominal disease [1, 6]. Apart from acute gastritis, vomiting in association with abdominal lesions is either due to a severe irritation of peritoneal or mesenteric nerve

endings as in the case of a perforated ulcer or is due to the obstruction of an involuntary muscular tube, as seen in the case of colics [11]. It is important to enquire about the timely relationship between vomiting and pain onset [1, 6, 11]. In surgical conditions, pain generally precedes vomiting, whereas in medical conditions, like for example acute gastroenteritis, the pain usually comes after the vomiting [1, 6, 11]. The character of the vomit should be noted. Here it is important to ask whether the vomitus was bilious or contained blood [6, 11]. The presence of blood or coffee ground emesis suggests gastric disease or might be caused by a complication of hepatic disease [6]. Bilious vomiting is commonly seen in colics [11]. A way of differentiating benign causes of vomiting like viral gastroenteritis or food poisoning from rather sinister ones is that they are usually self-limited [6].

- Nausea and anorexia:

Cope [11] states that nausea, anorexia and vomiting represent different grades of the same kind of stimulus, hence it is important to question about their presence or absence [11]. Anorexia is closely linked to the diagnosis of acute appendicitis and is often used as a discriminatory symptom for that matter [6]. Yet it is important to keep in mind that only 68% of patients with acute appendicitis also report it as a symptom [6].

- Bowel symptoms:

• Diarrhoea:

The passage of diarrhoeal stools typically characterizes gastroenteritis but should not be used as a marker to rule out more serious pathologies [1, 6]. Mesenteric ischemia, whose early symptoms are often missed, also presents with frequent loose bowel movements [8, 11]. Other differential diagnoses that have to be considered are acute appendicitis and partial small bowel obstruction or early complete small bowel obstruction, where in both cases in an attempt to clear itself bowel peristalsis becomes hyperactive [6, 11].

• Constipation:

Constipation by itself is no reliable symptom unless other symptoms are associated, most importantly the presence or absence of flatus [6, 11]. The clearing of gas happens more quickly than fluid, which is why the absence of flatus is a better sign of intestinal obstruction than constipation [6].

- Hematochezia/melena:

The passage of bloody stools in patients presenting with abdominal pain should alert one's mind to the possibility of mesenteric ischemia [6]. Melena is usually indicative of upper gastrointestinal bleeding, for example from a peptic ulcer [6].

- Genitourinary symptoms:

Due to the fact that the genitourinary and gastrointestinal organ systems lie in such close proximity to each other inflammatory processes in either of them may lead to a symptomatology in the other [6]. Such as for example testicular torsion may present with acute abdominal pain, nausea and vomiting, so can acute appendicitis lead to dysuria and pyuria [6]. Therefore it is important to take an exact history asking about dysuria, frequency, urgency and hematuria. In women, it is imperative to ask detailed questions about the menstrual cycle, including cycle length, date of last menses, changes in menstrual blood loss, dysmenorrhea and the use of contraceptives [1]. Furthermore, inquiries should be made about previous pregnancies or miscarriages and risk factors for ectopic pregnancy [1].

Time course and progression pattern:

Pain can be either of a constant, continuous nature or as in the case of colics intermittent [1]. Colics are defined as paroxysmal attacks of cramping pain that typically last a few minutes and are followed by periods of pain relief [1, 11]. Causative for this type of pain is the violent peristalsis of the muscular wall of hollow viscera like the intestines, bile ducts, ureters or fallopian tubes, in an attempt to overcome an obstruction in the tube [1, 11]. Continuous pain is more common than intermittent pain and usually points to a pathological process that will in its course cause ischemia or inflammation of the peritoneum [1]. According to Soybel and Delcore (Soybel & Delcore 2006): "The chronological sequence of events in the patient's history is often more important for diagnosis than the location of the pain alone." Therefore it is important to meticulously assess and record the chronology and time course of the symptoms the patient reports and their relationship to each other [11]. For example in small bowel obstruction the initial colicky pain progresses and changes as abdominal distention supervenes into a continuous pain [6]. So the change in pain character or the shifting of pain localization should be noted as such progression patterns might in some cases be diagnostic [6].

Exacerbating/Relieving factors:

During the patient history it is very important to ask about the settings, in which the pain worsened or was palliated. The pain of peritoneal irritation is typically exacerbated by jarring motions as those of a cough or while walking and should be enquired about [1, 5, 6]. Abdominal pain in the upper quadrants might originate from pleural irritation caused by pathological processes in the thorax, for example pneumonia [1, 6, 11]. Hence, it should be established, whether the pain is influenced by respiration. Eating might also be a provocateur or palliator of pain. In the case of peptic ulcer disease, eating exacerbates the pain if gastric and alleviates the pain if duodenal in origin [6]. Pain following especially fatty meals is oftentimes reported by patients suffering from gallstones. In abdominal angina, in the case of mesenteric ischemia, as the blood supply cannot meet the oxygen demand of the intestine created by food digestion, pain ensues [6, 11].

Severity:

Pain that is severe should heighten the concern for a serious underlying cause [5]. Descriptions cannot always be relied upon to exclude serious illness, especially in older patients who may underreport symptoms [6, 8]. As an attempt to objectivise and categorise the pain perceived by the patient, the visual analogue scale (VAS) may be used. The score obtained dictates, whether analgesics are of need and what type of pain medication should be used. Herein the use of opiate analgesia comes into play at a VAS of >3 [5].

The question whether the patient has felt a pain like this before should be asked at any rate [6, 11]. Except for mesenteric ischemia, cholecystolithiasis or partial intestinal obstruction, recurrent episodes generally suggest that the pain is of a medical causative origin [6].

After a thorough history of the presenting symptoms and abdomen focused patient history, the physician should obtain a history of past illnesses, medical and surgical [1, 5]. Inquiries should also be made about allergies and medications, since both of which might be causative aetiologies or have an impact on the diagnostic measures taken and treatment plan.

5.2. Physical examination

The abdomen focused physical examination of a patient with acute abdominal pain follows an IAPP (Inspection - Auscultation - Palpation - Percussion) scheme.

- Inspection:

Prior to focusing purely on the abdominal wall of the patient, the treating physician should actively look for signs indicating a systemic pathological process [1]. Inspecting the patients skin for signs of jaundice or spider naevi is as much part of the physical exam as the palpation of the abdomen. The patient's general appearance, vigilance and vital signs, which mostly are ascertained during the course of the triage give important information about the acuteness of the problem as well as clues which might point towards a certain differential diagnosis [5, 11, 13]. The patient's position and attitude in bed is worthy of attention. Note for example the contrasting nature of those enduring severe colics squirming restlessly about in bed and those suffering from peritonitis, who are trying to avoid any movement [1, 11, 13]. For the acute abdomen, every anomaly of vital signs or vigilance should lead suspicion to an intra-abdominal catastrophe and prompt urgent intervention [5]. An old surgeons' lore is that an abdominal examination is from nipples to knees. That means that the patient must be undressed and inspected accordingly, in order not to miss possible skin changes or masses, for example the signs of herpes zoster or the ecchymoses typical of intra-abdominal haemorrhage (Grey-Turner's sign, Cullen's sign) [6]. Furthermore, the treating physician must take notice of any abdominal distention, which might signify intestinal obstruction or ascites [1, 6].

- Auscultation:

It is imperative that the auscultation is performed before the abdominal palpation and percussion, since these could encourage bowel peristalsis and thereby falsify the findings [8]. The clinical significance of abdominal auscultation is quite a controversial topic though [14, 15, 16, 17]. Cope (Silen 2010) states: "Of all the modalities of physical diagnosis of the abdomen, auscultation is one of the least valuable and most misleading." Despite its inherent role in the examination process, we still have an insufficient understanding of the acoustic properties of bowel sounds and a lack of proper systematic training of abdominal auscultation [14, 18]. According to a traditional saying

silence at auscultation indicates peritonitis and loud rumbling or gurgling sounds point to intestinal obstruction [11]. However, among the different sounds of peristalsis, whether present or not, one cannot infer a pathological process, except for the high-pitched borborygmi of small bowel obstruction [5, 19]. Furthermore, it was shown that there is a lack of inter-observer agreement, which reflects the need for improvements of skill in differentiating bowel sounds [14, 18]. Although abdominal auscultation by itself is not useful in differentiating normal from pathological sounds of peristalsis, with patient history and clinics its diagnostic value may be increased [14]. Under these circumstances, namely the aforementioned improvements in education and training, the abdominal auscultation should be continued [14, 18].

- Palpation:

The palpation of the abdominal wall is the most important part of the abdominal examination [5]. Its main purpose is to look for signs of peritonitis, to localise tenderness and to detect organ enlargement, as for example that of the liver, spleen or possibly the aorta [6]. The palpation of the abdomen should be started at the point farthest away from the point of maximum tenderness in order to avoid unnecessary discomfort for the patient during the process [1, 11]. A too rough examination may by itself elicit pain and be therefore misleading for the examiner, which is why it should be done carefully and gently [5, 6, 11]. The classical signs of peritonitis are rebound tenderness and muscular rigidity or “defense musculaire” [2]. The test for rebound tenderness is performed by deeply pressing down on the abdominal wall and then suddenly releasing the pressure. Pain upon the pressure release means that the test is positive. Studies have shown that the test for rebound tenderness has a sensitivity and specificity of 80 % and 40-50 % respectively [6]. A way to increase the specificity is to use the “cough test”, which is an indirect test for rebound pain has a similar sensitivity but an even higher specificity of 79 % [6].

Abdominal wall rigidity or “defense” is an involuntary reflex, whereby the abdominal wall muscles contract in order to protect and prevent movement of the underlying viscera [6, 11]. The term “guarding” is often used instead of and synonymously with “rigidity”. The underlying pathophysiological process is in both cases the same. In some texts a differentiation is made by saying that rigidity represents the extreme form of guarding [6]. In praxis though, this is a purely nomenclatural problem. The differentiation of guarding and rigidity is of less importance. The crucial point is to differentiate between voluntary and involuntary guarding. This can be achieved

by assessing the muscular rigidity throughout the respiratory cycle. In case of true involuntary guarding, the abdominal musculature will remain stiff throughout inspiration and expiration. In voluntary guarding the muscle tone decreases during the inspiratory phase.

It is important to bear in mind that the manifestation of peritoneal signs might be diminished or simply overseen even though a serious peritonitis is looming beneath the examiner's fingers. This might especially be the case in elderly patients with weakened and lax abdominal musculature, fat abdominal wall or in instances of severe toxemia [1, 5, 6, 11].

- Percussion:

Gentle abdominal percussion can be viewed as a miniature version of the rebound tenderness, which does not only yield more precise results with respect to the localization of the peritoneal irritation but also spares the patient from unnecessary pain that results from the "rebound" during palpation [8, 11]. In suspected peritonitis the careful percussion of the abdominal wall is the examination technique of choice [8]. Percussion of the abdomen is also of aid in case of abdominal distention. Large bowel obstruction which leads to a drum-like tympanic note on percussion can be discerned from the shifting dullness indicative of advanced ascites [6].

5.3. Digital rectal examination

In conformance with the accepted standards of care, every patient who presents to the emergency department with acute undifferentiated abdominal pain should in order to complete the physical evaluation be examined by digital rectal examination [20, 21]. Without it, the physical exam is considered to be incomplete [21]. As Cope (Silen 2010) phrases it: "It is as important to insert a finger into the lower end as it is to order a plain film of the abdomen." Although both, the digital rectal examination as well as the plain abdominal film (vide infra) were and still are used as diagnostic modalities, studies have shown that their diagnostic utility is of less value than previously believed [5, 20, 21]. Thus the digital rectal exam's meaningfulness in the assessment of acute abdomen in the emergency department must be questioned [5, 6, 21]. There is no evidence in the literature supporting the routine performance of a digital rectal examination in patients with acute, undifferentiated abdominal pain and acute appendicitis [6, 20, 21]. However, it should not be entirely discarded. In cases of specific differential diagnoses, as that of suspected gastrointestinal

bleeding, intestinal ischemia or colorectal cancer the digital rectal examination remains to have a clear indication and justification [6, 21].

5.4. Special abdominal examination manoeuvres:

Tailored to the preliminary differential diagnoses formulated further examination manoeuvres can be useful in establishing a diagnosis [13]. Before the advent of imaging modalities the diagnosis was based solely on the clinical evaluation of the patient. In order to increase accuracy special signs and manoeuvres were utilized and still are in use. Studies which assess their sensitivity and specificity are scarce and thus diminish their value [8], which is why they have to be interpreted with care. Some examples are listed here:

- The iliopsoas sign:

The iliopsoas sign is performed by having the patient roll onto his/her left side and hyperextending the right hip joint. If pain is elicited the sign is positive and suggests an irritation of the iliopsoas muscle by a retrocecal appendicitis [1, 11, 19]. Other pathologies that might lead to a positive iliopsoas sign are pyelonephritis, pancreatitis and psoas abscess [6].

- The obturator sign:

With the patient supine, the thigh of the patient has to be flexed passively and fully rotated inward. The test is positive, if pain is elicited by that manoeuvre and means that the obturator muscle is inflamed because of pathology of a neighbouring viscus [1, 11, 19]. Causative pathologies might be a pelvic appendicitis, diverticulitis, pelvic inflammatory disease or ectopic pregnancy [6].

- The Rovsing sign:

The Rovsing sign is being tested by applying pressure the left lower quadrant. If pain is being referred to the McBurney point the sign is positive and increases the likelihood of appendicitis [1, 6, 19]. However, the test is not perfect, since it has both false positives and negatives [19].

- Murphy sign:

The Murphy sign is performed by asking the patient to take a deep breath while palpating the right upper quadrant of the abdomen. If the patient abruptly stops the inspiration, the

sign is positive and is suggestive of acute cholecystitis [1, 6, 11, 19]. Numerous studies were conducted, which evaluated the sensitivity and specificity of the Murphy sign, leading to varying results ranging from 44%-97% and 48%-96% respectively [19]. Although it is the most reliable clinical indicator of acute cholecystitis, with a positive LR, of 2.8 and a 95% CI of 0.8-8.6, since the 95% CI includes 1, further diagnostic testing is necessary to secure the diagnosis [6, 22].

- Cullen and Turner signs:

Both represent ecchymoses on the skin of the abdomen, which result from intraperitoneal or retroperitoneal haemorrhage which dissects through the skin. The Cullen sign was first described in case of a ruptured ectopic pregnancy and represents a periumbilical ecchymoses and the Turner sign is a discolouration of the flanks and is suggestive of haemorrhagic pancreatitis [1, 6, 19]. Strictly speaking, the only difference between those two signs is the eponym, especially as the location of the bruise does not give clues about the origin of the bleed [19]. The sensitivity of these tests is very limited, with less than 1% for a ruptured ectopic pregnancy and 3% for acute pancreatitis [19]. Taking into account that a whole array of different pathologies may cause these signs, their specificity and thus their relevance for the diagnosis of ruptured ectopic pregnancy and acute pancreatitis is limited [19].

6. Analgesia

Regarding the use of analgesics in patients with acute abdomen a change of paradigm has taken place [5]. For generations the regrettable doctrine of not administering analgesics until the diagnosis was secured, ruled [11, 23]. The fear was, that analgesics might mask symptoms, obscure findings of the physical exam and delay the diagnosis [23]. A Cochrane analysis [23] refuted this and showed that the administration of analgesics in fact does not obscure relevant findings of the physical exam, nor does it increase the risk of diagnosis errors or errors in decision making with respect to the treatment. Furthermore this not just fulfills the physician's duty of relieving pain and suffering but also by increasing patient comfort adds to the quality of the emergency care [5, 6]. What should be stressed though is, that prior to the administration of pain relieving medication the clinical findings are evaluated with ample security [5].

7. Investigative Studies

In light of the fact that at least one third of patients with acute abdomen present with atypical features [1], the diagnosis should and cannot be based solely on the clinical evaluation but makes investigative studies (laboratory tests and imaging) ultimately indispensable [5]. All diagnostic tests, whether laboratory tests or radiological studies have a false-negative rate and therefore, if the clinical evaluation of the patient leads to a high pre-test probability of a disease, the initially suspected diagnosis should not be discarded [6, 24]. For example, in the case of suspected appendicitis, the use of laboratory markers (WBC, granulocyte count and proportion of polymorphonuclear cells, CRP) is insufficient to ascertain the diagnosis and the use of computed tomography (CT), even though it is the most accurate diagnostic modality bears the burden of radiation [15]. This emphasises the importance of clinical experience and an understanding of the “inner workings” of the abdominal cavity. Moreover, the over-reliance on laboratory tests and radiological evaluation might be misleading, especially if the clinical evaluation of the patient was not conducted properly [11]. It is important to stress that one’s clinical judgement should not be led astray or blinded by an alleged infallibility of investigative studies. The ordering of laboratory or radiological tests should not be done blindly but build on a sound differential diagnosis.

7.1. Laboratory Tests

The extent of laboratory testing varies and is dictated by the suspected diagnosis and differential diagnoses. The minimal panel of laboratory tests in a patient with acute abdomen entails [3, 5, 6]:

- Complete blood count (CBC):

The CBC is useful in detecting changes in plasma volume due to dehydration (hematocrit), diagnosing anaemia and by virtue of the WBC detecting an inflammatory process [1]. The finding of an elevated WBC does not necessarily exclude, nor prove an intra-abdominal inflammatory process though. Besides this, it is important to remember that in the early stages of a hemorrhagic process the RBC count might be normal and should not delay appropriate treatment unnecessarily [11].

- C-reactive Protein (CRP):

The CRP is an acute phase protein and of the β -globulin fraction. Its levels start to rise

6-12h after the beginning of an inflammatory process. In adjunct with the WBC it increases the confidence in the diagnosis of an acute inflammatory condition [1, 15, 24].

- Procalcitonin (ProCT):

Procalcitonin, the precursor hormone of calcitonin, was found to be a useful marker in the assessment of sepsis and systemic inflammatory response and has also proven its worth in the differentiation of infectious from non-infectious inflammation [25, 26]. Although it is mainly produced by the C-cells in the thyroid gland and neuroendocrine cells in the lungs many other tissues have shown the capacity to synthesise it [26]. In the event of a systemic inflammatory process, hypersecretion of ProCT follows [26]. In the assessment of acute abdominal pain, ProCT can be of particular help, when acute mesenteric ischemia, necrosis in acute bowel obstruction or abdominal sepsis are suspected to be the causative aetiologies [25]. A systemic review by Mofidi et al. [27] concluded that ProCT may also be valuable in predicting the severity of acute pancreatitis and the risk of infected pancreatic necrosis.

- Liver function tests:

Liver function tests including a total bilirubin count, alkaline phosphatase, γ -glutamyltransferase (γ -GT), aspartate aminotransferase (AST) and alanine aminotransferase (ALT) are mandatory in abdominal pain suspected to be of hepatobiliary origin [1].

- Lipase/amylase:

The evaluation of amylase and lipase is obligatory in suspected pancreatitis [1]. Caution is in order though, as normal levels of amylase cannot exclude pancreatitis, but elevated levels do not necessarily prove it either, since the levels might be also elevated in conditions like intestinal obstruction, mesenteric thrombosis or a perforated peptic ulcer [1, 8]. A study conducted by Gomez et al. [28] showed that lipase has a higher sensitivity and specificity in the diagnosis of acute pancreatitis, with 96.6% and 99.4% respectively, and is therefore more suitable in the diagnosing of acute pancreatitis than amylase. Gomez et al. [28] concluded not only that determining lipase levels alone is sufficient to diagnose acute pancreatitis but also showed that by this approach a substantial amount of money may be saved. It is important to mention that although higher serum enzyme levels make the diagnosis of acute pancreatitis more likely they do not reflect the severity of the pancreatic involvement [8].

- Serum electrolytes & kidney function tests:

Assessing creatinine and blood urea nitrogen (BUN) levels may give important information about the hydration status of the patient and the nature of fluid loss [1]. BUN/creatinine, electrolytes together with CBC are the most commonly ordered laboratory tests in the ED [24]. Although these parameters might not be as useful in the detection of the underlying pathology as for example lipase levels in pancreatitis, they are of clinical importance as they serve as indicators of systemic involvement [24].

- Serum Glucose:

Derangements of the glucose metabolism, be it hypo-, or hyperglycemia can present in different colours and forms. It is not by chance that disturbances of glucose metabolism are seen as the “chameleon of emergency medicine”. To prove the point: Pseudoperitonitis diabetica is a condition that may be encountered in patients with decompensated diabetes mellitus in the course of ketoacidotic coma [2]. These patients present with the clinical picture of peritonitis, with severe abdominal pain and possibly vomiting, mimicking an inflammatory intra-abdominal condition.

- Lactate:

An increase in lactate levels indicates anaerobe glycolysis and therefore is a parameter for inadequate perfusion, oxygenation and an estimate of tissue oxygen deficiency [25]. Although not being specific to abdominal conditions increased lactate levels were found to be a possible marker of mesenteric ischemia [24]. Besides this elevated lactate levels may be found in conditions like general bacterial peritonitis, strangulated intestinal obstruction, diabetic ketoacidosis and acute pancreatitis [25].

- Urinalysis:

Urinalysis is a frequently ordered laboratory test and next to the abdominal CT the most useful test in the assessment of acute abdominal pain in the ED [24]. Erythrocytes in the urine suggest nephrolithiasis or urolithiasis, leucocytes and nitrites are suggestive of a urinary tract infection, and an elevation of glucose and ketones might point to diabetes [1].

In women of childbearing age it is imperative to order a β -human chorionic gonadotropin (β -hCG) test [1, 4, 5]. This is not only important since a complication of pregnancy might be the cause of the abdominal pain but also because a positive result has an impact on the evaluation of the patient with respect to the choice of imaging modality and treatment [4].

In patients with upper quadrant and epigastric pain troponin levels should be assessed in order to exclude myocardial ischemia [5]. Furthermore, it is mandatory to do an electrocardiography in elderly patients, patients who present with epigastric pain and patients with risk factors for cardiovascular disease (CVD) or a history of the same [1, 5, 8].

7.2. Imaging

Imaging diagnostics have an undisputed central role in the evaluation of the acute abdomen in the ED [5]. With plain X-rays, computed tomography (CT), ultrasonography (US) and magnetic resonance imaging (MRI) different imaging modalities are at disposal. In order to prevent the patient from being exposed to ionising radiation unnecessarily or undergo time-consuming and costly procedures which might delay treatment it is important that the treating physician chooses the imaging modality accordingly.

7.2.1. X-ray

Plain abdominal radiography (AXR) has until recently been in use as the initial imaging modality in the investigation acute abdominal pain but has since been surpassed by ultrasound imaging and CT [1, 3, 5, 16, 24]. Although current literature advises against the routine use of abdominal X-ray imaging in the work-up of patients with acute abdominal pain in the ED, yet it is often being utilised [4, 16]. Nevertheless there remain some conditions where plain films may be useful: air-fluid levels and the presence of dilated loops of bowel are suggestive of intestinal obstruction, suspected intestinal perforation might be proven by demonstrating the presence of free air (pneumoperitoneum), plain films also have a role in the detection of foreign bodies and in the follow-up of renal tract calculi [1, 16, 24]. A study conducted by Sreedharan et al. [16] found that the sensitivity of AXR has a sensitivity of 30 % and a specificity 88 %. This means that the AXR is not sensitive enough to safely rule out possibly causative pathologies, which also explains why 41% of patients with normal AXR had to undergo additional imaging studies [16]. Furthermore, in the case of a positive AXR finding in nearly 80% of cases further imaging studies became necessary to establish the diagnosis [16]. This translates into patients being exposed to unnecessary radiation, which besides being inefficient in proving or disproving possible pathologies may even delay

adequate treatment [16, 24]. In summary, the diagnostic value of plain AXR is questionable and should only be ordered with appropriate indication.

7.2.2. Ultrasound (US)

The ultrasound examination can and should be viewed as the continuation of the clinical evaluation of the acute abdomen and should rank first among the investigative studies [5, 8]. Thus, all patients with suspected acute abdomen, after a comprehensive patient history and thorough physical examination should undergo an abdominal sonography [5].

Pain film or computed tomography can only make a snapshot of a pathological process. A true advantage of the abdominal sonography is that the examination is dynamic and takes place in real-time [24]. In this way not only the intestinal peristaltic but also the perfusion of abdominal vessels can be evaluated [5]. Ultrasound imaging is non-invasive and repeatable as often as desired, which can be very useful in assessing the dynamic of the pathological process [1, 24].

The main drawback regarding its precision is its high user-dependency, which narrows its diagnostic conclusiveness [5]. Another disadvantage of the US are patient factors including the patient's body habitus and bowel gas, which may limit the examination [24]. Nevertheless, abdominal sonography is an easily accessible imaging modality that may be performed by the ED physician at the patient's bedside, which makes it especially useful in the evaluation of unstable patients [24].

7.2.3. Computed tomography (CT)

The diagnostic value of the CT is indisputable [5]. It is as a method more objective, reproducible and with less inter-observer variability than the US [5, 24]. A study by Stromberg et al. [17] showed that by the use of CT the correct diagnosis could be ascertained in 96.8%. Moreover it was found that the early use of CT leads to a decrease in duration of hospital stays and a decrease in hospital admissions overall [3, 5]. However, a clear and major drawback to the regular use of CT imaging is the considerable radiation exposure and the thereby increased lifetime risk of a radiation-induced cancer [3, 5, 24]. This risk rises indirect proportionally with the age of the patient. The radiation dose of an abdominal CT lies between 10-30 mSv [5, 24, 27]. Trentzsch et al. [5] have calculated that for a 25-year old patient this translates into a lifetime risk of getting a radiation-induced cancer

of 1:900 and dying from cancer of 1:1800. For a 50-year old patient the risk is with 1:1500 and 1:2500 respectively smaller but still important to consider. It was predicted that 1.5 to 2 percent of all cancers in the United States population can be attributed to CT exposure [24]. Therefore the indication for an abdominal CT must be strict and clear-cut [5].

7.2.4. CT- angiography

CT-angiography is the diagnostic modality of choice in the evaluation of suspected mesenteric ischemia or disturbances of renal or lienal blood flow [3, 8]. Since mesenteric blood flow disturbances are detected relatively late in its course should the indication for a CT-angiography be posed quite liberally [8]. Furthermore the CT-angiography can also be of use if the source of gastrointestinal bleeding cannot be found or if renal damage is assumed [8].

7.2.5. Endoscopy

Endoscopy represents the link between diagnostics and intervention but has a rather minor role in the evaluation of the acute abdomen in the ED [3, 5, 8, 11]. Nevertheless an upper GI endoscopy may be helpful in detecting peptic ulcers as the causative pathology in cases of unspecific acute abdominal pain [8].

7.2.6. Magnetic resonance imaging (MRI)

Currently MRI plays a rather minor role in the evaluation of acute abdominal pain in the emergency department [5, 29]. The reason for that is its low availability compared to CT, the time consumption and the cost of the procedure [5, 29]. The advantages of magnetic resonance imaging on the other hand, namely the lack of ionising radiation and a proven diagnostic track record make in light of the increased awareness about the detrimental effects of ionising radiation an increasingly attractive alternative to CT [29]. MRI has an established role as the imaging modality of choice in acute abdominal pain in the pregnant population, where the US was bland [8, 27].

Singh et al. [30] proposed that MRI should be recommended in all women with acute lower abdominal pain where the aetiology of the symptoms cannot be detected by US and the differential diagnosis of acute appendicitis, ovarian torsion or other pathologies of the adnexa have to be

investigated [3]. Worth exploring is the use of MRI in the young and young adults population for the suspected diagnosis of acute appendicitis or Crohn's disease, both of which having overlapping incidences at the ages of 10-19 and 15-29 respectively [29]. Due regard must be given to the fact that an ageing population and an increase in the prevalence of diabetes, the rates of renal dysfunction and therefore the risk attached to the use of intravenous contrast is rising [29]. That is why the use of MRI in preference to CT might be worthy of consideration even in the population of adults and older semesters.

7.3. Choice of imaging modality

The choice of the imaging modality should be based on two things: Firstly whether thereby a diagnosis can be ascertained or excluded and secondly whether this justifies the radiation exposure [3, 5, 7]. The OPTIMA study [7] was conducted with that goal in mind. On this basis a strategy was formulated which implies that all patients, who present with acute abdominal pain, should undergo an ultrasonographic examination. CT with i.v. contrast should be employed when the US exam is bland or yields non-specific results. Thereby a sensitivity of 94% and specificity of 68% could be achieved, which under the precondition of radiation protection produced the best results and should therefore be the diagnostic protocol to follow [3, 5, 7].

When the physical examination, laboratory tests and abdominal sonography do not show any abnormalities and therefore the aetiology remains unclear and the patient does not present with a symptomatology suggesting a surgical condition, the diagnosis undifferentiated abdominal pain can be assumed [1, 5]. In such an instance CT imaging might not be necessary [1, 5].

If the patient has risk factors for a surgical problem, namely abdominal pain that lasts less than 48h, pain after vomiting, involuntary guarding and rebound tenderness, is ≥ 65 years old or has a history of previous abdominal surgery, the indication for CT imaging should be posed generously [5]. This is especially true in older patients, as they are more likely to present with atypical and unspectacular symptoms, yet harbouring a significant underlying illness [5].

8. Management

On the basis of clinical evaluation and investigative studies a working diagnosis should be established and according to the SOAP scheme a treatment plan formulated [1]. In doing so the ED physician must first decide whether surgical treatment is required or not and if so, whether the patient must undergo emergent, urgent or early elective surgery [1, 3, 5]. If there is no clear indication for a surgical intervention or medical treatment, one of two routes can be chosen: Hospitalisation and conservative therapy under active observation or evaluation of the patient in an outpatient setting [1, 5].

Fortunately intra-abdominal calamities that call for emergent operation are a few [1]. They include the rupture of abdominal viscera – abdominal aortic aneurysm, liver or spleen, or the rupture of an ectopic pregnancy [1, 5]. The pointers of such crises are severe abdominal pain and haemodynamic instability represented by a critical derangement of vital signs and symptoms of shock [1, 5]. Obviously in such circumstances time is of essence and does not allow for an exhaustive evaluation but still if the patient's condition makes it possible, the basic diagnostic steps should be completed and a probable diagnosis found [1, 5].

Urgent surgical interventions are generally necessary in conditions like perforated hollow viscus, acute appendicitis, acute diverticulitis, acute cholecystitis, mesenteric ischemia, intestinal obstruction or incarcerated hernia [1, 5, 7]. The clinical picture that indicates such an approach is that of generalized or localized peritonitis or massive abdominal distention, accompanied by signs of sepsis and/or ischemia [1, 5]. Investigative studies that show findings of pneumoperitoneum, extravasation of contrast material or occlusion of blood flow are as well indications for urgent operation [1, 5]. An important exception to this “rule” is the acute pancreatitis, which might present with a similar symptomatology, is treated mostly conservatively [5].

A conservative approach with active observation may be chosen, when despite the exhaustion of noninvasive diagnostic efforts the aetiology of abdominal pain remains unclear [1, 3, 5]. Patients having severe abdominal pain, who are dehydrated and have an electrolyte dysbalance or elevated inflammatory parameters should be admitted and treated accordingly [1, 5]. If the patient's constitution and compliance allow it, the patient might be followed-up 24-48h later in an outpatient setting alternatively [1, 5]. The fear that such an approach opens the door for complications could not be proven true [1, 5]. Studies have shown that although the diagnosis and therapy did change at

the follow-up visit in 30% and 17% respectively, this fact did not influence the rate of morbidity [31].

Next to surgical causative pathologies, the ED physician must think of extra-abdominal causes too. Hereto it is important to stress once again that two thirds of patient who present to the ED with acute abdominal pain do not require surgical treatment [1].

In female patients special care has to be taken to exclude gynaecological pathologies and in male patients the possibility of an acute scrotum should be taken into consideration. In such circumstances it is necessary to call for gynaecological or urological consults [5].

8.1. Invasive diagnostics

An alternative to the “wait and see”-approach is the diagnostic laparoscopy. According to the guidelines laid out by the Society of American Gastrointestinal and Endoscopic Surgeons (SAGES) the explorative laparoscopy is indicated, when all non-invasive diagnostic measures were exhausted and yet the aetiology of the acute abdominal pain is unresolved [3, 4, 5, 32]. By the use of diagnostic laparoscopy a diagnosis can be made in 90-98% of cases [4]. However, there is not enough evidence to favour the explorative laparoscopy over active observation in suspected undifferentiated acute abdominal pain [3, 5].

9. Conclusion

The acute abdominal pain represents a diagnostic challenge for the ED physician. Apart from intra-abdominal pathologies, extra-abdominal and metabolic causes must be considered. Therefore a multi-disciplinary approach is of great importance.

In order to improve patient care and forestall diagnostic errors, diagnostic algorithms and patient evaluation forms should be used. They serve as a means for viewing highly complex clinical pictures, such as the acute abdomen, from a lucid, logically coordinated and systematic overall perspective, in order to maintain a problem- and priority oriented approach.

In the assessment of acute abdominal pain many pitfalls have to be avoided and tiptoed around. While these diagnostic algorithms are conceptualised to provide the best possible care for the majority of cases they do not substitute for the clinical experience and judgement of the physician.

10. References

- [1] Soybel DI, Delcore R (2006) Acute abdominal pain. Souba WW, Fink MP, Jurkovich GJ, Kaiser LR, Pearce WH, Pemberton JH, Soper NJ eds.; ACS Surgery: Principles and Practice. New York: WebMD.
- [2] Siegenthaler W (2007) Differential Diagnosis in Internal Medicine: from Symptom to Diagnosis. Stuttgart, New York: Thieme.
- [3] Grundmann RT, Petersen M, Lippert H, Meyer F (2010) Das akute (chirurgische) Abdomen Epidemiologie, Diagnostik und allgemeine Prinzipien des Managements. Z Gastroenterol 48: 696-706.
- [4] Hardy A, Butler B, Crandall M (2013) The Evaluation of the Acute Abdomen. Moore LJ, Turner KL, Todd SR eds.; Common Problems in Acute Care Surgery. New York: Springer.
- [5] Trentzsch H, Werner J, Jauch KW (2011) Der akute Abdominalschmerz in der Notfallambulanz - ein klinischer Algorithmus für den erwachsenen Patienten. Zentralbl Chir 136: 118–128.
- [6] Maculaso CR, McNamara RM (2012) Evaluation and management of acute abdominal pain in the emergency department. Int J Gen Med 5: 789-797.
- [7] Lameris W, van Randen A, Dijkgraaf MGW, Bossuyt PMM, Stoker J, Boermeester MA (2007) Optimization of diagnostic imaging use in patients with acute abdominal pain (OPTIMA): Design and rationale. BMC Emerg Med 7: 9.
- [8] Lankisch PG, Mahlke R, Lübbers H (2006) Das akute Abdomen aus internistischer Sicht. Dtsch Arztl 103: A2179-A2188.
- [9] de Dombal FT (1988) The OMGE acute abdominal pain survey. Progress report, 1986. Scand J Gastroenterol Suppl 144: 35–42.
- [10] Sebbane M, Dumont R, Jreige R, Eledjam JJ (2011) Epidemiology of Acute Abdominal Pain in Adults in the Emergency Department Setting. Toured P; CT of the Acute Abdomen. Berlin, Heidelberg: Springer.
- [11] Silen W (2010) Cope's Early Diagnosis of the Acute Abdomen. New York: Oxford.

- [12] Yamamoto W, Kono H, Maekawa M, Tsuguya F (1997) The relationship between abdominal pain regions and specific diseases: an epidemiologic approach to clinical practice. *J Epidemiol* 7: 27-32.
- [13] Cartwright SL, Knudson MP (2008) Evaluation of Acute Abdominal Pain in Adults. *Am Fam Physician* 77: 971-978.
- [14] Durup-Dickenson M, Christensen MK, Gade J (2013) Abdominal auscultation does not provide clear clinical diagnoses. *Dan Med J* 60: A4620
- [15] Shogilev DJ, Duus N, Odom SR, Shapiro NI (2014) Diagnosing Appendicitis: Evidence-Based Review of the Diagnostic Approach in 2014. *West J Emerg Med* 15: 859–871.
- [16] Sreedharan S, Fiorentino M, Sinha S, (2014) Plain abdominal radiography in acute abdominal pain - is it really necessary? *Emerg Radiol* 21: 597-603.
- [17] Strömberg C, Johansson G, Adolfsson A (2007) Acute abdominal pain: diagnostic impact of immediate CT scanning. *World J Surg* 31: 2347-2354.
- [18] Felder S, Margel D, Murrell Z, Fleshner P (2014) Usefulness of Bowel Sound Auscultation: A Prospective Evaluation. *J Surg Educ* 71: 768-773.
- [19] Orient JM (2010) *The Abdomen*. Seigafuse S ed.; Sapira's Art and Science of Bedside Diagnosis. Philadelphia: Lippincott Williams & Wilkins.
- [20] Kessler C, Bauer SJ (2012) Utility of the digital rectal examination in the emergency department: a review. *J Emerg Med* 43: 1196-1204.
- [21] Werner JC, Zock M, Khalil PN, Kanz KG, Jauch KW (2013) Sinnhaftigkeit der digital-rektalen Untersuchung bei akutem Abdomen in der Notfallaufnahme. *Zentralbl Chir* 138: 669-676.
- [22] Trowbridge RL, Rutkowski NK, Shojanian KG (2003) Does This Patient Have Acute Cholecystitis. *JAMA* 289: 80-86.
- [23] Manterola C, Astudillo P, Losada H, (2007) Analgesia in patients with acute abdominal pain. *Cochrane Database Syst Rev*, CD005660.

- [24] Panebianco NL, Jahnes K, Mills AM (2011) Imaging and Laboratory Testing in Acute Abdominal Pain. *Emerg Med Clin N Am* 29: 175-193.
- [25] Meyer ZC, Schreinemakers JMJ, van der Laan L (2012) The value of C-reactive protein and lactate in the acute abdomen in the emergency department. *World J Emerg Surg* 7: 22.
- [26] Becker KL, Snider R, Nysten ES (2010) Procalcitonin in sepsis and systemic inflammation: a harmful biomarker and a therapeutic target. *Br J Pharmacol* 159: 253-264.
- [27] Mofidi R, Suttie SA, Patil PV, Ogston S, Parks RW (2009) The value of procalcitonin at predicting the severity of acute pancreatitis and development of infected pancreatic necrosis: systematic review. *Surgery* 146:72-81
- [28] Gomez D, Addison A, De Rosa A, Brooks A, Cameron IC (2012) Retrospective study of patients with acute pancreatitis: is serum amylase still required? *BMJ Open* 2: e001471.
- [29] Ditkofsky NG, Singh A, Avery L, Novelline RA (2014) The role of emergency MRI in the setting of acute abdominal pain. *Emerg Radiol* 21: 615-624.
- [30] Singh AK, Desai H, Novelline RA (2009) Emergency MRI of acute pelvic pain: MR protocol with no oral contrast. *Emerg Radiol* 16:133-41.
- [31] Toorenvliet BR, Bakker RF, Flu HC, Merkus JW, Hamming JF, Breslau PJ (2010) Standard outpatient re-evaluation for patients not admitted to the hospital after emergency department evaluation for acute abdominal pain. *World J Surg* 34: 480-486.
- [32] Society of American Gastrointestinal and Endoscopic Surgeons (SAGES) (2007) Diagnostic laparoscopy for acute abdominal pain. *Diagnostic laparoscopy guidelines*, Los Angeles.

11. Biography

Mario Csenar was born in 1991 in Oberpullendorf, Austria. He is a Burgenlandcroat and attended a bilingual elementary school in Oslip/Uzlop, Austria from 1997-2001. After that he attended the grammar school in Eisenstadt (BG/BRG/BORG Eisenstadt), Austria for eight years until 2009. During the lower-grades he attended the subject Croatian language and in the advanced level of high school focused on natural sciences. He completed grammar school with the prerequisite for higher education, the general school leaving examination (Matura). From 2009-2015 Mario studied medicine in Zagreb, Croatia at the University of Zagreb, School of Medicine, English program.