

Osteoarthritis of the hip

Asofsky, Daniel Lotan

Master's thesis / Diplomski rad

2020

Degree Grantor / Ustanova koja je dodijelila akademski / stručni stupanj: **University of Zagreb, School of Medicine / Sveučilište u Zagrebu, Medicinski fakultet**

Permanent link / Trajna poveznica: <https://um.nsk.hr/um:nbn:hr:105:542778>

Rights / Prava: [In copyright](#)/[Zaštićeno autorskim pravom.](#)

Download date / Datum preuzimanja: **2024-07-23**



Repository / Repozitorij:

[Dr Med - University of Zagreb School of Medicine Digital Repository](#)



SCHOOL OF MEDICINE
UNIVERSITY OF ZAGREB

Daniel Lotan Asofsky

Osteoarthritis of the Hip

Graduate Thesis



Zagreb 2020

This graduation paper was released at the Department of Physical Medicine & Rehabilitation, Clinical Hospital "KBC Rebro", School of Medicine, University of Zagreb, under the supervision of Prof. Porin Perić, MD, PhD, and it was submitted for evaluation in the academic year of 2019/2020.

Mentor of the graduate thesis: Prof. Porin Perić, MD, PhD.

ABBREVIATIONS:

- OA: Osteoarthritis
- THA: Total Hip Arthroplasty
- VAS: Visual Analogue Scale
- K&L: Kellgren & Lawrence
- NSAIDS: Non-Steroidal Anti-inflammatory Drugs
- GI: Gastrointestinal
- SNRI: Serotonin Norepinephrine Reuptake Inhibitor
- RCT: Randomized Control Trial
- ACR: American College of Rheumatology

TABLE OF CONTENTS

1. Abstract.....	3
1.1. Sažetak.....	4
2. Introduction.....	5
3. Anatomy of the Hip.....	6
4. Incidence and Prevalence.....	10
5. Risk Factors.....	11
6. Pathogenesis.....	13
7. History Taking and Physical Examination.....	14
8. Symptoms.....	16
9. Differential Diagnosis.....	16
10. Diagnosis.....	17
11. Treatment.....	20
12. Conclusion.....	28
13. Acknowledgement.....	28
14. References.....	29

1. ABSTRACT

Subject: Osteoarthritis of the Hip

Key words: osteoarthritis, hip, hyaline cartilage, total hip arthroplasty

Author: Daniel Lotan Asofsky

Osteoarthritis of the hip is becoming increasingly more common throughout the world and is getting wider attention from the medical community. A growing elderly population and globally increasing rates of obesity are bringing forth more traumatic and idiopathic degeneration of the hip joint. Pathology in the joint causes irreversible degeneration due to the inability of hyaline cartilage to heal. Classification of the pathological extent of the disease can be described through symptomatic or radiographical degree. History taking and physical examination lead to a proper diagnosis and management. The aim of treatment is to improve pain, function and quality of life. In the case where surgical intervention is needed, total hip arthroplasty is the gold standard operation with the best long-term results.

1.1 SAŽETAK

Osteoartris kuka postaje sve češći problem u svijetu, te mu se sve više posvećuje pažnja u medicinskoj zajednici. Povećanje broja starije populacije i globalne stope pretilosti dovodi do traumatičnije i idiopatske degeneracije zgloba kuka. Patologija u kuku uzrokuje nepovratna oštećenja, budući da se hijalina hrskavica ne može oporaviti. Klasifikacija patološkog opsega bolesti može biti opisana putem simptomatskih ili radiografskih pretraga. Uzimanje anamneze i pregled dovode do dijagnoze i upravljanja tijekom bolesti. Cilj liječenja je smanjiti bol i poboljšati kvalitetu života. U slučaju kirurške intervencije, totalna artroplastika kuka je najbolja opcija sa dugoročnim rezultatima.

2. INTRODUCTION

The hip joint is a ball and socket-type joint which is commonly affected by degenerative changes leading to osteoarthritis. Osteoarthritis of the hip is a disease that mainly results from a progressive loss of cartilage on the surface of the femoral head and the acetabulum. As well as causing changes to the subchondral bone, synovium, ligaments and joint capsule which directly leads to loss of joint space. This in turn results clinically in restricted range of motion, limited function and pain experienced by the patient. The pathogenesis appears to be of multifactorial origins occurring as a result of pathological, mechanical, and molecular events where aging and genetic predisposition play important contributing risk factors. Diagnosis is made through clinical and radiographic investigations while treatment is provided only in the case that symptoms emerge and have an effect on the patient's quality of life. The approach with management of the disease should first be life style changes and only after pharmacologic or surgical intervention.

In the following review paper, we will take a deeper look into OA of the hip and analyze each part to give us a better understanding of the condition as a whole and the correct clinical approach.

3. ANATOMY OF THE HIP

The hip articulation is true diarthroidal ball and-socket style joint, formed from the head of the femur as it articulates with the acetabulum of the pelvis. This joint serves as the main connection between the lower extremity and the trunk, and typically works in a closed kinematic chain.

3.1. Structures of the Hip Joint

The hip joint consists of an articulation between the head of femur and acetabulum of the pelvis.

The acetabulum is a cup-like depression located on the inferolateral aspect of the pelvis. Its cavity is deepened by the presence of a fibrocartilaginous collar – the acetabular labrum. The head of femur is hemispherical, and fits completely into the concavity of the acetabulum.

Both the acetabulum and head of femur are covered in articular cartilage, which is thicker at the places of weight bearing.

The capsule of the hip joint attaches to the edge of the acetabulum proximally. Distally, it attaches to the intertrochanteric line anteriorly and the femoral neck posteriorly.

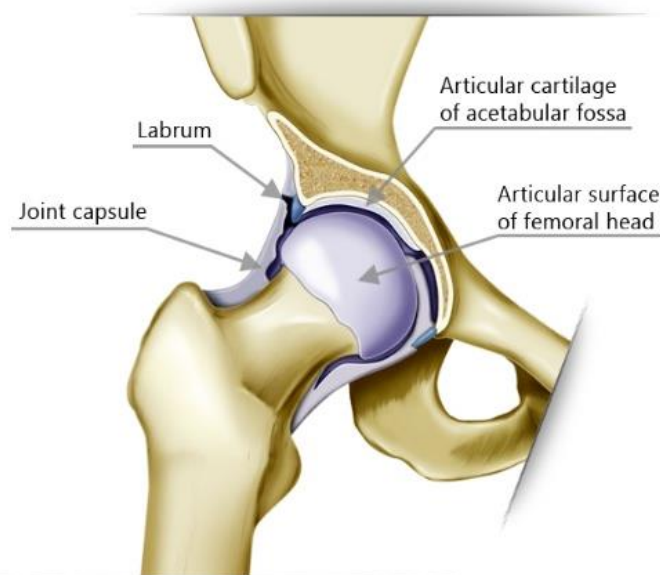


Figure 1. Structures of the hip joint.

3.2. Available Motions

- **Flexion:** forward and upward movement of the femur at the hip occurs in the sagittal plane about in a medial-lateral axis.
- **Extension:** upward movement toward the rear of the body of the femur at the hip occurring in the sagittal plane.
- **Abduction:** movement of the femur on the hip in a direction away from the midline of the body in the frontal plane.
- **Adduction:** movement of the femur on the hip in a direction toward the midline of the body in the frontal plane.
- **Internal Rotation:** rotation of the femur toward the midline of the body in the transverse plane.
- **External Rotation:** rotation of the femur away from the midline of the body in the transverse plane.

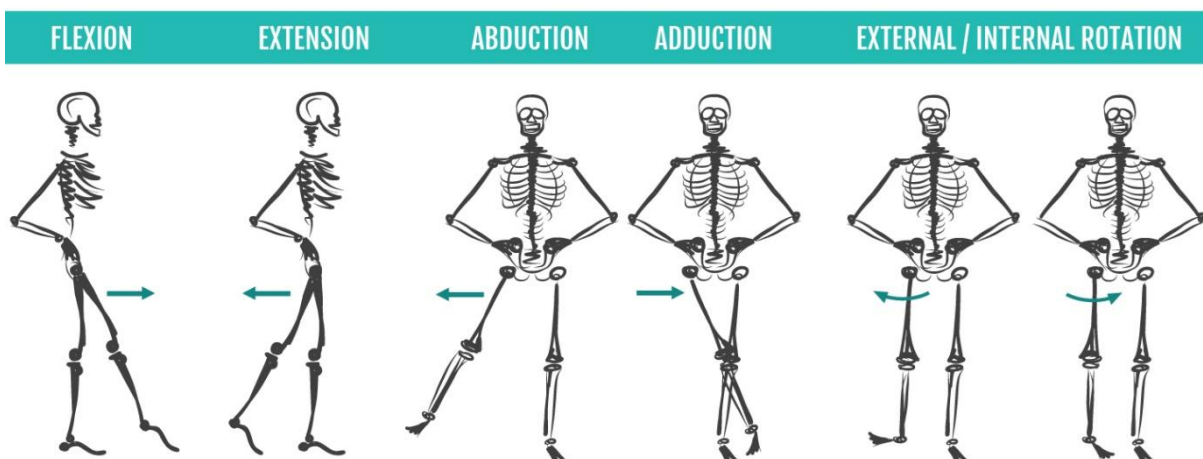


Figure 2. Visual representation of available motions of the hip joint.

3.3. Ligaments

The ligaments of the hip joint act to increase stability. They can be divided into two groups- intracapsular and extracapsular:

3.3.1 Intracapsular

The only intracapsular ligament is the **ligament of head of femur**. It is a relatively small structure, which runs from the acetabular fossa to the fovea of the femur.

It encloses a branch of the **obturator artery** (artery to head of femur), a minor source of arterial supply to the hip joint.

3.3.2 Extracapsular

There are three main extracapsular ligaments, continuous with the outer surface of the hip joint capsule:

- **Iliofemoral ligament-** attaches to the anterior inferior iliac spine and the acetabular rim proximally and the inter trochanteric line distally. Said to be the body's strongest ligament, the iliofemoral ligament prevents hyperextension of the hip joint during standing by screwing the femoral head into the acetabulum.
- **Pubofemoral ligament-** arises from the obturator crest of the pubic bone and passes laterally and inferiorly to merge with the fibrous layer of the joint capsule. This ligament blends with the medial part of the iliofemoral ligament and tightens during both extension and abduction of the hip joint. The pubofemoral ligament prevents over abduction of the hip joint.
- **Ischiofemoral ligament-** spans between the body of the ischium and the greater trochanter of the femur, reinforcing the capsule posteriorly. It prevents hyperextension and holds the femoral head in the acetabulum.

3.4. Neurovascular Supply

Arteries supplying the hip joint include the following:

- The **medial and lateral circumflex femoral arteries**, which are usually branches of the profunda femoris artery but occasionally they arise as branches of the femoral artery.
- The **artery to the head of the femur**, which is a branch of the obturator artery of variable size, it traverses the ligament of the head.

The **main blood supply** of the hip joint is from the **retinacular arteries** arising as branches of the circumflex femoral arteries. Retinacular arteries arising from the medial circumflex femoral artery are most abundant, bringing more blood to the head and neck of the femur because they are able to pass beneath the unattached posterior border of the joint capsule. Retinacular arteries arising from the lateral circumflex femoral must penetrate the thick iliofemoral ligament and are smaller and fewer.

The hip joint is innervated primarily by the **sciatic, femoral and obturator nerves**. These same nerves innervate the knee, which explains why pain can be referred to the knee from the hip and vice versa.

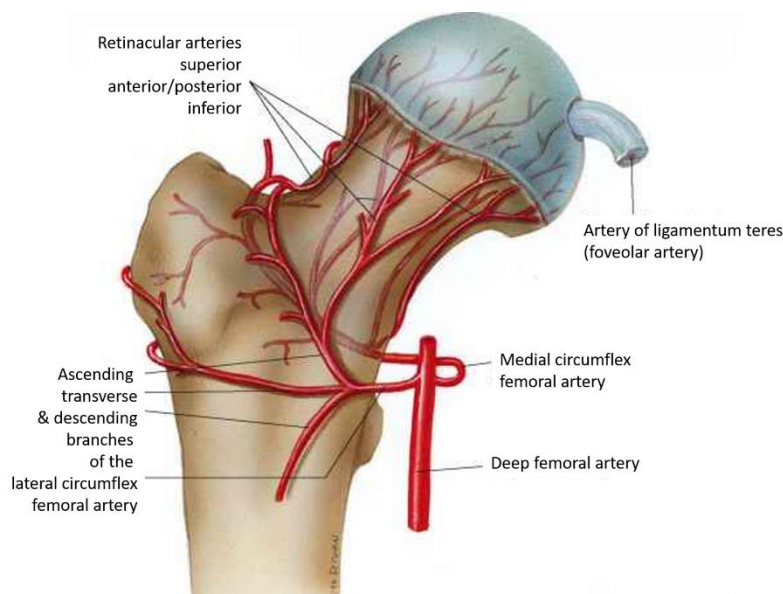


Figure 3. Vascular supply of the hip joint.

4. INCIDENCE AND PREVALENCE

The reported prevalence of hip osteoarthritis varies greatly due to differences in the definition of osteoarthritis used (radiographic, symptomatic, or self-reported) and the characteristics of the sample. A 2011 meta-analysis conducted by Pereira et al. found 27 studies of generally good quality reporting hip osteoarthritis prevalence rates from a range of countries [1]. The results of the meta-analysis showed that the reported rate varied immensely from 0.9% to 45% while radiographic rates were reported higher than symptomatic osteoarthritis per definition. When it came to gender differences, men and women showed similar overall prevalence: 11.5% for men and 11.6% for women. This differs from knee osteoarthritis where the disease is significantly more prevalent in women [1].

As far as incidence is concerned, data is limited probably because of the problems of defining it and how to determine its onset [2]. However, there also seems to be a tendency for radiographic definition to overestimate OA incidence. This can be exemplified by the study by Felson et al. [3], where in the same participants OA incidence was twice as high when radiographic definition was used. The meta-analysis reported only four cohort studies from the USA, Netherlands, and Norway, with cumulative incidence rates varying from 3.8% over 10 years to 33% over 8 years [1]. Despite the variation in reported rates, it is apparent that hip osteoarthritis is a major public health problem, and one that is likely to worsen with the ageing of the population.

5. RISK FACTORS

It seems that osteoarthritis of the hip is a condition that arises from a combination of both genetic and environmental factors. We will discuss in the treatment section how understanding the modifiable risk factors helps us prevent the disorder. Risk factors associated with hip OA can be divided into local risk factors that act on the joint level and more general risk factors.

5.1. Local Risk Factors

5.1.1. Joint Dysplasia- Conditions such as acetabular dysplasia and other developmental disorders leading to structural joint abnormalities are believed to play a major role in development of hip OA later in life [4]. Mild dysplastic changes often can go unnoticed and predispose to hip OA.

5.1.2. Trauma- Fractures involving the joint articular surface can lead to secondary posttraumatic arthritis. It is unclear whether isolated labral tears contribute to hip OA. [4]

5.2. General Risk Factors

5.2.1. Age- Increased age has been shown to be associated with an increased incidence of osteoarthritis in several studies [5]. The Research on Osteoarthritis/Osteoporosis Against Disability study,[6] which prospectively followed 745 Japanese men and 1470 Japanese women for 3 years, revealed that age greater than 60 years is an important risk factor for radiographic OA. However, it is also clear that aging of joint tissues and OA development are distinct processes. As in chondrocalcinosis, an age-related matrix change observed in

radiographs of arthritic joints, may contribute to OA by stimulating production of proinflammatory mediators [6].

5.2.2. Sex- Hip OA prevalence is higher among men younger than age 50 years, whereas women have the highest prevalence after age 50 years. [7] This finding may be attributable to postmenopausal changes [7] and is supported by observations from multiple studies that report protective effects of estrogen replacement therapy and hip OA. [7]

5.2.3. Obesity- Excess body weight is a risk factor for OA not only in weight-bearing joints, but also in the hand. [8] Excess weight produces increased load on the joint, but there is growing evidence for a metabolic contribution to OA as well [9]. Suggesting a role for circulating mediators released by the adipose tissue known as adipokines that may produce an inflammatory response [9].

5.2.4. Genetics- Several studies suggest that genetics have an important role in the etiopathogenesis of hip OA, and a twin study reported a 60% risk for hip OA attributable to genetic factors. [10] Another study demonstrated that having a first-, second-, or third-degree relative who undergoes THA for hip OA increases a person's risk for having the procedure [11].

5.2.5. Occupation- Certain occupations involving heavy manual work and high-impact sports activities are linked to OA in the hip and other joints later in life. [12] Repetitive stress and biomechanical overload, especially in the setting of a pre-existing hip joint anatomical abnormality, are likely causes. [13] However, no credible evidence demonstrates that exercise and physical activity are directly related to hip OA in the general population.

6. PATHOGENESIS

Osteoarthritis results in a progressive degradation of articular cartilage, which is the dense connective tissue at the ends of articulating bones. In the non-pathological patient, articular cartilage acts as a cushion to help glide the bone during movement and thereby protects the joint from damage during severe loading. The cartilage can prevent biomechanical damage that is caused by severe loading, however, patients with osteoarthritis hinder attempts at repair and result with a disrupted cartilage homeostasis [14]. As the articular cartilage degrades, there are also associated joint conformational changes that occur in an attempt to repair or compensate for the loss of the articular cartilage. This characterizes OA as an active repair process and not purely a degenerative disease only affecting the cartilage [15]. These changes include subchondral bone sclerosis, or thickening and hardening, and the formation of bone cysts and marginal osteophytes (bone remodeling). All of these changes cause the joint space to narrow [14]. Specifically, the changes that occur in the subchondral bone may predispose the cartilage for further damage. As the subchondral bone is less able to absorb forces/load that is placed on the joint, this may cause further degradation as the cartilage loses its integrity.

Ultimately osteoarthritis affects the whole joint due to synovial inflammation and fibrosis of the joint capsule [16]. The chondrocytes produce cytokines, chemokines, and proteolytic enzymes which are all mediators associated with inflammation that cause further damage to the cartilage [14]. These changes to the joint cause loss of range of motion/stiffness, tenderness, and pain. The development of osteoarthritis, due to the chemical and biological imbalances, can be illustrated by means of a self-sustaining vicious cycle where each step in the process influences and amplifies each other (Figure 4) [17].

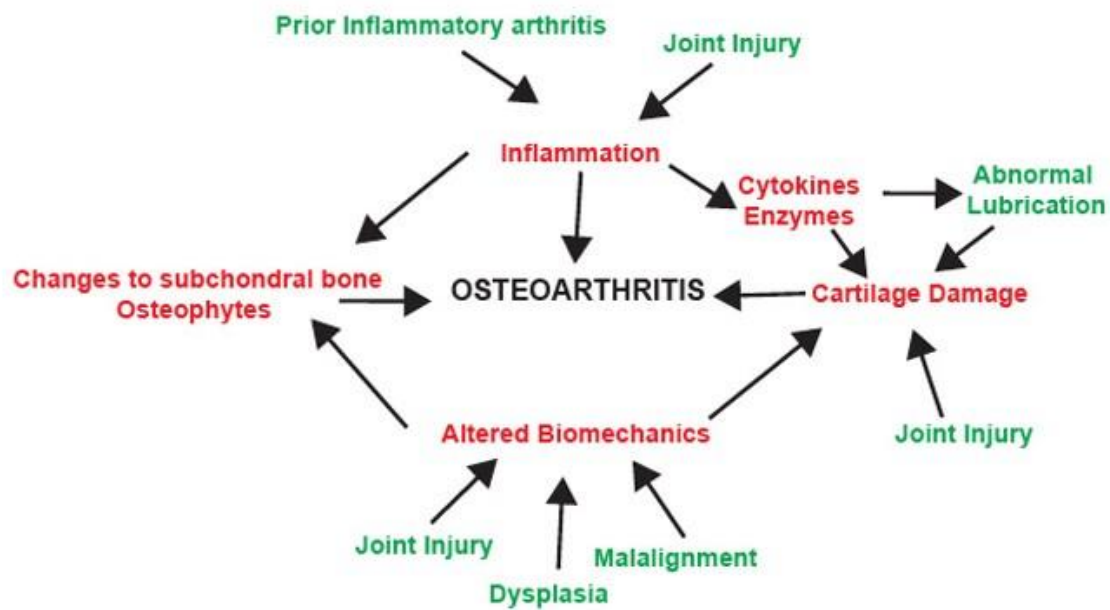


Figure 4. Osteoarthritis is a multifactorial disease with key pathways (in red) that collaborate to promote pathologic remodeling of the cartilage, bone and synovium leading to joint failure. The many ways to enter this cycle are shown in green. Adapted with permission from the American College of Rheumatology.

7. HISTORY TAKING & PHYSICAL EXAMINATION [18]

7.1. History Taking

A consultation with an orthopaedic surgeon or physiatrist would include the following: The first step during the examination is the patient interview, during which the clinician gets a description of the presenting symptoms from the patient. Taking a thorough history is an important component of the subjective examination because it will help us understand the mechanism of injury, type of the injured structures and extent of the injury or damage. We need to make sure we get a full overview regarding the pain the patient experiences such as its location, nature of the pain, a 24-hour pattern of the pain, activities that trigger the pain and if anything aggravates or relieves the pain. We should also look into the patient's family history relevant to the hip region since hereditary factors can play a role here. It's vital as well to document past and current drug history and allergies.

7.2. Physical Examination

7.2.1. General Checkup:

- Pain- we give the patient a VAS pain scale in order to determine the baseline pain level felt currently.
- Standing- we check balance and posture that might indicate a pathology
- Gait & Trendelenburg test- to determine the integrity of hip abductor muscle function and check for other pathologic gait patterns.
- Lying supine- leg length (apparent and real leg lengths), external rotation of leg.

7.2.2. Palpation:

- Tenderness experienced over the hip region
- Pain and sensitivity over the greater trochanter

7.2.3. Range of motion:

- Early signs of hip osteoarthritis are limited to abduction and rotation. As the disease progresses, flexion, extension and adduction become more difficult.
- Normally painful at end of available range of motion
- Crepitus with movement

8. SYMPTOMS [18]

According to the American Academy of Orthopaedic Surgeons the most common symptom of hip osteoarthritis is pain around the hip joint. Usually, the pain develops slowly and worsens over time, although sudden onset is also possible. Pain and stiffness may be worse in the morning, or after sitting or resting for a while. Over time, painful symptoms may occur more frequently, including during rest or at night. Additional symptoms may include:

- Pain in your groin or thigh that radiates to your buttocks or your knee.
- Pain that flares up with vigorous activity.
- Stiffness in the hip joint that makes it difficult to walk or bend.
- "Locking" or "sticking" of the joint, and crepitus during movement caused by loose fragments of cartilage and other tissue interfering with the smooth motion of the hip.
- Decreased range of motion in the hip that affects the ability to walk and may cause a limp.
- Increased joint pain with rainy weather.

9. DIFFERENTIAL DIAGNOSIS

- Trochanteric bursitis- presents with lateral hip pain radiating down the lateral leg, with associated point tenderness over the greater trochanter.
- Gluteus medius tendinopathy- lateral hip pain with point tenderness over the muscle insertion at the greater trochanter.

- Sciatica- lower back pain and buttock pain, but often radiates down the posterior leg to below the knee. Diagnosis is made with the straight leg raise to produce Lasègue’s sign.
- Femoral neck fracture- most commonly there will be a history of trauma or known severe osteoporosis (if it is a stress fracture), the patient will be unable to bear weight due to pain and the limb will appear shortened and externally rotated.

10. DIAGNOSIS

10.1. Diagnostic Procedure

The American College of Rheumatology have established criteria that are commonly used for the diagnosis of hip OA in clinical practice (Table 1) [19].

Clinical criteria A	Clinical criteria B	Clinical plus radiographic criteria
Hip pain; AND	Hip pain; AND	Hip pain; AND any 2 of the following:
Hip internal rotation <15°; AND	Pain with internal hip rotation; AND	ESR <20 mm/h
ESR ≤45 mm/h or hip flexion ≤115° if ESR unavailable	Morning stiffness of hip ≤60 min; AND	Radiographic femoral and/or acetabular osteophytes
	Over 50 years of age	Radiographic joint space narrowing

Table 1. American College of Rheumatology criteria for the diagnosis of hip osteoarthritis [19].

It is often possible to diagnose hip OA on the basis of clinical presentation alone, although radiographic investigation can be useful to confirm the diagnosis and to monitor disease progression. The most common system for measuring radiographic OA severity is the Kellgren and Lawrence grade [Table 2], which uses a five-point scale between 0 and 4, with grades of 2 and higher indicating radiographic OA [20]. Higher K&L grades demonstrate increased joint space narrowing, increased osteophyte involvement, and subchondral sclerosis.

Grade	Description
0	No radiographic features of osteoarthritis
1	Possible joint space narrowing and osteophyte formation
2	Definite osteophyte formation with possible joint space narrowing
3	Multiple osteophytes, definite joint space narrowing, sclerosis and possible bony deformity
4	Large osteophytes, marked joint space narrowing, severe sclerosis and definite bony deformity

Table 2. The Kellgren and Lawrence grading system [20].

Symptomatic disease progression can also be monitored with patient-reported outcomes such as the Oxford Hip Score. There is substantial discord between symptoms and radiographic findings; a high proportion of those with radiographic features of hip OA are asymptomatic, and a similarly high proportion of those with symptoms suggestive of hip OA lack radiographic evidence [21]. Consideration of both clinical and radiographic severity is relevant to direct clinical management.

10.2. Radiographic Investigation

Investigations used in hip osteoarthritis are dominated by the simple plain radiograph. An adequate X-ray of the pelvis will allow characterisation of the disease extent and even detailed preoperative planning in the vast majority of cases. There are 4 radiographic findings classically described when describing osteoarthritis of the hip joint:

1. Loss of joint space
2. Osteophyte formation
3. Subchondral sclerosis
4. Subchondral cysts

Loss of cartilage through the pathological mechanisms already discussed leads to an approximation of the acetabular and femoral bone on plain radiograph. With disease progression, the bony ends appear to be in direct contact due to the complete destruction of all articular cartilage. Cartilage is not ossified in the normal hip and so it is radiolucent giving the appearance of an apparent 'joint space'. Loss of cartilage therefore gives rise to a loss of this joint space.

Osteophytes are the metaplastic osseous and cartilaginous tissues found at the rim of articular surfaces of joints that experience subtle instability. They may play a number of roles including protection of articular cartilage and redistribution of stresses borne by the hip joint [22]. Interestingly, Tsurumoto et al. described the relationship between the severity of stress experienced by an osteoarthritic joint and the size of osteophyte. It was demonstrated that joints subjected to higher stresses were likely to develop larger osteophytes [23]. In this way, osteophytes may act as a surrogate marker for the severity of degeneration in the hip. Due to microscopic and macroscopic changes in the structural integrity of cartilage, areas of weakening develop. These are known as subchondral cysts. Areas of reactive sclerosis develop as a generic response to injury. This accounts for the common radiographic finding of subchondral cysts and subchondral sclerosis observed in severe cases of hip osteoarthritis (Figure 5).

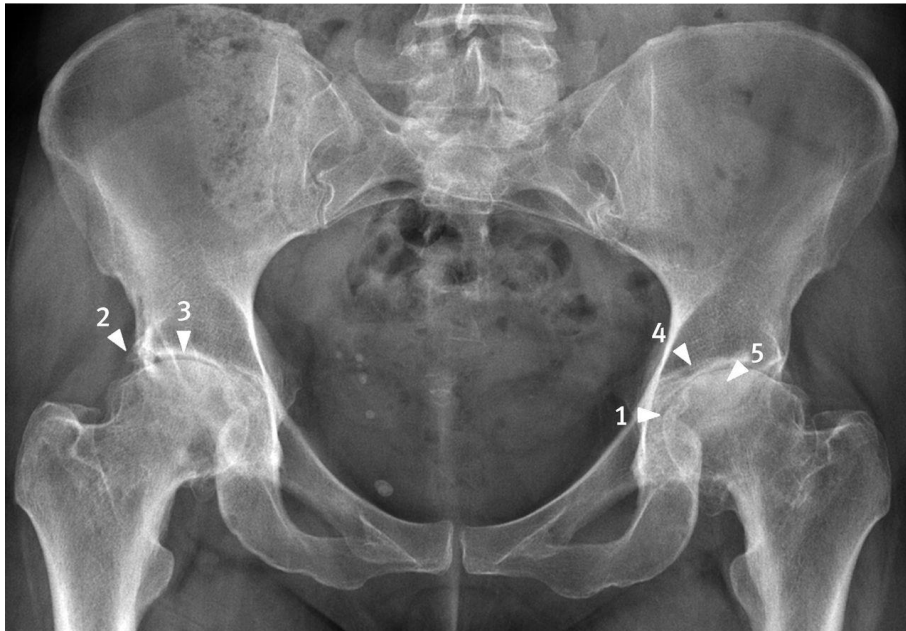


Figure 5. Typical plain radiograph of bilateral hip osteoarthritis. Notice the loss of joint space (1), osteophytes (2), subchondral sclerosis (3), and subchondral cysts (4). In this advanced case, there is also evidence of deformity of the femoral head (5). Joint space narrowing is the best diagnostic criterion. Adapted with permission from Croft P et al (1990) [24].

11. TREATMENT

Medical management of hip osteoarthritis focuses on treating the symptoms. The optimal management of hip osteoarthritis consists of a combination of pharmaceutical and non-pharmaceutical treatment modalities. It is also important to take the patient's wishes and expectations into consideration.

11.1. Non-Pharmacological Treatments

11.1.1. Exercise

According to a meta-analysis conducted by Fransen et al. exercise therapy has been shown to provide profound symptomatic relief for patients suffering from hip osteoarthritis [25]. They noted that the therapy should not consist of high impact activities and should be combined with exercises that strengthen and stretch the muscles around the hip in order to support the

joint and ease hip strain. In addition to the pain relief, participants in the studies reported a “higher quality of life and physical wellbeing”. In a pilot trial conducted by Uusi-rasi et al. spanning over 12 weeks found that “Exercise programs focusing on improving aerobic capacity, quadriceps muscle strength, or lower extremity performance carried out 3 times weekly are considered optimal for treatment”. Though it should be noted that further controlled studies with larger group sizes are needed to determine the long-term benefits of exercise and its effects on the progression of the disease [26].

Exercise therapy goes hand in hand with the next therapy we will discuss- weight reduction

11.1.2. Weight Reduction

We mention under the risk factors section how obesity has been shown to predispose individuals to osteoarthritis. Not surprisingly then weight reduction can be used not only as a preventive measure but as a treatment as well. According to Reyes et al. “gaining 10 pounds can exert an extra 60 pounds of pressure upon a hip with each step.” [27] Unloading the joint through weight loss can slow cartilage loss and decrease joint impact.

Therefore, an individualized exercise program combined with effective behavioural strategies aimed at weight loss may be most beneficial in reducing pain for overweight patients. One worthy of mentioning large clinical trial, the Arthritis, Diet, and Activity Promotion Trial (ADAPT) study, randomized 316 overweight or obese older subjects with knee OA to exercise only (combined aerobic and strengthening), dietary weight loss only, exercise plus dietary weight loss or a healthy lifestyle control group. After 18 months, despite only modest reductions in body weight, significant improvements in pain and physical function were seen in the diet plus exercise group. [28]

11.1.3. Physical Therapy

According to Zhang et al. referral to a physical therapist should be given according to the state of the condition. In mild and early hip OA, the aim is to strengthen the hip muscles and to maintain joint mobility. However, physical therapy provided during the later stages of hip OA may give little to no benefit [29].

11.1.4. Assistive Devices

Walking sticks and canes should be considered as adjuncts to core treatments for people with OA who have specific problems with activities of daily living. Assistive devices can improve mobility and independence of the patient. If needed, patients can be referred for further evaluation and treatment from occupational and physical therapists and/or specialized disability device and equipment companies [32]. In the occupational therapy setting the therapist can teach patients to work with functional assistive devices like a long-handled reacher to pick up low-lying things, which will help avoid movements that may cause pain.

11.1.5. Tai Chi

Tai Chi is an ancient Chinese tradition that today is practiced as a graceful form of exercise. It involves a series of movements performed in a slow, focused manner and accompanied by deep breathing. A meta-analysis conducted in 2013 examined the possibility of alleviating pain and reducing stiffness by practicing Tai Chi. It concluded that “twelve-week Tai Chi is beneficial for improving arthritic symptoms and physical function in patients with osteoarthritis and should be included in rehabilitation programs” [30]. These findings are also recognized by the conventional establishment and by the ACR guidelines [31]. However, the evidence is not clear cut and is as of today limited. More research with larger scale randomized controlled trials are needed to confirm the findings stated above and investigate the long-term effects of Tai Chi [30].

11.2. Pharmacologic Therapy

We use pharmacologic agents for patients with symptomatic OA who have not responded adequately to initial nonpharmacologic measures or concomitantly with these interventions for those with more severe symptoms [33]. Use of pharmacologic therapy should only be considered during periods when symptoms are present, this is because the medications are not disease modifying. If decided to use pharmacologic intervention we must make sure the benefits will outweigh the potential toxicities and that the treatment is individualized according to patient symptoms, preferences, and a therapeutic agent's overall safety profile. In the case where the symptoms of pain or disability persist despite trial of the different medications and dosages, or when controlling symptoms requires long-term opioids, high-dose acetaminophen or NSAIDs, and repeated intra-articular injections, referral for surgical options should be considered [33].

In the past, acetaminophen (paracetamol) used to be the first-line medication used in treatment for symptomatic pain relief. However, due to the latest data findings it has been increasingly apparent that the medication raises questions regarding its safety of use and holds negligible and non-clinically significant effects on symptomatic pain [34,35]. As a result, the updated clinical guidelines state to no longer prescribe the medication as freely as before [36].

The current approach to pharmacotherapy is as follows:

11.2.1. Oral NSAIDs

According to the American College of Rheumatology guidelines oral NSAIDs are the mainstay of the pharmacologic management of OA, and their use is strongly recommended. A large number of trials have established their short-term efficacy [31].

When treating with oral NSAIDs we aspire to use the lowest dose possible to control the patient's symptoms. This is in order to limit the risks of side effects and complications in the gastrointestinal, cardiovascular and renal systems. In patients at greater GI risk, there is evidence that NSAIDs should be used in combination with a proton pump inhibitor or misoprostol for gastroprotection, or that the use of a COX-2 selective agent should be considered [37,38].

11.2.2. Glucocorticoid Injection

Multiple systematic reviews conclude that GC injections are effective for relieving pain [37]. Although there is some evidence that GC injections may have a harmful effect on the patient's hyaline cartilage [41,42], the ACR states that it is "uncertain of the clinical significance of this finding, particularly since change in cartilage thickness was not associated with a worsening in pain, functioning, or other radiographic features" [31]. When available, deliverance of the GC injection should be done via ultrasound guidance. This will help ensure an accurate and correct injection into the joint site.

11.2.3. Duloxetine

Is an antidepressant of the SNRI family which is conditionally recommended for patients with OA in multiple joints and concomitant comorbidities that may contraindicate oral NSAIDs or for patients with hip OA who have not responded satisfactorily to other interventions. It's important to be aware of the fact that the combination of depression and osteoarthritis are both common and often coexist. Multiple studies have demonstrated that psychosocial factors are equally or more important than disease-specific factors in reports of pain intensity and disability in several conditions, including joint pain [39,40].

Awareness and treatment of depressive symptoms can result in significantly less pain and improved quality of life [39,40]. In one study of older adults with arthritis and comorbid depression, treatment of depression extended beyond improved mood to significant improvement in pain, function, and quality of life [40].

11.2.4. Opioids

Opioids such as Tramadol are only conditionally recommended as well and considered for short term use in patients with severe and disabling symptoms in whom other interventions have failed or are not appropriate. This is because of their overall small effect on pain over placebo, potential side effects and high chance of long-term dependence [32].

11.3. Surgical Interventions

The goals of the surgical management of patients with osteoarthritis are to reduce or eliminate pain, minimize disability, and improve the quality of life. Treatments should be individualized to the patient's functional status, disease severity, occupational and vocational needs, and the nature of any coexisting medical problems. The patient's expectations should be discussed to ensure they are realistic.

Surgical interventions for patients with OA are generally reserved for those who have failed less invasive modes of therapy. In this section we will discuss the effectiveness of surgical approaches used to treat OA.

11.3.1. Total Hip Arthroplasty

A total hip replacement is a surgical procedure in which both damaged surfaces of the hip joint are replaced with prosthetic substitutes.

It is currently the gold standard treatment in patients with severe end-stage symptomatic osteoarthritis who have failed to respond to nonpharmacologic and pharmacologic management and who have significant impairment in their quality of life due to OA [43]. Evidence shows that post surgery there is substantial pain relief and improved functional improvement reported by patients with severe hip OA [44]. As reported by Bayliss et al. currently, more than 95% of artificial hip joints survive beyond 10 years and many routinely do so beyond 30 years [45].

Alternatives to total hip arthroplasty:

11.3.2. Hemiarthroplasty

A surgical procedure which replaces one half of the joint with an artificial surface and leaves the other part in its natural (pre-operative) state. The procedure is recommended only for elderly and frail patients, due to their lower life expectancy and activity level. This is because with the passage of time the prosthesis tends to loosen or to erode the acetabulum [46].

11.3.3. Total Hip Resurfacing

Hip resurfacing has been developed as a surgical alternative to total hip replacement. The procedure consists of placing a cap (usually made of cobalt-chrome metal), over the head of the femur while a matching metal cup is placed in the acetabulum (pelvis socket), replacing the articulating surfaces of the patient's hip joint and removing very little bone compared to a THR. Although it does stand as a potential alternative procedure to THR it has been observed that it may induce serious adverse reactions associated with the toxic effects of the metal ions from the bearings [47].

In addition, an analysis of long-term data from several national registries found greater rates of re-revision following resurfacing compared with total hip arthroplasty and generally poorer outcomes [48].

11.3.4. Hip Osteotomy

Osteotomy is not commonly used to treat OA but does offer a solution in certain cases such as background hip developmental dysplasia or hip impingement in the absence of advanced OA.

11.3.5. Arthroscopic debridement

There is no established role for the use of hip arthroscopy in the treatment of advanced OA of the hip. There is prior evidence that arthroscopic debridement of the labrum in patients older than 45 has minimal benefit for pain and function and should be only be considered with caution [49].

12. CONCLUSION

Osteoarthritis is a chronic disorder affecting synovial joints and a leading cause of disability worldwide. As stated above it appears currently that hip OA results from a number of distinct conditions, each providing a unique etiologic factor to conjoin to a common final pathway. Pain around the hip joint area is the most common symptom, usually developing slowly and worsening over time but can also have a sudden onset. The symptoms or lack thereof do not always coincide with radiographic findings. Therefore, it's important that a thorough history and physical examination be conducted in order to aid in a correct diagnosis and management approach. Treatment should be accustomed according to how developed the condition is. Where early OA should be first managed with non-pharmacological and pharmacologic (mainly NSAIDS) options. More evidence in the past years are demonstrating that OA is disease directly affected by the patient's life style and that a change of diet and more physical exercise should be a mainstay treatment. While patients suffering from advanced disease should be referred to orthopedic surgery (usually THA). With more research being conducted on this subject, novel and more clinical study-based treatments are expected to advance our ability to manage the condition in the future. Be it pharmacological or surgical, we will be able to provide better quality of life and ability to cope with the condition in years to come.

13. ACKNOWLEDGEMENT

I would like to acknowledge my mentor Prof. Porin Perić, MD, PhD. of KBC Rebro for mentoring me on my work. I am very grateful for his support and positive feedback. I want to thank my family for all their unconditional love and incredible support I got during my medical school years. I will never be able to thank them enough and I am so grateful and respectful for all the sacrifices they did for me. Lastly, a big thank you to all my friends and wonderful people I met during this journey. They will always be in my heart and I am positive we will hear from each other in the coming future.

13. REFERENCES

1. D. Pereira, B. Peleteiro, J. Araujo, J. Branco, R.A. Santos, E. Ramos. The effect of osteoarthritis definition on prevalence and incidence estimates: a systematic review. *Osteoarthritis & Cartilage*, 19 (2011), pp. 1270-1285.
2. C.E. Chaisson, Y. Zhang, T.E. McAlindon, M.T. Hannan, P. Aliabadi, A. Naimark, *et al.* Radiographic hand osteoarthritis: incidence, patterns, and influence of pre-existing disease in a population based sample *J Rheumatol*, 24 (7) (1997 Jul), pp. 1337-1343
3. D.T. Felson, Y. Zhang, M.T. Hannan, A. Naimark, B.N. Weissman, P. Aliabadi, *et al.* The incidence and natural history of knee osteoarthritis in the elderly. The Framingham Osteoarthritis Study *Arthritis Rheum*, 38 (10) (1995 Oct), pp. 1500-1505.
4. Murphy NJ, Eyles JP, Hunter DJ. Hip osteoarthritis: Etiopathogenesis and implications for management. *Advances in therapy* 2016;33(11):1921-46.
5. Saase JL, Romunde LK, Cats A, Vandenbroucke JP, Valkenburg HA. Epidemiology of osteoarthritis: zoetermeer survey. Comparison of radiological osteoarthritis in a Dutch population with that in 10 other populations. *Ann Rheum Dis*. 1989;48(4):271-80.
6. Muraki S, Akune T, Oka H, *et al.* Incidence and risk factors for radiographic knee osteoarthritis and knee pain in Japanese men and women: A longitudinal population-based cohort study. *Arthritis Rheum*. 2012 May;64(5):11-56.
7. Felson DT. Epidemiology of hip and knee osteoarthritis. *Epidemiol Rev*. 1988;10:1-28.
8. Oliveria SA, Felson DT, Cirillo PA, Reed JI, Walker AM. Body weight, body mass index, and incident symptomatic osteoarthritis of the hand, hip, and knee. *Epidemiology*. 1999 Mar;10(2):161-6.
9. Sellam J, Berenbaum F. Is osteoarthritis a metabolic disease? *Joint Bone Spine*. 2013 Dec;80(6):568-73.

10. MacGregor AJ, Antoniadou L, Matson M, Andrew T, Spector TD. The genetic contribution to radiographic hip osteoarthritis in women: Results of a classic twin study. *Arthritis Rheum.* 2000 Nov;43(11):2410–6.
11. Pelt CE, Erickson JA, Peters CL, Anderson MB, Cannon-Albright L. A heritable predisposition to osteoarthritis of the hip. *J Arthroplasty.* 2015 Sep;30(9 Suppl):125–9.
12. Kujala UM, Kaprio J, Sarna S. Osteoarthritis of weight bearing joints of lower limbs in former elite male athletes. *BMJ.* 1994 Jan 22;308(6923):231–4.
13. Sulsky SI, Carlton L, Bochmann F, et al. Epidemiological evidence for work load as a risk factor for osteoarthritis of the hip: A systematic review. *PLoS One.* 2012;7(2):e31521.
14. Wieland, H. A., Michaelis, M., Kirschbaum, B. J., & Rudolphi, K. A. (2005). Osteoarthritis—an untreatable disease?. *Nature reviews Drug discovery*, 4(4), 331-344.
15. Brandt, K. D., Radin, E. L., Dieppe, P. A., & Van De Putte, L. (2006). Yet more evidence that osteoarthritis is not a cartilage disease. *Annals of the Rheumatic Diseases*, 65(10), 1261-1264.
16. Poulet, B., Hamilton, R. W., Shefelbine, S., & Pitsillides, A. A. (2011). Characterizing a novel and adjustable noninvasive murine joint loading model. *Arthritis & Rheumatism*, 63(1), 137-147.
17. Antonios Aliprantis, New Therapeutics for Osteoarthritis May Be in Sight. <https://www.the-rheumatologist.org/article/new-therapeutics-for-osteoarthritis-may-be-in-sight/2/> (accessed 23/04/2020).
18. American Academy of Orthopaedic Surgeons. Diseases and conditions: Osteoarthritis of the hip. <https://orthoinfo.aaos.org/en/diseases--conditions/osteoarthritis-of-the-hip> (accessed 23/04/2020).

19. Altman R, Alarcon G, Appelrouth D, et al. The American College of Rheumatology criteria for the classification and reporting of osteoarthritis of the hip. *Arthritis Rheum.* 1991;34(5):505–14.
20. Kellgren JH. *Atlas of standard radiographs: the epidemiology of chronic rheumatism.* Oxford: Oxford University Press; 1963.
21. Pereira D, Peleteiro B, Araujo J, Branco J, Santos RA, Ramos E. The effect of osteoarthritis definition on prevalence and incidence estimates: a systematic review. *Osteoarthr Cartil.* 2011;19(11):1270–85.
22. Mao Y, Yu D, Xu C, Liu F, Li H, Zhu Z. The fate of osteophytes in the superolateral region of the acetabulum after total hip arthroplasty. *The Journal of Arthroplasty.* 2014;29(12):2262-2266.
23. Tsurumoto TSK, Okamoto K, Imamura T, Maeda J, Manabe Y, Wakebe T. Periarticular osteophytes as an appendicular joint stress marker (JSM): Analysis in a contemporary Japanese skeletal collection. *PLoS One.* 2013;8(2):e57049.
24. Croft P, Cooper C, Wickham C, Coggon D. Defining osteoarthritis of the hip for epidemiologic studies. *Am J Epidemiol*1990;132:514-22.
25. Fransen M, McConnell S, Hernandez-Molina G, Reichenbach S. Exercise for osteoarthritis of the hip. *Cochrane Database Syst Rev* 2014 Apr 22;(4):CD007912.
26. Uusi-Rasi K, Patil R, Karinkanta S, Tokola K, Kannus P, Sievänen H. Exercise training in treatment and rehabilitation of hip osteoarthritis: a 12-week pilot trial. *Journal of Osteoporosis.* 2017;2017:1–7.
27. Reyes C, Leyland KM, Peat G, Cooper C, Arden NK, Prieto-Alhambra D. Association between overweight and obesity and risk of clinically diagnosed knee, hip, and hand osteoarthritis: A population-based cohort study. *Arthritis Rheumatol* 2016 Aug;68(8):1869-75.

28. Messier, S.P., Loeser, R.F., Miller, G.D., Morgan, T.M., Rejeski, W.J., Sevick, M.A. et al. (2004) Exercise and dietary weight loss in overweight and obese older adults with knee osteoarthritis: the Arthritis, Diet, and Activity Promotion Trial. *Arthritis Rheum* 50: 1501-1510.
29. Zhang W, Doherty M, Arden N, et al; EULAR Standing Committee for International Clinical Studies Including Therapeutics (ESCSIT). EULAR evidence based recommendations for the management of hip osteoarthritis: Report of a task force of the EULAR Standing Committee for International Clinical Studies Including Therapeutics (ESCSIT). *Ann Rheum Dis* 2005 May;64(5):669-81.
30. Yan JH, Gu WJ, Sun J, Zhang WX, Li BW, Pan L. Efficacy of Tai Chi on pain, stiffness and function in patients with osteoarthritis: a meta-analysis. *PLoS One*. 2013;8(4):e61672. Published 2013 Apr 19.
31. Kolasinski SL, Neogi T, Hochberg MC, et al. 2019 American College of Rheumatology/Arthritis Foundation Guideline for the Management of Osteoarthritis of the Hand, Hip, and Knee. *Arthritis Care Res (Hoboken)*. 2020;72(2):149-162.
32. Hochberg MC, Altman RD, April KT, et al; American College of Rheumatology. American College of Rheumatology 2012 recommendations for the use of nonpharmacologic and pharmacologic therapies in osteoarthritis of the hand, hip, and knee. *Arthritis Care Res (Hoboken)* 2012 Apr;64(4):465-74.
33. Stephen Kennedy, Michael Moran, et al. Issue: BCMJ, vol. 52 , No. 8 , October 2010 , Pages 404-409 Clinical Articles.
34. Machado GC, Maher CG, Ferreira PH, et al. Efficacy and safety of paracetamol for spinal pain and osteoarthritis: systematic review and meta-analysis of randomised placebo controlled trials. *BMJ* 2015; 350:h1225.

35. Roberts E, Delgado Nunes V, Buckner S, et al. Paracetamol: not as safe as we thought? A systematic literature review of observational studies. *Ann Rheum Dis* 2016; 75:552.
36. Bannuru RR, Osani MC, Vaysbrot EE, et al. OARSI guidelines for the non-surgical management of knee, hip, and polyarticular osteoarthritis. *Osteoarthritis Cartilage* 2019; 27:1578.
37. Zhang W, Moskowitz RW, Nuki G, et al. OARSI recommendations for the management of hip and knee osteoarthritis, part II: OARSI evidence-based, expert consensus guidelines. *Osteoarthritis Cartilage* 2008;16:137-162.
38. Richmond J, Hunter D, Irrgang J, et al. Treatment of osteoarthritis of the knee (nonarthroplasty). *J Am Acad Orthop Surg* 2009;17:591-600.
39. Vranceanu AM, Barsky A, Ring D. Psychosocial aspects of disabling musculoskeletal pain. *J Bone Joint Surg Am* 2009;91:2014-2018.
40. Lin EH, Katon W, Von Korff M. Effect of improving depression care on pain and functional outcomes among older adults with arthritis: A randomized controlled trial. *JAMA* 2003;290:2428-2434.
41. Kompel AJ, Roemer FW, Murakami AM, et al. Intra-articular Corticosteroid Injections in the Hip and Knee: Perhaps Not as Safe as We Thought? *Radiology* 2019; 293:656.
42. McAlindon TE, LaValley MP, Harvey WF, et al. Effect of Intra-articular Triamcinolone vs Saline on Knee Cartilage Volume and Pain in Patients with Knee Osteoarthritis: A Randomized Clinical Trial. *JAMA* 2017; 317:1967.
43. Mandl LA. Determining who should be referred for total hip and knee replacements. *Nat Rev Rheumatol* 2013; 9:351.
44. Buckwalter JA, Lohmander S. Operative treatment of osteoarthrosis. Current practice and future development. *J Bone Joint Surg Am* 1994; 76:1405.

45. Bayliss LE, Culliford D, Monk AP, et al. The effect of patient age at intervention on risk of implant revision after total replacement of the hip or knee: a population-based cohort study. *Lancet* 2017; 389: 1424–30.
46. van der Meulen, M.C.H.; Allen, W.A.; Giddings, V.L.; Athanasiou, K.A.; Poser, R.D.; Goodman, S.B.; Smith, R.L.; Beaupré, G.S. "Effect of hemiarthroplasty on acetabular cartilage". 1996 Project Reports. VA Palo Alto Health Care System's Bone and Joint Rehabilitation Research and Development Center.
47. Crawford R, Ranawat CS, Rothman RH. Metal on metal: Is it worth the risk? *J Arthroplasty* 2010; 25:1.
48. Corten K, MacDonald SJ. Hip resurfacing data from national joint registries: What do they tell us? What do they not tell us? *Clin Orthop Relat Res* 2010; 468:351.
49. Wilkin G, March G, Beaulé PE. Arthroscopic acetabular labral debridement in patients forty-five years of age or older has minimal benefit for pain and function. *J Bone Joint Surg Am* 2014; 96:113.