

Neonatal ovarian cyst management

Förster, Mira Jennifer Vanessa Elisa

Master's thesis / Diplomski rad

2020

Degree Grantor / Ustanova koja je dodijelila akademski / stručni stupanj: **University of Zagreb, School of Medicine / Sveučilište u Zagrebu, Medicinski fakultet**

Permanent link / Trajna poveznica: <https://um.nsk.hr/um:nbn:hr:105:943688>

Rights / Prava: [In copyright](#)/[Zaštićeno autorskim pravom.](#)

Download date / Datum preuzimanja: **2024-03-03**



Repository / Repozitorij:

[Dr Med - University of Zagreb School of Medicine Digital Repository](#)



**UNIVERSITY OF ZAGREB
SCHOOL OF MEDICINE**

Mira Jennifer Vanessa Elisa Förster

Management of Neonatal Ovarian Cysts

GRADUATE THESIS



Zagreb, 2020.

This graduate thesis was made at Klinika za dječje bolesti Zagreb (Clinic for Children's Diseases Zagreb) -"Klaićeva"- in the department of Pediatric surgery (Dječja kirurgija) mentored by Doc. dr. sc. Stjepan Višnjić and was submitted for evaluation in the academic year 2019/2020.

List of Abbreviations

AFP = alpha feto protein

ALET = assisted laparoscopic excision technique

CBC = complete blood count

hCG = human chorionic gonadotropin

ICU = intensive care unit

KDB = Klinika za dječje bolesti Zagreb

LATEC = laparoscopic-assisted transumbilical extracorporeal cystectomy

LDH = lactic dehydrogenase

MCDK = multicystic dysplastic kidney

MRI = magnetic resonance imaging

NGT = nasogastric tube

NSE = neuron-specific enolase

PHD = pathohistological diagnosis

US = ultrasound

Table of contents

Summary

Sažetak

1	Preface.....	1
1.1	Epidemiology.....	1
1.2	Classification.....	1
1.2.1	According to morphology.....	1
1.2.2	According to size.....	2
1.3	Etiology.....	2
1.4	Signs and symptoms.....	2
1.5	Ovarian torsion.....	3
1.6	Diagnosis.....	3
1.6.1	Diagnosing neonatal ovarian cysts.....	3
1.6.2	Assessment of neonatal ovarian cysts.....	3
1.6.3	Diagnosis of ovarian and adnexal torsion.....	4
1.7	Differential diagnosis of neonatal ovarian cysts.....	4
1.8	Complications due to neonatal ovarian cysts.....	5
1.8.1	Short-term complications.....	5
1.8.1.1	By mass effect.....	5
1.8.1.2	By bleeding.....	5
1.8.2	Long-term complications.....	5
1.9	Treatment.....	6
1.9.1	Conservative treatment.....	6
1.9.2	Surgical treatment.....	7
1.9.2.1	Oophorectomy.....	7
1.9.2.2	Preservation.....	7
1.10	Operative techniques.....	9
1.10.1	Laparotomy.....	9
1.10.2	Laparoscopy.....	9
1.10.3	Hybrid surgery.....	10
2.	Hypothesis.....	11
3.	Objectives.....	11
4.	Materials and Methods.....	12
4.1	Study design.....	12
4.2	Inclusion and Exclusion criteria.....	12
4.3	Data collection.....	12

4.3.1 General information about procedure	12
4.3.2 Data (variables) collected	13
4.4 Treatment protocols	14
4.4.1 General treatment protocols	14
4.4.2 Specific surgical treatment protocol	14
4.5 Outcomes	15
4.6 Statistical analysis	15
4.7 Ethical approval	15
5. Results	15
6. Discussion	22
7. Conclusions	24
8. Appendix	25
Appendix Table A Surgical Treatment Group (Group 1 and 2)	25
Appendix Table B Surgical Treatment Group (Group 1 and 2)	26
Appendix Table C Surgical Treatment Group (Group 1 and 2)	27
Appendix Table D Surgical Treatment Group (Group 1 and 2)	28
Appendix Table E Surgical Treatment Group (Group 1 and 2)	29
Appendix Table F Conservative Treatment Group (Group 3)	30
Appendix Table G Conservative Treatment Group (Group 3)	31
9. Acknowledgements	32
10. References	33
11. Biography	37

Summary

Title: “Neonatal ovarian cyst management”

Author: Mira Jennifer Vanessa Elisa Förster

Objective: To assess the short-term surgical outcomes of treatment of neonatal ovarian cysts in the department of pediatric surgery at KDB Zagreb using two operative modalities - classical laparotomy and a hybrid approach (combination of laparoscopy and open surgery). The two treatment groups were compared with regards to operating times, length of hospital stay, time spent in the ICU, postoperative care and indications for surgery. Another goal was to investigate the criteria used for the neonatal ovarian cyst management and it included a third group of patients that were treated conservatively.

Methods: A retrospective study was performed analyzing medical records of neonates that had been diagnosed and managed for neonatal ovarian cysts. Continuous numerical data was presented as mean \pm SD or mean and range (minimum-maximum) and differences between groups compared using the two-sample t-test (assuming unequal variances) and the single-factor ANOVA test.

Results: The operating times were shorter in the hybrid group (44 ± 15 minutes) than in the laparotomy group (56 ± 18 minutes) but the difference was not statistically significant ($p=0,23$). The length of hospital stay was shorter in the hybrid group ($7,2 \pm 1,2$ days) than in the laparotomy group ($10,8 \pm 3,1$ days; $p= 0,03$). The time spent in the ICU was shorter in the hybrid group ($0,4 \pm 0,9$ days) than in the laparotomy group ($3,6 \pm 2,5$; $p=0,02$). Antibiotics, opioid analgesics, H2 blockers were not used in the postoperative care of the hybrid group and there were less changes in wound dressing and less CBCs were ordered in the hybrid group ($1,0 \pm 0,7$) compared to the laparotomy group ($4,4 \pm 3,7$). Indications for surgery were cyst size, either excessive (≥ 6 cm), persistent (≥ 4 cm) or an increase in cyst size (open: $n=4$; hybrid: $n=3$) and the presence of a complex cyst based on US findings (open: $n=3$; hybrid: $n=2$). There were significant differences in the cyst sizes on prenatal US in the 3 treatment groups ($p=0,03$).

Conclusion: Neonatal ovarian cysts can be safely and successfully managed surgically using a hybrid approach with better cosmetic results and better short-term postoperative outcomes than traditional laparotomy, given the proper indication for surgery.

Key words: ovarian cyst, neonate, laparotomy, hybrid surgery

Sažetak

Naslov: Liječenje novorođenačke ciste ovarija

Autor: Mira Jennifer Vanessa Elisa Förster

Cilj: Procijeniti kratkoročne kirurške ishode liječenja novorođenačke ciste jajnika, na odjelu dječje kirurgije KDB Zagreb koristeći dva operativna modaliteta - klasična laparotomija i hibridni pristup (kombinacija laparoskopije i otvorene kirurgije). Dvije skupine liječenja uspoređene su s obzirom na vrijeme trajanja boravka u bolnici, vrijeme provedeno u operativnoj njezi i indikacije za operaciju. Drugi cilj bilo je istražiti kriterije koji se koriste za liječenje novorođenačke ciste jajnika te je uključivao treću skupinu bolesnika koji su liječeni konzervativno.

Metode: Napravljena je retrospektivna studija kojom se analizirala medicinska evidencija novorođenčadi kod kojih su dijagnosticirane i liječene novorođenačke ciste jajnika. Kontinuirani numerički podaci prikazani su kao srednja \pm SD ili srednja i raspon (minimalna-maksimalna) i razlike između skupina u usporedbi koristeći dva uzorka ispitivanja uz pretpostavku nejednakih varijacija i jednostruki faktor ANOVA test.

Rezultati: Operaciona vremena su bila kraća u skupini za hibridni postupak ($44 \pm$ minuta) nego u skupini za laparotomiju (56 ± 18 minuta) ali razlika nije bila statistički značajna ($p=0,23$). Duljina bolničkog boravka bila je kraća u skupini s hibridnim postupkom ($7,2 \pm 1,2$ dana) nego u skupini za laparotomiju ($10,8 \pm 3,1$ dana; $p=0,03$). Vrijeme provedeno u jedinici za intenzivnu njegu bilo je kraće u skupini s hibridnim postupkom ($0,4 \pm 0,9$ dana), nego u skupini za laparotomiju ($3,6 \pm 2,5$; $p=0,02$). Antibiotici, opioidi, analgetici, H₂ blokatori se nisu primjenjivali u postoperativnoj njezi skupine hibridnog postupka te je bilo manje potrebe za čestim previjanjem rana i manje KKS - a je naručeno u skupini za hibridni postupak ($1,0 \pm 0,7$), u usporedbi sa skupinom laparotomije ($4,4 \pm 3,7$). Indikacija za operaciju bile su veličine ciste, prekomjerna (≥ 6 cm), trajna (≥ 4 cm) ili povećanje veličine ciste (open: $n=4$; hibridna: $n=3$) i prisutnost složene ciste na temelju nalaza US (open: $n=3$; hibridna: $n=2$). Postojale su značajne razlike u veličini ciste na prenatnom US-u u 3 skupine liječenja ($p=0,03$).

Zaključak: Novorođenačke ciste jajnika mogu se sigurno i uspješno liječiti hibridnim pristupom s boljim kozmetičkim rezultatima i boljim kratkoročnim postoperativnim ishodima od tradicionalne laparotomije s obzirom na ispravne indikacije za operaciju.

Ključne riječi: cista jajnika, novorođenče, laparotomija, hibridna kirurgija

1 Preface

1.1 Epidemiology

Cysts in the ovaries of newborns are a frequent occurrence. It is estimated that 98% of female newborns have them at birth on routine ultrasound examination (1). In about 20% of cases they have a diameter greater than 9 mm (1). However, the incidence of clinically significant ovarian cysts is only 1 in 2500 (2–4), which makes it a rare condition. Nevertheless, it is the most commonly encountered type of cyst in the female abdomen (5). Furthermore, ovarian cysts usually present in the newborn's abdomen rather than pelvis because their pelvis is still small (6). This also means that if symptomatic their symptoms and complications can also be related to the abdomen (eg. cyst rupture with intra-abdominal hemorrhage, gastrointestinal obstruction). Ovarian torsion is the most common complication of neonatal ovarian cysts and occurs in 50-78% of cases because long utero-ovarian ligaments (pedicles) are present (6). It can also occur in the fetal period in up to 38% of cases (7,8).

1.2 Classification

Neonatal ovarian cysts are by definition benign regarding their appearance on histology and they are also called follicular ovarian cysts or congenital ovarian cysts. They can be classified into simple and complex cysts according to their size on prenatal or postnatal ultrasound and also according to their morphology on ultrasound. This is important as it determines the management of the cyst. For instance, simple cysts less than 4 cm in diameter tend to resolve spontaneously within 4-5 months, requiring abdominal ultrasound follow-up only, whereas cysts greater than 4 cm are more likely to persist and require surgical treatment (9). Size and ultrasound appearance also determine the perinatal outcome (10).

1.2.1 According to morphology

Neonatal ovarian cysts can be classified according to the Nussbaum criteria into simple and complex cysts (11). Simple cysts are anechoic, without fluid debris levels and with a thin to imperceptible wall, whereas complex cysts are hyperechoic with solid components and septated (11). Additionally, they may contain a blood clot and fluid debris levels (11). Classically, complex cysts have the following specific features: 1) partially anechoic with a fluid debris-level (formed by cyst fluid and liquid hematoma), 2) partially anechoic with a retracting clot, 3) septated (formed by strands of organized hematoma) and 4) solid (mass-like appearance produced by organized hematoma) (12). It is important to note that simple cysts might change into complex cysts according to their pattern on ultrasound, which might indicate the development of ovarian torsion (13). A meta-analysis by Bascietto et al showed

that more than 20% of simple cysts changed their ultrasound pattern to that of a complex cyst with a risk of change significantly higher in those >4 cm (10).

1.2.2 According to size

Cysts less than 2 cm in diameter are called mature follicular cysts whereas those greater than 2 cm in size are neonatal ovarian cysts (14). Cysts with a diameter of less than 4 cm are generally considered for watchful waiting (15) with serial ultrasound follow-ups whereas those greater than 4 cm are more likely to further enlarge, leading to ovarian torsion or they simply persist. The risk of ovarian torsion is significantly higher in cysts > 4 cm than < 4 cm irrespective of their ultrasound appearance (10). Persistence of a cyst could be a sign of malignancy or non-ovarian pathology (16) and must be further evaluated by MRI and laparoscopy. For example, according to a meta-analysis by Bascietto et al, 15 % of complex urogenital anomalies (e.g. persistent urogenital sinus or cloaca) were misdiagnosed neonatal ovarian cysts that were persisting (10).

1.3 Etiology

Neonatal ovarian cysts are thought to develop already in utero as fetal ovarian cysts due to high maternal estrogen levels and stimulation by fetal gonadotropins and placental hCG (17). Mature ovarian follicles have been found in 33 - 60% of newborn babies so it has been postulated that neonatal ovarian cysts are an exacerbation of a physiological process, which is the stimulation of the fetal ovary by the innately high hormone levels in utero (14). They are often detected incidentally on antenatal ultrasound in the third trimester (17) and the most common theory is that the ovary is stimulated by elevated hormone levels and stimulates the production of ovarian follicles. Another theory by Enriquez et al is that fetal ovarian cysts are caused by primitive gonadal dysgenesis due to vascular compromise (18). The true etiology, however, still remains unclear (14). It has also been noted that because most neonatal ovarian cysts regress spontaneously in 4-6 months, this can be tied to the postnatal fall in hCG hormonal levels (19) and maternal-placental estrogen as well as the neonate's neurological maturation (14).

1.4 Signs and symptoms

Neonatal cysts are usually asymptomatic and they were previously discovered incidentally (19) on prenatal ultrasound. They can also present as a palpable abdominal mass because the narrowness of the neonatal pelvis pushes the cyst upwards and out (16). The ovary that contains the cyst is frequently freely mobile. There can be symptoms related to their size such as urinary (hydronephrosis) or bowel obstruction (20). Also, babies with neonatal cysts that

led to ovarian torsion can present with nausea, vomiting, low-grade fever, irritability and feeding intolerance (21).

1.5 Ovarian torsion

Ovarian torsion can be isolated ovarian torsion, which is the twisting of the ovary only by twisting around the mesovarium or it could involve all the adnexal components of both ovary and fallopian tube known as adnexal torsion (22). Adnexal torsion is more common than isolated ovarian torsion and can also more often be found on the right side because the cecum and ileum are hypermobile, the utero-ovarian ligament and mesosalpinx are longer on that side, thus allowing for an increase in the mobility of the adnexa (22). When torsion occurs, venous flow is affected first because the walls of the arteries are thicker and more resistant to compression. Once venous obstruction occurs there is an increase in pressure inside the ovary that elicits ovarian edema and eventually arterial flow obstruction. This results in ischemia followed by necrosis. Prompt diagnosis and surgery are needed in order to prevent irreversible damage to the adnexa and maximize ovarian conservation (22).

1.6 Diagnosis

1.6.1 Diagnosing neonatal ovarian cysts

Diagnosis of ovarian cysts can be made prenatally or postnatally by ultrasound. It is important to distinguish between simple and complex ovarian cysts as their management is quite different. MRI might also be used in case of a limited acoustic window due to maternal habitus, fetal position or a low volume of amniotic fluid (17). MRI is also helpful in confirming the presence of a normal gastrointestinal and genitourinary tract, which is a prerequisite for diagnosing a fetal ovarian cyst (17). In addition to the previously explained ultrasound findings of simple and complex cysts above (see section 1.2.1), complex cysts can exhibit the “daughter cyst” sign, which describes a small, round, anechoic structure within a cyst (17) (a cyst within a cyst).

1.6.2 Assessment of neonatal ovarian cysts

Sometimes tumor markers such as AFP, β hCG, LDH, CA 125, NSE (neuron-specific enolase) and ferritin are used to evaluate the present yet minute risk for malignancy in this age group (3). In fact at Klinika za Dječje bolesti Zagreb (Children’s Hospital Zagreb) where this study was conducted, AFP and hCG are routinely measured as part of the preoperative work-up of neonatal ovarian cysts (13). It is important to note that the definitive diagnosis of neonatal ovarian cysts can only be made by pathology post-surgery. This is why cysts that

persist postnatally longer than 6 months are suspicious in that they may not be of ovarian origin (mesenteric cyst) or could be malignant and should be removed surgically.

1.6.3 Diagnosis of ovarian and adnexal torsion

The mere presence of a simple or complex cyst does not warrant treatment, however, suspected ovarian torsion does. It is therefore important to recognize ovarian torsion on ultrasound. A size discrepancy in the ovarian volumes with peripheralization of follicles could point towards ovarian torsion (23). Also, a fluid debris level and a retracting clot appearing as an echogenic nodule have been described in literature (11). A case series from 2011 investigating the 'role of sonography in diagnosing torsion' points out that all their patients with ovarian torsion had complex features on ultrasound (20). They also describe a "fish net appearance" in two of their patients, which is commonly seen in hemorrhagic ovarian cysts in adults (20). However, the presence of sonographic features of a complex cyst is not enough to diagnose torsion. An entire study was done by Cesca et al to show that it is safe to follow up asymptomatic complex ovarian cysts and therefore an unnecessary surgical intervention could be avoided (12). Furthermore, there may be a "string of pearls' sign" (24), which describes multiple small peripheral follicles that were displaced by edema. Doppler flow can also be used to see the presence of blood flow, although flow could be present in ovarian torsion due to the dual blood supply of the ovary. If arterial flow is present in systole but there is no flow in diastole, this indicates outflow obstruction (25). The presence of venous flow means that the ovarian tissue could still be viable (25). Another sign depicting the twisting of the vascular pedicle of the ovary is the Doppler gray scale "whirlpool sign" of the ovarian vessels (26), which is described as a round hyperechoic structure with concentric hypoechoic stripes or as a tubular structure with internal heterogenous echoes (25). Also, the uterus could be displaced from the midline and there might be free pelvic fluid (22). Ultimately, adnexal or ovarian torsion is a clinical diagnosis and only exploratory surgery is confirmatory.

1.7 Differential diagnosis of neonatal ovarian cysts

Included in the differential diagnosis should be disorders of the genitourinary tract such as MDCK (multicystic dysplastic kidney), a simple renal cyst, hydronephrosis, an ureterocele and disorders of the gastrointestinal tract such as intestinal duplication cysts and meconium pseudocysts (17). Other miscellaneous disorders that have been described are choledochal, splenic and pancreatic cysts, a lymphangioma (16) and a fetus in fetu (17). In one retrospective cohort study, two intestinal duplications were misdiagnosed as ovarian cysts (27), which illustrates the very real possibility for misdiagnosis. It is also crucial to determine

the correct diagnosis when prenatal (27) or postnatal aspiration is considered. US guided or blind surgical aspiration or puncture of a presumed ovarian cyst could have serious complications or even lead to death if a wrong diagnosis was made initially. In one case study a large cyst, presumed to be of ovarian origin, was percutaneously aspirated but turned out to be in fact a large proximal jejunal duplication cyst that led to midgut volvulus and the death of the child (28). Furthermore, it is difficult to differentiate between twisted, necrotic ovarian cysts, intestinal duplication and mesenteric cysts. As a result complex cysts, regardless of their size should be explored laparoscopically (28).

1.8 Complications due to neonatal ovarian cysts

1.8.1 Short-term complications

1.8.1.1 By mass effect

Neonatal ovarian cysts by sheer mass effect could cause gastrointestinal or urinary tract obstruction, incarceration in an inguinal hernia, difficulty with delivery due to fetal abdominal dystocia and also pulmonary hypoplasia as a result of pressure on the diaphragm, leading to respiratory distress at birth (16,29,30).

1.8.1.2 By bleeding

There could also be bleeding into the cyst and or the cyst could rupture, causing intra-abdominal hemorrhage. The risk of intracystic hemorrhage is greater for complex cysts compared to simple cysts and cysts > 4 cm than < 4 cm (10).

1.8.2 Long-term complications

The most common complication of neonatal ovarian cysts is ovarian torsion, leading to necrosis of the ovary that may turn into a calcified mass or disappear entirely (25). It may also lead to peritonitis and the formation of adhesions that decreases chances for pregnancy in the future. The main risk factor for ovarian torsion is the presence of an ovarian mass such as a neonatal ovarian cyst, especially with a cyst > 5 cm in diameter (31,32). Despite this, ovarian torsion is possible with cysts of any size (16) and there could be torsion of both ovaries, leading to future infertility. Additionally, neonatal ovarian cysts that have been complex from the beginning can impede the vascularization of the primitive gonad (18), thereby causing ovarian-vascular dysgenesis (14). It can also lead to an ipsilateral atretic fallopian tube (18), further decreasing future chances for pregnancy. Ovarian torsion could also lead to further complications such as ovarian rupture causing a hemoperitoneum, adhesions that result in urinary and gastrointestinal obstruction and auto-amputation of the ovary (14,33). Auto-

amputation of the ovary is the final result after ischemia and infarction and can be recognized on ultrasound by a mobile echogenic cyst, the absence of blood flow on Doppler and the presence of a fallopian tube blind stump (13). It is also worth noting that 92% of neonatal ovaries with torsion (Brandt et al) showed evidence on the first postnatal ultrasound, suggesting that in many cases torsion occurs in utero (7,34). A study by Zampieri et al mentions that the histologic findings after laparoscopy showed hemorrhagic cysts with little calcifications, which they suggest indicates that there was antenatal torsion in all cases (35). Infertility can also be correlated with the presence of complex cysts that in the majority of cases harbor already atrophic ovarian tissue (2).

1.9 Treatment

The treatment of neonatal ovarian cysts can be either conservative with serial ultrasound follow-ups every 4-6 weeks (16), encompass US cyst aspiration as done by some institutions or surgical by classic laparotomy, mini-laparotomy, classic laparoscopy, newer laparoscopy techniques (ALET) and a hybrid approach such as LATEC by Schenkman et al and the hybrid procedure (combination of laparoscopy and open surgery) performed at Klinika za Dječje bolesti Zagreb (Children's Hospital Zagreb) that will be described in this study. There is also the investigational and controversial treatment of very large, simple fetal ovarian cysts by antenatal cyst aspiration in an attempt to preserve ovarian tissue, enable vaginal delivery (to prevent cyst rupture and dystocia that would otherwise occur), and to prevent complications by mass effect of the very large cyst. Possible complications according to Heling et al are amnionitis and premature labor (36) as well as the high possibility of recurrence in > 70% (37). This last treatment option will not be discussed further as it is not part of the management of neonatal ovarian cysts.

1.9.1 Conservative treatment

Conservative treatment of neonatal ovarian cysts consists of serial abdominal ultrasound examinations starting at birth every 4-6 weeks. Some hospitals do an ultrasound check-up every 3 months (35). This 'watchful waiting' continues until the cyst decreases in size and eventually becomes undetectable on ultrasound by 6 months to 1 year of age, which would be the ideal situation. If the cyst persists or is increasing in size, this could point towards a misdiagnosis, malignancy or - what is most likely - a neonatal ovarian cyst with increasing potential for ovarian torsion, rupture and hemorrhage. If the diagnosis is certain, at a bare minimum, the latter requires further US follow-up until it regresses or changes its appearance. Tumor markers such as AFP and hCG could be measured when the cyst does not shrink (12) to assess the risk for malignancy (22), although their presence is not 100% specific for

malignancy, and they are in many cases present also in neonatal ovarian cysts, which are physiological and benign, until they are removed surgically and their levels decrease post-surgery. Another possibility would be to do an MRI to get more clarity as to the origin and consistency of the cyst. However, the only way to be sure that an ovarian cyst is not malignant after persisting for more than a year or enlarging, is to abandon the conservative treatment and opt for surgical exploration. One study showed that 42% (14/33 cases) of their patients with neonatal ovarian cysts, their cysts regressed spontaneously under conservative treatment (27), meaning it is definitely a valid treatment option. However, it is important to take into account the cyst size and whether the cyst is complicated (complex) or simple. All patients with ovarian torsion (12%) had cysts that were > 4 cm in diameter (27). And even though not all complex cysts led to ovarian torsion, all ovarian torsions were complex cysts at neonatal scan (27). The possibility to manage complex cysts conservatively is still somewhat of a gray area. A study by Cesca et al analyzed the conservative management of complex cysts and in 37 out of 41 cases the cysts regressed spontaneously, and they consider it a viable treatment option for asymptomatic complex cysts (12). However, the ovary ipsilateral to the complex cyst was, if present, atrophic. There was only evidence of the presence of 1 ovary in 40% of their patients at puberty and in 60% of cases there were two ovaries with one being atrophic (same side as the complex cyst) (12). These findings suggest that even though conservative management is safe, it might not be the best option to preserve future fertility.

1.9.2 Surgical treatment

1.9.2.1 Oophorectomy

Surgical treatment offers the potential for definitive diagnosis of the cyst being ovarian in origin and at the same time assessing the state of the ovary that bears the ovarian cyst, the fallopian tube and also the ovary on the contralateral side. The ovary may be completely necrotic or hemorrhagic and of nonviable appearance and as a result has to be removed by oophorectomy (38), but there may also be potential for untwisting the vascular pedicle with the potential to return blood flow to the ovary. In the 20th century after its description by J. Bland Sutton, adnexal torsion was always treated by salpingo-oophorectomy in order to prevent thromboembolic events by ovarian vein thrombosis (39).

1.9.2.2 Preservation

A review by Mc Govern et al discovered that the incidence of pulmonary embolism regardless of detorsion (untwisting) of twisted adnexa in cases of adnexal torsion was only 0.2% (40). Consequently, they recommend that detorsion of twisted adnexa should be undertaken if possible and can be safely performed without an increased risk for

thromboembolic events (40). As a result, so-called conservative laparoscopic approaches have been described in adults where the detorsion of twisted adnexa together with cystectomy is attempted in order to try to preserve ovarian function (41). Another study by Parelkar et al in a tertiary care center in Mumbai advocates detorsion with maximal preservation of ovarian tissue in prepubescent girls and states that “gross appearance of ovary and intraoperative grading of ischemia are not reliable indicators of ovarian viability” (42). The intraoperative grading system used in that institution was from 1 to 4; 1 being the best (slightly discolored, normal size ovary, which promptly reverted to normal color after detorsion) and 4 the worst (completely black, grossly enlarged ovary with hematoma and no improvement in color after detorsion and hematoma evacuation) (42). Notably, 9 out of 10 patients labeled as having moderate to severe ischemia (grade 3) had retained ovarian tissue with good vascularity and follicular development postoperatively on US Doppler (42). However, patients with cysts or malignancy were excluded from their research, hence this may or may not be applicable to neonatal ovarian cysts with ovarian/adnexal torsion. A new technique called “bivalving of the ovary” has been described in cases of severely edematous and hemorrhagic adnexa (39). It is performed by a linear incision along the antimesenteric side of the affected ovary after it has been untwisted (39). This serves to identify viable, reperfusable ovarian tissue as well as to relieve the pressure within the ovarian capsule to permit lymphatic and venous drainage and ultimately to reestablish arterial flow (39). However, this technique was used in patients aged 9.6 ± 4.2 years and it has so far not been reported in the management of neonatal ovarian torsion. Unfortunately, right now the only way to assess the viability of the ovary is by gross inspection during surgery and therefore depends on the surgeon’s interpretation (43). It is usually believed that dark, enlarged (edematous) ovaries are nonviable. However, several studies show that even black or blue-like ovaries are able to keep their ovarian function (42,44–47). Surgical management of neonatal ovarian cysts also enables the removal of adhesions that might make it more difficult to get pregnant and maintain a pregnancy in the future or cause genitourinary and gastrointestinal obstructions. Also, it increases the chances of preservation of ovarian tissue by detorsion of the vascular stalk of the ovary or by preventing the affection of the contralateral ovary due to the adhesions, which might increase the potential for torsion. Complex cysts are usually thought to represent antenatal torsion. However, in the study done by Papic et al the complex cysts that were treated surgically by oophorectomy, the pathologist could identify normal ovarian tissue (3). This suggests that an ovary conserving approach should be preferred in the surgical treatment of complex cysts. In addition, the study claims that postnatal ovarian torsion is a rare occurrence (1 patient only) and that also in that case the ovary could be salvaged (3). Only auto-amputated ovaries cannot be saved.

1.10 Operative techniques

1.10.1 Laparotomy

The traditional classic laparotomy that is nowadays less frequently used includes a transverse supra-pubic (or infraumbilical) incision (3,6,48,49). The transverse incision can also be supraumbilical (9). Marinković et al treated 8 neonates using this classical approach (49). In two newborns who were found to have ovarian torsion intraoperatively, detorsion, cyst extirpation, oophorectomy with salpingectomy and intramural excision of the intramural part of the fallopian tube were performed (49). The tubal stump was removed in order to prevent possible ectopic pregnancies in the future. One patient with auto-amputation of the ovary that was treated by laparotomy had complications. The cyst was connected to the mesentery and terminal ileum, which led to complete intestinal ischemia that necessitated 15 mm resection of the ischemic bowel. In addition, there was anastomotic and wound dehiscence complicated by peritonitis and sepsis (49). However, the 5 patients that were treated laparoscopically in the same study had no complications despite one cyst being connected to the cecum (49). Those patients had a normal postoperative course with short hospitalization only and minimal scarring (49). This is one example that sheds positive light on the laparoscopic approach, which will be addressed later on. Another study by Manjiri et al, although mainly describing the laparoscopic approach, successfully treated two clinically unstable neonates by laparotomy (2). Duration of classic laparotomy done by Schenkman et al was 51.8 minutes (\pm 17.1) (9) compared to a mini-laparotomy performed by Colby et al lasting from 28 to 49 minutes (50), suggesting that there are also variants of the classic laparotomy that may be less time consuming.

1.10.2 Laparoscopy

The laparoscopic approach is nowadays the preferred approach for the treatment of neonatal ovarian cysts due to shorter duration of surgery, better visualization of the contralateral ovary, faster post-operative recovery and better cosmetic results (9). Many different laparoscopic approaches have been described in literature. For example, Zampieri et al used a 5 mm-laparoscope that was placed in the lateral-umbilical position and a pneumoperitoneum from 8-10mmHg CO₂ with either one or two additional ports for the introduction of surgical instruments (35). The cysts were aspirated transabdominally and then removed via the umbilical port incision (35). Visnjic et al used the modified 2-port technique and inserted a 12-mm laparoscope with a CO₂ insufflation of 8 mmHg, which is standard for neonatal laparoscopy and another 5 mm-port in the left lower abdominal quadrant (13). He performed a laparoscopic oophorectomy of an autoamputated ovary (13). The 2-port laparoscopic technique was also used by Tseng et al in 6 cases without any complications (51). Prasad et al

performed a laparoscopic-assisted ovarian cystectomy in a neonate using a 5 mm umbilical camera port that was inserted using the open Hasson technique and a second 3 mm-port that was introduced into the left lumbar region to create a pneumoperitoneum of 8 mmHg CO₂ (1).

1.10.3 Hybrid surgery

In addition to these more traditional laparoscopic procedures, several hybrid approaches have already been described in literature. The so-called 'hybrid' technique combines laparoscopy with open surgery. The laparoscopic part of the procedure involves the extraction of the ovary from the peritoneal cavity, which is followed by extracorporeal excision or ablation of the ovarian cyst (and sometimes the entire ovary) like in open surgery. The surgical technique that was performed in this study at Klinika za dječje bolesti Zagreb (Clinic for Children's Diseases Zagreb) is a hybrid technique. It is explained further in section 4.4.2 'Specific Surgical Treatment Protocol'. The LATEC (laparoscopic-assisted transumbilical extracorporeal cystectomy) technique used by Schenkman et al similarly involves a hybrid approach. Here a 5 mm-trocar was inserted into the umbilicus and the abdomen inflated with CO₂ to a pressure of 10 mmHg, followed by the addition of a 3.5 mm-30 degree- laparoscope (9). Under laparoscopic guidance the cyst was punctured, aspirated and after removal of the trocar pulled out through the umbilicus either for cystectomy when ovarian preservation was attempted or salpingo-oophorectomy was done instead (9). Kozlov et al also describes a hybrid technique where the trocar was inserted through a circumbilical incision and the single working instrument was pushed through the umbilicus into the peritoneal cavity (52). The neonatal ovarian cyst was then deflated by transabdominal needle aspiration and the cyst extracted by extending the umbilical incision and then enucleated like in the standard open approach (52). Cimador et al describes a one-trocar video-assisted stripping technique for neonatal ovarian cysts using a 10mm umbilically placed operative laparoscope (pneumoperitoneum at a pressure of 8 mmHg for visualization) (8) that is equally considered to be hybrid surgery. The cysts were punctured transabdominally under direct vision using a 16-gauge needle and partially aspirated until it was possible to pull out the ovarian cyst through the umbilical port (8). The cysts walls were then stripped off the ovarian parenchyma using two atraumatic forceps (8). This technique was modeled after the stripping technique used by gynecologists for the enucleation of benign ovarian cysts and was performed without any complications, minimal scarring and the intention of preserving the maximum amount of ovarian tissue. Finally, a hybrid procedure called ALET (assisted-laparoscopic excision technique) was performed and described by Al-Zaiem et al (21). First a 5 mm or 10 mm-umbilical-trocar and camera was inserted and a pneumoperitoneum of 7 mmHg CO₂ produced

(21). The cyst was punctured and completely aspirated, then grabbed by artery forceps to be pulled through the umbilical port and to be excised extracorporally by diathermy (21).

2. Hypothesis

It was hypothesized that large neonatal ovarian cysts, complex cysts or cysts with suspected ovarian torsion can be as successfully treated surgically using the hybrid technique as by the traditional laparotomy with even better short term outcomes (shorter operating times, shorter length of hospital stay in general and also in the ICU, reduced need for and number of ordered blood tests and other diagnostic procedures, reduced need for antibiotics and analgesics, no need for nasogastric tubes, less surgical complications and better cosmetic results). In addition it was hypothesized that simple ovarian cysts less than 4 cm can be treated conservatively by serial transabdominal ultrasound follow-ups every 3 months with resulting spontaneous regression by one year of age. **Important: This research paper is a case series and as such is used to generate hypotheses and not to test them. There is no control group, which would be needed for case-control, cohort study or randomized control trial studies, which produce a higher level of evidence. However, the neonatal ovarian cysts that warrant treatment are rare and as such, even specialized secondary or tertiary care institutions do not encounter enough cases for higher evidence studies and therefore have to rely on lower evidence studies for guidance such as case series and case reports, many of which have already been mentioned in the Preface. The sample size being 20 only and the design of the study (retrospective, descriptive, not randomized) makes this a case series.**

3. Objectives

The aim of the study was to evaluate the three treatment modalities for neonatal ovarian cysts in the Klinika za dječje bolesti Zagreb (Clinic for Children's Diseases Zagreb) also known as KDB from 2008-2019, which are the conservative (watchful waiting) approach, surgical treatment by laparotomy and surgical treatment using the hybrid approach. In particular the aim was to compare the hybrid approach to the standard traditional open (laparotomy) approach. Furthermore, this case series describes and compares the unique hybrid technique at KDB Zagreb with a similar approach used by Schenkman et al called 'laparoscopic-assisted transumbilical extracorporeal cystectomy' (LATEC) (9).

4. Materials and Methods

4.1 Study design

This study was designed as a case series (descriptive, non-interventional) and 20 patients were included in this study. The sample size was 20 and therefore too small for a study with a higher level of evidence (e.g. cohort study). 10 patients were operated on because they had an indication for surgery, which was based on US findings and the general status of the patient. Five patients were treated surgically by the open approach and 5 by the hybrid approach. One group of pediatric surgeons at KDB performs laparotomy and the other group performs hybrid surgery (mixture of laparoscopy and open surgery). No surgeon performs both types of procedures and therefore they are experts in the type of procedure they perform. When a patient is admitted to the hospital, they are randomly assigned a pediatric surgeon, who is then responsible for the management of the neonatal cyst. In case surgery is warranted, the surgeon will operate using his preferred approach. This means that the patients were indirectly randomized and put into the open or laparoscopic group. It also means there was less inter-surgeon variability because the same group of surgeons performed the same type of procedure. Therefore, there is less error due to the surgical learning curve that is often the case with new procedures and might distort results.

4.2 Inclusion and Exclusion criteria

All patients with the ICD-10 diagnoses of neonatal ovarian cysts that were made based on US findings in the years 2008-2019 were initially included in this study and their medical records analyzed. However, patients that turned out not to have neonatal ovarian cysts but a different diagnosis after surgical removal of the cyst or biopsy of the cyst were then later excluded. For example, patients that were originally suspected to have ovarian cysts but later turned out to have a duplication cyst or an ovarian teratoma were reclassified and excluded from this study. One patient that did have a histologically confirmed ovarian cyst was excluded from this study because the cyst was not present or not diagnosed during the neonatal period (birth - 28 days after birth). In order to be included in this study, there had to be evidence of an ovarian cyst on ultrasound during the neonatal period as indicated by the title of this study.

4.3 Data collection

4.3.1 General information about procedure

The patients' medical records from 2008-2019 were analyzed. There was a switch from analogue (hard copy storage) to digital in 2010 and a transitional period that lasted until 2013 /2014, which made access to laboratory test printouts variable and in many cases impossible;

hence there is missing data for that reason. However, the laboratory findings that could be obtained can be found in the Appendix for completion but will not be further evaluated in this study. Patients were identified from the patient files in the department of pediatric surgery at Klinika za dječje bolesti Zagreb (Clinic for Children's Diseases Zagreb) according to diagnosis codes. The ICD-10 classification system is used in Croatia and the patients for this study were identified by the following ICD-10 codes: Q50.1 (Developmental ovarian cyst), N83.0 (Follicular cyst of ovary) and N83.2 (Other and unspecified ovarian cysts). Both digital and hardcopies of the medical records were reviewed for all patients in all years (2008-2019) in order not to miss data due to the analogue-digital transition. Most patients were diagnosed still in utero by prenatal ultrasound by a gynecologist, who suspected the presence of a fetal cyst of possible ovarian origin. These patients were then referred from the department of gynecology to the department of pediatric surgery at KDB where a postnatal ultrasound was made in order to reassess the suspected diagnosis of a neonatal ovarian cyst and decide on the need for surgical intervention or follow-up.

4.3.2 Data (variables) collected

The data that was collected included demographic information (date of birth), birth information (gestational age, weight, length, delivery mode). The birth information was incomplete because not all discharge letters from the gynecologist could be found in the medical records the department of pediatric surgery has access to (gestational age can only be found in the raw data tables in the Appendix). For all 20 patients the following data was obtained: prenatal US diagnosis (yes/no), size (in cm) and laterality (right or left) of ovarian cyst on prenatal US, symptoms and signs that can be attributed to the cyst, presence of other anomalies or diseases, tumor markers (AFP, hCG, NSE, ferritin, LDH). For the 10 patients that who were treated surgically (5 by laparotomy, 5 by hybrid surgery), additional data was extracted. This included the type of surgery (open/hybrid), age at surgery (calculated from the data of birth and date of surgery), indication for surgery (size of cyst, persistence or increase in size of cyst, type of cyst, suspected torsion on US), size (in cm), US description of cyst on postnatal US (used to classify cyst into simple and complex), complications, pathology report, residual disease (evidence of cyst after surgery on US) and preoperative signs and symptoms. Additional data related to the surgical procedure was collected including the description of the surgical procedure, intraoperative findings, operating time and time spent in operating theatre (time needed for preparation of the patient for anesthesia and waking up from anesthesia calculated/extrapolated from that), length of stay in hospital, length of stay in ICU, number of CBCs ordered, number of changes in wound dressing, antibiotics (type, duration), analgesics (type, dose, mode of delivery, duration) and nasogastric tube (yes/no).

4.4 Treatment protocols

4.4.1 General treatment protocols

After suspected diagnosis by a gynecologist during prenatal US, pediatric surgeons follow up neonatal cysts postnatally by US. In general, cysts with a maximum diameter of less than 4 cm and simple cysts (anechoic, fluid-filled on US) are usually treated conservatively by serial US follow-ups every 3 months until the cyst resolves completely or increases in size or consistency (appearance of septum, hyperechoic regions/sediment on US), which suggests a change from simple into a complex cyst or there is evidence of possible cyst hemorrhage (complex cyst features) or ovarian torsion (e.g. “string of pearls sign” with peripheralization of small follicles, size discrepancy of ovaries, reduced Doppler flow during diastole). If there are changes on US, follow-ups are scheduled more frequently such as every 2-4 weeks when there is an increase in the cyst size, even weekly when ovarian torsion is suspected and surgery has to be scheduled. Neonatal cysts that are treated conservatively are followed-up until they are no longer visible on US. The tumor markers AFP and hCG are routinely measured prior to surgery and then also checked afterwards for a postoperative decrease to exclude malignancy or residual disease. NSE (for neuroblastoma), ferritin and LDH are also sometimes being checked both preoperatively and postoperatively for similar purposes. The definitive diagnosis of neonatal ovarian cyst (follicular/congenital, hemorrhagic) is made by PHD after surgical retrieval and analysis of the tissue. Patients that are treated surgically by cystectomy, oophorectomy or salpingo-oophorectomy are followed up first every 6 months, later annually for presence of residual disease.

4.4.2 Specific surgical treatment protocol

At KDB all laparotomies are performed using an infraumbilical incision. They were mostly median (vertical incisions), except for one mini-Pfannenstiel incision (transverse) and the rest of the procedure is the same as already described in literature. However, the hybrid technique at KDB is similar to the LATEC(9) described by Schenkman et al with a few unique features that will be explained further. It is a one-trocar technique and the trocar is inserted using an open approach with a small vertical intra-umbilical incision with sutures placed on both sides. The trocar is inserted without a knife, causing less damage to the tissues. The camera, which is an optic with a working channel, is inserted through the trocar. The abdominal wall is lifted and fixated with traction sutures. There is no need for CO₂ insufflation as the neonatal abdominal wall is flexible enough to create enough working space, being distended using traction sutures only. The ovarian cyst and ovaries are identified and pulled through the umbilical port for visualization and extracorporeal extirpation. The ovarian cysts have to be

necrotic in order to fit through the umbilicus without need for widening the incision and not to necessitate intraabdominal puncture of the cyst. An appendectomy was additionally performed in one case using this technique. The procedure in that case was similar to TULA (transumbilical laparoscopic-assisted appendectomy) (53).

4.5 Outcomes

The primary or main outcomes (and goals) of management of neonatal ovarian cysts are the maximum preservation of ovarian tissue in order to preserve future fertility of the neonate, minimization of formation of adhesions that would similarly impede fertility and the avoidance of complications due to the mass effect of the cyst size such as gastrointestinal obstruction; in short, no morbidity and mortality. Unfortunately, this study does not provide this kind of data and would have required a different set of patients (patients that would be >18 years of age for example) and an interdisciplinary approach with gynecologists. However, KDB has very strict criteria and indications for surgery to minimize unnecessary resection of ovarian tissue and therefore is working towards the primary goal. The secondary measured outcomes of this study were presence of surgical complications, operating times, length of hospital stay and stay in the ICU, need for opioid analgesics (e.g. tramadol) or a nasogastric tube and presence of residual disease.

4.6 Statistical analysis

Continuous data are presented in tables by mean \pm standard deviation (e.g. operating times) or mean and range (e.g. maximum diameter of cyst on prenatal US). Categorical variables are shown by frequency of occurrence (e.g. number of simple cysts). The t-sample test assuming unequal variances and the single factor ANOVA test were used to determine differences between groups and a p-value <0.05 (95% confidence interval) was considered statistically significant.

4.7 Ethical approval

Permission to conduct the study was obtained from the Ethical Committee. The design of the study allowed the written consent to be waived.

5 Results

20 patients were diagnosed with having neonatal ovarian cysts, 5 of which were treated by laparotomy, 5 by hybrid surgery and 10 patients were treated using the conservative watchful waiting approach. The basic outcomes of surgery in both the laparotomy group and the hybrid

group were that all patients survived (no mortality) without serious long-term complications (no morbidity). The effect of the management of neonatal ovarian cysts on ovarian preservation was not investigated in this study and it remains unknown. In the surgical treatment group, 6 cysts were right-sided, 3 left-sided and 1 patient had bilateral ovarian cysts. In one hybrid approach case the cyst was hemorrhagic and torsed around the appendix and in one open laparotomy case, the cyst was hemorrhagic and adherent to the omentum, which had to be removed by partial omentectomy (Appendix Table A). In one of the open cases, the uterus was found to be unicornuate, in another the cornua of the uterus had a blind ending. The average age at surgery was $14,92 \pm 12,78$ weeks in the laparotomy group and $13,62 \pm 13,67$ weeks (Table 1) in the hybrid group and therefore very similar. This makes the age at surgery, which is one of the patient characteristics of the two surgical groups, comparable and less likely to be a confounder affecting the results. The youngest age at which surgery was performed was in the hybrid group with an age of 7 days compared to an age of 18 days in the laparotomy group (Appendix Table C). The oldest age at surgery was 9 months in the laparotomy group compared to 8 months of age in the hybrid group (Appendix Table C). The indication for surgery was the size of the cyst (excessive ≥ 6 cm; persistent ≥ 4 cm; increase in size) in 4 cases in the laparotomy group and in 3 cases in the hybrid group as shown in Table 1. The detailed description of the exact indication for surgery in each case can be found in Appendix Table C.

Table 1 Indication for surgery

	Laparotomy (n=5)	Hybrid (n=5)
Age at surgery (in weeks)	$14,92 \pm 12,78$	$13,62 \pm 13,67$
Indication for surgery		
Cyst size (excessive ≥ 6 cm; persistent ≥ 4 cm; increase in size)	4*	3
Complex cyst	3*	2

* Total number of indications greater than total number of procedures performed because sometimes more than one surgical indication per case

The cyst being complex was used as an indication for surgery three times in the laparotomy group compared to twice in the hybrid group. Suspected ovarian torsion as indication was categorized under complex cyst because the US criteria in that case must have had a complex pattern (and also a lack of Doppler flow). Appendix Table A contains the intraoperative findings that in all cases demonstrate the presence of ovarian torsion with or without hemorrhagic infarction of the ovary, hemorrhagic cysts, autoamputation of cyst or ovary, all of which confirm that the indications for surgery were correct. 4 out of 5 cysts were complex

in the laparotomy group compared to 2 out of 4 in the hybrid group as and one remains unclassified (see Table 2*). The mean maximum diameter of the cyst on prenatal US was 4,64 cm in the laparotomy group, ranging from 4,00- 5,60 cm in contrast to a mean of 5,26 cm and a range of 3,10 -6,50 cm in the hybrid group (Table 2). The mean maximum diameter of the cyst on postnatal US in the laparotomy group was 5,50 cm (range: 5,00-6,00 cm) compared to a mean of 5,00 (range: 3,00-6,50) in the hybrid group. The mean and range were used here instead of standard deviation to demonstrate that cysts < 4 cm were treated surgically, which goes against the consensus that cysts < 4 cm can be treated conservatively (see Preface 1.2.2). However, the cyst with the maximum diameter of only 3 cm in the hybrid group (see Appendix Table C) although small, was complex, which in itself can be an indication for surgery (see Preface 1.2.1).

Table 2 Operative findings

	Laparotomy (n=5)	Hybrid (n=5)
Simple cyst	1	2*
Complex cyst	4	2*
Maximum diameter of cyst on prenatal ultrasound (in cm)	4,64 (Range: 4,00 – 5,60)	5,26 (Range: 3,10- 6,50)
Maximum diameter of cyst on postnatal ultrasound (in cm)	5,50 (Range: 5,00- 6,00)	5,00 (Range: 3,00- 6,50)

* Only 4 cysts in total in the laparoscopy group because one US description of cyst was missing in the medical records and the cyst could not be classified as either simple or complex

Table 3 shows the outcomes of the surgical treatment groups, which are presented as means \pm standard deviation. The average operating time in minutes is shorter in the hybrid group (44 ± 15) than in the laparotomy group (56 ± 18). However, the difference between the 2 groups is not statistically significant because the p-value is 0,23 (calculated using t-test: two sample assuming unequal variances) and therefore $> 0,05$. The complexity of the procedure can also affect the operating time. For instance, in one case during an explorative hybrid procedure, a classic appendectomy was performed in addition to a cystectomy and oophorectomy, which may have increased the operating time to 45 minutes. This is why Appendix Table A contains a description of the surgical procedure next to the corresponding operating time to link the two. The total time spent in the operating theatre in minutes is equally shorter in the hybrid group (91 ± 10) compared to the laparotomy group (101 ± 27) but this difference is similarly not statistically significant ($p > 0,05$). Although the difference in results between the 2 groups is not statistically significant, yet there is an apparent difference and therefore, there is the

possibility that with a larger sample size, a statistically significant difference could be demonstrated. The time spent preparing the general endotracheal anesthesia and waking up from it in minutes was calculated by subtracting the operating times from the total time spent in the operating theatre and is higher in the hybrid group (47 ± 16) than in the laparotomy group (45 ± 12). However, the results were similar and the difference not statistically significant either ($p > 0.05$). Figure 1 contains boxplots that graphically show the operating times, times spent in the operating theatre and time spent preparing anesthesia and waking up from anesthesia in the operating theatre, containing the range, quartiles and median. This graph shows that the operating times are ranging from 35 to 70 minutes in the hybrid group compared to 35 to 75 minutes in the laparotomy group, which are therefore very similar. However, it also illustrates that the majority of hybrid cases are between 35 and 45 minutes whereas the operating times for the laparotomy cases are more widespread as shown by the larger box (UQ, LQ, median) within the box plot. This suggests that most hybrid cases have shorter operating times than laparotomy cases (results for individual cases can be found in Appendix Table A). The time spent in the operating theatre ranges from 80 to 105 minutes in the hybrid group compared to 70 to 130 minutes in the laparotomy group, there being a larger variation of times in the laparotomy group again as shown in Figure 1. The times preparing for and waking up from anesthesia are both very similar in range and values in both groups, suggesting there is no difference of any kind. The length of hospital stay in the hybrid group is shorter ($7,2 \pm 1,3$ days) than in the laparotomy group ($10,8 \pm 3,1$ days) and this difference is statistically significant ($p = 0.03$, therefore $p < 0.05$), which is illustrated in Figure 2. The Figure 2 error bars represent the 95% CI and because they do not overlap confirm the results of the t-test because the sample sizes are equal and there are no multiple comparisons (54). Similarly, the length of stay in the ICU is shorter in the hybrid group ($0,4 \pm 0,9$ days) compared to the laparotomy group ($3,6 \pm 2,5$ days), which is also statistically significant ($p = 0,02$, therefore $p < 0,05$) and illustrated in Figure 3. Also, the number of laboratory findings is smaller in the hybrid group ($1,0 \pm 0,7$) than in the laparotomy group ($4,4 \pm 3,7$). However, the t-test determined a p-value of 0.06, which is not yet statistically significant. The numbers of CBCs ordered postoperatively only were counted as laboratory findings in these calculations. Appendix Table B contains, in addition to the number of CBCs, the number of changes in wound dressing and postoperative USs, which are similarly more frequent in the patients treated by laparotomy than by hybrid surgery. In addition, there was no need for antibiotics and opioid analgesics such as Tramadol (Tramal) in the hybrid group (see Appendix Table B). NGTs were not needed in the hybrid group to prevent vomiting, aspiration and postoperative ileus(55) and no febrility was observed postoperatively in the hybrid group (Appendix Table B). Also, Ranitidin (H2 blocker) was not used and therefore not needed for stress ulcer prophylaxis in the hybrid group, only in some cases in the laparotomy group

(Appendix Table B). Dosage, duration, mode of administration of antipyretics, analgesics and antibiotics (if documented in medical records) can be found in Appendix Table B.

Table 3 Outcomes of Surgical Treatment groups

	Laparotomy (n=5)	Hybrid (n=5)
Operating time (in minutes)	56 ± 18	44 ± 15
Total time spent in operating theatre (in minutes)	101 ± 27	91 ± 10
Time spent preparing anesthesia and waking up from anesthesia in the operating theatre (in minutes)	45 ± 12	47 ± 16
Length of hospital stay (in days)	10,8 ± 3,1	7,2 ± 1,3**
Length of stay in ICU (in days)	3,6 ± 2,5	0,4 ± 0,9**
Number of laboratory findings ordered	4,4 ± 3,7	1,0 ± 0,7

Outcomes are defined as means ± standard deviation.

** p <0,05 compared to laparotomy

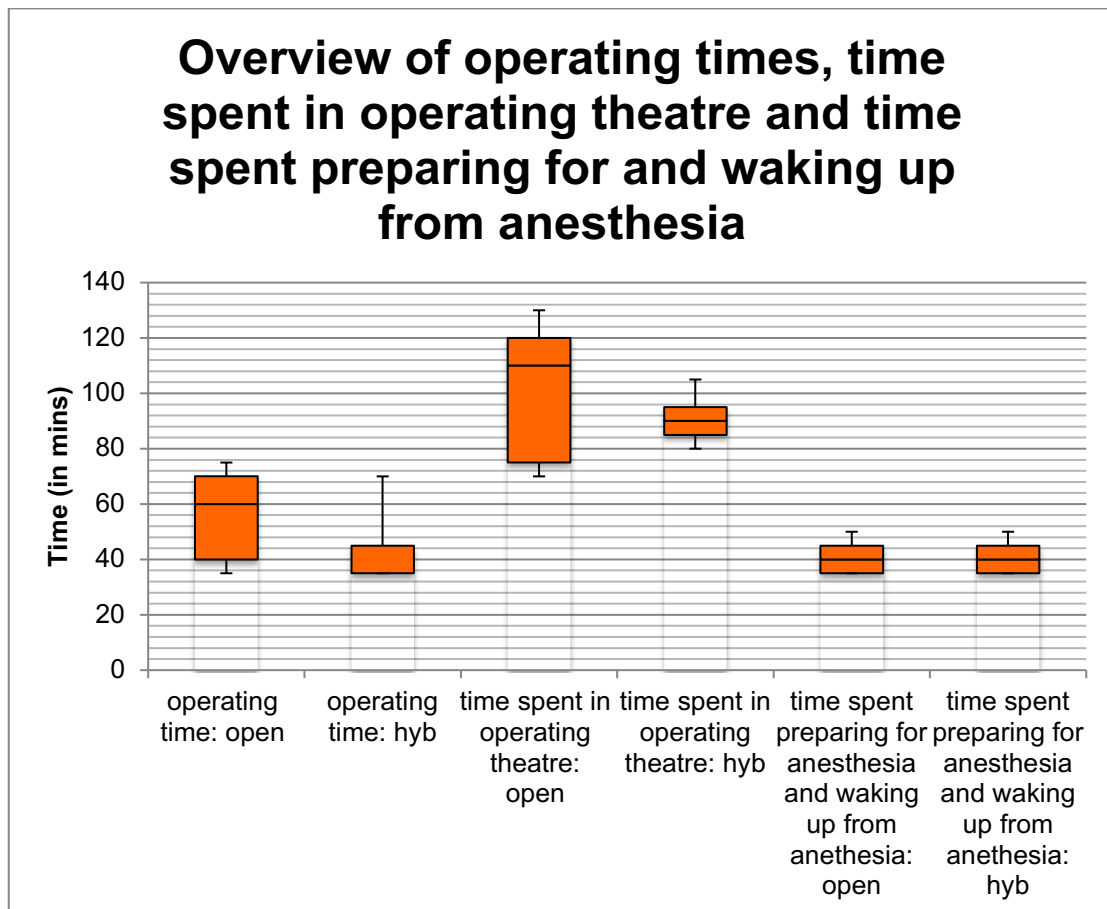


Figure 1 Overview

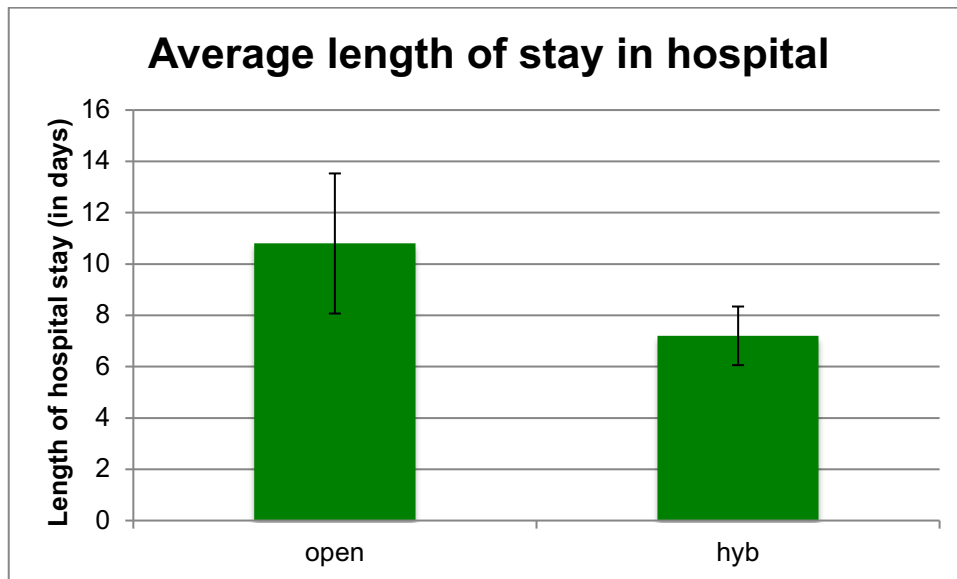


Figure 2 Length of hospital stay

Data displayed as means; error bars represent 95% CI.

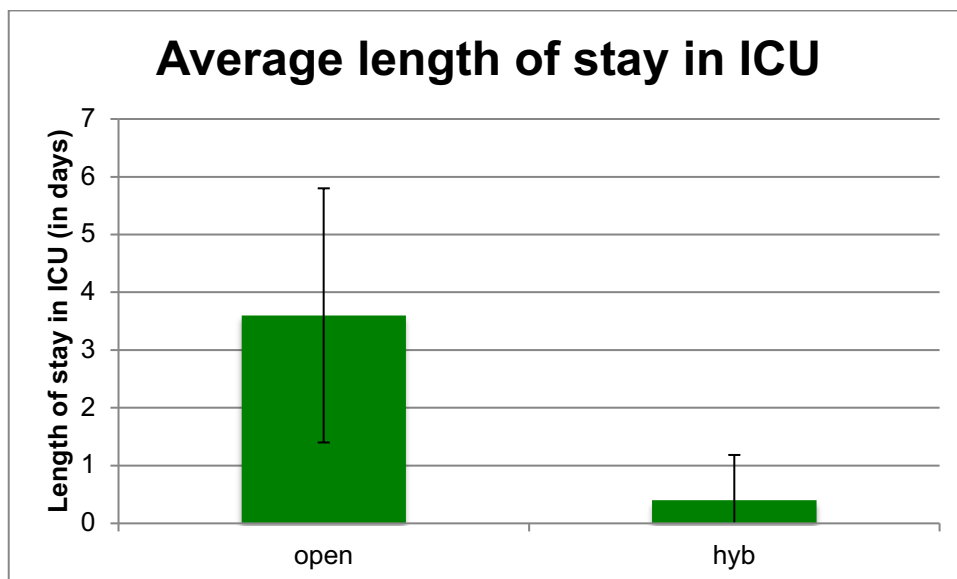


Figure 3 Length of stay in ICU

Data displayed as means; error bars represent 95% CI.

The maximum diameter of the neonatal ovarian cyst on prenatal US was smaller in the conservative treatment group ($3,57 \pm 1,17$ cm) than in both the laparotomy group ($4,46 \pm 0,68$ cm) and hybrid group ($5,26 \pm 1,32$ cm). A single factor ANOVA test revealed a statistically significant p-value of 0,033, which means there is a difference between the group means. This result was to be expected as smaller cysts are more likely to regress spontaneously and they are often treated conservatively rather than surgically.

Table 4 Comparison of ovarian cyst diameter on prenatal ultrasound in three treatment groups

	Laparotomy (n=5)	Hybrid (n=5)	Conservative treatment (n=10)
Maximum diameter of cyst on prenatal ultrasound (in cm)	4,64 ± 0,68 (Range: 4 - 5,6)	5,26 ± 1,32 (Range: 3,1 - 6,5)	3,57 ± 1,17** (Range: 2,1 - 5,7)

The smallest maximum diameter of the cyst on prenatal US in the hybrid group was 3,1 cm, which is smaller than 4 cm and highlights that cyst size is not the only relevant factor determining the management of neonatal ovarian cysts. Similarly, the largest maximum diameter of the cyst in the conservative group was 5,7 cm, which is larger than 4 cm and points out that cysts > 4 cm can be successfully treated by watchful waiting. The ranges of the cyst sizes in the 3 treatment groups are graphically displayed in Figure 4.

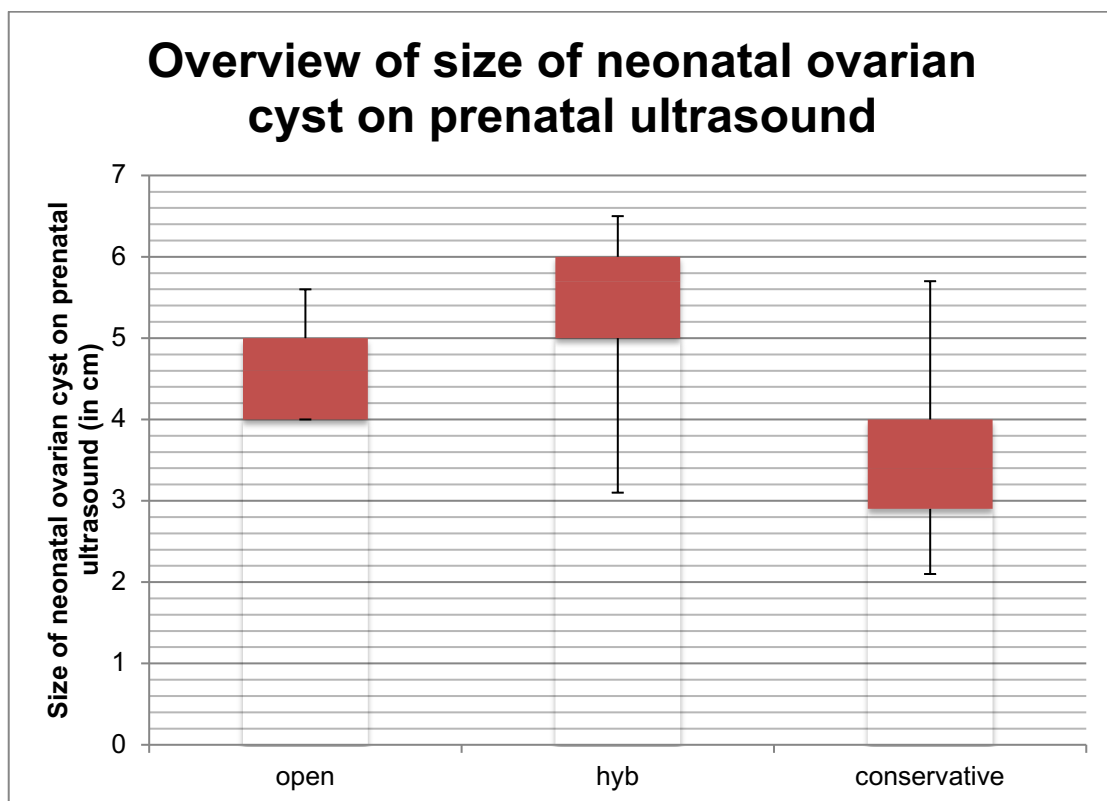


Figure 4 Overview of cyst sizes

All neonatal ovarian cysts that were treated surgically either by laparotomy or using the hybrid approach were diagnosed on prenatal US (Appendix Table C). There were no surgical complications in the hybrid group. However, in one case, laparotomy was complicated by ileus on the 5th day after surgery that had to be revised surgically by explorative laparotomy with appendectomy and peritoneal lavage (Appendix Table D). In that particular case, the

patient also had fever preoperatively (Appendix Table D). There were no postoperative US findings of residual disease in either group, except for one case in the hybrid group that required further US follow-up. The definite diagnosis of neonatal ovarian cyst was confirmed after analysis by a pathologist and described as either a follicular, hemorrhagic or congenital ovarian cyst. In one case, the pathologist was not able to confirm the tissue as being of ovarian tissue because it was completely necrotic, however, it was most likely a neonatal ovarian cyst (Appendix Table D). The age at spontaneous regression of the cyst of the patients that were treated conservatively can be found in Appendix Table F. The youngest age at regression was 1 month and the oldest was 18 months. The surgical technique used in the hybrid group is minimally invasive and has better cosmetic results.

6 Discussion

All of the neonatal ovarian cysts (2 cases still ongoing US follow-up) that were treated conservatively regressed spontaneously (earliest: 1 month of age; latest: 18 months of age), making serial US follow-up a valid treatment option. In two cases, the largest cyst diameter was > 4cm (5,1 cm and 5,7 cm respectively on prenatal US), challenging the general cut-off used in literature that cysts > 4cm are considered large and they should be operated on (10). It was not possible to discern the morphology of the cyst (simple vs complex) that may have set patients on the conservative management path (simple cyst) due to the absence of US descriptions of the cysts in the conservative treatment group. The indication for surgery threshold was high as can be shown by the fact that in the majority of cases the age at surgery went beyond the neonatal period (> 1 month of age), the average age being \approx 15 weeks in the laparotomy group and \approx 14 weeks in the hybrid group. This indicates that the conservative approach was attempted in each case. Also, the indication for surgery was correct as confirmed by the intraoperative findings of either ovarian torsion or autoamputation of the ovary that are unsalvageable and had to be treated by oophorectomy \pm adnexectomy. In one case in the hybrid group a hemorrhagic cyst was found and treated by cystectomy with preservation of the ovary, which shows the primary goal of ovarian preservation was attempted where feasible. All but two of the cysts that were treated surgically had complex US features in addition to a size > 5 cm. In one case, the maximum diameter of the cyst was only 3 cm but the cyst was complex and ovarian torsion was found intraoperatively, suggesting an individual approach is needed in each case because US measurements and findings do not necessarily correlate with the severity of the disease. In the two cases that had simple cysts, the size was either large (> 5cm) or excessive (> 6 cm). In two of the cases with complex cysts, ovarian torsion was suspected based on US criteria (see Preface 1.6.3) and the absence of Doppler flow. The indication for surgery in this study was either the morphology

of the cyst (complex cyst) or the size of the cyst (excessive $\geq 6\text{cm}$; persistent $\geq 4\text{cm}$; increase in size) whereas in a similar study by Schenkman et al 'fear of future torsion due to size', 'preoperative evidence of torsion' und 'uncertain diagnosis' was used instead (9). Furthermore, in the study by Schenkman et al, the average age at surgery ranged from 4,8 days to 16,3 days (depending on the surgical treatment group) and the surgeries were performed only during the neonatal period (9) whereas in this study the average age was between 13 and 15 weeks of age. The apparent difference in age at surgery between the two studies confirms the high indication threshold at KDB for the surgical management of neonatal ovarian cysts. There is no difference in major outcomes between the laparotomy and hybrid group as the indication for surgery used in the two groups was the same, the indication threshold was high and consequently all cases that were treated surgically had irreparably damaged ovaries, foregoing any real possibility for preservation of ovarian tissue. Also, no mortality was observed in any of the treatment groups. The hybrid approach demonstrated a statistically significant shorter hospital stay and less time spent in the ICU compared to the laparotomy group. The number of CBCs ordered postoperatively was also lower in the hybrid group than in the laparotomy group but this was not yet statistically significant. The shorter hospital stay, length of stay in the ICU and reduced blood sampling in the hybrid group could make it also cheaper/more cost-effective. The mean operating time for the hybrid procedure at KBD was 44 minutes and therefore comparable to the one needed for LATEC (45,6 minutes) (9). Antibiotics, opioids, antacids and NGTs were not used at all postoperatively after hybrid surgery was performed. This highlights the fact that the postoperative care for hybrid surgery is less demanding than for the traditional laparotomy. Hybrid surgery is less invasive and therefore, no postoperative ileus is expected, for which a NGT would be needed. For the same reason, there was no need for opioid pain management, only paracetamol, which is preferable due to a better safety profile.

One of the limitations of this study is the small sample size, which makes it difficult to show statistical significance, the study design (low evidence study, retrospective) and the missing data especially in the group of patients that were managed conservatively. There may have been bias in that pediatric surgeons manage neonatal ovarian cysts and they are therefore looking for US findings with indications for surgery, and also did not document all that well patients that were treated conservatively (lack of US descriptions of cysts, so the type of cyst cannot be determined). It is also important to note that this study is unable to provide information related to ovarian preservation (primary goal) postoperatively and cannot make predictions related to fertility matters in the future.

7 Conclusions

Neonatal ovarian cysts can be as successfully managed surgically by hybrid surgery as by the standard laparotomy. Short-term outcomes were improved (e.g. shorter length of hospital stay; shorter stay in ICU) in patients treated using the hybrid approach, suggesting that hybrid surgery is a good and safe alternative to open surgery (laparotomy).

8 Appendix

Appendix Table A Surgical Treatment Group (Group 1 and 2)

Cases	Type of surgery	Operating time (in minutes)	Time spent in the operating theatre (in minutes)	Description of surgical procedure	Intraoperative findings
1	Hyb	35	80	Laparoscopic cystectomy and oophorectomy (dex)	Ovarian torsion
2	Hyb	35	95	Laparoscopic (trocar 12mm) partial oophorectomy and cystectomy (dex)	
3	Hyb	35	85	Laparoscopic (trocar 12mm; TULA) extirpation of ovary (sin)	Ovarian torsion with hemorrhagic infarction of left ovary
4	Hyb	45	105	Explorative laparoscopy with supraumbilical incision, detorsion, cystectomy, classic appendectomy, oophorectomy (dex)	Hemorrhagic cyst with torsion around appendix
5	Hyb	70	90	Laparoscopic cystectomy (lat.dex)	Hemorrhagic cyst
6	Open	75	130	Median laparotomy with adnexectomy (lat.dex), partial oophorectomy (lat. sin)	5cm sized mass with congestive changes of left ovary
7	Open	70	110	Median laparotomy with extirpation of ovarian cyst (dex), partial omentectomy, appendectomy)	Torsion with autoamputation of right hemorrhagic ovarian cyst 6-7cm, right unicornuate uterus
8	Open	60	120	Explorative median laparotomy with oophorectomy (sin), appendectomy	Torsion and autoamputation of left ovary, left cornua of uterus blind ending
9	Open	35	70	Mini-Pfannenstiel incision oophorectomy (dex)	Autoamputation of right ovary
10	Open	40	75	Lower median explorative laparotomy with cystectomy and oophorectomy (sin)	Hemorrhagic cyst with ovarian torsion

Appendix Table B Surgical Treatment Group (Group 1 and 2)

Cases	Type of surgery	Length of hospital stay (in days)	Length of stay in ICU (in days)	Postoperative procedures/laboratory evaluations/wound dressing changes	Antibiotics	Analgesics	Nasogastric tube
1	Hyb	8	0	1 CBC	0	120mg Lupocet suppository during surgery	0
2	Hyb	7	2	2 CBC, 1 change in wound dressing	0	Lupocet 3x (postop day 1): 1x 50mg, 2x35mg	0
3	Hyb	9	0	1CBC, 1 postop US	0	Lupocet 120mg suppository during surgery	0
4	Hyb	6	0	1CBC, 1 change in wound dressing, 1postop US	0	Lupocet 120mg suppository during surgery	0
5	Hyb	6	0	0	0	0	0
6	Open	16	8	11 lab tests, a lot of changes in wound dressing	Ketocef 9days, Efloran 8days	Perfalgan, Voltaren, Tramal, Lasix 8 days	NGT, febrile 6days
7	Open	9	3	3 CBC, 2x change in wound dressing	Ketocef 4 days	Tramal 2x, Ranitidin 7x, 1 preop caudal block	NGT, febrile 1 day
8	Open	8	2	3 CBC, 1 change in wound dressing	0	Tramal 1x (preop), Tramal2x and Lupocet 1x (ICU)	NGT, febrile 1 day
9	Open	10	2	2 CBC	0	Lupocet 120mg suppository preop	0
10	Open	11	3	3CBC, 2x change in wound dressing	Ketocef 2 days	Lupocet 8x 60mg, Ranitidin 2x	NGT, febrile 3 days

Appendix Table C Surgical Treatment Group (Group 1 and 2)

Cases	Type of surgery	Age at surgery	Indication for surgery	Prenatal ultrasound diagnosis	Gestational age at prenatal ultrasound diagnosis (in weeks)	Size of cyst on prenatal ultrasound	Ultrasound description of cyst
1	Hyb	8 months	Persistence of cyst size 5x3.5cm	Yes	30	6.5x5cm (sin)	Septated with hypoechoic regions
2	Hyb	7 days	Persistence of cyst size 5.5x2cm	Yes	39	5x4cm (dex)	Anechoic cyst; can't visualize left ovary
3	Hyb	6 months	Complex cyst 3x2cm with calcifications	Yes	-	3.1x2.1cm (sin)	Complex neonatal cyst with hypoechoic and hyperechoic regions, zones with calcifications
4	Hyb	2 months	Suspected torsion on ultrasound	Yes	28	5.7x5.1cm (dex)	-
5	Hyb	22 days	Cyst size 6.5x4.2cm	Yes	-	6 x 4cm (dex)	Fluid-filled cyst
6	Open	3 months	Suspected torsion on ultrasound	Yes	34	4x3cm (dex); 3x3cm (sin)	Hyperechoic with two small parts that are anechoic, septated and filled with content (dex); hyperechoic with sediment (sin)
7	Open	9 months	Persistence of cyst size 6x4cm	Yes	29	4.6x2.7x3.8cm (dex)	Septated with fluid, hyperechoic
8	Open	4 months	Cyst size 5x3cm, complex cyst	Yes	-	3.0x1.4cm (dex); 5.6x4.6cm (sin)	Hyperstimulated right ovary with follicles 5-6mm, subseptated with fluid (hypoechoic) and sediment (hyperechoic)
9	Open	2 months	Cyst increasing in size to 5x4cm, complex cyst	Yes	-	5.0x4.3cm (dex)	Heterogenic cyst with hypo and hyperechoic regions
10	Open	18 days	Cyst size 6x5cm	Yes	-	4x3.5cm (sin)	Anechoic, fluid-filled cyst

Appendix Table D Surgical Treatment Group (Group 1 and 2)

Cases	Type of surgery	Complications	Pathology report	Residual disease	Preoperative signs and symptoms
1	Hyb	0	Hemorrhagic cyst	No	
2	Hyb	0	Follicular congenital cyst	No	
3	Hyb	0	Congenital hemorrhagic cyst	No	
4	Hyb	0	Congenital ovarian cyst	Ovary (sin) with cystic changes 20 x10mm, need for follow up	
5	Hyb	0	Hemorrhagic cyst	No	
6	Open	5th day postop: Ileus, explorative laparotomy with appendectomy and peritoneal lavage	Pseudocysts on ovarian specimens (dex and sin), possibly burned out gonadoblastoma; karyotyping: 46 XX, BCR-13	No	Fever
7	Open	0	Congenital hemorrhagic cyst	No	Hard mass in right hemiabdomen, spitting up small quantities on first day of life, redness of face and acne, problem with passage (intestine), intolerance of enteral feeding, R abdomen resistance
8	Open	0	Cyst necrotic, therefore no detailed analysis possible; most likely follicular congenial ovarian cyst; Appendix: normal, lymph node with reactive changes	No	
9	Open	0	Hemorrhagic ovarian cyst	No	
10	Open	0	Follicular cyst	No	

Appendix Table E Surgical Treatment Group (Group 1 and 2)

Cases	Type of Surgery	AFP Preop (IU/ml)	AFP Postop (IU/ml)	hCG Preop (IU/ml)	hCG Postop (IU/ml)	Ferritin Preop (U/ml)	Ferritin Postop (U/ml)	NSE Preop (ng/ml)	NSE Postop (ng/ml)	LDH (U/l)
1	Hyb	-	40,6 (1 day after); 9,6 (3 weeks after)	-	0.135 (1 day); 1,11 (3 weeks)	-	17 (1day); 18.7 (3 weeks)	-	17,5 (3 weeks)	303 (2 months)
2	Hyb	-	-	-	-	-	-	-	-	-
3	Hyb	1200	-	-	-	-	-	-	-	274 (2 months)
4	Hyb	0	910; 21,17 (1 year)	0	0,1	0	398; 43,3 (1year)	0	13,8; 31,59 (1 year)	0
5	Hyb	7067,1	845 (1 month); 141,8 (2 months)	<1,2	0	763	414 (2 months)	29,4	19,1 (1month)	380 (1 month)
6	Open	732,9	120 (2 months)	1,4	1,5	147	-	9,71	-	-
7	Open	-	-	-	-	-	-	-	-	-
8	Open	-	-	-	-	-	-	-	-	-
9	Open	1053,4 1	141,53	1,09	0,279	484,5	-	20,53	-	-
10	Open	9707,1	-	0,533	-	538,6	-	23,6	-	-

Appendix Table F Conservative Treatment Group (Group 3)

Cases	Prenatal US diagnosis	Age at prenatal US diagnosis (in weeks)	Size of cyst at prenatal US diagnosis (in cm)	Location of cyst	Spontaneous regression (no longer visible on ultrasound)	Age at regression (in months)
11	Yes	32	4x3	?	Yes	8
12	Yes	34	2.5x4.0x4.0	Left	Yes	9
13	No	0	3.5x2-5 (2 weeks after birth)	Left	Yes	12
14	?	?	3.0x1.17	?	Yes	1
15	?	?	2.9x2.2	?	Ongoing follow-up; increase in size to 7.6x3.3	-
16	Yes	?	2.1x1.0	Right	Ongoing follow-up	-
17	?	?	2.1x1.0	Left	Yes	?
18	?	?	5.1x1.0	Left (left ovary with multiple cysts, biggest one recorded)	Yes	?
19	?	?	2.6x3.3	Right	Yes	?
20	?	?	5.7x4.3	Right	Yes	18

Appendix Table G Conservative Treatment Group (Group 3)

Cases	AFP (IU/ml)	hCG (IU/ml)	Ferritin (U/l)	NSE (ng/ml)
11	28 (8months)	1(8months)	0 (8months)	16(8 months)
12	22698,0 (4 days); 167,4 (3 months)	0,5 (4 days); <0,1 (3 months)	207,2 (4 days)	34,8 (4 days)
17	254,7 (initial); 10,6 (last follow-up)	<1,2	231 (initial); 26 (last follow-up)	22,3 (initial); 21,7 (last follow-up)
19	5,6	85	32,8	24,4

9 Acknowledgements

First of all, I would like to thank my mentor Doc. dr.sc. Stjepan Višnjić for giving me the opportunity to do research at his department, answering my numerous questions and organizing the help that made this thesis possible in the first place. Said help included Dr. Andro Gliha (pediatric surgeon) and Dr. Tonko Čolić. Their continuous support, humor and optimism during the data collection phase kept me sane and also made 'project thesis' rather enjoyable. Special thanks go to my family and friends for their ongoing love and support and my boyfriend who keeps finding solutions to problems and who helped with the English-Croatian translation of the summary. Finally, I want to thank the University of Zagreb for realizing my dream of becoming a doctor.

10 References

1. Prasad S, Chui CH. Laparoscopic-assisted transumbilical ovarian cystectomy in a neonate. *JSLs*. 2007;11(1):138–41.
2. S M, SK P, J S. Management of Complex Ovarian Cysts in Newborns – Our Experience. *J Neonatal Surg*. 2017;6(1):3.
3. Papic JC, Billmire DF, Rescorla FJ, Finnell SME, Leys CM. Management of Neonatal Ovarian Cysts and its Effect on Ovarian Preservation. *J Pediatr Surg* [Internet]. 2014;49(6):990–4. Available from: <http://dx.doi.org/10.1016/j.jpedsurg.2014.01.040>
4. Sakala EP, Leon ZA, Rouse GA. Management of antenatally diagnosed fetal ovarian cysts. *Obstet Gynecol Surv*. 1991 Jul;46(7):407–14.
5. Jain M, Pujani M, Madan NK, Chadha R, Puri A. Congenital ovarian cyst: a report of two cases. Vol. 4, *Journal of laboratory physicians*. 2012. p. 63–5.
6. Ogul H, Havan N, Pirimoglu B, Guvendi B, Kisaoglu A, Kantarci M. Prenatal and postnatal ultrasonographic findings of the torsioned ovarian cyst: A case report and brief literature review. *Int Surg*. 2015;100(3):514–7.
7. Meizner I, Levy A, Katz M, Maresh AJ, Glezerman M. Fetal ovarian cysts: prenatal ultrasonographic detection and postnatal evaluation and treatment. *Am J Obstet Gynecol*. 1991 Mar;164(3):874–8.
8. Cimador M, Sireci F, Di Pace MR, De Grazia E. One-Trocar, Video-Assisted Stripping Technique for Use in the Treatment of Large Ovarian Cysts in Infants. *J Pediatr Adolesc Gynecol* [Internet]. 2010;23(3):168–71. Available from: <http://dx.doi.org/10.1016/j.jpag.2009.11.007>
9. Schenkman L, Weiner TM, Phillips JD. Evolution of the surgical management of neonatal ovarian cysts: Laparoscopic-assisted transumbilical extracorporeal ovarian cystectomy (LATEC). *J Laparoendosc Adv Surg Tech*. 2008;18(4):635–40.
10. Bascietto F, Liberati M, Marrone L, Khalil A, Pagani G, Gustapane S, et al. Outcome of fetal ovarian cysts diagnosed on prenatal ultrasound examination: systematic review and meta-analysis. *Ultrasound Obstet Gynecol*. 2017;50(1):20–31.
11. Nussbaum AR, Sanders RC, Hartman DS, Dudgeon DL, Parmley TH. Neonatal ovarian cysts: sonographic-pathologic correlation. *Radiology*. 1988 Sep;168(3):817–21.
12. Cesca E, Midrio P, Boscolo-Berto R, Snijders D, Salvador L, D'Antona D, et al. Conservative treatment for complex neonatal ovarian cysts: A long-term follow-up analysis. *J Pediatr Surg* [Internet]. 2013;48(3):510–5. Available from: <http://dx.doi.org/10.1016/j.jpedsurg.2012.07.067>
13. Visnjic S, Domljan M, Zupancic B. Two-port Laparoscopic Management of an Autoamputated Ovarian Cyst in a Newborn. *J Minim Invasive Gynecol*. 2008;15(3):366–9.
14. Akin MA, Akin L, Özbek S, Tireli G, Kavuncuoğlu S, Sander S, et al. Fetal-neonatal ovarian cysts-their monitoring and management: Retrospective evaluation of 20 cases and review of the literature. *JCRPE J Clin Res Pediatr Endocrinol*. 2010;2(1):28–33.
15. Luzzatto C, Midrio P, Toffolutti T, Suma V. Neonatal ovarian cysts: management and follow-up. *Pediatr Surg Int*. 2000;16(1–2):56–9.
16. Laufer MR. Ovarian cysts and neoplasms in infants, children, and adolescents. Lockwood, Charles J, Middleman, Amy B, editor. UpToDate, Inc. and/or its affiliates.; 2019. 1–28 p.

17. Trinh TW, Kennedy AM. Fetal ovarian cysts: Review of imaging spectrum, differential diagnosis, management, and outcome. *Radiographics*. 2015;35(2):621–35.
18. Enriquez G, Duran C, Toran N, Piqueras J, Gratacos E, Aso C, et al. Conservative versus surgical treatment for complex neonatal ovarian cysts: outcomes study. *AJR Am J Roentgenol*. 2005 Aug;185(2):501–8.
19. Widdowson DJ, Pilling DW, Cook RCM. Neonatal ovarian cysts: therapeutic dilemma. *Arch Dis Child*. 1988;63(7 SPEC NO.):737–42.
20. Chinchure D, Ong CL, Loh AHP, Rajadurai VS. Neonatal ovarian cysts: Role of sonography in diagnosing torsion. *Ann Acad Med Singapore*. 2011;40(6):291–5.
21. Al-Zaiem MM. Assisted laparoscopic excision of huge abdominal cysts in newborns and infants using the umbilical laparoscopicport incision. *J Pediatr Surg* [Internet]. 2011;46(7):1459–63. Available from: <http://dx.doi.org/10.1016/j.jpedsurg.2011.03.004>
22. Childress KJ, Dietrich JE. Pediatric Ovarian Torsion Adnexal torsion Ovarian torsion Pediatric Adolescent Surgical management. 2017;97:209–21.
23. Servaes S, Zurakowski D, Laufer MR, Feins N, Chow JS. Sonographic findings of ovarian torsion in children. *Pediatr Radiol*. 2007 May;37(5):446–51.
24. Chang HC, Bhatt S, Dogra VS. Pearls and pitfalls in diagnosis of ovarian torsion.1. Chang HC, Bhatt S, Dogra VS. Pearls and pitfalls in diagnosis of ovarian torsion. *Radiographics*. 2008;28(5):1355–68. *Radiographics*. 2008;28(5):1355–68.
25. Laufer MR. Ovarian and fallopian tube torsion. In: Sharp HT, Levine D, editors. *UpToDate*. UpToDate, Inc. and/or its affiliates.; 2018.
26. Vijayaraghavan SB. Sonographic whirlpool sign in ovarian torsion. *J Ultrasound Med*. 2004;23(12):1643–9.
27. Nakamura M, Ishii K, Murata M, Sasahara J, Mitsuda N. Postnatal outcome in cases of prenatally diagnosed fetal ovarian cysts under conservative prenatal management. *Fetal Diagn Ther*. 2014;37(2):129–34.
28. Puligandla PS, Laberge JM. Lethal outcome after percutaneous aspiration of a presumed ovarian cyst in a neonate. *Semin Pediatr Surg* [Internet]. 2009;18(2):119–21. Available from: <http://dx.doi.org/10.1053/j.sempedsurg.2009.02.012>
29. Siegel MJ. Pediatric gynecologic sonography. *Radiology*. 1991 Jun;179(3):593–600.
30. Armentano G, Dodero P, Natta A, Magillo P, Sugliano GC. Fetal ovarian cysts: prenatal diagnosis and management. Report of two cases and review of literature. *Clin Exp Obstet Gynecol*. 1998;25(3):88–91.
31. Varras M, Tsikini A, Polyzos D, Samara C, Hadjopoulos G, Akrivis C. Uterine adnexal torsion: pathologic and gray-scale ultrasonographic findings. *Clin Exp Obstet Gynecol*. 2004;31(1):34–8.
32. Oltmann SC, Fischer A, Barber R, Huang R, Hicks B, Garcia N. Cannot exclude torsion--a 15-year review. *J Pediatr Surg*. 2009 Jun;44(6):1212–6; discussion 1217.
33. Jawad AJ, Zaghmout O, al-Muzrakchi AD, al-Hammadi T. Laparoscopic removal of an autoamputated ovarian cyst in an infant. *Pediatr Surg Int*. 1998 Mar;13(2–3):195–6.
34. Brandt ML, Luks FI, Filiatrault D, Garel L, Desjardins JG, Youssef S. Surgical indications in antenatally diagnosed ovarian cysts. *J Pediatr Surg*. 1991 Mar;26(3):272–6.
35. Zampieri N, Mantovani A, Scirè G, Camoglio FS. Neonatal surgery for giant floating abdominal cysts in females: Clinical and surgical management. *J Pediatr Adolesc*

- Gynecol. 2014;27(5):271–3.
36. Heling K-S, Chaoui R, Kirchmair F, Stadie S, Bollmann R. Fetal ovarian cysts: prenatal diagnosis, management and postnatal outcome. *Ultrasound Obstet Gynecol.* 2002 Jul;20(1):47–50.
 37. Noia G, Riccardi M, Visconti D, Pellegrino M, Quattrocchi T, Tintoni M, et al. Invasive fetal therapies: approach and results in treating fetal ovarian cysts. *J Matern Fetal Neonatal Med.* 2012 Mar;25(3):299–303.
 38. Shalev E, Mann S, Romano S, Rahav D. Laparoscopic detorsion of adnexa in childhood: a case report. *J Pediatr Surg.* 1991 Oct;26(10):1193–4.
 39. Styer AK, D M, Laufer MR, D M. Ovarian bivalving after detorsion. 2002;77(5):1053–5.
 40. McGovern PG, Noah R, Koenigsberg R, Little AB. Adnexal torsion and pulmonary embolism: case report and review of the literature. *Obstet Gynecol Surv.* 1999 Sep;54(9):601–8.
 41. Zweizig S, Perron J, Grubb D, Mishell DRJ. Conservative management of adnexal torsion. *Am J Obstet Gynecol.* 1993 Jun;168(6 Pt 1):1791–5.
 42. Parelkar S V., Mundada D, Sanghvi B V., Joshi PB, Oak SN, Kapadnis SP, et al. Should the ovary always be conserved in torsion? A tertiary care institute experience. *J Pediatr Surg* [Internet]. 2014;49(3):465–8. Available from: <http://dx.doi.org/10.1016/j.jpedsurg.2013.11.055>
 43. Huang C, , Mun-Kun Hong DD. A review of ovarian torsion. *Tzu Chi Med J.* 2017;29(3):143–7.
 44. Harkins G. Ovarian torsion treated with untwisting: second look 36 hours after untwisting. *J Minim Invasive Gynecol.* 2007;14(3):270.
 45. Oelsner G, Bider D, Goldenberg M, Admon D, Mashiach S. Long-term follow-up of the twisted ischemic adnexa managed by detorsion. *Fertil Steril.* 1993 Dec;60(6):976–9.
 46. Aziz D, Davis V, Allen L, Langer JC. Ovarian torsion in children: is oophorectomy necessary? *J Pediatr Surg.* 2004 May;39(5):750–3.
 47. Wang J-H, Wu D-H, Jin H, Wu Y-Z. Predominant etiology of adnexal torsion and ovarian outcome after detorsion in premenarchal girls. *Eur J Pediatr Surg Off J Austrian Assoc Pediatr Surg . [et al] = Zeitschrift fur Kinderchirurgie.* 2010 Sep;20(5):298–301.
 48. Monnery-Noch M, Auber F, Jouannic J, Benifla J, Carbonne B. Fetal and neonatal ovarian cysts: is surgery indicated? *Prenat Diagn.* 2008;28(10):1184–8.
 49. Marinković S, Jokić R, Bukarica S, Mikić AN, Vucković N, Antić J. Surgical treatment of neonatal ovarian cysts. *Med Pregl.* 2011;64(7–8):408–12.
 50. Colby C, Brindle M, Moss RL. Minimally invasive laparotomy for treatment of neonatal ovarian cysts. *J Pediatr Surg.* 2001 Jun;36(6):868–9.
 51. Tseng D, Curran TJ, Silen ML. Minimally invasive management of the prenatally torsed ovarian cyst. *J Pediatr Surg.* 2002 Oct;37(10):1467–9.
 52. Kozlov IA, Novozhilov VA, Rasputin AA, Syrkin N V, Podkamenev A V, Iurkov PS, et al. [Hybrid surgery for the treatment of ovarial cysts in newborns]. *Khirurgiia (Sofiia).* 2013;(11):40–5.
 53. Go DY, Boo YJ, Lee JS, Jung CW. Transumbilical laparoscopic-assisted appendectomy is a useful surgical option for pediatric uncomplicated appendicitis: A

- comparison with conventional 3-port laparoscopic appendectomy. *Ann Surg Treat Res.* 2016;91(2):80–4.
54. Graphpad.com. WHAT YOU CAN CONCLUDE WHEN TWO ERROR BARS OVERLAP (OR DON'T)? - FAQ 1362 - GRAPHPAD [Internet]. 2020 [cited 2020 Apr 25]. Available from: <https://www.graphpad.com/support/faq/spanwhat-you-can-conclude-when-two-error-bars-overlap-or-dontspan/>
 55. Abantanga FA. Nasogastric tube use in children after abdominal surgery- how long should it be kept in Situ? *West Afr J Med.* 2012;31(1):19–23.

11 Biography

Mira Jennifer Förster was born on 20th September 1996 in Troisdorf, Germany. She did half of her secondary education at Gymnasium Holthausen, Hattingen, and graduated with the International Baccalaureate from Ardingly College in the UK. In 2013 she was involved in a school project in Gambia where she taught Biology at schools in Banjul and surrounding areas. She was first enrolled in the Medical Studies in English Program at the University of Zagreb in 2014, where she has been studying since. She was a student instructor in the Department of Anatomy in 2015 and in the Department of Histology in 2016. Apart from her studies, she worked at Lingua language school in Zagreb from 10/2017 -6/2018 to teach children German. She is currently working at the Public Health Institute Wuppertal to help in the fight against COVID-19.