

Meibomian gland dysfunction

Štimac Rojtinić, Ivan

Master's thesis / Diplomski rad

2020

Degree Grantor / Ustanova koja je dodijelila akademski / stručni stupanj: **University of Zagreb, School of Medicine / Sveučilište u Zagrebu, Medicinski fakultet**

Permanent link / Trajna poveznica: <https://um.nsk.hr/um:nbn:hr:105:138093>

Rights / Prava: [In copyright](#)/[Zaštićeno autorskim pravom.](#)

Download date / Datum preuzimanja: **2024-07-23**



Repository / Repozitorij:

[Dr Med - University of Zagreb School of Medicine Digital Repository](#)



UNIVERSITY OF ZAGREB
SCHOOL OF MEDICINE

Ivan Štimac Rojtinić

MEIBOMIAN GLAND DYSFUNCTION

Graduate thesis



Zagreb, 2020

This graduate thesis was made at University Hospital Centre Zagreb, Department of Ophthalmology mentored by Assistant Professor Igor Petriček, MD, PhD. and was submitted for evaluation in the academic year 2019/2020

ABBREVIATIONS

DED- dry eye disease

EDE- evaporative dry eye

MCJ-mucocutaneous junction

TFLL- tear film lipid layer

MGD- Meibomian gland disease

1	Introduction	1
1.1	Dry eye disease	1
1.2	Generally about the Meibomian gland disease	2
2	Structure of the Meibomian gland.....	2
2.1	Anatomy of the Meibomian gland.....	2
2.2	Embryology and Histology of the Meibomian gland	4
2.2.1	Embryology.....	4
2.2.2	Histology.....	5
2.3	Physiology.....	6
2.4	Meibum	9
3	Patophysiology.....	10
3.1	Physiological changes.....	11
3.1.1	Age related Meibomian gland changes	11
3.1.2	Sex hormone related Meibomian gland changes.....	12
3.2	Patophysiological changes.....	13
3.2.1	High delivery state	13
3.2.2	Low delivery state	14
3.2.3	MGD secondary to local disease	18
4	Diagnosis and Therapy	19
4.1	Diagnosis	19
4.1.1	Lid wiper epitheliopathy	20
4.1.2	Interferometry	20
4.1.3	Meibography	21
4.1.4	Meibometry	22
4.1.5	Meibomian gland expressibility/duct assessment	22
4.2	Treatment.....	23
4.2.1	Ocular lubricants.....	23
4.2.2	Warm compress.....	23
4.2.3	Physical treatment	24
5	Acknowledgements	27
6	References.....	27
7	Biography.....	37

List of pictures

Figure 1 Anatomy of the Meibomian glands.....	4
Figure 2 Histology of the Meibomian glands	6
Figure 3 Physiology of the Meibomian glands	9
Figure 4 Pathophysiological pathways	19
Figure 5 Physiological Meibography	21
Figure 6 Transillumination meibography meibomian gland dropout	21
Figure 7 Forceful bimanual gland expression	25

Summary

Title: Meibomian gland dysfunction

Author: Ivan Štimac Rojtinić

Meibomian gland disease (MGD) is defined as chronic and disperse dysfunction of Meibomian glands. MGD is a disease that can be acquired or congenital. This disease is recognized as an obstruction of the terminal duct of the gland and changes in the composition of the tear film. MGD covers the part of Dry eye disease (DED) that is known as evaporative dry eye (EDE). EDE is connected to the lipid part of the tear film. The lipid part of the tear film plays an important role in stabilizing the tear film, without the lipid component the tear film evaporation time dramatically decreases. With the decrease of tear film stability some of the symptoms can start showing. The most common type of MGD is obstructive MGD. Obstructive MGD encompasses a lot of subtypes but the most important one would have to be hyperkeratinization. Hyperkeratinization is important because the process of obstruction is directly connected to the histology and embryology of the glands. MDG has a specific parent of presentation, because of that there are a lot of methods that can be used to diagnose

the disease. Although the methods used for diagnosis are precise and up to date there is a need to combine the different test to get the most accurate result. Finally the treatment for MDG is not complicated but some aspects of it can prove to be challenging for the patient whilst others may be painful.

Key words: Hyperkeratinization, Evaporative dry eye, evaporation.

Sažetak

Naslov: Disfunkcija meibomovih žlijezda

Autor: Ivan Štimac Rojtinić

Bolest meibomanske žlijezde (MGD) definirana je kao kronična i disperzna disfunkcija meibomanskih žlijezda. MGD je bolest koja može biti stečena ili urođena. Ova je bolest prepoznata kao začepljenje terminalnog kanala žlijezde i promjena u sastavu suznog filma. MGD pokriva dio bolesti suhog oka (DED) koji je poznat pod nazivom evaporativno suho oko (EDE). EDE je povezan s lipidnim dijelom suznog filma. Lipidni dio suznog filma igra važnu ulogu u stabilizaciji suznog filma, bez lipidne komponente vrijeme isparavanja suza filma dramatično se smanjuje. S padom stabilnosti suznog filma neki od simptoma mogu se početi prikazivati. Najčešća vrsta MGD je opstruktivni MGD. Opstruktivni MGD obuhvaća puno podvrsta, ali najvažnija od njih bi trebala biti hiperkeratinizacija. Hiperkeratinizacija je važna jer je proces opstrukcije izravno povezan s histologijom i embriologijom žlijezda. MDG ima specifičnu strukturu

prezentacije, zbog čega postoji puno metoda pomoću kojih se može dijagnosticirati bolest. Iako su metode koje se koriste za dijagnozu precizne i suvremene, postoji potreba da se kombiniraju različiti testovi kako bi se dobio najprecizniji rezultat.

Konačno, liječenje MDG-a nije komplicirano, ali neki njegovi aspekti mogu se pokazati izazovnim za pacijenta, dok drugi mogu biti bolni.

Ključne riječi: hiperkeratinizacija, evaporativon suho oko, evaporacija

1 Introduction

1.1 Dry eye disease

Dry eye disease (DED) affects hundreds of millions of people around the world and is one of the most frequent causes of patient visits to eye care practitioners. It is a symptomatic disease characterized by a cycle of tear film hyperosmolarity and instability which leads to increased ocular inflammation, damage and neurosensory abnormalities. Historically, DED was considered to be largely due to tear insufficiency and was treated by prescribing tear replacement products or by conserving the tears via punctal plugs. Ocular surface damage results from a wide variety of interplaying factors, such as increased tear evaporation, hyperosmolarity, proinflammatory mediators in the tears, and decreased lubrication between the lids and globe. It is generally believed that rather than representing two distinct categories, most people with symptoms related to ocular surface disease (OSD) suffer from variable combinations of both abnormal meibomian gland physiology (resulting in evaporative DED) and tear underproduction (resulting in aqueous deficient DED)

The official definition of TFOS DEWS(II) from 2017

“Dry eye is a multifactorial disease of the ocular surface characterized by a loss of homeostasis of the tear film, and accompanied by ocular symptoms, in which tear film instability and hyperosmolarity, ocular surface inflammation and damage, and neurosensory abnormalities play etiological roles.”

The multifactorial term acknowledges DED as a significant and complex, functional disorder that cannot be characterized by a single symptom, process or sign. In the classification of DED, the latest evidence supports a scheme based on its pathophysiology in which aqueous deficient dry eye (ADDE) and evaporative dry eye (EDE) exist as a union, such that elements of each need to be considered in diagnosis and management.

1.2 Generally about the Meibomian gland disease

Meibomian gland disease is recognized in the world as one of the leading causes of Dry eye disease. MGD is a chronic, diffuse abnormality of the meibomian glands, commonly characterized by terminal duct obstruction and/or qualitative/quantitative changes in the glandular secretion which in end result in the alteration of the tear film. Thus in turn affects the health of the ocular surface. MGD is a term that brings together a group of several meibomian gland disorders ranging from acquired to congenital. A classification of MGD into two major categories based on meibomian gland secretion is proposed: low-delivery states and high-delivery states. To properly understand the MGD we must understand the glandular anatomy and physiology first.

2 Structure of the Meibomian gland

2.1 Anatomy of the Meibomian gland

A single meibomian gland is made up out of clusters of secretory acini that are arranged circularly around a long central duct and connected to it by short ductules. [1] The distal part of the central duct is blind, and the proximal end opens close to the posterior lid border, just anterior to the mucocutaneous junction(MCJ), at the lid margin, where the oily meibum on is delivered onto the tear meniscus. These separate glands are arranged in single parallel rows throughout the length of the tarsal plates in the lower and upper lids, in all probability they act in a coordinated fashion that is under control of hormonal and neural regulation and by the mechanical forces of muscle contraction during the eye blink.[2,3,4] The arrangement of the glands has been said to look like a chain of onions.[5] The length of the meibomian glands roughly corresponds to the dimensions of the tarsal plates in the lower and upper eyelids and therefore we can observe certain differences. For example the number of separate glands in the upper lid is given to be higher than the number of separate glands in the lower lid whit their median number being 31 to 26. [6] Additionally the lengths of the gland has been reported to differ with the length of the upper glands being approximately 5.5 mm and the length of the glands in the lower lid approximately 2 mm. and hence their calculated total volume is also higher: approximately double in the upper lid [5]




Figure 1 Anatomy of the Meibomian glands[1]

2.2 Embryology and Histology of the Meibomian gland

2.2.1 Embryology

The embryologic development of the meibomian glands occurs from the third to the seventh month of gestation, at the same time the sealed-lid phase of eyelid development occurs. [7] During this time, the loose connective tissue of the mesoderm in the lid folds differentiates into the tarsal plate and muscles (orbicularis and Riolan's muscle), the blood vessels, and the loose connective tissue underlying the outer lid skin and the conjunctiva. The development of the meibomian glands shows considerable similarities to that of the hair follicles, the hair anlage. The development of the meibomian glands shows considerable similarities to that of the hair follicles, the hair anlage. Both of them grow from the ectodermal sheet, which seals the fused lid folds down into the mesoderm, although the meibomian anlage is larger, grows deeper, and takes longer for complete development. [8] The epithelial cord of the meibomian anlage

develops lateral outgrowths that later differentiate further into the connecting ductules and secretory holocrine sebaceous acini. Inside the epithelial cylinder of the meibomian anlage the production of lipids leads to the formation of a central canal that later develops into the central duct. Lipid production by the more mature meibomian anlage and by the ciliary glands of Zeis has also been found to be related to the formation of a canal between the two sealed lid folds, which leads to the separation of the then fully differentiated upper and lower lids in the seventh month of gestation. [8]

2.2.2 Histology

The meibomian glands are composed of secretory acini that are connected via smaller ductules to the larger, long, straight central duct that extends throughout the length of the tarsal plate and opens onto the free lid margin close to the posterior lid border. The whole internal ductal system is lined by a stratified squamous epithelium with signs of beginning keratinization. Full keratinization (cornification), as indicated by the presence of luminal keratin lamellae, is physiologically only present in the terminal part of the central duct. [9,2] An acinus is a special kind of sebaceous gland, the secretory acini of the meibomian glands follow a holocrine secretion mode. They are completely filled with secretory cells, termed meibocytes. [10] The meibocytes are located more toward the center of the acinus and show progressive accumulation of lipids in the cytoplasm. One, or sometimes more, acini are connected to a ductile. The ductules are lined by a stratified squamous epithelium and they connect the acini to the central duct. At the junction from the acinus to the ductile, a fast transition from the peripheral layer of basal meibocytes to the ductal epithelium can be seen. [11] This observation was confirmed

when comparing the content of the cells. The cells of the ductules didn't show presence of lipid droplets inside them instead they contained keratohyalin granules. The connecting ductules enter the long central duct. The central duct is also lined by stratified squamous epithelium but has a wider lumen. The central duct extends throughout the total length of the gland, which corresponds roughly to the extension of the tarsus. [2,5,6] Around the terminal part of the central duct and among the terminal acini close to the free lid margin, there are various amounts of striated fibers of Riolan's muscle. Since epithelium of the free lid margin extends into the terminal part of the central duct and the epithelium in this terminal part has a different structure compared with the rest of the central duct, it appears justified to term it as an excretory duct. [12]

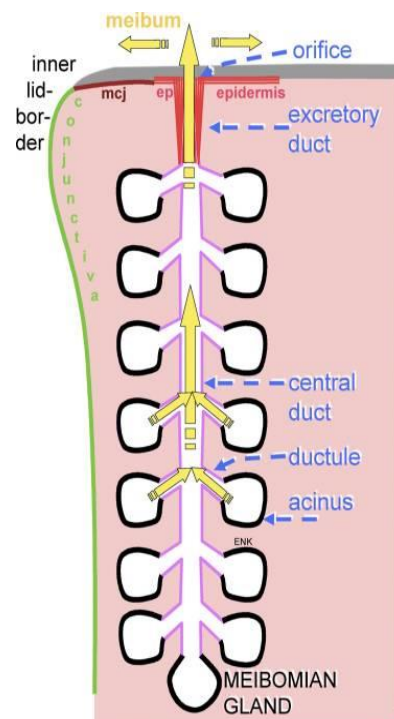


Figure 2 Histology of the Meibomian glands [1]

2.3 Physiology

The secretion of meibum occurs when Basal meibocytes move during their maturation, which includes the production and accumulation of lipids, from the basal compartment of the acinus toward its center and eventually toward the entrance of the ductile. [13] During this process, the meibocytes go through several stages that can be morphologically differentiated (basal, differentiating, mature, and hypermature), depending on several structural characteristics. [14] Cell organelles that are necessary for the production of lipids inside the cells increase in number and size during this process. All the components of the whole cell including nucleic acids, lipids and proteins contribute to the oily secretory product, which is also called meibum.[10] The ductal system may contribute to the final secretory product that is released onto the posterior lid margin in an active or passive way since at least in one part the originally secreted meibomian lipids are modified by hydrolyzing enzymes from commensal bacteria inside the ductal system that lead to a breakdown of triglycerides into free fatty acids and small portions of monoglycerides and other modifications in patients with blepharitis and even in normal conditions. Because of the length of the meibomian glands, there is frequently a long distance between the cell biological process of secretion of the meibum in the secretory acini and its actual delivery onto the lid margin where it exerts its functions therefore we tend to separate secretion of the meibum from its delivery. Constant production of new meibocytes in the secretory acini and their disintegration into the final secretory product generates a continuous secretory force that drives the meibomian oils within the ductal system of the gland toward the orifice at the free lid margin. The hypothesis of a continuous production is not only supported by the observed generation time of new meibocytes but also by the finding that in the morning after sleep, during

which the lids are closed, an increased amount of lipid that has accumulated within the ductal system is then delivered in increased amounts onto the lid margin. [13,15] The constant secretion further represents a solid basis for the generation of increased pressure within an obstructed gland. Furthermore the mechanical action of the lid muscles also contributes to delivery. During the movement of the eyelids during a blink, the orbicularis muscle, generates a compression of the tarsal plate and the enclosed tarsal glands of Meibom. As well the contraction of Riolan's muscle exerts compression of the terminal part of the ductal system and acini and contributes to the delivery of the oily meibum onto the surface of the lid margin. It has been assumed that the constrictive forces of Riolan's muscle may also close the terminal part of the meibomian gland, hence preventing the outflow (i.e., act in a somewhat antagonistic way on the flow of meibum compared to the pretarsal orbicularis muscle). It has been speculated that, in the act of a blink, the pretarsal orbicularis performs a "milking action" while Riolan's muscle is relaxed and, vice versa, between blinks, while the orbicularis is relaxed, Riolan's muscle contracts to prevent the outflow of meibum. [16]

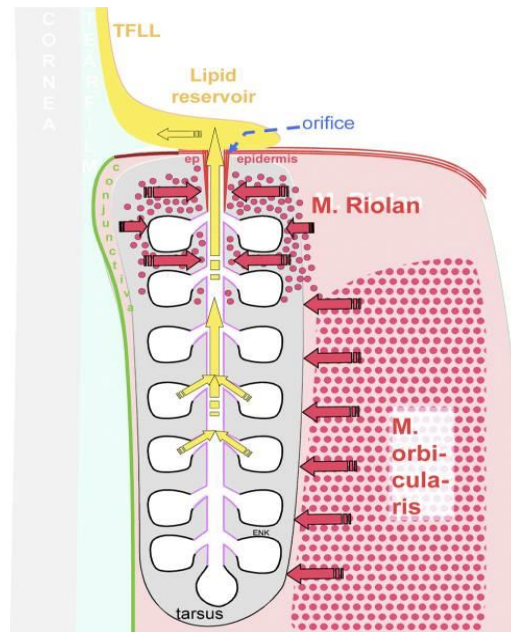


Figure 3 Physiology of the Meibomian glands [1]

2.4 Meibum

Increased expression of meibum in normal eyes correlates with reduced evaporation in both patients with DED and healthy individuals. The tear film lipid layer is derived from meibum which is secreted from the lid margins and is spread onto the tear film with each blink. It plays an important role in stabilizing the tear film and in the past has been thought to take part as a key role in retarding tear evaporation. The tear film lipid layer lowers the tear surface tension, consequently sustaining the tear film's high area-to-volume aspect ratio. In most cases the amount of meibum stored in the meibomian glands is in the range of several hundred micrograms per eyelid. [17] The lid reservoir contains at least 30 times the amount of lipid present on the surface of the tear film (approximately 300 μg vs. 10 μg , respectively). [15, 18] Meibum is composed of roughly 95% non-polar lipids and 5% amphipathic lipids. [19] The most abundant components of the meibomian lipids are waxes and sterol esters, consisting of fatty acids and fatty

alcohols, long-chain (>20C) fatty acids and alcohols, and sterols, particularly cholesterol. Sterol esters are formed by condensation of sterols with fatty acids, and wax esters are formed by condensation of fatty alcohols with fatty acids. The most abundant fatty acid is oleic acid, which has 18C and is monounsaturated (18:1(cis Δ 9) fatty acid.[20, 21] The non-polar component is composed of 30–50 mol% of wax esters,[22,23,24] 30–45 mol% of cholesterol esters,[25,26,27] and a really small percentage of triglycerides (~2%).[2] Other lipids that can be found in meibum include free cholesterol, which makes up <0.5 mol% and phospholipids, which make up <0.01 mol% of meibum.[27] The predominant amphipathic lipid family that is found in meibum is the (O-acyl)- ω -hydroxy fatty acids (OAHFAs), which contains about 4 mol% of total meibum.[26,27,28] The amount of OAHFAs and the low level of phospholipids imply that OAHFAs are the major surfactants in the tear film lipid layer.[29] Theoretically, these lipid components could either be synthesized de novo in the acinar cells or taken up from the bloodstream or both. The evidence for de novo synthesis is supported because the synthetic enzymes for the components and the transesterases to form the final products have been detected either directly or indirectly (mRNA) in the acinar cells. There is no direct evidence to date that the lipids are taken up from the bloodstream, and this is an area that warrants further investigations. Such uptake could show variations in lipid composition with change in diet, and the plasma cholesterol levels warrant further investigation relative to the cholesterol or cholesterol esters in tear fluid or meibomian secretions. [30]

3 Patophysiology

All forms of DED are evaporative in the sense that the ocular surface and tear hyperosmolarity can only arise in response to evaporation. EDE comes about as a result of a loss of evaporative barrier function of the tears or due to reduced ocular surface wettability. This has led to a sub classification into lid-related EDE and ocular surface related DED. MGD falls into the category of Lid-related evaporative dry eye. Furthermore we can differentiate MGD that come from physiological and pathophysiological changes. Physiological changes encompass Age-related Meibomian gland changes and the influence of sex hormones on the Meibomian gland. The pathophysiological changes to the Meibomian gland can be divided into hypersecretory or high meibum delivery state and hyposecretory or Low meibum delivery state. Further we can divide the Low meibum delivery state as shown in the table.

Hypersecretory	Hyposecretory
Meibomian Seborrhea	Cicatrical <ul style="list-style-type: none"> • Primary • Secondary Non-cicatrical

3.1 Physiological changes

3.1.1 Age related Meibomian gland changes

Age-related meibomian gland changes come from the change in the number of gland acini with increasing age. A study of Meibomian gland loss done by non-contact infra-red meibography in 236 healthy volunteers between the ages of 4 and 98 years [31] has

shown that there were few meibomian gland changes in either females or males younger than 20 years, after which there was a significant dropout with age, without a statistical difference between the sexes. Gland dropout was expressed as a combined score for the upper and lower lids of one eye. There have been reports that show that the Meibomian score becomes positive after 40 years of age [32], furthermore the observation of alteration in the expressibility of meibum in keeping with obstructive MGD has been noted. Studies suggest that the deficit of meibomian acini with age may on the one hand be caused by a primary, age-related, nonobstructive acinar atrophy and on the other hand by obstructive MGD. at the cellular level, of reduced meibocyte differentiation and cell cycling, together with reduced expression of the lipogenesis factor, peroxisome proliferator-activated receptor gamma (PPAR γ), in subjects over 50 years of age. Also, there are known, age-related changes in meibum polar and neutral lipid composition [33].

3.1.2 Sex hormone related Meibomian gland changes.

Meibomian function is strongly influenced by the sex hormones, particularly androgens. Androgen deficiency is a risk factor for meibomian gland dysfunction and a corresponding evaporative DED. The presence of dihydrotestosterone and testosterone have a significant role in upregulation of gene expression in the human Meibomian gland. Both of those compounds are known for influencing the differentiation, development and lipogenesis of sebaceous glands. [34]. The presence of androgens also helps in suppression of genes which are related to keratinization of the Meibomian glands. Androgens also influence the composition of the lipids and possibly

proteins within the Meibomian glands. In a study where an orchietomy was done to rabbits shows marked alteration in the lipid profile of the meibomian glands thus proving the importance of androgens in normal functioning Meibomian gland.

3.2 Pathophysiological changes

3.2.1 High delivery state

Meibomian seborrhea is the condition characterized with high Meibomian gland content expression. The prevalence of high delivery states has not been common but is still important. Seborrhea is described as “a disease marked by an excessive discharge from the sebaceous glands.” In seborrhea, “The mouths of the ducts of the sebaceous glands are less dilated, and from the dilated ducts slender filaments of sebaceous material can be readily expressed.”[35] Meibomian seborrhea has been encountered in association with rosacea and seborrheic dermatitis. The glands and the easily expressed meibum appear normal however, the clinical sign of bulbar injection and foam in the tear film support the likelihood that the chemical composition of the meibum has changed. [35] In meibomian seborrhea the symptoms frequently outweigh the clinical signs, symptoms being worse upon awakening. It is theorized that non-blinking during sleep causes retention of secretions upon first awakening the initial blinks release the stored secretions. Furthermore the composition of meibum make the secretion in this group of patients very fluid and toxic to the cornea. Toxicity of the meibum can be linked to the elevated levels of oleic acid present. The tear film appears to be thickened and although the release rate appears normal further production occurs while blinking which causes ocular irritation. In addition posterior blepharitis has been

seen to show clinical signs of high delivery of meibum, the signs can be seen by examining the posterior eyelid margin. Glands appear capped with oil, can be dilated, or be visibly obstructed.

3.2.2 Low delivery state

MGD is the most common cause of low meibum delivery, mainly due to obstructive disease. Obstructive MGD is the most frequent cause of EDE and it is believed that MGD-dependent EDE is the most common form of DED overall [1,38,39,40,41,42,43]

3.2.2.1 Cicatricial Meibomian gland dysfunction

Cicatricial MGD may occur as an isolated, primary condition, in combination with noncicatricial MGD or is most commonly found in association with the various forms of cicatricial conjunctivitis as a secondary condition.

3.2.2.1.1 Primary

In primary, cicatricial MGD, duct obstruction results from elongation, stretching and narrowing of the terminal ducts, so that each orifice and associated duct is dragged from its position anterior to the mucocutaneous junction and into the marginal conjunctival mucosa. As this occurs, the affected terminal duct comes to lie horizontally and is visible as a characteristic, elevated ridge in the occlusal mucosa of the free margin of the lid, which represents the dragged terminal ducts exposed under a thinned mucosal epithelium. [36] This is termed ductal exposure and presents as a slightly elevated, riblike feature that is a positive sign of the cicatricial process in addition the

affected orifices may be dragged posteriorly, across the MCJ, onto the tarsal plate, where they are ultimately lost to view or absorbed. [37] Primary, cicatricial MGD may affect scattered glands in the same lid exhibiting non-cicatricial MGD. It is probably less common than obstructive MGD but the frequency of its occurrence has not been documented.

3.2.2.1.2 Secondary

Secondary, cicatricial MGD is caused by conjunctival scarring and occurs in cicatricial conjunctival diseases. It is most commonly found in association with trachoma, erythema multiforme, and pemphigoid. [37] It may also accompany rosacea and vernal kerato-conjunctivitis. The process is more extensive than in primary disease and the orifices and ducts are dragged into the tarsal mucosa, where, in severe cicatricial disease they may no longer be visible, as they are absorbed into the scar tissue. In both the primary and secondary forms of the disease, even at an early stage when the ducts are still patent, once the orifices have been dragged into the mucosa, and therefore into the region of the tear meniscus, any oil that the glands deliver is released into the aqueous phase of the tear film and therefore is unlikely to contribute effectively to the tear film lipid layer (TFLL). With increasing severity the process leads to duct obstruction. [37] The affected ductules are frequently obstructed, but on occasion, pressure over the glands may express clear meibomian oil. Cicatricial MGD should be regarded as both structurally and functionally irreversible. Although therapy may suppress the inflammatory events, it cannot restore anatomic relationships. [37] In both conditions the MCJ may also be dragged posteriorly. Cicatricial MGD has not been

studied histologically and it would be beneficial to do a clinicopathological study directed specifically at orifices, ducts and glands.

3.2.2.2 *Non-cicatricial Meibomian gland dysfunction*

Non-cicatricial MGD most commonly occurs as a primary disorder with increasing frequency after the age of 50 years. [44] It also has multiple secondary associations, including dermatoses such as atopic dermatitis, seborrheic dermatitis and rosacea.

Additionally, the retinoid, isotretinoin, used in the treatment of acne vulgaris, causes meibomian gland atrophy in a number of patients, which shows features of MGD.

[45,46] In non-cicatricial MGD, the terminal ducts are obstructed by a process of hyperkeratinisation and the shedding of duct lining cells into the duct lumen forming keratotic plugs. [1,47,48,49] The hyperkeratinisation process may be linked to the remarkably increased expression of keratin genes in meibomian glands.

Hyperkeratinization is a major reason for obstructive MGD and causes degenerative gland atrophy and degeneration without inflammation. This typical pathology of the meibomian glands that comes as no surprise in view of the glands embryologic development. Factors increasing epithelial keratinization, meibomian gland obstruction and alterations of the lipid profile range from advancing age [50,51,52] and hormonal disturbances [53,54,55] to the toxic effects of medication and chemicals. [56,57]

Histological changes of the glands has shown signs obstruction and dilatation of the ducts as well as cystic degeneration and loss of secretory meibocytes that were replaced by a squamous metaplasia of the acinar epithelium. [58] Alterations occurred without the appearance of inflammatory leukocytes. It can be assumed that acinar degeneration and atrophy of the ductal system that were caused by dilatation results in

obstruction of the gland which subsequently leads to a later secondary hyposecretion due to the loss of secretory meibocytes. Further, it is likely that obstruction is worsened by an increase in meibomian lipid viscosity due to changes in meibomian lipid chemistry, and possibly interactions of lipids with cytokeratin proteins. The gland orifices remain located in the skin of the lid margin, initially anterior to the MCJ although, with age they may come to lie behind it as the MCJ migrates forwards. [59] The importance of the migration lies in its therapeutic implications, since, if gland function can be restored, the orifices remain in position to deliver the oil. The obstruction made by the thickened and cloudy meibum accompanied by the shedding of the ductal lining blocks the ducts and causes plugging of the orifices which leads to secondary, disuse- or pressure-atrophy of the glands [13,60,61] which appears as gland 'dropout' on meibography. [31] Gland loss is similar between left and right eyes and correspond to the loss between lower and upper lids. But there are regional differences, with greater loss nasally than temporally and lower loss on the upper compared to the lower. [62,63] Dropout has positive correlation with MGD grade and is inversely related to Meibomian gland expressibility and TFL thickness. Diagnosis of non-cicatricial MGD is based on the morphologic changes in the Meibomian orifices and gland acini observed by confocal microscopy, non-contact meibography and biomicroscopy. The changes seen are the narrowing of the orifices and lesser visibility of the distinctive ring which surrounds the healthy glands. [37,64] At an earlier stage, features include plugging of the orifices by cellular debris and absence of expressed. In severe stages the increase in vascularity and the appearance of telangiectasia can be noted as well as the distortion and finally scarring and atrophy of the orifices. Symptoms are present because of lid involvement and

ocular surface inflammation in the absence of increased evaporation. However, with progression of disease, the stage and extent of obstruction results in a reduced delivery of meibum to the tear film resulting in TFL deficiency and loss of its barrier function.

[65,66]

3.2.3 MGD secondary to local disease

3.2.3.1 Anterior blepharitis

Anterior blepharitis-related MGD may occur in conjunction with anterior blepharitis, particularly when they are both secondary manifestations of a dermatosis such as rosacea. [67,68,69,70,71] Potential sources of inflammation are the commensal bacteria of the lid whose lipolytic enzymes are capable of degrading meibum, with the production of altered lipid species, such as free fatty acids, that are irritant to the tissues. [72] A plethora of bacteria products that are capable of inducing inflammation is being reviewed such as lipopolysaccharides and chemoattractant lipids. The role of microorganisms in the etiology of MGD is not yet fully proven and not all studies report an increased bacterial commensal population or a consistent bacterial profile. Another cause of anterior blepharitis is the ectoparasite *Demodex*, which is found more and more with age on the surface of the human body. [73,74,75] *Demodex folliculorum*, is found in eye-lash and hair follicles and *Demodex brevis*, is found within sebaceous glands therefore including the meibomian glands. [73,74,75] Ectoparasites have been observed non-invasively at the orifices of meibomian glands, but their causative role in MGD and DED is not established.

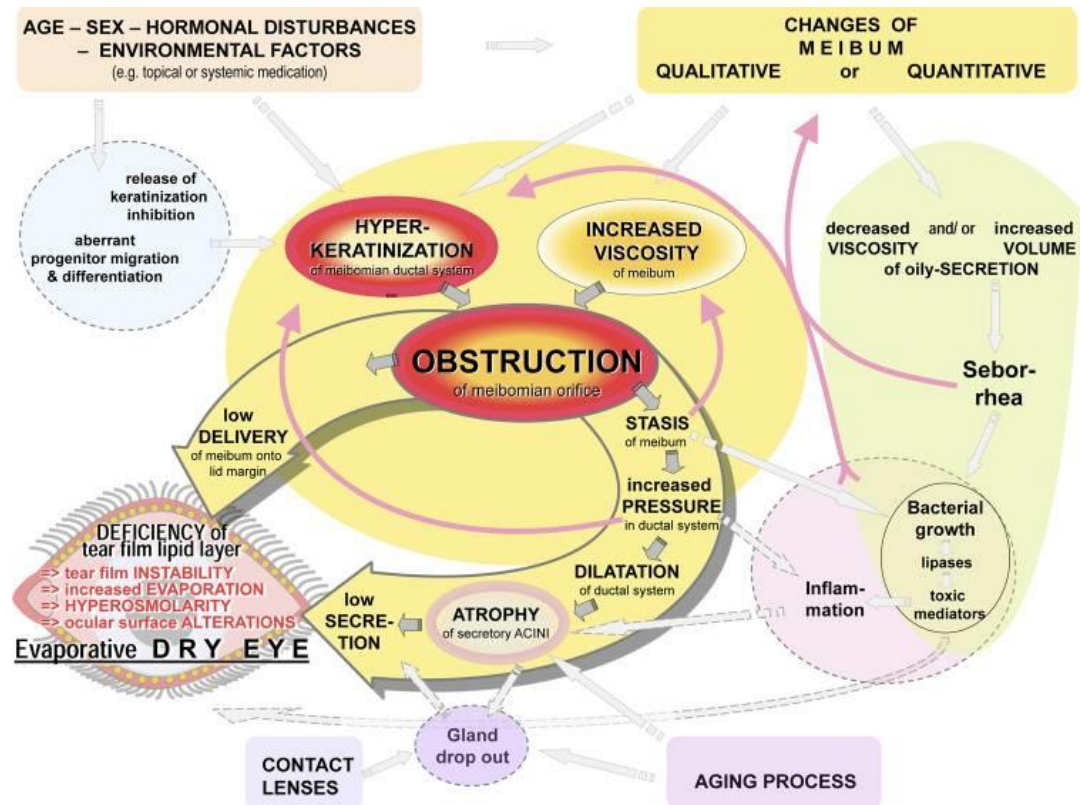


Figure 4 Pathophysiological pathways [1]

4

Diagnosis and Therapy

4.1 Diagnosis

Diagnostic methods that can be used to confirm Meibomian gland dysfunction are

- Lid wiper epitheliopathy
- Interferometry
- Meibography
- Meibometry
- Meibomian gland expressibility/duct assessment

4.1.1 Lid wiper epitheliopathy

A portion of the marginal conjunctiva of the upper and lower lid acts as a wiping surface that spreads the tear film over the ocular surface. [76,77] This contacting surface has been termed 'lid wiper'. It is postulated that when the tear film is thinned or becomes unstable that there might be a more mechanical/frictional effect on the lid wiper as the lid travels across the ocular during blinking. [76] As a result of insufficient boundary lubrication the wiper is traumatized and progresses into Lid wiper epitheliopathy. Lid wiper staining with dyes such as fluorescein and lissamine green, occurs principally in patients with abnormal eyelid structures and dry ocular surfaces. [76,78,79,80]

4.1.2 Interferometry

Oily substances spread over the surface of water to form a thin layer. Exposure of that layer to adequate light results in generation of an interferometric fringe pattern. The superficial oily layer of the tear film is thought to delay evaporation of the tears, and, with the rest of the tear film, produces an optically smooth surface over the cornea. [17,65,81] In conjunction with the surface reflection pattern and dynamics, interferometry can allow the thickness of the lipid layer of the tear film to be measured. Using slit lamp photometry to measure reflectivity, Olsen first estimated the thickness of the lipid layer of the tear film to be approximately 40 nm. [82] Interferometry is now an established technique for clinical examination of MGD that allows visualization of the kinetics of the oily layer of the tear film.

4.1.3 Meibography

Meibography is a specialized imaging study developed exclusively for the purpose of directly visualizing the morphology of meibomian glands. [83,84,85,86,87] Meibography allows observation of the silhouette of the meibomian gland morphological structure. Several different scoring scales, such as the meiboscore, have been proposed for the evaluation of meibography. Meibography alone does not appear to be sufficient for the diagnosis of MGD, but instead should be interpreted in the context of other clinical parameters such as Interferometry [41,88,89,90]

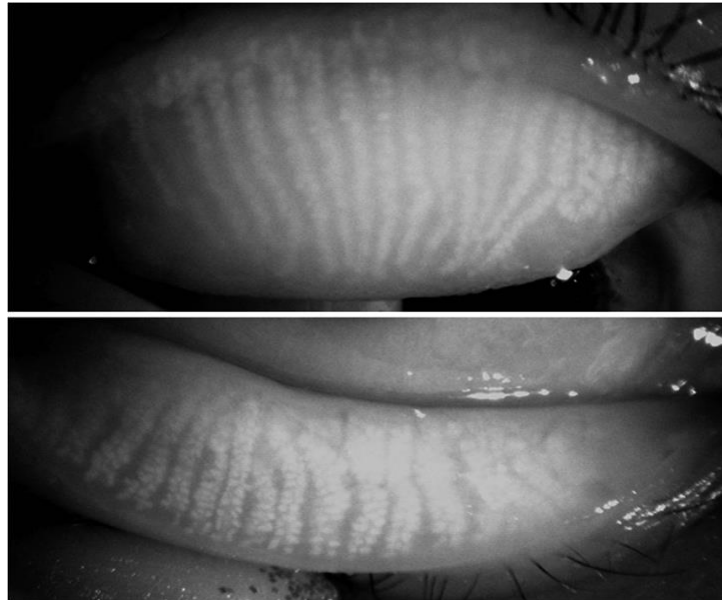


Figure 5 Physiological Meibography [37]

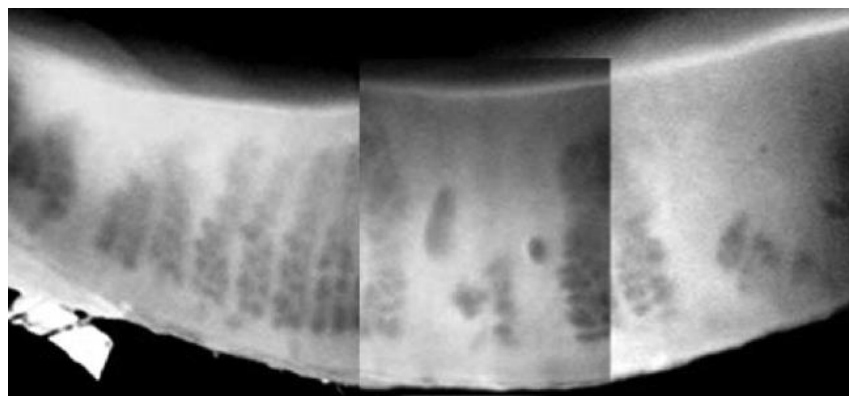


Figure 6 Transillumination meibography meibomian gland dropout [37]

4.1.4 Meibometry

Meibometry is a technique developed to measure basal meibum levels at the eyelid margin. [91,92,93] Essentially, a sample of meibum at the lid margin is moved to specialized tape whose transparency is altered by exposure to meibum. The percentage of change in tape transparency is analyzed photometrically for the purpose of quantifying the amount of basal meibum levels at the lid margin. Studies have shown that basal meibum levels can be different in MGD. Unfortunately, MGD can vary in the position of the dropout, rendering meibometric analysis endangered to inconsistent measurements within a given eyelid depending on the site of meibum collection along the lid margin. [91]

4.1.5 Meibomian gland expressibility/duct assessment

Meibomian glands secrete meibum and the quantity, quality and expressibility are thought to reflect meibomian gland function. The expressibility of meibum, as an indicator of meibum secretion, is commonly determined by the application of digital pressure to the glands. In the normal eyelid, meibum is clear and readily expressed with gentle pressure. Conversely, the condition of meibum in patients with MGD is varied. In such individuals, meibum can lose its clarity to become cloudy and then opaque and its viscosity can be increased, becoming toothpaste-like and difficult to express in patients with severe MGD. The number and location of expressible glands, as well the response of the glands to different levels of digitally applied pressure, have thus been scored and

graded, providing information directly related to meibomian gland condition.

[94,95,96,97] However, the diagnostic value of meibomian gland expressibility and duct appearance has not been established in DED.

4.2 Treatment

The treatment of Meibomian gland disease can be divided into the use of

- Ocular lubricants
- Warm Compresses
- Physical treatment

4.2.1 Ocular lubricants

The final result of MGD is decrease in the lipid layer thickness, it may be beneficial to replace the lipids with ocular lubricant eye drops or sprays that which are lipid-based. Increased lipid layer thickness grade and normal tear break up time in patients with MGD that had their eyes treated with a liposomal spray was confirmed. [98] To enhance the potential performance of lipid-based drops, nano-technology concepts have been incorporated into lipid emulsion eye drops. [99,100]

4.2.2 Warm compress

The efficacy of warm compresses has been proven in clinical studies but the drawback has been that the compliance is often poor due to the time required and the difficulty to maintain the temperature of the compress for an extended time. The efficacy of warm compresses has been proven in clinical studies but the drawback has been that

the compliance is often poor due to the time required and the difficulty to maintain the temperature of the compress for an extended time. [101,102,103] A study has concluded that wet surface increased heat transmission through the lid and should be used versus dry treatments. The ability of warm compresses to soften or liquefy the obstructions in MGD has been proven. The exact temperature and time that is required for the melting of the obstructive material in the Meibomian gland excretory duct has not been definitively proven. Evidence from multiple studies show that the melting points which range from 32 to 45 C actually depend on the content and the complexity of the lipids in the meibomian glands. [104,105,106,107] The recommended temperature for treatment is 40 C for the palpebral conjunctiva and the glands. Extra care should be taken not to increase the heat of the eyelids to more than 45 C to avoid thermal damage. [108,109] Fortunately ones response to pain is the safeguard that prevents extensive thermal damage to the eyelid skin by simply removing the excessively hot cloth when it is not tolerable. One of the possibly biggest concerns with this treatment method is that if the cornea is heated for approximately 8 min at a temperature form 36 C to 39.4 C it could be easily deformed ant visual blur can occur. [110,111] Therefore it has been deemed necessary to instruct the patient in the proper way of doing it.

4.2.3 Physical treatment

The purpose of applying physical treatment to the Meibomian glands is to restore and improve the function of the glands by relieving or removing ductal obstruction therefore allowing the glands to become functional. [112,114] Physical expression should not be confused with diagnostic expression, where minimal forces are used to determine if the

gland is functional. There are three established methods for physically treating ductal obstruction: forceful expression, intraductal probing and debridement scaling

4.2.3.1 Forceful expression

The forceful expression method includes isolating the eyelid to be expressed between the examiner's fingers and applying force by squeezing the eyelids against each other, or utilizing a rigid object on the inner surface of the eyelid or using another rigid object on the outer lid to apply force. [113] However the limiting factor with these methods is pain experienced by the patient, which is only minimally relieved by topical anesthetics.

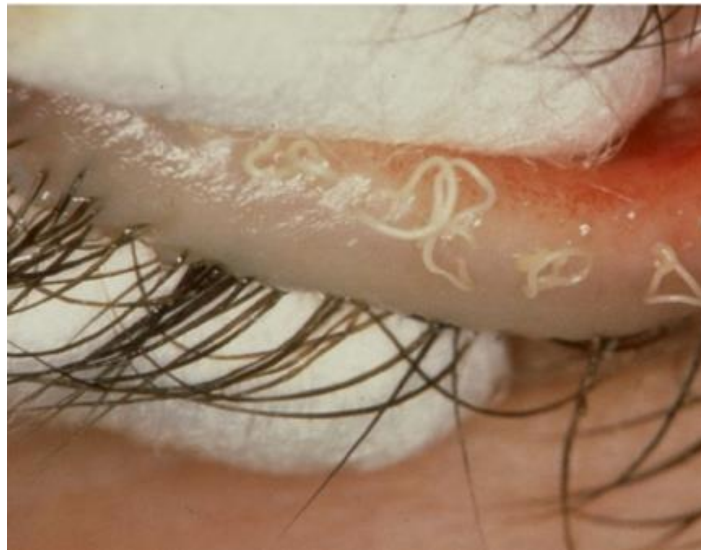

Figure 7 Forceful bimanual gland expression [37]

4.2.3.2 Intraductal probing

Intraductal probing is a procedure designed to clear obstructions in the meibomian glands. The procedure uses a probe to clear the ductal system from obstruction. It is an

effective treatment for meibomian gland dysfunction. The procedure is considered non-invasive, and is performed in the office with only topical anesthetic. [115] Intraductal probing may offer relief to MGD patients who are unresponsive to conventional treatment.

4.2.3.3 Debridement scaling

One of the primary mechanisms driving obstruction of the meibomian glands is hyper-keratinization of the eyelid margin and duct orifices. [1] Keratinized material is built up around and within the orifice, the gland is obstructed and meibum cannot be delivered from the gland to the tear film. This technique works by mechanically removing accumulated debris and keratinized cells using a stainless steel golf spud from the eyelid margin to allow increased flow of meibum into the tear film.

5 Acknowledgements

I would like to thank my mentor, Assistant Professor Igor Petriček, MD, PhD. for his support, mentorship and expert advice that helped me significantly during the process of writing my final thesis. I would also like to thank my Family, friends and specially my Fiance for their constant support during the past 6 years and especially during these last challenging months of my studies.

6 References

1 Knop E, Knop N, Millar T, Obata H, Sullivan DA. The international workshop on meibomian gland dysfunction: report of the subcommittee on anatomy, physiology, and pathophysiology of the meibomian gland. Invest Ophthalmol Vis Sci 2011;52:1938-78

- 2 Duke-Elder S, Wybar KC. The Anatomy of the Visual System. London: Henry Kimpton; 1961:577
- 3 Virchow H. Mikroskopische Anatomie der äusseren Augenhaut und des Lidapparates. In: Saemisch T. ed. Graefe-Saemisch Handbuch der gesamten Augenheilkunde. Band 1, 1. Abteilung, Kapitel II 2 ed. Leipzig: Verlag W. Engelmann; 1910:431
- 4 Wolff E. Anatomy of the Eye and Orbit. London: Lewis and Co.; 1954
- 5 Bron AJ, Tripathi DM, Tripathi BJ. Wolff's Anatomy of the Eye and Orbit. London: Chapman & Hall Medical; 1997: 231
- 6 Greiner JV, Glonek T, Korb DR, et al. Volume of the human and rabbit meibomian gland system. Adv Exp Med Biol. 1998;438:339–343
- 7 Mann I. The Development of the Human Eye. Cambridge UK: Cambridge University Press; 1928, Barber AN. Embryology of the Human Eye. St. Louis: C. V. Mosby Co.;1955:193–195
- 8 Andersen H, Ehlers N, Matthiessen ME. Histochemistry and development of the human eyelids. Acta Ophthalmol (Copenh). 1965;43:642–668
- 9 Knop N, Knop E. [Meibomian glands, Part I: anatomy, embryology and histology of the meibomian glands]. Meibom-Drüsen, Teil I: Anatomie, Embryologie und Histologie der Meibom-Drüsen. Ophthalmologe. 2009;106:872–883,
- 10 Nicolaides N, Kaitaranta JK, Rawdah TN, Macy JI, Boswell FM, Smith RE. Meibomian gland studies: comparison of steer and human lipids. Invest Ophthalmol Vis Sci. 1981;20:522–536
11. Jester JV, Nicolaides N, Smith RE. Meibomian gland studies: histologic and ultrastructural investigations. Invest Ophthalmol Vis Sci. 1981;20:537–547
- 12 Knop E, et al. IOVS 2009;50:ARVO E-Abstract 4833
13. Olami Y, Zajicek G, Cogan M, Gnessin H, Pe'er J. Turnover and migration of meibomian gland cells in rats' eyelids. Ophthalmic Res. 2001;33:170–175
- 14 Gorgas K, Völkl A. Peroxisomes in sebaceous glands. IV. Aggregates of tubular peroxisomes in the mouse Meibomian gland. Histochem J. 1984;16:1079–1098
15. Chew CK, Hykin PG, Jansweijer C, Dikstein S, Tiffany JM, Bron AJ. The casual level of meibomian lipids in humans. Curr Eye Res. 1993;12:255–259
16. Linton RG, Curnow DH, Riley WJ. The meibomian glands: An investigation into the secretion and some aspects of the physiology. Br J Ophthalmol. 1961;45:718–723

17. Bron AJ, Tiffany JM, Gouveia SM, Yokoi N, Voon LW. Functional aspects of the tear film lipid layer. *Exp Eye Res.* 2004;78:347–60.
18. Chew CK, Jansweijer C, Tiffany JM, Dikstein S, Bron AJ. An instrument for quantifying meibomian lipid on the lid margin: the Meibometer. *Curr Eye Res.* 1993;12:247–54.
19. Kunnen CM, Brown SH, Lazon de la Jara P, Holden BA, Blanksby SJ, Mitchell TW, et al. Influence of meibomian gland expression methods on human lipid analysis results. *Ocul Surf.* 2016;14:49–55.
20. Butovich IA, Uchiyama E, McCulley JP. Lipids of human meibum: mass-spectrometric analysis and structural elucidation. *J Lipid Res.* 2007;48:2220–2235
21. Harvey DJ, Tiffany JM, Duerden JM, Pandher KS, Mengher LS. Identification by combined gas chromatography-mass spectrometry of constituent long chain fatty acids and alcohols from the meibomian glands of the rat and a comparison with human meibomian lipids. *J Chromatogr.* 1987;414:253–263
22. Pucker AD, Nichols JJ. Analysis of meibum and tear lipids. *Ocul Surf.* 2012;10:230–50.
23. Butovich IA. Tear film lipids. *Exp Eye Res.* 2013;117:4–27.
24. Butovich IA. The Meibomian puzzle: combining pieces together. *Prog Retin Eye Res.* 2009;28:483–98.
25. Butovich IA. Cholesteryl esters as a depot for very long chain fatty acids in human meibum. *J Lipid Res.* 2009;50:501–13.
26. Lam SM, Tong L, Yong SS, Li B, Chaurasia SS, Shui G, et al. Meibum lipid composition in Asians with dry eye disease. *PLoS One.* 2011;6:e24339.
27. Brown SH, Kunnen CM, Duchoslav E, Dolla NK, Kelso MJ, Papas EB, et al. A comparison of patient matched meibum and tear lipidomes. *Invest Ophthalmol Vis Sci.* 2013;54:7417–24
28. Butovich IA, Wojtowicz JC, Molai M. Human tear film and meibum. Very long chain wax esters and (O-acyl)-omega-hydroxy fatty acids of meibum. *J Lipid Res.* 2009;50:2471–85.
29. Schuett BS, Millar TJ. An investigation of the likely role of (O-acyl) omega-hydroxy fatty acids in meibomian lipid films using (O-oleyl) omega-hydroxy palmitic acid as a model. *Exp Eye Res.* 2013;115:57–64.

- 30 Cholesterol in human tear fluid. van Haeringen NJ, Glasius E *Exp Eye Res.* 1975 Mar; 20(3):271-4
- 31 Arita R, Itoh K, Inoue K, Amano S. Noncontact infrared meibography to document age-related changes of the meibomian glands in a normal population. *Ophthalmology* 2008;115(5):911-5
- 32 Den S, Shimizu K, Ikeda T, Tsubota K, Shimmura S, Shimazaki J. Association between meibomian gland changes and aging, sex, or tear function. *Cornea* 2006;25:651-5
- 33 Sullivan BD, Evans JE, Dana MR, Sullivan DA. Influence of aging on the polar and neutral lipid profiles in human meibomian gland secretions. *Arch Ophthalmol* 2006;124:1286-92
- 34 <https://www.sciencedirect.com/journal/american-journal-of-ophthalmology/vol/5/issue/1>
- 35 Jimmy D. Bartlett, OD, DOS, ScD, Siret D. Jaanus, PhD, LHD Clinical Ocular Pharmacology
- 37 Alan Tomlinson, Anthony J. Bron, Donald R. Korb, Shiro Amano, Jerry R. Paugh, E. Ian Pearce, Richard Yee, Norihiko Yokoi, Reiko Arita, and Murat Dogru The International Workshop on Meibomian Gland Dysfunction: Report of the Diagnosis Subcommittee
- 36 Foulks GN, Bron AJ. Meibomian gland dysfunction: a clinical scheme for description, diagnosis, classification, and grading. *Ocul Surf* 2003;1:107-26
- 38 Shimazaki J, Sakata M, Tsubota K. Ocular surface changes and discomfort in patients with meibomian gland dysfunction. *Arch Ophthalmol* 1995;113:1266-70
- 39 Heiligenhaus A, Koch JM, Kemper D, Kruse FE, Waubke TN. [Therapy of dry eye disorders]. *Klin Monbl Augenheilkd* 1994;204:162-8
- 40 Nichols KK, Foulks GN, Bron AJ, et al. The international workshop on meibomian gland dysfunction: executive summary. *Investig Ophthalmol Vis Sci* 2011;52:1922-9
- 41 Lemp MA, Crews LA, Bron AJ, Foulks GN, Sullivan BD. Distribution of aqueous-deficient and evaporative dry eye in a clinic-based patient cohort: a retrospective study. *Cornea* 2012;31:472-8
- 42 Horwath-Winter J, Berghold A, Schmut O, Floegel I, Solhdju V, Bodner E, et al. Evaluation of the clinical course of dry eye syndrome. *Arch Ophthalmol* 2003;121:1364-8

- 43 Schaumberg DA, Nichols JJ, Papas EB, Tong L, Uchino M, Nichols KK. The international workshop on meibomian gland dysfunction: report of the subcommittee on the epidemiology of, and associated risk factors for, MGD. *Investig Ophthalmol Vis Sci* 2011;52:1994-2005
- 44 Mathers WD, Lane JA. Meibomian gland lipids, evaporation, and tear film stability. *Adv Exp Med Biol* 1998;438:349-60.
- 45 Fraunfelder FT, LaBraico JM, Meyer SM. Adverse ocular reactions possibly associated with isotretinoin. *Am J Ophthalmol* 1985;100:534-7
- 46 Mathers WD, Shields WJ, Sachdev MS, Petroll WM, Jester JV. Meibomian gland morphology and tear osmolarity: changes with Accutane therapy. *Cornea* 1991;10:286-90
- 47 Jester JV, Nicolaidis N, Kiss-Palvolgyi I, Smith RE. Meibomian gland dysfunction. II. The role of keratinization in a rabbit model of MGD. *Invest Ophthalmol Vis Sci* 1989;30:936-45
- 48 Jester JV, Nicolaidis N, Smith RE. Meibomian gland dysfunction. I. Keratin protein expression in normal human and rabbit meibomian glands. *Investig Ophthalmol Vis Sci* 1989;30:927-35.
- 49 Ong BL, Hodson SA, Wigham T, Miller F, Larke JR. Evidence for keratin proteins in normal and abnormal human meibomian fluids. *Curr Eye Res* 1991;10:1113-9
- 50 Norn M. Expressibility of meibomian secretion: relation to age, lipid precorneal film, scales, foam, hair and pigmentation. *Acta Ophthalmol (Copenh)*. 1987;65:137-142
- 51 Nien CJ, Paugh JR, Massei S, Wahlert AJ, Kao WW, Jester JV. Age-related changes in the meibomian gland. *Exp Eye Res*. 2009;89:1021-1027
- 52 Hykin PG, Bron AJ. Age-related morphological changes in lid margin and meibomian gland anatomy. *Cornea*. 1992;11:334-342
- 53 Cermak JM, Krenzer KL, Sullivan RM, Dana MR, Sullivan DA. Is complete androgen insensitivity syndrome associated with alterations in the meibomian gland and ocular surface? *Cornea*. 2003;22:516-521
- 54 Suzuki T, Schirra F, Richards SM, Jensen RV, Sullivan DA. Estrogen and progesterone control of gene expression in the mouse meibomian gland. *Invest Ophthalmol Vis Sci*. 2008;49:1797-1808
- 55 Schaumberg DA, Sullivan DA, Dana MR. Epidemiology of dry eye syndrome. *Adv Exp Med Biol*. 2002;506:989-998

- 56 Kohno T, Ohnishi Y. Histopathology of chronic meibomian gland abnormalities in experimental PCB-poisoned monkeys (in Japanese). *Fukuoka Igaku Zasshi*. 1987;78:254–258
- 57 Ohnishi Y, Kohno T, Ishibashi T, Shinoda Y. Macroscopic observation of the meibomian gland of the monkeys with experimental PCB intoxication (in Japanese). *Fukuoka Igaku Zasshi*. 1983;74:240–245
- 58 Gutgesell VJ, Stern GA, Hood CI. Histopathology of meibomian gland dysfunction. *Am J Ophthalmol*. 1982;94:383–387
- 59 Yamaguchi M, Kutsuna M, Uno T, Zheng X, Kodama T, Ohashi Y. Marx line: fluorescein staining line on the inner lid as indicator of meibomian gland function. *Am J Ophthalmol* 2006;141:669-75
- 60 Gutgesell VJ, Stern GA, Hood CI. Histopathology of meibomian gland dysfunction. *Am J Ophthalmol* 1982;94:383-7
- 61 Straatsma BR. Cystic degeneration of the meibomian glands. *AMA Arch Ophthalmol* 1959;61:918-27
- 62 Yin Y, Gong L. Uneven Meibomian Gland Dropout Over the Tarsal Plate and its Correlation With Meibomian Gland Dysfunction. *Cornea* 2015;34: 1200-5
- 63 Finis D, Ackermann P, Pischel N, et al. Evaluation of Meibomian Gland Dysfunction and Local Distribution of Meibomian Gland Atrophy by Noncontact Infrared Meibography. *Curr Eye Res* 2015;40:982-9
- 64 Bron AJ, Benjamin L, Snibson GR. Meibomian gland disease. Classification and grading of lid changes. *Eye (Lond)* 1991;5(Pt 4):395-411
- 65 Craig JP, Tomlinson A. Importance of the lipid layer in human tear film stability and evaporation. *Optom Vis Sci* 1997;74:8-13
- 66 Green-Church KB, Butovich I, Willcox M, Borchman D, Paulsen F, Barabino S, et al. The international workshop on meibomian gland dysfunction: report of the subcommittee on tear film lipids and lipid-protein interactions in health and disease. *Invest Ophthalmol Vis Sci* 2011;52:1979-93
- 67 Lemp MA, Nichols KK. Blepharitis in the United States 2009: A Survey-based Perspective on Prevalence and Treatment. *Ocul Surf* 2009;7:S1-14
- 68 McCulley JP, Dougherty JM, Deneau DG. Classification of chronic blepharitis. *Ophthalmology* 1982;89:1173-80.
- 69 McCulley JP, Shine WE. Meibomian secretions in chronic blepharitis. *Adv Exp Med Biol* 1998;438:319-26

- 70 Auw-Haedrich C, Reinhard T. Chronic blepharitis. Pathogenesis, clinical features, and therapy. *Ophthalmologie* 2007;104:817-26. quiz 827-818.
- 71 Kaercher T, Brewitt H. Blepharitis *Ophthalmologie* 2004;101:1135-47. quiz 1148
- 72 McCulley JP, Dougherty JM. Bacterial aspects of chronic blepharitis. *Trans Ophthalmol Soc U. K* 1986;105(Pt 3):314-8
- 73 Czepita D, Kuzna-Grygiel W, Czepita M, Grobelny A. Demodex folliculorum and Demodex brevis as a cause of chronic marginal blepharitis. *Ann Acad Med Stetin* 2007;53:63-7. discussion 67
- 74 Lacey N, Kavanagh K, Tseng SC. Under the lash: Demodex mites in human diseases. *Biochem (Lond)* 2009;31:2-6
- 75 Ng A, Bitton E, et al. Demodex infestation of the eyelash. *Contact Lens Spectr* 2014;29:36-41.
- 76 Korb DR, Greiner JV, Herman JP, Hebert E, Finnemore VM, Exford JM, et al. Lid-wiper epitheliopathy and dry-eye symptoms in contact lens wearers. *CLAO J* 2002;28:211-216
- 77 Bron AJ, de Paiva CS, Chauhan SK, Bonini S, Gabison EE, Jain S, et al. TFOS DEWS II Pathophysiology Report. *Ocul Surf* 2017;15:438-510
- 78 Berry M, Pult H, Purslow C, Murphy PJ. Mucins and ocular signs in symptomatic and asymptomatic contact lens wear. *Optom Vis Sci* 2008;85:E930-8.
- 79 Pult H, Purslow C, Berry M, Murphy PJ. Clinical tests for successful contact lens wear: relationship and predictive potential. *Optom Vis Sci* 2008;85:E924-9
- 80 Jones L, Varikooty J, Keir N, Soong F, Patel P. The evaluation of lid wiper epitheliopathy in contact lens wearers in a controlled low humidity environmental exposure chamber. *ARVO Meet Abstr* 2013;54:5475
- 81 Abusharha AA, Pearce EI. The effect of low humidity on the human tear film. *Cornea* 2013;32:429-34
- 82 Olsen T. Reflectometry of the precorneal film. *Acta Ophthalmol (Copenh)* 1985;63:432-8
- 83 Tapie R. Etude biomicroscopique des glandes de meibomius. *Ann Oculistique.* 1977;210:637-648.
- 84 Jester J.V., Rife L., Nii D., Luttrull J.K., Wilson L., Smith R.E. In vivo biomicroscopy and photography of meibomian glands in a rabbit model of meibomian gland dysfunction. *Invest Ophthalmol Vis Sci.* 1982;22:660-677.

- 85 Robin J.B., Jester J.V., Nobe J., Nicolaidis N., Smith R.E. In vivo transillumination biomicroscopy and photography of meibomian gland dysfunction. A clinical study. *Ophthalmology*. 1985;92:1423–1426.
- 86 Mathers W.D. Ocular evaporation in meibomian gland dysfunction and dry eye. *Ophthalmology*. 1993;100:347–351.
- 87 Mathers W.D., Shields W.J., Sachdev M.S., Petroll W.M., Jester J.V. Meibomian gland morphology and tear osmolarity: changes with Accutane therapy. *Cornea*. 1991;10:286–290.
- 88 Pult H, Riede-Pult BH. Non-contact meibography: keep it simple but effective. *Cont Lens Anterior Eye* 2012;35:77-80
- 89 Arita R, Itoh K, Maeda S, Maeda K, Furuta A, Fukuoka S, et al. Proposed diagnostic criteria for obstructive meibomian gland dysfunction. *Ophthalmology* 2009;116. 2058-63 e1.
- 90 Finis D, Ackermann P, Pischel N, Konig C, Hayajneh J, Borrelli M, et al. Evaluation of meibomian gland dysfunction and local distribution of meibomian gland atrophy by non-contact infrared meibography. *Curr Eye Res* 2015;40:982-9
- 91 Yokoi N., Mossa F., Tiffany J.M., Bron A.J. Assessment of meibomian gland function in dry eye using meibometry. *Arch Ophthalmol*. 1999;117:723–729.
- 92 Chew C.K., Jansweijer C., Tiffany J.M., Dikstein S., Bron A.J. An instrument for quantifying meibomian lipid on the lid margin: the Meibometer. *Curr Eye Res*. 1993;12:247–254.
- 93 Komuro A., Yokoi N., Kinoshita S., Tiffany J.M., Bron A.J., Suzuki T. Assessment of meibomian gland function by a newly-developed laser meibometer. *Adv Exp Med Biol*. 2002;506:517–520.
- 94 Pflugfelder SC, Tseng SC, Sanabria O, Kell H, Garcia CG, Felix C, et al. Evaluation of subjective assessments and objective diagnostic tests for diagnosing tear-film disorders known to cause ocular irritation. *Cornea* 1998;17:38-56
- 95 Blackie CA, Korb DR. The diurnal secretory characteristics of individual meibomian glands. *Cornea* 2010;29:34-8
- 96 Shimazaki J, Goto E, Ono M, Shimmura S, Tsubota K. Meibomian gland dysfunction in patients with Sjogren syndrome. *Ophthalmology* 1998;105:1485-8. Henriquez AS, Korb DR. Meibomian glands and contact lens wear. *Br J Ophthalmol* 1981;65:108-11.
- 97 Blackie CA, Korb DR. Recovery time of an optimally secreting Meibomian gland. *Cornea* 2009;28:293-7

- 98 Craig JP, Purslow C, Murphy PJ, Wolffsohn JS. Effect of a liposomal spray on the pre-ocular tear film. *Cont Lens Anter Eye* 2010;33(2):83-7
- 99 Zhang W, Wang Y, Lee BT, Liu C, Wei G, Lu W. A novel nanoscale-dispersed eye ointment for the treatment of dry eye disease. *Nanotechnology* 2014;25(12):125101
- 100 Gan L, Wang J, Jiang M, Bartlett H, Ouyang D, Eperjesi F, et al. Recent advances in topical ophthalmic drug delivery with lipid-based nanocarriers. *Drug Discov Today* 2013;18(5-6):290-7
- 101 Geerling G, Tauber J, Baudouin C, Goto E, Matsumoto Y, O'Brien T, et al. The international workshop on meibomian gland dysfunction: report of the subcommittee on management and treatment of meibomian gland dysfunction. *Invest Ophthalmol Vis Sci* 2011;52(4):2050-64
- 102 Alghamdi YA, Camp A, Feuer W, Karp CL, Wellik S, Galor A. Compliance and Subjective Patient Responses to Eyelid Hygiene. *Eye Contact Lens* 2017. In press. Sim HS, Petznick A, Barbier S, Tan JH, Acharya UR, Yeo S, et al. A Randomized, Controlled Treatment Trial of Eyelid-Warming Therapies in Meibomian Gland Dysfunction. *Ophthalmol Ther* 2014;3(1-2):37-48
- 103 Villani Edoardo, Garoli Elena, Canton Veronica, Pichi Francesco, Nucci Paolo, Ratiglia Roberto. Evaluation of a novel eyelid-warming device in Meibomian gland dysfunction unresponsive to traditional warm compress treatment: an in vivo confocal study. *Int Ophthalmol* 2015;35(3):319-23.
- 104 Bron AJ, Tiffany JM. The contribution of meibomian disease to dry eye. *Ocul Surf* 2004;2(2):149e65
- 105 Nichols KK, Ham BM, Nichols JJ, Ziegler C, Green-Church KB. Identification of fatty acids and fatty acid amides in human meibomian gland secretions. *Invest Ophthalmol Vis Sci* 2007;48(1):34-9
- 106 Blackie CA, Korb DR, Knop E, Bedi R, Knop N, Holland EJ. Nonobvious obstructive meibomian gland dysfunction. *Cornea* 2010;29(12):1333-45
- 107 Goto E, Endo K, Suzuki A, Fujikura Y, Tsubota K. Improvement of tear stability following warm compression in patients with meibomian gland dysfunction. *Adv Exp Med Biol* 2002;506(Pt B):1149-52.
- 108 Despa F, Orgill DP, Neuwald J, Lee RC. The relative thermal stability of tissue macromolecules and cellular structure in burn injury. *Burns* 2005;31(5):568-77
- 109 Moritz AR, Henriques FC. Studies of Thermal Injury: II. The Relative Importance of Time and Surface Temperature in the Causation of Cutaneous Burns. *Am J Pathol* 1947;23(5):695-720

- 110 Blackie CA, McMonnies CW, Korb DR. Warm compresses and the risks of elevated corneal temperature with massage. *Cornea* 2013;32(7):e146-9
- 111 Solomon JD, Case CL, Greiner JV, Blackie CA, Herman JP, Korb DR. Warm compress induced visual degradation and Fischer-Schweitzer polygonal reflex. *Optom Vis Sci* 2007;84(7):580-7.
- 112 Lane SS, DuBiner HB, Epstein RJ, Ernest PH, Greiner JV, Hardten DR, et al. A new system, the LipiFlow, for the treatment of meibomian gland dysfunction. *Cornea* 2012;31(4):396e404
- 113 Hom MM, Silverman MW. Displacement technique and meibomian gland expression. *J Am Optom Assoc* 1987;58(3):223-6
- 114 Korb DR, Henriquez AS. Meibomian gland dysfunction and contact lens intolerance. *J Am Optom Assoc* 1980;51(3):243-51
- 115 <https://www.dovepress.com/intraductal-meibomian-gland-probing-background-patient-selection-proce-peer-reviewed-fulltext-article-OPHTH>

7 Biography

I was born in Zagreb on November the 2nd 1994. After elementary school I finished a General education high school in Zagreb, and started university at the University of Zagreb, Faculty of Science - Chemistry and Geology Department where I studied chemistry for a year. After a year I decided to go into Medicine, and enrolled into the University of Zagreb School of Medicine in 2014 where I am currently a 6th year student. I was a student demonstrator at the department of Physics in the year 2015/2016. I was also a student demonstrator for the course "History taking and physical examination" in the years 2018/2019 and 2019/2020. Outside of medicine I am fluent in English and German. I also practice Ice Hockey on a semi-professional level where im a Goalie. I have won the Best goalie of the season award 2 times once in 2014/2015 and in 2018/2019. I have represented team Croatia in categories of U-18 and U-20 on multiple occasions. I have also participated in the Olympic Games qualifiers for the Croatian national team in 2019/2020.