

All-Inside anterior cruciate ligament reconstruction

Schumacher, Bastian So-Song

Master's thesis / Diplomski rad

2021

Degree Grantor / Ustanova koja je dodijelila akademski / stručni stupanj: **University of Zagreb, School of Medicine / Sveučilište u Zagrebu, Medicinski fakultet**

Permanent link / Trajna poveznica: <https://um.nsk.hr/um:nbn:hr:105:193967>

Rights / Prava: [In copyright](#)/[Zaštićeno autorskim pravom.](#)

Download date / Datum preuzimanja: **2024-10-16**



Repository / Repozitorij:

[Dr Med - University of Zagreb School of Medicine Digital Repository](#)



UNIVERSITY OF ZAGREB

SCHOOL OF MEDICINE

Bastian So-Song Schumacher

**All-Inside Anterior Cruciate Ligament
Reconstruction**

GRADUATE THESIS



Zagreb, 2021

This graduate thesis for achieving the degree of Medical Doctor (M.D.) was realized under the supervision of Prof. dr. sc. Mislav Jelić at the Department of Orthopaedic Surgery and was submitted for evaluation during the academic year of 2020/2021.

Mentor of the graduate thesis: Mislav Jelic, MD, PhD, Associate Professor

ABBREVIATIONS

- ACL: Anterior Cruciate Ligament
- PKL: Prednji Križni Ligament
- ACLR: Anterior Cruciate Ligament Reconstruction
- AIT: All-Inside Technique
- AL: Anterolateral
- AM: Anteromedial
- TL: Translateral
- BPTB: Bone Patellar Tendon Bone

Table of Contents

Table of Figures	5
1. Abstract	6
1.2. Sažetak	7
2. Introduction	8
2.1. Anatomy and function of the ACL	9
2.2. ACL injuries and causes	11
2.3. General Principles of ACL reconstruction	13
2.4. Evolution of ACL Reconstruction Techniques	13
2.5. Presumptive Advantages of All-Inside ACL Reconstruction	15
3. All-Inside ACL Reconstruction Technique	17
3.1. Procedural Overview	17
3.2. Graft	18
3.2.1. Graft Selection	18
3.2.2. Graft Harvesting	18
3.2.3. Graft Preparation	19
3.3. Socket creation	22
3.3.1. Femoral Socket Drilling	22
3.3.2. Tibial Socket Drilling	26
3.4. Graft Passage and Fixation	29
4. All-Inside Technique vs. Standard Technique	32

4.1. Free anatomical socket positioning	32
4.2. Closed tunnel sockets versus open tunnel	33
4.3. Graft selection	34
4.4. Autograft harvest associated functional deficits	34
4.5. Morbidity of the harvest site	35
4.6. Dual suspensory fixation	35
4.7. Costs	36
4.8. Application in skeletally immature individuals	36
Conclusion	38
Acknowledgement	39
Bibliography	40

Table of Figures

Figure 1: Anatomy of the knee and position of the ACL.....	10
Figure 2: Causes of ACL injuries – numbers in percentage.....	12
Figure 3: Superior edge of sartorius. Release of tendon with stripper	18
Figure 4: Graft loaded to graft-preparation station	19
Figure 5: Closing the loop on the tibial side	20
Figure 6: Closure of the loop with a wrapped cinch	20
Figure 7: Final four stranded graft construct	21
Figure 8: Graft inside the spring-loaded tensioning device	21
Figure 9: Transtibial drilling of femoral tunnel	22
Figure 10: Second generation retrograde drill.....	23
Figure 11: ACL femoral socket in the left knee	24
Figure 12: Antero-medial portal drilling of femoral socket.....	25
Figure 13: Retrograde inside-out tibial socket drilling.. ..	27
Figure 14: Tibial socket drilling. Nitinol wire. Flexible reamer.	28
Figure 15: Arthroscopic view of tibial socket.	28
Figure 16: Flexible silicon cannula in anteromedial portal of left knee.....	29
Figure 17: Overview of femoral sutures and graft	29
Figure 18: Advancement of graft and placement inside sockets.....	30
Figure 19: Graft fixation.....	31

1. Abstract

Title: All-Inside Anterior Cruciate Ligament Reconstruction

Key words: anterior cruciate ligament, ACL, ACL rupture, all-inside technique, ACL reconstruction, retrograde drilling, closed socket tunnel, tibial socket, femoral socket, graft preparation, graft fixation, suspensory fixation.

Author: Bastian So-Song Schumacher

Rupture of the anterior cruciate ligament (ACL) remains one of the most frequent orthopaedic pathologies, especially affecting the young population. The aim of the ACL reconstruction surgery is to restore the original stability and functionality of the knee joint, enabling the individual to return to the previous level of physical activity. A variety of surgical techniques have been introduced mainly differing in graft selection, positioning, drilling, fixation and tensioning. The all-inside ACL reconstruction technique including its two closed socket tunnels, double suspensory fixation and smaller skin incisions, features a unique improvement over the standard technique. This fairly new technique is therefore gaining popularity as a more anatomic and less invasive option with the potential for a faster and better recovery. The goal of this review is to present and explain all surgical steps of the all-inside ACL reconstruction procedure, to outline the advantages and challenges of this technique and to analyse and compare the outcome to previous methods.

1.2. Sažetak

Naslov: Rekonstrukcija prednjeg križnog ligamenta tehnikom “All Inside”

Ključne riječi: prednji križni ligament, PKL, ruptura prednjeg križnog ligamenta, tehnika “All Inside”, Rekonstrukcija prednjeg križnog ligamenta, retrogradno bušenje, zatvorena čahura, tibijalna čahura, femoralna čahura, preparacija presatka, fiksacija presatka, fiksacija suspenzora.

Autor: Bastian So-Song Schumacher

Oštećenje prednjeg križnog ligamenta (PKL) predstavlja jednu od najčešćih ortopedskih patologija, koja posebice pogađa mlađu populaciju. Cilj rekonstrukcije PKL jest uspostava prvotne stabilnosti i funkcionalnosti zgloba koljena, omogućavajući pojedincu povratak prethodnom stupnju fizičke aktivnosti. Uvedene su razne operacijske tehnike koje se uglavnom razlikuju u izboru transplantata, pozicioniranju, bušenju, fiksiranju i zatezanju. Rekonstrukcija prednjeg križnog ligamenta tehnikom “All Inside”, koja uključuje dvije zatvorene čahure, dvostruku suspenzorsku fiksaciju i manje rezove na koži, predstavlja jedinstveni napredak u odnosu na standardni postupak. Ova relativno nova metoda stoga zadobiva popularnost kao više anatomska i manje invazivna opcija s potencijalom za brži i bolji oporavak. Cilj ovog pregleda jest predstaviti i objasniti sve kirurške korake “All-Inside“ PKL rekonstrukcijske procedure, naglasiti prednosti i izazove ove tehnike te analizirati i usporediti ishod s prijašnjim postupcima.

2. Introduction

Injuries to the ACL have nowadays become one of the most common problems among all age groups. This specifically affects young athletes, but it is also the case for recreationally active people as well as for physically inactive or obese individuals. The ACL is a crucial element for the functional stability of the human knee. Therefore, any sort of injury or even rupture of this ligament inevitably results in the loss of knee stability. Consequently, this condition critically affects the individual's daily life, not only limiting their sportive activities but simply their physical mobility. In addition to that a simple isolated injury to the ACL can consequently cause degeneration of all the other knee components as well as an increased risk for meniscal injuries.

For these obvious reasons the surgical ACL reconstruction has become a very common orthopaedic procedure, designed to restore the original stability of the knee. While there is also the lengthy possibility of non-surgical treatment, statistical observations have proven a better overall outcome for a surgical intervention. Over the past decades numerous techniques have been described by various authors, ranging from intra- to extra-articular approaches. The usage of arthroscopy is the current mainstay of ACL reconstruction while the success rates of such interventions depend on three crucial elements, namely the biological, mechanical and rehabilitation factors. The overall goal of ACL reconstruction surgery is to restore stability and to maintain full active range of movement. For this purpose, the surgeon has to reproduce the restraining action of the ACL with the utilization of a graft that is able to withhold the kinematics of the human knee.

The all-inside ACL reconstruction technique is a relatively new technique in ACL reconstruction surgery. This new technique includes closed socket tunnels retrogradely drilled into both femur and tibia and therefore enabling less bone removal, dual graft fixation with suspensory buttons on femur and tibia and lastly minimized skin incisions.

The purpose of this paper is to address the components and procedure steps of the all-inside ACL reconstruction technique and to analytically compare the outcomes of this method with the standard mainstream technique.

2.1. Anatomy and function of the ACL

The anterior or inner cruciate ligament, or simply the ACL, is situated inside the joint capsule and is one of the core ligaments of the knee joint. It is isolated from the true joint surfaces by lying partially between the outer and inner sheets of the joint capsule. Along with the posterior cruciate ligament and the two collateral ligaments, the ACL ties the knee joint together by extending between the epicondyles of both, the femur and the tibia. It runs from the inner surface of the femoral bone, precisely the lateral femoral condyles, to the cartilage-free anterior, middle portion of the tibial head, precisely the anterior intercondylar area (Figure 1). As a result, it pulls from top to bottom, back to front, and outside to inside.

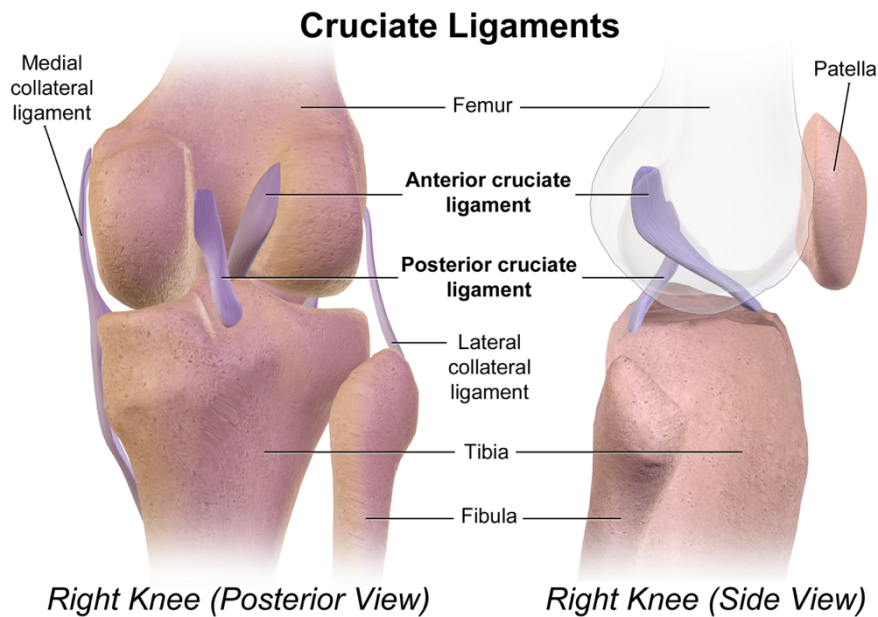


Figure 1: Anatomy of the knee and position of the ACL. [1]

The ACL is the smaller one of the two cruciate ligaments. It has a length of about 2 – 4 cm and a thickness of approximately 1 cm. The ligament is made up of tightly oriented fibres of connective tissue, namely closely woven collagen fibre bundles. There are three sections of the ACL which can be functionally distinguished from one another – the anteromedial part, the posterolateral part and the intermediate section which is connecting both parts. The anteromedial part tenses further when the knee is flexed and the posterolateral part tenses when the knee is stretched.

The stabilizing function of the anterior and the posterior ligaments is to avoid sagittal forward or backward movement between the femoral and the tibial bone, in addition to merely keeping the knee joint together. The anterior cruciate ligament, which is especially tense on the posterolateral side, limits tibia extension and avoids anterior displacement. Because it remains partly tense in any position, the anterior cruciate ligament stabilizes the knee during the entire flexion and extension movement. And since both the cruciate and collateral ligaments are maximally tense in the stretched knee, this position represents the most stable state of the knee. In contrary, the

collateral ligaments slacken in the flexed knee position, while the cruciate ligaments are securing the knee stability solely. Both cruciate ligaments often serve as the pivot of the knee joint's rotational axis. They coil around each other during flexion and when rotated internally, but are almost parallel to each other when rotated externally. Thus, there is a higher degree of outward rotation than inward rotation of the lower leg [2].

2.2. ACL injuries and causes

Damage to the anterior cruciate ligament represent the most frequent knee ligament injuries. The isolated injury of the inner collateral ligament comes second. The clinically most significant injury of the anterior cruciate ligament is a rupture, which can be a total or partial tear of the ligament. Especially events in which the knee is exposed to high physical forces such as acceleration, braking, changing of direction and rotation bear a high risk for this kind of knee injuries. These can either occur completely isolated to the ACL or in combination with damage to other ligament, for example the inner collateral ligament and the inner meniscus. The so-called “anterior drawer sign” can be used as a diagnosis, in which the lower leg can be freely shifted forward in relation to the thigh with the knee bent at an angle of 90°.

Because the ACL has a naturally poor blood supply, spontaneous healing scarcely occurs following such injury. Therefore, treatment should always be assessed on an individual basis. Non-operative treatment could be considered when the patient is older than 35 years, is not highly active, has a minimal tibial subluxation and does not suffer from any additional intra-articular injury. But although conservative therapy through targeted muscle training could be a reasonable treatment option,

reconstruction surgery is mostly the ideal form of therapy. The operative treatment is especially preferred when the patient is under the age of 25 years, is highly active, has a marked tibial subluxation and suffers from additional intra-articular injury. Under no circumstances should a cruciate ligament tear be left untreated, as this certainly results in further damage to the knee joint.

The majority of people affected by ACL injuries are in their twenties, participating in athletics, and male in more than two-thirds of the cases. An isolated anterior cruciate ligament tear occurs only infrequently in less than 10 % of the cases. About half of the ACL injuries are accompanied by a concomitant meniscal injury. In around 25 % of the cases, the anterior cruciate ligament is torn and not completely interrupted. [3].

Over 90 % of the ACL injuries are related to sport-trauma (Figure 2). Injuries due to soccer are accountable for over 50 % of these cases. Skiing, volleyball and basketball are more or less equally liable for around 8 % each. Sport-unrelated ACL injuries are mainly the results of road accidents (5 %) and accidental falls (3 %) [4].

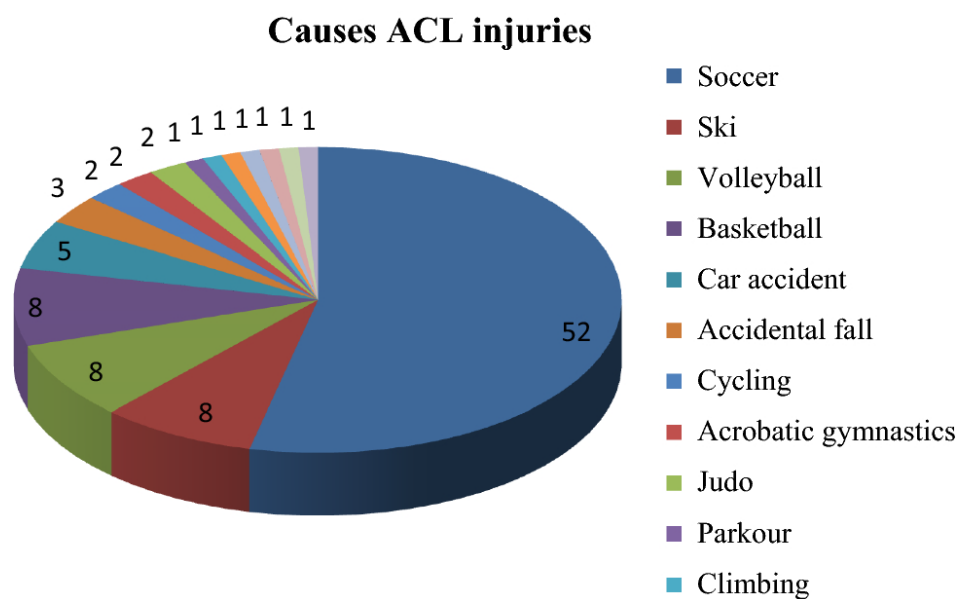


Figure 2: Causes of ACL injuries – numbers in percentage [4]

2.3. General Principles of ACL reconstruction

The natural ACL in an undamaged knee provides a functional stability which is both, resisting to rotational subluxation as well as to anteroposterior translation. The overall purpose of ACL reconstruction surgery is to restore this knee stability while maintaining the full active range of movement with an isometric ligament function. There is a vast variety of different ACL reconstruction techniques, depending on the patient's symptoms and involving different graft materials, as well as the surgeon's preference. This range of options includes arthroscopic or open techniques, intra-articular or extra-articular techniques, different tunnel placement options, number of graft strands and the graft fixation techniques.

Factors such as patient selection, surgical technique, postoperative rehabilitation and associated secondary restraint ligamentous instability are crucial for a satisfactory ACL reconstruction outcome. False tunnel placement, wrong graft selection or inferior fixation techniques could lead to a poor long-term outcome and subsequent damage to other knee components.

2.4. Evolution of ACL Reconstruction Techniques

The first successful reconstruction of the ACL was performed in 1895. Ever since the orthopaedic techniques of surgically restoring the stability of the knee have passed through a constant process of change and tremendously advanced over the years. Although the standard open procedure technique has also evolved over the last century, it has a distinctive disadvantage, namely the invasiveness and the potential to further destabilize the knee. Consequently, the arthroscopic ACL surgeries have

started to become more popular since the 1980s and became the surgical technique of choice as the technological progress improved enormously and opened up new possibilities. Different application types of arthroscopic techniques for ACL reconstruction have been introduced from various sources. Techniques were constantly adjusted and evolved drastically over time, with the aim to limit the number and extent of incision as well as to achieve higher anatomical accuracy. The initial outside-in drilling technique with two incisions created two full tunnels on both the femoral and the tibial side. Later this technique was changed to an inside-out method which enabled the creation of a closed tunnel, or socket, on the femoral side. This was achieved by drilling the femur only halfway while fixating the graft with cortical suspensory buttons to the condyle and therefore making the distal-lateral femoral incision redundant [5]. Eventually the all-inside method was introduced, distinguishing itself from other methods by the use of two sockets on both the femoral and tibial side. This method further obviated the need of the proximal-medial tibial incision [6]. The unique features of the all-inside technique (AIT) are the aforementioned closed socket tunnels which reduce unnecessary bone removal, the femoral and tibial fixation with suspensory buttons and an overall minimized number of required incisions for this intervention. Since its first introduction the all-inside technique has constantly been modified and many variations of this method have been introduced over the past two decades. But despite all these series of modifications, there are two crucial factors that have remained common in most of the available variations [7]: Firstly, they are all using so-called closed-tunnels or sockets on both the femoral and tibial sides, which are independently created by inside-out drilling mode. Secondly, all methods share the common feature of inserting the graft via the arthroscopic tunnel into the knee [8].

The replacement of full bone tunnels by these closed sockets, which not only preserve bone stock but supposedly also minimize any graft motion and synovial fluid leakage, is one major advantage and the reason why the majority of surgeons prefers the all-inside technique over other techniques. Nevertheless, one of the disadvantages worth mentioning with this technique are the higher costs of new instrumentations and its associated economic impact on the health care system [7].

2.5. Presumptive Advantages of All-Inside ACL Reconstruction

The all-inside technique is proposed to have various advantages making it superior over the standard procedure techniques. This includes among others an enhanced postoperative preservation of muscle tone, tendon and bone tissue and therefore lowering the overall impact on the individual's musculoskeletal system. Further, there is a better bone-graft integration as a result of the manual drilling procedure, which allows a highly anatomic tibial socket placement while decreasing the risk of tibial plateau fractures. This anatomic reproduction creates a better graft resistance towards the kinematic forces exerted by natural knee movements and therefore decreasing recurrence of the injury. Specifically, the physical properties of the socket itself are suggestive for speeding up the graft's maturation process while simultaneously avoiding any tunnel enlargement and wear-out failure due to elimination of dead space [9]. The minimally invasive procedure requires less incisions and therefore facilitates not only a better cosmetic outcome for the patient, but also decreases the risk of postoperative complications such as pain or infections. This again reduces the required days of minimal hospital stay and could therefore contribute to a better economic compatibility.

Nevertheless, many of these presumptive advantages of the AIT still remain to be statistically proven in dedicated research studies.

3. All-Inside ACL Reconstruction Technique

3.1. Procedural Overview

Before the initial start of the AIT for ACL reconstruction the surgeon must conduct a thorough arthroscopic evaluation to identify the possibility of associated lesions in the surrounding structures which then first need to be taken care of. Next step is the harvesting of the graft, namely from the gracilis or the semitendinosus muscle, which is then quadruplicated and equipped with polyester-braided sutures for further application. After acquiring the dimensions of the drilled tunnels, the surgeon will now have to make sure that the resulting length of the prepared graft along with its sutures is sufficient. After debriding the condylar notch from any remnants of ligament, the surgeon will manually drill two narrow guide tunnels into the femoral and the tibial condyles in an outside-in fashion using a specific device [6]. In the next step the surgeon will use these guide tunnels to insert the femoral and the tibial pin-guides respectively into the knee. These pin-guides are equipped with a flippable tip that is rotated 90° once placed intraarticular in order to drill the half-tunnels inside-out and thereby creating the characteristic sockets. The graft is then introduced into the knee, pulled into position with both endings placed inside both sockets and the attached sutures emerging from the exterior openings of either guide tunnel. After tensioning the graft, the sutures are fixated with buttons to the cortex [10].

3.2. Graft

3.2.1. Graft Selection

Surgeons usually select a quadrupled semitendinosus autograft, which typically provides sufficient length and strength for the ACL reconstruction. The required width of the harvested graft should not come under a value of 8.5 mm while the minimal length must measure at least 260 mm. If these values cannot be met by the semitendinosus alone, a gracilis autograft can be incorporated into the structure [8].

3.2.2. Graft Harvesting

The leg is positioned in 90° flexion and prepped either inside an arthroscopic leg holder or standard lateral post. The tourniquet is positioned up high right below the peritoneum to not later block the progression of the tendon stripper. A 3-cm incision is made on the anteromedial side of the tibia, exposing the sartorius muscle which is covering the gracilis and semitendinosus.

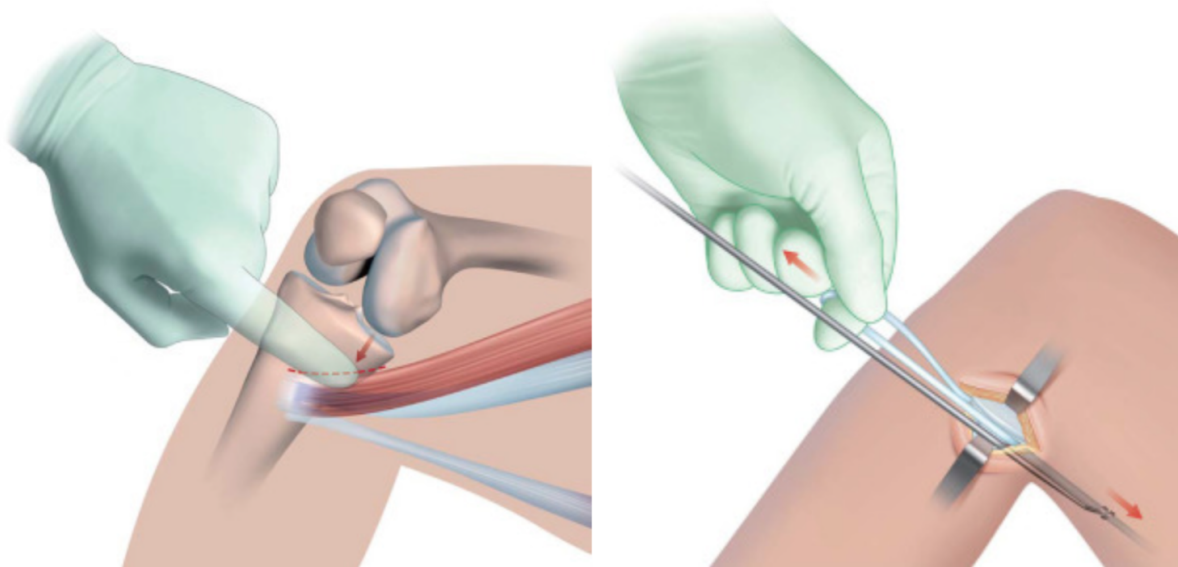


Figure 3: LEFT: Superior edge of sartorius. RIGHT: Release of tendon with stripper [11]

When palpating the superior edge of the sartorius (Figure 3: LEFT) and elevating it away from the bone, the hamstring tendons can be identified and caught using a hook. Traction on the tendon will reveal them and they can easily be sectioned using scissors [11]. While pulling on the loose end the tendon stripper is pushed towards the ischium to release the proximal end of the tendon (Figure 3: RIGHT).

3.2.3. Graft Preparation

For the graft link-suture technique the tendon is cleaned of any residual muscle tissue and both ends are then held by haemostats (Figure 4). If two tendons have to be used for the procedure the loose ends can be whipstitched together [12]. The graft is then passed through a tibial and a femoral tightrope (Figure 4: white suture loops at both ends) and wrapped around the two hooks of the graft-preparation station with an approximate length of 60 mm before tensioning. A locking high strength suture is placed through the centre of each strand, including the two loose ends in order to close the loop on the tibial side (Figure 4: tibial side is on the right side of the image).

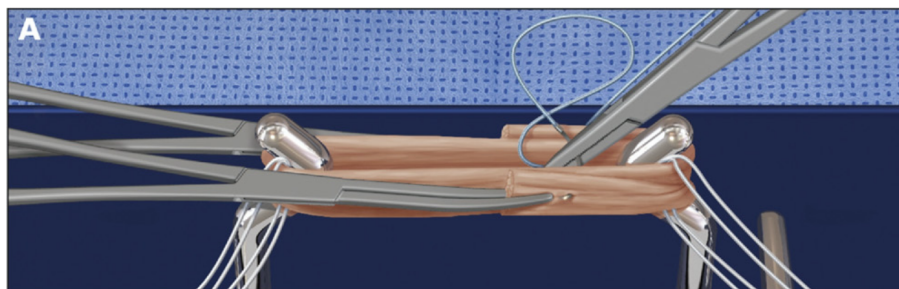


Figure 4: Graft loaded to graft-preparation station - tibial side is on the right side of the image [10]

After the loop has been conflated, the surgeon will now have to secure and condense the whole construct of strands. Therefore, the free ends of the suture are crossed with each other and loosely wrapped around all four strands of the graft (Figure 5).

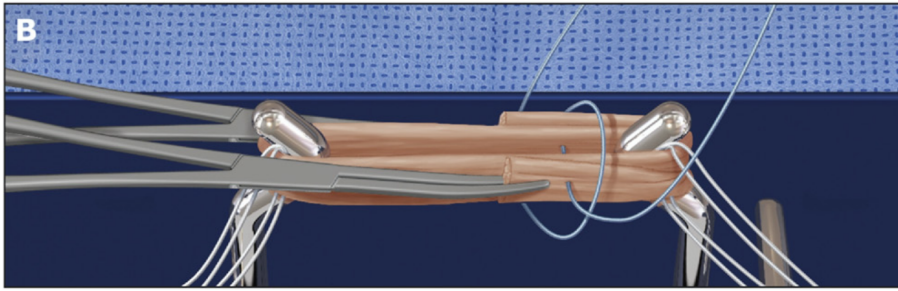


Figure 5: Closing the loop on the tibial (right) side [10]

With the suture being wired around all four strands the surgeon can now tie a wrapped cinch to securely close the loop (Figure 6).

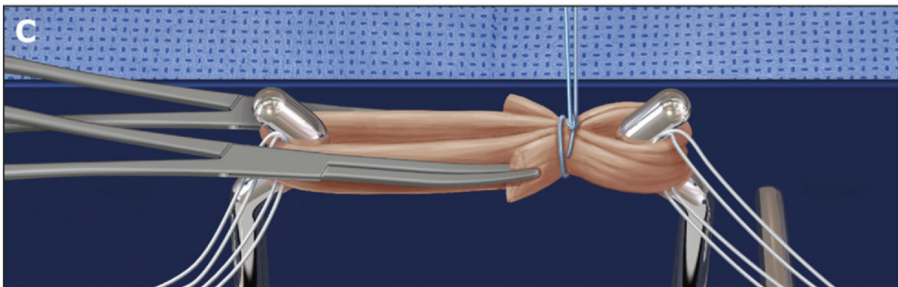


Figure 6: Closure of the loop with a wrapped cinch [10]

A second suture will be placed right next to the first suture using the same technique to wrap and secure all four strands of the graft. After the tibial side is brought to completion, two additional circumferential sutures incorporating all four strands are placed in the same manner at around 1-2 cm from the femoral end of the graft. It is important that the knots are all buried inside the graft bundle [12]. The final construct with all four sutures in place is now a four stranded graft with a femoral tightrope on the left side and a tibial tightrope on the right side (Figure 7).

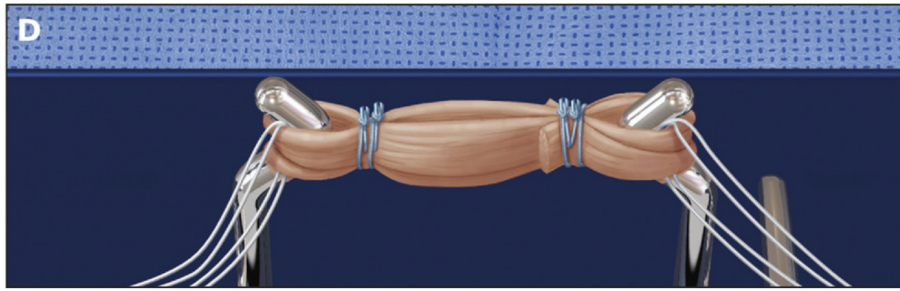


Figure 7: Final four stranded graft construct [10]

Eventually the final graft construct is clammed into a spring-loaded tensioning device applying about 40 N of tension to the graft (Figure 8). After the tensioning procedure the graft will have elongated to a total length of 70-75 mm, which allows for an intra-articular graft length of 35 mm with approximately 40 mm of graft length remaining for placement inside the two sockets, 20 mm inside the femoral socket and 20 mm inside the tibia socket respectively [8]. A graft diameter sizing block is used to ensure a maximal graft diameter of 5 mm for subsequent fitting inside the sockets [10].

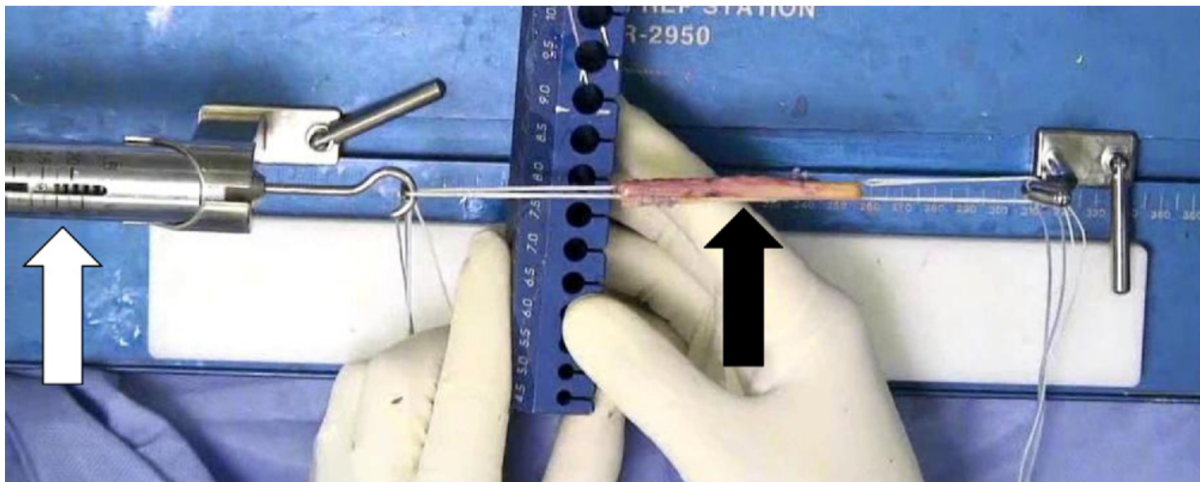


Figure 8: Graft (black arrow) inside the spring-loaded tensioning device (white arrow) [10]

3.3. Socket creation

3.3.1. Femoral Socket Drilling

Transtibial drilling (Figure 9) used to be the standard technique for creating the femoral sockets in ACL reconstruction surgery. The major disadvantage of this technique is the limitation of free positioning of the femoral socket as it is dictated by the tibia tunnel. Transtibial drilling therefore created a relatively vertical and nonanatomic alignment of the inserted ACL graft, consequently resulting in its diminished resistance to the kinematic forces of the knee movement and ultimately to early onset osteoarthritis [13].

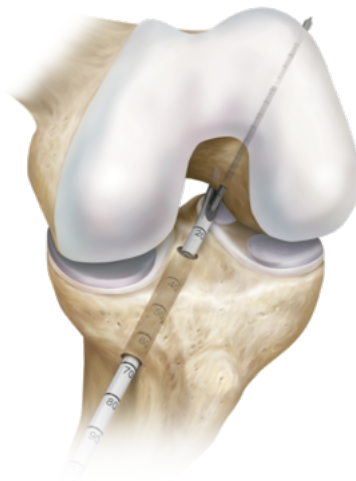


Figure 9: Transtibial drilling of femoral tunnel [14]

The alternative to transtibial drilling that allows free and precise anatomic positioning of the femoral tunnel is facilitated by independent drilling of both femoral and tibial tunnels. This can either be performed using the translateral retrograde drilling with a special retrograde drilling device [14] or using the anteromedial portal drilling with a low-profile reamer.

Translateral Retrograde Drilling with Retrograde Drilling Device

The translateral all-inside technique does not require an accessory medial port and is carried out with the knee flexed to 90° with no hyperflexion needed throughout the whole procedure. The arthroscope is inserted through a modified anterolateral portal, which is placed more medially and somewhat lower than the common traditional anterolateral portal. A curved marking and measuring device is then inserted through the lateral portal to directly measure the medial wall of the lateral femoral condyle and its anatomic footprint. After identifying the precise location of the native ACL, the surgeon uses the sharp tip of the device to mark the centre for the positioning of the femoral socket [13]. The surgeon then inserts the retrograde drilling device guide with the marking hook into the modified anterior-lateral portal and places its tip inside the marked anatomic femoral origin of the ACL (Figure 10).

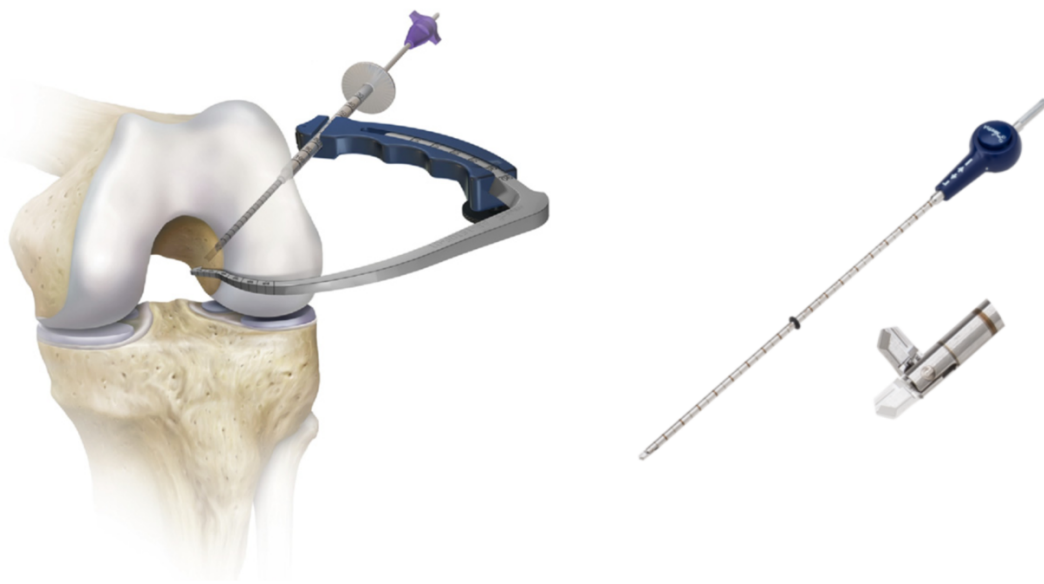

Figure 10: LEFT: 2nd generation retrograde drilling device [10]. RIGHT: deployable tip for retrograde drilling [14]

The guide pin sleeve is pushed via a stab incision through the skin and the iliotibial band all the way to the bone using a blunt trochar. The guide pin then drills a 3.5 mm narrow pilot hole in an outside-in manner into the lateral femoral condyle. Deploying the tip of the drill transforms the guide pin of the device into a retrograde drill (Figure 10: RIGHT). Continued forward drilling with a retrograde force will create the femoral socket (Figure 11). The preadjusted guide is set to optimize the interosseous distance with 32 mm depth resulting in a 25 mm socket with a 7 mm cortical bone bridge [10]. After reaching the required depth the pin is pushed back inside the knee, flipped back into the simple guide pin mode and the whole aperture is removed. The final distance is then also measured from the femoral graft end and is indicated on the graft. When the mark on the graft itself enters the femoral socket orifice during graft passage, the surgeon realizes that the femoral socket graft tensioning is complete. This is achieved on the graft's tibial side as well.

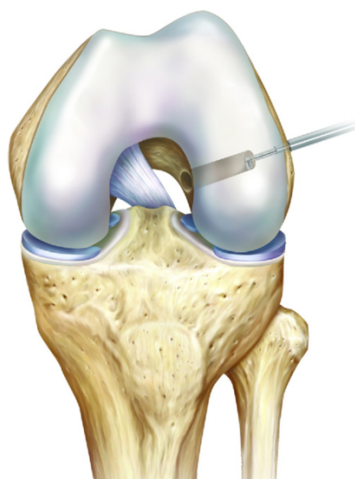


Figure 11: ACL femoral socket in the left knee [10]

Anteromedial Portal Drilling with Low-profile Reamer

Drilling of the femoral tunnel through an anteromedial portal in an inside-out manner offers a high degree of flexibility to allow for independent positioning of the femoral tunnel when compared with transtibial drilling [14]. While use of the anteromedial portal technique offers distinct advantages, there are also inherent risks associated with this technique. One risk is iatrogenic injury to the articular cartilage of the medial femoral condyle as the reamer passes adjacent to the condyle [15].

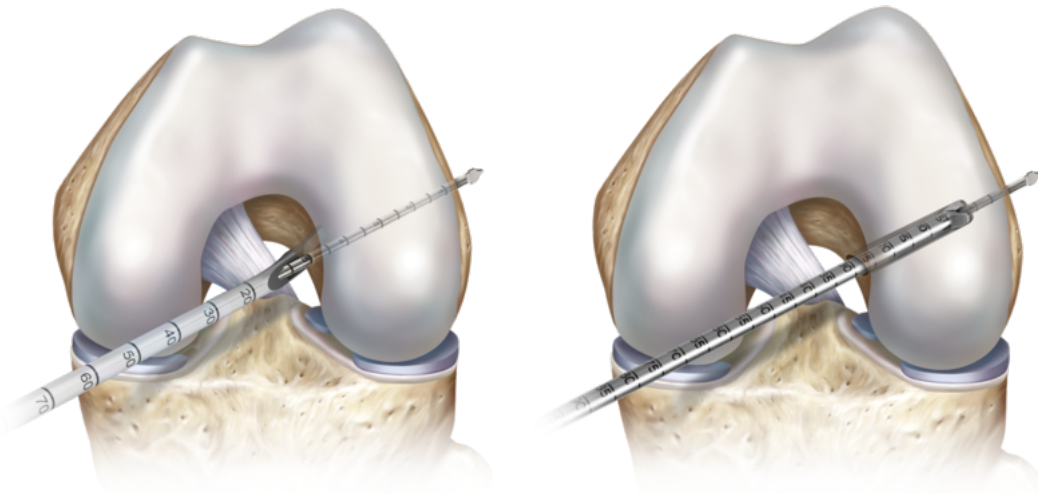


Figure 12: Anteromedial portal drilling of femoral socket. [14]

With the knee flexed in 90° the surgeon first has to mark the the exact starting location of the femoral guide pin and tunnel on the lateral femoral condyle. The acorn reamer is then inserted into the anteromedial portal and guided around the medial femoral condyle and pushed into the femoral notch. The guide pin is placed inside the hollow acorn reamer and its tip is precisely engaged into the previously marked notch. With the knee turned into hyperflexion, the guide pin drills itself all the way through the lateral condyle exiting on the lateral surface of the femur. With the guide pin in place,

the reamer is now used to drill the femoral socket to the desired depth. After the guide pin is extracted, the knee moves back to 90° flexion and the reamer is gently removed from the knee [16].

3.3.2. Tibial Socket Drilling

The tibial side of the ACL origin is cleared of remnant fibres before the tibial footprint can be precisely identified. Regarding the drilling manner of the tibial socket, there are two possible techniques prevalently described in the literature that have gained acceptance over others in the past decades. One being the retrograde drilling technique with a special retrograde drilling device and the other one being the tunnel drilling technique using a flexible reamer. Both techniques have the inside-out drilling mode in common.

Retrograde Inside-Out Drilling with Retrograde Drilling Device

The optimized socket drilling is described as being positioned right between the original tibial ACL centre and the anterior horn attachment of the lateral meniscus [8]. The retrograde drilling device's tibial marking hook is locked at a convenient angle of approximately 60° inside the guide ring. With the arthroscopic view through the anterolateral portal, the aperture is inserted through the anteromedial portal. As previously described with the femoral socket creation, the guide pin sleeve is then pushed via a stab incision through the skin to the bone using a blunt trochar. The tibial bone tunnel is then prepared in the same fashion as during retrograde inside-out preparation of the femoral socket (Figure 13).

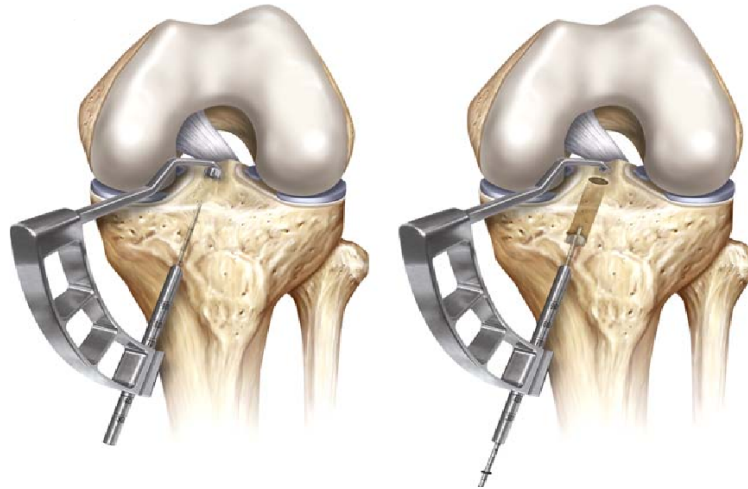


Figure 13: Retrograde inside-out tibial socket drilling. LEFT: Advancement of guide pin into tibial condyle. RIGHT: Retrograde inside-out drilling of socket. [17]

Antegrade Inside-Out Drilling with Flexible Reamer

This method creates the tibial socket through the standard anterolateral portal by using inside-out tunnel drilling with a flexible reamer. Firstly, the special 55° tibial drill guide aimer is inserted through the anterolateral portal, advanced into the knee and precisely placed at the original ACL tibial footprint. The surgeon will now introduce the guide pin through the anteromedial portal access, which is then followed by a 4.5 mm cannulated drill bit. Having created a tibial tunnel ranging from the anteromedial to the anterolateral portals, both the drill bit and the guide pin can now be removed again.

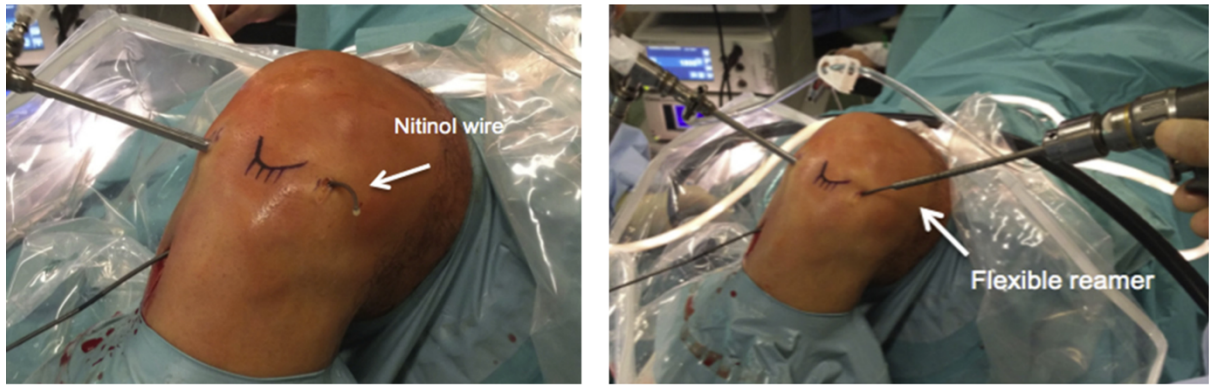


Figure 14: Tibial socket drilling. LEFT: Nitinol wire. RIGHT: Flexible reamer. [7]

A nitinol wire is then advanced from the anteromedial entry and pushed all the way through the tibial tunnel until exiting from the anterolateral portal (Figure 14: LEFT). By imposing on the nitinol wire (Figure 14: RIGHT), the flexible reamer is finally inserted through the anterolateral portal, drilling the tibial socket in an inside-out manner to the required depth (Figure 15).

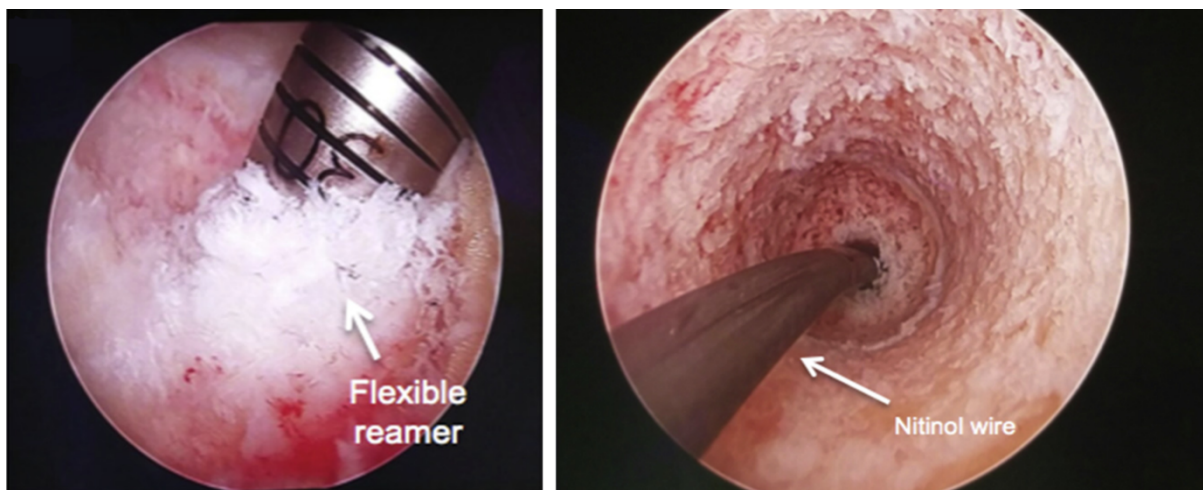


Figure 15: Arthroscopic view of tibial socket. LEFT: flexible reamer. RIGHT: Nitinol wire inside the tibial socket. [7]

3.4. Graft Passage and Fixation

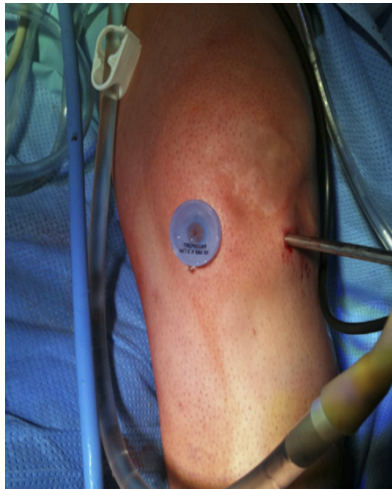

Figure 16: Flexible silicon cannula in anteromedial portal of left knee. [7]

The graft must pass through the anteromedial arthroscopic portal. In order to prevent any risk of soft-tissue interposition during this process, it is advisable to equip the portal with a flexible silicon cannula. Figure 16 displays the left knee with a flexible, blue silicon cannula placed inside the anteromedial portal. In the next step, the surgeon can then start introducing the graft construct with the help of the attached sutures via the silicon cannula into the knee.

First the femoral (Figure 17) and tibial graft passing sutures have to be retrieved. To avoid any soft tissue bridge that would obstruct graft movement, the femoral and tibial graft passing sutures must be extracted simultaneously via the anteromedial portal. While doing this the surgeon has to make sure that both passing sutures, which have been retrieved are cleared of any soft tissue bridges.

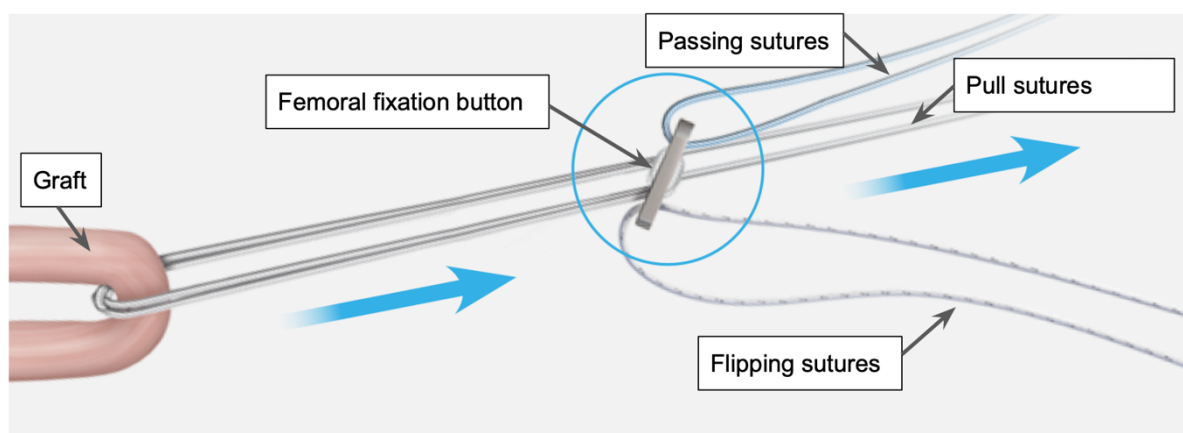


Figure 17: Overview of femoral sutures and graft [14]

The graft is then shuttled through the same portal into the knee using the femoral passing sutures, which also advances the femoral fixation button through the femoral tunnel (Figure 18: LEFT). The ACL femoral pull sutures, indicated with the dark endings in Figure 18 (LEFT), emerge superior to the graft from the femoral socket [10].

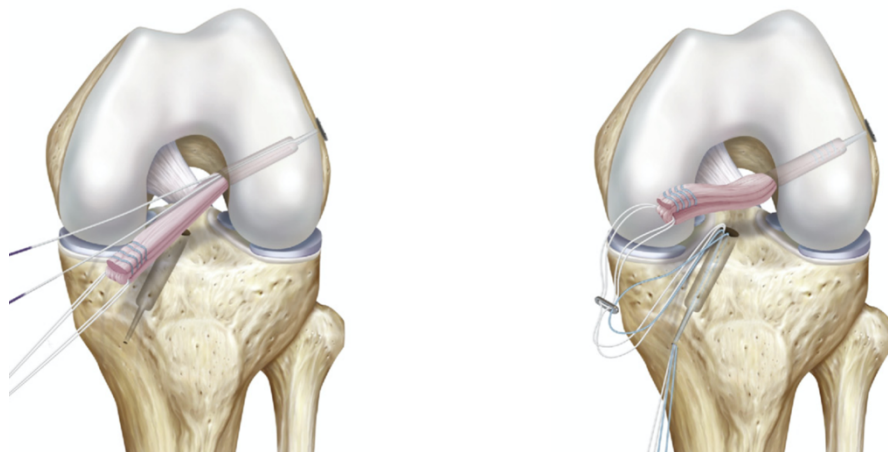


Figure 18: Advancement of graft and placement inside sockets. LEFT: Placement inside femoral socket. RIGHT: Placement inside tibial socket. [14]

These pull sutures are necessary to keep the tensioning strands under tension in order to prevent slack and bunching up in the tunnel until the graft is securely fitted inside the femoral socket. For this, the fixation button has to be pulled all the way through the femur exiting through the lateral surface of the femoral bone [14]. As soon as the button is flipped and tightly seated flat on the femoral cortex, rigorous pulling ensures a solid femoral fixation.

Once the femoral part of the graft is securely seated inside the socket, the tibial pull sutures and the tibial passing sutures are introduced into the tibial socket (Figure 18: RIGHT). Along with the tibial fixation button these sutures are shuttled through the

tibial tunnel and emerge from the proximal tibial metaphysis. With the cortical button being flipped analogously to the femoral process, the graft can be securely pulled into the socket (Figure 19: LEFT). The free ends of the pull suture are eventually tied over the tibial button at the end of this procedure. The knee is terminally moved through all range of possible movements and the tension on the graft is adequately readjusted if necessary. The illustration on the right side of Figure 19 shows the final outcome of the all-inside ACL reconstruction technique with the tibial pull suture tensioned and cut off [10].

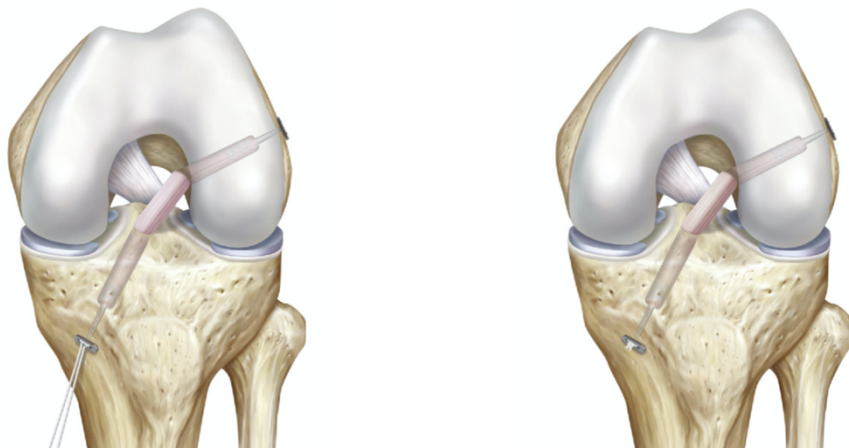


Figure 19: Graft fixation. LEFT: Graft securing and tensioning. RIGHT: Final result with tensioned graft and cut off pull suture. [8]

4. All-Inside Technique vs. Standard Technique

The fairly new all-inside technique includes unique features such as the bone-sparing closed-socket tunnels, dual suspension fixation and downscaled skin incisions. These features are destined to produce an overall improvement not only regarding patient's satisfaction, but also in terms of technical advantages, anatomical replication, cost reduction and overall clinical outcome. The following sections of this chapter are focusing on the comparison of the all-inside technique with the so-called standard ACL reconstruction techniques, which typically utilize bone patellar tendon bone (BPTB) and hamstring tendon grafts.

4.1. Free anatomical socket positioning

Transtibial drilling as seen in various standard ACL reconstruction lacks the ability of placing the tunnels intraarticularly in the correct anatomical position. This results in non-anatomic fixation points, placing the graft anterior to the femur and posterior to the tibia in a comparatively vertical orientation. Consequently, this produces a change of dynamic physical forces with a post-operative rotational laxity, as has been confirmed by clinical kinematic assessment. The biomechanical superiority of lateral femoral tunnel implantation over standard high and deep placements has been demonstrated by the research of Kondo et al. in 2011. The key point is not necessarily the fact that the anatomic positioning of the new ACL graft results in an improved clinical outcome. Rather the translateral access for the drilling procedure is highly advantageous by promoting precise placement of the femoral socket due to the clear

view of the lateral femoral condyle from the medial portal while operating from the lateral side.

4.2. Closed tunnel sockets versus open tunnel

Expansion movement and motion of the suspensory fixated graft are a major concern of ACL reconstruction as they could possibly cause tunnel widening and also impede the graft healing process resulting in a bad overall outcome of the intervention. There are two mechanisms, namely the “windshield wiper” and the “bungee cord phenomenon”, describing the motion of the graft within the tunnels and therefore likely to be responsible for this concern. While the most distal parts of the graft, specifically the tibial and femoral fixation ends remain rather stationary throughout all knee movements, studies have shown that especially the intra-articular portions of the graft display a high degree of motion and deformation. Therefore these parts of the graft consequently showed a decreased and prolonged healing process. Specifically, the physical property of a suspensory graft fixation was identified to cause a constant relative movement within the tunnels which consequently can lead to tunnel widening. Nevertheless, other studies have eliminated any relationship between tunnel widening and impairment of the clinical outcome [18]. In opposition to a full tunnel graft fixation, the socket technique requires a shorter graft distance being inside the bony tunnel and therefore could possibly offer a protective effect. Studies have confirmed this assumption and reported a bone preservation with diminished socket expansion [19]. Further, the closed socket application was shown to correlate with a diminished pain score in comparison with the standard full tunnel drilling [20].

4.3. Graft selection

While the standard techniques usually default to bone patellar tendon bone (BPTB) and hamstring tendon grafts, the all-inside method typically utilizes a quadrupled semitendinosus tendon autograft. Since the closed sockets of the all-inside technique naturally require a diminished graft length, a single hamstring harvest usually provides sufficient length [21]. A couple of biomechanical as well as clinical studies have shown that the usage of a single quadrupled semitendinosus tendon in the all-inside method has the ability to restore the native knee stability and thus has a comparable biomechanical strength of the natural ACL [21]. While the knee extension was slightly diminished with the quadrupled semitendinosus tendon autograft [22], both reconstruction techniques result in a comparable clinical outcome and none of it is significantly superior over the other [21].

4.4. Autograft harvest associated functional deficits

A few studies investigated possible functional deficits associated with different types of autografts harvesting methods. Since the all-inside technique requires a single hamstring tendon the essence of these investigations was whether this would also result in a diminished functional deficit, compared to the bone patellar tendon bone (BPTB) and hamstring tendon grafts of the standard techniques [21]. More than 90 % of these studies however reported no major difference in muscle strength between all types of techniques [23].

4.5. Morbidity of the harvest site

Short and long-term trials have shown that hamstring tendon autografts are more favourable than BPTB autografts in terms of anterior knee pain and donor site pain. The thickness of the patellar tendon harvest site for the BPTB autograft has been known to increase with time, but it may still present irregularities two years after harvesting on various imaging and histologic tests. Even so, MRI and ultrasound tests have shown some regeneration of the hamstring tendons which appears to be complete two years after they were harvested [21]. The regrown tendons also histologically present as normal hamstring tendon tissue [24].

4.6. Dual suspensory fixation

Unlike the screw fixation of the standard technique, the all-inside technique uses the dual suspension fixation which secures the semitendinosus graft inside both, the tibial and the femoral sockets. A few studies were conducted to investigate the performance of various types of fixation mechanisms, including intra-tunnel fixation with interference screws and extra-tunnel suspensory fixation with posts, staples and buttons [21]. The outcome of these meta-analysis revealed an inferior performance of the suspensory fixation although it has to be mentioned that none of these studies have actually utilized the all-inside technique for their experiments [25]. As further biomechanical and clinical outcome studies conclusively confirmed, there is no measurable inferiority of the suspensory fixation in combination with the all-inside technique [21].

4.7. Costs

A retrospective study was performed in 2011 to investigate the material costs of different ACL reconstruction techniques, the standard technique with the tibial tunnel being drilled in an outside to inside fashion, and the all-inside technique with both tunnels being drilled in the inside-to-outside manner. All of the material used from the first swab to the final bandage was reported and categorized into “reusable arthroscopy material“, “disposable arthroscopic material“ and “disposable surgical supplies“. The outcome of this study revealed the standard ACL reconstruction with an overall cost of 791.59 € to be less expensive than the all-inside technique with an overall expense factor of 931.06 €, thereby being 18 % more costly. The study also showed that the largest percentage of expenses is allocated to disposable arthroscopic material and implants, 81 % for the standard technique and 84 % for the all-inside technique [26].

4.8. Application in skeletally immature individuals

Due to iatrogenic damage to the femoral or tibial epiphyses, growth disruption can be a common issue when ACL repair surgery has to be conducted in a skeletally immature patient. Several physeal-sparing ACL reconstruction techniques in various combinations have been described over the past decades. The all-inside method however combines the advantages of anatomic reconstruction with sockets without causing physeal damage. A study of Nawabi et al. from 2014 quantified the zone of physeal injury in skeletally immature athletes following all-inside ACL reconstruction by the use of physeal-specific magnetic resonance imaging. The aim was to assess

physeal violation, growth arrest, graft survival, angular deformity, and leg length discrepancy. The cohort study had an average follow-up of 18.5 months patients, with one group of test subjects undergoing an all-epiphyseal ACL reconstruction (Group 1) while the other group had a partial transphyseal ACL reconstruction (Group 2), which only crossed the tibial physis but spared the femoral counterpart. While all patients of the latter group showed a tibial physeal breach, which by definition of the surgical intervention was to be expected, this was only the case in 66 % of the all-epiphyseal ACL reconstruction patients. Group 1 showed an average tibial physeal disturbance area of $57.8 \pm 52.2 \text{ mm}^2$ corresponding to 2.1 % of the total physeal area, while the measurements of Group 2 showed a mean area of $145.1 \pm 100.6 \text{ mm}^2$, equal to 5.4 % of the area. Further there had been no indications for growth arrest, postoperative angular deformities or any leg length discrepancies. Conclusively the short-term follow-up data suggest that the all-inside ACL reconstruction technique is a safe method to use for skeletally immature athletes [27].

In 2016 Cordasco et al. assessed the 2-year clinical outcomes of the all-inside ACL reconstruction, focusing on return to sport and the incidence of a second surgery. These case series were conducted on skeletally immature athletes with an average remaining growth of 3 to 6 years. They had been prospectively evaluated after receiving an all-epiphysial ACL reconstruction. The results of physical examinations, radiographs and postoperative MRI scans at months 6, 12, and 24 were taken into account to evaluate the movement quality. In both subjective and objective clinical outcomes, the all-inside ACL reconstruction technique presented excellent results without any indications of physeal arrest [28].

Conclusion

The All-Inside ACL reconstruction technique has proven to be an adequate alternative with a huge potential for the future of ACL surgery. While it is reproducible and allows the surgeon complete flexibility in the graft positioning for anatomic accuracy, it also shows satisfactory subjective and objective results. This technique demonstrates a low graft failure rate with clinically significant outcomes concerning re-established knee function, range of movement, stability and overall patient satisfaction. Several studies certify an overall low complication rate as well as good clinical short term to medium term outcome.

Long-term observations and additional comparative studies with bigger sample sizes are still necessary to investigate the proposed advantages and to allow more definite conclusions regarding the all-inside technique.

Acknowledgement

Thank you, Prof. dr. sc. Mislav Jelić, for mentoring me on my work. Further, I would like to show my appreciation to the whole Medical School of Zagreb, including all my professors and doctors, every single member of the staff and especially all the patients I have worked with, for supporting me to achieve the degree of Medical Doctor (M.D.). My deepest gratitude to all the Croatian people for always receiving me with open arms and for providing me a true home away from home.

Bibliography

- [1] Researchgate.net, 09 03 2021. [Online]. Available: https://www.researchgate.net/figure/Anterior-cruciate-ligament-ACL-and-posterior-cruciate-ligament-PCL-12_fig1_337962948.
- [2] Med-Library.com, 04 03 2021. [Online]. Available: <https://www.med-library.com/ligamentum-cruciatum-anterius-vorderes-kreuzband-anatomie-funktion/#>.
- [3] Netdoctor.de, 22 03 2021. [Online]. Available: <https://www.netdokter.de/krankheiten/baenderriss/kreuzbandriss/>.
- [4] Pautasso, Andrea, et al. , “All-inside Technique in ACL Reconstruction: Mid-Term Clinical Outcomes and Comparison with AM Technique (Hamstrings and BpTB Grafts),” *European Journal of Orthopaedic Surgery & Traumatology*, vol. 31, no. 3, p. pp. 465–472., 2020.
- [5] Potalivo et al., “History of the “all-inside” technique and its clinical application,” *J Orthop*, p. 3(02): 81–86, 2011.
- [6] Cerulli et al., “ACL Reconstruction with ‘the Original All-inside Technique,” *Knee Surgery, Sports Traumatology, Arthroscopy*, vol. 19, no. 5, p. pp. 829–831, 2011.
- [7] J. C. Noronha and J. P. Oliveira, “Inside-out Tibial Tunnel Drilling Technique for All-inside Anterior Cruciate Ligament Reconstruction,” *Arthroscopy Techniques*, vol. 7, no. 4, 2018.

- [8] M. Stuart and A. Blackman, "All-Inside Anterior Cruciate Ligament Reconstruction," *Journal of Knee Surgery*, vol. 27, no. 05, p. pp. 347–352, 2014.
- [9] J. Lubowitz, "All-inside ACL: retroconstruction controversies," *Sports Med Arthrosc Rev*, p. 18(01):20–26, 2010.
- [10] Lubowitz et al., "All-Inside Anterior Cruciate Ligament Graft-Link Technique: Second-Generation, No-Incision Anterior Cruciate Ligament Reconstruction," *Arthroscopy: The Journal of Arthroscopic & Related Surgery*, vol. 27, no. 5, p. pp. 717–72, 2011.
- [11] Lanternier et al., "Short Medial Approach Harvesting of Hamstring Tendons," *Orthopaedics & Traumatology: Surgery & Research*, vol. 102, no. 2, p. pp. 269–272, 2016.
- [12] P. E. Jones and D. J. Schuett, "All-Inside Anterior Cruciate Ligament Reconstruction as a Salvage for Small or Attenuated Hamstring Grafts," *Arthroscopy Techniques*, vol. 7, no. 5, 2018.
- [13] Wilson et al., "Anatomic All-Inside Anterior Cruciate Ligament Reconstruction Using the Translateral Technique," *Arthroscopy Techniques*, vol. 2, no. 2, 2013.
- [14] Arthrex.com, 31 03 2021. [Online]. Available: <https://www.arthrex.com/resources/product-and-technique-highlights/>.
- [15] Abdelkafy A., "Protection of the medial femoral condyle articular cartilage during drilling of the femoral tunnel through the accessory medial portal in anatomic anterior cruciate ligament reconstruction," *Arthrosc Tech.*, p. 1:e149–e154, 2012.

- [16] K. F. Bonner and A. Mannino, "An Alternative Technique to Avoid Injury to the Medial Femoral Condyle When Reaming the Femoral Tunnel During Anterior Cruciate Ligament Reconstruction," *Arthroscopy Techniques*, vol. 6, no. 1, 2017.
- [17] McAdams et al. , "Tibial Aperture Bone Disruption after Retrograde versus Antegrade Tibial Tunnel Drilling: a Cadaveric Study," *Knee Surgery, Sports Traumatology, Arthroscopy*, vol. 16, no. 9, p. pp. 818–822, 2008.
- [18] Majewski et al., "Tibial Tunnel Enlargement after Arthroscopic Anterior Cruciate Ligament Reconstruction.," *Sportverletzung · Sportschaden*, vol. 16, no. 1, p. pp. 22–25., 2002.
- [19] Osti et al., "Quantification of Tibial Bone Loss in Antegrade versus Retrograde Tunnel Placement for Anterior Cruciate Ligament Reconstruction," *International Orthopaedics*, vol. 39, no. 8, p. pp. 1611–1614, 2015.
- [20] Lubowitz et al., "Randomized Controlled Trial Comparing All-Inside ACL Reconstruction Technique Versus ACL Reconstruction with a Full Tibial Tunnel," *The Journal of Arthroscopic & Related Surgery* , 2013.
- [21] Connaughton et al., "All-inside ACL reconstruction: How does it compare to standard ACL reconstruction techniques?," *Journal of Orthopaedics*, vol. 14, no. 2, p. pp. 241–246, 2017.
- [22] K. e. a. Eriksson, "A comparison of quadruple semitendinosus and patellar tendon grafts in reconstruction of the anterior cruciate ligament," *The Journal of Bone and Joint Surgery. British Volume*, 83-B, no. 3, p. pp. 348–354, 2001.

- [23] Ardern et al., "Hamstring Strength Recovery After Hamstring Tendon Harvest for Anterior Cruciate Ligament Reconstruction: A Comparison Between Graft Types," *Arthroscopy: The Journal of Arthroscopic & Related Surgery*, vol. 26, no. 4,, p. pp. 462–469, 2010.
- [24] Kartus et al., "Donor-Site Morbidity and Anterior Knee Problems after Anterior Cruciate Ligament Reconstruction Using Autografts," *Arthroscopy: The Journal of Arthroscopic & Related Surgery*, vol. 17, no. 9, p. pp. 971–980, 2001.
- [25] Ilahi et al. , "Intratunnel Fixation Versus Extratunnel Fixation of Hamstring Anterior Cruciate Ligament Reconstruction –A Meta-Analysis," *Journal of Knee Surgery*, vol. 22, no. 02, p. pp. 120–129, 2009.
- [26] Cournapeau et al., "Material costs of anterior cruciate ligament reconstruction with hamstring tendons by two different techniques," *Orthopaedics & Traumatology: Surgery & Research*, vol. 99, no. 2, p. pp. 196–201, 2013.
- [27] Nawabi et al., "All-Inside, Physeal-Sparing Anterior Cruciate Ligament Reconstruction Does Not Significantly Compromise the Physis in Skeletally Immature Athletes," *The American Journal of Sports Medicine*, vol. 42, no. 12, p. pp. 2933–2940, 2014.
- [28] Cordasco et al., "All-Inside, All-Epiphyseal Anterior Cruciate Ligament Reconstruction in Skeletally Immature Athletes," *The American Journal of Sports Medicine*, vol. 45, no. 4, p. pp. 856–863, 2016.

[29] Benea et al., "Pain evaluation after all-inside anterior cruciate ligament reconstruction and short term functional results of a prospective randomized study," *The Knee*, vol. 24, no. 1, 2017.