

Management of pelvic organ prolapse

Budak, Bercem

Master's thesis / Diplomski rad

2021

Degree Grantor / Ustanova koja je dodijelila akademski / stručni stupanj: **University of Zagreb, School of Medicine / Sveučilište u Zagrebu, Medicinski fakultet**

Permanent link / Trajna poveznica: <https://um.nsk.hr/um:nbn:hr:105:125302>

Rights / Prava: [In copyright](#)/[Zaštićeno autorskim pravom.](#)

Download date / Datum preuzimanja: **2024-07-15**



Repository / Repozitorij:

[Dr Med - University of Zagreb School of Medicine Digital Repository](#)



UNIVERSITY OF ZAGREB
SCHOOL OF MEDICINE

Bercem Budak

Management of Pelvic Organ Prolapse

Graduate Thesis



Zagreb, 2022.

„This graduate thesis was made at The Department of Obstetrics and Gynaecology at the University Hospital Centre Zagreb, mentored by doc.dr.sc. Vladimir Banović and was submitted for evaluation in the academic year 2021/2022.”

Abbreviations

1. AR – Augmented repair
2. AVP – Anterior vaginal prolapse
3. ASC– Abdominal sacrocolpopexy
4. BMI – Body mass index
5. COPD – Chronic obstructive pulmonary disease
6. ERs – Estrogen receptors
7. FDA – Food and drug administration (of the United States)
8. HIR – Host immune response
9. ICIQ-VS - International Consultation on Incontinence Questionnaire - Vaginal symptoms
10. ICS – International continence society
11. IUGA – International Urogynecological Association
12. LSC - Laparoscopic sacrocolpopexy
13. NTR – Native tissue repair
14. OSUI – Occult stress urinary incontinence
15. POP – Pelvic organ prolapse
16. POP-Q – Pelvic organ prolapse quantification
17. POD – Pouch of Douglas
18. PFMT – Pelvic floor muscle training
19. PFM – Pelvic floor muscle
20. RCT – Randomized controlled trial
21. SSLS – Sacrospinous ligament suspension
22. SUI – Stress urinary incontinence
23. USL – Uterosacral ligament
24. USLS – Uterosacral ligament suspension

Abstract

Title: Management of pelvic organ prolapse

Author: Bercem Budak

Pelvic organ prolapse (POP) is the herniation or prolapse of pelvic organs through the vaginal walls. POP is a very common condition among women, especially of older age, and is one of the main indications for performing gynaecological surgery at present time. The etiology of POP is still not fully understood, but many predisposing risk factors have been associated with the weakening or damage of the endopelvic fascia, such as vaginal delivery, increasing age, obesity, and other conditions leading to increased intraabdominal pressure. Depending on the type and degree of prolapse, women may be symptomatic or completely asymptomatic. We differentiate between three types of POP concerning the involved vaginal segment, namely apical, anterior, and posterior POP. The diagnosis of POP is made after a thorough patient history and physical examination and can be quantified using the POP-Q system. POP is treated with either conservative or surgical management but there are still challenges in determining the best treatment option for POP. The most superior surgical management option for POP is yet to be determined even though successful attempts have been made to repair POP with both native tissue repair and mesh surgery. The issues related to the choice of surgical treatment include associated complications such as mesh erosion, occult incontinence, and recurrence rates, which have led to difficulties in determining the most superior choice for POP treatment.

Keywords: Pelvic organ prolapse, management of POP, native tissue repair, transvaginal mesh, complications of POP surgery

Sažetak

Titula: Liječenje defekata dna zdjelice

Autor: Bercem Budak

Prolaps zdjelčnih organa (POP) je hernija ili prolaps zdjelčnih organa kroz zidove rodnice. POP je vrlo često stanje kod žena, osobito starije životne dobi, te je danas jedna od glavnih indikacija za izvođenje ginekoloških operacija. Etiologija POP-a još uvijek nije u potpunosti shvaćena, ali mnogi predisponirajući čimbenici rizika povezani su sa slabljenjem ili oštećenjem endopelvične fascije, kao što su vaginalni porod, starenje, pretilost i druga stanja koja dovode do povećanog intraabdominalnog tlaka. Ovisno o vrsti i stupnju prolapsa, žene mogu biti simptomatske ili potpuno asimptomatske. Razlikujemo tri vrste POP-a s obzirom na zahvaćeni vaginalni segment, a to su apikalni, prednji i stražnji POP. Dijagnoza POP-a postavlja se nakon temeljite anamneze i fizičkog pregleda i može se kvantificirati pomoću POP-Q sustava. POP se liječi konzervativnim ili kirurškim liječenjem, ali još uvijek postoje izazovi u određivanju najbolje opcije liječenja POP-a. Najnaprednija opcija kirurškog upravljanja POP-om tek treba biti određena iako su učinjeni uspješni pokušaji da se POP popravi i popravkom nativnog tkiva i operacijom mreže. Problemi u vezi s izborom kirurškog liječenja uključuju povezane komplikacije kao što su erozija mreže, okultna inkontinencija i stopa recidiva, što je dovelo su do poteškoća u određivanju najvrjednijeg izbora za POP liječenje.

Ključne riječi: prolaps zdjelčnog organa, liječenje POP-a, popravak nativnog tkiva, transvaginalna mrežica, komplikacije POP operacije

Table of Contents

Abbreviations	2
Abstract	3
Sažetak	4
1. INTRODUCTION	7
2. PREVALENCE & EPIDEMIOLOGY	9
3. ETIOLOGY AND RISK FACTORS	10
3.1. <i>Modifiable risk factors</i>	10
3.1.1. Parity and mode of delivery	10
3.1.2. Obesity	11
3.2. <i>Unmodifiable risk factors</i>	11
3.2.1. Aging & Menopause.....	11
3.2.2. Genetics	12
3.2.3. Race.....	12
3.2.4. Comorbidity	12
4. PATHOPHYSIOLOGY AND CLASSIFICATION	13
4.1. <i>Apical Vaginal Prolapse</i>	13
4.2. <i>Anterior Vaginal Prolapse</i>	15
4.3. <i>Posterior Vaginal Prolapse</i>	16
5. CLINICAL PICTURE	17
5.1. <i>Vaginal symptoms</i>	17
5.2. <i>Urinary Symptoms</i>	18
5.3. <i>Bowel symptoms</i>	18
5.4. <i>Sexual dysfunction</i>	19
6. EVALUATION & DIAGNOSIS	20
7. APPROACH TO MANAGEMENT	22
8. CONSERVATIVE MANAGEMENT	23
8.1. <i>Mechanical Pessaries</i>	23
8.2. <i>Pelvic floor muscle training (PFMT)</i>	24
8.3. <i>Estrogen therapy</i>	25
8.4. <i>Expectant management</i>	25
9. RECONSTRUCTIVE SURGERY	26
9.1. <i>Native tissue repair</i>	26

9.1.1. Anterior Colporrhaphy	26
9.1.2. Posterior Colporrhaphy	27
9.1.3. McCall’s Culdoplasty	27
9.1.4. Uterosacral ligament suspension	27
9.1.5. Sacrospinous ligament suspension	28
9.1.6. Iliococcygeus Fascia suspension.....	28
9.1.7. Uterosacral Plication	28
9.1.8. Manchester procedure	29
9.1.9. Abdominal Sacrocolpopexy (ASC)	29
9.2. Augmented repair (AR).....	29
9.2.1. Synthetic Mesh	30
9.2.2. Transvaginal prolapse repairs using mesh	31
9.3. Laparoscopic surgery.....	32
9.3.1. Laparoscopic Sacrocolpopexy	32
10. OBLITERATIVE SURGERY.....	34
10.1. LeFort’s partial colpocleisis	34
10.2. Total colpocleisis (Vaginectomy).....	35
11. COMPLICATIONS OF POP MANAGEMENT	36
11.1. Intraoperative complications	36
11.2. Post-operative complications	36
11.2.1. Complications of Mesh augmentation	36
11.2.2. De novo stress urinary incontinence.....	37
11.2.3. Recurrence of POP	38
11.3. Uterine prolapse in pregnancy	39
12. CONCLUSION.....	41
Acknowledgments	43
References.....	44
Biography	51

1. INTRODUCTION

Pelvic organ prolapse (POP) is defined as “the downward descent of female pelvic organs, including the bladder, uterus or post-hysterectomy vaginal cuff, and the small or large bowel, resulting in protrusion of the vagina, uterus, or both” (1) into the vaginal canal or beyond the vaginal opening. POP is a very common condition among women, especially in those of advancing age and in women who have given birth vaginally (2). Women who have POP may be asymptomatic or symptomatic, depending on the severity of the prolapse and organs involved (3). Symptomatic women usually experience a severe decline in their quality of life (4). There are different types of POP, and they can be distinguished based on which organ is involved and the location of the prolapse relative to the vagina. We classify POP into apical vaginal prolapse, anterior vaginal wall prolapse, and posterior vaginal wall prolapse (2). The management options that exist include conservative treatment options, e.g., the use of mechanical pessaries and/or PFMT, as well as surgical intervention (5). Women with symptomatic POP or women who fail to relieve their symptoms with conservative measures are candidates for surgical intervention. The choice of appropriate surgical technique depends on many patient factors and each approach to surgery must be individualized according to the patient’s anatomic defect, patient desires and expectations, age, general health, and previous surgeries as well as a desire for future sexual function (6). There is currently no consensus on which surgical technique is the best for POP repair, and successful attempts have been made to correct POP with both native tissue repair and augmented tissue repair with a synthetic mesh (7). The problems that we are faced with when approaching surgical treatment include choosing whether native tissue repair or augmented tissue repair should be done and

acknowledging intraoperative as well as postoperative complications such as mesh erosion pain, occult incontinence, and post-operative sexual dysfunction (7). Patient factors should be considered when choosing a specific treatment option to successfully repair the anatomic defect, relieve POP symptoms and improve the patient's quality of life.

2. PREVALENCE & EPIDEMIOLOGY

POP is a very common condition among women, and it is estimated that around 50% of all women are bound to develop POP in their lifetime. However, this only refers to the anatomical defect of POP and does not correlate with the extent of experienced symptoms (2). Considering this, it is very challenging to estimate the exact prevalence and epidemiology of symptomatic POP.

Roughly, there is a 7% lifetime risk of undergoing surgical correction for POP by the age of 80. The peak incidence of such surgery occurs in patients aged 60-69 years (1). Women between the ages of 20 to 29 years account for 6% of symptomatic POP, those aged 50 to 59 years account for 31%, and close to 50% of women aged 80 years or older complain of symptoms related to the disorder (8).

Even though POP is one of the most frequent indications for gynecological surgery (1) the epidemiological studies of the disorder are rare (1,9).

3. ETIOLOGY AND RISK FACTORS

It is postulated that a combination of anatomical, physiological, genetic, lifestyle and reproductive factors interact throughout a woman's lifetime and contribute to pelvic floor dysfunction and the subsequent development of POP (10). The underlying factor that results in the herniation of organs is a weakened or damaged endopelvic fascia (2,4). There are several risk factors associated with the development of POP. These include modifiable predisposing factors such as parity, vaginal childbirth, obesity, and surgery, and non-modifiable factors including age, gender, and genetic factors (2). In addition, obesity, chronic cough, constipation, and occupations requiring heavy lifting, all raise the intra-abdominal pressure and can aggravate the condition (2).

3.1. Modifiable risk factors

3.1.1. Parity and mode of delivery

Vaginal childbirth – Women who have given birth vaginally represent one of the biggest risk groups for developing POP (1,11). During vaginal delivery, the presenting fetal parts that pass through the pelvis cause compression of the pelvic floor resulting in a risk of pelvic floor damage (12). The increased pressure from the fetal parts and maternal expulsive efforts can lead to injury of muscles, nerves, and connective tissue of the pelvic floor (13).

Non-vaginal delivery – POP rarely occurs in women with no history of vaginal delivery but it is possible in women who have undergone cesarian section and instrumental delivery, especially with forceps delivery (2).

Hysterectomy – Women who have undergone previous hysterectomy have an increased likelihood of POP development (2), however development of symptomatic prolapse usually occurs many years after the hysterectomy procedure (1).

3.1.2. Obesity

Chronic increase in intra-abdominal pressure is the most probable mechanism of POP development in obese women (14). Increased intra-abdominal pressure leads to weakened pelvic floor innervation and musculature (2,14). It has been reported that BMI >30 kg/m² increases the risk of POP by 40 % to 75 % (15).

3.2. Unmodifiable risk factors

3.2.1. Aging & Menopause

Many epidemiological studies have identified advancing age as a significant risk factor for POP (4,9,11,16). The hormonal changes during menopause involve a significant decline in endogenous estrogen levels and have been suggested to play a role in the development of POP (17).” Estrogen receptors (ERs) have been identified in the nuclei of connective tissue and smooth muscle cells of the bladder trigone, urethra, vaginal mucosa, levator ani muscle, stromal cells, and the uterosacral ligaments” (18). Additionally, estrogen has an effective role in the synthesis and metabolism of

interstitial collagen, elastin, and fibroblasts (16) which are all components of pelvic connective tissue (19). A decline in the total collagen content of the pelvic floor has been demonstrated with decreasing systemic estrogen levels (18).

3.2.2. Genetics

Genetic predisposition is another unmodifiable risk factor that has been shown to put certain women at risk for POP (2). Women with a family history of a POP show a 2.5-fold increased incidence of POP compared with the general population (20).

3.2.3. Race

African American women as compared to white women, are less likely to develop POP (18). Population-based studies that have been made have demonstrated elevated rates of POP in Caucasians over Hispanics and African American women (9).

3.2.4. Comorbidity

Connective tissue disorders such as Ehlers-Danlos syndrome or Marfan syndrome are considered risk factors for POP (2,21). Additionally, chronic respiratory diseases associated with forceful and repetitive coughing put women at risk for developing POP as well (22).

4. PATHOPHYSIOLOGY AND CLASSIFICATION

The pelvic floor encompasses several tissue types that act together to provide support and sustain the physiologic function of the rectum, vagina, urethra, and bladder. These tissues include the supporting muscles of the pelvic diaphragm (pubococcygeus, puborectalis, coccygeus, iliococcygeus), ligaments, and the endopelvic fascia. (11,15,22). The pelvic organs are embedded in the endopelvic fascia that is comprised of a connective tissue network of a loose matrix of collagen, elastin, and smooth muscle fibers (22). The anterior component of the endopelvic fascial is called the pubocervical fascia the posterior component is referred to as the rectovaginal fascia (22). Excessive stretching of the supporting pelvic fascia, ligaments, and muscles can cause weakening or damage of these tissues and can lead to POP (11). Damage can result from a variety of factors such as childbirth, connective tissue disorders, a chronic increase in intra-abdominal pressure, pelvic surgery, and neuropathies (22).

POP can be classified into the following three types: apical vaginal prolapse, anterior vaginal wall prolapse, and posterior vaginal wall prolapse (2,23).

4.1. Apical Vaginal Prolapse

Prolapse of the most superior aspect of the vagina is referred to as apical vaginal prolapse and includes herniation of the uterus (uterine prolapse) or the post-hysterectomy vaginal cuff (vaginal vault prolapse) (1). The uterus is supported by the cardinal ligaments, uterosacral ligament, and the round ligaments of the uterus, and act together to keep the uterus in its anatomical position (98). Damage or attenuation

of the uterosacral and cardinal ligaments that suspend the uterus in its anatomical site can lead to prolapse of the uterus (24). “The complete prolapse of the uterus through the hymen is referred to as “complete procidentia” and represents a total failure of all the vaginal supports” (99).

Vaginal vault prolapse is “a complete or partial inversion of the vaginal apex, usually found in women who have undergone a hysterectomy procedure” (18).

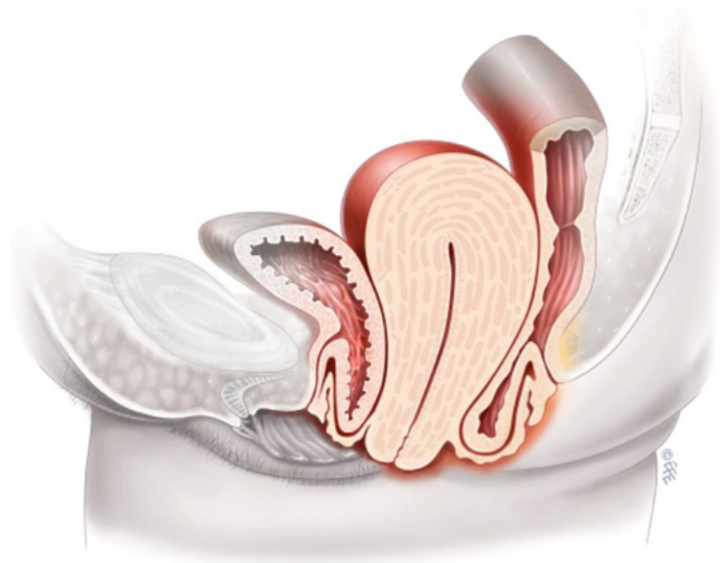


Fig. 1 Utero-vaginal prolapse

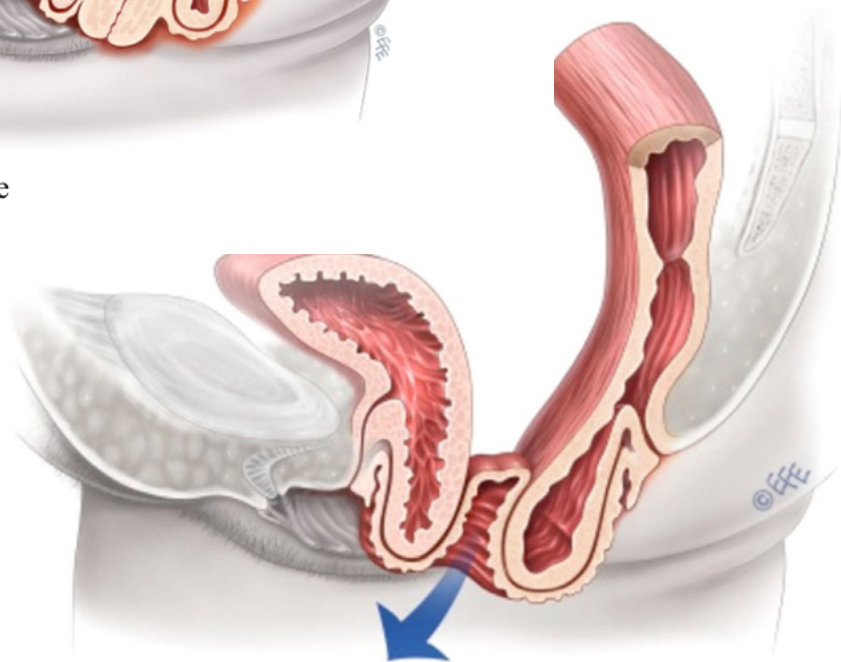


Fig. 5 Vaginal vault prolapse

Figures 1. and 5.
Represent uterovaginal and vaginal vault prolapse respectively according to Bernard T. Haylen.
© 2016 Wiley Periodicals, Inc., and The International Urogynecological Association (25)

4.2. Anterior Vaginal Prolapse

The most common vaginal segment to undergo prolapse is the anterior vaginal wall (1) and includes prolapse of the bladder (Cystocele) (26) and prolapse of the urethra (urethrocele) (100). The pathogenesis of anterior vaginal prolapse (AVP) is not fully understood but possible underlying causes include childbirth, congenital weakness, iatrogenic factors including hysterectomy, and increased intra-abdominal pressure caused by obesity or chronic pulmonary disease (27)

The part of the vaginal wall that supports the urethra can herniate and cause an anterior vaginal wall prolapse, referred to as a urethrocele (100). Cystocele and urethrocele may occur together and when both are present the term cystourethrocele is used (100).

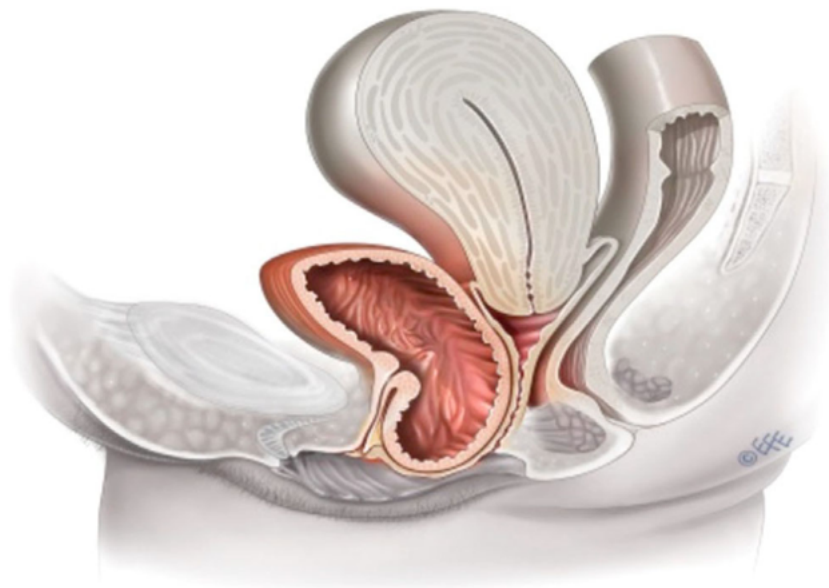

Figure 3. Anterior vaginal wall prolapse according to Bernard T. Haylen. © 2016 Wiley Periodicals, Inc., and The International Urogynecological Association(25)

4.3. Posterior Vaginal Prolapse

Posterior vaginal wall defects can cause POP that usually involves the rectum (rectocele) and/or small bowel (enterocele) (1,26). A weakening of the rectovaginal septum can lead to posterior vaginal wall defects and POP development (99)

A rectocele is the protrusion or herniation of the rectum into the lower posterior wall of the vagina. This occurs when the muscular layer of the rectum encounters the vaginal mucosa due to a defect in the rectovaginal fascia (28). During childbirth, the supporting tissues of the distal posterior vaginal wall, including the perineal muscles, can become stretched and damaged leading to weakened support and subsequent rectocele (98).

“Enteroceles occur when the peritoneum meets vaginal mucosa with no intervening fascia and may be classified into three groups depending on the exact location of the herniation relative to the vaginal compartments (or level of fascial tissue break): anterior, apical, and posterior enteroceles” (28). An enterocele is the only type of POP that can be called a true hernia because it encompasses a sac, neck, and contents (100). The sac represents a herniation of the peritoneum of the Pouch of Douglas (POD) (100).

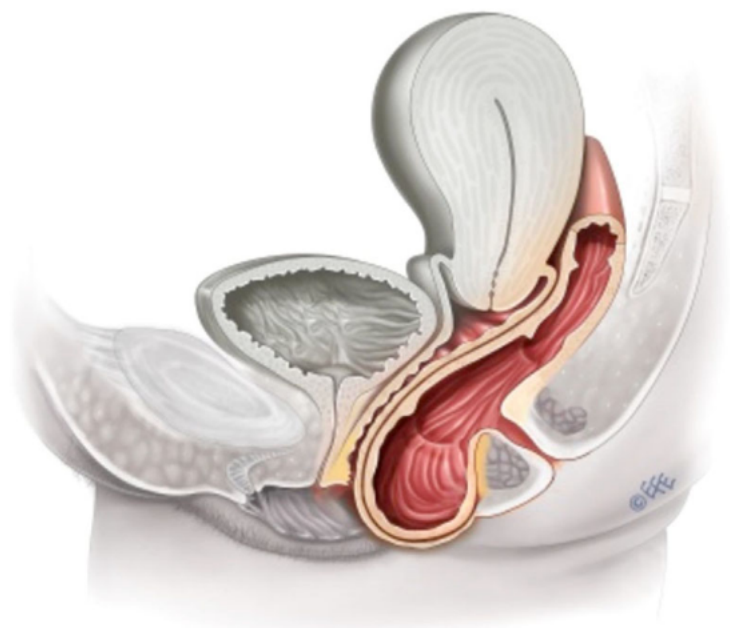


Figure 4. Posterior vaginal (compartment) wall prolapse according to Bernard T. Haylen. © 2016 Wiley Periodicals, Inc., and The International Urogynecological Association (25)

5. CLINICAL PICTURE

Many women with POP may be asymptomatic and the condition may go unnoticed until detection is made during a routine gynecological examination or when women attend for a routine cervical pap smear (3,17). In symptomatic women, however, POP usually causes a discomforting feeling of “something falling out” accompanied by a feeling of fullness, pressure, heaviness (29), and a feeling of a vaginal or perineal bulge (1,30). There may be accompanying organ malfunction that can lead to symptoms such as urinary, defecatory, and/or sexual dysfunction (3). In general, symptoms may worsen when gravitational force plays a role, e.g., after standing or exercising for a longer duration (25). It is not uncommon for women to present with several symptoms simultaneously (1). Symptomatic POP can lead to a severe decline in the quality of life, affecting women’s social, physical, and mental health (10,15). Sometimes, the degree of POP does not always correlate directly with the symptoms, therefore a pelvic exam is crucial to fully evaluate the extent of the prolapse (31).

5.1. Vaginal symptoms

The most frequent complaint of women suffering from POP is a vaginal bulge that can be seen or felt by direct palpation (25,30). Women also experience symptoms such as pelvic pressure, fullness, and increased heaviness or dragging sensation in the suprapubic area and/or pelvis (1,30). Sometimes patients may perform splinting or digitation, which is the manual reduction of prolapse by use of the fingers (25). This is done by applying pressure to the vagina or perineum (splinting) or to the vagina and

rectum (digitation) to successfully void or defecate (26,30). Additionally, low backache has also been a reported symptom of POP (25).

5.2. Urinary Symptoms

Loss of the anterior vaginal wall support can cause lower urinary tract complaints in women who suffer from anterior vaginal wall prolapse. The anterior vaginal wall acts to support the bladder and urethra and the loss of this support causes urethral hypermobility and cystocele formation, which in turn can contribute to the development of SUI (stress urinary incontinence) (1). POP extending beyond the level of the hymen may cause symptoms of obstructive voiding rather than SUI, such as urinary hesitancy, intermittent flow, weak or prolonged stream, feeling of incomplete emptying of the bladder, and a need to manually reduce the prolapse to start or complete urination (1).

5.3. Bowel symptoms

The symptoms of posterior vaginal prolapse can be very similar to the other types of prolapse because symptoms of discomfort, pressure and the sense of a vaginal bulge are nonspecific (99). However, if patients experience difficulties with defecation, e.g., feeling of incomplete emptying, straining to defecate, an urgency to defecate, digital evacuation to complete defecation, splinting/pushing on or around the vagina or perineum to start or complete defecation, a sensation of blockage or obstruction during defecation, lower posterior vaginal prolapse is likely (32)

5.4. Sexual dysfunction

„Potential prolapse-related sexual dysfunction symptoms include dyspareunia, obstructed intercourse, vaginal laxity, and complaints of loss or decreased libido“ (25).

6. EVALUATION & DIAGNOSIS

When evaluating patients for POP, it can be helpful to obtain relevant standardized questionnaires regarding bulge and pressure symptoms as well as splinting maneuvers. “International Consultation on Incontinence Questionnaire – Vaginal symptoms” (ICIQ-VS) is a useful tool for assessing bothersome symptoms, the frequency and severity of urinary, bowel, and sexual symptoms, and thus evaluates how much their quality of life is being affected (33). However, the definitive diagnosis of POP can only be made following a detailed patient history and pelvic examination (33,34). “Pelvic examination should be carried out at maximum Valsalva and with an empty bladder whilst the woman is both supine and standing to fully assess the extent of any prolapse and the compartments affected” (33).

Today, POP can be staged according to the Pelvic Organ Prolapse Quantification (POP-Q) system. POP-Q is a clearly defined objective system used to give a detailed description, quantification, and staging of female POP (3,26,35).

The hymen is used as the fixed point of reference with a plane being defined as zero (0), and “the six defined points should be measured in centimeters (cm) above or proximal to the hymen (negative number) or cm below or distal to the hymen (positive number)” (25).

The stages of POP are measured from stage 0 to 4 as follows (1,3):

Stage 0 – No prolapse demonstrated

Stage 1 – The most distal portion of the prolapse is > 1 cm above the level of the hymen

Stage 2 – the most distal portion of the prolapse is between ≤ 1 cm proximal and ≤ 1 cm distal to the level of the hymenal ring

Stage 3 – the most distal portion of the prolapse is between > 1 cm distal to the level of the hymenal ring but protrudes no further than 2 cm less than the total vaginal length

Stage 4 – Eversion of the total length of the vagina

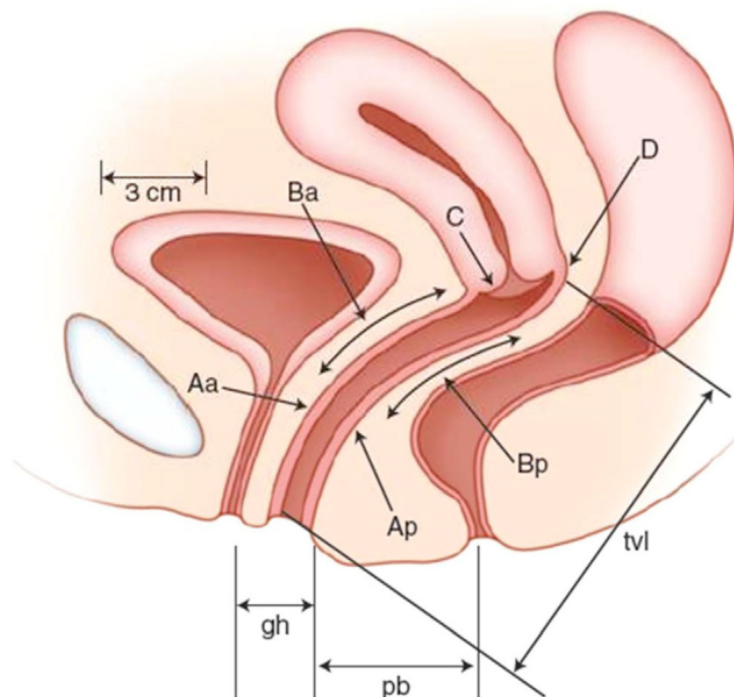


Figure 7. The six defined points (Aa, Ba, C, D, Ap, Bp) should be measured (cm) and recorded during POP-Q staging according to Bernard T. Haylen © 2016 Wiley Periodicals, Inc., and The International Urogynecological Association (25).

7. APPROACH TO MANAGEMENT

The management options for POP that exist today include conservative therapy and surgical therapy. The choice of therapeutic approach depends on several factors that can be very individual from patient to patient such extent and severity of the prolapse, whether the patient experiences bothersome symptoms, the woman's general health, and risks associated with certain types of surgical approaches (23).

Women with a mild degree of prolapse will generally be managed with conservative treatment options initially (23). Patients with mild POP who do not experience a long-term improvement of POP symptoms with conservative measures, or patients with very severe prolapse that express a desire for surgical intervention, are candidates for surgical treatment (3).

The surgical management of POP can be divided into reconstructive surgery and obliterative surgery (36). There is a wide variation of vaginal and abdominal surgical techniques at hand for the treatment of POP. The choice of operation depends on the anatomical defects, site, and severity of the prolapse; concomitant defective urinary, bowel, or sexual function; the general health of the woman; patient desire for future sexual activity; patient desires for NTR or graft-augmented repair; patient preference on the route of surgery; and surgeon preference and capability (6).

The goal of surgical intervention includes the "restoration of normal vaginal anatomy; the restoration or maintenance of normal bladder, bowel and/or sexual function" (6).

8. CONSERVATIVE MANAGEMENT

The conservative management options for POP include pessary placement and pelvic floor muscle training (PFMT). These options can be used simultaneously or individually (37). Generally, conservative treatments are appropriate for women who suffer from a mild degree of prolapse, those who wish to conceive more children, or those women unwilling to undergo surgery (23) or who are at high risk of complications post-operatively (38).

8.1. Mechanical Pessaries

Vaginal pessaries devices that are designed to support the vagina and hold the prolapsed organs in their anatomically correct position (39,40) There are many different pessaries in terms of material and size (41). Vaginal pessaries are indicated in women who (40):

- Choose to try a pessary
- Want symptomatic relief while waiting for or delaying surgery
- Are pregnant or wish to consider future pregnancies
- Are unfit or choose to not undergo surgery

Pessaries can provide immediate relief of POP symptoms and can be used either short or long-term (39,40). Nevertheless, "it is reported that up to 22 % of women with POP are unsuitable for vaginal pessaries due to the shape of the woman's vaginal canal or

severity of POP, the size of the genital hiatus, and the presence of scarring in the vaginal area from previous surgeries” (40).

Common reported side-effects of using pessaries include increased vaginal discharge and odor (38). If a pessary is forgotten or neglected, it can become embedded in the vaginal mucosa which leads to difficult and painful removal (3).

8.2. Pelvic floor muscle training (PFMT)

The goal of PFMT in the treatment of POP includes improvement of pelvic floor muscle strength and thereby improving the structural support to the pelvic organs, and improvement of pelvic organ support during increases in abdominal pressure (42). PFMT or “Kegel exercises” are done correctly by contracting, holding, and relaxing the pelvic floor muscles (PFMs). Patients should begin by contracting the PFMs, holding the contraction for 8-10 seconds, and finally relaxing the muscles fully (91). A basic regimen usually consists of 8 to 12 contractions, 3 times a day (91). At the beginning of treatment, patients may be unable to hold contractions for long and it is important to inform them that their muscle strength will improve with time and that they should not be discouraged (37). Even with clear instructions, many women are unsuccessful in performing PFMTs (43) and may therefore benefit from physical therapy with proper guidance.

A study (44) performed an RCT comparing a 16-week PFMT intervention plus lifestyle advice program (n=23) to a control group with lifestyle advice only (n=24), for women with symptomatic stage I or II POP (according to the POP-Q system). The intervention

group showed superior improvements in both prolapse symptoms and POP-Q staging as compared to the control group.

In another study (45), 37 women with POP stage II according to the POP-Q system, were randomized to a PFMT intervention group (n=21) and a control group with no active treatment (n=16) for 14 weeks. Results showed that the intervention group showed significantly higher anatomic and symptomatic improvements compared to the control group.

8.3. Estrogen therapy

It is thought that estrogen usage in POP can prevent or treat vaginal prolapse when used alone, or in combination with other conservative methods such as PFMT or pessaries (46). Estrogens are thought to improve the strength of the pelvic fascia, ligaments, and muscles by restoring the thickness, elasticity, and pH of the vagina (3).

8.4. Expectant management

Expectant management is appropriate for patients who suffer from mild prolapse and/or associated symptoms or in those who decline treatment or who are unfit for a surgical procedure when conservative treatment has failed (3). Weight loss, smoking cessation, and optimizing treatment of coexisting conditions e.g., COPD, and when possible, avoidance of precipitating factors such as heavy lifting and prolonged standing should be done (3).

9. RECONSTRUCTIVE SURGERY

Most reconstructive surgical procedures in POP management are performed using the patient's tissues, this is called a "native tissue repair" (NTR). By contrast, an "augmented repair" (AR) uses a biologic graft or synthetic mesh to reinforce the damaged tissues and creates support for the pelvic organs, and ultimately repairs POP (47).

9.1. Native tissue repair

9.1.1. Anterior Colporrhaphy

Anterior colporrhaphy is a surgical procedure that can be performed to repair a cystocele or cystourethrocele (27). Anterior colporrhaphy, together with posterior colporrhaphy, are two of the most frequently performed surgical procedures in the management POP, accounting for >90% of all prolapse surgeries (6). The classic NTR of anterior vaginal prolapse involves a midline vaginal incision, separation of the vaginal skin from the pubocervical fascia, and insertion of plicating sutures into the pubocervical fascia with the goal of reinforcing the area of fascial deficiency and supporting the bladder into normal anatomical position, thus relieving the prolapse (27). If a patient suffers from concomitant urinary incontinence, plicating sutures may be placed at the urethra and bladder neck to treat it (Kelly plication) (48).

9.1.2. Posterior Colporrhaphy

Posterior Colporrhaphy is a surgical procedure performed in the treatment of symptomatic rectocele (92). NTR involves the separation of vaginal skin from the rectovaginal fascia that lies between the vagina and rectum. The defective fascia is then plicated with buttress sutures to reduce the prolapse and support the rectum in its anatomical position. The vaginal skin is then closed with or without trimming the excess skin that is left (92).

9.1.3. McCall's Culdoplasty

McCall's culdoplasty is a surgical technique performed for the treatment of apical vaginal prolapse (49). Various surgical procedures involve fixation of the apex following a vaginal hysterectomy and these are McCall culdoplasty, sacrospinous ligament suspension (SSLS), uterosacral ligament suspension (USLS), and iliococcygeus suspension (50). McCall's culdoplasty involves plication of the USL (uterosacral ligament) to the posterior peritoneum in the midline, which suspends the vaginal cuff and at the same time, obliterates the posterior cul de sac and thus prevents any future enterocele formation (49–51).

9.1.4. Uterosacral ligament suspension

Uterosacral ligament suspension (USLS) or colpexy, is another approach to repairing apical vaginal prolapse. It is predominantly performed transvaginally but may also be done laparoscopically or abdominally (93). USLS technique involves suture placement through the uterosacral ligaments bilaterally at the level of the ischial spine (48). Once the suspensory sutures are placed, sutures are placed into the lateral

pubocervical and rectovaginal fascia (92). By doing this, the vaginal cuff is anchored and elevated to the uterosacral ligaments (52) and additionally corrects any enterocele if present (48).

9.1.5. Sacrospinous ligament suspension

Sacrospinous ligament suspension (SSLS) is another common transvaginal approach for apical prolapse management. It can either be done to correct vaginal vault prolapse after hysterectomy or can also be done simultaneously with hysterectomy (93). The SSLS technique involves the placement of sutures via the sacrospinous ligament (medial to the ischial spine attempting to avoid the pudendal neurovascular bundle), and ultimately fixates the vaginal muscular layer to the sacrospinous ligament (48).

9.1.6. Iliococcygeus Fascia suspension

Iliococcygeus fascia suspension is a surgical procedure that involves suturing the vaginal apex to the iliococcygeal fascia below the ischial spine. This is usually done in women who need to repair vaginal vault prolapse (53).

9.1.7. Uterosacral Plication

Women who suffer from uterine prolapse and who wish to preserve their uterus can choose a surgical procedure alternative called uterosacral plication. There are both transvaginal and abdominal surgical approaches to uterosacral plication (48).

9.1.8. Manchester procedure

The Manchester procedure is a uterine-sparing surgical technique that involves excision of the cervix and suturing the cervical stump to the cardinal ligaments (48,54,55).

9.1.9. Abdominal Sacrocolpopexy (ASC)

Abdominal sacrocolpopexy (ASC) is a surgical procedure involving suspension of the vaginal apex to the anterior longitudinal ligament of the sacrum (49,56).

9.2. Augmented repair (AR)

In general, augmenting grafts are indicated when the host tissue is inadequate for reinforcing the compromised tissue (57), and in certain circumstances in which the patient faces a high risk for surgical failure with NTR (47). However, there is still an ongoing discussion and uncertainty on whether augmented repair with mesh is superior to NTR (58).

Presently, there are four types of augmenting materials that can be utilized in reconstructive surgery for POP. These include autografts, allografts, xenografts, and synthetic meshes (57). The most frequently used autografts are the fascia lata and the rectus fascia which are harvested from and then implanted in the same patient (47,57). “Autografts eliminate the risk of a host immune response (HIR), but their employment is restricted because of morbidity at the harvest site, inconsistent quantity, and quality of the material (57), longer operative duration, and increased blood loss” (47,57).

“Allografts are harvested from the donated human cadaveric fascia and must be processed to reduce the HIR by a cleaning procedure that removes cells without damaging the connective tissue scaffold” (47,57). Utilization of allografts is advantageous in eliminating the morbidity associated with autograft harvest but poses a potential risk of donor-related viral infection (47,57). “Xenografts are harvested from non-human (bovine, porcine) sources and are made of acellular extracts of collagen and pose a potential risk of rejection and infection when transplanted” (47). Synthetic mesh, which will be discussed in the following sections, is available in both absorbable and non-absorbable forms. The advantages of utilizing synthetic mesh, as compared with other augmenting materials, are high availability (57) and elimination of risk of infectious disease transmission (47,57).

9.2.1. Synthetic Mesh

The main reasoning for mesh usage was to theoretically reduce the high prolapse recurrences seen after traditional NTR without mesh (with an average of 30% reoperation rate) (57,59). In the 1990s, prosthetic material was demonstrated to be successful in treating abdominal hernia and stress urinary incontinence (SUI), which in turn led surgeons to begin using synthetic meshes to augment prolapse repairs (57). Nonetheless, we now know that using synthetic mesh results in increased adverse events, such as mesh erosion, contracture, and infection (31,59). Consequently, the utilization of mesh for transvaginal POP repair has led to two public health notifications from the US Food and Drug Administration (FDA) regarding its safety (57,60). Even though mesh augmentation in POP repair comes at a cost of increased risks and complications, the decision on performing such procedures is based on whether the benefits outweigh these risks and must be individualized to each patient.

Synthetic meshes can be used in a variety of surgical procedures in POP management. Abdominal, vaginal, and laparoscopic surgery or a combination of these routes have been successful in repairing POP with the use of synthetic mesh (94).

9.2.2. Transvaginal prolapse repairs using mesh

Anterior compartment – Advantages of using mesh in the repair of anterior vaginal wall prolapse include increased efficacy and durability in treating the signs and symptoms of prolapse and lower recurrence and reoperation rates, compared to NTR (61). One systematic review and meta-analysis (27) that compared patient outcomes of mesh repair and colporrhaphy for the treatment of AVP have suggested that mesh repair was significantly superior to NTR colporrhaphy and that both techniques showed similar complication rates. However, the rate of post-operative POP-Q stage <II was significantly higher for mesh repair than for colporrhaphy (27).

Posterior compartment – Schimpf, and colleagues (62) reviewed outcomes of augmented posterior compartment prolapse, stating that “current evidence suggests that there is no difference in the anatomic and quality-of-life outcomes when using synthetic absorbable mesh, synthetic nonabsorbable mesh, or biologic graft compared with the traditional NTR for posterior vaginal prolapse”. Regarding posterior repair, the 2011 FDA update on the safety and effectiveness of transvaginally placed surgical mesh stated that there is no evidence of added benefit of AR using mesh compared with traditional surgery without mesh (63).

Apical compartment – As previously discussed, vaginal procedures to repair apical vaginal prolapse consists of SSLS or USLS, however, there is “consistent and reproducible evidence that abdominal sacrocolpopexy (ASC) using mesh has a higher

success rate than vaginal surgery along with less post-operative dyspareunia” (57). Additionally, ASC with synthetic mesh also seems to have lower erosion rates than synthetic transvaginally placed mesh (64).

9.3. Laparoscopic surgery

Laparoscopic surgery is a minimally invasive surgical procedure. This technique provides superior anatomical exposure (65) and surgical detail, and reduces blood loss and excessive tissue manipulation, making it an exceptional method for performing functional surgery (66). The indications for a laparoscopic approach in the management of POP are the same as for other types of surgical approaches (95). Nevertheless, surgeons must be properly trained and skilled in laparoscopic surgery to successfully repair the defect and obtain satisfactory treatment results.

9.3.1. Laparoscopic Sacrocolpopexy

Traditionally, Sacrocolpopexy is performed either by a vaginal or abdominal approach, however, it can also be performed laparoscopically (67). At present time, laparoscopic sacrocolpopexy (LSC) is considered the gold standard in the management of apical vaginal prolapse in women (68) and has become a very attractive technique due to certain advantages of LSC compared to conventional POP surgeries. These include lower recurrence and reoperation rates (68) and faster recovery (49,65). Furthermore, when comparing LSC and open ASC, laparoscopic benefits include less post-operative pain and blood loss (65), together with a more aesthetically pleasing cosmetic result (65). Nevertheless, the LSC technique is at a disadvantage compared

to conventional surgical techniques due to its extended operative duration as compared to other surgical procedures (67,68).

10. OBLITERATIVE SURGERY

Obliterative surgery, or colpocleisis, is a surgical technique performed via the vaginal route (38) and involves obliterating the vaginal canal, making future sexual intercourse no longer possible for patients (49). There are two approaches, namely, partial colpocleisis (LeFort's procedure) or total colpocleisis. A potential candidate for total colpocleisis or LeFort's partial colpocleisis is usually an elderly woman who is no longer sexually active (38) and has failed to relieve POP symptoms with conservative management. Considering that POP is very common in women of advancing age and that elderly women usually have other comorbidities and are less sexually active, obliterative surgery is considered the more appropriate surgical treatment option (69). Additionally, women who suffer from procidentia make good candidates for obliterative surgery (92,96), as well as women who have undergone previous hysterectomy (49).

10.1. LeFort's partial colpocleisis

LeFort's procedure or partial colpocleisis is suitable for women who still retain their uterus and wish to undergo obliterative surgery. The technique involves excising rectangular portions of the vaginal epithelium from the anterior and posterior walls (49) and using vertical sutures to close the area. The epithelial edges on the lateral segments (of the anterior and posterior vaginal walls) are then sewn together to create a channel or tunnel that will allow for any future vaginal discharge or drainage (49,70,71). Considering the uterus is retained in partial colpocleisis, evaluating any future uterine bleeding or cervical pathology becomes a challenge, and patients must

therefore undergo preoperative transvaginal US or endometrial biopsy, and Pap-smear to hinder a delayed diagnosis of potential malignancies (96).

10.2. Total colpocleisis (Vaginectomy)

Total colpocleisis is performed in patients with no uterus in situ or concomitantly with a hysterectomy, therefore this procedure is suitable for patients who suffer from vaginal vault prolapse and who are no longer interested in future sexual function (26,71,72). A total colpocleisis technique involves a vaginectomy, where the vaginal epithelium is completely removed, and no channels are created as compared with LeFort's procedure (26). It is possible to perform a simultaneous vaginal hysterectomy (26) if the patient so desires, with the rationale to prevent future endometrial or cervical cancer (70,71). Nevertheless, patients should be informed about possible complications, such as higher blood loss, that may arise when performing a concomitant hysterectomy (70).

The advantage of obliterative surgery over traditional vaginal reconstructive procedures lies in the fact that the prolapse recurrence is greatly diminished (26), surgical success rates are as high as >90% (72), it requires shorter operative time and is associated with lower risks (71).

11. COMPLICATIONS OF POP MANAGEMENT

11.1. Intraoperative complications

The NTR of anterior vaginal prolapse is usually not associated with many intraoperative complications. When faced with a complication, these usually include excessive blood loss, hematoma formation in the anterior vagina, and accidental puncturing of the bladder or urethra during dissection (97). McCall's culdoplasty and USLS both carry a risk of ureteral compromise during the procedure which is why it is crucial to perform cystoscopy after tying the culdoplasty or colpopexy sutures, to verify ureteral patency (48). When comparing transvaginal and laparoscopic USLS, reports have shown that both procedures have similar rates of complications but that the laparoscopic approach has a lower rate of ureteral injuries than the transvaginal approach (73,74). Intraoperative complications for LeFort's partial colpocleisis and complete colpocleisis are generally low, but like any surgery, it carries with it certain risks such as bleeding and injury to other organs. (72). Complications that may arise with SSLs include hemorrhage, gluteal pain, and bladder or rectal injury (48).

11.2. Post-operative complications

11.2.1. Complications of Mesh augmentation

"The US Food and Drug Administration (FDA) issued a black box warning on the use of mesh in October 2008, citing 'Most frequent complications included erosion through vaginal epithelium, infection, pain, urinary problems, and recurrence of prolapse and/or incontinence.' (31)."

Mesh erosion or exposure is the most common complication that follows transvaginally placed mesh (64,75). The mesh can either extrude into the vaginal tissue causing dyspareunia, pelvic pain, and/or inability to have sexual intercourse (75) or can also cause erosion into the bladder or rectum resulting in fistula formation (57).

Another complication that has been reported in women following mesh surgery is the development of vaginal mesh contraction, which is the shrinkage or reduction in the size of the mesh graft that ultimately leads to vaginal pain and dyspareunia. (64,76). Other complications that are associated with mesh augmentation in POP surgery include infection, urinary problems, and re-operation (57).

Considering the FDA warnings that have been issued regarding the utilization of synthetic mesh in POP surgery, physicians need to give patients informed consent regarding mesh surgery procedures (31).

11.2.2. De novo stress urinary incontinence

“The International Continence Society and International Urogynecological Association (ICS/IUGA) defines SUI as a patient complaint of involuntary leakage of urine during physical exertion” (77). It is not uncommon for women with POP to suffer from concomitant SUI (78,79), however, at very advanced stages of anterior or apical POP, SUI may go unnoticed due to the theoretical urethral kinking (occult SUI) (77,78). Surgical treatment of POP can therefore unmask the occult SUI, and this is referred to as de novo SUI (77). Women with occult SUI (OSUI) appear to have an elevated risk of developing de novo SUI and for this reason, it is important to perform preoperative prolapse reduction during urodynamic evaluation (78). OSUI can be treated with anti-incontinence procedures at the time of POP repair and thereby

reduce the incidence of de novo SUI (78). In patients without a history of occult SUI or any symptoms of urinary leakage before POP repair, postoperative de novo SUI development may be associated with the type of surgical procedure that is attempted. A systematic review performed by Baessler and Maher (80) showed that continent women that underwent transobturator vaginal mesh repairs had a higher incidence of de novo SUI, compared to women who were treated with the native tissue anterior colporrhaphy technique.

11.2.3. Recurrence of POP

“The true definition for success and failure of POP surgery is unknown” (81). Despite many reports on recurrence rates, there is limited knowledge of the natural history of POP recurrence (82). “The term ‘recurrence’ implies the ‘failure’ of previous surgery, which can be either subjective or objective” (81,83). Prolapse may recur in a previously treated compartment (direct) or a different compartment (indirect). These are some of the reasons why there is no agreed definition for recurrence POP and why the incidence of recurrence is so difficult to ascertain (83).

According to one study (82), the success rates of surgical intervention for POP management range between 50-80%, depending on the type of surgery and the involved vaginal compartment. The highest rate of prolapse recurrence occurs in anterior compartment prolapse, with a recurrence rate of 20-59% and a peak prevalence between 18-24 months after primary POP surgery (84). In general, patients have a 10.8% risk of undergoing re-operation for POP within the next 11 years, often due to indirect recurrence (a new prolapse at a different site) (85). A retrospective cohort study that involved 1,811 women who underwent primary surgery for POP from

January 1988 to June 2007, showed a re-operation incidence of 5.1 per 1,000 women-years, with a cumulative incidence of 5.6 % (86).

Risk factors for POP recurrence include “levator avulsion injury, levator ani muscle weakness, enlarged hiatus, advanced stage prolapse (\geq POP-Q stage 3) and family history of POP at the time of primary surgery” (83). Some studies have shown that younger age, high BMI, and advanced preoperative prolapse grade (III-IV) have been associated with an elevated risk of reoperation (86).

An RCT study (87) comparing long-term outcomes of transvaginal mesh and NTR in women with recurrent POP after 7 years, concluded that composite success rates (a combination of anatomical success, functional success, and absence of reoperation) were similar for mesh and native tissue.

According to a Cochrane review (7), when comparing any transvaginal permanent mesh with any native tissue vaginal repair, one of the advantages included reduced reoperation for prolapse. However, the use of NTR surgery showed a significantly lower rate of de novo SUI, mesh exposure, and an even lower reoperation rate for prolapse as compared with mesh. Therefore, the choice of mesh surgery should be individualized for patients who are aware of the risks of the procedure (7).

11.3. Uterine prolapse in pregnancy

The development of uterine prolapse in a pregnant woman is uncommon (88–90) with an estimated incidence rate of 1 per 10,000-15,000 deliveries (88,90). Complications that may arise due to uterine prolapse during pregnancy vary from minor cervical desiccation to more serious complications such as preterm labor, spontaneous

abortion, and maternal sepsis (88). Additionally, dystocia may occur as a complication of uterine prolapse, which can demand emergency intervention for delivery of the baby (89).

12. CONCLUSION

It is estimated that the elderly population will increase notably by the year 2050 and considering that advancing age is one of the biggest risk factors for POP, we can expect a significant number of new patients presenting to the healthcare system in the future (9). To potentially help decrease the health burden on at-risk POP patients and better the prevention and treatment strategies, it is important to identify modifiable risk factors at an early stage and enhance the understanding of the pathophysiology contributing to POP (9).

Management of POP is highly dependent on the type and severity of the prolapse. The choice of therapy depends not only on the anatomical defect and severity of symptoms, but also on the patient's expectations, wishes for future coitus and/or children, the complications that may arise with certain types of surgeries, and of course, the general health of the patient. The most optimal choice of surgical procedure is difficult to establish. The discussion regarding the choice of surgery must be a strategic one, including both pros and cons for performing the surgery at hand. When approaching any patient with POP, physicians are expected to offer a variety of surgical treatment options and given the differences in efficacy and complications of the various types of procedures (70), the aim is to make a well-informed decision that is consistent with the patient's values (58). Factors that must be considered when counseling a patient include durability, recovery time, immediate and delayed postoperative complications, risks of foreign body, and desire for future vaginal intercourse (70).

Currently, there is no consensus (7) on which is the most superior treatment option for the management of POP and the choice of surgery unfortunately remains a challenging one (31). Future perspectives on the management of POP include robot-assisted surgical procedures, and stem cell tissue engineering strategies that may provide new alternatives to NTR or mesh repair for POP (57).

Acknowledgments

I would like to express my gratitude to my mentor, doc.dr.sc Vladimir Banović for his support and guidance during the process of writing this thesis.

A special thank you to my dear family and friends who have supported and motivated me throughout my medical studies. Without you, none of it would have been possible.

I would like to express my deepest gratitude to my beloved and incredible mother, Helin Burkay. Thank you for being a true role model for me from a very early age, showing me how to be a good mother, friend, doctor, and human being.

References

1. Eric Jelovsek J, Maher C, Barber MD, Jelovsek JE, Barber MD. Pelvic organ prolapse [Internet]. Vol. 369, *www.thelancet.com*. 2007. Available from: www.thelancet.com
2. Weintraub AY, Gliner H, Marcus-Braun N. Narrative review of the epidemiology, diagnosis and pathophysiology of pelvic organ prolapse. *International Braz J Urol*. 2020 Jan 1;46(1):5–14.
3. Machin SE, Mukhopadhyay S. Pelvic organ prolapse: Review of the aetiology, presentation, diagnosis and management. Vol. 17, *Menopause International*. 2011. p. 132–6.
4. Vergeldt TFM, Weemhoff M, IntHout J, Kluivers KB. Risk factors for pelvic organ prolapse and its recurrence: a systematic review. Vol. 26, *International Urogynecology Journal*. Springer London; 2015. p. 1559–73.
5. Maher C. Surgical management of pelvic organ prolapse in women (Review) [Internet]. 2013. Available from: <http://www.thecochranelibrary.com>
6. Maher C, Feiner B, Baessler K, Schmid C. Surgical management of pelvic organ prolapse in women. Vol. 2013, *Cochrane Database of Systematic Reviews*. John Wiley and Sons Ltd; 2013.
7. Maher C, Feiner B, Baessler K, Christmann-Schmid C, Haya N, Marjoribanks J. Transvaginal mesh or grafts compared with native tissue repair for vaginal prolapse. Vol. 2016, *Cochrane Database of Systematic Reviews*. John Wiley and Sons Ltd; 2016.
8. Weintraub AY, Gliner H, Marcus-Braun N. Narrative review of the epidemiology, diagnosis and pathophysiology of pelvic organ prolapse. *International Braz J Urol*. 2020 Jan 1;46(1):5–14.
9. Chow D, Rodríguez L v. Epidemiology and prevalence of pelvic organ prolapse. Vol. 23, *Current Opinion in Urology*. 2013. p. 293–8.
10. Vergeldt TFM, Weemhoff M, IntHout J, Kluivers KB. Risk factors for pelvic organ prolapse and its recurrence: a systematic review. Vol. 26, *International Urogynecology Journal*. Springer London; 2015. p. 1559–73.
11. Word RA, Pathi S, Schaffer JI. Pathophysiology of Pelvic Organ Prolapse. Vol. 36, *Obstetrics and Gynecology Clinics of North America*. 2009. p. 521–39.
12. Tegerstedt G, Miedel A, Mæhle-Schmidt M, Nyrén O, Hammarström M. Obstetric risk factors for symptomatic prolapse: A population-based approach. *American Journal of Obstetrics and Gynecology*. 2006 Jan;194(1):75–81.
13. Schaffer JI, Wai CY, Boreham MK. Etiology of Pelvic Organ Prolapse.
14. Lee UJ, Kerkhof MH, van Leijssen SA, Heesakkers JP. Obesity and pelvic organ prolapse. Vol. 27, *Current Opinion in Urology*. Lippincott Williams and Wilkins; 2017. p. 428–34.
15. Jons KA, Moalli PA. Pathophysiology of pelvic organ prolapse. *Female Pelvic Medicine and Reconstructive Surgery*. 2010;16(2):79–87.

16. Brito LGO, Pereira GMV, Moalli P, Shynlova O, Manonai J, Weintraub AY, et al. Age and/or postmenopausal status as risk factors for pelvic organ prolapse development: systematic review with meta-analysis. Vol. 33, *International Urogynecology Journal*. Springer Science and Business Media Deutschland GmbH; 2022. p. 15–29.
17. Reddy RA, Cortessis V, Dancz C, Klutke J, Stanczyk FZ. Role of sex steroid hormones in pelvic organ prolapse. Vol. 27, *Menopause (New York, N.Y.)*. NLM (Medline); 2020. p. 941–51.
18. Tinelli A, Malvasi A, Rahimi S, Negro R, Vergara D, Martignago R, et al. Age-related pelvic floor modifications and prolapse risk factors in postmenopausal women. Vol. 17, *Menopause*. 2010. p. 204–12.
19. Liu X, Zhao Y, Pawlyk B, Damaser M, Li T. Failure of elastic fiber homeostasis leads to pelvic floor disorders. *American Journal of Pathology*. 2006;168(2):519–28.
20. Lince SL, van Kempen LC, Vierhout ME, Kluivers KB. A systematic review of clinical studies on hereditary factors in pelvic organ prolapse. Vol. 23, *International Urogynecology Journal*. Springer London; 2012. p. 1327–36.
21. Carley ME, Schaffer J. Urinary incontinence and pelvic organ prolapse in women with Marfan or Ehlers-Danlos syndrome. *American Journal of Obstetrics and Gynecology*. 2000;182(5):1021–3.
22. Gill EJ, Hurt WG. PATHOPHYSIOLOGY OF PELVIC ORGAN PROLAPSE.
23. Maher C, Feiner B, Baessler K, Schmid C. Surgical management of pelvic organ prolapse in women. Vol. 2013, *Cochrane Database of Systematic Reviews*. John Wiley and Sons Ltd; 2013.
24. Doshani A, Teo REC, Mayne CJ, Tincello DG. Uterine prolapse. Vol. 335, *British Medical Journal*. 2007. p. 818–23.
25. Haylen BT, Maher CF, Barber MD, Camargo S, Dandolu V, Digesu A, et al. An International Urogynecological Association (IUGA) / International Continence Society (ICS) Joint Report on the Terminology for Female Pelvic Organ Prolapse (POP). Vol. 35, *Neurourology and Urodynamics*. John Wiley and Sons Inc.; 2016. p. 137–68.
26. Good MM, Solomon ER. Pelvic Floor Disorders. Vol. 46, *Obstetrics and Gynecology Clinics of North America*. W.B. Saunders; 2019. p. 527–40.
27. Sun Y, Tang C, Luo D, Yang L, Shen H. The treatment of anterior vaginal wall prolapsed by repair with mesh versus colporrhaphy. Vol. 48, *International Urology and Nephrology*. Springer Netherlands; 2016. p. 155–67.
28. Kim S, Pollock GR, Twiss CO, Funk JT. Surgery for Posterior Compartment Vaginal Prolapse: Graft Augmented Repair. Vol. 46, *Urologic Clinics of North America*. W.B. Saunders; 2019. p. 87–95.
29. *Clinical Obstetrics and Gynaecology, 3e* by Brian A. Magowan MB CHB FRCOG DIPFETMED, Philip Owen MB BCh MD FRCOG, Andrew Thomson BSc MB ChB MRCOG MD (z-lib.org).
30. Haylen BT, de Ridder D, Freeman RM, Swift SE, Berghmans B, Lee J, et al. An International Urogynecological Association (IUGA)/International Continence Society (ICS)

- joint report on the terminology for female pelvic floor dysfunction. *International Urogynecology Journal*. 2010;21(1):5–26.
31. Lee U, Raz S. Emerging concepts for pelvic organ prolapse surgery: What is cure? *Current Urology Reports*. 2011 Feb;12(1):62–7.
 32. Sultan AH, Monga A, Lee J, Emmanuel A, Norton C, Santoro G, et al. An International Urogynecological Association (IUGA)/International Continence Society (ICS) joint report on the terminology for female anorectal dysfunction. *Neurourology and Urodynamics*. 2017 Jan 1;36(1):10–34.
 33. Thiagamorthy G, Cardozo L, Srikrishna S, Toozs-Hobson P, Robinson D. Management of prolapse in older women. Vol. 20, *Post Reproductive Health*. SAGE Publications Ltd; 2014. p. 30–5.
 34. Iglesia CB, Smithling KR. Pelvic Organ Prolapse [Internet]. Vol. 96. 2017. Available from: www.aafp.org/afp
 35. Madhu C, Swift S, Moloney-Geany S, Drake MJ. How to use the Pelvic Organ Prolapse Quantification (POP-Q) system? *Neurourology and Urodynamics*. 2018 Aug 1;37:S39–43.
 36. Brubaker L, Maher C, Jacquetin B, Rajamaheswari N, von Theobald P, Norton P. Surgery for pelvic organ prolapse. *Female Pelvic Medicine and Reconstructive Surgery*. 2010;16(1):9–19.
 37. Culligan PJ. Nonsurgical management of pelvic organ prolapse. Vol. 119, *Obstetrics and Gynecology*. 2012. p. 852–60.
 38. Chung SH, Kim W bin. Various Approaches and Treatments for Pelvic Organ Prolapse in Women. *Journal of Menopausal Medicine*. 2018;24(3):155.
 39. Atnip SD. Pessary Use and Management for Pelvic Organ Prolapse. Vol. 36, *Obstetrics and Gynecology Clinics of North America*. 2009. p. 541–63.
 40. Rantell A. Vaginal Pessaries for Pelvic Organ Prolapse and Their Impact on Sexual Function. Vol. 7, *Sexual Medicine Reviews*. Elsevier B.V.; 2019. p. 597–603.
 41. Bugge C, Adams EJ, Gopinath D, Stewart F, Dembinsky M, Sobiesuo P, et al. Pessaries (mechanical devices) for managing pelvic organ prolapse in women. Vol. 2020, *Cochrane Database of Systematic Reviews*. John Wiley and Sons Ltd; 2020.
 42. Stark HS. Conservative prevention and management of pelvic organ prolapse in women (Review) [Internet]. 2011. Available from: <http://www.thecochranelibrary.com>
 43. Mateus-Vasconcelos ECL, Ribeiro AM, Antônio FI, Brito LG de O, Ferreira CHJ. Physiotherapy methods to facilitate pelvic floor muscle contraction: A systematic review. Vol. 34, *Physiotherapy Theory and Practice*. Taylor and Francis Ltd; 2018. p. 420–32.
 44. Hagen S, Stark D, Glazener C, Sinclair L, Ramsay I. A randomized controlled trial of pelvic floor muscle training for stages I and II pelvic organ prolapse. *International Urogynecology Journal*. 2009;20(1):45–51.
 45. Stüpp L, Magalhães Resende AP, Oliveira E, Castro RA, Castello Girão MJB, Ferreira Sartori MG. Pelvic floor muscle training for treatment of pelvic organ prolapse: An

- assessor-blinded randomized controlled trial. *International Urogynecology Journal*. 2011;22(10):1233–9.
46. Weber MA, Kleijn MH, Langendam M, Limpens J, Heineman MJ, Roovers JP. Local oestrogen for pelvic floor disorders: A systematic review. Vol. 10, PLoS ONE. Public Library of Science; 2015.
 47. Kalkan U, Yoldemir T, Ozyurek ES, Daniilidis A. Native tissue repair versus mesh repair in pelvic organ prolapse surgery. Vol. 20, *Climacteric*. Taylor and Francis Ltd; 2017. p. 510–7.
 48. Houman J, Weinberger JM, Eilber KS. Native Tissue Repairs for Pelvic Organ Prolapse. Vol. 18, *Current Urology Reports*. Current Medicine Group LLC 1; 2017.
 49. Alas AN, Anger JT. Management of apical pelvic organ prolapse. Vol. 16, *Current Urology Reports*. Current Medicine Group LLC 1; 2015. p. 1–7.
 50. Barber E, Kleiner I, Tairy D, Bar J, Ginath S. The effectiveness of McCall culdoplasty following vaginal hysterectomy in advanced stages of uterine prolapse. Available from: <https://doi.org/10.1007/s00192-021-04890-z>
 51. Alas A, Chandrasekaran N, Devakumar H, Martin L, Hurtado E, Davila GW. Advanced uterovaginal prolapse: is vaginal hysterectomy with McCall culdoplasty as effective as in lesser degrees of prolapse? *International Urogynecology Journal*. 2018 Jan 1;29(1):139–44.
 52. Shull BL, Bachofen C, Coates KW, Kuehl TJ. A transvaginal approach to repair of apical and other associated sites of pelvic organ prolapse with uterosacral ligaments. In: *American Journal of Obstetrics and Gynecology*. Mosby Inc.; 2000. p. 1365–74.
 53. Meeks GR, Washburne JF, McGehee RP, Wisner WL. Repair of vaginal vault prolapse by suspension of the vagina to iliococcygeus (prespinous) fascia. *American Journal of Obstetrics and Gynecology*. 1994;171(6):1444–54.
 54. Park YJ, Kong MK, Lee J, Kim EH, Bai SW. Manchester operation: An effective treatment for uterine prolapse caused by true cervical elongation. *Yonsei Medical Journal*. 2019;60(11):1074–80.
 55. Dharmasena D, Spence-Jones C, Khasriya R, Yoong W. Manchester repair ('Fothergill's operation') revisited. *The Obstetrician & Gynaecologist*. 2021 Apr;23(2):148–53.
 56. Nygaard IE, McCreery R, Brubaker L, Connolly AM, Cundiff G, Weber AM, et al. Abdominal sacrocolpopexy: A comprehensive review. Vol. 104, *Obstetrics and Gynecology*. 2004. p. 805–23.
 57. Dällenbach P. To mesh or not to mesh: A review of pelvic organ reconstructive surgery. Vol. 7, *International Journal of Women's Health*. Dove Medical Press Ltd; 2015. p. 331–43.
 58. Geynisman-Tan J, Kenton K. Surgical Updates in the Treatment of Pelvic Organ Prolapse. *Rambam Maimonides Medical Journal*. 2017 Apr 28;8(2):e0017.
 59. Mancuso E, Downey C, Doxford-Hook E, Bryant MG, Culmer P. The use of polymeric meshes for pelvic organ prolapse: Current concepts, challenges, and future perspectives.

- Vol. 108, *Journal of Biomedical Materials Research - Part B Applied Biomaterials*. John Wiley and Sons Inc.; 2020. p. 771–89.
60. Chughtai B, Mao J, Buck J, Kaplan S, Sedrakyan A. Use and risks of surgical mesh for pelvic organ prolapse surgery in women in New York state: Population based cohort study. *BMJ (Online)*. 2015 Jun 2;350.
 61. Kontogiannis S, Goulimi E, Giannitsas K. Reasons for and Against Use of Non-absorbable, Synthetic Mesh During Pelvic Organ Prolapse Repair, According to the Prolapsed Compartment. Vol. 33, *Advances in Therapy*. Springer Healthcare; 2017. p. 2139–49.
 62. Schimpf MO, Abed H, Sanses T, White AB, Lowenstein L, Ward RM, et al. Graft and mesh use in transvaginal prolapse repair. Vol. 128, *Obstetrics and Gynecology*. Lippincott Williams and Wilkins; 2016. p. 81–91.
 63. *Urogynecologic Surgical Mesh: Update on the Safety and Effectiveness of Transvaginal Placement for Pelvic Organ Prolapse*. 2011.
 64. Ellington DR, Richter HE. Indications, Contraindications, and Complications of Mesh in Surgical Treatment of Pelvic Organ Prolapse [Internet]. Available from: www.clinicalobgyn.com
 65. Burgess KL, Elliott DS. Robotic/laparoscopic prolapse repair and the role of hysteropexy. A urology perspective. Vol. 39, *Urologic Clinics of North America*. 2012. p. 349–60.
 66. van Geluwe B, Wolthuis A, D’Hoore A. Laparoscopy for pelvic floor disorders. Vol. 28, *Best Practice and Research: Clinical Gastroenterology*. Bailliere Tindall Ltd; 2014. p. 69–80.
 67. Zwain O, Aoun J, Eisenstein D. Minimally invasive surgery in pelvic floor repair. Vol. 29, *Current Opinion in Obstetrics and Gynecology*. Lippincott Williams and Wilkins; 2017. p. 276–81.
 68. Campagna G, Vacca L, Panico G, Vizzielli G, Caramazza D, Zaccoletti R, et al. Laparoscopic High Uterosacral Ligament Suspension vs. Laparoscopic Sacral Colpopexy for Pelvic Organ Prolapse: A Case-Control Study. *Frontiers in Medicine*. 2022 Mar 4;9.
 69. van der Ploeg JM, van der Steen A, Oude Rengerink K, van der Vaart CH, Roovers JP. Prolapse surgery with or without stress incontinence surgery for pelvic organ prolapse: A systematic review and meta-analysis of randomised trials. Vol. 121, *BJOG: An International Journal of Obstetrics and Gynaecology*. Blackwell Publishing Ltd; 2014. p. 537–47.
 70. Abbasy S, Kenton K. Obliterative Procedures for Pelvic Organ Prolapse [Internet]. Available from: www.clinicalobgyn.com
 71. Wheeler TL, Gerten KA, Garris JB. Obliterative Vaginal Surgery for Pelvic Organ Prolapse. Vol. 36, *Obstetrics and Gynecology Clinics of North America*. 2009. p. 637–58.
 72. Buchsbaum GM, Lee G. Number 3 OBSTETRICAL AND GYNECOLOGICAL SURVEY [Internet]. Vol. 72. 2017. Available from: www.obgynsurvey.com
 73. Barbier HM, Smith MZ, Eto CU, Welgoss JA, von Pechmann W, Horbach N, et al. Ureteral Compromise in Laparoscopic Versus Vaginal Uterosacral Ligament Suspension: A

- Retrospective Cohort. *Female Pelvic Medicine and Reconstructive Surgery*. 2015 Nov 1;21(6):363–8.
74. Turner LC, Lavelle ES, Shepherd JP. Comparison of complications and prolapse recurrence between laparoscopic and vaginal uterosacral ligament suspension for the treatment of vaginal prolapse. *International Urogynecology Journal*. 2016 May 1;27(5):797–803.
 75. Siddiqui NY, Edenfield AL. Clinical challenges in the management of vaginal prolapse. Vol. 6, *International Journal of Women's Health*. Dove Medical Press Ltd; 2014. p. 83–94.
 76. Chermansky CJ, Winters JC. Complications of vaginal mesh surgery. Vol. 22, *Current Opinion in Urology*. 2012. p. 287–91.
 77. Alas AN, Chinthakanan O, Espaillet L, Plowright L, Davila GW, Aguilar VC. De novo stress urinary incontinence after pelvic organ prolapse surgery in women without occult incontinence. *International Urogynecology Journal*. 2017 Apr 1;28(4):583–90.
 78. Tran H, Chung DE. Incidence and Management of De Novo Lower Urinary Tract Symptoms After Pelvic Organ Prolapse Repair. Vol. 18, *Current Urology Reports*. Current Medicine Group LLC 1; 2017.
 79. Anderson KM, Davis K, Flynn BJ. Urinary Incontinence and Pelvic Organ Prolapse. Vol. 99, *Medical Clinics of North America*. W.B. Saunders; 2015. p. 405–16.
 80. Baessler K, Maher C. Pelvic organ prolapse surgery and bladder function. Vol. 24, *International Urogynecology Journal and Pelvic Floor Dysfunction*. 2013. p. 1843–52.
 81. Toozs-Hobson P, Freeman R, Barber M, Maher C, Haylen B, Athanasiou S, et al. An international urogynecological association (IUGA)/international continence society (ICS) joint report on the terminology for reporting outcomes of surgical procedures for pelvic organ prolapse. Vol. 31, *Neurourology and Urodynamics*. 2012. p. 415–21.
 82. Roos EJ, Schuit E. Timing of recurrence after surgery in pelvic organ prolapse. *International Urogynecology Journal*. 2021 Aug 1;32(8):2169–76.
 83. Ismail S, Duckett J, Rizk D, Sorinola O, Kammerer-Doak D, Contreras-Ortiz O, et al. Recurrent pelvic organ prolapse: International Urogynecological Association Research and Development Committee opinion. Vol. 27, *International Urogynecology Journal*. Springer London; 2016. p. 1619–32.
 84. Dietz HP, Hankins KJ, Wong V. The natural history of cystocele recurrence. *International Urogynecology Journal and Pelvic Floor Dysfunction*. 2014;25(8):1053–7.
 85. Price N, Slack A, Jwarah E, Jackson S. The incidence of reoperation for surgically treated pelvic organ prolapse: An 11-year experience. *Menopause International*. 2008;14(4):145–8.
 86. Dällenbach P, Nancoz CJ, Eperon I, Dubuisson JB, Boulvain M. Incidence and risk factors for reoperation of surgically treated pelvic organ prolapse. *International Urogynecology Journal*. 2012;23(1):35–41.
 87. Milani AL, Damoiseaux A, Int'Hout J, Kluivers KB, Withagen MIJ. Long-term outcome of vaginal mesh or native tissue in recurrent prolapse: a randomized controlled trial. *International Urogynecology Journal*. 2018 Jun 1;29(6):847–58.

88. Guariglia L, Carducci B, Botta A, Ferrazzani S, Caruso A. Uterine prolapse in pregnancy. *Gynecologic and Obstetric Investigation*. 2005 Nov;60(4):192–4.
89. Tsikouras P, Dafopoulos A, Vrachnis N, Iliodromiti Z, Bouchlariotou S, Pinidis P, et al. Uterine prolapse in pregnancy: Risk factors, complications and management. Vol. 27, *Journal of Maternal-Fetal and Neonatal Medicine*. 2014. p. 297–302.
90. Meydanli MM, Üstün Y, Yalcin OT. Pelvic organ prolapse complicating third trimester pregnancy: A case report. *Gynecologic and Obstetric Investigation*. 2006 Apr;61(3):133–4.
91. Brubaker, L. Patient education: Pelvic floor muscle exercises (Beyond the basics). In: UpToDate, Post TW editor: UpToDate [Internet]. Barbieri, RL: UpToDate; 2021 [cited 2022 May 9] Available from: <http://www.uptodate.com>
92. De Barro AT, Spirtos NM, Hilton P, Monaghan JM. Bonney’s gynaecological surgery. In: Hilton P, editors. *Operations for pelvic organ prolapse*. Hoboken, NJ: John Wiley & Sons Ltd. Inc; 2018. p 161 – 191.
93. Walters MD, Karram MM. Urogynecology and Reconstructive Pelvic Surgery. In: Karram MM, Ridgeway BM, Walters MD, editors. *Surgical treatment of vaginal apex prolapse*. Philadelphia, PA: Elsevier Inc; 2015. p 360 – 382.
94. Walters MD, Karram MM. Urogynecology and Reconstructive Pelvic Surgery. In: Paraiso MFR, Chen CCG, editors. *The use of biologic tissue and synthetic mesh in urogynecology and reconstructive pelvic surgery*. Philadelphia, PA: Elsevier Inc; 2015. p 326 – 341
95. Walters MD, Karram MM. Urogynecology and Reconstructive Pelvic Surgery. In: Tarr ME, Paraiso MFR, editors. *Laparoscopic and robotic surgery for pelvic organ prolapse and stress urinary incontinence*. Philadelphia, PA: Elsevier Inc; 2015. p 295 – 317
96. Walters MD, Karram MM. Urogynecology and Reconstructive Pelvic Surgery. In: Evans J, Silva WA, Karram MM, editors. *Obliterative procedures for pelvic organ prolapse*. Philadelphia, PA: Elsevier Inc; 2015. p 400 – 410.
97. Walters MD, Karram MM. Urogynecology and Reconstructive Pelvic Surgery. In: Walters MD, Barber MD, editors. *Surgical treatment of anterior vaginal wall prolapse*. Philadelphia, PA: Elsevier Inc; 2015. p 326 – 341.
98. Oats J, Abraham S. Fundamentals of Obstetrics and Gynaecology. In: Oats J, Abraham S, editors. *Uterovaginal Displacements, damage, and prolapse*. Philadelphia, PA: Elsevier Limited. Inc; 2017. p 318 - 324.
99. Hacker NF, Gambone JC, Hobel CJ. Hacker & Moore’s Essential of Obstetrics & Gynecology. In: Rosenman, AE, editors. *Pelvic floor disorders*. Philadelphia, PA: Elsevier Inc; 2015. p 291- 303.
100. Magowan BA, Owen P, Thomson A. Clinical Obstetrics & Gynaecology. In: Magowan BA, Owen P, Thomson A, editors. *Genital Prolapse*. Philadelphia, PA: Saunders Ltd; 2014. p 587-621

Biography

Bercem was born in Varna, Bulgaria in the year 1991 and was raised in Stockholm, Sweden. She was introduced to the medical field at a very young age thanks to her parents, Helin and Serdar, who are both medical doctors. After graduating from high school at Kungsholmens Gymnasium, she decided to travel and work for a few years before finally attending medical school in Zagreb.