

# Treatment of diabetic retinopathy

---

**Haccart, Pierre Paul Francis Marie**

**Master's thesis / Diplomski rad**

**2021**

*Degree Grantor / Ustanova koja je dodijelila akademski / stručni stupanj:* **University of Zagreb, School of Medicine / Sveučilište u Zagrebu, Medicinski fakultet**

*Permanent link / Trajna poveznica:* <https://um.nsk.hr/um:nbn:hr:105:533100>

*Rights / Prava:* [In copyright / Zaštićeno autorskim pravom.](#)

*Download date / Datum preuzimanja:* **2024-07-27**



*Repository / Repozitorij:*

[Dr Med - University of Zagreb School of Medicine  
Digital Repository](#)



**UNIVERSITY OF ZAGREB  
SCHOOL OF MEDICINE**

**Pierre Haccart**

# **Treatment of diabetic retinopathy**

**Graduate thesis**



**Zagreb, 2022.**

This graduate thesis was produced at the Department of Ophthalmology and Optometry, Faculty of Medicine, University of Zagreb mentored by Prof. Dr. Sc. Nenad Vukojević and was submitted for evaluation the academic year 2021/2022.

## List of abbreviations

**AHFVP** : Anterior Hyaloidal Fibrovascular Proliferation

**ALA** : Alpha-Lipoic Acid

**b-FGF** : basic Fibroblast Growth factor

**CSME** : Clinically Significant Macular Edema

**DBP** : Diastolic Blood Pressure

**DM** : Diabetes Mellitus

**DME** : Diabetic Macular Edema

**DR** : Diabetic Retinopathy

**ETDRS** : Early Treatment Diabetic Retinopathy Study

**FA** : Fluorescein Angiography

**NAVILAS** : Navigated Laser System

**NPDR** : Non Proliferative Diabetic Retinopathy

**NSAIDS** : Non-Steroidal Anti-Inflammatory Drugs

**NVD** : Neovascularization of disc

**OCT** : Optical Coherence Tomography

**PASCAL** : Pattern Laser Scanning

**PDGF** : Platelet derived-growth Factor

**PDR** : Proliferative Diabetic Retinopathy

**PRP** : Panretinal Photocoagulation

**RPE** : Retinal Pigment Epithelium

**SBP** : Systolic Blood Pressure

**SDM** : Subthreshold Diode Micropulse laser

**SRT** : Selective Retinal Therapy

**TNF-alpha** : Tumor Necrosis Factor - alpha

**VEGF** : Vascular Endothelial Growth Factor

**VISC** : Vitreous Infusion Suction Cutter

**VTDR** : Vision Threatening Diabetic Retinopathy

# List of content

## Summary

## Sažetak

1. Introduction .....	1
2. Epidemiology of Diabetic Retinopathy .....	2
3. Risk factors and prevention.....	3
4. Pathophysiology .....	4
5. Diagnosis and clinical manifestations .....	5
5.1. Symptoms.....	5
5.2. Clinical manifestations.....	5
5.3. Classification of Diabetic Retinopathy .....	9
5.4. Imagery in Diabetic Retinopathy .....	11
6. Treatment of Diabetic Retinopathy .....	14
6.1. Pharmacological therapy.....	15
6.1.1. Anti-VEGF .....	15
6.1.2. Anti-inflammatory treatment.....	16
6.1.3. Potential Neuroprotective drugs .....	17
6.2. Laser Treatment .....	19
6.2.1. Conventional laser treatment.....	19
6.2.2. Newest laser treatment .....	21
6.3. Surgical Treatment : Vitrectomy .....	22
6.4. Anti-VEGF and laser treatment in clinical practice .....	24
7. Conclusion .....	26
8. Acknowledgements .....	27
9. References .....	28
10. Biography.....	35

## Summary

### Treatment of diabetic retinopathy

Pierre Haccart

Diabetic Retinopathy (DR) is the most common complication of diabetes and is the leading cause of vision-loss in working-age adults in industrialized countries. As the prevalence of diabetes in population worldwide is increasing, the prevalence of DR is also increasing. Reasons leading to the increase prevalence of DR also include the aging of the population and the increase in life expectancy in diabetic patient, duration of disease being one of the main risk factors for the development of DR. Other main risk factors include poor glycaemic control and high blood pressure, those risk factors being modifiable. Systemic treatment acting on those risk factors have proven beneficial in the treatment of DR.

Concerning local treatment of DR, it involves different kinds of approaches that are chosen according to cost, compliance of the patient, and staging of the disease. The main treatment options are pharmacological, laser treatment and surgery. Anti-Vascular Endothelial Growth Factor (Anti-VEGF), an anti-angiogenic drug, greatly improved treatment of DR, but despite the improve outcome of therapy with such new drugs, laser treatment, which is destructive, can still be needed as an adjuvant or in case of failure of anti-VEGF treatment. Further improvement of treatment is ongoing with newer laser treatment technology and studies on novel drugs such as novel anti-angiogenic drugs and drugs targeting the neurodegenerative process involved in DR. Vitrectomy, as a surgical option treatment, also has a role, especially in treatment of late complications of DR.

Key words: Diabetic retinopathy, anti-VEGF treatment, laser treatment, vitrectomy

## Sažetak

### Liječenje dijabetičke retinopatije

Pierre Haccart

Dijabetička retinopatija (DR) je najčešća komplikacija dijabetesa i vodeći je uzrok gubitka vida u radno sposobnih odraslih osoba u industrijaliziranim zemljama. Kako prevalencija dijabetesa u populaciji diljem svijeta raste, tako se povećava i prevalencija DR-a. Razlozi koji dovode do povećanja prevalencije DR također uključuju starenje stanovništva i produljenje očekivanog životnog vijeka dijabetičara, pri čemu je trajanje bolesti jedan od glavnih čimbenika rizika za razvoj DR. Drugi glavni čimbenici rizika uključuju lošu kontrolu glikemije i visoki krvni tlak, a ti se čimbenici rizika mogu mijenjati. Sustavno liječenje koje djeluje na te čimbenike rizika pokazalo se korisnim u liječenju DR.

Što se tiče lokalnog liječenja DR, ono uključuje različite vrste pristupa koji se biraju prema cijeni, suradljivosti pacijenta i stadiju bolesti. Glavne mogućnosti liječenja su farmakološki, laserski i kirurški. Anti-Vascular Endothelial Growth Factor (Anti-VEGF), lijek protiv angiogeneze, uvelike je poboljšao liječenje DR, no unatoč poboljšanom ishodu terapije takvim novim lijekovima, lasersko liječenje, koje je destruktivno, još uvijek može biti potrebno kao adjuvans ili u slučaju neuspjeha anti-VEGF liječenja. Daljnje poboljšanje liječenja je u tijeku s novijom tehnologijom laserskog liječenja i studijama o novim lijekovima kao što su novi lijekovi protiv angiogeneze i lijekovi koji ciljaju neurodegenerativne procese uključene u DR.

Vitrektomija, kao kirurška opcija liječenja, također ima ulogu, posebice u liječenju kasnih komplikacija DR.

Ključne riječi : dijabetička retinopatija, anti-VEGF liječenje, lasersko liječenje, vitrektomija



# 1. INTRODUCTION

Diabetes Mellitus (DM) is a major public health problem. Worldwide, in 2021, there was around 537 million people affected by diabetes mellitus, mainly in low- and middle-income countries, including both diabetes type 1 and diabetes type 2. It is estimated that this figure will increase significantly in the future. As the prevalence of diabetes in population worldwide is increasing, the prevalence of Diabetic Retinopathy (DR) is also increasing. DR is the most complication of DM and is the leading cause of vision loss in adults. (1)

The Early Treatment Diabetic Retinopathy Study showed that up to 98 % of diabetic blindness can be prevented (2). Prevention of risk factors and ophthalmologic treatment can then be combined to achieve this possible high rate of success in prevention of blindness in diabetic patients.

The treatment of DR involves different kinds of approaches that are chosen according to cost, compliance of the patient, and staging of the disease (3). The main treatment options are pharmacological, laser treatment and surgery (vitrectomy).

After briefly reviewing the pathophysiology of DR, as well as current epidemiological data and risk factors, we will here describe the different treatments used today in the setting of DR, by first describing the clinical manifestations and the different stages of the disease. Also, we will mention some of the drugs that aim to be neuroprotective in the setting of DR and that could potentially be used in the treatment of DR in the future.

## **2. EPIDEMIOLOGY OF DIABETIC RETINOPATHY**

Worldwide, in 2021, there was around 537 million people affected by diabetes mellitus, mainly in low- and middle-income countries, including both diabetes type 1 and diabetes type 2. It is estimated that this number will rise to 643 million by 2030 and to 783 million by 2045, with the prevalence being quite variable in different geographical areas in the world. For example, in 2021 there was 1 in 7 adults living with diabetes in North America and Caribbean compared with 1 in 22 adults living with diabetes in Africa (1,4).

DR is the most common complication of diabetes and the leading cause of vision loss in adults aged 20 to 74 years old. It affects around one third of diabetic patient, of which a third have Vision Threatening Diabetic Retinopathy (VTDR), defined as severe Non Proliferative Diabetic Retinopathy (NPDR) or Proliferative Diabetic Retinopathy (PDR) or the presence of Diabetic Macula Edema (DME), meaning that worldwide in 2021 there was around 177 million people affected by DR, with roughly 58 million of them having VTDR. Those numbers are expected to rise due to the increase prevalence of diabetes, the aging of the population and the increase life expectancy in diabetic patients, leading to an increase duration of disease, one of the main risk factors for the development of DR (1, 4). Diabetes type 2 is by far more prevalent than diabetes type 1 in adult population, with more than 90% of patients with diabetes having diabetes type 2 (1,5). Both patients with diabetes type 1 and type 2 are at risk of developing DR and its associated complications, with a higher prevalence of DR in patients affected by diabetes type 1 than in patients with diabetes type 2 (5).

### 3. RISK FACTORS AND PREVENTION

DR being a complication of DM, risk factors of DM are indirect risk factors for DR. Among modifiable risk factors of DM, there are a lack or an inadequate amount of physical activity, unhealthy eating with high-energy density diet with low fiber content and excessive body weight, especially in the instance of visceral obesity (6, 7).

Risk factors specific for the development of DR in diabetic patients are either non-modifiable risk factors or modifiable ones. Modifiable risk factors include poor glycaemic control, hypertension, dyslipidaemia, smoking, obesity and nephropathy, (8) while non-modifiable risk factors include duration of disease, age, genetic predisposition and ethnicity (9).

According to several scientific articles, the stronger predictors of development of DR are poor glycaemic control, hypertension and duration of disease (8, 10, 11).

It appears that some of the other modifiable risk factors such as dyslipidaemia, smoking and obesity are weaker predictors of the development of DR as studies showed conflicted results (11, 12).

Focusing on modifiable risk factors, main ones are poor glycaemic control and hypertension. It has been shown that a higher HbA1c increases both the incidence and the progression of DR (10, 11). There is also evidence that conventional glycaemic management (target of HbA1c of 7.0% to 7.9%) is less effective in preventing DR and its complication than intensive glycaemic management (target of HbA1c <6.0%) (11).

Concerning hypertension, a poorly controlled hypertension (Sistolic Blood Pressure (SBP)  $\geq 140$  and Diastolic Blood Pressure (DBP)  $\geq 90$ ) has been correlated with higher risk of developing DR and VTDR in diabetic patients. While increase SBP has

been associated with DR and VTDR, results showing an association between DR and VTDR with an increase of DBP have not been consistent (13).

## **4. PATHOPHYSIOLOGY**

Several mechanisms have been identified in the development and progression of DR. Even though one of the first description of DR was as a microvascular complication of DM, there is now evidence that neurodegenerative changes are involved in DR, some of these neurodegenerative changes being seen before vascular manifestations of DR (14, 15). It is believed that inflammation precedes neurodegenerative and vascular changes (16).

In the pathogenesis of DR, not only endothelial cells and pericytes are affected, but also retinal neurons and retinal glial cells.

Retinal glial cells being involved in maintaining homeostasis in the retina, their activation and dysfunction caused by hyperglycaemia participates in the development of an early retinal inflammatory response. The chronic metabolic stress provoking their activation leads to an increase level of cytokines, cytotoxic molecules and growth factors such as Vascular Endothelial Growth Factor (VEGF), involved in vascular dysfunction and neurodegeneration (15). As such, the expression level of inflammatory cytokines including Tumor Necrosis Factor - alpha (TNF-alpha), Interleukin-6, -8, and -1beta has been shown to be correlated with the severity of DR. Also, chemokines leading to leukostasis have been shown to be involved in DR (14).

Multiple metabolic pathways affected by hyperglycaemia are believed to be involved in the retinal vascular damage in DR, among which the polyol pathway, the advanced glycation end-product formation and accumulation, the protein kinase C

pathway and the hexosamine pathway (14, 17). This increase in retinal metabolism then leads to dilatation of blood vessels and blood flow changes. There is evidence of loss of pericytes and endothelial cells in this process, resulting in capillary occlusion and ischemia, associated with microaneurysms formation (14).

The increased in vascular permeability resulting from endothelial cells damage, which are involved in the maintenance of the blood-retinal barrier, is causing an accumulation of extracellular fluid in the macula, responsible for the appearance of DME, while the aforementioned capillary occlusion and ischemia is causing pathological neovascularisation due to expression of angiogenic factors (including VEGF), characteristic of PDR (18).

## **5. DIAGNOSIS AND CLINICAL MANIFESTATIONS**

### **5.1.SYMPTOMS**

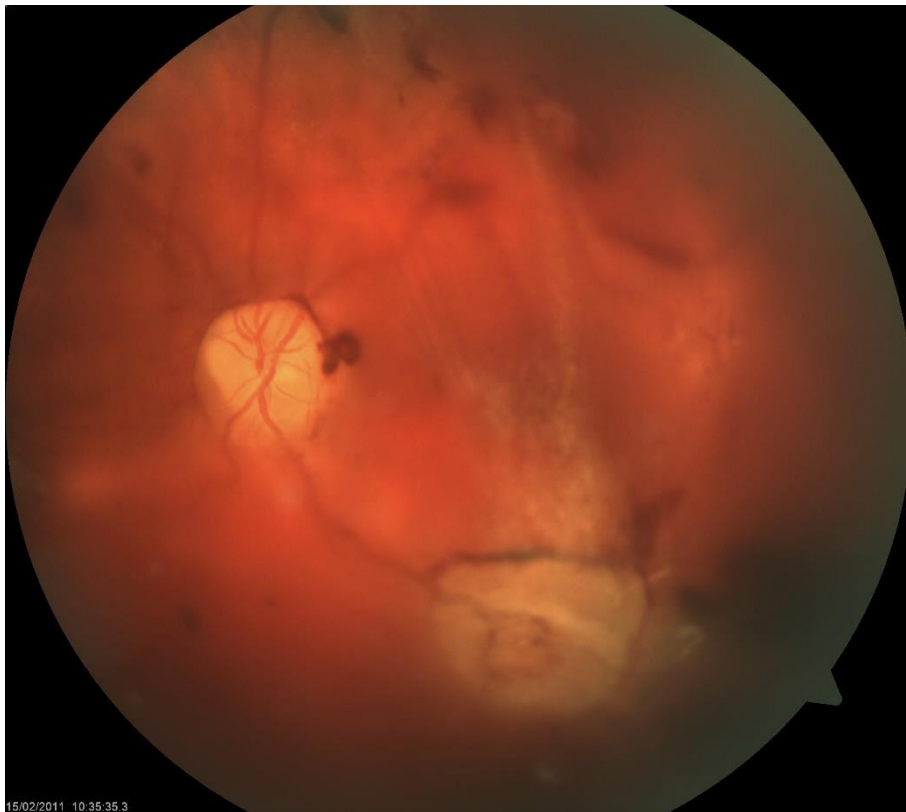In the early stage of disease, patients are often asymptomatic, but as the disease progresses, symptoms usually start to appear, usually in both eyes, such as an increased number of floaters, blurry vision, vision that changes sometimes from blurry to clear, blank or dark areas in the field of vision, poor night vision, colours that appear faded or washed out, and loss of vision (19).

### **5.2.CLINICAL MANIFESTATIONS**

Usually, the first clinical examination performed to assess if a diabetic patient has developed DR is an ophthalmoscopic examination of the fundus. Through fundus examination, ophthalmologists are looking for signs of vascular lesions or lesions

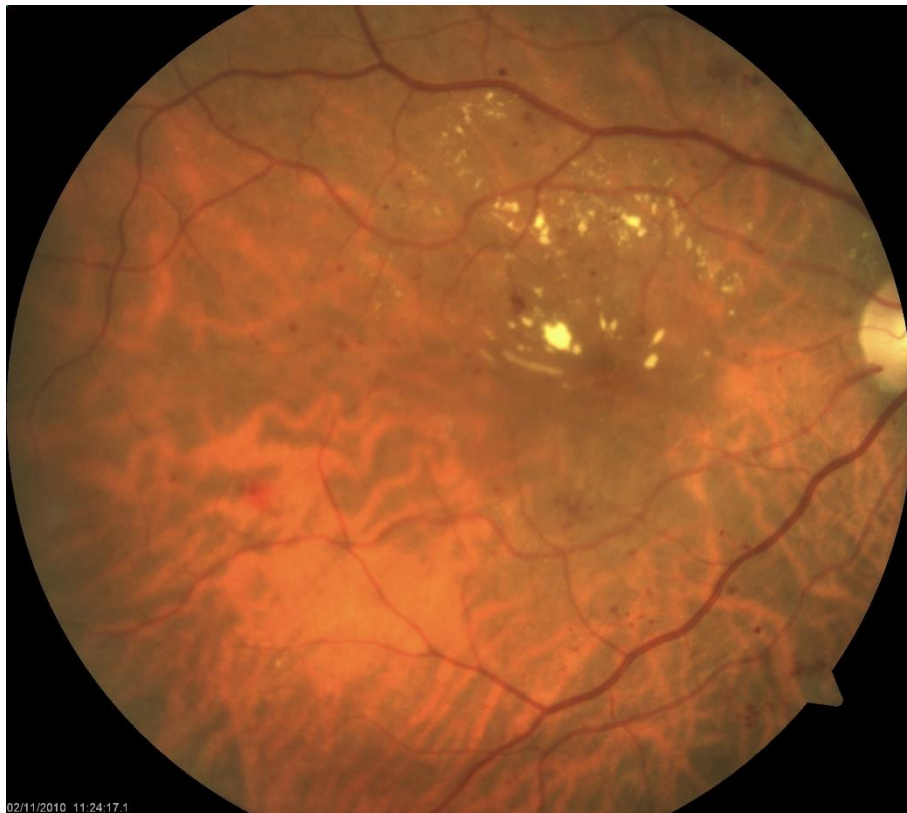
associated to them and the presence or absence of neovascularisation. The early clinical signs that can be seen when the patient is affected by DR and which corresponds to NPDR include : microaneurysms, one of the earliest clinically visible sign, corresponding to dilation of microvessels ; haemorrhages, occurring due to rupture of weakened capillaries, manifestation as small dots or larger blot haemorrhages dot and blot haemorrhages ; hard exudates, consisting of lipoproteins and other proteins leaking through abnormal retinal vessels, appearing as yellow lipid deposit ; and in advanced NPDR stages, cotton wool spots appearing as white lesions due to vascular occlusion (20) and intra-retinal microvascular anomalies, which are following larger areas of retinal ischemia (16).

As DR progresses, retinal ischemia will lead to intra-retinal and intra-vitreous neovascularisation, characteristic of PDR. These new vessels can be the cause of vitreous haemorrhage, that, if repeated, can lead to tractional retinal detachment and vision loss (21). PDR is associated with an increased occurrence of DME and fibroproliferative events, such as retinal traction, retinal detachment and vitreous hemorrhage (20).



**FIGURE 1 : FUNDUS PHOTOGRAPHY OF PROLIFERATIVE DIABETIC RETINOPATHY (SOURCE : ARCHIVES OF THE UNIVERSITY HOSPITAL CENTRE ZAGREB, 'ARHIVA UHC ZAGREB')**

DME can occur at any stage of DR (14). It involves thickening of the macula due to leakage of fluid from retinal capillaries (22). Sight loss from macular edema is typical of DM type 2 while intraocular haemorrhage and tractional retinal detachment are more common in DM type 1. DME is the most common cause of visual disability in DR (16). Even though DME can occur at any stage, it is more commonly associated with later stages of diabetic retinopathy. It is traditionally classified as either focal edema, with leakage associated with discrete areas of microaneurysms and hard exudates, and diffuse edema (21).



**FIGURE 2 : FUNDUS PHOTOGRAPHY OF DIABETIC MACULAR EDEMA AND NONPROLIFERATIVE DIABETIC RETINOPATHY (SOURCE : ARCHIVES OF THE UNIVERSITY HOSPITAL CENTRE ZAGREB, 'ARHIVA UHC ZAGREB')**



### 5.3.CLASSIFICATION OF DIABETIC RETINOPATHY

The most widely used classification of DR is based on the result of the Early Treatment Diabetic Retinopathy Study, according to which DR is classified as NPDR and PDR based on visible ophthalmological changes and on the presence of retinal neovascularisation (23).

NPDR is classified as either mild, moderate, severe or very severe. PDR is classified in early PDR and high-risk PDR. Here are detailed the associated clinical features of each stage, as well as the associated risk to develop PDR for each NPDR stage (23) :

#### Mild NPDR :

At least one microaneurysm. Few intraretinal dot or blot haemorrhages.

(Have only a 5% risk of progressing to PDR within 1 year and only a 15% risk progressing to high -risk PDR.)

#### Moderate NPDR :

Microaneurysms and/or intraretinal haemorrhages present in fewer than 4 quadrants of the retina, as well as presence of cotton wool spots, venous beading, and intraretinal microvascular abnormalities.

(Have a 12-27% risk to progressing to PDR within 1 year and a 33% 5-year risk of progressing to PDR.)

#### Severe NPDR :

Patients have one of these elements, known as « 4-2-1 rule »:

- 4 quadrants of intraretinal haemorrhages or microaneurysm

- 2 quadrants of significant venous beading
- 1 quadrant of intraretinal microvascular abnormalities.

(Have a 52% risk of progressing to PDR within 1 year and a 60% 5-year risk of progressing to PDR.)

#### Very severe NPDR :

Patients have at least two of the elements of the « 4-2-1 rule ».

(Have a 75% risk of progressing to PDR within 1 year.)

#### Early PDR :

Presence of new vessels.

#### High-risk PDR :

Have one of these elements:

- Neovascularization of disc (NVD) > 1/3rd to 1/4th disc diameter
- NVD < 1/3rd to 1/4th disc diameter with vitreous/pre-retinal haemorrhage
- Neovascularization with vitreous/pre-retinal haemorrhage.

(Have a high risk of severe visual loss.)

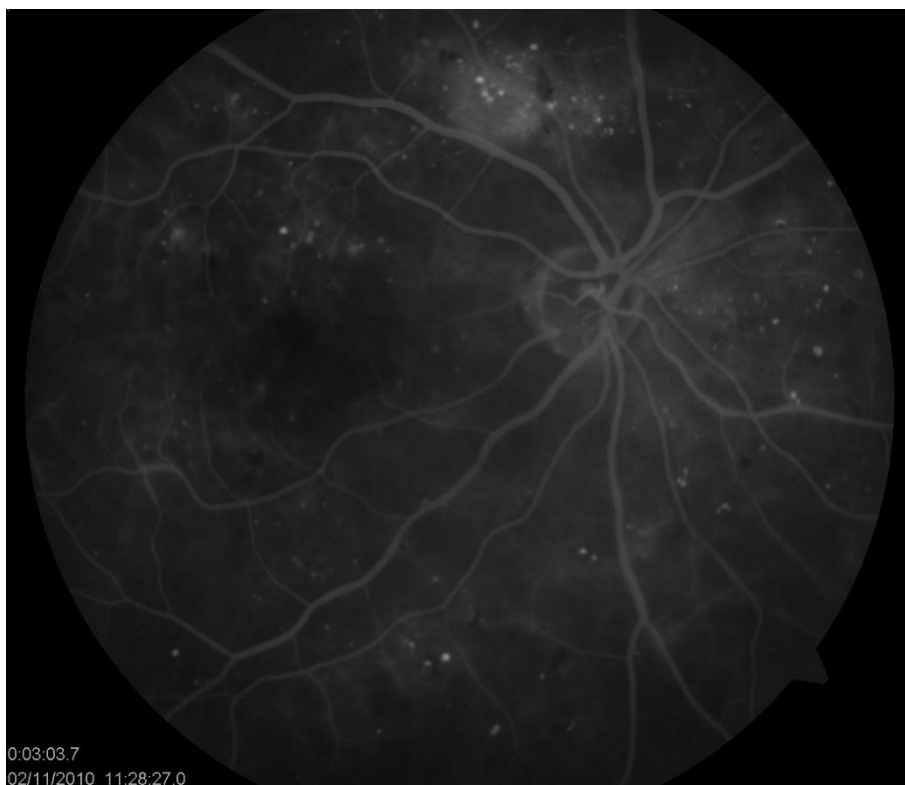Regarding the visible features such as tractional retinal detachment, non-clearing vitreous haemorrhage and DME, that are taught to be leading to loss of vision, they do not strictly correlate with this clinical classification. As such, people with mild retinopathy can have reduced vision while patients with advanced PDR can have nearly normal vision, when vision is defined as visual acuity (24).

## 5.4.IMAGERY IN DIABETIC RETINOPATHY

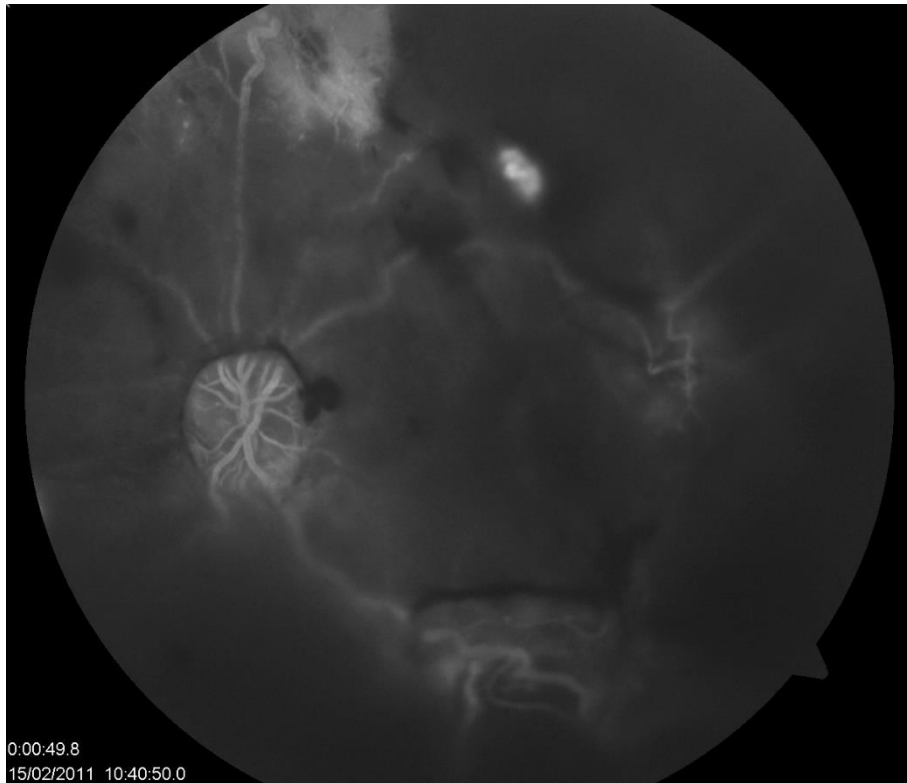
Different technical imaging tools are used to diagnose DR. Such tools include fundus photography, Fluorescein angiography (FA), Optical Coherence Tomography (OCT) and B-scan ultrasonography.

Fundus photography is helpful to screen patient for DR and to document retinal disease over time (25).

Fluorescein angiography (FA) is an invasive medical imaging technique. It provides images of the fundus of the eye after injecting a fluorescent dye (fluorescein) into a vein. It is a dynamic test with a larger field of view (26). FA is helpful for visualizing retinal ischemia, as well as leakage from retinal neovascularization and also in macular edema (25).

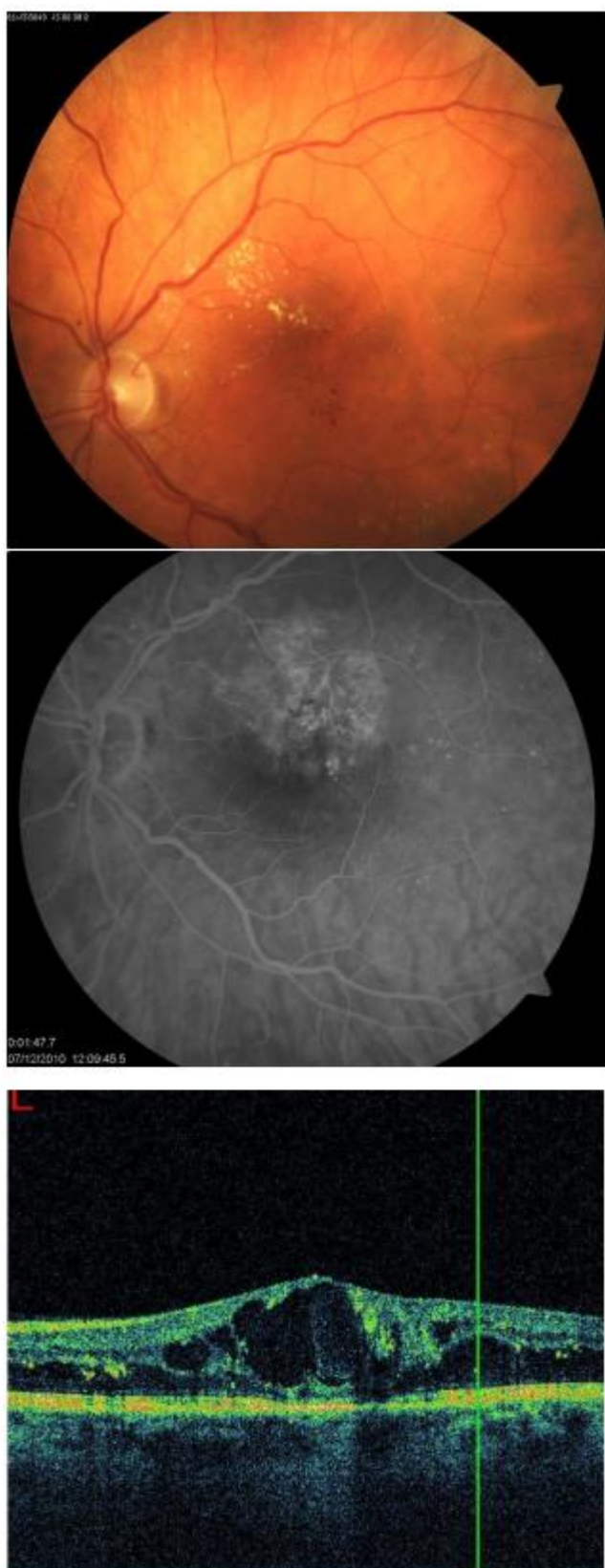

**FIGURE 3 : FLUORESCEIN ANGIOGRAPHY OF DIABETIC MACULAR EDEMA AND NONPROLIFERATIVE DIABETIC RETINOPATHY (SOURCE : ARCHIVES OF THE UNIVERSITY HOSPITAL CENTRE ZAGREB, 'ARHIVA UHC ZAGREB')**



**FIGURE 4 : FLUORESCIN ANGIOGRAPHY OF PROLIFERATIVE DIABETIC RETINOPATHY (SOURCE : ARCHIVES OF THE UNIVERSITY HOSPITAL CENTRE ZAGREB, 'ARHIVA UHC ZAGREB')**

Optical Coherence Tomography (OCT) is a non-invasive medical imaging technique. It provides three-dimensional images with resolution in the order of micrometer ( $1\mu\text{m}$ ) with individual slice display. This imaging technique is now an essential tool for ophthalmologists and allows to highlight the slightest abnormalities of the fundus of the eye. It is increasingly used to detect retinopathy in diabetic patients. It is well suited for the management of retinal diseases. It has become the most important imaging tool for the diagnosis and management of diabetic macular edema (25). It allows non-invasive monitoring of retinal thickness and progression of edema (21).



**FIGURE 5 : FUNDUS PHOTOGRAPHY, FLUORESCEIN ANGIOGRAPHY AND OPTICAL COHERENCE TOMOGRAPHY OF DIABETIC MACULAR EDEMA (SOURCE : ARCHIVES OF THE UNIVERSITY HOSPITAL CENTRE ZAGREB, 'ARHIVA UHC ZAGREB')**

Newer techniques, including OCT angiography, are also increasingly being used (27). OCT angiography is a non-invasive technique, consisting of the OCT system associated with an angiography system. It visualizes retinal thickness and retinal blood vessels (26).

B-scan ultrasonography can be helpful in patients with media opacity, such as vitreous hemorrhage or cataract (25).

## **6. TREATMENT OF DIABETIC RETINOPATHY**

When considering the treatment of DR, control of glycemia, dyslipidaemia, and blood pressure, are important means of delaying the progression of the disease and its associated complication as they showed beneficial effects for both DR and DME. (28) For this reason, the treatment and follow-up of patients with DR is not only a task for ophthalmologists but also for general practitioners and endocrinologists, in order to act on modifiable risk factors mentioned earlier, the most important ones being poor glycaemic control and the hypertension (8, 10, 11).

Concerning specific ophthalmologic treatments, chosen treatments depend on the progression of the disease, as well as the cost and expected compliance of patients, as some treatment options require more regular visits to the hospital (3). Main treatment options are pharmacological treatment, laser treatment, and surgical treatment. Regardless of the treatment options chosen, regular fundus examination in patients with diabetes is necessary to diagnose as early as possible the appearance of DR in order to implement treatment the earliest, which decreases the prevalence of poor vision and blindness (8).

## **6.1.PHARMACOLOGICAL THERAPY**

When considering pharmacological therapy, the most important classes of drugs are the anti-VEGF drugs, followed by corticosteroids (29).

### **6.1.1.ANTI-VEGF**

As mentioned earlier, VEGF is an important factor involved in the pathophysiology of DR. For this reason, anti-VEGF drugs have emerged in order to stabilize or improve vision in patients with DR. The intravitreal administration is now the first-line therapy for the treatment of DR, in both early and advanced stages (14).

Several anti-VEGF drugs exist. The 3 most widely being bevacizumab (monoclonal antibody), ranibizumab (monoclonal antibody fragment) and aflibercept (fusion protein), all administered through intravitreal injections (30). The efficacy in treating DME of bevacizumab and ranibizumab was proven in 2010 while the efficacy of aflibercept in 2014 (29).

Today, not only intravitreal anti-VEGF injections became the gold standard for DME, but it also has been shown that anti-VEGF may improve DR severity. Concerning the treatment of PDR, anti-VEGF agents are considered viable treatment options (31). Anti-VEGF agents also showed efficacy in delaying the progression from high-risk NPDR to PDR, as showed by a study on ranibizumab (20). They also showed their usefulness in the case of recurrent vitreous haemorrhage following PRP, preoperatively before pars plana vitrectomy to decrease vessel size and in the case of neovascularization of the iris (3).

Regarding the side effects, there were concerns that intravitreal injection of one of the 3 aforementioned anti-VEGF could raise cardiovascular risk, but no consistent

evidence has been reported. (29) However, elevation in intraocular pressure, vitreous haemorrhage, and inflammation have been reported following treatment (14).

Despite proven efficacy of anti-VEGF drugs, for example in the management of DME, there is not a complete response to therapy in some patients (30). This may be due to other angiogenic factors besides VEGF involved in the pathogenesis of DR. For this reason, several anti-angiogenic drugs are under clinical investigations. Such drugs include Nesvacumab which aim to decrease vascular permeability by inhibiting Angiopoietin-2 therefore activating the tyrosine receptor kinase Tie2 (14). It involves interaction between angiopoietins and tyrosine receptor kinase. For example, Angiopoietin-2 deactivates Tie2 causing vascular destabilization (32). RO6867461, a bispecific antibody which targets VEGF but also Ang-2, the target of Nesvacumab, and also Squalamine, a drug that act by inhibiting multiple angiogenic factors, Vascular Endothelial Growth Factor (VEGF), Platelet Derived-Growth Factor (PDGF) and basic-Fibroblast Growth Factor (b-FGF) (14).

### **6.1.2.ANTI-INFLAMMATORY TREATMENT**

As described above in pathophysiology part, inflammation plays an important in the pathogenesis of DR. For this reason, some anti-inflammatory drugs are being used as treatment and some other are in clinical trials.

#### **Intravitreal corticosteroids :**

Even though anti-VEGF is the first line treatment for DME, intravitreal corticosteroids are being used especially in refractory DME and when the outcome of anti-VEGF treatment is not satisfactory. Corticosteroids are potent anti-inflammatory agents and therefore target several mediators in the pathogenesis of DME. Such drugs



include triamcinolone acetonide, dexamethasone intravitreal implant and fluocinolone acetonide intravitreal implant (14).

The use of corticosteroids, despite their promising efficacy in the treatment of DME, is still considered as a second-line treatment, because of the high incidence of adverse effects, including cataract, elevation of intraocular pressure and vitreous haemorrhage (14).

### **Non-Steroidal Anti-Inflammatory drugs (NSAIDs) :**

Another class of drugs that has anti-inflammatory properties are the NSAIDs. With their use, positive effects have been noticed in the treatment of DR. Among such drugs is ketorolac, a prostaglandin synthesis inhibitor that targets the cyclooxygenase family of enzymes. Intravitreal and topical administration of ketorolac showed an increase in visual acuity, but side effects have been reported. However, compared to corticosteroids, there is a decreased risk of cataracts and decrease risk of elevated intraocular pressure (27).

### **6.1.3.POTENTIAL NEUROPROTECTIVE DRUGS**

As mentioned earlier, neurodegeneration plays a significant role in the pathogenesis of DR. For this reason, drugs aiming to prevent or slow this process are being studied. We will here present some of these drugs and their target.

MTP-131 is a drug targeting cardiolipin. Cardiolipin is an abundant lipid in the inner mitochondrial membrane. As in some patients with PDR circulating cardiolipin antibodies were found, it was suggested that cardiolipin could be a risk factor for DR. MTP-131 is a water soluble peptide which was shown to protect visual function in diabetic mice (33).

Alpha-lipoic (ALA) acid is a coenzyme involved in regulating mitochondrial metabolism and appears to have antioxidant properties. These antioxidant capacities, its ability to prevent lipid peroxidation in diabetic retina and the evidence showing that administration of ALA promotes visual acuity in diabetic patients, gives an opportunity to do more research to establish the effectiveness for ALA as a neuroprotective agent. (33)

Carotenoids are natural pigments synthesized by some microorganisms and plants and include carotenes, lutein, zeaxanthin and lycopene. They have a potential to modulate degenerative diseases. In diabetic retina, they have been shown to protect retinal mitochondrial function from hyperglycemia induced stress, and zeaxanthin and lutein have been shown to promote the survival of neuronal cells in the inner layer of the retina by reducing the incidence of apoptosis. (33)

Nuclear factor (erythroid-derived 2) -like 2 (Nrf2) is a key transcription factor in the regulation of cellular responses to oxidative stress and inflammation. Dimethyl and monomethyl fumarate, drugs that target Nrf2, have been shown to reduce the relapse rate in patients with multiple sclerosis and as such they may be a future approach in treating retinal neurodegeneration in diabetes. Nrf2 is suggested to play a protective role in the retina, and when its activity appears compromised by diabetes (33).

ARA 290, a small erythropoietin-derived peptide, has been shown to have a neuroprotective role. In diabetic rats, it has showed efficacy in treating DR by preventing neuroglial and vascular degeneration (14).

## **6.2.LASER TREATMENT**

Before the emergence of anti-VEGF treatment, laser treatment was the first line therapy in both DME and PDR. Today, in the context of DR, it is still used in the treatment of PDR and DME, for example, as an adjuvant to anti-VEGF treatment. Laser treatment is a destructive process but is still used to increase the results of overall therapy as an adjuvant, but also as a rescue therapy in case of failure of anti-VEGF treatment, and because anti-VEGF treatment requires more frequent visit to the hospital for the patient, necessitating greater compliance of the patient compared to laser treatment. Anti-VEGF treatment also represents a higher cost than laser treatment (14, 34).

### **6.2.1.CONVENTIONAL LASER TREATMENT**

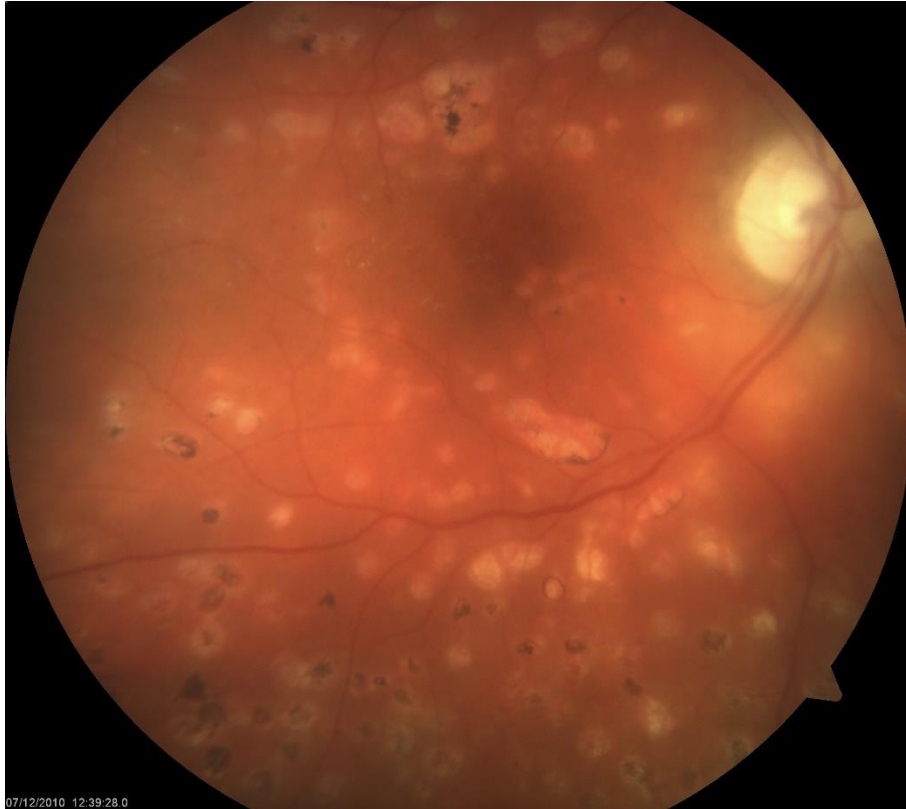Different kind of laser treatment exists today, with conventional/traditional laser treatment being focal/grid laser treatment and panretinal photocoagulation, both part of traditional laser treatment. Focal/grid laser treatment is indicated as an adjuvant in the treatment of DME, while Panretinal Photocoagulation (PRP) is also used as an adjuvant but in the treatment of PDR.

PRP consists of as many as 2500 of laser foci to the peripheral retina in order to reduce neovascularisation and its complication, while focal/grid laser treatment consists of targeting leaking microaneurysms and capillaries in the area around the fovea when clinically significant DME is present (35). Specifically, focal laser treatment is meant to treat focal areas of leakage while grid laser treatment is meant to treat diffuse retinal thickening secondary to diffuse leakage (36).

The mechanism of action of laser therapy is not fully understood, but regarding PRP in the treatment of PDR, given that 'the photoreceptors are the most metabolically

active and numerous cell type within the retina', their destruction through laser treatment decreases the oxygen demand of the retina which downregulates the production of angiogenic factors by the retinal tissue, delaying the neovascularisation characteristic of PDR (36).

The use of conventional laser treatments was justified by the good results it provided and are still used today. The Diabetic Retinopathy Study, which was focusing on the efficacy of PRP in advanced NPDR and PDR, showed a risk reduction of severe visual loss by 60% at 2 years in patients with high-risk PDR (36, 35), while a study aimed to measure the efficacy on Clinically Significant Macular Edema (CSME), named the Early Treatment Diabetic Retinopathy Study (ETDRS), showed that focal/grid laser therapy was reducing the risk of vision loss by 50% after a 3-year follow up (14, 36). 'The ETDRS definition of CSME was based on the presence of any one of the following three characteristics: Retinal thickening within 500  $\mu$ m of the center of the macula, Hard exudate within 500  $\mu$ m of the center of the macula with associated thickening, or Zone or zones of thickening larger than one disc area in size, any part of which is within one disc diameter of the center of the macula.' (36).



**FIGURE 6 : FUNDUS PHOTOGRAPHY OF PROLIFERATIVE DIABETIC RETINOPATHY AND MACULAR EDEMA AFTER LASER PHOTOCOAGULATION (SOURCE : ARCHIVES OF THE UNIVERSITY HOSPITAL CENTRE ZAGREB, 'ARHIVA UHC ZAGREB')**

However, conventional laser treatment being a destructive treatment, it can lead to undesirable side effects affecting vision, such as permanent scotomas in the visual fields, worsening of night vision and delay in light-to-dark adaptation (29). Other side effects include permanent retinal scarring, choroidal detachments, elevated intraocular pressure, cystoid macular edema and decreased patient peripheral vision and color vision (36).

### **6.2.2. NEWEST LASER TREATMENT**

With the goal of reducing the side effects of treatment but also improving outcome, efforts are being made to develop newer kind of laser treatment by modifying laser parameters, such as laser pulse duration, spot size and wavelength (34, 36).

Among the new laser therapies, there are the Selective Retinal Therapy (SRT), the Subthreshold Diode Micropulse laser (SDM), the Pattern Laser Scanning (PASCAL), or also the Navigated Laser System (NAVILAS).

PASCAL and NAVILAS are one of the newest laser treatment modalities that are already commercially available and aimed to be used for both DME and PDR (36). PASCAL allows for 'delivery of various predetermined laser spots patterns' (34). It reduces retinal damage, treatment time (14), reduces pain and visual field defect (37). NAVILAS is a laser treatment modality with a 'computerized image capture and tracking assistance'. In addition to reduction of pain from laser burns and shorter duration of treatment (37), one of the most significant benefits of this treatment is a higher accuracy of the laser spots (14).

SRT and SDM have their indications limited to DME (36). With the use of SRT, the duration of the laser pulse is reduced, which allows to selectively target the Retinal Pigment Epithelium (RPE) cells and avoid damage to the photoreceptors, neurosensory retina and choroid, as high temperatures are confined to the RPE (34, 36). In SDM, the RPE is also selectively targeted as the energy threshold required to damage or scar the neurosensory retina is not reached, with the use of a shorter duration of pulse. Also, in SDM, as the micro pulses are delivered, they are separated by period of time without treatment which allows for a return to baseline temperature of the tissue between pulses (36).

### **6.3.SURGICAL TREATMENT : VITRECTOMY**

Vitrectomy is a surgical technique. It has an important role in the management of DR, especially for late complications.

It consists of removing the vitreous humor, which is immediately replaced by liquid or gas in order to maintain the spherical shape of the eye. It can be an intermediate step in operations such as retinal detachment. It is performed under an operating microscope with introduction of micro-instruments (Vitreous Infusion Suction Cutter – VISC) into the eye through a corneoscleral incision or through the pars plana.

It is an operation with possible Intra- and Post-operative complications. Concerning patients with diabetes, the possible complications are the following: (38)

- corneal edema,
- iatrogenic retinal breaks,
- intraoperative bleeding and intraocular fibrin formation (may require injection of recombinant tissue plasminogen activator),
- elevated intraocular pressure (eyes with diabetic retinopathy are quite susceptible to visual loss from elevated postoperative intraocular pressure – IOP- and require close monitoring),
- cataract (significant cataract occurs in 17-37% of eyes undergoing vitrectomy for diabetic retinopathy),
- rubeosis and neovascular glaucoma (treatment with topical steroids, cycloplegics and intravitreal bevacizumab).
- postoperative vitreous hemorrhage (intravitreal injection of bevacizumab at the end of diabetic vitrectomy can decrease this risk).
- anterior hyaloidal fibrovascular proliferation (AHFVP) (in nearly 13% of cases. additional panretinal photocoagulation, cryotherapy of sclerotomy sites, and surgical intervention are usually necessary).

New techniques and pharmacological interventions, including minimally invasive vitreoretinal surgery and intravitreal bevacizumab, promotes the vitrectomy, including early vitrectomy, with improved prognosis for a favorable visual outcome (38,39).

Early vitrectomy is discussed according to the types of diabetes, the profiles of the patients, the comparison of the results obtained with the other treatments (pharmacology, laser), the risk analysis.

However, other treatments as preventive measures (control of glucose levels and application of pan retinal photocoagulation) can produce better results (39).

#### **6.4.ANTI-VEGF AND LASER TREATMENT IN CLINICAL PRACTICE**

Today, anti-VEGF drugs are the subject of many indications in the treatment of diabetic eye disease. However, anti-VEGF is not a magic cure and anti-VEGF therapies cannot replace PRP. Both PRP and anti-VEGF agents are viable treatment options, while specific factors. Anti-VEGF should be combined with PRP according to the clinical manifestations, their progress and their severity and also according to the cost of treatments. These associations are the subject of treatment strategies (40,31).

Zhao M, Sun Y and Jiang Y in 'anti-VEGF therapy is not a magic bullet' recommend the following specific treatment strategies (40) :

- 'for visual impairment due to centre-involving DME in eyes with NPDR, anti-VEGF therapy is the first choice of treatment. When DR progresses to severe NPDR and PDR, PRP is the standard of care and anti-VEGF therapy should be used as an adjuvant or to prevent the aggravation of DME after PRP.'



- 'for high-risk PDR, anti-VEGF therapy may be used to inhibit neovascularization prior to completion of PRP within the effective period of drug action, so as to avoid the disease progression caused by the slow uptake of PRP.'
- 'for patients in whom PRP is indicated but cannot complete PRP immediately, anti-VEGF therapy may be used or even repeated as a temporary measure. Anti-VEGF therapy can be terminated after completion of PRP.'
- 'for patients with advanced PDR, anti-VEGF therapy is recommended before vitrectomy to reduce the probability of intraoperative and postoperative haemorrhage, to create a bloodless field for the operation and to avoid postoperative complications. However, it is necessary to strictly adhere to the timing of anti-VEGF injection.'
- 'for neovascular glaucoma secondary to DR, a comprehensive treatment strategy of anti-VEGF treatment, completion of PRP and anti-glaucoma surgery has to be adopted' (40).

## **7. CONCLUSION**

Diabetic Retinopathy represents a major burden worldwide as it is the leading cause of vision-loss in working adults in industrialized countries. Its prevalence is increasing due to the aging of the population and the increase life expectancy in diabetic patient, as duration of disease is an important risk factor. Some risk factors, such as poor glycaemic control and high blood pressure, are modifiable. This can lead to treatment targeting those risk factors with a positive outcome.

With numerous studies showing that ophthalmic treatment can have greatly positive outcome on DR, several treatment options exist and help lowering the burden of vision loss in diabetic patients. Before the anti-angiogenic treatment with anti-VEGF, laser treatment showed good results. Nowadays, both anti-VEGF and laser treatment are used, with anti-VEGF treatment often being used as first line treatment and laser treatment as an adjuvant or in case of failure of anti-VEGF treatment. Other factors involved in the decision making of treatment management involve the cost of treatment, the compliance of the patient and the staging of disease.

Improvements are being made in laser treatment with technologies that allow for less destruction of retinal tissue and better outcome. Pharmacological treatment may also improve with new drugs being studied, such as novel anti-angiogenic drugs and drugs that aim to target the process of neurodegeneration involved in DR rather than targeting the microvascular changes. Vitrectomy, a surgical option treatment, is mainly used in case of late complications of DR.

## **8. ACKNOWLEDGEMENTS**

I would like to thank my mentor prof.dr.sc. Nenad Vukojevic, especially for providing the pictures, from the Archives of the University Hospital Centre of Zagreb (Arhiva UHC Zagreb).

## 9. REFERENCES

1. International Diabetes Federation. IDF Diabetes Atlas 10th Edition. 2021. Available on :

[https://diabetesatlas.org/idfawp/resourcefiles/2021/07/IDF\\_Atlas\\_10th\\_Edition\\_2021.pdf](https://diabetesatlas.org/idfawp/resourcefiles/2021/07/IDF_Atlas_10th_Edition_2021.pdf)

2. Shukla D, Dhawan A, Kalliath J. Featureless retina in diabetic retinopathy: Clinical and fluorescein angiographic profil. Indian J Ophtalmol. 2021 Nov; 69(11): 3194–3198.

Available on : <https://www.ncbi.nlm.nih.gov/pmc/articles/PMC8725138/>

3. B. Kansora M, Goldhardt R. Decision Making in Proliferative Diabetic Retinopathy Treatment. Current Ophtalmology Reports. 2019 Mar;7(1):45-50. Available on :

<https://www.ncbi.nlm.nih.gov/pmc/articles/PMC6781632/>

4. Lee R, Wong TY, Sabanayagam C. Epidemiology of diabetic retinopathy, diabetic macular edema and related vision loss. Eye and Vis (Lond). 2015 Sep 30;2:17.

Available on : <https://doi.org/10.1186/s40662-015-0026-2>

5. Xu G, Liu B, Sun Y, Du Y, G Snetselaar L, B Hu F, Bao W. Prevalence of diagnosed type 1 and type 2 diabetes among US adults in 2016 and 2017: population based study. BMJ.2018;362:k1497. Available on

<https://www.ncbi.nlm.nih.gov/pmc/articles/PMC6122253/>

6. Kolb H, Martin S. Environmental/lifestyle factors in the pathogenesis and prevention of type 2 diabetes. BMC Med. 2017;15:131. Available on :

<https://www.ncbi.nlm.nih.gov/pmc/articles/PMC5516328>

7. Wu Y, Ding Y, Tanaka Y, Zhang W. Risk Factors Contributing to Type 2 Diabetes and Recent Advances in the Treatment and Prevention. *Int J Med Sci*. 2014;11(11):1185-1200. Available on : <https://www.ncbi.nlm.nih.gov/pmc/articles/PMC4166864/>
8. Lin KY, Hsieh WH, Lin YB, Wen CW, Chang TJ. Update in the epidemiology, risk factors, screening, and treatment of diabetic retinopathy. *J Diabetes Investig*. 2021 Aug;12(8):1322-1325. Available on : <https://www.ncbi.nlm.nih.gov/articles/PMC8354492/>
9. H Scanlon P, J Aldington S, M Stratton I. Epidemiological Issues in Diabetic Retinopathy. *Middle East Afr Ophthalmol*. 2013 Oct-Dec;20(4):293-300. Available on : [Epidemiological Issues in Diabetic Retinopathy - PMC \(nih.gov\)](https://pubmed.ncbi.nlm.nih.gov/27779095/)
10. Simo-Servat O, Hernandez C, Simo R. Diabetic Retinopathy in the Context of Patients with Diabetes. *Ophthalmic Res*. 2019;62:211-217. Available on : <https://www.karger.com/Article/FullText/499541#ref6>
11. Watt N, Wong RLM, Wong IYh. Associations between diabetic retinopathy and systemic risk factors. *Hong Kong Med J*. 2016 Dec;22(6):589-599. Available on : <https://pubmed.ncbi.nlm.nih.gov/27779095/>
12. F. Magliyah S, Bardisi W, Al Attah M, M. Khorsheed M. The prevalence and risk factors of diabetic retinopathy in selected primary care centers during the 3-year screening intervals. *J Family Med Care*. 2018 Sep-Oct;7(5):975-981. Available on : <https://www.ncbi.nlm.nih.gov/pmc/articles/PMC6259536/#:~:text=%5B8%5D%20The%20risk%20factors%20are,were%20variably%20associated%20with%20DR.>

13. Liu L, Duc Quang N, Banu R, Kumar H, Tham YC, Cheng CY, YinWong T, Sabanayagam C. Hypertension, blood pressure control and diabetic retinopathy in a large population-based study. PLoS One. 2020;15(3):e0229665. Available on : <https://www.ncbi.nlm.nih.gov/pmc/articles/PMC7058315/>
14. Wang W, C. Y. Lo A. Diabetic Retinopathy : Pathophysiology and Treatments. Int J Mol Sci. 2018 Jun;19(6):1816. Available on : <https://www.ncbi.nlm.nih.gov/pmc/articles/PMC6032159/>
15. Singh A, Sharma I, Krishna Das G, Sahu PK, and Rohatgi J. Commentary: recent concepts of pathophysiology and advancements in treatment strategies of diabetic retinopathy. Indian J Ophthalmol. 2021 Nov;69(11):3050-3051. Available on : <https://www.ncbi.nlm.nih.gov/pmc/articles/PMC8725151/#R16>
16. V. Forrester J, Kuffova L, Delibegovic M. The Role of Inflammation in Diabetic Retinopathy. Front Immunol. 2020;11:583687. Available on : <https://www.ncbi.nlm.nih.gov/pmc/articles/PMC7677305/>
17. Qian H, Ripps H. Neurovascular Interaction and the Pathophysiology of Diabetic Retinopathy. Exp Diabetes Res. 2011;2011:693426. Available on : <https://www.ncbi.nlm.nih.gov/pmc/articles/PMC3124285/>
18. A. Ciulla T, G. Amador A, Zinman B. Diabetic Retinopathy and Diabetic Macular Edema: Pathophysiology, screening, and novel therapies. Diabetes Care. 2003;26(9):2653-2664. Available on : <https://diabetesjournals.org/care/article/26/9/2653/22508/Diabetic-Retinopathy-and-Diabetic-Macular>

19. Ninel Z, Gregori MD. Diabetic Retinopathy : Causes, Symptoms, Treatment.

American Academy of Ophthalmology. 2021 Sep 14. Available on :

<https://www.aao.org/eye-health/diseases/what-is-diabetic-retinopathy>

20. C.Wyckoff C, A.Eichenbaum D, B.Roth D, Hill L, E.Fung A, Haskova Z.

Ranibizumab Induces Regression of Diabetic Retinopathy in Most Patients at High Risk of Progression to Proliferative Diabetic Retinopathy. Ophthalmology Retina.

2018 Oct;2(10): 997-1009. Available on :

<https://www.sciencedirect.com/science/article/pii/S2468653018300472?via%3Dihub>

21. Lechner J, E. O'Leary O, W. Stitt A. The pathology associated with diabetic retinopathy. Vision Research. Oct 2017;139:7-14. Available on :

<https://doi.org/10.1016/j.visres.2017.04.003>

22. T. Bolinger M, A. Antonetti D. Moving Past Anti-VEGF: Novel Therapies for

Treating Diabetic Retinopathy. Int J Mol Sci. 2016 Sep;17(9):1498. Available on :

<https://www.ncbi.nlm.nih.gov/pmc/articles/PMC5037775/>

23. L. Rodríguez M, Pérez S, Mena-Mollá S, Desco MC, Ortega AL. Oxidative Stress and Microvascular Alterations in Diabetic Retinopathy: Future Therapies. Oxid Med

Cell Longev. 2019;2019:4940825. Available on :

<https://www.ncbi.nlm.nih.gov/pmc/articles/PMC6878793/>

24. W Gardner T, M.Sundstrom J. Proposal for Early and Personalized Treatment of Diabetic Retinopathy Based on Clinical Pathophysiology and Molecular Phenotyping.

Vision Res. 2017 Oct;139:153-160. Available on :

<https://www.ncbi.nlm.nih.gov/pmc/articles/PMC5987228/>

25. A. Salz D, J. Witkin A. Imaging in Diabetic Retinopathy. Middle East Afr J Ophthalmol. 2015 Apr-Jun; 22(2): 145–150. Available on : <https://www.ncbi.nlm.nih.gov/pmc/articles/PMC4411609/>
26. F Shaikh N, Vohra R, Balaji A, V Azad S, Chawla R, Kumar V, Venkatesh P, Kumar A. Role of optical coherence tomography-angiography in diabetes mellitus: Utility in diabetic retinopathy and a comparison with fluorescein angiography in vision threatening diabetic retinopathy. Indian J Ophthalmol. 2021 Nov; 69(11): 3218–3224. Available on : <https://www.ncbi.nlm.nih.gov/pmc/articles/PMC8725072/>
27. Whitehead M, Wickremasinghe S, Osborne A, Van Wijngaarden P, R. Martin K. Diabetic retinopathy: a complex pathophysiology requiring novel therapeutic strategies. Expert Opin Biol Ther. 2018;18(12):1257-1270. Available on : <https://www.ncbi.nlm.nih.gov/pmc/articles/PMC6299358/>
28. Mansour SE, Browning DJ, Wong K, Flynn Jr HW, Bhavsar AR. The Evolving Treatment of Diabetic Retinopathy. Clinical Ophthalmology. 2020;14:653-678. Available on : <https://www.dovepress.com/the-evolving-treatment-of-diabetic-retinopathy-peer-reviewed-fulltext-article-OPHTH>
29. E Mansour S, J Browning D, Wong K, W Flynn Jr H, R Bhavsar A. The Evolving Treatment of Diabetic Retinopathy. Clin Ophthalmol. 2020;14:653-678. Available on : <https://www.ncbi.nlm.nih.gov/pmc/articles/PMC7061411/>
30. Bahrami B, Hong T, C Gilles M, Chang A. Anti-VEGF Therapy for Diabetic Eye Diseases. Asia Pac J Ophthalmol (Phila). 2017 Nov-Dec;6(6):535-545. Available on : [Anti-VEGF Therapy for Diabetic Eye Diseases - PubMed \(nih.gov\)](https://pubmed.ncbi.nlm.nih.gov/3061411/)



31. Chatziralli I, Loewenstein A. Intravitreal Anti-Vascular Endothelial Growth Factor Agents for the Treatment of Diabetic Retinopathy: A Review of the Literature. *Pharmaceutics*. 2021 Aug;13(8):1137. Available on :  
<https://www.ncbi.nlm.nih.gov/pmc/articles/PMC8399287/>
32. P Leley SQ, A Ciulla T, D Bhatwadekar A. Diabetic Retinopathy in the Aging Population : A Perspective of Pathogenesis and Treatment. *Clin Interv Aging*. 2021;16:1367–1378. Available on :  
<https://www.ncbi.nlm.nih.gov/pmc/articles/PMC8289197/>
33. J Barber A, Baccouche B. Neurodegeneration in diabetic retinopathy: Potential for novel therapies. *Vision Res*. 2017 Oct;139:82-92. Available on:  
[Neurodegeneration in diabetic retinopathy: Potential for novel therapies - PubMed \(nih.gov\)](https://pubmed.ncbi.nlm.nih.gov/31811111/)
34. Li J, Manta Paulus Y. Advances in Retinal Laser Therapy. *Int J Ophthalmic Res*. 2018;4(1):259-264. Available on :  
<https://www.ncbi.nlm.nih.gov/pmc/articles/PMC6824197/>
35. N. Kollias A, W. Ulbig M. Diabetic Retinopathy- Early Diagnosis and Effective Treatment. *Dtsch Arztebl Int*. 2010 Feb;107(5):75-84. Available on :  
<https://www.ncbi.nlm.nih.gov/pmc/articles/PMC2828250/>
36. A. Everett L, Manta Paulus Y. Laser Therapy in the Treatment of Diabetic Retinopathy and Diabetic Macular Edema. *Curr Diab Rep*. 2021;21(9):35. Available on : <https://www.ncbi.nlm.nih.gov/pmc/articles/PMC8420141/#CR10>
37. H.Yun S, A.Adelman R. Recent Developments in Laser Treatment of Diabetic Retinopathy. *Middle East Afr J Ophthalmol*. 2015 Apr-Jun;22(2):157-163. Available on : <https://www.ncbi.nlm.nih.gov/pmc/articles/PMC4411611/>

38. Gupta V, Arevalo JF. Surgical management of diabetic retinopathy. Middle East Afr J Ophthalmol. 2013 Oct-Dec;20(4):283-92. Available on :[Surgical management of diabetic retinopathy Gupta V, Arevalo J F - Middle East Afr J Ophthalmol \(meajo.org\)](#)
39. Smiddy WE, Flynn Jr HW, Vitrectomy in the management of diabetic retinopathy, Surv Ophthalmol, 1999 May-Jun;43(6):491-507.  
Available on : [Vitrectomy in the management of diabetic retinopathy - PubMed \(nih.gov\)](#)
40. Zhao M, Sun Y, Jiang Y. Anti-VEGF therapy is not a magic bullet for diabetic retinopathy. Eye (Lond). 2020 Apr;34(4): 609-610. Available on : [Anti-VEGF therapy is not a magic bullet for diabetic retinopathy - PubMed \(nih.gov\)](#)

## 10. BIOGRAPHY

I was born on the 7<sup>th</sup> of December, in 1989, in Marcq-en-Baroeul near Lille. I graduated from high school (Baccalauréat général français, section scientifique) with honors in 2007.

After high school, I was curious and interested in many subjects. After several experiences at university and in the workplace I finally chose the path of medicine and enrolled at the University of Zagreb, School of Medicine, Medical Studies in English. Studying in English was a great challenge and a valuable experience for me ; discovering another country, Croatia, in the European Union was also a great opportunity.

I took courses at the University of Philosophy in Zagreb to perfect my Croatian that I am proud to speak now almost fluently.