

# The use of botulinum toxin in medicine

---

Kralj, Lara

Master's thesis / Diplomski rad

2021

Degree Grantor / Ustanova koja je dodijelila akademski / stručni stupanj: **University of Zagreb, School of Medicine / Sveučilište u Zagrebu, Medicinski fakultet**

Permanent link / Trajna poveznica: <https://um.nsk.hr/um:nbn:hr:105:997611>

Rights / Prava: [In copyright](#)/[Zaštićeno autorskim pravom.](#)

Download date / Datum preuzimanja: **2024-09-27**



Repository / Repozitorij:

[Dr Med - University of Zagreb School of Medicine Digital Repository](#)



UNIVERSITY OF ZAGREB SCHOOL OF MEDICINE

Lara Kralj

# THE USE OF BOTULINUM TOXIN IN MEDICINE

GRADUATE THESIS



Zagreb 2022

This graduate thesis was made at the Department of Plastic, Reconstructive Surgery & Breast surgery, Clinic of Surgery (KBC Zagreb- University Hospital Centre Zagreb) and mentored by dr.sc. Anto Dujmović.

It was submitted for evaluation during the academic year 2021/2022.

## Table of Contents

<b>INTRODUCTION .....</b>	<b>- 5 -</b>
<b>HISTORY .....</b>	<b>- 5 -</b>
<b>PHARMACODYNAMICS.....</b>	<b>- 5 -</b>
<b>TOXICITY &amp; SIDE EFFECTS.....</b>	<b>- 6 -</b>
1. BOTULISM .....	- 6 -
2. BIOTERRORISM .....	- 8 -
<b>TREATING MUSCLE SPASTICITY &amp; OTHER MUSCLE DISORDERS.....</b>	<b>- 9 -</b>
<b>MUSCLE SPASTICITY .....</b>	<b>- 9 -</b>
<b>CEREBRAL PALSY .....</b>	<b>- 9 -</b>
<b>DYSTONIA .....</b>	<b>- 11 -</b>
<b>MIGRAINES &amp; BOTULINUM TOXIN.....</b>	<b>- 12 -</b>
<b>TREATMENT OF HYPERHIDROSIS .....</b>	<b>- 13 -</b>
<b>COSMETIC DERMATOLOGY .....</b>	<b>- 15 -</b>
<b>ANATOMY OF THE HEAD AND NECK .....</b>	<b>- 15 -</b>
I. THE SKULL .....	- 15 -
II. MUSCLES OF FACIAL EXPRESSION.....	- 16 -
III. FACIAL ARTERY.....	- 17 -
IV. FACIAL VEIN .....	- 19 -
V. FACIAL GLANDS.....	- 19 -
VI. NECK MUSCLES .....	- 22 -
VII. ANATOMY OF THE SKIN .....	- 23 -
<b>COSMETIC USAGE OF BOTULINUM BOTOX .....</b>	<b>- 24 -</b>
I. The periorbital area .....	- 24 -
II. The glabella, frontalis, eyebrows and eyelids.....	- 25 -
III. The middle and lower face .....	- 27 -
<b>CONCLUSION .....</b>	<b>- 29 -</b>
<b>ACKNOWLEDGEMENTS.....</b>	<b>- 31 -</b>
<b>REFERENCES .....</b>	<b>- 32 -</b>
<b>BIOGRAPHY.....</b>	<b>- 35 -</b>

Figure 1: Anterior view of the skull (from atlas of human anatomy, ed 7, Plate 11)..... - 15 -

Figure 2: Muscles of facial expression (from atlas of human anatomy, ed7, plate 31.)..... - 16 -

Figure 3: arterial supply of face. Netter atlas of anatom ..... - 18 -

Figure 4: dissected human head (wikipedia) ..... - 19 -

Figure 5: Salivary glands, Wikipedia, Blausen.com staff (2014)..... - 20 -

Figure 6: wikipedia, Anatomy of the human body - Gray's anatomy (20th edition)..... - 22 -

Figure 7: "crow's feet" wrinkles (Injection treatments in Cosmetic surgery, Benjamin Ascher)  
..... - 25 -

Figure 8: before and after treatment with Botox ..... - 26 -

Figure 9: injection points for the upper lip (injection treatments in cosmetic surgery, B.  
Ascher) ..... - 27 -

Figure 10: Before and after result of treatment with Botox ..... - 28 -

## **Abstract**

### ***The use of botulinum toxin in medicine***

***Lara Kralj***

Neurotoxin made by a bacterium called *Clostridium botulinum* is an important medical substance. It is so versatile, that it can be used as a lethal weapon and in modern medicine is even gaining its popularity in the aesthetic procedures. Although it was first recognized as early as 1793 in Germany, it was not until 1989 that surgeons found its beneficial usages in medicine. The so called »miracle poison« exists in eight different exotoxins (A,B,C1,C2,D,E,F,G) – the most potent being type A. All serotypes work by a similar mechanism in interfering with the neural transmission by blocking the release of the neurotransmitter acetylcholine – causing muscle paralysis. Botulinum toxin, or »botox«, takes about 24-72 hours to take effect and lasts nearly 8-12 weeks. Most common usages of botulinum toxin in medicine are to treat cervical dystonia, hyperhidrosis, chronic migraine, bladder dysfunction, eye twitching, cross eyes, eyelid spasms, foot pain, stomach issues, cosmetic correction of wrinkles, etc...

Although the current usage of botox is primarily medical, it can also cause a serious poisoning called botulism, in fact this is also how it was first isolated from poisoned food. *Clostridium botulinum* bacteria produces spores and thrives in conditions where there is no oxygen, therefore most common sources of poisoning are home-canned foods, contaminated soil, honey and corn syrup. In the times of world wars, a common infection was botulism entering open wounds, whereas now it is most commonly spread through ingestion of spore contaminated foods. Although most cases of botulism aren't life threatening, especially in the modern times, sometimes recovery requires mechanical ventilation and weeks to months of time.

## **Sažetak**

### ***Upotreba botulinum toksina u medicini***

***Lara Kralj***

Neurotoksin kojeg proizvodi bakterija *Clostridium botulinum* je važna medicinska supstanca. Može se koristiti kao smrtonosno oružje, u modernoj medicini, a svoju popularnost dobiva čak i u estetskoj medicini. Iako je prvi put otkriven još 1793. godine u Njemačkoj, kirurzi su tek 1989. pronašli njegovu korisnu primjenu u medicini. Takozvani »čudotvorni otrov« postoji u osam različitih egzotoksina (A,B,C1,C2,D,E,F,G) – najsnažniji je tip A. Svi serotipovi djeluju sličnim mehanizmom u ometanju neuronskog prijenosa blokiranjem oslobađanja neurotransmitera acetilkolina – uzrokujući paralizu mišića. Botulinskom toksinu ili »botoksu« potrebno je oko 24-72 sata do početka djelovanja i traje gotovo 8-12 tjedana. Najčešća primjena botulinum toksina u medicini je za liječenje cervikalne distonije, hiperhidroze, kronične migrene, disfunkcije mokraćnog mjehura, trzanja očiju, grčeva očnih kapaka, bolova u stopalima, želučanih problema, kozmetičke korekcije bora, itd...

Iako je trenutna uporaba botoxa prvenstveno medicinska, on može uzrokovati i ozbiljno trovanje zvano botulizam, dapače i prvi put je izoliran iz otrovane hrane. Bakterija *Clostridium botulinum* stvara spore i uspijeva u uvjetima u kojima nema kisika, stoga su najčešći izvori trovanja domaća konzervirana hrana, kontaminirana zemlja, med i kukuruzni sirup. U vrijeme svjetskih ratova uobičajena infekcija je bio botulizam koji je ušao u otvorene rane, a sada se najčešće širi unosom hrane kontaminirane sporama. Iako većina slučajeva botulizma nije opasna za život, osobito u moderno doba, ponekad je za oporavak potrebna mehanička ventilacija i duž vremenski period (više tjedana, ponekad i mjeseci).

## INTRODUCTION

### HISTORY

Botulinum toxin has a very colorful and chequered history, going from a poison to remedy through the years. Outbreaks of botulism have been described throughout history. In general, they have been related to poorly preserved food (sausages, ham, fish) or home-canned food. First time documented as late as the 18th century, botulinum toxin was recorded due to its poisonous effect, causing many deaths to people eating meat and blood sausages in the kingdom of Wuttemberg (South Western Germany). Botulism as a food borne disease was first described by a medical officer, also a well known poet, Justinus Kerner between 1817 and 1822. Kerner studied patients with botulism, their autopsies and also did experiments by inoculating extracts of infected tissues into animals. He never managed to isolate the toxin, but he did describe how it acted by disturbing the peripheral and autonomic nervous signal transmission, therefore the disease was then called the »Kerner's disease«. Not long after, in 1895 – also because of a botulism outbreak from ingestion of smoked ham, the bacteria producing the toxin was discovered by Emile Pierre van Ermengem (profesor of bacteriology at the University of Ghent) to be *Clostridium botulinum*. This bacteria got its name due to its association with sausages – latin word for sausage = botulus. It took many years for the therapeutic use of botulinum toxin to be reported, and that is when Alan Scott, an ophthalmologist, described its use in treatment of strabismus in 1973 – he is known as the father of modern »botox«.

In 1989, FDA approved botulinum toxin A for the treatment of blepharospasm and in 1990s for cerebral spasticity. (1,2)

### PHARMACODYNAMICS

The botulinum neurotoxins are divided into seven serotypes – from A to G. They are produced as protein complexes that besides the neurotoxin also contain non-toxin hemagglutinin and non-hemagglutinin proteins. Only types A and B are currently available commercially, some of the others being tried in humans only on an experimental basis. Botulinum toxin as a drug is considered as a long-term, long-lasting but most importantly fully reversible and easily controllable substance. Even in large dosages it is considered one



of the safer drugs used for cosmetic procedures, muscle relaxation, exocrine gland secretion suppression (excessive sweating) and analgesia. To understand the mechanism of action we must first revise how normal muscle contraction occurs. When an action potential comes down to the nerve ending vesicles filled with acetylcholine fuse with the nerve membrane with the help of SNARE proteins and exit in to the neuromuscular junction via exocytosis. Acetylcholine then bind to the receptors on the muscle fibers and make muscle contraction possible. Botulinum toxin is taken in by the cholinergic nerve endings, but not by the adrenergic nerve endings. When inside of the nerve, botulinum toxin binds to the SNARE protein and inhibits its function – consequently inhibiting nerve conduction and muscle contraction. In conclusion the neurotransmission fails due to dysfunction of pre-synaptic membrane exocytosis process. The maximum effect of therapeutic doses for muscle paralysis occur four to seven days after the administration. There is no specific data on the half-life of botulinum toxin in humans, but the elimination half-life for non-metabolized toxin in blood and serum ranges from 230 to 260 minutes in studies with rats and mice. The effect of botox lasts anywhere between two to six months, in average three to four months. As the body creates new extra junctional synapses the effect of botox fades over time. (3,4)

## TOXICITY & SIDE EFFECTS

### 1. BOTULISM

Botulism, although very rare in modern times, is a serious disease that causes paralysis and can be life threatening.

There are different types of botulism:

- food born botulism,
- infant botulism,
- wound botulism,
- inhalation botulism,
- adult intestinal toxemia
- iatrogenic botulism
- 

Food born botulism is by far the most common type and occurs due to incorrect canning of fruits and vegetables. When foods are improperly canned or fermented the spores of the Clostridium bacteria can produce the potent neurotoxin which enters the body and causes

neurological symptoms as well as some digestive symptoms like vomiting, diarrhea, stomach pain and nausea. After the initial intoxication, the common neurological problems start – muscle weakness, vision problems – blurry vision, difficulty breathing and other symptoms that result from inhibiting nerve conduction. The symptoms that can help differentiate botulism from other neurological diseases are flaccid, descending paralysis that is symmetrical and affects cranial and peripheral nerves. Most deaths occur due to paralysis of the so-called breathing muscles. Although the symptoms and signs are significant and life threatening the diagnosis of food born botulism remains a challenge and misdiagnosis is still common. The symptoms usually start 18 to 36 hours after eating a contaminated food. Toxin type A is the one that causes the most severe symptoms, whereas type B is milder. Treatment is most successful when a diagnosis is made fast (ideally in the first 24 hours), since the antitoxin doesn't reverse the existing paralysis, but only neutralizes the molecules of neurotoxin that have not yet bound to nerve endings. (5)

Infant botulism or so called “floppy baby syndrome” is also an intestinal toxemia caused by *C.botulinum* (or related species). It occurs when a baby swallows a clostridium spore containing neurotoxins – usually from food like honey or even soil. Infant botulism also presents with descending paralysis but has some additional signs specific for this age group – constipation, poor feeding, ptosis, diminished suck/gag reflexes, weak cry, etc. Diagnosis is made on high suspicion and the antidote should be administered as soon as possible; doctors usually don't wait for test results. (6,7)

Wound botulism presents with the same symptoms as food-born botulism, excluding the gastrointestinal symptoms of course. The disease was commonly known to present in soldiers during war where spores would enter their wounds of traumatic battlefield injuries, nowadays it is mostly common in intravenous drug users – especially those using black tar heroin. Incubation period is usually 7-14 days, although with IV drug users it is very unpredictable due to multiple sites of injections and also the fact that they will inject multiple times per day. Treatment is the same as with all other botulisms – antitoxin and supportive therapy. (8,9)

Inhalation botulism is extremely rare and results from intentional or accidental inhalation of botulinum toxin. So far there has only been around 10 cases reported and most of them have been accidental – laboratory workers and drug users (after abuse of intranasal cocaine). When inhaled the toxin is absorbed through the nasal mucosa in to the blood stream and distributed

through the body. Clinical picture is similar to other forms of botulism – cranial nerve palsies, descending and symmetric flaccid paralysis of voluntary muscles which can lead to death by respiratory compromise. The lethal dose is 3 times larger than that of the foodborne variety – 2 nanograms of botulinum toxin per kilogram of body weight.

Adult intestinal toxemia affects adults and older children. Its clinical picture is typical for botulism poisoning with symmetrical descending paralysis, but compared to food borne botulism, intestinal toxemia has a much more gradual onset. It is important to understand that in adult intestinal toxemia the botulinum toxin is not ingested, but produced “in situ” by *C. Botulinum* (toxin type A, B, C) , *C. Butyricum* (type E) or *C. Baratii* (type F and C). Colonization, and hence in situ production of toxins is associated with anatomical abnormalities of the gastrointestinal tract or disturbance of the protective endogenous microflora (by antibiotics) that lines the intestines. (10)

Iatrogenic botulism is a modern man-made form of botulism, that occurs as an adverse effect after using botulin toxin for cosmetic or therapeutic use. Since doses used for esthetic treatment are low, they rarely cause iatrogenic botulism. The most common cause of man-made botulism is the treatment of lower limb spasticity, which requires large dosages of botulinum toxin. As of 2008 there have been 180 cases reported to the FDA. (11)

## 2. BIOTERRORISM

Botulinum neurotoxin possesses an extremely serious threat as a bioweapon, due to its potency, lethality, availability and due to the fact that treatment is prolonged and intense. If dispersed and inhaled correctly, one gram of crystalline toxin can kill more than one million people. To be used as a weapon, the toxin must be either disseminated via aerosol or by contamination of water/food supplies. The toxicity of botulinum toxin has been known since the end of 19<sup>th</sup> century (the first attempts to weaponize the toxin were made during the WW2).(12–14)

## TREATING MUSCLE SPASTICITY & OTHER MUSCLE DISORDERS

### MUSCLE SPASTICITY

Spasticity is a movement disorder caused by chronic central nervous system disorders in various diseases and injuries of the brain and spinal cord. Problems with severe chronic diseases and spinal cord injuries are not just related to loss of motor skills. Uncontrolled and excessive neuromuscular activity in the form of spasticity and neuropathic pain, which can be severe and persistent, is often a very disturbing consequence of neurological failure. also disorders of the internal organs, in particular the intestines, bladder...

Spasticity or muscle contraction further hinders the remaining intentional mobility of weakened muscles. It also hinders the movement that is necessary to maintain the flexibility of tissues and prevent their permanent shrinkage.

Spasticity is mostly more severe and more disruptive in spinal cord injuries than in brain disorders. Since botox is considered a non-invasive treatment it is commonly used together with physical and occupational therapy. Injections of botulinum toxin are used to paralyze the pathologically contracted muscle and will have an effect for up to 16 weeks. The main issue with botox is that new nerve endings will soon be introduced and no longer inhibited, therefore the number of injections is limited. (15,16)

### CEREBRAL PALSY

Cerebral palsy is a disorder of movement, posture or coordination resulting from non-progressive damage or damage to the immature brain. Cerebral palsy covers a range of different conditions, from the most severe to the mild forms, and can affect an individual in a variety of ways. This means that each individual with cerebral palsy is special - an individual. The basic feature of cerebral palsy is the inability to fully control motor function, especially muscle control and coordination of movements. "Cerebral" means that the cause of the problem lies in the brain and not in the muscles themselves, as they first thought. Paralysis, on the other hand, means having problems with movement and posture, or poorer motor control. The injury affects one or more of the following areas, depending on which part of the brain is damaged / impaired: muscle tightness or spasticity, involuntary movements, difficulty moving and mobility, swallowing problems and speech problems. (17)

In addition to cerebral palsy, the following symptoms may occur: problems with perception / sensation and perception, vision, hearing or speech problems, epileptic seizures, mental

retardation or learning difficulties. In severe cases, there may be problems with feeding and excretion, breathing problems (due to seizures) and bedsores. A common problem with cerebral palsy is also tendon tightness in the back of the leg, which makes it difficult to stretch the legs. Botulinum toxin injection alleviate this problem, the leg is no longer as tight, walking improves, as does sitting and transfers. Botox can also be used to improve the effectiveness of the muscles in the hips and groin (even here, children with a spastic form of cerebral palsy may have problems). Spasticity in this area affects an individual's overall mobility as he pulls his legs together (in scissors). In spasticity in the upper extremities, BTA injection helps to reduce the tone in the elbow, wrist and fingers. The child becomes more independent in self-care, personal hygiene, and improves squeezing, gripping, and releasing movements. In addition to the above, this treatment may reduce the development of secondary problems. Spasticity can cause an imbalance in joint muscle tone, which not only affects motor function but can also lead to contractures - permanent shortening of muscles and tendons, resulting in bone irregularities and joint instability (such as hip dislocation). In some cases, surgery is required. The possibility of recurrence of problems with growing up must be ruled out. BTA injection after surgery increases the elasticity of the muscles in the joints and thus reduces the possibility of joint damage and the need for re-operation. The use of BTA thus has the effect of reducing pain, improving posture, controlling tremor and cramps and salivation. Sometimes this even reduces the need for orthopedic surgery. BTA reduces postoperative pain and shortens hospital stays. Some doctors use BTA during the operation itself, thus reducing painful post-operative spasms and protecting the soft tissue from involuntary movements until the end of treatment. (18)

Many teenagers and adults with cerebral palsy report a high level of satisfaction with cosmetic improvements that occur after using BTA, as it contributes to a better appearance and comfort in reducing tone and spasms, even in cases where there have been no major changes in functionality and flexibility.

A common problem faced by people with cerebral palsy is fatigue. Fatigue causes increased effort required to move. After movement gradually becomes easier after BTA treatment, reduced energy expenditure is shown as a result. (18–20)

## DYSTONIA

Patients with dystonia have involuntary muscle contractions or cramps that cause twisting or twitching of joints and unusual postures. Dystonia can affect any part of the body. It most often covers a single part. The most common types of dystonia are:

- muscle spasms and contractions involve the neck muscles, we speak of cervical dystonia or torticollis. Unusual postures and tilts of the head may occur, which may be accompanied by inadvertent twitching or shaking joints.
- Facial muscle spasms cause excessive squinting or eye spasms called blepharospasm. If they are accompanied by muscle spasms of the lower half of the face, they are called Meige's syndrome.
- When the muscles of the tongue and jaw are also affected, we speak of oromandibular dystonia.
- In spasmodic dysphonia, patients have a sighing and strained voice.
- Other more commonly covered body parts are the arms and legs. Hand dystonia often occurs with prolonged repetition of specific activities, such as playing a musical instrument. These are t.i. work-specific dystonias.
- In rare cases, several parts of the body are covered at the same time. It most often appears early in childhood, progresses and covers several areas. Then we talk about generalized dystonia

Dystonia can be caused by several different factors. Some patients have dystonia because they have inherited the gene that causes it. In some, dystonia is the result of head injury, inflammation or infection, exposure to chemicals or medications. Dystonia can also occur as a result of frequent repetition of the same movements, such as writing (writer's cramp) or playing a musical instrument (musician's cramp). Nevertheless, in most cases, the cause of dystonia remains unexplained. Botulinum toxin injection directly targets the muscles involved in dystonia. The toxin has an effect on the nerves in the area of their connection with the muscle, blocking the release of the chemical transporter acetylcholine that is responsible for the formation of muscle contraction. The result is the suppression of a signal that normally tells the muscle to contract, leading to a reduction or elimination of muscle spasms. Botulinum toxin is mainly used in the treatment of focal dystonia, as each muscle involved in dystonia must be injected individually and there is a limit to the total permissible dose of toxin applicable in one treatment. (21–24)

## MIGRAINES & BOTULINUM TOXIN

Migraine is a type of headache in which the pain is very severe and is accompanied by other signs such as nausea and sensitivity to light and sound. Migraine is one of the most common forms of headache worldwide. The World Health Organization (WHO) ranks it among the third most common health problems and the second most common neurological disorder that impairs the ability to work, effects daily activities and the quality of life. Migraines are common, affecting 1 in 4 women and 1 in 12 men. Migraines are believed to be more common in women, mainly due to hormonal influences. For example, some find that they have more frequent migraine attacks around the time of menstruation. However, this connection has not been scientifically proven. Migraines can occur later in life, but more often in childhood or in young adults. About 90% of people who have it first have a migraine before they turn 40. There are two types of migraine - with and without aura. In migraine with aura, the headache follows the symptoms called aura (stiffness in neck, speech problems, loss of consciousness, coordination problems, vomiting...). Aura symptoms usually begin 15 minutes to 1 hour before the onset of the headache. Some people feel an aura only with a mild headache. In migraine without aura, the person does not perceive symptoms of aura. Some people suffer from frequent migraine attacks, for example several times a week, while others only occasionally. It is possible that years pass between individual migraine attacks. (25)

Botox is approved by the FDA for treatment for chronic migraines, these are headaches lasting 15 days or more per month. Botulinum toxin is used as an injection in to the pain fibers involved in the migraine. When injected it enters the nerve endings and blocks release of chemicals involved in pain transmission – prevents activation of pain networks in brain, but its exact function in treating chronic migraines is still not completely understood. The treatment must be done multiple times in order for the patients to see any effect. Guidelines recommend injections in a series between 31-39 small injections under the skin or into the muscles in and around the head of the forehead, above the ears and also into the neck. Botox is injected every 12 weeks until the chronic migraine changes in to an episodic migraine for three months in a row – with a significant improvement in quality of life. (26)

## TREATMENT OF HYPERHIDROSIS

Sweating is a normal body function. We all sweat in hot weather or during physical activity such as playing sports. This creates a salty, clear liquid (99% water, 1% salt) that is released through the eccrine sweat glands to fulfill an important physical function of cooling the body. The sweat glands secrete a path through the pores. We also sweat more when we are overwhelmed or nervous: in addition to the eccrine sweat glands, the apocrine sweat glands are also activated and release a relatively small amount of sweat, which has a different composition - it contains a lot of protein and lipids. When the apocrine pathway is metabolized by bacteria, an unpleasant body odor occurs. Most people have experience with excessive and unpredictable sweating, for example after exercise, in hot weather, etc. In these situations, the body generates and releases more moisture. However, if this also happens in circumstances that do not normally cause sweating (ie at moderate temperatures or when the body is at rest), this condition is called hyperhidrosis. People with hyperhidrosis can sweat excessively and sometimes even a change in external circumstances does not help, e.g. avoiding the sun. Their sweat glands are simply overactive.

The term hyperhidrosis is used when heavy sweating exceeds normal limits. There are two main types of hyperhidrosis. If heavy sweating affects certain parts of the body, such as palms, feet, parts of the face or armpits, it is primary (idiopathic) or focal hyperhidrosis. Although heavy sweating is not unhealthy, it can be a symptom of a medical condition. Sometimes even serious. In this case, it is called secondary hyperhidrosis, which means that heavy sweating is a side effect of an existing medical condition or has a hormonal cause (for example, pregnancy or menopause). People suffering from primary or secondary hyperhidrosis may experience embarrassment, strain, and sometimes even exhaustion due to their condition. Heavy sweating can thus have serious psychological consequences and effects, such as depression and anxiety due to embarrassment in society.

There is no exact definition of excessive sweating based on the "amount of sweat". If heavy sweating affects daily life and normal activities, it can be hyperhidrosis.

The following description may help with the diagnosis:

- Primary hyperhidrosis is very likely if excessive sweating is present for more than six months. It mostly appears under the armpits, on the palms, soles or parts of the face. Sweating is quite symmetrical, not present at night and in most cases occurs at least once a week. He has a genetic predisposition and starts before the age of 25.



- In the case of primary or focal hyperhidrosis (only certain parts of the body are affected), the affected parts are as follows: armpits (axillary hyperhidrosis), back, palms (palm hyperhidrosis), face (facial hyperhidrosis), soles, chest, the back of the knees.

There is an unusually high concentration of eccrine glands in these areas, which are responsible for sweating. An outbreak of focal hyperhidrosis can occur in several parts of the body at the same time.

Research has shown that in the case of primary or focal hyperhidrosis, the part of the brain that regulates the sweating process sends signals to the eccrine glands even when there is no need to cool the body. This disorder of the autonomic nervous system causes increased sweat formation for no apparent reason and burdens the affected with unpleasant effects. Primary or focal hyperhidrosis is thought to be genetically determined: the condition is inherited within the family (30 to 50% of people have a family history). Focal hyperhidrosis affects only healthy people at the onset of puberty and usually peaks in their twenties or thirties.

The causes of secondary hyperhidrosis are different. They can be: pregnancy, menopause, anxiety, drug and alcohol abuse, heart disease, diabetes, respiratory failure, obesity, gout, increased thyroid function (hyperthyroidism), certain medicines, peripheral nerve damage and Parkinson's disease. Botox works by blocking the neurotransmitter (acetylcholine) that stimulates sweat glands, thereby essentially paralyzing it. In this way, we reduce excessive sweating locally. Studies have shown that the use of Botox to reduce excessive sweating under the armpits, palms, feet, head and face, and other relatively small body areas, e.g. under the breasts, very successful and safe. Botox itself does not cure hyperhidrosis, but gradually eliminates the symptoms that return later, and then the treatment must be repeated. Sweating under the armpits is reduced by 82-87 percent, the results begin to show two to four days after injection, and the maximum effect is reached after fourteen days. The effect lasts four to twelve months, according to some studies up to fourteen months. After cessation of the effect, the therapy can be repeated. When using Botox on the palms, transient pain and less strength in the hands may occur. The use of Botox to treat hyperhidrosis of the feet is less effective; according to some studies, 50 percent of patients are said to be dissatisfied with the results and the pain is also more frequent and severe. On the head and face, Botox therapy is successful in treating hyperhidrosis. However, asymmetry on the face may occur, which is transient and is treated with additional Botox injections. Although thermoregulation is very important for the human body, the treatment of primary hyperhidrosis is safe. Under the armpits is less than two percent of the sweat glands of all on the body, and when we block

them, e.g. with Botox, it does not affect thermoregulation, so the fear of overheating the body is unnecessary. (4,4,27–29)

## COSMETIC DERMATOLOGY

### ANATOMY OF THE HEAD AND NECK

The head and neck area are anatomically very complex parts of the body, due to the density and complexity of its structures. The head can be divided into interconnected parts as follows: cranium, orbits, nasal cavities with paranasal sinuses, ears and oral cavity. In terms of the neck one can divide its anatomy into compartments which go from superficial to deep – musculofascial, visceral, neurovascular and paravertebral.

#### I. THE SKULL

In total the skull is built up out of 22 bones – 8 form the cranium, 14 the viscerocranium and 7 associated bones (auditory ossicles and the hyoid bone).

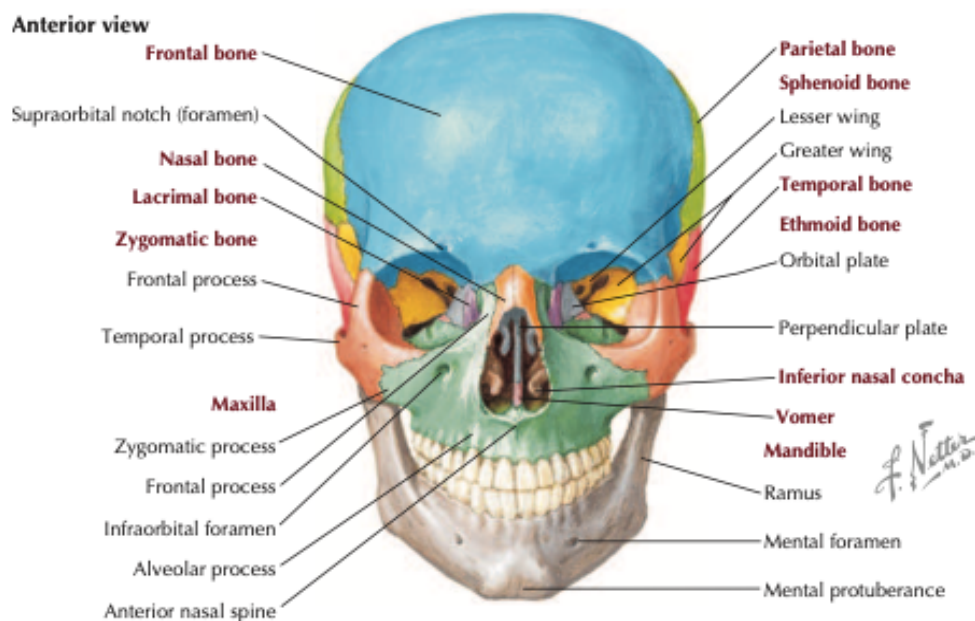


Figure 1: Anterior view of the skull (from atlas of human anatomy, ed 7, Plate 11) (30)

The frontal bone forms the forehead and contains frontal sinuses, inferiorly it connects to the nasal bone, lacrimal bone, zygomatic bone and the maxilla. The jaw encompasses the maxilla that is a paired bone with 16 maxillary teeth and the mandible which forms the lower jaw and contains 16 mandibular teeth. The superolateral portion of the skull is made of the parietal bone, which connects to the temporal and sphenoid bones inferiorly. Occipital bone is the most posterior bone of the skull.

## II. MUSCLES OF FACIAL EXPRESSION

All muscles of facial expression are embryologically derived from the brachial arches which means they are innervated by the cranial nerves, even though they are histologically skeletal muscles. The seventh cranial nerve (facial nerve) innervates all muscles of facial expression with its five terminal motor branches: temporal, zygomatic, buccal, marginal mandibular and cervical branch. Whilst the facial nerve innervates the motor function of facial muscles, the trigeminal nerve (fifth cranial nerve) is responsible for sensory innervation and is divided in to three divisions – ophthalmic, maxillary and mandibular.

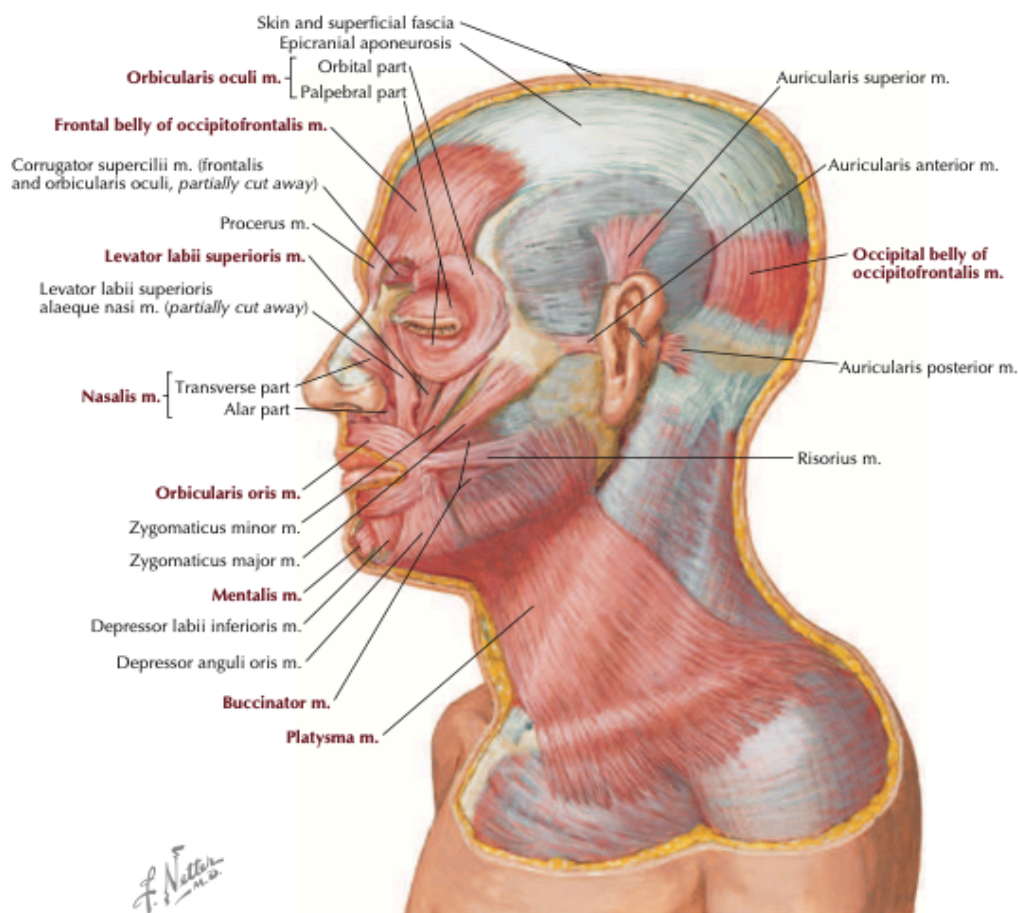


Figure 2: Muscles of facial expression (from atlas of human anatomy, ed7, plate 31. (30))

Elevation of eyebrows and forehead (producing the wrinkles on the forehead) is done by the frontal belly of occipitofrontalis muscle which originates on the epicranial aponeurosis and inserts at the skin of the forehead. Orbicularis oculi closes the eyelids and is responsible for blinking. The nasal cartilages are the point of insertion of nasalis muscle which pulls the ala of nose towards its septum to compress nasal openings. Closing and protruding the lips

(whisteling, pouting, etc) is produced by orbicularis oris, originating from the median plane of maxilla superiorly and mandible inferiorly. Levator labii superioris elevates lips, dilates the nostrils and raises angle of mouth, being inserted in to the skin of upper lip and alar cartilage. The tension of lower face and depression of mandible is produced by the platysma muscle which also connects the neck and face – origin being the superficial fascia of deltoid and pectoral region and insertion the mandible, skin of cheek, angle of mouth and the orbicularis oris muscle. One of the smaller muscles, the mentalis muscle, is responsible for wrinkling of the chin, as well as protrusion of lower lip. Last but not least, the deep buccinator muscles which originate from the mandible and alveolar processes is the one that presses cheeks inwards towards the molar teeth and aids in chewing, as well as expelling air. The buccinator muscle is the only muscle of facial expression to be surrounded by a fascia. (31–33)

### III. FACIAL ARTERY

The facial muscles and skin are supplied with oxygen and nutrients by the facial artery, one of the eight branches of the external carotid artery. Blood supply of the head and face starts at the aortic arch where the common carotid arteries branch out of the aortic arch (the left one) or the innominate artery (the right one). The common carotid artery bifurcates at the level of the thyroid cartilage into the external and internal carotid arteries. External carotid artery travels laterally on the neck within the carotid sheath, which is behind the sternocleidomastoid muscle. It is the only branch of the common carotid artery that also supplies the neck and external structures of the head and face.

The eight branches of the external carotid artery are:

1. Superior thyroid artery
2. Ascending pharyngeal artery
3. Lingual artery
4. Occipital artery
5. Posterior auricular artery
6. Maxillary artery
7. Superficial temporal artery

Just above where the lingual artery arises from the external carotid, the facial artery emerges (sometimes from a common trunk with the lingual artery). After branching off, the facial artery also called the external maxillary artery, travels anterosuperiorly under the digastric and stylohyoid muscles and enters the face by curving around the inferior border of the mandible. From there it ascends along the angle of the mouth and goes under the zygomaticus major and risorius muscles. It terminates at the medial angle of the orbit, after ascending along the lateral side of the nose.

Branches of the facial artery are:

1. Ascending palatine
2. Submental
3. Inferior labial
4. Superior labial
5. Angular arteries
6. Tonsillar arteries
7. Glandular branches

As said, the facial artery supplies the whole face (muscles, skin), from the inferior mandibular border, anterior to the masseter muscle and to the medial corner of the orbit. Besides facial muscles and skin, it also supplies the soft palate, palatine tonsils, pharyngotympanic tube and the submandibular gland.

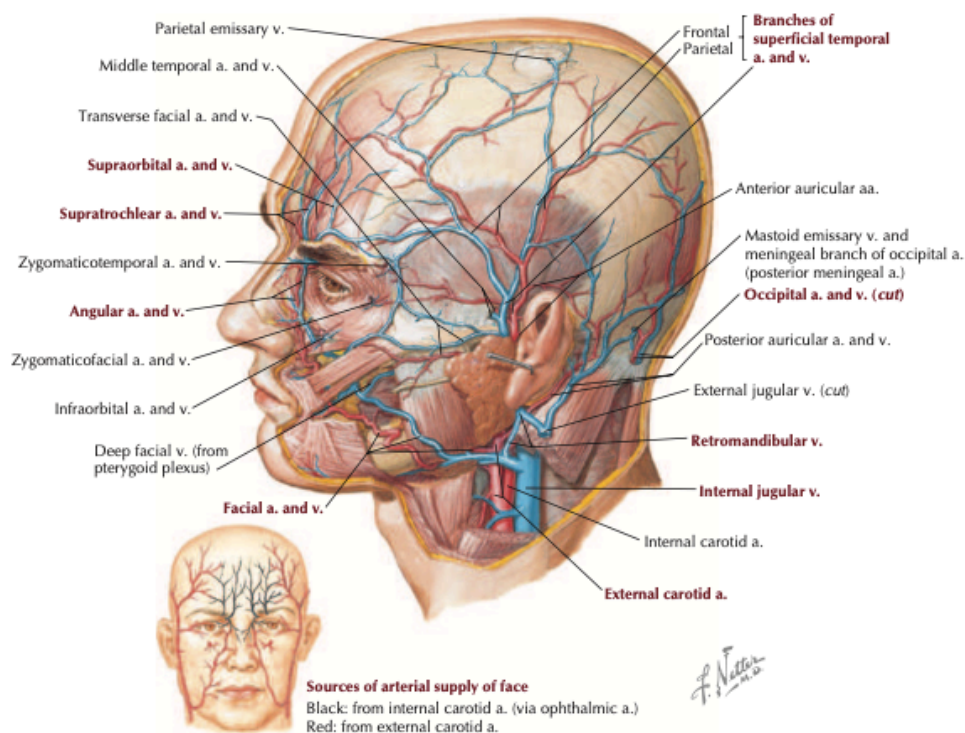


Figure 3: arterial supply of face. Netter atlas of anatom (30)

#### IV. FACIAL VEIN

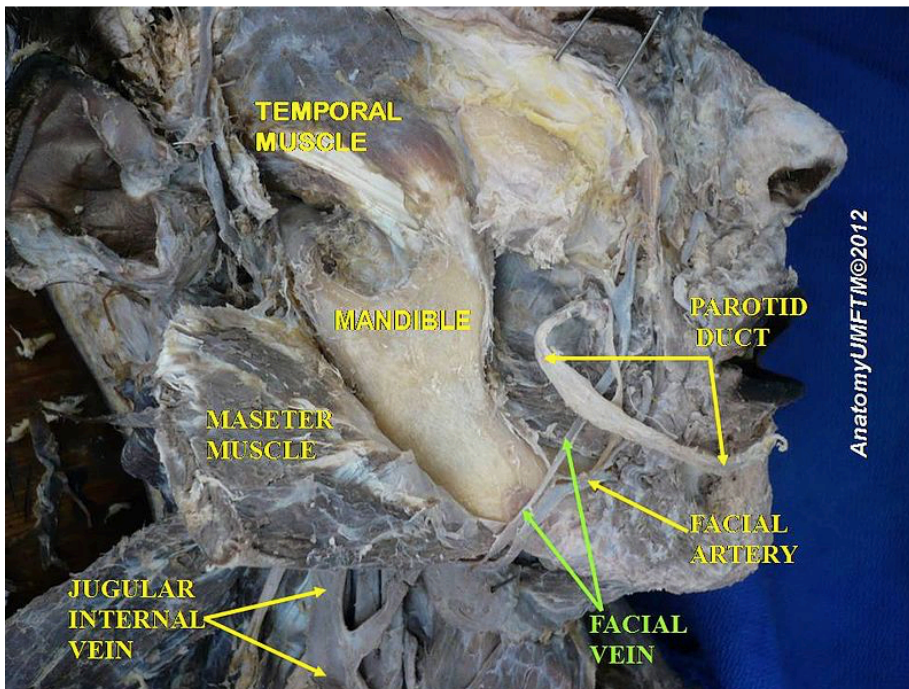


Figure 4: dissected human head (wikipedia)

The facial vein, also called the anterior facial vein is the main vessel draining the face. Due to its course through the face and also the neck it can be divided into facial and cervical segments. From its origin at the root of the nose (angular vein) it runs inferiorly and posteriorly with an oblique course, under the zygomaticus major and zygomatic head of the quadratus labii superior muscle. It crosses the mandible superficially, where it receives many branches from the superficial structures and then emerges in the neck. After collecting additional branches in the neck it unites with the anterior branch of the retromandibular vein, which forms the common facial vein. The final destination of the facial vein is the internal jugular vein.

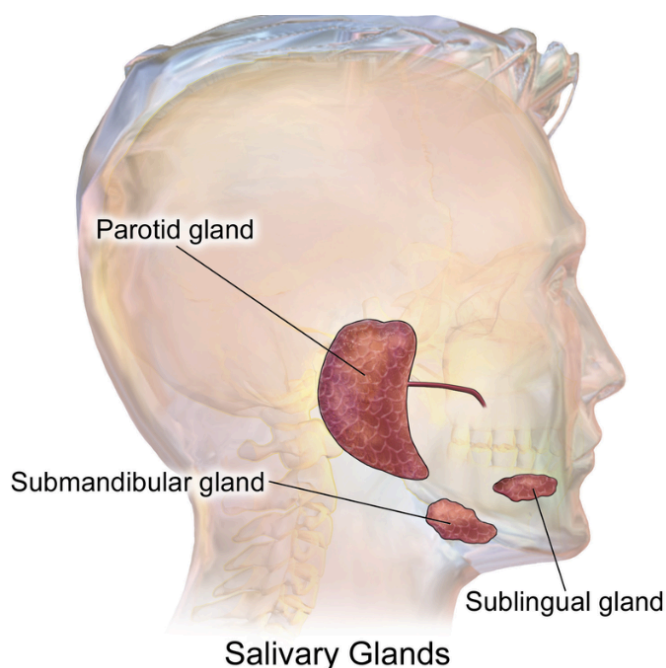
#### V. FACIAL GLANDS

##### 1) Salivary glands

Three large paired salivary glands (parotid - parotid, submandibular - submandibular and sublingual - sublingual) and hundreds of small salivary glands, which are distributed along the mucous membrane of the oral cavity, ensure proper salivation. They excrete 0.5 to 1.5 liters of saliva daily.

Saliva has many functions:

- maintains the appropriate pH in the oral cavity, thus protecting teeth from caries;
- mucins in saliva take care of its viscoelasticity and protect teeth and mucous membranes;
- allows the formation of a protective shell (pellicle) on the teeth, which protects them from demineralization;
- lactoferrin, antimicrobial peptides and immunoglobulins A protect against bacteria;
- accelerates the healing of wounds in the oral cavity;
- enzymes begin to break down food;
- allows the melting of substances that can be detected by the taste buds.



*Figure 5: Salivary glands, Wikipedia, Blausen.com staff (2014)*

The biggest salivary gland is the bilateral parotid gland. It is positioned in the deep parotid region bordering superiorly to the zygomatic arch, inferiorly to the mandible, anteriorly to the masseter muscle and posteriorly to the external ear and sternocleidomastoid. The gland produces serous saliva rich in enzymes that travels to the oral cavity through the Stensen duct. It has an important anatomical relationship with cranial nerve VII (facial nerve), because this nerve gives rise to five terminal branches within the gland itself. It is also important to mention that the external carotid artery travels superiorly through the parotid gland and divides into the maxillary artery and the superficial temporal artery on its exit.

At the anterior part of the submandibular triangle lies the submandibular gland, producing serous and mucous salivary secretions. Superiorly its boundary is the mandible, anteriorly the anterior belly of the digastric muscle and posteriorly the posterior belly of the digastric muscle. The secretions from the submandibular gland travel to the mouth via Warthon's duct which opens as 1-3 orifices on a sublingual caruncle at the base of the lingual frenulum bilaterally. Warthon's duct and the submandibular gland share an intimate anatomical connection with three important nerves – lingual, hypoglossal and marginal mandibular branch of the facial nerve.

The smallest of the three salivary glands is the paired sublingual gland. It only contributes 3-5% of the total salivary volume and produces mainly mucous like secretions. The sublingual glands both lie on the floor of the mouth under the tongue. They are laterally bordered by the mandible and medially by the genioglossus muscle, the almond shaped glands form the so called sublingual fossa on the medial surface of the mandible. The sublingual glands attach together in a »horseshoes« shape around the lingual frenulum.

## 2) Lacrimal glands

Lacrimal glands are paired serous type exocrine glands that produce lacrimal fluid and secrete it onto the conjunctiva and cornea of the eye. The gland is located in the superolateral part of the orbit and lies anteriorly within the lacrimal fossa, which is an anatomical depression in the frontal bone. It is a very small gland, measuring around 2cm in length and is divided into the orbital part and the palpebral part. Its structure is lobular – formed by multiple acini, which produce the lacrimal fluid. The fluid produced by the lacrimal gland is excreted via ducts which empty into the superior conjunctival fornix.



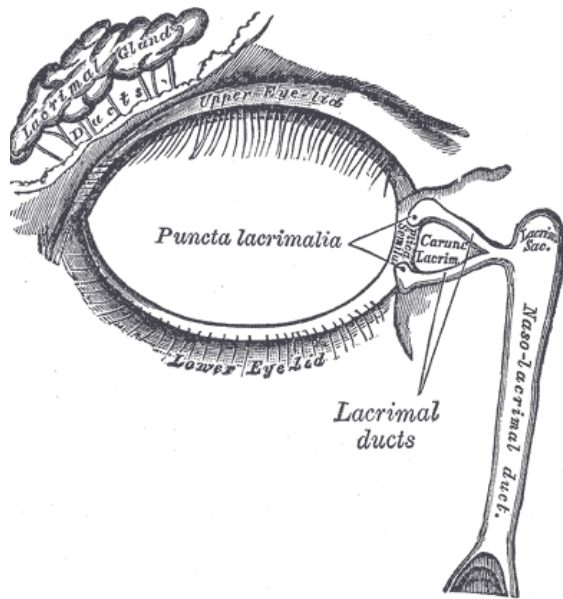


Figure 6: wikipedia, *Anatomy of the human body - Gray's anatomy (20th edition)*(34)

### 3) Nasal gland

These glands are located in the respiratory portion of the nasal mucous membrane and are of seromucous type. There are three major subtypes – the anterior serous glands, seromucous glands and the bowman glands. Their main purpose is to keep the nasal mucosa moisturized and to aid the olfactory system with the sensation of smell.

### 4) Anterior lingual gland

Also called the apical glands, placed near the tip of the tongue on each side of the frenulum. The bilateral glands are covered in muscle fibres derived from the styloglossus muscle and the inferior longitudinal muscle. They are seromucous in nature and findings suggest they secrete a lipase that eventually helps with dietary lipid digestion.

## VI. NECK MUSCLES

The neck is covered in a large number of muscles, responsible for the movement of the head and neck. According to their location they can be divided in to anterior, posterior and lateral neck muscles.

### 1) Anterior neck muscles

Covering the anterior part of the neck, these muscles can be further divided in to three subgroups – superficial (platysma, sternocleidomastoid), suprahyoid (digastric,

mylohyoid, geniohyoid, stylohyoid) and infrahyoid muscles (sternohyoid, omohyoid, sternothyroid, thyrohyoid). The platysma is a sheet like muscle lying within subcutaneous tissue of the anterior neck, it inserts in to the skin of the lower face. It is the main muscle of the neck with a function in facial expression – it pulls the corners of the mouth inferiorly expressing sadness.

## 2) Lateral neck muscles

Also called the lateral vertebral muscles, pass along the lateral sides of the neck and includes the group of scalene muscles – anterior, middle and posterior scalene muscles. These muscles connect the cervical vertebrae and the upper two ribs and their main function is ipsilateral flexion of the neck.

## 3) Posterior neck muscles

The posterior segment of the neck muscles connects the skull to the spinal column and also the pectoral girdle. We can further divide these in to three layers according to their depth – superficial layer (trapezius, splenius capitis, splenius cervicis), deep layer (semispinalis capitis, semispinalis cervicis, multifidus cervicis), deepest layer (suboccipital muscles, interspinales cervicis, intertransversarii colli muscles).

## VII. ANATOMY OF THE SKIN

The skin is a complex organ that serves to protect the internal structures as a mechanical barrier and also has important roles in thermoregulation, immunological activity and in hydration balance of the body. The skin is composed of three layers: the epidermis, dermis and the hypodermis (subcutaneous tissue, superficial fascia).

### 1) Epidermis

The most external layer of the skin that is separated from the lower dermis by a basement membrane. It can be further divided in to stratum basale, stratum spinosum, stratum granulosum, stratum lucidum (only on palms and soles of foot) and the most superficial layer the stratum corneum. The epidermis contains many different cell types with different roles – Langerhans cells (immunologic role), melanocytes, merkel cells.

### 2) Dermis

The dermis is made up of many cells called fibroblast that secrete extracellular matrix (for example collagen) and it is mainly a connective tissue layer. There are also mast cells in the dermis which are very important in allergy, hypersensitivity and inflammatory response. Sensory nerve fibers and vasculature of the skin pass through the dermis and travel all the way up to the basement membrane to supply the stratum basale layer of the epidermis where nutrients are needed for new cell formation.

### 3) Hypodermis/subcutaneous tissue

Hypodermis is the innermost layer of the skin and connects the dermis to the muscles and bones. It is made up of adipose tissue, blood vessels, bursas, connective tissue, fibroblasts, hair follicles, lymphatic vessels, macrophages, nerves and sweat glands. The thickness of this layer of skin differs across the body – fatty tissue accumulates differently according to the body part and also hormones/genetics.

## COSMETIC USAGE OF BOTULINUM BOTOX

### I. The periorbital area

Botulinum toxin is used in the orbital area to treat “crow’s feet”, hypertrophic low eyelid orbicularis (“jelly roll”), narrow eye aperture and eyebrow elevation/lift. Intrinsic skin aging, ultraviolet damage and repetitive contraction of the periorbital muscles all cause periorbital wrinkles and are usually one of the earliest signs of aging on the face.

In most cases of treating the periorbital region, 2-4 injection points are used, which are 1-1,5cm apart. The injection should be given when the patient is relaxed to better visualize blood vessels and minimize bruising. A key anatomical point is the zygomatic bone – all injections of the periorbital area should be given above it, to prevent lip drooping. There are some severe, but rare side effects associated particularly with treating this area – overweakening of the orbital muscles, that can cause diplopia, ectropion or lagophthalmos. As mentioned, injections under the zygomatic bone can cause lateral mouth drop due to zygomaticus major/minor paralysis. (35,36)

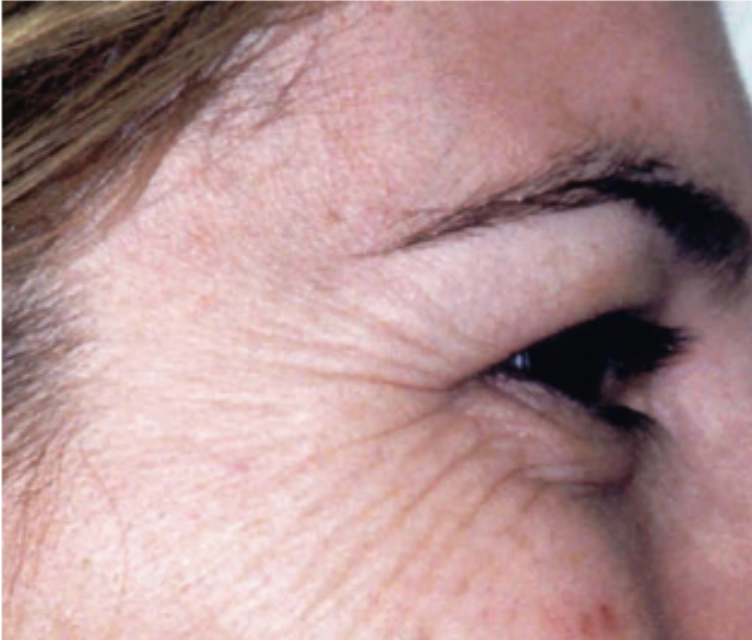

Figure 7: "crow's feet" wrinkles (Injection treatments in Cosmetic surgery, Benjamin Ascher)(37)

## II. The glabella, frontalis, eyebrows and eyelids

### - Glabellar lines

These lines, also known as the “frown lines” are produced by the muscles of the glabellar complex – corrugator supercilia, depressor supercilia and procerus muscle. The glabellar rhytids or frown lines are eliminated by treating the glabellar complex with botulin toxin and with this there is also a slight elevation of the eyebrows, due to the parts of the frontalis muscle having unopposed action. Men require a much larger dose of botox for this treatment, due to the testosterone effect on muscular growth. There are minimal risks of eyelid ptosis in correction of glabellar lines, if the injections are given at the correct anatomical position. (38–40)

### - Frontalis (forehead rhytids)

Forehead wrinkles are produced by excessive contraction of the frontalis muscle, they are horizontal of nature. The frontalis muscle is a flat, broad muscle that traditionally has two muscle bellies, but due to the overlap of midline fibers, most medical professionals regard it as simply one sheet when treating with botox. An important point to mention is that the lower 2cm of

frontalis muscle should not be treated, as it also controls the eyebrow position, meaning that treating this portion with botulinum toxin could lower the eyebrow position. Wrinkles that are caused by the lower 2cm of the frontalis muscles are usually treated with fillers. (41–43)

- *Eyebrows*

Aging also effects the shape and position of the eyebrows, new techniques using botox are used to lift and reshape eyebrows without invasive surgery. As mentioned above the lower 2cm of the frontalis muscle is the only muscle that actually elevates the brow, but there are multiple depressors of the brow – procerus and depressor supercillii being the main ones. The most common brow lift is injecting botulinum toxin in to the tail of the eyebrow to produce a simple lateral eyebrow lift. There is also a technique where the medial and lateral part of the lower portion of frontalis muscle are injected, in order to create a greater arch of the brow – due to the central portion of the frontalis still being active. (44)

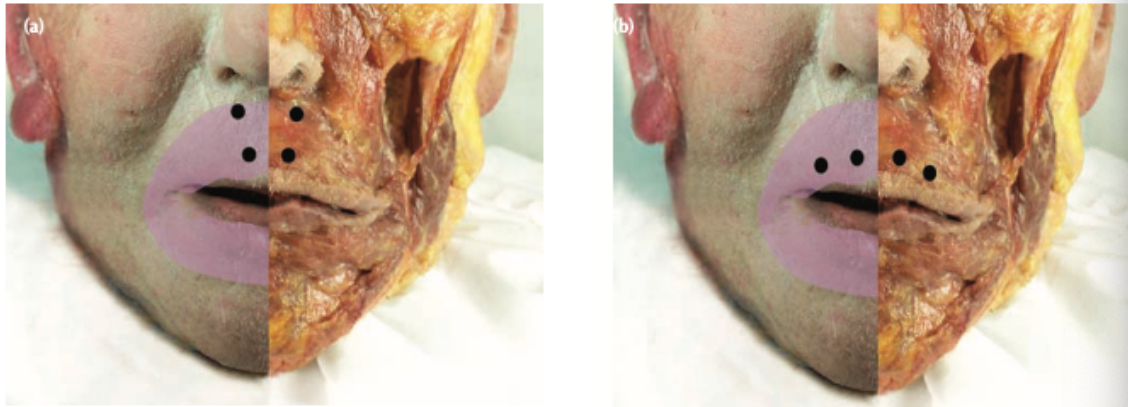


Figure 8: before and after treatment with Botox

- *Eyelids*

Treatment of eyelids is popular in individuals with fine wrinkling of the lower eyelid and in those with a ptotic brow. The inferior eyelid wrinkling and the narrow eyelid aperture are caused by contraction of the inferior pretarsal orbicularis and can be treated with botulinum toxin injection in to the muscle.

This type of botox application has some risks with overtreatment causing excessive drooping of the lower eyelid skin, photophobia and inability to close the eye completely. (37)



III. The middle and lower face

- “Bunny lines”

These are lines that cover the v-shaped pattern on the nose and are induced by the contractions of the nasalis and levator labii superioris alaeque nasi muscles. They occur more commonly when a patient has already been treated for glabellar and crow’s feet wrinkles. The injections to this area should be done superficially to avoid spread beneath the fascia.

- Nasolabial folds

Botox is not the best option for treating deep nasolabial folds, but it can be used to decrease the active depth. In the procedure muscles that elevate the folds are injected – nasalis, levator labii superioris and levator labii superioris alaeque nasi. The main treatment for nasolabial folds is dermal fillers, botulinum toxin can only add to the final result.

Figure 9: injection points for the upper lip (injection treatments in cosmetic surgery, B. Ascher) (37)

- “Gummy smile”

A gummy smile is a phenomenon that describes a person who is smiling also showing their gum, not only the teeth. It can easily be corrected with injecting

botulinum toxin in to levator labii superioris muscle, which causes an elongation of the upper lip. (45,46)

- Upper and lower lip lines

Wrinkles of around the lips are a common sign of aging, they occur vertically and are not symmetrical. Treatment of this area should be conservative since over dosing can cause dysfunctional mouth function. Upper lip injection points are around the philtrum or follow the lip line.



- “Marionette lines”

Constant activity of the depressor anguli oris cause deep lines drawing down the corners of the mouth, making the patient look sad. The platysmal bands also increase the downward pull of the corner of lips. Injections should be at least 1cm away from the corners of the mouth and in low dosages to avoid asymmetry and mouth dysfunction. (47)

- “Cobblestone chin”

Also called the dimpled chin which arises from contraction of the mentalis muscle, which inserts fibers in to the dermis of the chin. Botox can be injected in to a single area or two lateral points, with no injection coming closer than 1cm from lower lip.

Figure 10: Before and after result of treatment with Botox

## CONCLUSION

Botulinum toxin was first described between 1817 and 1822 in connection to the disease botulism and the toxin itself was isolated in 1895. The first medical use of the toxin was connected to treatment of strabismus in 1973. Botulinum toxin is produced by *Clostridium botulinum* bacteria and exists in 7 different serotypes – only serotype A and B are currently available for commercial use. It works by binding and inhibiting the SNARE proteins which are crucial for nerve conduction and muscle contraction.

The toxicity of botulinum toxin – botulism - is well studied, but not a lot of cases of poisoning occur in modern times. We can describe 6 types of botulism: food born botulism, infant botulism, wound botulism, inhalation botulism, adults intestinal toxemia and iatrogenic botulism. Botox can be used in a wide variety of medical conditions such as muscle cramps, migraines, excessive sweating, etc.

It is most often used in aesthetic medicine, for facial rejuvenation, as it effectively eliminates facial wrinkles and provides a youthful and rested look. Botox is suitable for adults between 18 and 65 years of age. Due to its safe use, it is becoming increasingly popular among both women and men.

Botox has a certain period of action, which varies, but depending on the place of use and indications. It works the shortest for wrinkles between the eyebrows. The length of action of Botox is unpredictable and cannot be recognized in advance or predict an individual's reaction. Individuals may react less well to Botox, but there is also a distinctly small group of people who do not react at all.

The results are visible in 7 - 15 days after treatment. Botox does not cause any permanent change in the body and when it stops working, everything returns to its original state, without deterioration. It is not possible to remove wrinkles or reduce sweating 100%, but wrinkles can be removed almost completely and sweating can be reduced almost completely. Its effect usually lasts from 3-6 months, depending on the individual.

With accurate knowledge of facial anatomy and the position of facial muscles, with accurate injection of botulinum toxin, or. botox we achieve looseness of certain mimic muscles. Botulinum toxin works by blocking the transmission of a nerve signal to the facial muscle, thus weakening or completely inhibiting its contraction. The skin above the muscle stops wrinkling due to muscle inactivity, and the furrows on it are smoothed out.



With Botox we usually correct wrinkles and furrows in the upper third of the face, i.e. on the forehead, between the eyebrows and at the sides of the eyes. However, it can also be used to lift the lowered corners of the mouth or to correct wrinkles on the neck.

Botox should not be used in skin inflammations at the intended injection site, in patients with myasthenia gravis, Eaton Lambert syndrome or in individuals with known hypersensitivity to botulinum toxin or any of the excipients in the formulation. Botox is contraindicated in pregnant and lactating women and in the concomitant use of certain antibiotics and muscle relaxants. Besides its use in medicine and its properties as a harmful toxin, botulinum toxin also has the potential to be used as a dangerous bioweapon.

## ACKNOWLEDGEMENTS

I would like to thank my mentor, dr. sc. Ante Dujmović for all the help and inspiration whilst writing this thesis paper. Also, thank you .dr.sc Tomislav Meštrović for all the advice.

The biggest thank you goes to my friends and family who helped me, even when I wanted to give up.

***“Whenever the art of medicine is loved, there is also a love of humanity.”***  
***– Hippocrates***

## REFERENCES

1. Dressler D. Botulinum toxin drugs: brief history and outlook. *J Neural Transm Vienna Austria* 1996. 2016 Mar;123(3):277–9.
2. França K, Kumar A, Fioranelli M, Lotti T, Tirant M, Roccia MG. The history of Botulinum toxin: from poison to beauty. *Wien Med Wochenschr* 1946. 2017 Oct;167(Suppl 1):46–8.
3. Huang W, Foster JA, Rogachefsky AS. Pharmacology of botulinum toxin. *J Am Acad Dermatol*. 2000 Aug;43(2 Pt 1):249–59.
4. Nawrocki S, Cha J. Botulinum toxin: Pharmacology and injectable administration for the treatment of primary hyperhidrosis. *J Am Acad Dermatol*. 2020 Apr;82(4):969–79.
5. Lonati D, Schicchi A, Crevani M, Buscaglia E, Scaravaggi G, Maida F, et al. Foodborne Botulism: Clinical Diagnosis and Medical Treatment. *Toxins*. 2020 Aug 7;12(8):E509.
6. Cox N, Hinkle R. Infant botulism. *Am Fam Physician*. 2002 Apr 1;65(7):1388–92.
7. Rosow LK, Strober JB. Infant botulism: review and clinical update. *Pediatr Neurol*. 2015 May;52(5):487–92.
8. Holmaas G, Gilhus NE, Gjerde IO, Lund-Tønnessen S, Langørgen J. [Wound botulism in heroin addiction]. *Tidsskr Den Nor Laegeforening Tidsskr Prakt Med Ny Raekke*. 1998 Nov 20;118(28):4357–9.
9. Mechem CC, Walter FG. Wound botulism. *Vet Hum Toxicol*. 1994 Jun;36(3):233–7.
10. Harris RA, Anniballi F, Austin JW. Adult Intestinal Toxemia Botulism. *Toxins*. 2020 Jan 24;12(2):E81.
11. Berntsen M, Bøgevig S, Høgberg LCG, Barnung SK. [Iatrogenic botulism in therapeutic use of botulinum toxin]. *Ugeskr Laeger*. 2022 Feb 14;184(7):V07210574.
12. Patocka J, Splino M, Merka V. Botulism and bioterrorism: how serious is this problem? *Acta Medica (Hradec Kralove)*. 2005;48(1):23–8.
13. Rossow H, Kinnunen PM, Nikkari S. [Botulinum toxin as a biological weapon]. *Duodecim Laaketieteellinen Aikakauskirja*. 2012;128(16):1678–84.
14. Bioterrorism - PubMed [Internet]. [cited 2022 Jun 14]. Available from: <https://pubmed.ncbi.nlm.nih.gov/34652097/>
15. Picelli A, Santamato A, Chemello E, Cinone N, Cisari C, Gandolfi M, et al. Adjuvant treatments associated with botulinum toxin injection for managing spasticity: An overview of the literature. *Ann Phys Rehabil Med*. 2019 Jul;62(4):291–6.
16. Thibaut A, Chatelle C, Ziegler E, Bruno MA, Laureys S, Gosseries O. Spasticity after stroke: physiology, assessment and treatment. *Brain Inj*. 2013;27(10):1093–105.

17. Krigger KW. Cerebral palsy: an overview. *Am Fam Physician*. 2006 Jan 1;73(1):91–100.
18. Lukban MB, Rosales RL, Dressler D. Effectiveness of botulinum toxin A for upper and lower limb spasticity in children with cerebral palsy: a summary of evidence. *J Neural Transm Vienna Austria* 1996. 2009 Mar;116(3):319–31.
19. Ross Raftemo AE, Mahendran A, Hollung SJ, Jahnsen RB, Lydersen S, Vik T, et al. Use of botulinum toxin A in children with cerebral palsy. *Tidsskr Den Nor Laegeforening Tidsskr Prakt Med Ny Raekke*. 2019 May 7;139(8).
20. Wimalasundera N, Stevenson VL. Cerebral palsy. *Pract Neurol*. 2016 Jun;16(3):184–94.
21. Batla A. Dystonia: A review. *Neurol India*. 2018 Apr;66(Supplement):S48–58.
22. Dressler D, Adib Saberi F, Rosales RL. Botulinum toxin therapy of dystonia. *J Neural Transm Vienna Austria* 1996. 2021 Apr;128(4):531–7.
23. Scott BL. Evaluation and treatment of dystonia. *South Med J*. 2000 Aug;93(8):746–51.
24. Zakin E, Simpson DM. Botulinum Toxin Therapy in Writer’s Cramp and Musician’s Dystonia. *Toxins*. 2021 Dec 14;13(12):899.
25. Dodick DW. Botulinum neurotoxin for the treatment of migraine and other primary headache disorders: from bench to bedside. *Headache*. 2003 Aug;43 Suppl 1:S25-33.
26. Olla D, Sawyer J, Sommer N, Moore JB. Migraine Treatment. *Clin Plast Surg*. 2020 Apr;47(2):295–303.
27. Al-Khalil O, Stöwhas AC, Hoetzenecker W. [Hyperhidrosis]. *Praxis*. 2015 Dec 9;104(25):1365–70, 1372; quiz 1371–2.
28. de Almeida ART, Montagner S. Botulinum toxin for axillary hyperhidrosis. *Dermatol Clin*. 2014 Oct;32(4):495–504.
29. McConaghy JR, Fosselman D. Hyperhidrosis: Management Options. *Am Fam Physician*. 2018 Jun 1;97(11):729–34.
30. MD FHN. *Atlas of Human Anatomy*. 7th edition. Philadelphia Pa: Elsevier; 2018. 640 p.
31. Gruber RP, Levine SM, Levine JP. Facial topography: clinical anatomy of the face. *Plast Reconstr Surg*. 2013 Jul;132(1):249.
32. Hotta TA. Anatomy of the Periorbital Area. *Plast Surg Nurs Off J Am Soc Plast Reconstr Surg Nurses*. 2016 Dec;36(4):162–6.
33. Paulsen F, Waschke J. *Sobotta Atlas of Human Anatomy, Vol. 3, 15th ed., English: Head, Neck and Neuroanatomy*. 15th edition. Urban & Fischer; 2013. 384 p.
34. PhD RD, PhD AWV, FRCR AWMMMBF, Tibbitts R, Richardson P. *Gray’s Atlas of Anatomy*. 3rd edition. Philadelphia: Churchill Livingstone; 2020. 648 p.

35. Erickson BP, Lee WW, Cohen J, Grunebaum LD. The role of neurotoxins in the periorbital and midfacial areas. *Facial Plast Surg Clin N Am*. 2015 May;23(2):243–55.
36. Morera Serna E, Serna Benbassat M, Terré Falcón R, Murillo Martín J. Anatomy and Aging of the Perioral Region. *Facial Plast Surg FPS*. 2021 Apr;37(2):176–93.
37. Ascher B, Landau M, Rossi B, editors. *Injection Treatments in Cosmetic Surgery*. 1st edition. London : Boca Raton, FL: CRC Press; 2008. 480 p.
38. Dessy LA, Fallico N, Mazzocchi M, Scuderi N. Botulinum toxin for glabellar lines: a review of the efficacy and safety of currently available products. *Am J Clin Dermatol*. 2011 Dec 1;12(6):377–88.
39. Kaufman-Janette J, Cox SE, Dayan S, Joseph J. Botulinum Toxin Type A for Glabellar Frown Lines: What Impact of Higher Doses on Outcomes? *Toxins*. 2021 Jul 16;13(7):494.
40. Lorenc ZP, Smith S, Nestor M, Nelson D, Moradi A. Understanding the functional anatomy of the frontalis and glabellar complex for optimal aesthetic botulinum toxin type A therapy. *Aesthetic Plast Surg*. 2013 Oct;37(5):975–83.
41. Cohen S, Artzi O, Heller L. Forehead Lift Using Botulinum Toxin. *Aesthet Surg J*. 2018 Feb 15;38(3):312–20.
42. Garritano FG, Quatela VC. Surgical Anatomy of the Upper Face and Forehead. *Facial Plast Surg FPS*. 2018 Apr;34(2):109–13.
43. Kim YJ, Lim OK, Choi WJ. Are There Differences Between Intradermal and Intramuscular Injections of Botulinum Toxin on the Forehead? *Dermatol Surg Off Publ Am Soc Dermatol Surg Al*. 2020 Dec;46(12):e126–31.
44. Karimi N, Kashkouli MB, Sianati H, Khademi B. Techniques of Eyebrow Lifting: A Narrative Review. *J Ophthalmic Vis Res*. 2020 Jun;15(2):218–35.
45. Duruel O, Ataman-Duruel ET, Berker E, Tözüm TF. Treatment of Various Types of Gummy Smile With Botulinum Toxin-A. *J Craniofac Surg*. 2019 Jun;30(3):876–8.
46. Razmaitė A, Trakinienė G. The effect of botox for the correction of the gummy smile: A systematic review. *Stomatologija*. 2021;23(3):63–8.
47. Shetty MK, IADVL Dermatotomy Task Force. Guidelines on the use of botulinum toxin type A. *Indian J Dermatol Venereol Leprol*. 2008 Jan;74 Suppl:S13-22.

## BIOGRAPHY

Lara Kralj was born in Ljubljana, Slovenia and grew up in a small town called Litija, where she finished primary school and secondary school. She played tennis competitively and received a full scholarship to pursue a medical career and life in the USA, but soon decided to come back to Europe and start her medical education at the University of Zagreb. During her 6 years in Zagreb, Lara played for the university tennis team, participated as a volunteer during COVID19 pandemic and pursued her favourite hobby – animals.