

# Non-Surgical Facial Rejuvenation Techniques

---

**Zaid, Daniel Neamat**

**Master's thesis / Diplomski rad**

**2021**

*Degree Grantor / Ustanova koja je dodijelila akademski / stručni stupanj:* **University of Zagreb, School of Medicine / Sveučilište u Zagrebu, Medicinski fakultet**

*Permanent link / Trajna poveznica:* <https://um.nsk.hr/um:nbn:hr:105:621695>

*Rights / Prava:* [In copyright](#)/[Zaštićeno autorskim pravom.](#)

*Download date / Datum preuzimanja:* **2025-03-13**



*Repository / Repozitorij:*

[Dr Med - University of Zagreb School of Medicine Digital Repository](#)



UNIVERSITY OF ZAGREB  
SCHOOL OF MEDICINE

**Daniel Neamat Zaid**

**Non-Surgical Facial Rejuvenation  
Techniques**

**Nekirurške Tehnike Pomlađivanja Lica**

GRADUATION THESIS



Zagreb, 2022

This graduation paper was made at the Department of Plastic Surgery – Clinical Hospital Center Rebro, Zagreb.

Submitted for evaluation during the academic year 2021/2022.

Mentor: AP. dr. sc. Anto Dujmović

Head of the Committee: prof. dr. sc. Davor Mijatović

Second member of the Committee: izv. prof. dr. sc. Krešimir Bulić

## Table of Contents

<b>1. Abstract - Sažetak</b> .....	<b>- 4 -</b>
<b>2. Introduction and Basic Anatomy</b> .....	<b>- 6 -</b>
2.1. Facial Skeleton .....	- 7 -
2.2. Superficial fat and musculoaponeurotic system .....	- 8 -
2.3. Retaining ligaments.....	- 11 -
2.4. Mimetic Muscles .....	- 12 -
2.5. Facial innervation and vascularization .....	- 15 -
<b>3. Skin resurfacing</b> .....	<b>- 20 -</b>
<b>3.1 Skincare</b> .....	<b>- 21 -</b>
3.1.1 Sunscreen.....	- 21 -
3.1.2 Antioxidants .....	- 21 -
3.1.3 Retinoids .....	- 22 -
<b>3.2 Chemical peels</b> .....	<b>- 23 -</b>
3.2.1 Pretreatment .....	- 23 -
3.2.1.1 Superficial.....	- 23 -
3.2.1.2 Medium .....	- 24 -
3.2.1.3 Deep .....	- 24 -
3.2.2 Post Treatment .....	- 24 -
<b>4. Laser resurfacing</b> .....	<b>- 25 -</b>
<b>5. Dermabrasion and Microdermabrasion</b> .....	<b>- 27 -</b>
<b>6. Soft tissue tightening</b> .....	<b>- 28 -</b>
6.1 Radiofrequency .....	- 28 -
6.2 Ultrasound .....	- 29 -
<b>7. Infrared light energy</b> .....	<b>- 30 -</b>
<b>8. Micro-needling</b> .....	<b>- 31 -</b>
<b>9. Neuromodulators</b> .....	<b>- 32 -</b>
<b>10. Volume restoration fillers and fat grafting</b> .....	<b>- 35 -</b>
<b>11. Volume reduction - Deoxycholic Acid and Cryolipolysis</b> .....	<b>- 40 -</b>
<b>12. Fibonacci – The Golden Ratio in esthetics dermatology</b> .....	<b>- 42 -</b>
<b>13. Conclusion</b> .....	<b>- 46 -</b>
<b>14. Acknowledgements</b> .....	<b>- 50 -</b>
<b>15. References</b> .....	<b>- 51 -</b>
<b>16. Biography</b> .....	<b>- 57 -</b>

## **1. Abstract - Sažetak**

Our skin bears the imprint of our lives. The hormonal shifts our bodies have gone through, the sun we have absorbed over time, and the changes that come with maturation.

Sun damage, pigmentation, acne, other scars and wrinkles are all chapters in our lives that our skin keeps track of and can cause us to be unhappy with our look.

Facial rejuvenation is a cosmetic procedure (or combination of techniques) that aims to restore the youthful appearance of the human face. Surgical and non-surgical facial rejuvenation are options with varying degrees of invasiveness and treatment depth.

Leading cosmetics, and regular visits to the makeup artist who will ostensibly teach us how to restore vital volume to the face, simply serve to demonstrate that we pay a significant amount of time and money in this regard.

Wrinkle filler treatments and adding volume to the face are the ideal technique to rejuvenate the facial skin and soft tissue most effectively and immediately possible.

Our natural maturation causes a loss of volume in the various tissue areas of the face, which does not contribute to the youthful and energetic image we desire.

Collagen levels in these locations decline over time, causing intercellular connective tissue, as well as subcutaneous adipose tissue and muscle tissue, to sag and produce depressions that age our face substantially.

Socket filling is a simple, practical, easy-to-perform procedure with a quick recovery time. The procedure is aimed to restore volume to areas such as beneath the eyes, cheekbones, and the sides of the lips, rejuvenating the face to the youthful and fresh appearance it had before it began to sink. This is accomplished by utilizing advanced fillers and technologies that have been used in aesthetic medicine for years and have proven to be effective.

## **Sažetak**

Na koži se reflektira naš način života. Hormonske promjene kroz koje prolazi tijelo, sunce koje smo apsorbirali tijekom vremena i promjene koje dolaze sa starenjem utječu na izgled kože. Oštećenja od sunca, pigmentacije, akne, drugi ožiljci i bore su dijelovi u naših života koje naša koža prati i mogu uzrokovati nezadovoljstvo izgledom.

Pomlađivanje lica je kozmetički postupak (ili kombinacija tehnika) kojem je cilj vratiti mladolik izgled ljudskog lica. Kirurško i nekirurško pomlađivanje lica opcije su s različitim stupnjevima invazivnosti i dubine tretmana.

Redoviti odlasci u kozmetičke salone nemaju dugoročan i značajan utjecaj na kvalitetu kože.

Tretmani za popunjavanje bora i dodavanje volumena licu idealna su tehnika za najučinkovitije i trenutno pomlađivanje kože i mekog tkiva lica. Starenje uzrokuje gubitak volumena u različitim dijelovima tkiva lica, što ne pridonosi mladolikoj i svježoj slici koju želimo. Razina kolagena na tim mjestima s vremenom opada, uzrokujući opuštanje vezivnog tkiva, potkožnog masnog tkiva i mišićnog tkiva i stvaranje udubljenja koje značajno postaraju lice.

Aplikacija dermalnih punila je jednostavan, praktičan postupak koji se lako izvodi s brzim vremenom oporavka. Postupak je usmjeren na vraćanje volumena područjima oko očiju, jagodica, nazolabijalnih bora, čela i usana, vraćajući licu mladenački i svjež izgled koji je imalo prije nego što je počelo stariti. To se postiže korištenjem dermalnih punila, botoksa i tehnologija koje se godinama koriste u estetskoj medicini i koje su se pokazale učinkovitima.

## **2. Introduction and Basic Anatomy**

Thorough knowledge and comprehension of facial anatomy are required for safe and effective cosmetic procedures.

Imaging, staining techniques, and dissections are used both intraoperatively and in the research laboratory on cadavers to find and delineate the complex layered architecture and soft tissue compartments of the face (1). The doctor attempts to reverse some of the changes that occur as a result of aging in order to create a more young, natural - looking appearance.

Volumetric alterations in soft tissue compartments, gravitational changes, and ligament attenuation are examples of these. Whether the rejuvenation strategy includes muscle paralyzing, volume restoration as well as surgical options as rhytidectomy, platysmaplasty, autologous fat transfer, implants, or endoscopic methods, a thorough understanding of facial and neck anatomy will improve the chances of success and lower the risk of unfavorable outcomes or complications.

The anatomy of the face will be presented in layers or planes, with some key structures or regions, such as the facial nerve, sensory nerves, and facial arteries, topography and superficial layers of the neck.

The facial skeleton is the hard tissue of the face that provides structural support and projection for the soft tissues beneath it, as well as transporting nerves through foramina and supplying attachments for various mimetic and mastication muscles.

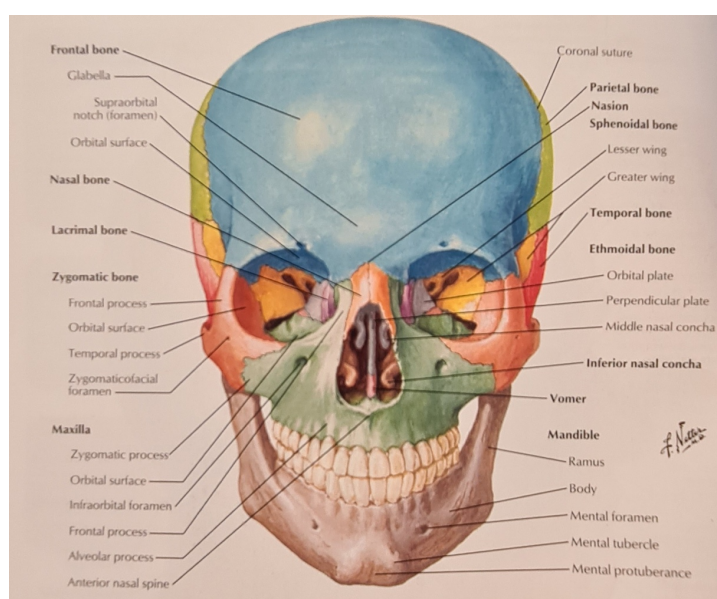
## 2.1. Facial Skeleton

The underlying facial bones convexities and concavities determine the look of the face to a considerable extent. The convexities and projection given by the zygomatic bone and mental protuberance of the mandible, respectively, are responsible for the "high" cheekbones and strong chin associated with attractiveness (Figure 1). The frontal bone is superior to the bones of the midface, while the mandible is inferior to the frontal bone. The zygomaticofrontal suture lines run superiorly, the maxillary teeth run inferiorly, and the sphenothmoid junction and pterygoid plates run posteriorly.

The maxillae, zygomatic bones, palatine bones, nasal bones, zygomatic processes of the temporal bones, lacrimal bones, ethmoid bones, and turbinates are the bones of the midface.

The lower half of the face is formed by the mandible. The mental protuberance gives the underlying soft tissues anterior protrusion in the midline. The ramus of the jaw lies beneath the masseter muscle and continues superiorly to articulate with the cranium through the mandible's coronoid process and condylar process. In line vertically with the infraorbital and supraorbital nerves, the mental nerve comes from the mental foramen on the body of the mandible.

The facial skeleton offers places of attachment for the muscles of facial expression and mastication, as well as structural support, projection, and protection of sensory organs such as the eyes.

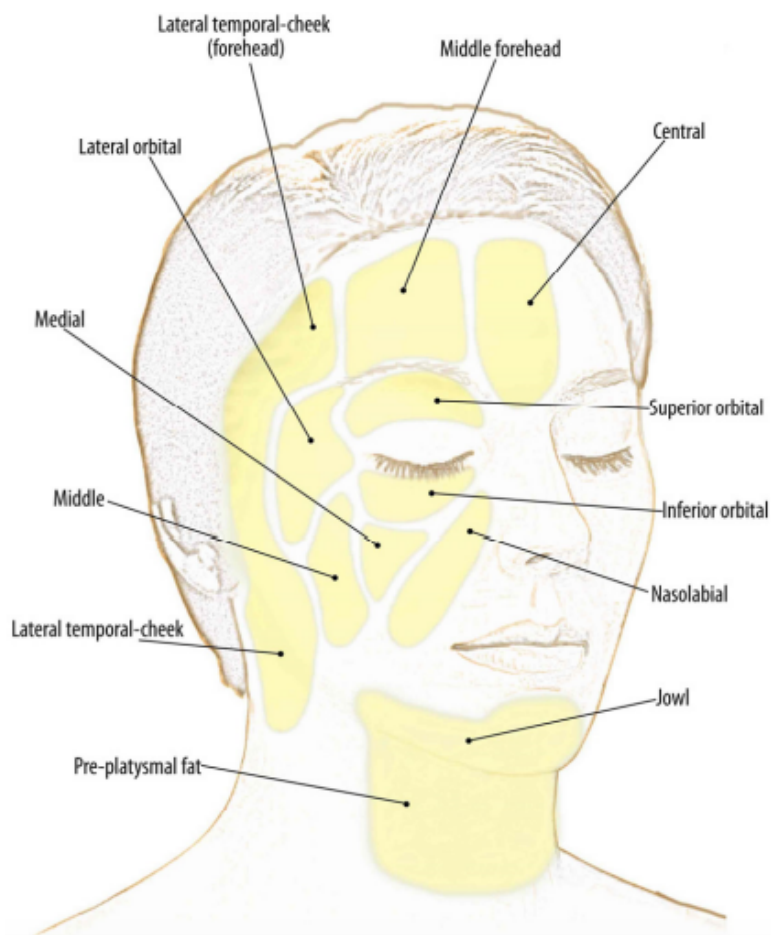


**Figure 1.** Facial skeleton (Frank H. Netter, MD – Atlas of human anatomy 5<sup>th</sup> edition).



## **2.2. Superficial fat and musculoaponeurotic system**

Rohrich and Pessa's pioneering work (2) has identified a number of unique superficial fat compartments in the face (Figure 2). These sections are divided from one another by a divider, fragile fascial tissue and septae, which converge to create retaining ligaments where adjacent compartments meet. The nasolabial, the superior, inferior, and lateral orbital fat pads ("malar" fat pads). The central, middle, and lateral temporal cheek pads on the forehead, and the superior, inferior, and lateral temporal-cheek fat pads are all the superficial fat compartments of the face. Nasolabial fat is found medial to the cheek fat pad compartments and contributes to the nasolabial fold's overhang. The nasolabial fat compartment's superior border and the medial cheek compartment's superior border is represented by the orbicularis retention ligament.



**Figure 2.** The superficial fat compartments of the face (3).

Between the fat chambers of the medial and lateral temporal cheeks is the middle cheek fat compartment, which is delimited superiorly by the superior cheek septum. The zygomatic ligament is formed when the margins of the middle cheek compartment, inferior orbital fat pad compartment, and lateral orbital fat pad compartment converge to form a harder band of tissue called the zygomatic ligament (4). The masseteric ligaments in the same location coincide with the condensation of connective tissue at the boundaries of the medial and central fat compartments (5). The lateral temporal-cheek fat pads run the length of the face, from the brow to the neck. The lateral cheek septum, which forms its anterior limit, is encountered during facelift treatments with medial dissection from the preauricular incision. The superior and inferior temporal septa define the upper and bottom limits of the forehead. The middle temporal fat pad is bordered inferiorly by the orbicularis retaining ligament and medially by the central forehead fat compartment, which is medial to the lateral temporal cheek fat compartment in the forehead. The superior and inferior orbital fat compartments are located above and below the eyes, respectively. The medial and lateral canthi divide these periorbital fat pads from one another medially and laterally. The third orbital fat pad is the lateral orbital fat compartment, which is bordered on the superior side by the inferior temporal septum and on the inferior side by the superior cheek septum. Along its length, the zygomaticus major muscle joins to overlaying superficial fat compartments by fibrous septae. The jowl fat compartment clings to the depressor anguli oris muscle in the lower third of the face and is bordered medially by the depressor labii and inferiorly by platysma muscle bands. The jowl fat compartment is bordered by premental and preplatysmal fat. The aging process is influenced by the segmented structure of the face's superficial subcutaneous fat. Volume loss appears to happen at different rates in different compartments, resulting in abnormalities in facial contour and the loss of the smooth, seamless transitions between the convexities and concavities of the face that are associated with youth and beauty.

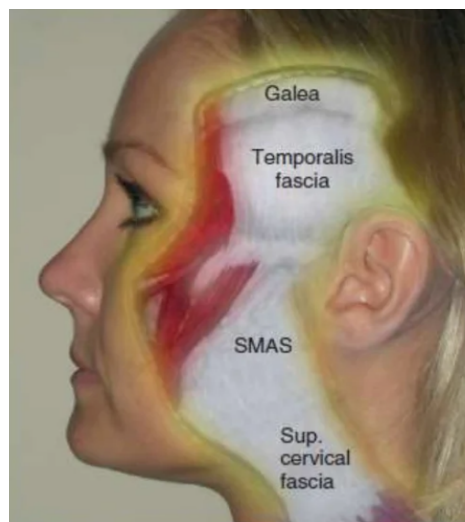
Mitz and Peyronie described a fibro-fatty superficial facial fascia that they named the superficial musculoaponeurotic system (SMAS) in 1976 (6) as demonstrated in Figure 3.

The mimetic muscles are connected to the overlying dermis by this system or network of collagen fibers, elastic fibers, and fat cells, which plays a vital functional role in facial expression. The SMAS is a key component of most modern facelift procedures, it is a tissue sheet that runs from the neck (platysma) onto the face, temporal area (superficial temporal fascia), and medially past the temporal crest into the forehead. The exact structure of the SMAS, regional differences, and even the existence of the SMAS are all subjected for different opinion (7) and two of the architecture are described by Ghassemi (8).

SMAS of type I is made up of a network of small fibrous septae that run perpendicularly between fat lobules and the dermis, as well as deep into the face muscles or periosteum. The forehead, parotid, zygomatic, and infraorbital areas all have this variance.

Type II SMAS is a thick web of collagen, elastic, and muscle fibers found in the upper and lower lips, medial to the nasolabial fold, links the face muscles around the mouth to the overlying skin, despite its thinness, and plays a vital role in the transmission of complicated motions during animation.

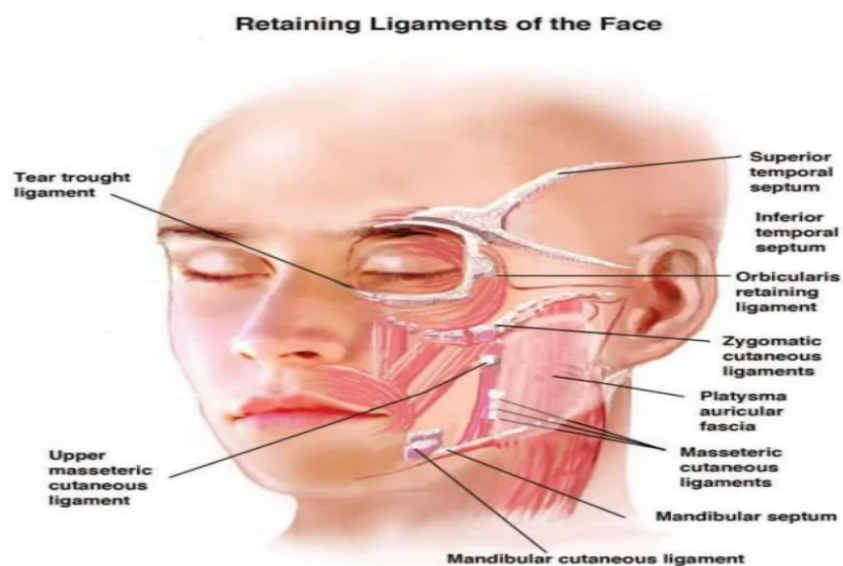
SMAS encompasses the facial nerve branches as well as the sensory nerves in the lower face. In this location, procedures superficial to the SMAS protects facial nerve branches (9).



**Figure 3.** Superficial musculoaponeurotic system (SMAS) (10).

## 2.3. Retaining ligaments

The dermis and the underlying periosteum are connected by true retaining ligaments (Figure 4). False retaining ligaments are fibrous tissue condensations that connect the superficial and deep fasciae of the face (11). The zygomatic ligament (McGregor's patch) is a genuine ligament that connects the zygomatic arch's inferior border to the dermis and is located directly posterior to the zygomaticus minor muscle's origin (4). The lateral orbital thickening on the superolateral orbital rim, which results from a thickening of the orbicularis retaining ligament, and the mandibular retaining ligament are two more genuine ligaments that latter connects the mandible's periosteum to the overlying dermis immediately medial to the origin of depressor anguli oris. The labiomandibular crease forms just anterior to the jowl because of this connection. The masseteric ligaments are false retention ligaments that originate from the masseter's anterior edge and extend into the SMAS and cheek's overlying dermis. These ligaments weaken with age, and the SMAS across the masseter becomes ptotic, resulting in the creation of jowls (12). The platysma-auricular ligament is a fibrous tissue condensation below the lobule of the ear, where the lateral temporal-cheek fat compartment meets the postauricular fat compartment. True and false holding ligaments are met and frequently released during facial rejuvenation procedures to mobilize tissue planes. When releasing ligaments, such as the zygomatic and mandibular retention ligaments, extra caution should be exercised because vital facial nerve branches are intricately tied to the ligaments.



**Figure 4.** Retaining ligaments of the face (10).

## **2.4. Mimetic Muscles**

Facial expression muscles are thin, flaccid muscles that operate as sphincters of facial orifices or elevators and depressors of the brows and lips. The periorbital face muscles include the frontalis, corrugator supercilii, depressor supercilii, procerus, and orbicularis oculi. The levator muscles, zygomaticus major and minor, risorius, orbicularis oris, depressor anguli oris, depressor labii, and mentalis are all perioral muscles. Compressor naris, dilator naris, and depressor septi are all part of the nasal group (Figure 5) while the platysma muscle is a superficial muscle in the neck that extends into the lower face but will not be demonstrated in the picture.

The principal elevator of the brows is the frontalis, which is the anterior belly of the occipitofrontalis muscle and innervated by the temporal branch of the facial nerve. It originates in the epicranial aponeurosis and travels forward across the forehead, where it is inserted into the orbicularis oculi, corrugators, and dermis fibers and while contraction occur it generates horizontal lines across the forehead and lifts the eyebrows.

The orbicularis oculi are a sphincter that surrounds the eyes. It is divided into three sections: orbital, preseptal, and pretarsal. The nasal section of the frontal bone, the frontal process of the maxilla, and the anterior part of the medial canthal tendon make up the orbital part. Its fibers wrap around the orbit in concentric loops, far beyond the orbital rim's confines. Contraction causes the eyes to slam shut tightly and superior fibers also reduce brow furrowing. The medial canthal tendon gives way to the preseptal orbicularis oculi, which passes across the orbital rim's fibrous orbital septum and into the lateral palpebral raphe. The facial nerve's temporal and zygomatic branches supply innervation to these muscles.

Corrugator supercilii arises from the orbital rim's superomedial aspect and travels upward and outward before inserting into the dermis of the brow's middle layer. Two muscle slips, one vertical and the other transverse, move through frontalis fibers to reach the dermis from their origin deep in the muscle. The superficial and deep branches of the supraorbital nerve are tightly connected to the corrugator supercilii at its origin and are vulnerable to injury during muscle manipulation.

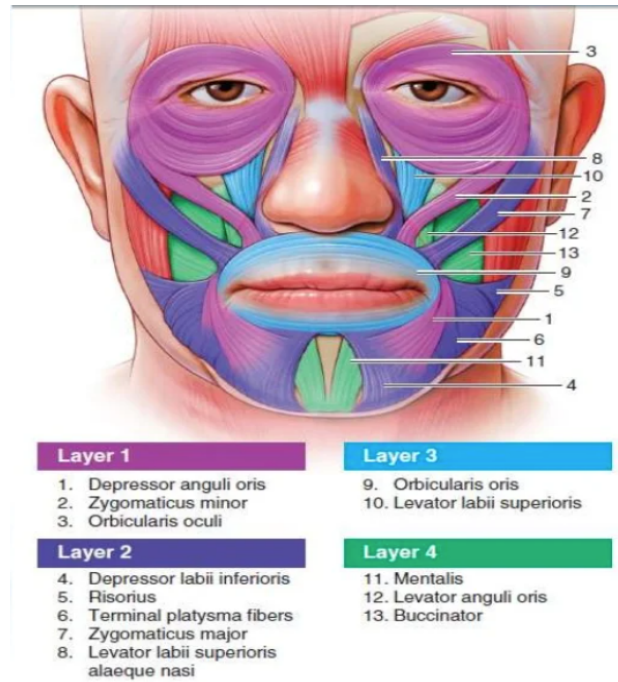
When you frown, the corrugator supercilii depresses and drags your brow medially. It operates as a depressor by inserting into the medial brow.

Procerus emerges from the nasal bone, ascends superiorly, and enters the glabella's dermis between the brows. It creates a horizontal wrinkle at the bridge of the nose by depressing the lower forehead skin in the midline. One of the most prevalent aesthetic indications for botulinum toxins is chemo-denervation of the procerus and corrugator supercilii to reduce frown lines. During endoscopic brow lift treatments, the procerus is occasionally debulked to decrease the horizontal frown crease. The zygomaticus major and minor are superficial muscles that arise from the zygoma's body and insert into the mouth corner and the lateral aspect of the top lip, respectively. The zygomatic and buccal branches of the facial nerve provide them on their deep surface with nerve supply.

Levator labii is deep to orbicularis oculi, it enters the upper lip and orbicularis oris after passing downhill.

The levator labii superioris alaeque nasi is a smaller slip of muscle medial to this, arises from the frontal process of the maxilla and inserts into the nasal cartilage and upper lip. Both muscles elevate the upper lip and are supplied by branches of the facial nerve's zygomatic and buccal branches.

The Levator anguli oris arises from the maxilla's canine fossa, just behind the infraorbital foramen, and enters the upper lip. The zygomatic and buccal branches of the facial nerve innervate it on its superficial aspect, and it lifts the corner of the mouth. Risorius derives from a thickening of the platysma muscle over the lateral cheek. It is inserted into the mouth corner and pulls the mouth corners laterally. Orbicularis oris acts as a sphincter around the mouth, and its fibers intertwine with the fibers of the other face muscles that work on the mouth. The facial nerve's buccal, marginal mandibular branches provide motor supply to the orbicularis oris, which controls the lips' pursing, dilatation, and closure.



**Figure 5.** Mimetic Muscles (10).

Along the oblique line lateral to depressor labii inferioris, depressor anguli oris develops from the periosteum of the mandible. Its fibers converge in spindle fashion with orbicularis oris, risorius, and occasionally levator anguli oris fibers. It is supplied by the facial nerve's marginal mandibular branch and contracts to depress the mouth corners. Depressor labii inferioris arises from the mandible's oblique line in front of the mental foramen, which is covered by fibers of the depressor anguli oris, It goes upward and medially into the lower lip's skin and mucosa, as well as the orbicularis oris fibers. Mentalis emerges from the mandible's incisive fossa and descends to the dermis of the chin. Contraction by marginal mandibular nerve raises and protrudes the lower lip, resulting in the "peach-pit" dimpling of the skin above the chin. The transverse section (compressor naris) and the alar part make up the Nasalis (dilator naris). The compressor naris arises from the maxilla and goes over the dorsum of the nose, interlacing with fibers from the opposing side. Dilator naris arises from the maxilla and attaches into the alar cartilage of the nose, just below and medial to compressor naris and during respiration, it dilates the nostrils. Depressor septi is a muscle slip that arises from the maxilla above the central incisor and runs deep into the upper lip's mucous membrane. It pushes the nose tip inferiorly by inserting into the cartilaginous nasal septum which also can be manipulated by filler injections as Hyaluronic Acid. The superior buccal branches of the facial nerve supply innervation to the nasalis and depressor septi.

## **2.5. Facial innervation and vascularization**

The motor innervation of the facial muscles is provided by the facial nerve (seventh cranial nerve as shown in figure 6). It starts in the face, medially to the tympanomastoid suture of the skull, at the stylomastoid foramen. The posterior auricular nerve and nerves to the posterior belly of the digastric and stylohyoid branch arise from the main trunk before entering the parotid gland. The facial nerve is divided into five primary branches within the parotid gland: temporal branch, zygomatic branch, buccal branch, marginal mandibular branch, and cervical branch. The facial nerve's temporal branch splits into three or four rami at the superior border of the parotid gland. They cross the zygomatic arch anterior to the external auditory meatus. The most anterior branch of the zygomatic arch is usually posterior to the lateral orbital rim at the level of the zygomatic arch. The temporal branches pass through a superficial temporal fascia envelope that connects the intermediate fat pad to the deep temporal fascia. Just behind the anterior branch of the superficial temporal artery, the temporal branch enters frontalis just above the brow. The facial nerve has up to three zygomatic branches. The upper branch supplies the frontalis and orbicularis oculi from above the eye. The lower branch of the zygomaticus major usually runs under the origin and supplies this muscle, as well as other lip elevators and the lower orbicularis oculi. Depressor supercilii and the superomedial orbicularis oculi are supplied by smaller branches that continue around the medial portion of the eye. Within the parotidomasseteric fascia, the buccal branch exits the parotid and is securely linked to the anterior surface of the masseter. It runs anteriorly over the buccal fat pad, below and parallel to the parotid duct, supplying the buccinators and upper lip and nose muscles. A second branch is occasionally found, but it goes anteriorly above to the parotid duct.

One to three major branches of the marginal mandibular nerve emerge from the lower region of the parotid gland, it normally runs above the mandible's inferior border, but it can slip up to 4 cm below it. The nerve goes upward and more superficially to innervate the lip depressors posterior to the angle of the mouth.

It is prone to harm during procedures in the lower face at this region, even though it is deep to the platysma. The platysma muscle is innervated by the cervical branch of the facial nerve, which enters the neck at the level of the hyoid bone.



The ophthalmic nerve, maxillary nerve, and mandibular nerve are the three divisions of the trigeminal nerve (fifth cranial nerve) that supply sensory innervation to the face. The supraorbital, supratrochlear, infratrochlear, lacrimal, and external nasal nerves supply the ophthalmic nerve, which supplies the forehead, upper eyelid, and dorsum of the nose. Through the infraorbital, zygomaticofacial, and zygomaticotemporal nerves, the maxillary nerve nourishes the lower eyelid, cheek, upper lip, ala of the nose, and part of the temple. The deeper structures as the alveolar and pterygopalatine nerves, respectively, supply the maxillary teeth and the nasal cavity via the maxillary nerve. There are motor and sensory fibers in the mandibular nerve and the inferior alveolar nerve, lingual nerve, buccal nerve, and auriculotemporal nerve are some of its branches. The skin across the mandible, lower cheek, part of the temple and ear, lower teeth, gingival mucosa, and lower lip are all supplied by these. The skin across the angle of the jaw is supplied by the larger auricular nerve, which is derived from the anterior primary rami of the second and third cervical nerves. The supraorbital nerve exits from the orbit at the supraorbital notch (or foramen), which is 2.3–2.7 cm from the midline in men and 2.2–2.5 cm in women (13). It straddles the corrugator muscle and has superficial and deep branches. These branches can sometimes emerge from different foramina, with the deep branch emerging lateral to the superficial one.

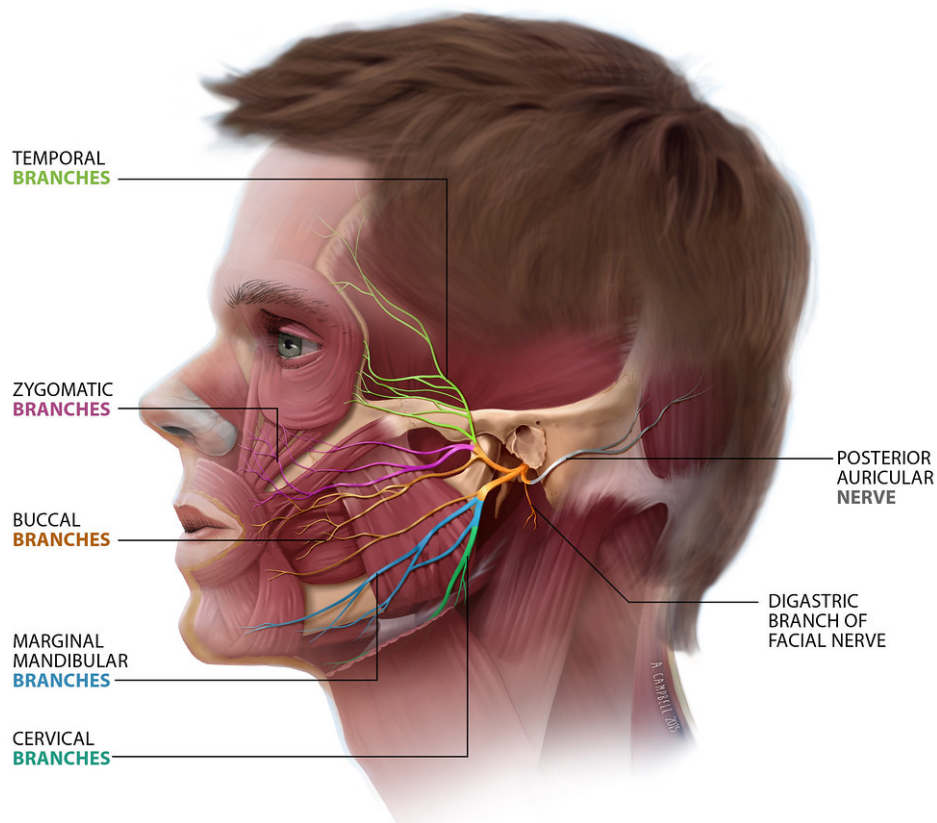
The supratrochlear nerve exits the orbit medial to the supraorbital nerve and passes under the corrugator and frontalis, near to the periosteum. The skin across the medial eyelid and lower medial forehead is supplied by its many branches. The infratrochlear nerve is a nasociliary nerve branch that serves a tiny area on the medial portion of the upper eyelid and the bridge of the nose.

Except for the skin over the external nares, the external nasal nerve provides the skin of the nose below the nasal bone and across the lateral region of the upper eyelid is supplied by the lacrimal nerve. The infraorbital nerve is the maxillary nerve's greatest cutaneous branch and enters the face through the infraorbital foramen emerges from a foramen immediately below the levator labii superioris origin. The lower eyelid, ala of the nose, and upper lip are all supplied by this nerve.

The zygomaticofacial nerve feeds skin to the malar eminence and arises from the zygomaticofacial foramen below and lateral to the orbital border. The anterior temple is supplied by the zygomaticotemporal nerve, which arises from its foramen on the deep

surface of the zygomatic bone. The mental nerve is a branch of the inferior alveolar nerve that exits the mental foramen between the apices of the premolar teeth, in line vertically with the infraorbital foramen, it is frequently visible and palpable due to stretched mouth mucosa. It nourishes the skin that covers the lower lip and the jaw.

The buccal branch of the mandibular nerve offers sensory innervation to the buccal mucosa and cheek skin, while the lingual nerve supplies sensory innervation to the tongue's anterior two-thirds and the floor of the mouth. The skin of the upper one-third of the ear, the external auditory meatus, the tympanic membrane, and the skin over the temporal region are all supplied by the auriculotemporal nerve, which arises from behind the temporomandibular joint, secretomotor fibers also travel to the parotid gland via the auriculotemporal nerve.



© University of Dundee School of Medicine 2015. Illustrated by Annie Campbell.

This resource is shared under an Attribution-NonCommercial-NoDerivatives Creative Commons licence (CC BY-NC-ND 4.0). You are free to copy and reuse this for non-commercial purposes but we ask that you acknowledge the University of Dundee when doing so. If you remix or modify this material, you may not distribute the modified material.

**Figure 6.** "Head Anatomy Facial Nerve WITH Labels by Annie Campbell" by dundeetilt is licensed under CC BY-NC-ND 2.0. To view a copy of this license, visit <https://creativecommons.org/licenses/by-nd-nc/2.0/jp/?ref=openverse>.

The facial skin and soft tissue vascularization is supplied by branches of the facial, maxillary, and superficial temporal arteries, all of which are branches of the external carotid artery (Figure 7). The ocular arteries supply a mask-like area, which includes the middle forehead, eyelids, and top part of the nose, through the internal carotid system.

From the external carotid, the facial artery wraps around the inferior and anterior borders of the mandible, just anterior to the masseter. The masseteric fascia is pierced, and it ascends upward and medially toward the eye (14). The facial artery sends two labial arteries, inferior and superior, into the lips, passing below orbicularis oris, at the level of the mouth.

The angular artery is a branch of the facial artery that branches off near the medial canthus beside the nose.

The mental, buccal, and infraorbital arteries are three branches of the maxillary artery, which is a terminal branch of the external carotid. The mental artery is a branch of the inferior alveolar artery that supplies the chin and lower lip after passing through the mental foramen. To nourish the cheek tissue, the buccal artery crosses the buccinators.

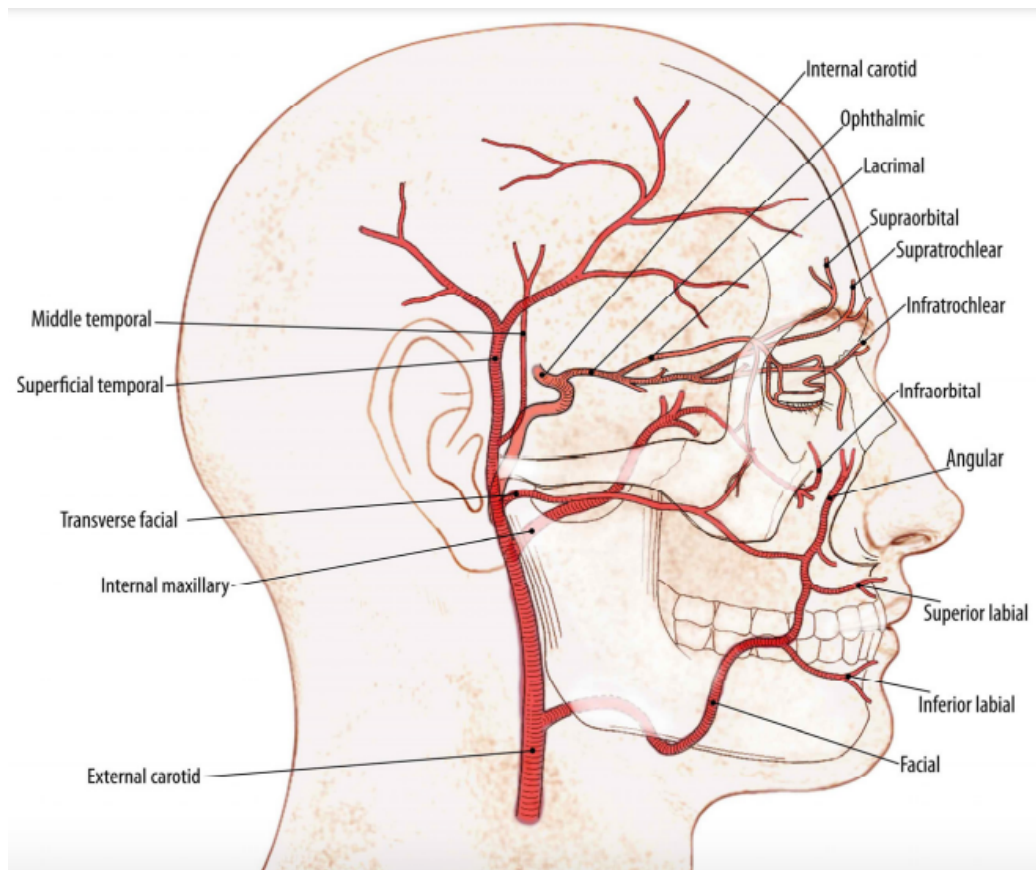
The lower eyelid, cheek, and lateral nose are all supplied by the infraorbital artery, which enters the face through the infraorbital foramen. It connects to the transverse facial, ophthalmic, buccal, and facial arteries by anastomosis.

The superficial temporal artery is the external carotid artery's terminal branch. It gives off the transverse facial artery in the level of the parotid, just before reaching the zygomatic arch, which travels inferior and parallel to the arch and supplies the parotid, parotid duct, masseter, and skin of the lateral canthus.

Within the superficial temporal fascia, the superficial temporal artery crosses the zygomatic arch. It produces a middle temporal artery above the arch, which pierces the deep temporal fascia and nourishes the temporalis muscle. The superficial temporal artery separates into anterior and posterior branches above the zygomatic arch and the anterior branch feeds the forehead and connects to the supraorbital and supratrochlear arteries via anastomoses.

The internal carotid system has a branch called the ocular artery. The lacrimal, supraorbital, supratrochlear, infratrochlear, and external nasal arteries are among its branches. Several anastomoses connect the exterior and internal carotid artery networks

around the eye, allowing for extensive communication. Accidental intra-arterial injection of fillers for soft tissue augmentation around the eye might cause central retinal artery blockage and possibly blindness (15–17). Fillers should be administered in tiny amounts with blunt cannulas and a careful retrograde injection method to avoid this problem (18).



**Figure 7.** The arterial supply of the face (3).

### **3. Skin resurfacing**

Plastic surgeons have noticed a significant increase in demand for noninvasive rejuvenation operations over the previous decade. According to figures from the American Society of Plastic Surgeons, 15.9 million minimally invasive cosmetic treatments were performed in 2018, up 2% from 2017 and 22.8% from 2000.

In comparison, in 2018, there were 1.8 million cosmetic surgical procedures performed, down 5% from 2000. These numbers shows that noninvasive techniques are outpacing surgical operations in terms of growth. As a result, plastic surgeons must be prepared to provide safe and effective nonsurgical rejuvenation in order to meet this expanding demand (American Society of Plastic Surgeons).

In order to understand few of the following sections it is important to understand the concept of the Fitzpatrick skin type.

Thomas B. Fitzpatrick created Fitzpatrick skin phototypes in 1975 based on a person's skin color and responses to sun exposure in terms of degree of burning and tanning. Fitzpatrick skin typing has been shown to have diagnostic and therapeutic utility, despite its subjective nature. It's most typically used to assess sun sensitivity in population-based and case-control studies on the causes of skin cancer, UV radiation exposure, tanning, and protective behavior (19,20). The Fitzpatrick scale has been used as a standard for self-assessment of sun sensitivity in self-administered questionnaires, and it has been found to correspond well for white skin versus brown skin (21).

For determining UV, PUVA, and laser treatment doses, skin phototype typing is commonly utilized (22).

## **3.1 Skincare**

### **3.1.1 Sunscreen**

Sun exposure hastens intrinsic skin aging by causing damage to dermal collagen and elastin and disrupting normal skin metabolism. These abnormalities are linked to uneven pigmentation, telangiectasias, elastosis, and rhytids (23).

Sunscreen, on the other hand, has been shown in several trials to successfully slow the course of photoaging while without reversing current effects (24). When compared to organic sunscreens such as aminobenzoates, cinnamates, and salicylates, inorganic sunscreens, notably zinc oxide and titanium dioxide, provide improved broad-spectrum ultraviolet radiation protection, increased photostability, and lower allergic potential (25). The best sunscreen to recommend to plastic procedures patients is one that contains the maximum percentage of titanium dioxide and zinc oxide, which allows for a more elegant application without the white appearance of standard inorganic sunscreens (26). Sun protection should be used thirty minutes before sun exposure, reapplied often, and used in conjunction with other sun avoidance habits (27).

### **3.1.2 Antioxidants**

Antioxidants are used to protect skin from oxidative stress and to repair skin that has been damaged by the environment (28). Vitamin C improves skin surface look by increasing collagen formation and epidermal turnover, whereas vitamin E neutralizes reactive oxygen species synergistically (29). Ferulic acid stabilizes these two antioxidants and improves their potency in delaying and reversing epidermal age signs (30). The optimal antioxidant should have a combination of these and other components, such as polyphenols, flavonoids, and carotenoids, in a stable formulation and at a concentration high enough to be effective without causing irritation (25). Patients should be urged to incorporate these antioxidants into their everyday skin care regimens.

### **3.1.3 Retinoids**

Retinoids increase dermal collagen content and glycosaminoglycan deposition. Increased skin smoothness and wrinkle reduction are the results of these histologic effects (31). The prescription formulation of tretinoin is limited by compliance issues due to problematic side effects such as redness, irritation, and desquamation, which If patients are not thoroughly educated on how to address these concerns, they may quit receiving treatment, such as by reducing the frequency of application or the concentration of medication. While these negative effects have been demonstrated to be dose dependent, the skin rejuvenating effects have not been proven to be so. As a result, patients can be given the lowest dose of tretinoin (0.025 percent) and yet expect maximum benefit (31). Because retinol, a tretinoin precursor, must be converted to its active counterpart in the skin, it is 20 times less effective and has a 1000-fold lower dermal concentration than tretinoin (30). Retinaldehyde, a tretinoin precursor with similar efficacy but less side effects, is another tretinoin precursor. In terms of long-term benefits, however, it has yet to be compared to tretinoin (31). Tretinoin is still the gold standard retinoid for skin rejuvenation due to these reasons, and it should be taken in conjunction with other aesthetic products.

## **3.2 Chemical peels**

Chemical peeling has been a significant part of facial rejuvenation for decades. Photoaging, scarring, pigmentary dyschromias can all be treated with eradication of superficial skin lesions techniques, which are both safe and successful.

Chemical peels are categorized as superficial, medium, or deep depending on how much damage they cause to the skin. The doctor's job is to help the patient choose the resurfacing treatment that will most effectively meet his or her goals while preserving a high margin of safety. Chemical peeling remains an important aspect of a face rejuvenation program despite the availability of numerous microdermabrasion and laser systems for facial rejuvenation. This is due to its popularity with patients and low cost to the practitioner (34).

### **3.2.1 Pretreatment**

Chemical peels are more effective when they are pretreated, which should begin four to six weeks before the procedure. Pretreatment with tretinoin leads to more homogenous icing and faster reepithelialization (35). To lessen the likelihood of post-inflammatory hyperpigmentation, hydroquinone should be prescribed to patients with Fitzpatrick type III or higher (36). In order to speed up the exfoliation, glycolic acid at a concentration of 10% or less is also given daily before to treatment and to avoid irritation before the peel, these are all ceased one week before the procedure (37). Patients with a history of herpes simplex should get antiviral medication starting two days before and continuing for ten days after the outbreak.

#### **3.2.1.1 Superficial**

Skin texture problems and dyschromias are treated with superficial chemical peels. They have the advantage of requiring little to no downtime and are typically applied in sequence to achieve maximum effect. When a hazy white frost on a pink background is observed, the proper superficial peel depth through epidermis is obtained. If necessary, the peel should be neutralized once this icing is complete. Glycolic acid is a superficial peeling agent that must be neutralized with water or a weak base at a concentration of 30%-50%.



### **3.2.1.2 Medium**

Fine wrinkles and dyschromias are treated with medium depth peels. When a white frost appears and an erythematous strikethrough detected, indicating penetration to or through the papillary dermis, the depth of peel is acceptable. Glycolic acid 70 percent is neutralized as described above. Patients should expect soreness and erythema after these peels, which can last anywhere from three to seven days (38).

### **3.2.1.3 Deep**

For coarse wrinkles and deeper acne scars, thorough chemical peels treatments are recommended. These peels should be given with intravenous sedation or regional blocks due to their depth of penetration. The use of phenol-based peels, such as the Baker-Gordon formula, requires cardiac monitoring and intravenous fluids. Solid white frosting without background erythema indicates a depth of peel through the papillary dermis into the reticular dermis. A grey color should be avoided since it shows severe peeling depth. Deep chemical peels require 10 to 14 days of downtime and are more unpleasant to recover from (38).

The nature of the frost will reveal the depth of the peel, with pink frost suggesting epidermal injury, pink white showing papillary dermal injury, and white indicating reticular dermal injury.

Hetter's solution, which uses phenol and croton oil to improve penetration, is available as a superficial, intermediate, or deep peel. The depth can be adjusted by changing the number of swipes, the volume of solution used, or the phenol and croton oil concentration.

### **3.2.2 Post Treatment**

Patients are encouraged to use a petroleum-based lotion to moisturize often after medium and deep peels. Sun protection should be started right away, however sunscreen can be applied again after a superficial peel or two weeks after a severe peel if reepithelialization has occurred. At the first evidence of hyperpigmentation, the treating physician should start hydroquinone treatment right away (38).

## **4. Laser resurfacing**

Laser resurfacing causes epidermal or dermal damage and regeneration, which results in improved skin tone, wrinkle effacement, and dyspigmentation reduction. In patients with a history of scarring and a Fitzpatrick type of V or above, resurfacing should be done with caution. Pretreatment includes tretinoin and hydroquinone, as well as acyclovir, which can be used selectively for patients with a history of herpes infection or used universally for all patients. Deeper procedures should be done under nerve blocks, intravenous sedation, or general anesthesia while superficial resurfacing can be done with a topical anesthetic (39). Ablative and non-ablative resurfacing lasers, as well as fractionated and non-fractionated lasers are also available.

Non-ablative lasers have less downtime and are safer, however ablative lasers rejuvenate more dramatically. Water is used as a chromophore by ablative lasers, such as the carbon dioxide (CO<sub>2</sub>) and erbium lasers, which evaporate treated zones and induce collagen remodeling. CO<sub>2</sub> lasers are limited by their extended recovery time, up to six months in some cases, and the danger of hypopigmentation. Water-containing tissue is more specifically absorbed by the erbium laser, resulting in less collateral damage and his skin rejuvenating effect, however, may be less pronounced due to these characteristics (40).

Intense pulsed light (IPL), pulsed-dye are non-ablative lasers and non-ablative non-coherent light sources that generate heat to cause skin damage and improve rhytids without generating open wounds.

Thermotherapy is thought to stimulate dermal fibroblasts while keeping the epidermis cold and safe from injury (40).

Fractionated and non-fractionated lasers are also available. Non-fractionated lasers harm the entire treated area, whereas fractionated lasers create small columns of injury with unaffected parts in between. Due to the unharmed skin between affected columns, fractionated lasers can reach a deeper depth of injury with less downtime.

Multiple treatments spaced 2-4 weeks apart may be required to obtain the desired result for the same reason (39).

After epithelialization is complete, which takes between 24-48 hours for fractional treatments or a few weeks for whole field treatments, posttreatment skincare consists of petrolatum or occlusive dressings until reepithelialization is complete. After that, a nonocclusive moisturizer can be used. As soon as the reepithelialization is complete, sunscreen should be used.

Other skin care should be used with caution to avoid irritation.

Erythema is the most prevalent side effect of laser resurfacing, and it is a normal component of the healing process. Occlusive agents can cause skin outbreaks like milia or acne, which normally go away as the occlusive agent is stopped. Hypopigmentation is not treatable, although it can be hidden by treating and reducing pigmentation in other regions. Hyperpigmentation is a self-limiting side effect of laser treatments in patients with higher Fitzpatrick types or who have had early sun exposure (41).

## **5. Dermabrasion and Microdermabrasion**

Microdermabrasion is a procedure that uses a vacuum and an abrasive component, which is usually a solid crystalline substance. Though it is advertised as a treatment for rhytids, dyspigmentation, and superficial scarring, studies have shown that its effects are minimal. When these techniques are combined, however, it has been shown to efficiently improve transdermal delivery of active skincare components. Microdermabrasion has the advantage of being safe in most patients, unlike lasers and chemical peels, including those with higher Fitzpatrick types or who are otherwise at risk of pigmentary alterations or scarring (42).

The technique begins with a thorough washing and degreasing of the face, followed by three passes over the treated skin in different directions. The amount of dermabrasion is determined by the rate of handpiece movement and the flow strength and there is no need for anesthesia. Sunscreen is applied after treatment, and there is usually no social downtime. Patients are informed that they will almost certainly require multiple treatments and that erythema, itching, and petechiae are some of the most common side effects (41).

Dermabrasion creates a mid-dermal wound using an abrasive motorized wheel. Since the introduction of laser resurfacing, it has been less popular due to the increased danger of virus particles being aerosolized, dyspigmentation, and scarring. It's still a good alternative for treating deeper acne scars, but his facial rejuvenation applications are limited (43).

## **6. Soft tissue tightening**

Tissue tightening is the process of reducing skin laxity. Patients who do not want surgery or are not good candidates for rhytidectomy are good candidates for nonsurgical skin tightening. Furthermore, some patients who have had a face lift operation have discovered that nonsurgical skin tightening after the procedure improves their outcomes.

### **6.1 Radiofrequency**

The mechanism of action in this type of skin tightening treatment works by sending thermal energy to the reticular dermis, which sets off a remodeling cascade that results in the creation of collagen, elastin, and blood vessels. It is a non-ablative therapy that focuses on the dermis while leaving the epidermis alone, reducing scarring and pigmentation issues while also speeding up healing. Radiofrequency treatments have been shown to help with facial wrinkles, brow lifting, periorbital wrinkles, nasolabial folds, jawline contouring, and neck laxity (42).

Radiofrequency skin tightening should be avoided by patients with implantable medical devices and those who have underlying healing difficulties. Multiple studies have shown that it is less successful in senior persons because their reduced dermal healing ability, less tissue hydration, or worse degree of preoperative deformity (45).

The treating practitioner must choose whether to use more energy in one session or less energy in subsequent sessions, that with time was found that applying lower energy over a longer period of time was more effective for collagen remodeling and skin elasticity improvement (46).

Microneedle electrodes provide fractional radiofrequency energy directly to the reticular dermis while sparing adnexal structures, also known as radiofrequency microneedling. Microneedling's ablative action allows for both resurfacing and tightening, which can be advantageous in individuals who need therapy for both of these indications of aging and are ready to undergo a longer recovery time than non-ablative radiofrequency treatments (44). Patients should be told that full treatment results can take anywhere from six months to a year.

Swelling, numbness, and bruising are the most prevalent side effects, which usually go away in 1-2 months and can be managed expectantly (47).

## **6.2 Ultrasound**

Ultrasound-based skin tightening heats tissue through vibration and friction using a lower intensity, a type of a micro-focused ultrasound. This heating causes small coagulation spots in the reticular dermis, which causes remodeling while sparing the papillary dermis and epidermis on top. This epidermal sparing treatment, like radiofrequency skin tightening, decreases the danger and recovery time associated with this procedure. Micro-focused ultrasonic energy, unlike radiofrequency skin tightening, may heat deeper tissues without heating the epidermis, allowing for increased energy transmission and penetration to the superficial muscular aponeurotic system and platysma (48). It also enables direct observation of treated tissues during therapy, which adds an extra layer of safety (49).

The brows, chin, neck, and chest have all been authorized for ultrasound skin tightening and it should be used with caution in patients with Fitzpatrick type V or VI (50).

Micro-focused ultrasound, like radiofrequency skin tightening, has been proven to be less successful in older individuals with more severe age-related deformities (48). The procedure is usually following application of a topical anesthetic. Given the moderate to severe discomfort associated with this treatment, nerve blocks, nitrous oxide gas, and oral anxiolytics are some options for additional anesthetics. Before delivering a linear array of ultrasonic pulses, the focal depth is visualized on the monitor and calibrated to correspond to the layer to be treated.

Pre-programmed regimens for multiple treatment locations are included in the majority of therapy platforms, with treatment times ranging from 30 to 60 minutes per region (49). Patients should expect edema, erythema, and transitory bruising after treatment, all of which are self-limiting. More than 80% of patients and providers notice a difference after treatment and in most cases, complete outcomes can be expected within six months (48) (49).

## **7. Infrared light energy**

Of the noninvasive skin tightening treatments, infrared technology has the least amount of study. By delivering infrared energy via broadband light, the approach creates heat in the dermis and stimulates collagen remodeling.

Infrared energy does not enter the deeper subcutaneous layers, unlike ultrasound-based skin tightening. As a result, it's only recommended for modest skin laxity without affecting the underlying tissue. It should be taken with caution in people with higher Fitzpatrick types, as with earlier treatments.

Infrared skin tightening is usually not unpleasant enough to necessitate the use of anesthetics, it involves several treatment cycles and skin temperature readings to heat individual treatment zones to a specific degree. After that, the skin is allowed to cool or cool compresses are used.

Patients usually report slight discomfort after therapy. After three to six treatments spaced two to four weeks apart, full benefits should be expected.

The outcomes and complications data are not well published, and the results are variable (51).

## **8. Micro-needling**

Microneedling involves puncturing the epidermis with micron-sized needles to cause a damage to the skin's outermost layer. These micro-punctures are promoted as a way to injure the skin and stimulate the creation and deposition of elastin and collagen (52).

The treatment has only been proved to treat very superficial rhytids since it is so shallow (53).

Washing and applying a topical anesthetic are the first steps in the procedure, to uniformly distribute passes, the microneedling device is put to the skin perpendicularly and moved in different directions. The operation is completed with uniform, precise bleeding, followed by the application of a moisturizing sunscreen every 48 hours or indefinitely.

Treatments can be repeated every 3 weeks in average until the desired results are obtained (52). Due to the minor nature of the damage, the consequences are minor. However, because of the shallow penetration, the treatment's downtime and risk profile are reduced, with the most common side effects being bruising, erythema, and irritation, which are all self-limiting (53).



## **9. Neuromodulators**

In the United States, botulinum toxin is the most often utilized nonsurgical facial rejuvenation method (American Society of Plastic Surgeons). The toxin works by paralyzing face muscles for a short period of time, removing dynamic rhytids and lowering static ones. The main difference between those products is their protein concentration, which might cause sensitivity or resistance over time. Although a meta-analysis of trials comparing three botulinum toxin formulations found no significant differences in treatment response, it recommended that more research is needed (56).

Treatment with botulinum toxin is generally safe, however it is not recommended for people who are allergic to eggs or albumin, have an infection at the injection site, or are pregnant or breastfeeding. Anticoagulation is a relative contraindication due to the increased risk of bleeding, underlying neuromuscular disorders are a relative contraindication due to the possibility of worsening severity and blepharoptosis is a relative contraindication due to the risk of worsening with frontalis paralysis.

Because each injection will have an impact on brow position, forehead and periorbital botulinum toxin injections should be administered with particular attention to brow morphology.

Injection into the frontalis, which causes transverse forehead rhytids, in 1.25 - 2 units, depending on the injector's chosen dilution and given the structure of the frontalis muscle, injections should be deep and scheduled based on the specific patient's rhytid pattern. To sustain brow height and arch, injections should not reach too far inferiorly or laterally to maintain an appealing brow shape.

The corrugator and procerus are glabellar muscles that form mid-brow rhytids. With no more than 5 units of botulinum toxin per injection it can be administered in a V pattern and in order to retain the frontalis in this location, the injection plane should be deep while the orbicularis oculi should be injected very superficially.

When animating, the injection pattern should be titrated to the rhytid anatomy of the individual patient, to target the muscle and avoid spreading to the levator palpebrae superioris. The lateral orbital rhytids are obliterated and the lateral brow is raised with these injections. Injections should be done in three to five sites in 1-2 unit.

A second row of injections may be required in patients with particularly active muscles (57). Upper face botulinum toxin injection complications are unwelcome but reversible due to the treatment's brief effect, additionally, sensible injections can be used to correct brow asymmetries or overly peaked brows while blepharoptosis, on the other hand, is not reversible for the length of the therapeutic effect and can only be alleviated by briefly elevating the eyelid with alpha-adrenergic activation of Muller's muscle (e.g. apraclonidine drops). Swelling, bruising, and redness are further side effects that are self-limiting.

Injecting botulinum toxin into the lower face and neck is more difficult and unreliable than injecting it into the upper face. As a result, understanding anatomy is necessary for using this treatment safely and successfully.

The orbicularis oris is treated to soften tiny vertical perioral rhytids that arise during animation. It's done by injecting very superficially at the vermilion border in two points on the superior and inferior lips. To reduce diffusion, only a modest amount and volume of product should be injected. It will not treat static rhytids that develop because of chronological aging or smoking but for those resurfacing therapies are more effective.

The oral commissures are raised by injecting into the depressor anguli oris in two sites per side are usually the standard, each with 2 - 2.5 units, should be injected a few millimeters above the mandibular boundary immediately anterior to the jowl.

The mentalis muscle can be worked on to decrease the chin's cobblestone look. 2 - 2.5 units per injection are administered at one place per side, five millimeters lateral to the midline and about one centimeter above the tip of the chin in order to soften the platysmal bands. Several sites up to 10 superficial injections of 2 - 2.5 units in a vertical line at the anterior edge of the muscle are usually required, with one to two centimeters between injection sites on either side.

By compressing the muscle between the injector's fingers, this method is made easier, and this area can also be treated to assist and elevate the oral commissures.

Botulinum toxin side effects in the lower face can be debilitating and difficult to manage. Smile asymmetry, speaking difficulty, drooling, and dysphagia are just a few examples. Complications can be reduced by using a safe injection technique and mastering the relevant anatomy (58).

## **10. Volume restoration fillers and fat grafting**

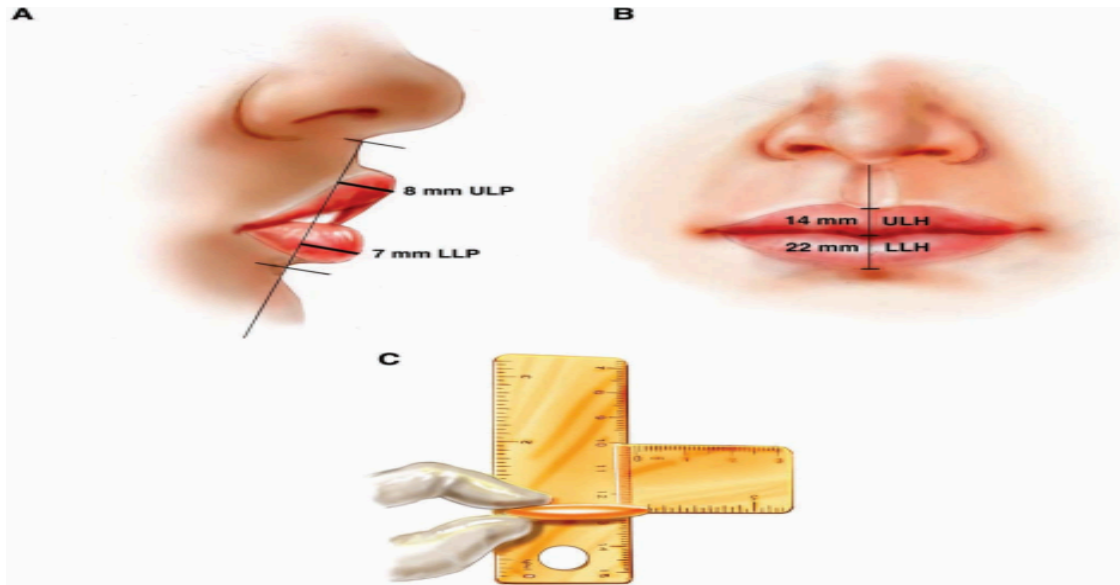
Injectable soft tissue fillers can be resorbable (hyaluronic acid and poly-L-lactic acid) or non-resorbable (calcium hydroxyapatite and polymethylmethacrylate). Hyaluronic acid compounds are the most commonly used filler because of its enzymatic reversibility in the event of negative outcomes. Its viscosity and indicators are determined by the degree of cross-linking. More heavily cross-linked formulations are viscous and recommended for deeper injections, whilst less cross-linked formulations are thinner and recommended for superficial injections.

Lips can be injected in the lower face to give it a fuller, more youthful appearance (Figure 8). For this procedure, many patients require tiny dose of local anesthetic or nerve blocks. Lip augmentation can be done in a variety of ways, but the optimal method is one that is customized to the patient's anatomy and asymmetries (Figure 9). When injecting along the white roll, within the vermilion, and below the commissure, a lower viscosity filler should be used and aesthetic lip proportions should be observed.

Following injection, all areas are rubbed to generate a smooth, even contour.

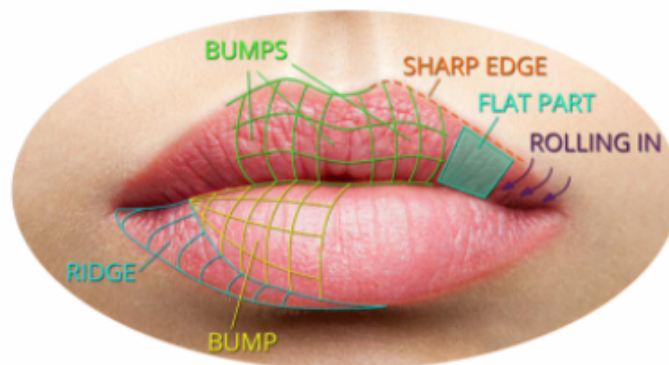
Small volume injections along the zygoma area at the level of the periosteum, beginning lateral to the midpupillary line, can be used to enhance the cheeks in the midface, with following massage to smooth the filler and given the depth of the injection, a more heavily crosslinked filler should be employed in this location (Figure 10). Nasolabial creases are addressed by injecting a medium cross-linked filler into the mid to deep dermis (59).

Filler can be utilized to raise the lateral brow in the upper face by injecting 0.25 - 0.5 mL into the deep tissue of the lateral eyebrow at the inferior aspect of the supraorbital rim. To correct an A-frame distortion, it can also be injected into the upper lid sulcus deep to the orbicularis. Because of the thin skin and high likelihood of contour defects, the tear trough is more difficult to fix. instead of injecting directly into the tear trough, the safest way to treat this area is to insert a 0.25 mL of a low cross-linked filler along the preperiosteal infraorbital rim (Figure 12).



**Figure 8.** (A) An aesthetically pleasing lip, with a rare midline notch and an upper lip height (ULH) of 10 mm. In this case, the ULH could also be measured laterally from the midline (17 mm). The lower lip height (LLH) is 22 mm. (B) A line is drawn from the columella-lip junction to the horizontal chin fold, and the maximal protrusion of the lips is measured perpendicular to this line (ULH = 8 mm, LLH = 7 mm). (C) To recreate the authors' measuring device, a short mm measure should be cut from the end of a simple metric ruler and then attached to the other piece in a perpendicular fashion. The horizontal part of the ruler measures the protrusion of the lips from an imaginary line between the base of the nose and the horizontal chin fold (either directly on the patient or on the computer screen). The ratio should be 1:1 (60).

### Lip Anatomy and Areas on lips for filler



**Figure. 9** Lip fillers injection sites (61).

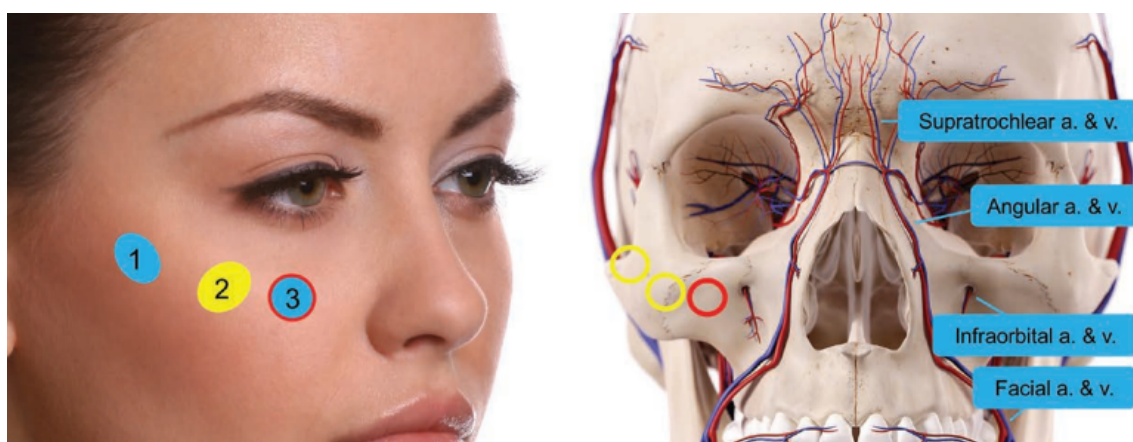Finally, a sunken chin can be enhanced by three supraperiosteal boluses of a highly cross-linked filler material over the lower chin (62).

Bruising, edema, and erythema are all mild side effects of filler injections that are self-limiting. A herpes flare is a more serious reaction, emphasizing the significance of taking a full preoperative history to establish whether pre and postprocedural prophylaxis is required. If there is a case that too much filler is injected in one location or highly cross-linked fillers are put too superficially, nodules might form.

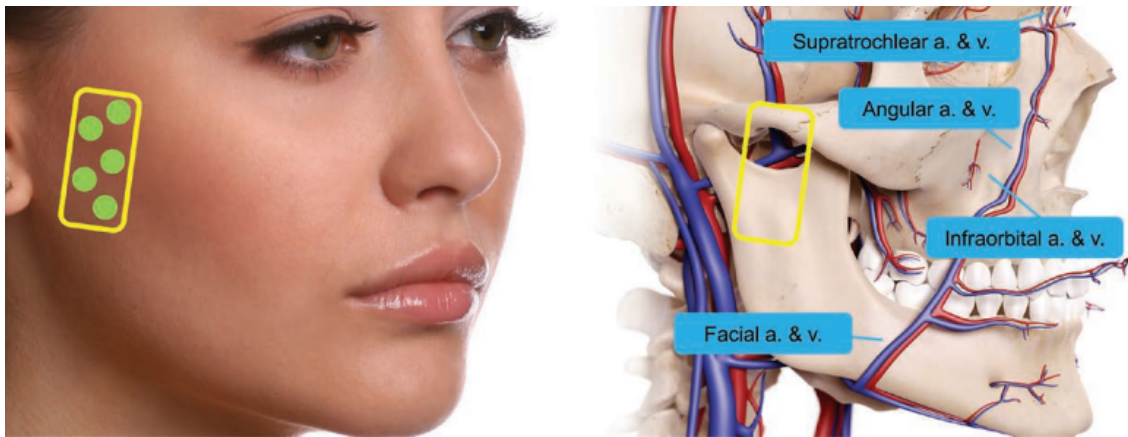
Massage can be tried first, followed by hyaluronidase breakdown of the nodule (20 units of enzyme for every 0.1 mL of filler).

Within a few minutes following injection, most of disintegration should occur. An uncommon but well-known hazard of filler injection is vascular occlusion, which can result in soft tissue damage or blindness.

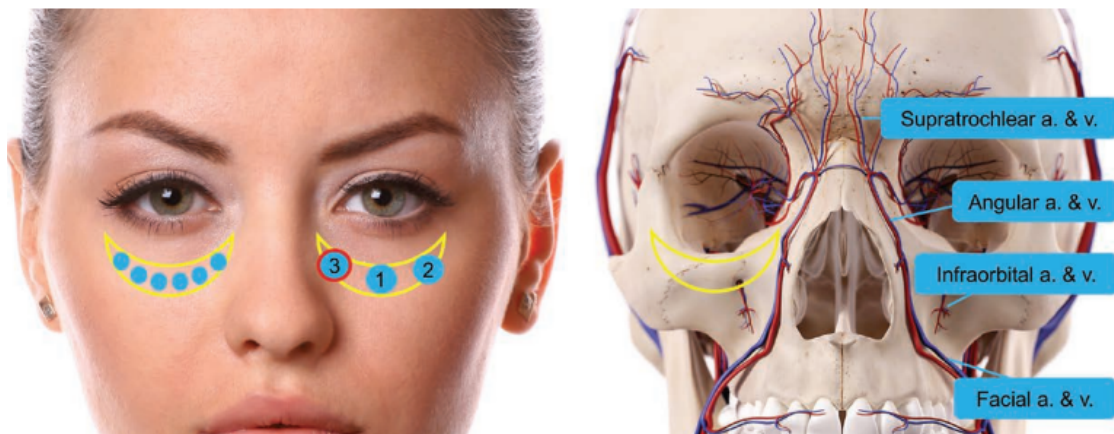Safe injection techniques help to reduce the severity of this catastrophic result (aspiration prior to injection of the compound can assist the avoidance of anatomic areas which can risk vascular compromise via compression, intravascular injection or embolization, and avoidance of injecting large volumes). If a hyaluronic acid filler was injected intravascularly, early detection is crucial with urgent hyaluronidase injection at the first evidence of color or sensory change or onset of pain if this problem occurs. The therapy protocol entails administering 500 units per anatomic unit every hour until soft tissue alterations are no longer visible. The most feared side effect of fillers is blindness, which is caused by retrograde arterial flow after injection into an ocular artery branch. There is no known consistent way to reverse filler-induced visual alterations if this happens. Retrobulbar hyaluronidase has been suggested, although it is a contentious treatment option that should not be used by inexperienced hands. However, urgent ophthalmologic assessment is indicated to lower intraocular pressure and facilitate blood flow return. Because the effectiveness of hyaluronidase injection in clearing an intravascular blockage cannot be guaranteed, embolism prophylaxis is essential.



**Figure 10.** “Volume replacement in the upper cheek using Voluma. Potential injection sites in the upper cheek: lateral cheek (designated by site 1), anterior cheek (site 2), and medial cheek (site 3) (left). Areas of caution: avoid zygomatic facial vessels and nerves in the lateral cheek, infraorbital artery and vein in the anterior cheek, and angular and infraorbital arteries and veins in the medial cheek (right). a., artery; v., vein” (59).



**Figure 11.** “Volume replacement in the preauricular area can be delivered with Voluma, Volift, or Ultra Plus. Injections are made at three to five sites in the lateral cheek region (left). Areas of caution: avoid the parotid gland and the transverse facial artery and vein (right). a., artery; v., vein” (59).



**Figure 12.** “Volume replacement along the lid-cheek junction using Volbella or Ultra. Injections are made at three main locations (two injections per location; up to six total aliquots) (left). Areas of caution: avoid the orbit by making injections 1 to 2 mm below the orbital rim (right). a., artery; v., vein” (59).

Another technique for face rejuvenation and volume restoration is fat grafting. It has the benefits of availability and cost effectiveness, but its ultimate retention is unknown. Many of the injection techniques are comparable to filler injections. However, extra attention must be paid to fat graft harvesting and processing techniques that maximize fat graft retention, as well as ways for reducing fat graft-related problems.

To minimize adipocyte stress and enhance viability, a cautious approach should be employed while harvesting fat for grafting. Although there has been no evidence that harvest location affects viability, ultrasound or power-assisted liposuction should be avoided due to the stress to adipocytes. Fat is then separated by gravity, centrifugation,

none of which has been demonstrated to be beneficial for boosting eventual graft retention as long as centrifugation is kept under 3000 rpm for less than three minutes. To limit the possibility of fat necrosis or nodule formation, fat should be injected with 18-20 blunt-tipped cannulas in modest 0.1 mL (63). Injections should be made deep into the orbicularis in the periorbital region, and overcorrection should be avoided. Suborbicularis injections are crucial since injections that are only a few millimeters deep in the skin might cause obvious contour irregularities and nodule formation.

The most common complication of fat grafting, especially periorbital fat grafting, is a visible or palpable contour irregularity. Liposuction is a rare management practice that works although triamcinolone injections are also an option and if failed, direct excision may be required. Similar to synthetic fillers, vascular impairment might occur, but treatment is more difficult because of the lack of enzymatic digestion (64). Importantly, patients should be informed that achieving the desired outcome may necessitate numerous treatments.



## **11. Volume reduction - Deoxycholic Acid and Cryolipolysis**

The submental region is the most typically targeted for volume reduction during face rejuvenation. Deoxycholic acid is an injectable fat-burning medication that works by disrupting the membranes of adipocyte cells.

Deoxycholic acid injections are recommended for the pre-platysmal fat, but not for the platysma itself. They can be done on both men and women, and they don't require anesthetic.

When injected into the submental fat, three to four cycles of injections with decreasing volumes of product are required to produce about 92% reduction in submental fat. Injections are carried out in a pre-marked grid with two milligrams of product per square centimeter, resulting in up to fifty injection sites.

Swelling, which happens within 48 hours of the procedure, lasts an average of 2 weeks, and resulting in an average 9% volume increase, is one of the procedure's risks. Despite the post-procedure edema, deoxycholic acid injections dramatically enhanced patient satisfaction. Nerve paralysis, dysphagia, dysphonia, and wound formation have also been recorded as concerns, however these are uncommon and reversible (65).

Cryolipolysis can also help with submental fat reduction and controlled cooling is used to selectively kill adipocytes while sparing surrounding tissue. The area is cleansed and a gel is administered before the therapy and after that, a little applicator designed for the submental region is used to complete the treatment, which takes around 45 minutes. Following treatment, massage is required to rewarm and restructure the tissue, which will be substantially swollen upon probe removal.

Submental cryolipolysis treatment resulted in about 20% volume reduction that remained constant after 6 weeks. Seventy-six percent of patients were happy with their treatment results (66). Patients with severe overlaying skin laxity will have worsening laxity following fat disintegration, therefore patient selection is crucial in this regard and in the expectations of skin retraction levels.

Erythema, edema, and paresthesias are the most prevalent side effects of cryolipolysis. All these things are self-restrictive. There have been occurrences of paradoxical fat enlargement as a result of the treatment, but these are uncommon, affecting only around 1% of patients with risk factors for this condition as male gender, a history of cryolipolysis, and Hispanic ethnicity while the submental region is not affected by other risk factors such as the abdominal region or a large handpiece (67).

## **12. Fibonacci – The Golden Ratio in esthetics dermatology**

Symmetry is seen to be a distinguishing feature of attractive looks (Figure 13). This isn't to say that the most aesthetically acceptable proportions are always the ones that result from dividing the face into thirds or fifths. We claim that  $\phi$  - value, often known as the golden ratio or the divine proportion, can characterize symmetrical shapes based on the etymology of the word symmetry, as well as specific examples and ideas of beauty.

As a result, it is proposed that this ratio will be used in facial aesthetics.

Humans have always strived to define beauty and clarify fundamental aspects of facial aesthetics. The classical position that relates beauty to certain symmetrical proportions has been questioned from ancient Greece through the Renaissance to modern medical practice. The incorrect definition of symmetry as a precise and well-defined idea of balance is the source of this skepticism.

Beauty, according to Aristotle, is "an inaccurate feeling of harmonic or aesthetically attractive proportionality". A variety of aesthetic proportions have been proposed since then, including the 1:1 ratio and the axial facial division into thirds.

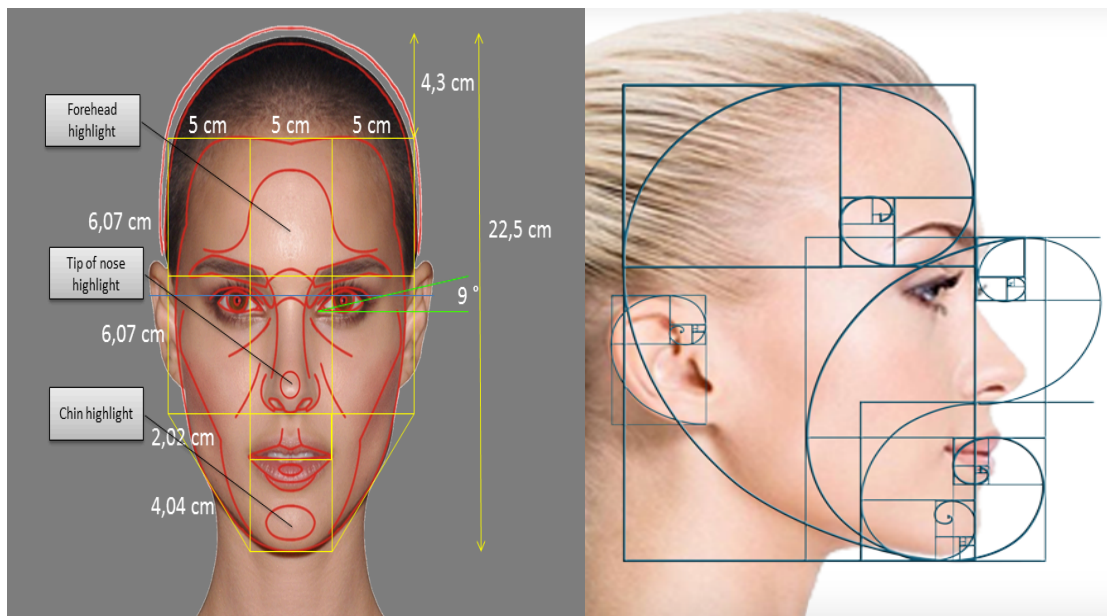
However, it appears that when the "golden ratio" is used as the most aesthetically beautiful proportion, the quantitative qualities of beauty are best clarified. The "golden ratio" is a proportion that can be seen all over nature and has long been thought to be a beautiful feature of both natural and artistic creations. The golden ratio splits a line at a point so that the ratio of the two sides' lengths ( $a/b$ ) equals the ratio of the two sides' sum ( $a + b$ ) to the longer side ( $a$ ). The golden ratio can be used as the most appealing symmetrical form that distinguishes attractive faces.

The irrational number phi ( $\Phi = a/b = (a+b)/a = 1.61803399\dots$ ), named by the sculptor of the Parthenon Phidias, is the exact value of the golden ratio. The Fibonacci ratio, or "divine proportion", is another name for the golden ratio. In both nature and art, there are numerous examples of the phi ratio's presence. The ancient Greeks detailed its mathematical features in full, while it appears that other cultures, such as the Egyptians, had known about them for millennia.

The “Golden ratio” has intrigued several Western thinkers throughout the years, from architecture to medicine, and from the arts to philosophy.

However, there has been much dispute about its aesthetic characteristics.

The usage of this proportion in art and architecture, as well as in the beauty business in general, has been both praised and criticized. Furthermore, it is argued that the aesthetic concept of beauty is misty, subjective, and unlikely to be reduced to a few simple ratios. Nonetheless, adopting the aforementioned concept of symmetry, “ $\phi$ ” may describe a symmetrical object as beauty of form deriving from balanced proportions that are not always reduced to mirror images (68).



**Figure 13.** The Golden Ratio applied on facial measures and structure respectively (69,70).

Determining what "beautiful is" is a challenging struggle for everyone, since the ancient Greek era as mentioned before, however, attempts have been attempted to measure "beautiful" using mathematical standards. Many scientists and artists, including Pythagoras, Plato, Euclid, and Da Vinci, have been fascinated by the ratio of the human body's beauty, and this fascination continues today.

One of the outcomes of these efforts was the "golden ratio". Euclid proposed the "Golden ratio" produced when a line is divided into two unequal segments, where the ratio of the longer segment to the whole line is equal to the ratio of the shorter section to the longer, roughly 3 centuries before Christ.

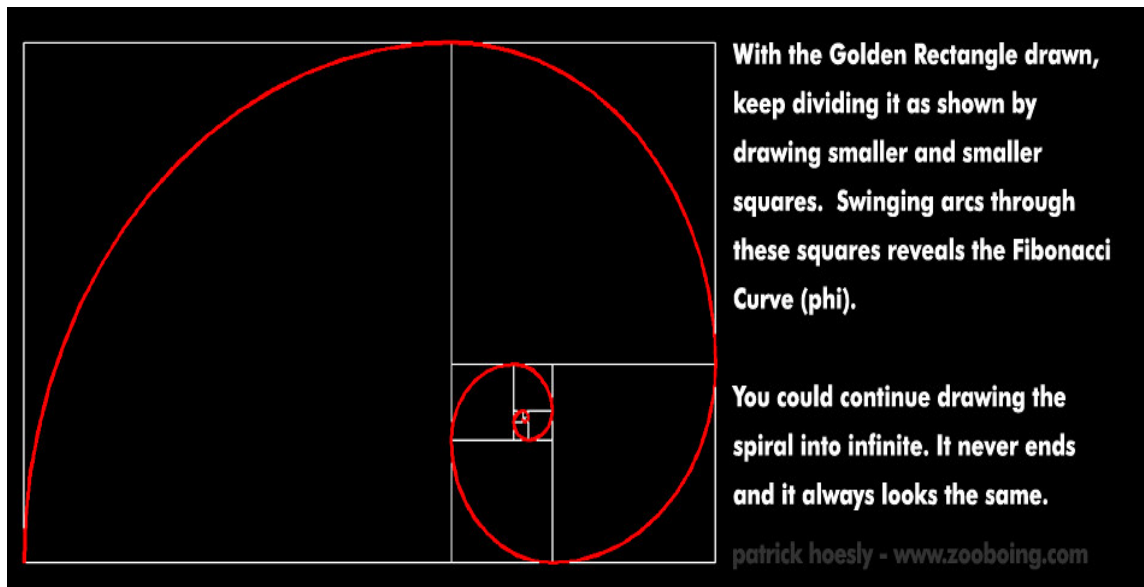
When a greater number is divided by a smaller nearby number in the Fibonacci sequence, which is a sum of two preceding terms, the result is always 1.618, which equals the golden ratio (Figure 14). The length-width ratio of an egg or the ratio of radii in the arrangement of fern leaves, the tail of a comet, a vortex, a spiral galaxy, a storm, the spiral arrangement of sunflower seeds, or the spirals in most mammal ears are all examples of this ratio (71).

Individuals from various cultures have varying ideas of beauty, which is exacerbated by the dynamic character of the face and the human eye's rapid ability to identify abnormalities and asymmetries in movement. This is crucial when performing aesthetic operations that may result in a lovely face in terms of stature but not so much in terms of movement. This insight has inspired some surgeons to capture movies of their aesthetic surgery patients instead of static pictures, seeking to assess beauty in motion subjectively and objectively and not using a one-mask-fits-all strategy.

The aesthetic characterization of face beauty is difficult to pin down and cannot be reduced to a single "perfect" ratio.

Nurture society, and media exposures all interact to form our perceptions, but the speed with which we analyze a stranger's face in a fraction of a second, and with remarkably identical judgments across cultures, suggests a likely hardwired basis rooted in evolutionary biology.

As a theory, the golden ratio is appealingly simple and alluring, but it is ultimately incomplete. The search for a unifying theory continues, yet evidence exists to support universally enduring standards of beauty based on similar mathematical concepts (72). As for 2022 there is still no inclusive evidence, study or research that support the idea that the “golden ratio” defines humans’ beauty and attractiveness but it is obvious that along the facial aesthetic field, doctors applying this ratio in outstanding satisfying fashion and favorable results which may imply in other words that attractiveness can be measures symmetrically.



**Figure 14.** "How to Draw a Golden Triangle Spiral" by Patrick Hoesly is licensed under CC BY 2.0. To view a copy of this license, visit <https://creativecommons.org/licenses/by/2.0/?ref=openverse>.

### **13. Conclusion**

There are various components to facial aging that are not restricted to soft tissue alone. Loss of volume, which is most noticeable in the midface, and cheek flaccidity, which causes "jowling" of the lower face are two key characteristics. There are pigment changes, vascular ectasias, and epidermal keratoses, as well as the production of dynamic and static lines.

Face rhytides, photodamage, and scarring can all be treated with laser resurfacing. CO2 lasers' precise control over the extent of tissue vaporization reduces thermal injury to the skin, lowering the risk of scarring while increasing therapeutic efficacy. Laser resurfacing's clinical, histologic, and ultrastructural benefits in reversing photoaging's cumulative effects are outstanding and repeatable. The mechanisms by which these changes occur will become apparent with time and increased investigation. New technologies will definitely emerge that will allow us to harness the power of lasers even more effectively, allowing our patients to fully benefit from cutaneous laser resurfacing.

For tightening and regenerating wrinkled, photoaged face skin and contouring facial skin laxity, non-ablative radiofrequency is an effective and non-invasive treatment. It works on the basis of stimulus repair, which involves the production of new collagen and elastin as well as the reversal of clinical and histological symptoms of aging. The technique also has the benefit of being generally risk-free and requiring little to no downtime.

Microneedling is a safe, minimally invasive, and effective esthetic treatment option for acne and other scars, rhytides, and striae, among other dermatologic diseases. Microneedling is a great option of more invasive procedures like laser skin resurfacing and deep chemical peeling because of its quick recovery time, low risk of side effects, and remarkable clinical results.

Fillers for face rejuvenation are a common minimally invasive procedure for combating clinical signs of facial aging. Deep supraperiosteal filler insertion to restore midfacial volume loss has proven to be a dependable strategy for restoring a young facial appearance. Longer filler efficacy has been found with this approach for HA filler, this cannot be explained just by the fact that imitation musculature has less influence as previously discussed but these already subjected for Botox treatment adjuvant therapy. The deep midfacial filler injection has some positive impacts on nearby esthetic units such as tear trough deformity, nasolabial folds, and upper lip position. This will also cut down on the amount of filler required to get the appropriate clinical results if the crosslink product will be higher

Correction of midfacial volume loss should be the first step in facial rejuvenation planning. Midfacial filler injections are an important part of achieving a more youthful appearance and improving facial appearance.

It has long-lasting benefits, which are most likely due to the activation of white adipose tissue stem cells beneath the skin.

Dermal fillers come in a variety of kinds to treat various signs of aging. Fillers can plump up thinning lips, enhance or fill in shallow areas on the face, decrease or remove the shadow or wrinkle under the eyes caused by the lower eyelid, fill in or soften the look of recessed scars, and fill in or soften static wrinkles, particularly on the lower face, depending on the filler chosen.

For the treatment of face aging, proper evaluation and application of these minimally or less invasive treatments resulted in a younger and healthier appearance. Botox is one of the most popular nonsurgical procedures. This neurotoxin, when used in combination with fillers, has a low risk, effectively treats skin aging, and also prevents or lowers various elements and characteristics of the aging process in the face. Chemical peels can also help to achieve a more youthful facial appearance by improving skin tone and brightness as combination therapy.

Botox is only effective on wrinkles induced by muscular activity. Dynamic wrinkles, often known as "expression lines," are this type of wrinkle.

Lines on the upper face, such as the "11" between the brows, horizontal lines on the forehead, and crow's feet around the eyes, are the most prevalent dynamic wrinkles that



Botox can improve. Smiling, frowning, squinting, and other facial expressions generate these lines, and it is ineffective for fine lines and wrinkles produced by sagging or a lack of facial plumpness to be treated that way (static wrinkles are what they're called) and the lines in the cheeks, neck, and jowls are examples of this.

Botox isn't a long-term solution, treatments must be repeated in order to maintain the wrinkle-reducing results and its effect usually lasts 3 to 4 months for most people.

The creases around the mouth and along the cheeks are examples of static wrinkles their loss of collagen and flexibility in the skin is their most common cause.

In summary, the following are the differences between Botox and fillers:

Botox - This injection temporarily paralyzes muscles, preventing creases and wrinkles caused by facial expressions. These are most commonly found on the upper face, particularly the forehead and around the eyes.

Hyaluronic acid and related chemicals are used in dermal fillers to "fill in" or plump regions that have lost volume and smoothness. Wrinkles around the mouth, thin lips, and hollow cheeks are examples of this. They can also be used to fill in wrinkles on the forehead, scars, and other places that need more volume for a smoother appearance.

The outcomes of dermal fillers vary depending on the type of filler utilized. Because Botox and fillers are two different substances with different purposes, they can sometimes be used in the same therapy. Botox can be used to treat wrinkles between the eyes, and a filler can be used to treat smile lines around the lips. Botox and filler procedures are performed in millions every year, and they have a proven track record of safety when performed by skilled board-certified physician, Botox and filler procedures are quite safe, only about 1% of people experienced side effects and the most of these were minor. Even though they are minimally intrusive, they still come with some dangers.

Before undergoing these therapies, an individual should be aware of all potential dangers and advantages. Botox and fillers are not advised for pregnant or breastfeeding women and are not recommended for those with specific health concerns or who are taking drugs. People should also talk about what Botox and fillers may accomplish for them in terms of aesthetics. Though they can help you seem younger but the results are usually not as dramatic as a surgical operation like a facelift since it is fine esthetics procedure and prolonged until solid results are maintained.

Using a qualified medical specialist, such as a board-certified dermatologist, plastic surgeon, or cosmetic surgeon, ensures that the operation is carried out safely and correctly. Before making a decision, people should inquire about the provider's experience and training in dermal fillers and Botox.



Figure 15. Botox and Fillers site of injections. (73)

## **14. Acknowledgements**

I would like to thank my mentor, Doctor Anto Dujmović (AP. dr. sc.) for the help, patience and every advice given while writing this thesis.

My profound gratitude goes out to my parents, siblings, friends, and acquaintances for their patience, motivation and support.

## **15. References**

1. Gassner HG, Rafii A, Young A, Murakami C, Moe KS, Larrabee WF. Surgical anatomy of the face: implications for modern face-lift techniques. *Arch Facial Plast Surg*. 2008;10(1):9–19.
2. The Fat Compartments of the Face: Anatomy and Clinical Impl... : Plastic and Reconstructive Surgery [Internet]. [cited 2022 Apr 7]. Available from: [https://journals.lww.com/plasreconsurg/Abstract/2007/06000/The\\_Fat\\_Compartments\\_of\\_the\\_Face\\_\\_Anatomy\\_and.36.aspx](https://journals.lww.com/plasreconsurg/Abstract/2007/06000/The_Fat_Compartments_of_the_Face__Anatomy_and.36.aspx)
3. Prendergast P. Minimally Invasive Face and Neck Lift Using Silhouette Coned Sutures. In: Serdev N, editor. *Miniinvasive Face and Body Lifts - Closed Suture Lifts or Barbed Thread Lifts* [Internet]. InTech; 2013 [cited 2022 May 21]. Available from: <http://www.intechopen.com/books/miniinvasive-face-and-body-lifts-closed-suture-lifts-or-barbed-thread-lifts/minimally-invasive-face-and-neck-lift-using-silhouette-coned-sutures>
4. Furnas DW. The retaining ligaments of the cheek. *Plast Reconstr Surg*. 1989;83(1):11–6.
5. Stuzin JM, Baker TJ, Gordon HL. The relationship of the superficial and deep facial fascias: relevance to rhytidectomy and aging. *Plast Reconstr Surg*. 1992;89(3):441–9.
6. Mitz V, Peyronie M. The superficial musculo-aponeurotic system (SMAS) in the parotid and cheek area. *Plast Reconstr Surg*. 1976;58(1):80–8.
7. Gardetto A, Dabernig J, Rainer C, Piegger J, Piza-Katzer H, Fritsch H. Does a superficial musculoaponeurotic system exist in the face and neck? An anatomical study by the tissue plastination technique. *Plast Reconstr Surg*. 2003;111(2):664–72.
8. Ghassemi A, Prescher A, Riediger D, Axer H. Anatomy of the SMAS revisited. *Aesthetic Plast Surg*. 2003;27(4):258–64.
9. Prendergast PM. Anatomy of the face and neck. In: *Cosmetic surgery*. Springer; 2013. p. 29–45.
10. ahmed fawzy mashaly. Fawzy a fat compartments and retaining ligaments of the face [Internet]. 12:10:17 UTC [cited 2022 May 21]. Available from: <https://www.slideshare.net/fawziahmedmashali/fawzy-a-fat-compartments-and-retaining-ligaments-of-the-face>
11. Carniol PJ, Monheit G. AESTHETIC REJUVENATION CHALLENGES AND SOLUTIONS.

12. Mendelson BC, Freeman ME, Wu W, Huggins RJ. Surgical anatomy of the lower face: the premaseter space, the jowl, and the labiomandibular fold. *Aesthetic Plast Surg.* 2008;32(2):185–95.
13. Rohrich RJ, Arbique GM, Wong C, Brown S, Pessa JE. The Anatomy of Suborbicularis Fat: Implications for Periorbital Rejuvenation: *Plast Reconstr Surg.* 2009 Sep;124(3):946–51.
14. Mendelson BC, Muzaffar AR, Adams WP. Surgical Anatomy of the Midcheek and Malar Mounds: *Plast Reconstr Surg.* 2002 Sep;110(3):885–96.
15. Silva MTT, Curi AL. Blindness and total ophthalmoplegia after aesthetic polymethylmethacrylate injection: case report. *Arq Neuropsiquiatr.* 2004;62:873–4.
16. McCleve DE, Goldstein JC. Blindness secondary to injections in the nose, mouth, and face: cause and prevention. *Ear Nose Throat J.* 1995;74(3):182–8.
17. Feinendegen DL, Baumgartner RW, Vuadens P, Schroth G, Mattle HP, Regli F, et al. Autologous fat injection for soft tissue augmentation in the face: a safe procedure? *Aesthetic Plast Surg.* 1998;22(3):163–7.
18. Coleman SR. Avoidance of arterial occlusion from injection of soft tissue fillers. *Aesthet Surg J.* 2002;22(6):555–7.
19. Beral V, Evans S, Shaw H, Milton G. Cutaneous factors related to the risk of malignant melanoma. *Br J Dermatol.* 1983 Aug;109(2):165–72.
20. Weinstock MA. Assessment of sun sensitivity by questionnaire: validity of items and formulation of a prediction rule. *J Clin Epidemiol.* 1992 May;45(5):547–52.
21. Youn JI, Oh JK, Kim BK, Suh DH, Chung JH, Oh SJ, et al. Relationship between skin phototype and MED in Korean, brown skin. *Photodermatol Photoimmunol Photomed.* 1997 Oct 12;13(5–6):208–11.
22. Sachdeva S. Fitzpatrick skin typing: Applications in dermatology. *Indian J Dermatol Venereol Leprol.* 2009;75(1):93.
23. Sambandan DR, Ratner D. Sunscreens: an overview and update. *J Am Acad Dermatol.* 2011;64(4):748–58.
24. Hughes MCB, Williams GM, Baker P, Green AC. Sunscreen and prevention of skin aging: a randomized trial. *Ann Intern Med.* 2013;158(11):781–90.
25. Wang SQ, Balagula Y, Osterwalder U. Photoprotection: a review of the current and future technologies. *Dermatol Ther.* 2010;23(1):31–47.
26. Xu S, Kwa M, Agarwal A, Rademaker A, Kundu RV. Sunscreen product performance and other determinants of consumer preferences. *JAMA Dermatol.* 2016;152(8):920–7.

27. Mancuso JB, Maruthi R, Wang SQ, Lim HW. Sunscreens: an update. *Am J Clin Dermatol.* 2017;18(5):643–50.
28. Verschoore M, Nielson M. The Rationale of Anti-Aging Cosmetic Ingredients. *J Drugs Dermatol JDD.* 2017;16(6):s94–7.
29. Nusgens BV, Colige AC, Lambert CA, Lapière CM, Humbert P, Rougier A, et al. Topically applied vitamin C enhances the mRNA level of collagens I and III, their processing enzymes and tissue inhibitor of matrix metalloproteinase 1 in the human dermis. *J Invest Dermatol.* 2001;116(6):853–9.
30. Murray JC, Burch JA, Streilein RD, Iannacchione MA, Hall RP, Pinnell SR. A topical antioxidant solution containing vitamins C and E stabilized by ferulic acid provides protection for human skin against damage caused by ultraviolet irradiation. *J Am Acad Dermatol.* 2008;59(3):418–25.
31. Hubbard BA, Unger JG, Rohrich RJ. Reversal of skin aging with topical retinoids. *Plast Reconstr Surg.* 2014;133(4):481e–90e.
32. Chiu A, Kimball AB. Topical vitamins, minerals and botanical ingredients as modulators of environmental and chronological skin damage. *Br J Dermatol.* 2003;149(4):681–91.
33. Mukherjee S, Date A, Patravale V, Korting HC, Roeder A, Weindl G. Retinoids in the treatment of skin aging: an overview of clinical efficacy and safety. *Clin Interv Aging.* 2006 Dec;1(4):327–48.
34. Monheit GD, Chastain MA. Chemical peels. *Facial Plast Surg Clin N Am.* 2001 May 1;9(2):239–55, viii.
35. Hevia O, Nemeth AJ, Taylor JR. Tretinoin accelerates healing after trichloroacetic acid chemical peel. *Arch Dermatol.* 1991 May;127(5):678–82.
36. Grimes PE. A microsponge formulation of hydroquinone 4% and retinol 0.15% in the treatment of melasma and postinflammatory hyperpigmentation. *Cutis.* 2004 Dec;74(6):362–8.
37. Sharad J. Glycolic acid peel therapy – a current review. *Clin Cosmet Investig Dermatol.* 2013 Nov 11;6:281–8.
38. Pathak A, Mohan R, Rohrich RJ. Chemical Peels: Role of Chemical Peels in Facial Rejuvenation Today. *Plast Reconstr Surg.* 2020 Jan;145(1):58e.
39. Preissig J, Hamilton K, Markus R. Current Laser Resurfacing Technologies: A Review that Delves Beneath the Surface. *Semin Plast Surg.* 2012 Aug;26(3):109–16.
40. Hirsch RJ, Dayan SH, Shah AR. Superficial skin resurfacing. *Facial Plast Surg Clin.* 2004;12(3):311–21.

41. Pozner JN, DiBernardo BE. Laser Resurfacing. *Clin Plast Surg.* 2016 Jul;43(3):515–25.
42. Karimipour DJ, Karimipour G, Orringer JS. Microdermabrasion: An Evidence-Based Review: *Plast Reconstr Surg.* 2010 Jan;125(1):372–7.
43. Hirsch RJ, Dayan SH, Shah AR. Superficial skin resurfacing. *Facial Plast Surg Clin N Am.* 2004 Aug;12(3):311–21.
44. Kim JMS and JE. Radiofrequency in Clinical Dermatology. *Med Lasers.* 2013 Dec 30;2(2):49–57.
45. Bonjorno AR, Gomes TB, Pereira MC, Carvalho CM, Gabardo MCL, Kaizer MR, et al. Radiofrequency therapy in esthetic dermatology: A review of clinical evidences. *J Cosmet Dermatol.* 2020 Feb;19(2):278–81.
46. Zelickson BD, Kist D, Bernstein E, Brown DB, Ksenzenko S, Burns J, et al. Histological and Ultrastructural Evaluation of the Effects of a Radiofrequency-Based Nonablative Dermal Remodeling Device: A Pilot Study. *Arch Dermatol.* 2004 Feb 1;140(2):204–9.
47. Dendle J, Wu DC, Fabi SG, Melo D, Goldman MP. A Retrospective Evaluation of Subsurface Monopolar Radiofrequency for Lifting of the Face, Neck, and Jawline. *Dermatol Surg.* 2016 Nov;42(11):1261–5.
48. Gutowski KA. Microfocused Ultrasound for Skin Tightening. *Clin Plast Surg.* 2016 Jul;43(3):577–82.
49. Minkis K, Alam M. Ultrasound Skin Tightening. *Dermatol Clin.* 2014 Jan;32(1):71–7.
50. Suh DH, Shin MK, Lee SJ, Rho JH, Lee MH, Kim NI, et al. Intense Focused Ultrasound Tightening in Asian Skin: Clinical and Pathologic Results. *Dermatol Surg.* 2011 Nov;37(11):1595–602.
51. Bunin LS, Carniol PJ. Cervical Facial Skin Tightening with an Infrared Device. *Facial Plast Surg Clin N Am.* 2007 May;15(2):179–84.
52. McCrudden MTC, McAlister E, Courtenay AJ, González-Vázquez P, Raj Singh TR, Donnelly RF. Microneedle applications in improving skin appearance. *Exp Dermatol.* 2015 Aug;24(8):561–6.
53. Ablon G. Safety and Effectiveness of an Automated Microneedling Device in Improving the Signs of Aging Skin. *J Clin Aesthetic Dermatol.* 2018 Aug;11(8):29–34.
54. Alster TS, Graham PM. Microneedling: A Review and Practical Guide. *Dermatol Surg.* 2018 Mar;44(3):397–404.

55. Kim SE, Lee JH, Kwon HB, Ahn BJ, Lee AY. Greater Collagen Deposition with the Microneedle Therapy System Than with Intense Pulsed Light. *Dermatol Surg.* 2011 Mar;37(3):336–41.
56. Bonaparte JP, Ellis D, Quinn JG, Rabski J, Hutton B. A Comparative Assessment of Three Formulations of Botulinum Toxin Type A for Facial Rhytides: A Systematic Review with Meta-Analyses. *Plast Reconstr Surg.* 2016 Apr;137(4):1125–40.
57. Hogan S, Beleznav K, Carruthers J. Forehead Rejuvenation. *Adv Cosmet Surg.* 2020 Jun;3(1):109–21.
58. Trévidic P, Sykes J, Criollo-Lamilla G. Anatomy of the Lower Face and Botulinum Toxin Injections: *Plast Reconstr Surg.* 2015 Nov;136:84S-91S.
59. de Maio M, DeBouille K, Braz A, Rohrich RJ. Facial Assessment and Injection Guide for Botulinum Toxin and Injectable Hyaluronic Acid Fillers: Focus on the Midface. *Plast Reconstr Surg.* 2017 Oct;140(4):540e–50e.
60. Lemperle G, Anderson R, Knapp TR. An Index for Quantitative Assessment of Lip Augmentation. *Aesthet Surg J.* 2010 May 1;30(3):301–10.
61. <https://en.ermateb.com/blog/Lip-Fillers-Techniques>
62. de Maio M, Wu WTL, Goodman GJ, Monheit G. Facial Assessment and Injection Guide for Botulinum Toxin and Injectable Hyaluronic Acid Fillers: Focus on the Lower Face. *Plast Reconstr Surg.* 2017 Sep;140(3):393e–404e.
63. Donofrio L. Techniques in Facial Fat Grafting. *Aesthet Surg J.* 2008 Nov;28(6):681–7.
64. Kranendonk S, Obagi S. Autologous Fat Transfer for Periorbital Rejuvenation: Indications, Technique, and Complications. *Dermatol Surg.* 2007 May;33(5):572–8.
65. Grow JN, Holding J, Korentager R. Assessing the Efficacy of Deoxycholic Acid for the Treatment of Submental Fat: A Three-Dimensional Study. *Aesthet Surg J.* 2019 Nov 13;39(12):1400–11.
66. Jain M, Savage NE, Spiteri K, Snell BJ. A 3-Dimensional Quantitative Analysis of Volume Loss Following Submental Cryolipolysis. *Aesthet Surg J.* 2020 Jan 29;40(2):123–32.
67. Stroumza N, Gauthier N, Senet P, Moguelet P, Nail Barthelemy R, Atlan M. Paradoxical Adipose Hypertrophy (PAH) After Cryolipolysis. *Aesthet Surg J.* 2018 Mar 14;38(4):411–7.
68. Prokopakis EP, Vlastos IM, Picavet VA, Nolst Trenite G, Thomas R, Cingi C, et al. The golden ratio in facial symmetry. *Rhinol J.* 2013 Mar 1;51(1):18–21.



69. Golden ratio for female face morphs 1 by Fascinator01 on DeviantArt [Internet]. [cited 2022 May 21]. Available from: <https://www.deviantart.com/fascinator01/art/Golden-ratio-for-female-face-morphs-1-856673682>
70. The Golden Ratio and Facial Beauty - Dr. Eddie Siman [Internet]. TMJ Expert. [cited 2022 May 21]. Available from: <https://tmjexpert.com/blog/all-about-the-golden-ratio/>
71. Kim YH. Easy Facial Analysis Using the Facial Golden Mask. *J Craniofac Surg*. 2007 May;18(3):643–9.
72. Singh P, Vijayan R, Mosahebi A. The Golden Ratio and Aesthetic Surgery. *Aesthet Surg J*. 2019 Jan 1;39(1):NP4–5.
73. What's The Difference Between Botox And Dermal Fillers? [Internet]. Southeastern Dermatology. 2021 [cited 2022 Jun 9]. Available from: <https://www.drdoppelt.com/botox-vs-fillers/>

## **16. Biography**

Daniel Neamat Zaid was born in Eilat, Israel, on January 5, 1992.

After finishing kindergarten in a collective community settlement called Grofit, his family decided to relocate themselves back to Eilat, Israel's most far city in the south. While attending the school system in the town, Daniel was most intrigued in high school with physics and mathematics in his extracurriculars. After graduating, He joined the air force division as a pilot for six months during his mandatory military services. For incompatibility reasons, he continues the rest of his service as a combat warrior and commander in the bomb-sniffing squad - "Oketz K9" unit. Daniel worked as a deputy chief security in Royal Caribbean for two years following the army. In between the contracts, while having a kite surfing trip in the Dominican Republic, he experienced a surfing injury. The spinal fracture midshaft of the right femur made him resign from the company and start intensive physiotherapy back in his hometown. It was then that he finally realized what was his most significant interest and perhaps life passion as it is running in his family. As he was raised in a surrounding of his grandfather Dr. Zaid Jaime (RIP), who was the head of the Anesthesiology department in Yoseftal hospital Eilat, his mom Yafa Zaid who works as deputy chief nurse in the Gynecology department in the same hospital, and his father who works as an x-ray technician.

Daniel decided to apply for pre-med school to pursue his destiny and prepare for the European medical faculties entrance exams and eventually scored the top 3 high scores in his class. In the end, he decided to enroll in the Faculty of Medicine at the University of Zagreb in 2016.

In 2020, he was elected to lead the class as a student representative along with his colleague Kilian Wieland. During his studies, he became active in many student societies and volunteered in the public health institute alongside Prof. Marjeta Majer in the Covid-19 vaccination operation. During his 3-month clinical rotations, he has worked in the emergency room at the University hospital centre Rebro, as well as in the plastic ward of the surgery department at the same hospital. He is actively involved in sports, speaks Hebrew, English, Croatian and Spanish, and has traveled the world.