

Spontaneous spinal subdural hematoma in COVID-19 patient: Croatian national COVID hospital experience

Dlaka, Domagoj; Vavro, Hrvoje; Romić, Dominik; Almahariq, Fadi; Chudy, Darko; Lukšić, Ivica; Raguž, Marina

Source / Izvornik: **Surgical Neurology International, 2022, 13**

Journal article, Published version

Rad u časopisu, Objavljena verzija rada (izdavačev PDF)

https://doi.org/10.25259/SNI_87_2022

Permanent link / Trajna poveznica: <https://urn.nsk.hr/urn:nbn:hr:105:015021>

Rights / Prava: [Attribution-NonCommercial-ShareAlike 4.0 International/Imenovanje-Nekomercijalno-Dijeli pod istim uvjetima 4.0 međunarodna](#)

Download date / Datum preuzimanja: **2024-11-02**



Repository / Repozitorij:

[Dr Med - University of Zagreb School of Medicine
Digital Repository](#)





Case Report

Spontaneous spinal subdural hematoma in COVID-19 patient: Croatian national COVID hospital experience

Domagoj Dlaka^{1,2}, Hrvoje Vavro^{2,3}, Dominik Romić^{1,2}, Fadi Almahariq^{1,2}, Darko Chudy^{1,2,4}, Ivica Lukšić^{2,5}, Marina Raguz^{1,2,6}

¹Department of Neurosurgery, ²Primary respiratory intensive care centre, ³Department of Diagnostic and Interventional Radiology, Dubrava University Hospital, ⁴Department of Surgery, ⁵Department of Maxillofacial Surgery, Dubrava University Hospital, University of Zagreb School of Medicine, ⁶Catholic University of Croatia, School of Medicine, Zagreb, Croatia.

E-mail: Domagoj Dlaka - domagojdlaka@gmail.com; Hrvoje Vavro - hrvavro@gmail.com; Dominik Romić - dominikromic00@gmail.com; Fadi Almahariq - fadi.almahariq@gmail.com; Darko Chudy - darko.chudy@gmail.com; Ivica Luksic - luksic@kdb.hr; *Marina Raguz - marinaraguz@gmail.com



*Corresponding author:

Marina Raguz,
Department of Neurosurgery,
University Hospital Dubrava,
Zagreb, Croatia.

marinaraguz@gmail.com

Received : 21 January 2022

Accepted : 29 July 2022

Published : 02 September 2022

DOI

10.25259/SNI_87_2022

Quick Response Code:



ABSTRACT

Background: Spontaneous spinal subdural hematoma (SSDH) is a rare condition and causes of acute spinal cord compression, with symptoms varying from mild to severe neurological deficit. SSDH could occur as a consequence of posttraumatic, iatrogenic, or spontaneous causes, including underlying arteriovenous malformations, tumors, or coagulation disorder. Due to its rarity, it is difficult to establish standardized treatment. We present a rare case of SSDH in COVID-19 patient and course of treatment in COVID hospital.

Case Description: A 71-year-old female patient was admitted due to instability, weakness of the left leg, and intensive pain in the upper part of thoracic spine as well as mild respiratory symptoms of COVID-19. She was not on pronounced anticoagulant therapy and her coagulogram at admission was within normal range. MRI revealed acute subdural hematoma at the level C VII to Th III compressing the spinal cord. The patient underwent a decompressive Th I and Th II laminectomy and hematoma evacuation. Post-operative MRI revealed a satisfactory decompression and re-expansion of the spinal cord. COVID-19 symptoms remained mild.

Conclusion: SSDH represents a neurological emergency, possibly leading to significant deficit and requires urgent recognition and treatment. One of the main difficulties when diagnosing is to consider such condition when there is no history of anticoagulant treatment or previous trauma. Since high incidence of coagulation abnormalities and thromboembolic events was described COVID-19 patients, when considering the pathology of the central nervous system, the bleeding within it due to COVID-19 should be taken into account, in both brain and spine.

Keywords: COVID-19, Neurosurgery, Spontaneous spinal subdural hematoma

INTRODUCTION

Coronavirus disease 2019 (COVID-19) stands for novel infection that led to worldwide pandemic, caused by Severe Acute Respiratory Syndrome CoronaVirus-2 (SARS-Cov2). Different clinical outcomes have been observed in patients, ranging from asymptomatic, mild or moderate disease to severe, and progressive pneumonia leading to acute respiratory distress syndrome and multisystem organ failure.^[1,2,4,10] Although most of the COVID-19 patients have respiratory infection, a number of patients developed coagulation abnormalities.^[1,2,5]

This is an open-access article distributed under the terms of the Creative Commons Attribution-Non Commercial-Share Alike 4.0 License, which allows others to remix, transform, and build upon the work non-commercially, as long as the author is credited and the new creations are licensed under the identical terms.

©2022 Published by Scientific Scholar on behalf of Surgical Neurology International

Spontaneous spinal subdural hematoma (SSDH), a rare acute or subacute condition and cause of acute spinal cord compression accounting approximately for 4.1% of spinal hematomas, was firstly reported in 1948 by Schiller *et al.* [3,6,12,16,18-20] SSDH leads to spinal cord or cauda equine compression, with symptoms varying from mild-to-severe neurological deficit, causing devastating neurological consequences, even death. [3,14,16,17] SSDH could occur as a consequence of posttraumatic, iatrogenic, or spontaneous, that is, idiopathic causes, including underlying arteriovenous malformations or tumors and coagulation disorder. [3,6,12,14,16,20] In spontaneous cases, diagnosis may be frequently delayed. [19,20] Taken into account the SSDH rarity, it is quite difficult to establish standardized treatment.

Hereby, we present a rare case of SSDH in COVID-19 patient and course of treatment in Croatian national COVID hospital.

CASE DESCRIPTION

History

A 71-year-old female patient was admitted due to dizziness, instability, and intensive pain in the upper part of thoracic spine. Initial neurological examination revealed the left leg monoparesis, lower extremity reflexes were lively presented, accompanied with positive Babinski sign on the left. Initial

brain CT was unremarkable and initial chest X-ray revealed no inflammation infiltrates; thoracic spine and pelvis CT revealed degenerative changes that corresponded to age.

At the admission, she was tested with fast antigen SARS-CoV-2 and SARS-CoV-2 RT PCR test (three sequences), both tests were positive. The patient had mild respiratory symptoms of COVID-19 and was afebrile.

Before admission, the patient was taking acetylsalicylic acid 100 mg due to stents implanted more than 10 years ago, and in hospital 0.3 ml of Clexane was administered daily. Coagulogram at the admission was inside normal range (*D-dimers* 0.66, *CRP* 1.8). Within 3 days from admission, she developed left leg plegia, severe right leg paresis, and hypoesthesia at the Th10 level on the left and at the Th8 level on the right side and was not able to control the sphincters.

MRI revealed acute subdural hematoma at the level C VII to Th III, length 55 mm and 6 mm thick; in segments C V to Th III the elevated spinal cord signal corresponds to compression myelopathy [Figure 1].

Operation

The patient underwent a decompressive laminectomy of levels Th I and Th II. After subdural hemorrhage evacuation, a small coil of thrombosed blood vessels partially adherent to the arachnoid and thoracic roots laterally was completely

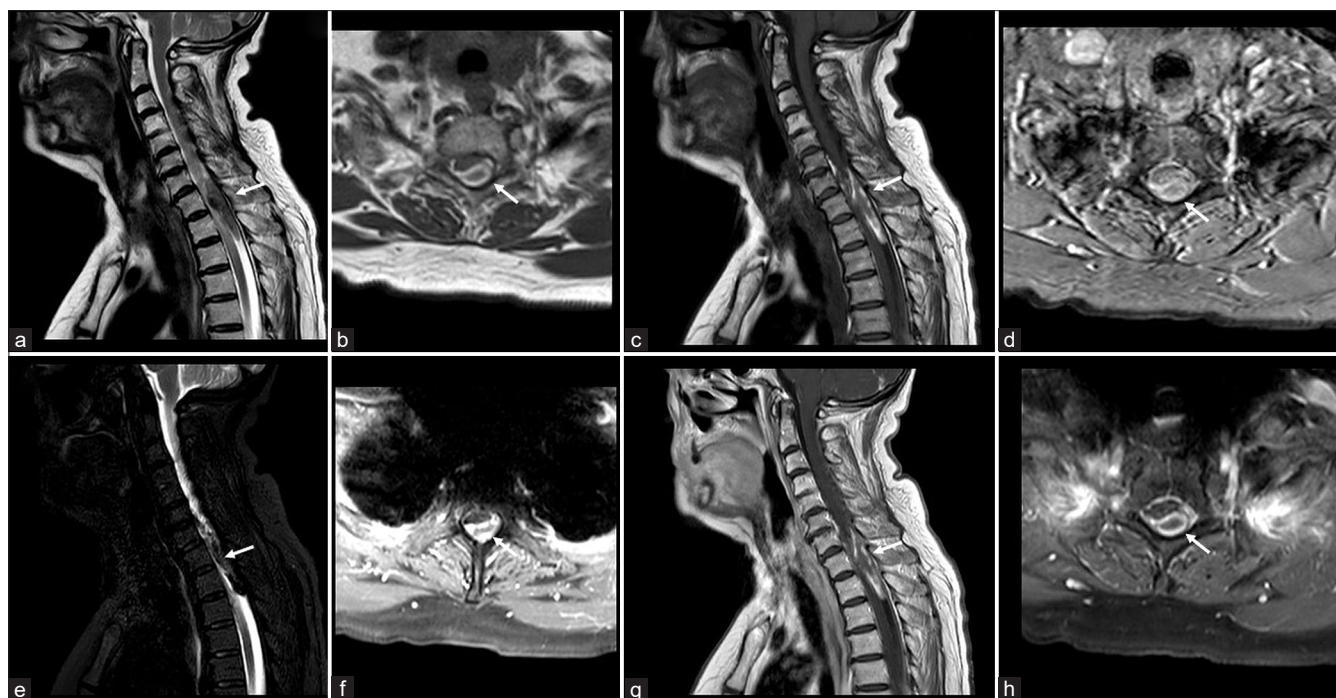


Figure 1: Initial MRI of the cervical and proximal thoracic spine. Sagittal T2WI (a), axial T2WI (b), sagittal T1WI (c), axial T1WI (d), sagittal STIR (e), and axial STIR (f) images demonstrate an inhomogeneous intradural extramedullary collection in the posterior spinal canal at levels C VII to Th III, compressing the spinal cord. There is also some T1-hyperintense material in the anterior subdural space. Postcontrast sagittal T1wi (g) and axial FS T1WI (h) do not demonstrate any contrast enhancement. The hematoma location is marked with white arrow in all images.

removed without any damage to the neural structure. The surgery went without any complications. Postoperative MRI revealed a satisfactory postoperative finding, including good decompression and re-expansion of the spinal cord with regression of myelopathy [Figure 2].

Postoperative course

Postoperatively, CRP levels were increased, with peak of 41.9 on 2nd postoperative day, and lowering to 1.8, while the levels of D-dimers were also increased (> 4.37) and persisted until discharge. The left leg was paretic with movements in knee joint and foot, right leg recovered completely, while full control of the sphincters was not regained. COVID-19 symptoms remained mild. The patient was further appointed to stationary medical rehabilitation.

DISCUSSION

SSDH is a rare, uncommon condition characterized by a sudden onset of headache, back pain, or radicular pain and has rapid progression of spinal cord compression symptoms such as sensorimotor change, autonomous function, and neurogenic bladder.^[3,8,11,12,16,19,20] Early diagnosis of SSDH is essential, because the compression can compromise the spinal cord and/or roots of the cauda equina, resulting in permanent neurologic deficit or death.^[6,20] SSDH usually presents in between 45 and 60 years of life, with a slight

female predominance, predominantly in the thoracic spine, followed by the cervicothoracic and thoracolumbar spine.^[3,14,16,19,20] Previously, SSDH was clinically classified in four levels; grade 0 = normal, I = weakness, pain and/or mild hypoesthesia, II = invalidating paresis and level of hypoesthesia, and III = abolished motor and sensory capacities.^[7]

Although only several spontaneous cases were described in literature, to the best of our knowledge, this is the one of a very few cases described in COVID-19 patient.^[9,15] Our patient was not on pronounced anticoagulant therapy and her coagulogram at admission was within normal range.

The determination of the SSDH pathogenesis is very challenging. Although several different theories were previously suggested, it has been generally accepted that SSDH may originate from within the subdural space, or due to subarachnoid vessels rupture in the subdural space, following an acute rise of abdominal or intrathoracic pressure, such as yawning or coughing.^[17,19,20]

It has been described that approximately 70% of COVID-19 treated patients developed coagulation abnormalities and autopsy revealed almost 58% of patients died due to venous thrombosis and pulmonary embolism.^[1-3,5] COVID-19-associated coagulopathy presents with prominent elevation of D-dimer and fibrin/fibrinogen-degradation products, whereas abnormalities in prothrombin time, partial thromboplastin time, and platelet counts are relatively uncommon in initial presentations.^[5]

Although the detailed molecular mechanism of SARS-CoV-2-mediated hypercoagulation is unclear, it has been discussed that COVID-19 infection could induce coagulation disorder leading to overt clot formation, pulmonary embolism, and serious effects on patient recovery and survival^[2] with the high incidence of thromboembolic events described in COVID-19 patients.^[13,21] Further, research suggests SARS-CoV-2 virus attachment to the angiotensin-2 receptor of the endothelial cells lead to pro-inflammatory cytokines release, endothelial dysfunction, and systemic inflammation.^[1] Previously suggested mechanism could offer explanation of SSDH in our patient; COVID-19-associated coagulopathy can cause thrombolytic incidents, while cough due to respiratory symptoms could contribute to increased intra-abdominal and intrathoracic pressure, leading to spinal subarachnoid hemorrhage progressing to subdural hematoma. The hemorrhage started gradually expanding through subdural space, which confirmed by intraoperative finding, where we found diffuse hematoma and a minor part which was like a nidus, bound to the arachnoid, and strongly imprinted in the medulla.

When symptoms suggest a spinal cord compression due to a spinal hematoma, MRI appears to be the gold standard

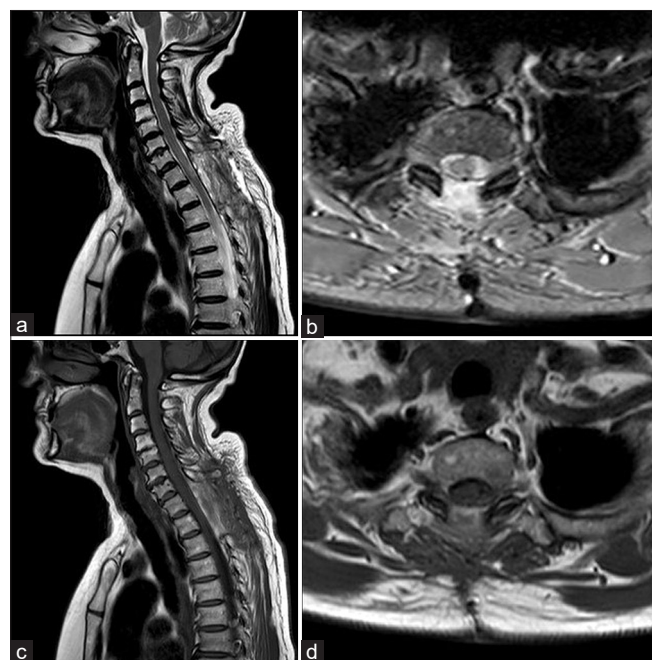


Figure 2: MRI of the cervical and proximal thoracic spine after surgical evacuation of the collection. Sagittal T2WI (a), axial T2WI (b), sagittal T1WI (c), and axial T1WI (d). The collection has been completely removed, there is almost complete re-expansion of the spinal cord.

and the modality of choice, providing information on the exact level of the hematoma, degree of nervous structures compression, and consequence for the spinal cord.^[3,12,19] SSDH diagnosis is challenging, particularly in idiopathic cases, sometimes resulting in delayed management; the time from the onset of hemorrhage to the clinical presentation can vary from a few hours to a few months.^[19,20] Due to the few reported cases, the management of SSDH is not well standardized.^[3] Emergency surgical decompression by laminectomy and evacuation of the hematoma is gold standard in the management of the patients with severe or deteriorating neurological impairment, while some authors reported satisfactory results using conservative treatment such as intravenous methylprednisolone injection therapy with strict rest for patients with minor and recovering neurologic deficits.^[3,6,12,19,20] The prognosis of SSDH depends on the preoperative neurologic status, symptom duration, and spinal hematoma location.

CONCLUSION

SSDH represents a neurological emergency, possibly leading to significant deficit and requires urgent recognition and treatment. One of the main difficulties when diagnosing is to consider such condition when there is no history of anticoagulant treatment or the previous trauma. Since it has been shown that COVID-19 increases the incidence of thromboembolic incidents, when considering the pathology of the central nervous system, the bleeding within it due to COVID-19 should be taken into account, not only in the brain but also in the spine.

Compliance with ethical standards

The patient has given informed consent for participation in this paper.

Declaration of patient consent

The authors certify that they have obtained all appropriate patient consent.

Financial support and sponsorship

Nil.

Conflicts of interest

There are no conflicts of interest.

REFERENCES

1. Al-Samkari H, Leaf RS, Dzik WH, Carlson JC, Fogerty AE, Waheed A, *et al.* COVID-19 and coagulation: Bleeding and thrombotic manifestations of SARS-CoV-2 infection. *Blood* 2020;136:489-500.
2. Biswas I, Khan GA. Coagulation disorders in COVID-19: Role of toll-like receptors. *J Inflamm Res* 2020;13:823-28.
3. Benyaich Z, Laghmari M, Lmejjati M, Aniba K, Ghannane H, Benali SA. Acute lumbar spinal subdural hematoma inducing paraplegia after lumbar spinal manipulation: Case report and literature review. *World Neurosurg* 2019;128:182-85.
4. Chen N, Zhou M, Dong X, Qui J, Yu T, Liu Y, *et al.* Epidemiological and clinical characteristics of 99 cases of 2019 novel coronavirus pneumonia in Wuhan, China: A descriptive study. *Lancet* 2020;395:507-13.
5. Connors JM, Levy JH. COVID-19 and its implications for thrombosis and anticoagulation. *Blood* 2020;135:2033-40.
6. De Beer MH, Smeets MM, Koppen H. Spontaneous spinal subdural hematoma. *Neurologist* 2017;22:34-9.
7. Domenicucci M, Ramieri A, Paolini S, Russo N, Occhiogrosso G, Di Biasi C, *et al.* Spinal subarachnoid hematomas: Our experience and literature review. *Acta Neurochir (Wien)* 2005;147:741-50.
8. Faiek S, Wazzan NI, Sompalli S, Bansal A, Hota P. A rare case presentation of apixaban-induced nontraumatic spinal subdural hematoma. *Cureus* 2020;12:e6743.
9. Goyal J, Mishra V, Sharma M, Bullagan A. Spontaneous spinal sub-dural hematoma: A rare complication in severe Covid-19 disease. *Int J Curr Res* 2021;13:18131-3.
10. Huang C, Wang Y, Li X, Ren L, Zhao J, Hu Y, *et al.* Clinical features of patients infected with 2019 novel coronavirus in Wuhan, China. *Lancet* 2020;395:497-06.
11. Jimbo H, Asamoto S, Mitsuyama T, Hatayama K, Iwasaki Y, Fukui Y. Spinal chronic subdural hematoma in association with anticoagulant therapy: A case report and literature review. *Spine (Phila Pa 1976)* 2006;31:E184-7.
12. Joubert C, Gazzola S, Sellier A, Dagain A. Acute idiopathic spinal subdural hematoma: What to do in an emergency? *Neurochirurgie* 2019;65:93-7.
13. Klok FA, Kruip MJ, van der Meer NJ, Arbous MS, Gommers DA, Kant KM, *et al.* Incidence of thrombotic complications in critically ill ICU patients with COVID-19. *Thromb Res* 2020;191:145-47.
14. Kreppel D, Antoniadis G, Seeling W. Spinal hematoma: A literature survey with meta-analysis of 613 patients. *Neurosurg Rev* 2003;26:1-49.
15. Lim SW, Wong E. Spontaneous epidural hematoma of the cervical spine in an elderly woman with recent COVID-19 infection: A case report. *Am J Case Rep* 2020;21:e926784.
16. Pereira BJ, De Almeida AN, Muio VM, De Oliveira JG, De Holanda CV, Fonseca NC. Predictors of outcome in nontraumatic spontaneous acute spinal subdural hematoma: Case report and literature review. *World Neurosurg* 2016;89:574-7.
17. Rettenmaier LA, Holland MT, Abel TJ. Acute, nontraumatic spontaneous spinal subdural hematoma: A case report and systematic review of the literature. *Case Rep Neurol Med* 2017;2017:2431041.
18. Schiller F, Neligan G, Budtz-Olsen O. Surgery in haemophilia: A case of spinal subdural haematoma producing paraplegia. *Lancet* 1948;2:842-5.
19. Vastani A, Mirza AB, Lavrador JP, Boardman TM, Khan MF,

Malik I, *et al.* Risk factor analysis and surgical outcomes of acute spontaneous spinal subdural hematoma. An institutional experience of four cases and literature review. *World Neurosurg* 2021;146:e384-97.

20. Wang B, Liu W, Zeng X. Idiopathic cervical spinal subdural haematoma: A case report and literature review. *J Int Med Res* 2019;47:1365-72.
21. Wichmann D, Sperhake JP, Lütgehetmann M, Steurer S,

Edler C, Heinemann A, *et al.* Autopsy findings and venous thromboembolism in patients with COVID-19: A prospective cohort study. *Ann Intern Med* 2020;173:268-77.

How to cite this article: Dlaka D, Vavro H, Romic D, Almahariq F, Chudy D, Luksic I, *et al.* Spontaneous spinal subdural hematoma in COVID-19 patient: Croatian national COVID hospital experience. *Surg Neurol Int* 2022;13:394.