

A rare case of giant 5 mm port-site preperitoneal small-bowel incarceration without fascial defect following laparoscopic hysterectomy

Marton, Ingrid; Sever, Marko; Prka, Matija; Šerman, Alan; Tupek, Tvrtko; Klancir, Tino

Source / Izvornik: **Journal of Obstetrics and Gynaecology, 2022, 43**

Journal article, Published version

Rad u časopisu, Objavljena verzija rada (izdavačev PDF)

<https://doi.org/10.1080/01443615.2022.2130209>

Permanent link / Trajna poveznica: <https://um.nsk.hr/um:nbn:hr:105:976211>

Rights / Prava: [Attribution-NonCommercial-NoDerivatives 4.0 International/Imenovanje-Nekomercijalno-Bez prerada 4.0 međunarodna](#)

Download date / Datum preuzimanja: **2025-02-18**



Repository / Repozitorij:

[Dr Med - University of Zagreb School of Medicine Digital Repository](#)



A rare case of giant 5 mm port-site preperitoneal small-bowel incarceration without fascial defect following laparoscopic hysterectomy

Ingrid Marton, Marko Sever, Matija Prka, Alan Šerman, Tvrtko Tupek & Tino Klancir

To cite this article: Ingrid Marton, Marko Sever, Matija Prka, Alan Šerman, Tvrtko Tupek & Tino Klancir (2023) A rare case of giant 5 mm port-site preperitoneal small-bowel incarceration without fascial defect following laparoscopic hysterectomy, *Journal of Obstetrics and Gynaecology*, 43:1, 2130209, DOI: [10.1080/01443615.2022.2130209](https://doi.org/10.1080/01443615.2022.2130209)

To link to this article: <https://doi.org/10.1080/01443615.2022.2130209>



© 2022 The Author(s). Published by Informa UK Limited, trading as Taylor & Francis Group.



Published online: 17 Oct 2022.



Submit your article to this journal [↗](#)



Article views: 576

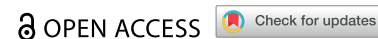

View related articles [↗](#)



View Crossmark data [↗](#)

CASE REPORT



A rare case of giant 5 mm port-site preperitoneal small-bowel incarceration without fascial defect following laparoscopic hysterectomy

Ingrid Marton^a, Marko Sever^b, Matija Prka^a, Alan Šerman^c, Tvrtko Tupek^c  and Tino Klancir^d

^aDepartment of Gynecology and Obstetrics, Clinical Hospital Sveti Duh, School of Medicine, Croatian Catholic University, Zagreb, Croatia; ^bDepartment of Surgery, Clinical Hospital Sveti Duh, School of Medicine, University of Zagreb, Zagreb, Croatia; ^cDepartment of Gynecology and Obstetrics, Clinical Hospital Sveti Duh, School of Medicine, University of Zagreb, Zagreb, Croatia; ^dDepartment of Anesthesiology, Clinical Hospital Sveti Duh, School of Medicine, University of Zagreb, Zagreb, Croatia

KEYWORDS 5 mm port-site hernia (PSH); blunt trocars; preperitoneal bowel incarceration

Introduction

The increased use of laparoscopy has resulted in certain complications specifically associated with the laparoscopic approach like port-site hernia (PSH). PSH following laparoscopic surgery is less common compared with incisional hernia occurring after open surgery. According to the literature, the incidence of PSH ranges from 0.2% to 3.1% (Swank *et al.* 2012). It is believed that port diameter and access technique affect the rate of hernia formation. In most of the reported cases, PSH appears when larger diameter port is used, in elderly and patients with higher body mass index (BMI). Extensive tissue manipulation, increased operative time and the effect of a partial vacuum while withdrawal of the port increase the risk of PSH formation (Tonouchi *et al.* 2004). Clinical signs include gross disruption of the wound and the drainage, presence of a bulge with exertion or Valsalva or painful bulge due to bowel or omentum incarceration. Patients usually present with clinical signs of bowel obstruction or infarction.

Case report

Forty-four-years old Para 4 presented second postoperative day with complaints of heavy abdominal pain and large intumescences in left lower abdomen. The patient underwent total laparoscopic hysterectomy and bilateral salpingectomy due to high squamous intraepithelial lesion that persisted after loop conisation. After placing Veress needle and producing pneumoperitoneum an 11 mm umbilical blunt trocar was placed followed by three accessory 5 mm conical blunt trocars in the right, left and suprapubic regions under direct visualisation. Specimen was removed through vagina. Course of the operation was uneventful. Second day after the operation she presented with acute abdomen. Clinical manifestations (painful continuous bulge) developed after patient's verticalisation. Computed tomography (CT) revealed

incarceration of small-bowel that measured 120 × 100 × 90 mm in the left lower abdomen. Laparoscopic exploration revealed small-bowel preperitoneal incarceration that increased by bowel peristalsis but with small fascial defect (Figure 1(a)). Incarceration was resolved laparoscopically (Figure 1(b)). Fourteen centimetre of ileum was resected due to necrosis (Figure 1(c)) through mini-laparotomy on the side of left port incision. After resolving small bowel incarceration, peritoneal, and insignificant fascial defects were visualised (Figure 1(d)). Termino-terminal 2-layer anastomosis was performed, peritoneum and fascia were closed with absorbable polyglycolic acid 2/0 suture. Although we have not measured the size of the fascial defect we believe that it did not exceed 10 mm. Histopathology revealed necrosis of the resected ileal loop. Intestinal necrosis occurred in spite of an urgent procedure, performed immediately after the CT scan. Forth postoperative day patient presented with heavy nasogastric tube retention (>4000 mL) during 12 h and with absent auscultatory signs of peristalsis. Repeated CT suspected large intestinal incarceration. Although there were no evident clinical signs of acute abdomen, on grounds of radiologic imaging appearance and previous procedures, laparotomy was performed. Bowel oedema without any signs of anastomosis disruption was revealed. Patient suffered from prolonged postoperative paralytic ileus that was resolved 6 d after the open surgery. She was discharged 14 d after the last procedure.

Discussion

PSH is relatively rare but serious complication defined as an incisional hernia occurring after laparoscopic procedures. Clinical presentation includes abdominal pain and distension, nausea, vomiting, and lack of bowel movement and/or flatulence. These symptoms generally occur within a few days after the surgery. If PSH is suspected ultrasonography and/or abdominal CT should be performed. PSH is classified into

CONTACT Ingrid Marton  ingridmarton@gmail.com  Department of Gynecology and Obstetrics, Clinical Hospital Sveti Duh, School of Medicine, Croatian Catholic University, Zagreb, Croatia

© 2022 The Author(s). Published by Informa UK Limited, trading as Taylor & Francis Group.
This is an Open Access article distributed under the terms of the Creative Commons Attribution-NonCommercial-NoDerivatives License (<http://creativecommons.org/licenses/by-nc-nd/4.0/>), which permits non-commercial re-use, distribution, and reproduction in any medium, provided the original work is properly cited, and is not altered, transformed, or built upon in any way.

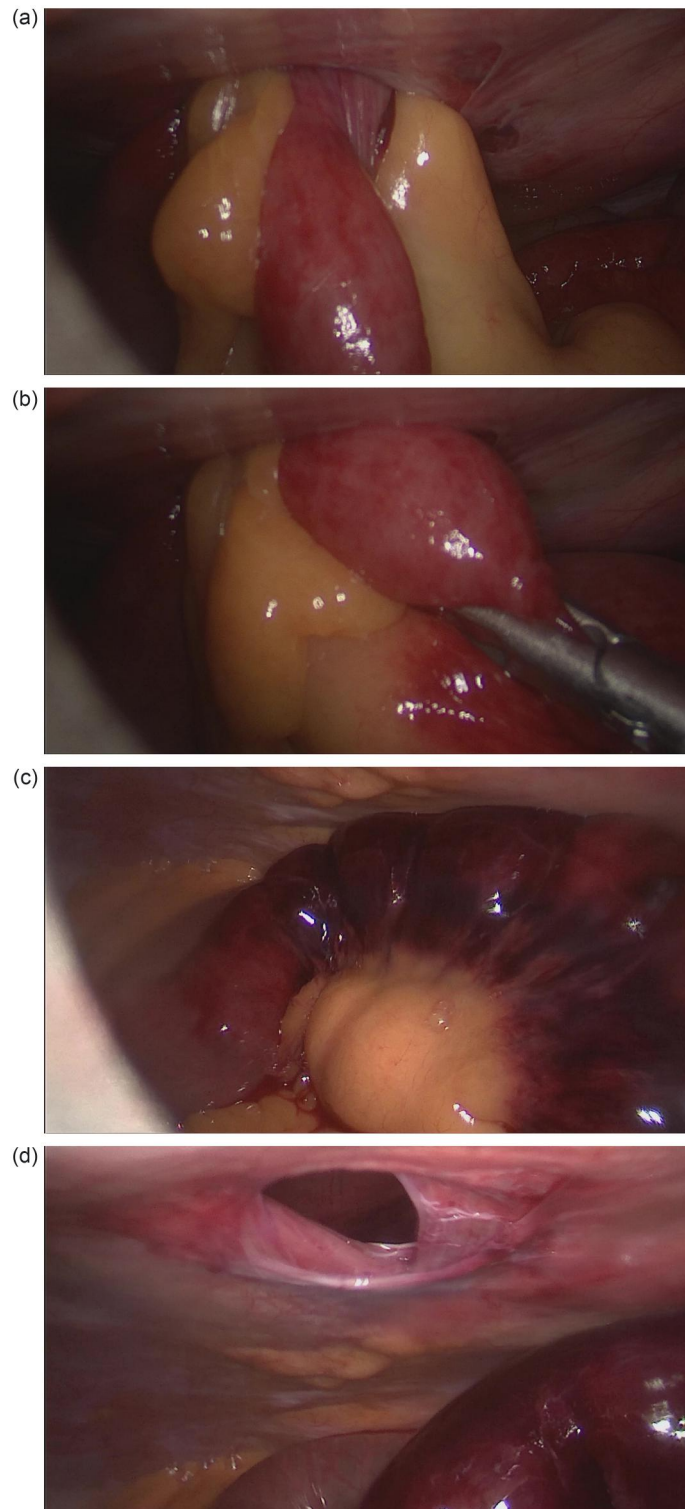


Figure 1. (a) Small-bowel preperitoneal incarceration in the site of the left port incision. (b) Incarceration was resolved laparoscopically. (c) Necrosis of the ileum was detected. (d) After resolving small-bowel incarceration small fascial defect was visualised.

three types (Velasco *et al.* 1998, Tonouchi *et al.* 2004). The early-onset type indicates dehiscence of the anterior and posterior fascial plane and peritoneum. It develops within 2 weeks after the surgery, often presenting as a small-bowel obstruction. In the late-onset type, there is dehiscence of the anterior and posterior fascial plane and the hernia sac is the peritoneum that manifests as asymptomatic swelling several

months after the surgery. The third type involves dehiscence of the whole abdominal wall, which is recognised as a protrusion of the intestine and other tissue (e.g. greater omentum). The majority of described PSH occurred at ≥ 10 mm port sizes and those of 5 mm after removal of the drain (Liu and McFadden 2000, James *et al.* 2021). Reliable data support a lower relative risk of overall complications with blunt than

bladed trocars, even suggesting that nonbladed trocars may not need port closure (Moreaux *et al.* 2009, Gutierrez *et al.* 2020). Fascial closure is recommended for only extraumbilical port sites > 10 mm (Kadar *et al.* 1993).

Excessive BMI is recognised as an independent risk factor for preperitoneal herniation (Cottam *et al.* 2002). In this particular case, patient was overweight (BMI 29.3). Conical blunt 5 mm trocar was used but manipulation with the port was not excessive: trocar was inserted first time on the beginning of the operative procedure, second time for introducing wound closure device (V-loc™) and third time for taking out the needle. Drain was not inserted into the abdominal cavity. Much smaller preperitoneal small-bowel herniation into a 5-mm nonbladed right port-site has already been described (Huang *et al.* 2010).

To our knowledge, this is first case of giant small-bowel preperitoneal herniation into a left port-site without significant fascial defect after insertion of the 5 mm blunt trocar. Deflation of the pneumoperitoneum during port removal and/or patient's overweight could be identified as risk factors for developing PSH.

Ethical approval

Ethical approval was unnecessary due to nature of the study.

Disclosure statement

No potential conflict of interest was reported by the author(s).

Funding

The author(s) reported there is no funding associated with the work featured in this article.

ORCID

Tvrtko Tupek  <http://orcid.org/0000-0003-4052-4178>

References

- Cottam, D. R., *et al.*, 2002. Preperitoneal herniation into a laparoscopic port site without a fascial defect. *Obesity Surgery*, 12 (1), 121–123.
- Gutierrez, M., *et al.*, 2020. Does closure of fascia, type, and location of trocar influence occurrence of port site hernias? A literature review. *Surgical Endoscopy*, 34 (12), 5250–5258.
- Huang, M., *et al.*, 2010. Postoperative bowel herniation in a 5-mm nonbladed trocar site. *Journal of the Society of Laparoendoscopic Surgeons*, 14 (2), 289–291.
- James, M., *et al.*, 2021. A case of unusual evisceration through laparoscopic port site. *Journal of Minimal Access Surgery*, 17 (4), 559–561.
- Kadar, N., *et al.*, 1993. Incisional hernias after major laparoscopic gynecologic procedures. *American Journal of Obstetrics and Gynecology*, 168 (5), 1493–1495.
- Liu, C. D. and McFadden, D. W., 2000. Laparoscopic port sites do not require fascial closure when nonbladed trocars are used. *American Surgeon*, 66 (9), 853–854.
- Moreaux, G., *et al.*, 2009. Five-millimeter trocar site bowel eviscerations after gynecologic laparoscopic surgery. *Journal of Minimally Invasive Gynecology*, 16 (5), 643–645.
- Swank, H. A., *et al.*, 2012. Systematic review of trocar-site hernia. *The British Journal of Surgery*, 99 (3), 315–323.
- Tonouchi, H., *et al.*, 2004. Trocar site hernia. *Archives of Surgery (Chicago, IL: 1960)*, 139 (11), 1248–1256.
- Velasco, J. M., *et al.*, 1998. Postlaparoscopic small bowel obstruction. Rethinking its management. *Surgical Endoscopy*, 12 (8), 1043–1045.