

Facelift

Miljak, Matej

Master's thesis / Diplomski rad

2023

Degree Grantor / Ustanova koja je dodijelila akademski / stručni stupanj: **University of Zagreb, School of Medicine / Sveučilište u Zagrebu, Medicinski fakultet**

Permanent link / Trajna poveznica: <https://um.nsk.hr/um:nbn:hr:105:829250>

Rights / Prava: [In copyright](#)/[Zaštićeno autorskim pravom.](#)

Download date / Datum preuzimanja: **2024-11-06**



Repository / Repozitorij:

[Dr Med - University of Zagreb School of Medicine Digital Repository](#)



**UNIVERSITY OF ZAGREB
SCHOOL OF MEDICINE**

Matej Miljak

Facelift

Graduate Thesis



Zagreb, 2023

This graduation thesis was made at the Department of Plastic - Reconstructive and Breast Surgery, University Hospital Center Zagreb, Croatia, mentored by prof. dr. sc. Davor Mijatović, dr. med., and was submitted for evaluation in the academic year 2022/2023.

Abbreviations

CO₂	Carbon Dioxide
HA	Hyaluronic Acid
ION	Infraorbital nerve
ITS	Inferior Temporal Septum
LLS	Levator labii superioris
MACS	Minimum Access Cranial Suspension
OOM	Orbicularis Oculi Muscle
SMAS	Superficial Musculo-Aponeurotic System
STS	Superior Temporal Septum
TFN	Temporal Branch of Facial Nerve
TLA	Temporal Ligamentous Adhesion
TTF	Tear Through Fold
ZMM	Zygomaticus major muscle

Table of Contents

Summary	i
Sažetak	ii
Introduction	1
Anatomy of the Face	6
1 st Composite Layer: The Skin	6
2 nd Composite Layer: The Subcutaneous tissue	6
3 rd Composite Layer: The musculo-aponeurotic system	7
4 th Composite Layer: Retaining ligaments; Spaces and facial nerve rami	8
5 th Composite Layer: Periosteum and deep fascia	11
The Structure and mechanisms of the Ageing Face	12
Ageing mechanism of the skin	12
Ageing mechanism of the subcutaneous tissue	13
Ageing mechanism of Facial muscle	13
Ageing mechanism of Spaces	13
Ageing mechanism of Bones	14
Age associated changes in the Midcheek	14
Age associated changes in the Lower face	17
The Patient consult and clinical assessment	18
Surgical Facelift Techniques	20
Subcutaneous Facelift	20
SMAS plication/imbrication Facelift	22
Deep Plane, Extended SMAS and Composite Facelifts	23
Lateral SMASectomy	26
High SMAS Facelift	26
Minimum Access Cranial Suspension (MACS) Facelift	27
Subperiosteal Facelift	28
Complications and Recovery	28
Non-surgical Facelift techniques and Comparisons	30
Botulinum Toxin Injections	31
Soft Tissue Fillers	32
Minimum Invasion Liposuction (Kybella and Cryolipolysis)	35
Skin Remodelling Techniques	36
Advancements and Future Directions of Facelifts	41
Conclusion	44
References	45
Author's Biography	iii

Summary

Facelifts

Matej Miljak

The individual human being is defined and recognised by their identity, and their natural identity card is their face. As humans we express beauty, character and emotions using our face. Thus we strive to conserve one of our most priceless entities. To do so, our medical and surgical capabilities have significantly advanced over the course of the last 100 years. Beginning with the Subcutaneous Facelift, many decades ago, cosmetic facelifting has modernised to include both surgical and non-surgical techniques. The new anatomical discoveries of the face has led to the development of the surgical SMAS facelift: (extended) deep plane facelifts, SMAS plication/imbrication, lateral SMASectomy, Composite facelifts and Minimum Access Cranial Suspension facelift. Recently though, as our technology developed, new trends emerged that demanded less invasive techniques with quicker recoveries. This brought to light the use of Injectables, such as Botulinum Toxin and Hyaluronic Acid fillers; devices such as radiofrequency, microneedling, thread lifting, etc.

Therefore, this thesis will evaluate and discuss the various surgical and non-surgical techniques in the present day. Further providing a comparison between them and general arguments used by patients in deciding the trends of using one option over the other. In addition, there are several new technologies in the pipeline waiting to be implemented into the plastic surgery clinic. Stem Cell Regeneration, Nanotechnology, Gene-editing and Artificial Intelligence have only begun to be translated into practise and are yet to show their true uses.

Keywords: Facelift, SMAS, deep plane facelift, composite facelift, minimum access cranial suspension facelift, SMASectomy, Botulinum Toxin, Hyaluronic Acid, Fillers, Radiofrequency, Microneedling, Thread lifting, Stem Cell, Nanotechnology, Gene-editing

Sažetak

Facelift

Matej Miljak

Pojedino ljudsko biće definirano je i prepoznato po svom identitetu, a njihova prirodna iskaznica je lice. Kao ljudi izražavamo ljepotu, karakter i emocije koristeći svoje lice. Na taj način nastojimo sačuvati jedan od naših najcjenjenijih entiteta. Da bismo to učinili, naše medicinske i kirurške sposobnosti značajno su napredovale tijekom posljednjih 100 godina. Počevši s Subkutanim faceliftom, prije mnogo desetljeća, kozmetičko dizanje lica moderniziralo se tako da uključuje kirurške i nekirurške tehnike. Nova anatomska otkrića lica dovela su do razvoja kirurškog SMAS dizanja lica: (prošireni) duboki facelift, SMAS imbrikacija, lateralna SMASektomija, sastavljeni i MACS facelift. U posljednje vrijeme, kako se razvijala naša tehnologija, pojavili su se novi trendovi koji su zahtijevali manje invazivne tehnike s bržim oporavcima. To je ukazalo na upotrebu tvari, poput Botulinum Toxin i hialuronskih punila; uređaji kao što su radiofrekvencija, mikronedling, podizanje s navojima, itd.

Stoga će ova teza procijeniti i raspraviti različite kirurške i nekirurške tehnike. Nadalje, pružanje usporedbe između njih i općih argumenata koje pacijenti koriste u odlučivanju o trendovima korištenja jedne opcije u odnosu na drugu. Uz to, u planu je nekoliko novih tehnologija koje čekaju da se primijene u kliniku za plastičnu kirurgiju. Regeneracija s matičnim stanicama, Nanotehnologija, editiranje genoma i umjetna inteligencija tek su se počeli pretvarati u praksu i tek trebaju pokazati svoju istinsku upotrebu.

Ključne riječi: Facelift, duboki facelift, SMAS, SMASektomija, MACS facelift, radiofrekvencija, mikronedling, podizanje navojima, matične stanice, nanotehnologija, editiranje genoma, umjetna inteligencija

Introduction

Beauty and individual identity has been portrayed in many facial portraits by artists such as Leonardo da Vinci and Johannes Vermeer. The painting of the Mona Lisa and Girl with a Pearl Earring are by character so exclusive because they are uniquely defined by the beautiful faces of the portrayed women. An individual's face is a person's natural identity card, because it represents their self, psychological wellbeing and all in all - their life (1). It is the first region of someone's body that is noticed, whether in the mirror or in public. People are mostly (often inappropriately) judged on the appearance of their face before they are assessed on their personality and character (2). This powerful influence of a person's face from all facets of life mentioned above has given birth and rise to aesthetic facial surgery. People that have experience of negative social commentary or poor self-esteem due to ever changing social pressures of beauty have sought out facelifts and other cosmetic procedures (1). These pressures are translated from such patients to the plastic surgeons involved as the demand for successful outcomes and thus beauty is unforgiving (3). The human face is designed for higher levels of social communication, most notably representing emotions (2). Therefore it is largely an important and complex task to perform face altering surgery while preserving all the subtleties of natural expression. Some of these subtle expressions are so small that they are at the level of the subconscious, so it is important to find an appropriate standard for facelifts, and other procedures, where it is a fair compromise between the deteriorating effects on a patient's communicating ability and the effect it has on their future wellbeing (2). The complexity of facial anatomy has only been recently revealed and is soon reaching its peak of discovery, which has allowed for the development of "new anatomy" based techniques (2). This allows for a more efficient way to tackle the pathology of ageing and the revitalisation of one's face. The more intricate the anatomy, the greater the surgical risk, thus the conundrum exists: to give preference to safety or outstanding results (3). Any lasting complications lead to defining changes on a person's face and thus detrimental consequences. One of these famous revitalising surgical procedures what is commonly spoken about is the Facelift. Loosely, it means a lifting and tightening of the face and facial skin, however there is more to it than that (4). In their beginnings, facelifts were localised to small isolated regions such as lateral cheek, upper and lower eye lids, etc. This resulted in surgical terms of meloplasty, meaning "shaping of the cheek", and rhytidectomy, meaning "excision of wrinkles", being coined (3). The progression and adaptation of such procedures resulted in trends to extend the benefits of operating on one isolated regions to include the neighbouring regions (3). Soon after browlifts were first used, they were combined with upper eyelid and temporal lift surgeries, which ultimately improved the upper outer region of the cheek (3). The previously untouched midcheek also benefitted from the advancement of the lower lid blepharoplasty to the implementation of the extended midface lift, which involves lifting of the midcheek and lower eyelid (3). This finally enabled facelifts to focus on rejuvenating the shape of the face rather than skin tightening for removal of wrinkles. However, these procedures affect the areas of the neck and as a result today a facelift is termed cervicofacial rhytidectomy (even though facelifts are not truly excision of wrinkles) (3).

Facelifts have the most variety of techniques of any surgical procedure even in today's world of evidence based medicine (1,2). There is a significant subjective component from the professional aspect as well as the patient's satisfaction. This satisfaction is also influenced by a patient's background, i.e. their cultural and social factors, that may trigger praise or disappointment (even though a great surgical outcome presents) (3). A multiple segmented strategy can produce an unnatural and discordant outcome in some patients, but it can also be a cunning technique to covertly introduce an imperceptible refinement of appearance in others (3). So whether to adjust patient wishes or ignore a professional opinion is also of key ethical consideration. This leads to the importance of having a good psychological consultation between patient and surgeon (3,4). The multiple facelift techniques underline the complexity of performing such surgeries as the best possible technique is subjective based on a "best" outcome which is subjective (3). This is in contrast to hand surgery where the primary goal is to restore functionality, which can be directly measured (3). Thus when looking for a "best result" technique it depends on the satisfaction of the patient, the level of risk, cost-recovery efficiency and duration the results will last (3). Nowadays, adjuvant procedures are added to the classic facelift, such as blepharoplasties, temporal lifts, etc, to visually stimulate a "greater result" (2). Here patients may be unaware that an even better outcome may have been possible with the addition of other techniques. As a result, it is important for the surgeon to be well versed with the possible techniques, which will be introduced next and elaborated on and criticised as the subject matter of this thesis.

The primary objective of a facelift is to restore the youthful shape of one's face (Figure 1). Other concomitant procedures such as CO₂ laser skin resurfacing are additionally used to remove wrinkles (Figure 1) (1). The approximate regions affected by a classic facelift are shown in figure 2 below.

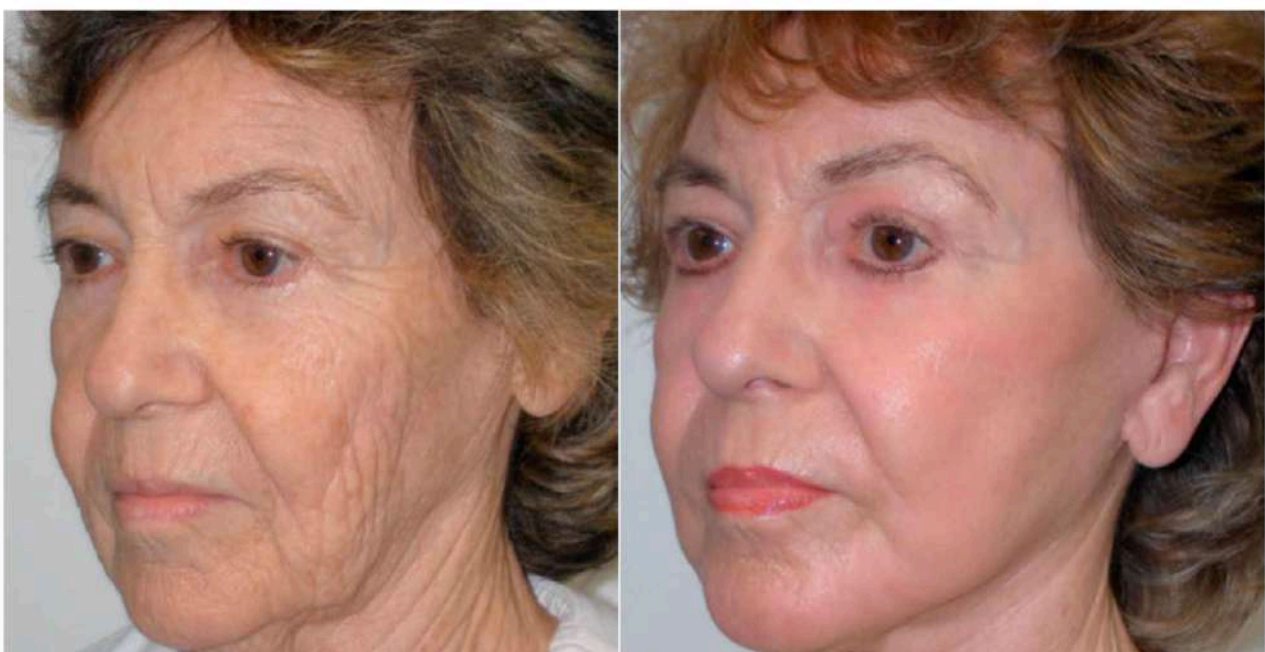

Figure 1 - shows the before and after a patient has undergone a facelift to remove jowling and nasolabial folds and CO₂ for wrinkle correction. Adapted from (1).

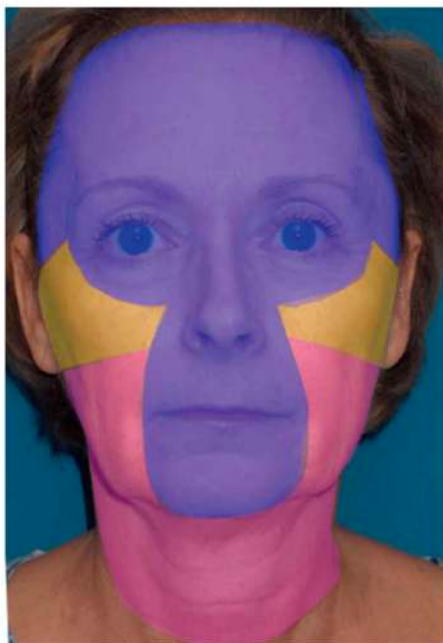

Figure 2 - shows the yellow and pink areas which are primarily affected by performing a facelift. Adapted from (1).

In order to understand how to rejuvenate the face, it is important to introduce the concept and pathophysiology of the ageing face (6). Environmental, genetic, time and lifestyle factors all interplay to affect our appearance (2). This deterioration manifests as jowls, sagging neck and face, fatigued appearance, reshaping and more (7). The metabolic component of ageing weighs in especially in females during menopause, which results in epidermal and dermal alterations (2). Weight gain and changes are similarly affected, where there is loss of subcutaneous fat as well as the loss of the glandular component in the volume of the face and neck structures, diminishing support to the skin (2). Skeletal muscles also undergo atrophy (up to 50%) together with underlying bone resorption (2). These osteoporotic changes are attributable to both males and females, therefore with greater resorption even more support to soft tissue is lost (2,3). Retaining ligamentous laxity and ptosis are also contributing factors, that not all surgeons agree on (7). However, other extrinsic factors also influence the ageing process. Alcohol, tobacco smoke, and photo-damage are some significant agents involved in the pathophysiology of ageing (1). The mechanisms of ageing will be briefly described later in this thesis.

When such appearances were first battled with in the early 20th century, only the skin was manipulated with (3). But it was only in the 1960s that Millard, introduced direct submental lipectomy and this was followed by Skoogs, who pioneered a new anatomical perspective for the facelift (3). Building on this idea, Mitz and Peyronie described the concept of the Superficial Muscular Aponeurotic System (SMAS) (3). These new anatomical concepts are described as involving 5 layers of soft tissue: 1 - Skin, 2 - Subcutaneous tissue, 3 - musculo-aponeurotic tissue, 4 - Dissecting plane (functional spaces, retaining ligaments, deep intrinsic muscles) and 5 - Periosteum and deep fascia (Figure 3) (3). This anatomy will be further elaborated on later. Skoog then developed the first SMAS dissection plane facelift (3). Adaptations to SMAS facelifts is still ongoing and later other concepts were introduced in that the ageing face also has components of soft tissue atrophy and well as skeletal remodelling (5).

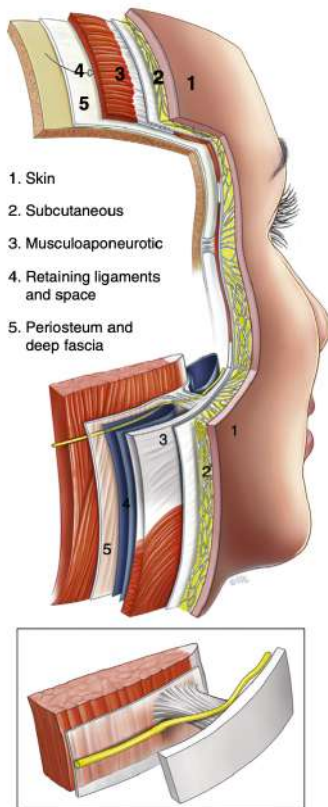


Figure 3 - shows the different layers of facial soft tissue and their topographical relations. The inset below shows the relation of facial nerve branches to the soft tissues. Adapted from (2).

Based on these new anatomical foundations a new era of facelift techniques has arisen. Modern subcutaneous facelifts involves a skin flapping technique which can be either more superficial within the subcutaneous layer, with its advantages of having less facial nerve branches (2,6); and the preferred deeper layer subcutaneous facelifts along the superficial musculo-aponeurotic plane (SMAP), which has less bleeding and ligamentous fibres and is used as a preparatory part for SMAS and platysma manipulation techniques (1,3). SMAS manipulation techniques stem from Skoog's, Mitz's and Peyronie's findings. SMAS plication/imbrication, the deep plane and (limited dissection) composite rhytidectomy, lateral SMASectomy, extended SMAS, the high SMAS facelift, the subperiosteal facelift and minimal access cranial suspension facelift form the different SMAS facial reshaping surgical techniques (2). These subcutaneous and SMAS manipulation techniques form the body of this thesis and will be detailed later on.

Non-surgical facelift techniques are broad spanning and are used as preventative and noninvasive methods to reshape or maintain the shape of the face. Furthermore, they can be used as adjuvant treatments alongside surgical facelifts (8). Injections of Botulinum Toxin (Botox) are used to induce paresis of "hyperkinetic" lines on the face (and neck), alter muscle elevation and depression by blockade for establishing facial symmetry, lifting, crease prevention as well as perioperatively for scar management (2). Soft tissue fillers allow for volume restoration as they enhance the support provided by the facial skeleton to the soft tissue which also reduces wrinkles and lines (8). They can be subcategorized in non-biodegradable and biodegradable fillers (2). Submental fullness treatment removes unwanted fat deposits in the chin and neck areas. This is achieved by injections of deoxycholic acid and cryolipolysis treatment (2,8). Cutaneous remodelling can also be accomplished using devices for microdermabrasion, microneedling, microfocused ultrasound,

radiofrequency treatment, laser and intense pulsed light; and various solutions for chemical exfoliation and platelet rich plasma treatment for skin tissue rejuvenation (2).

Although these techniques may seem relatively harmless they do bring along their complications. An unsuccessful or undesired surgical outcome may be one of the most important complications as it affects a patients psychological state, which may not be surgically later correctable (1).

Different techniques have their advantages in controlling certain complications but hematomas, nerve injuries, skin loss, undesired scarring and infections still may occur (2,3,7). Non-surgical techniques carry their own set of complications as well and these range from ptosis (botox), allergic reactions, granulomas and embolisms to aesthetic complications such as overfilling, displaced or misplaced filler and dyschromia (2).

All in all, it is important to evaluate the patients desires and educate them in a preoperative process and find a silver lining between the patients desires and the surgeons capabilities (3). In continuation, the body of this thesis will further discuss the surgical anatomy of the aforementioned procedures, the concept of an ageing face, the preoperative process and establishing a common patient-surgeon goal, the surgical and non-surgical techniques employed to reshape the face, associated complications with these procedures and finally future directions of facial rejuvenation.

Anatomy of the Face

New era anatomical concepts are a fundamental discovery that paved the way in the understanding of the pathogenesis of facial ageing (9). Using these concepts facelifts could develop a more “natural” outcome, become longer lasting and with reduced side effects. Thus to master the difficulty of facelifts it is imperative to understand these anatomical layers upon which the face is constructed (10). These anatomical structures and locations are important landmarks for orientation and anticipation of fundamental structures such as the facial nerve when performing deep plane and other facelifts (11).

When dissecting back the layers, the face is composed of 5 layers of soft tissue: 1 - Skin, 2 - Subcutaneous tissue, 3 - musculo-aponeurotic tissue, 4 - Dissecting plane (functional spaces, retaining ligaments, deep intrinsic muscles) and 5 - Periosteum and deep fascia (2). These layers are explained in more detail now. These layers work together to allow structures to perform their physiological tasks. Layer 4 is essentially an “avascular gliding layer,” that allows the superficial layers to glide over the deep fascia in layer 5 (2). Critical structures such as arterioles and nerves can be found in close proximity to retaining ligaments in layer 4 as they expand into the superficial layers (2,3). These ligaments anchor the dermis of the skin to the bony structure of the face (10). These layers can more discreetly be seen on the forehead and scalp.

1st Composite Layer: The Skin

The skin is characteristically split into the dermis and epidermis. The epidermis is further divided into 5 layers (11), which are beyond the scope of this thesis. However, it generally is made up of differentiated keratinocytes, several melanocytes and immune cells such as antigen-presenting cells (2). The dermis contains the vasculature that provides the nutrients to the epidermal layers (11). The breadth of the dermis is indirectly correlated with the amount of movement in that region of the skin (2,6,8). For example, the dermis of the eyelids is the thinnest and is wider on the forehead and tip of the nose (2). The relation of the dermis, skin, to other layers can be seen in figures 3 and 4.

2nd Composite Layer: The Subcutaneous tissue

The subcutaneous tissue is formed from a superficial layer of fat and a deeper fibrous layer called the retinacular cutis (Figure 4) (2). This retinacular cutis layer attaches the dermis to the underlying SMAS (2). This layer is made from the smaller ligamentous portion of the retinacular ligament extensions (10). The extent of the attachments and breadth of subcutaneous layer varies throughout the face similarly to how the skin layer is formed (2,3). In comparison, the eyelids barely have a fatty component of tissue, to the contrary, the nasolabial region has a much thicker fat layer (8). The thick parts of the subcutaneous tissue have longer retinacular cutis fibres which predisposes them to stretching with age (5). The attachment of the subcutaneous tissue to the underlying bone is stronger than the attachment of the SMAS to the bone (Figure 4) (2). This is

because the number of fibre attachment points, i.e. surface area of attachment of the retaining ligaments, is much greater in the retinacular cutis than in the SMAS (10). These micro-ligaments form boundaries that create fat patches such as McGregor's patch over the zygomatic bone (2,10). Variations of density of these micro-ligaments within the subcutaneous layer and orientation affect how well supported this layer is. The more vertical and more dense the formation of fibres, the greater the support of the subcutis (2). These dense vertical fibres form these aforementioned boundaries and thus "superficial subcutaneous fat compartments" (2).

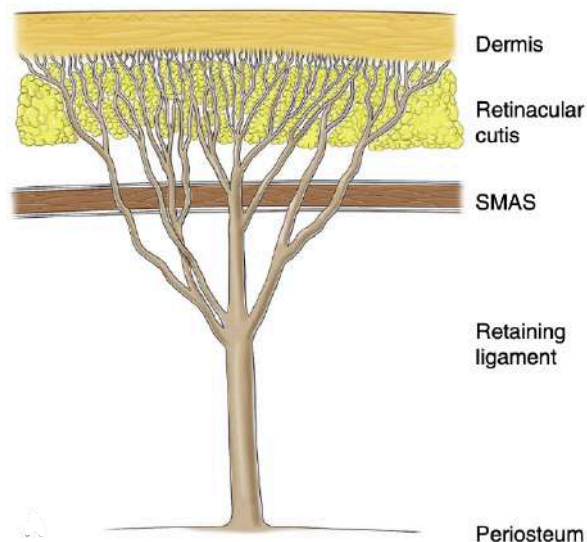


Figure 4 - shows how the retaining ligament is related to other soft tissues. The retaining ligament inserts its microfibrils into the subcutis with a greater surface area than when crossing the SMAS with thicker branches but in smaller number. Adapted from (2).

3rd Composite Layer: The musculo-aponeurotic tissue

This musculo-aponeurotic system forms a single sheet more or less continuous sheet traversing the scalp (frontalis), the orbicularis, mid and lower face (SMAS) to the platysma in the neck (Figure 5) (2). The SMAS is the focus of facelifts and thus what will be elaborated on more here. This layer contains muscles involved in facial expression and they are responsible for the movement of the layers above, i.e. the skin and the subcutis (2,7). The muscles are fixated partially to the underlying bone by retaining ligaments, that have relatively fewer points of contact than within the reticular cutis, as mentioned earlier (Figure 5) (10). Muscles of the middle and inferior face include the elevators which are zygomaticus major and minor, levator labii superioris, levator anguli oris and depressors which are depressor anguli oris, depressor labii inferioris (2,11). The other muscles of the head are omitted for simplicity because although they are part of facial surgery they do not have a direct role in facelifts which primarily targets the mid and lower face.

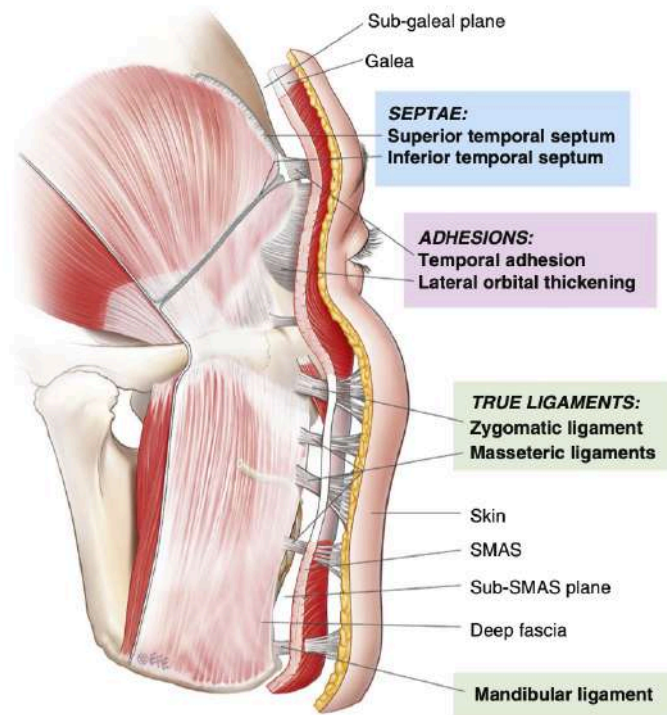


Figure 5 - shows the various retaining ligaments in relation to other soft tissue layers and their topographical locations. Adapted from (2).

4th Composite Layer: Retaining ligaments; Spaces and facial nerve rami

This layer is implicated in a deep plane facelift and is constructed by a number of components: retaining ligaments, tissue spaces, deep parts of muscles where their attaching portions transition toward the underlying bone and intrinsic muscles, and finally branches of the facial nerve (8). Several tissue spaces exist in this layer. The upper temporal space which is isolated inferiorly by the bilaminar inferior temporal septum and superiorly by the superior temporal septum (STS) (Figure 6) (2,5). The space lies in between the fascia of the temporalis muscle as the floor and the roof is represented by the superficial temporal fascia (2). The STS separates this space and the forehead (2).

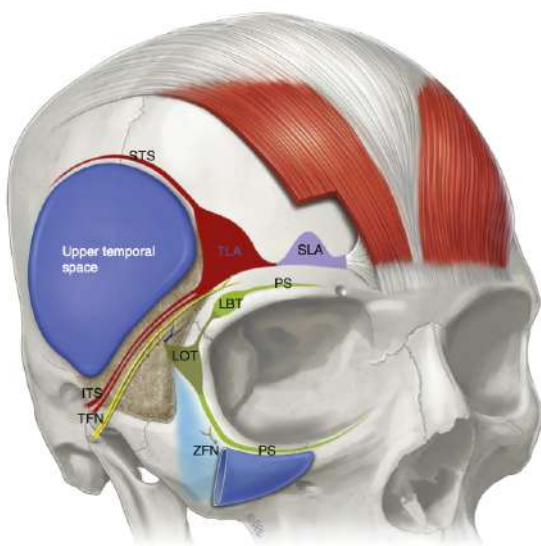


Figure 6 - shows the Inferior Temporal Septum (ITS) joining the Superior Temporal Septum (STS) forming the Temporal ligamentous adhesion (TLA). It is important to notice the path of the temporal branch of the facial nerve (TFN) to the ITS, when dissections are done. Adapted from (2).

The supraorbital nerve runs medially and close to the STS and must be taken care of when releasing the STS (2). The STS meets with the ITS to form the temporal ligamentous adhesion (5). Inferior to the ITS lies a region of the lower temple which is a continuation of the superior cheek (2,3). Both the upper temporal space and lower temple region are surgically important. The upper temporal space provides access to the lateral areas of the eyebrows and the superior portion of the cheek (2). While the lower temporal region inferior to the ITS have important structures such as the temporal branch of the facial nerve (which follows the ITS), and thus has to be dissected with caution (2,3). Once the superficial fascia is elevated in this region sentinel vein can be seen, and between this vein and the ITS is where branches of the facial nerve can be located coursing through fat underneath the superficial fascia (2).

The prezygomatic space, is found anterior to the zygomatic bone, with its floor being the zygomatic muscles and the roof being the orbicularis oculi muscles (Figure 7) (2,3). Laxity in the roof of this space results in age related changes and emphasising of the zygomatic lines (2,6). This understanding forms the basis for surgical treatment of so called “bags” under the eyes (7).

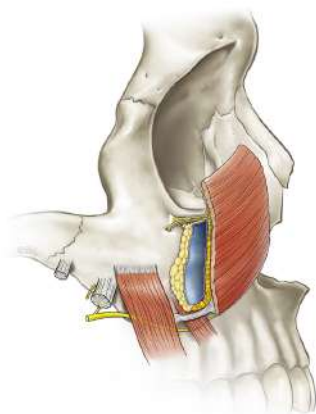


Figure 7 - shows the prezygomatic space in the blue area surrounded by fatty tissue, under the orbicularis oculi muscle. Adapted from (2).

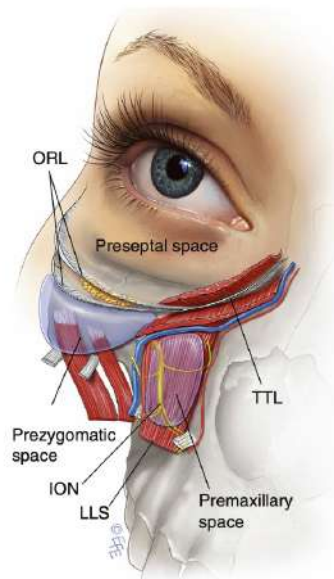


Figure 8 - shows the premaxillary space “lying” on top of the Levator labii superioris (LLS) and infraorbital nerve (ION). Adapted from (1).

The premaxillary space is found anterior to the maxillary sinus, medial to the prezygomatic space (Figure 8) (2,3). Its floor is formed by the Levator labii superioris, and this space separates the orbicularis oculi in its roof to grant free movement (Figure 8) (2). Similarly, the laxity in the roof of this space results in greater depth to the nasolabial fold (2,4). Essentially, it also provides access for a deep plane dissection in the middle inner cheek for surgical intervention of a tear through deformity (8).

The lower premasseteric space overlies the inferior half of the masseter (Figure 9) (3). The roof is comprised of the platysma (3). Logically, this space, as the others, allows for gliding of soft tissue over each other during mastication (2). Laxity in the roof of this space, i.e. of the platysma, leads to the formation of a labiomandibular fold and jowls, from weakened anterior masseteric attachment and no ligamentous attachment of the platysma at the inferior boundary of this space (10).

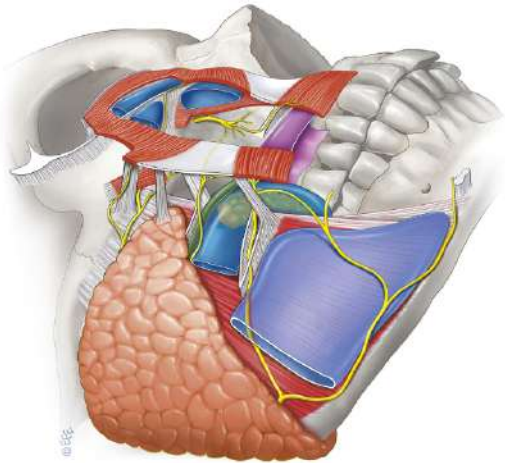


Figure 9 - shows the large lower premasseteric space overlying the inferior masseter. The boundaries of this space are traversed by the facial nerve branches (yellow). Superior to this space lies the middle premasseteric space, separated by the masseteric retaining ligaments at the border of the 2 spaces. *Adapted from (2).*

Lastly, the rectangular middle premasseteric space is found superior to the lower premasseteric space (Figure 9) (2). The fascia of the masseter forms the floor while the superficial musculo-aponeurosis forms its roof (2). The parotid gland and duct of Stenson are found in adjacent to the superior and lateral junctions of this space (Figure 9) (3). The facial nerve branches pass immediately above and below this space (Figure 9) and are found in conjunction with the retaining ligaments in their course to innervate the SMAS musculature (Figure 10) (10). As a result, this space provides a great means to perform deep plane facelifts (4) as these important aforementioned anatomical structures are found around this space, not inside it.

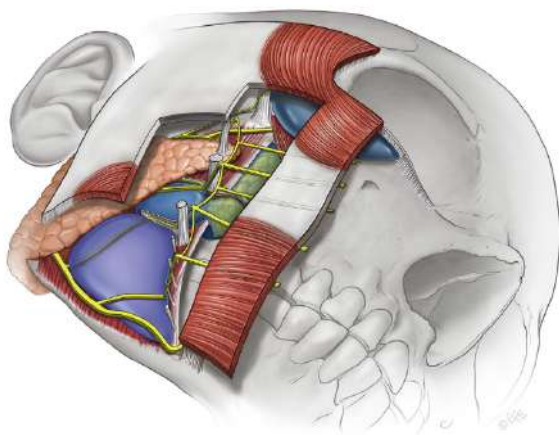


Figure 10 - shows the SMAS cut out, revealing the course of the facial nerve branches in proximity to the retaining ligaments. *Adapted from (2).*

Apart from these spaces other anatomical formations should also be addressed. The Platysma Auricular Fascia (PAF) is found anterior to the ear and forms a ligamentous attachment in that region adjoining all 5 layers (2,10). Here no muscle layer is apparent (3).

The retaining ligaments, as mentioned, are placed around the boundaries of spaces (Figure 11) and at the edges of cavities, such as around the orbit and at the lips, to allow for appropriate movement (5,11). The facial nerve also uses the retaining ligaments as sites where its branches can traverse to superficially to their respected muscle (Figure 10) (11).

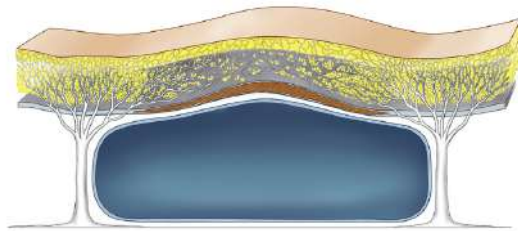


Figure 11 - shows a schematic a facial space under the skin, subcutis and SMAS while overlying the periosteum. At the boundaries of these space, retaining ligaments can be found, as shown on either side of the blue space in this figure. Similarly these retaining ligaments isolate areas of fat as they infiltrate the subcutis forming fat pads. Adapted from (2).

5th Composite Layer: Periosteum and deep fascia

Layer 5 contains the periosteum overlying the facial bones, the muscles of mastication and the deep fascia overlying them (5). The deep fascia is continuous with the fascia of the parotid and neck (Figure 5) (2). Within the bony cavities and areas of the face that require more movement, the deep fascia is replaced with another, more loose, tissue (2). From the periosteum and the deep fascia arise the retaining ligaments (Figure 4) (10). The retaining ligaments, and their changes with ageing, are responsible for grooves seen in the midcheek, for example, the tear through deformity of the lower eyelid (9). Interestingly, deep fatty tissue has also been located in this layer termed, “preperiosteal fat”, and can be seen in figure 7, under the prezygomatic space (2).

These spaces and anatomical structures contribute to the ageing process and will be discussed in the next section.

The structure and mechanisms of the Ageing Face

Ageing occurs throughout all tissues, i.e all layers of the face (9). This remodelling with age can be seen using all imaging tools available in medicine. Generally, the facial appearance changes due to 2 primary mechanisms which is the increased laxity of the roofs of various spaces, as mentioned in the previous section, from degenerative effects of retaining ligaments and other soft tissues (9). Secondly, there could be an illusion of laxity that results from loss of volume of bone and soft tissues (2). Furthermore, it could be a combination of the 2 mechanisms, both primary degeneration causing true laxity and loss of volume. Several factors are implicated in the ageing these are genetics, environmental (such as sun exposure, alcohol, emotional stress, gravity photo-radiation), and hormonal and metabolic changes (2). This tissue ageing manifests as protrusions of these different regions of the face as well as increased depth of grooves in the face (5). Different regions have different appearances when undergoing ageing and will be discussed below. Firstly, brief descriptions of how the different layer undergo ageing will be explained and then how this affects different regions especially that of the midface and lower face, that are related to classic facelift surgery separately from blepharoplasties, browplasties, forehead lifts, etc.

Ageing mechanism of the skin

With age the skin becomes thinner and more flat, loosening with loss of structural integrity (2). Histologically, this can be seen as alterations in the intercellular matrix. There is loss of collagen (types 1 and 3, mostly), reduced number of fibroblasts as well as loss of elastin in the dermis (5). Both photo-ageing and chronological ageing have overlapping pathophysiology (2,9). Alterations in matrix metalloprotease (MMP) production, reduced collagen formation and increased reactive oxygen species (ROS), all lead to connective tissue damage (2). ROS molecules, are highly reactive molecules, that undergo chemical reactions with various protein molecules and genes, resulting in defective functioning of these biological structures (3). Ageing resulting from ROS production is a primary factor to be considered in ageing. There is decreased expression of anti-oxidant enzymes and increased ROS molecules as a result of their defective clearance and various environmental exposure (2). Smoking is a very common recreational activity that leads to highly increased ROS production (5). In retrospect it seems to speed up ageing by 10-20 years (2,9).

Collagen and elastin in the skin, that provide support to the skin's integrity against directional muscle activity and tension, i.e. facial expression, when lost lead to wrinkling of the skin (5). As muscles continuously generate basal tension and even more tension on the skin when performing facial expressions, the skin becomes less able to resist against this tension (6).

Ageing mechanism of the subcutaneous tissue

Earlier, it was described and can be deduced from figure 11, that fat is compartmentalised by retaining ligaments that are found in discreet locations (2). The retaining ligaments form the boundaries of these fat pads, which are integrated into the retinacular cutis and lower dermis (2,11). Ageing causes degeneration and thus weakening of these retaining ligaments which results in deterioration of the structural scaffold of this loose fatty tissues (7). This has a number of consequences as the tissue weakens, the fatty tissue is no longer fixed in place and may herniate into adjacent areas (2). Atrophy and hypertrophy of fat occurs leading to wavy, “peaks and valley” contours forming (2). All this leads to repositioning of fatty tissue that alter facial contours with age.

Ageing mechanism of Facial Muscle

Muscles of facial expression that are consistently used throughout life are more resistant to atrophy as compared to muscles of mastication that lose volume due to lower use and possible deterioration of teeth (2,3). Based on Magnetic Resonance Imaging (MRI) studies, the superior portion of the orbicularis oris does undergo chronological atrophy (2,9).

Ageing mechanism of Spaces

The above listed factors that contribute to ageing of the retaining ligaments affect the various spaces of the face. As these retaining ligaments weaken, the laxity of these structure increases and consequently allows for spaces to expand (9). Retaining ligaments are found at the boundaries of spaces (Figure 11), so as they weaken the spaces protrudes in these parts of increased laxity (2). This can be seen in areas of larger scales of movement, predominantly in the lower premasseteric space, while it is seen less, for example, over the zygoma with less movement (Figure 12) (6,8).

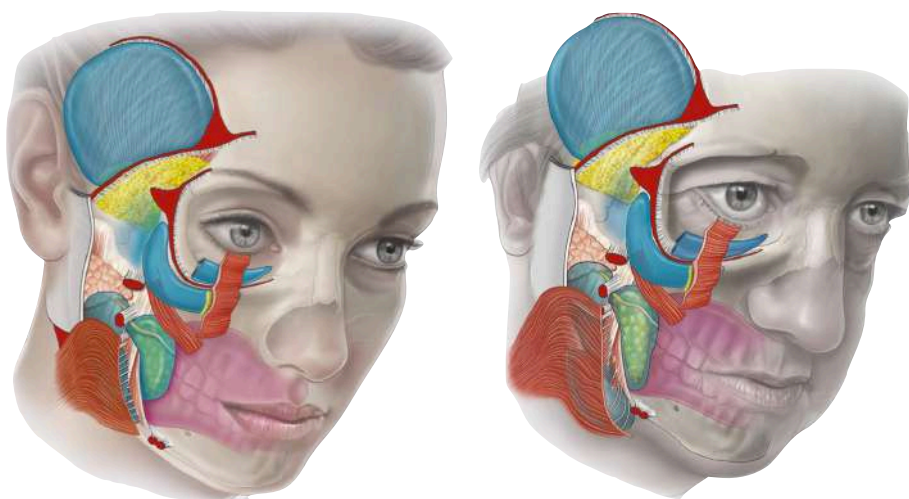


Figure 12 - shows jowl formation as laxity in the roof of lower premasseteric space with age occurs, due to weakening of the platysma and anterior masseteric ligaments. Adapted from (2).

Ageing mechanism of Bones

The skeleton is modified continuously from birth, and the facial skeleton as with the rest of the bones undergo varying degrees of resorption and adsorption (9). Unbalanced regions of resorption and adsorption lead to alterations of the ageing facial skeleton (12). Regions which undergo resorption relevant to classic facelifts are areas of the mid and lower face (13). The orbital aperture in its superior nasal and inferior temple parts undergoes expansion, the pyriform aperture widens, the zygomatic process and area of the maxilla is displaced inward along with the body of the mandible, as can be seen in figure 13 (2,9).

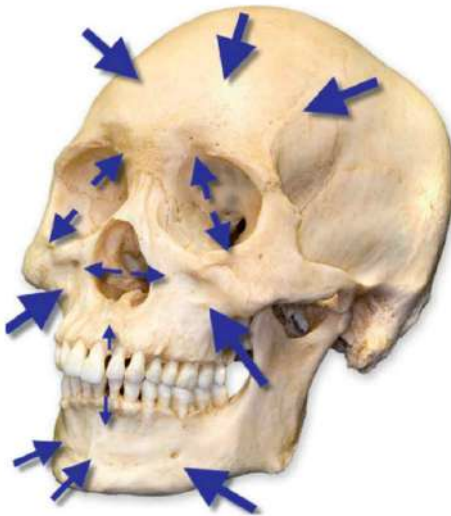


Figure 13 - shows vectors of cavity expansion (bone resorption) and bone formation (adsorption) with age. Adapted from (9).

As the bone retracts inward it pulls with it the retaining ligaments and thus all the overlying soft tissue (11). This gives the effect that the tissue underneath the retracted parts are bulging out and have sagged lower down (2,12). The retracted maxilla also accentuates the nasolabial and tear through folds (TTF) (12). Bony features may not be as pronounced in certain individuals with genetic congenital alterations and may undergo early ageing changes (2). This should be taken into consideration to maximise post-surgical and interventional results.

Based on these findings regions of the midcheek and lower face are susceptible to different forms of reshaping with age.

Age associated changes in the Midcheek

The midcheek is subdivided into 3 regions: the malar, lid-cheek and nasolabial segment. They are divided according to the presence of grooves at the boundaries of these segments (Figure 14) (2).

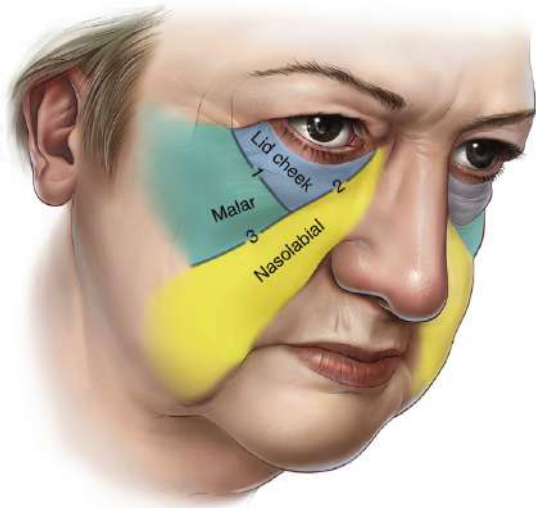


Figure 14 - shows a schematic of the midcheek, with boundaries that result from groove formation with age. The grooves separate 3 regions as indicated. 1 - Palpebromalar groove; 2 - Nasojugal groove ; 3 - Midcheek groove. Adapted from (2).

A youthful facial appearance has difficult to discern separations of these boundaries, making them seem as one surface area (9). With age however, the progression of these grooves become more apparent creating the distinguishable 3 regions of the midcheek (2). The increased effect of the nasojugal, palpebromalar and midcheek grooves (Figure 14) give the impression of a fatigued and aged look (12). The midcheek has a particular sensitivity to ageing changing as it inherently has several predispositions that affect this region more. Firstly, underlying bone of the maxilla has a posteriorly angled structure, which then undergoes disproportionate resorption, more medially and inferiorly, with ageing (Figure 13) (2,3). Secondly, the soft tissue is formed in a triangular shape with the apex at the medial canthus of the eye (2). These predispositions make the midcheek and lower lid more susceptible to ageing. With bone resorption and increased laxity of the orbicularis retaining ligaments (ORL) and zygomatico-cutaneous ligaments (ZCL), ageing changes occur (10,12). An important distinction between the aged and youthful lid-cheek area, is that during youth there is the appearance of a high lid-cheek junction (2). This is seen at the boundary of the orbital septum and tarsal plate, where the lower lid is then considered to start at the pretarsal bulge (2). With ageing there is lowering of this lid-cheek groove, which is manifested as the nasojugal and palpebromalar grooves (12). As the ORL and the ZCL weaken, together with underlying malar bone resorption, intraorbital fat tends to herniate from the infraorbital rim creating accentuated convexities in that region (Figure 15) (11).

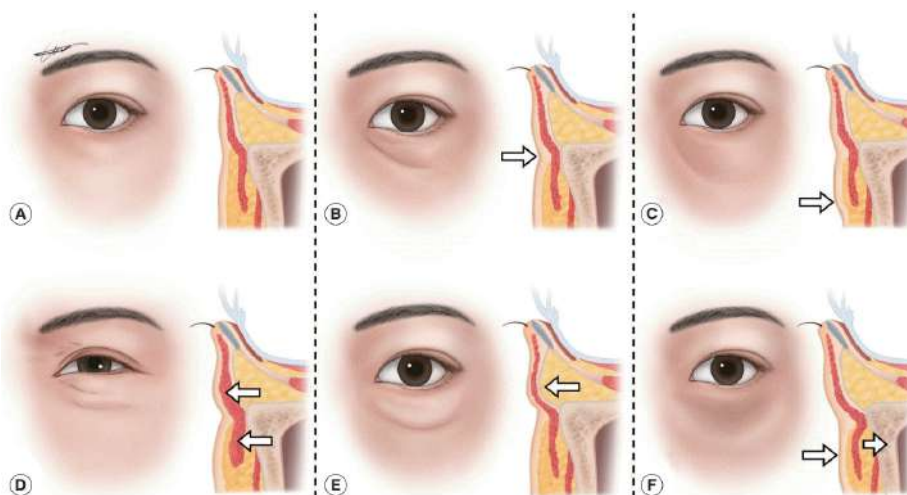


Figure 15 - shows formation of the TTF (B) and nasojugal fold (C) from skin, subcutis atrophy. D/E show OOM contraction and orbital fat herniation, respectively, worsening the folds. (F) shows malar hollowness as underlying bone resorbs. Adapted from (12).

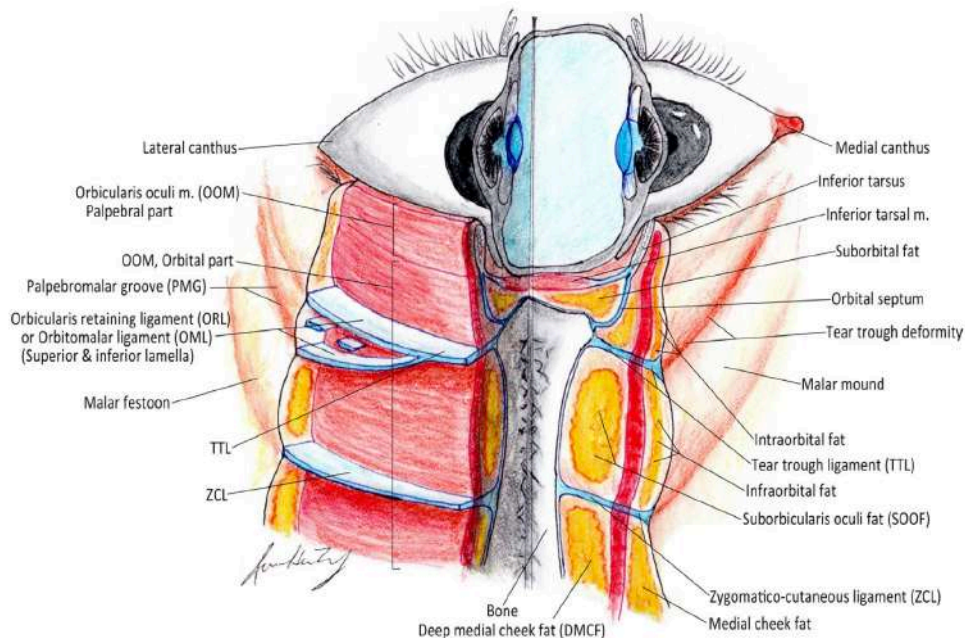


Figure 16 - shows relations of the various osteocutaneous ligaments to the fat compartments and muscles of the malar region. The various groove may be seen overlying their respective ligaments. Adapted from (13).

These convexities that form are referred to as malar mounds (eye bags) (13). The tear through deformity is considered as separate entity to the nasojugal groove, although they lie in proximity of each other, and some consider it the same, much debate remains around this in literature (12). It is proposed that the tear through ligament medially forms the tear through groove up to the mid-pupillary line and laterally continues as the palpebromalar groove (14). While the ZCL starts medially in close proximity to the tear through ligament but continues inferiorly to it as the nasojugal groove and then forms the midcheek groove (13). The malar bags forms between the ZCL and ORL, i.e. between the tear through, palpebromalar groove and the nasojugal, midcheek groove (Figure 16, above) (13).

Furthermore, other anatomical changes may be found. Atrophy of the skin and subcutaneous fat overlying these osteocutaneous ligaments, deepen these grooves (12). Contraction of the orbicularis oculi worsens the depth appearance even more (12). A protrusion of the infraorbital rim may also create a greater convexity in this region (12). Congenital differences in orbital septum (OS) attachment and its laxity also influence the extent of expansion of intraorbital fat, for example, more anterior OS attachment allows for anterior displacement of fat (15).

Bone resorption in the orbit leads to retrusion of the overlying tissue giving the impression that soft tissues have displaced inferiorly (12). Similarly, this maxillary bone retrusion accentuates the nasolabial fold (15). The SMAS at the nasolabial folds loses muscle tone, together with atrophy of the skin and fat and weakening of the local retaining ligaments further add to the deepening the fold (16).

Treatment for the aged midcheek has both surgical and non surgical interventions, where the surgical interventions include facelifting and may be with an extended lower lid blepharoplasty (17).

Age associated changes in the Lower Face

2 important ageing features will be elaborated on here, firstly Jowls and secondly, the labiomandibular fold (Figure 17). Jowls form as a result of weakening of the roof of the lower premassesteric space, i.e. the platysma, together with increased laxity of the anterior masseteric retaining ligaments, results in ptosis of fat and other soft tissue (18). The labiomandibular fold or marionette line, similarly forms from laxity of anterior masseteric retaining ligaments, which allows ptosis of buccal fat and other superficial fat (Figure 18) that is still however confined in its buccal space (17). The mandibular cutaneous ligament does not considerably weaken, thus the tighter it remains the greater the presence of jowling (18).

Features of the aged face should be adequately identified and treated appropriately, making the patient consult and clinical examination critical (11) and so is discussed in the next section.

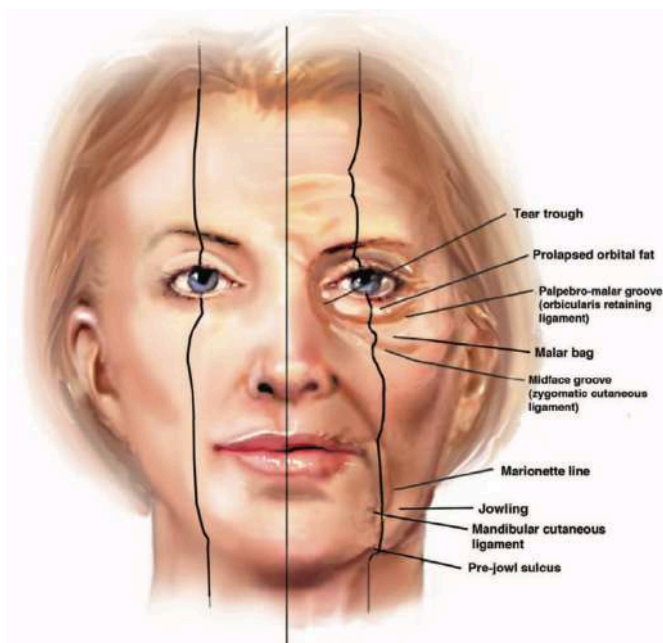


Figure 16 (above) - shows the characteristics of the youthful face on the left and associated changes with ageing on the right. Adapted from (10).

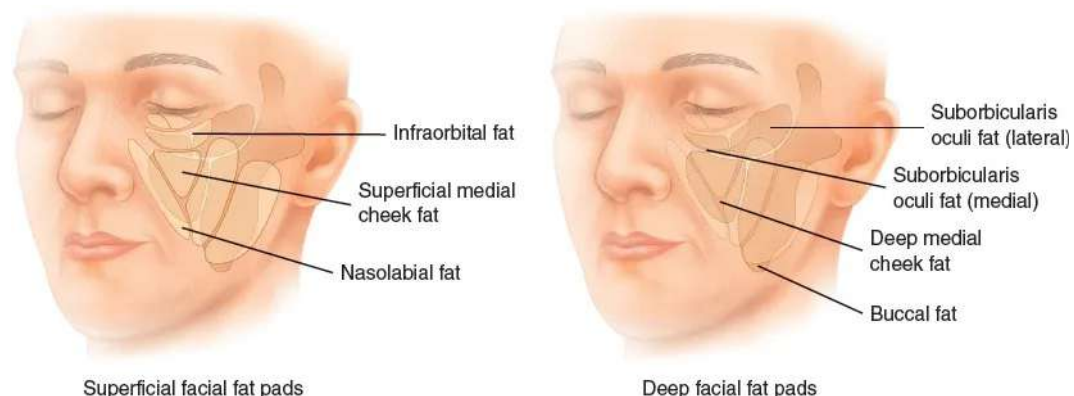


Figure 18 - shows the anatomy of superficial and deep fat compartments separated by various ligaments. Adapted from (17).

The patient consult and clinical assessment

Aesthetic facelifts are elective procedures and patients arrange consults to seek a professional opinion stemming from a psychological desire to improve the image of one's self (3). Initially, it is important to ascertain from the patient what is it that they would like to correct and the goals of the treatment. 2 assessments should be conducted, firstly the aesthetic facial evaluation and then general preoperative screening (11).

All mostly facelift procedures tighten the SMAS in the vertical vector (18). The choice of facelift is at the discretion of the surgeon as there is no standard consensus for the different techniques, thus a precise cephalometric analysis is imperative for a good outcome (11). Cephalometric analysis is evaluated by dividing the face into 3 equal thirds at the trichion, nasion, subnasale and at the menton (Figure 19) (2).

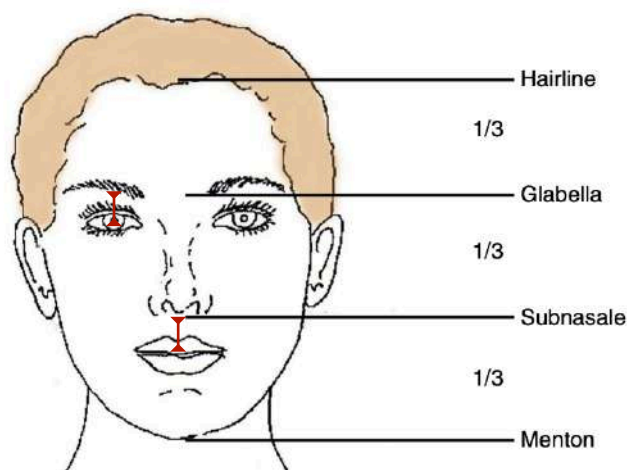


Figure 19 - shows the division of equal thirds across the face that define symmetry, proportions and beauty. This guides outcomes of facelift interventions. Adapted from (2).

Using these thirds the presence of facial asymmetry can be determined. In the middle and lower thirds, ageing characteristics should be identified, in the context of this thesis (2,14). Malar bags, jowls, deeper nasolabial and labiomandibular folds, for example should be identified (Figure 20) (14).

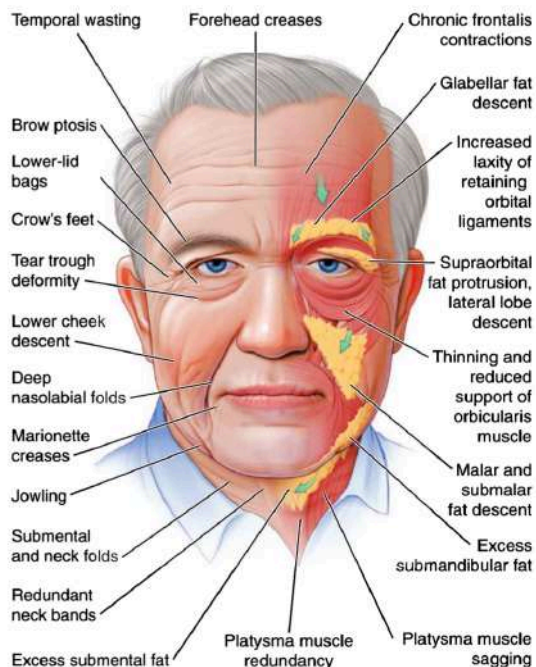


Figure 20 - shows the changes, such as ptosis of the underlying soft tissue of the different regions that contribute to the effects of ageing. Adapted from (9).

Non-surgical techniques may also be used and are actually becoming the more common form of facelifting (8). The surgeon should evaluate whether the extent of ageing changes can be corrected non-surgically, for example, if there is an isolated nasojugal groove that may be corrected with fillers or it is associated with deep nasolabial folds, i.e. larger region of the face is affected and a surgical facelift may be more effective, longer lasting and more economical (11). These techniques correct for volume deficiency, as opposed to ligament laxity and loss of muscle tone (14). However, even when a surgical facelift is performed, injectable fillers such as fat, hyaluronic acid, etc, may be used to augment the contours during a facelift surgery to perfect results, especially where there is considerable volume loss (16). Non-surgical and adjuvant rejuvenation will be discussed later.

After the aesthetic analysis has been determined and agreed on, a general medical screen is also important to conduct to determine the health of the patient and their capacity to undergo a facelift procedure, as would be done with any preoperative assessment (11). Patient history and physical examination need to be performed (11).

Following this, preoperative risk factors such as hypertension, anticoagulant medication, smoking, deep vein thrombosis and body morphic disorder need to be tested for (11). Hypertension leads to worsening postoperative hematoma complications (2). A group of surgeons, Beer *et al.*, reduced the hematoma complication rate from 7% to 0% by giving 0.15 mg of clonidine (19). Furthermore, Aspirin and Vitamin E should be avoided (11). In another study it was reported that smoking increases risk of skin sloughing by 1200% (11). Thus certain recommendations should be made regarding such scenarios, i.e. hypertension control and smoking cessation (9). Former smokers generally have poorer quality of skin and may have worse aesthetic outcomes (2,3). Certain groups have reported that there is significant reduction of complications and improvement of results after 4-weeks of smoking cessation prior to free-flap breast augmentation (11). Other claim that there is a 20% relative risk reduction for all complications, for every week of smoking cessation. There is no standard protocol for smoking cessation for facelifts (11).

Risk of skin sloughing may be reduced by performing deep plane facelifts (as they increase vascularity of the skin flap), minimal skin undermining, reduced skin tension and incision length (11,15). Interestingly, based on one study the highest rate of severe cases of body morphic disorder are found in facelift patients (11).

It is important to discuss all the possible complications (elaborated on in a later section) and thus the risk of a suboptimal result of a facelift has to be understood by the patient so they may give appropriate consent.

Once the general screening, aesthetic analysis and outcome risks have been discussed with the patient, the surgeon decides based on their opinion what surgical/non-surgical technique is best to employ (9). Here the patient decides where this is inline with their desire and may consent to the procedure. These techniques are discuss in more detail next.

Facelift Surgical Techniques

Subcutaneous Facelift

The subcutaneous technique (superficial and deep) (Figure 21) is the first facelift procedure to have been implemented (2). The initial skin incision is done preauricular, and may be endotragal to hide the scar at the anterior auricular sulcus (20). However it may be visible still in the superior and inferior portions (20). It continues, temporally along the hairline, rather than into the temporal hair, to prevent lifting of the hairline superoposteriorly (Figure 22) (21). The blade may be angled parallel or perpendicular to the hairs. A perpendicular angle allows regrowth of hair through the flap masking the scar. While a parallel angle may be used if there is hair remaining on the flap (Figure 23) (20). It involves the dissection and making of skin flaps either at the superficial or deeper subcutaneous level (2,3). It creates flaps of the cheek and jowls which are suspended in the superolateral vector (18). Nowadays, it involved extended dissection of the flap towards the nasolabial fold, however stops a few centimetres before it (5). During dissection it is important to pay attention to McGregor's patch. McGregor's patch contains the zygomatic cutaneous and masseteric ligaments, which are highly vascularised and have perforating vessels in their region, thus may lead to hematoma complications and intraoperative bleeding (10). Generally, osteocutaneous ligaments traverse through all layers of the face and anchor at the retinacular cutis in the subcutis (2,10). The amount of undermining of the skin has considerable variations, together with the extent of their dissection in each direction (15). Additionally, the extent of ligamentous release should be done with caution as they compartmentalise soft tissue structures, to prevent iatrogenically induced ptosis (2).

2 levels in the subcutaneous tissue can be dissected: a superficial and deep level. Superficial dissection provides for better protection of the facial nerve as it is found deeper in the subcutis (2,3). Atrophy of this layer with ageing exposes the facial nerve more, increasing the risk of damage during surgery (7,8). Superficial dissection can be performed when planning to do a SMAS flap, as leaving the retinacular cutis attached to the SMAS flap provides greater support to the flap (5,18). Deeper dissection is used to uncover the SMAS, to perform SMAS manipulation techniques (2,3). Due to further distance from the dermis and less vascularisation, there is less risk of bleeding, however, the possibility of damage to the facial nerve branches is greater (2). The levels of dissection are illustrated in Figure 21.

For example, deep dissection may be done on the surface of orbicularis oculi and may be dissected more laterally into the malar fat pad for greater subcutaneous suspension of the nasolabial fold, but hold greater complications of edema (12,13). Indications for a subcutaneous facelift are appropriate for patients for patients with excess and atrophied skin, and with only slight soft tissue ptosis and bone resorption (2,3,5). This technique may also be used for a revision facelift of other deeper facelifts (2,15). However, the outcome depends on the quality of skin and skin tension does not lift underlying tissues (11,13). Furthermore, skin tension also may lead to tissue necrosis, auricular displacement and scar stretching (2,8).

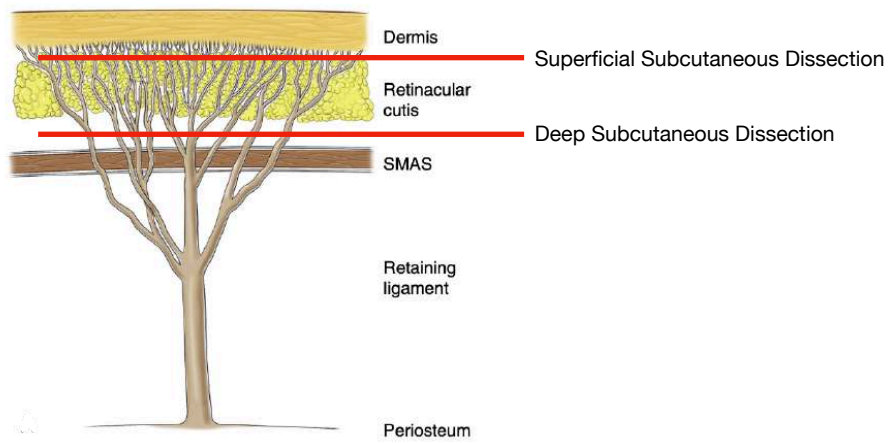


Figure 21 - shows the levels of possible dissection when performing a subcutaneous facelift. Adapted from (2).

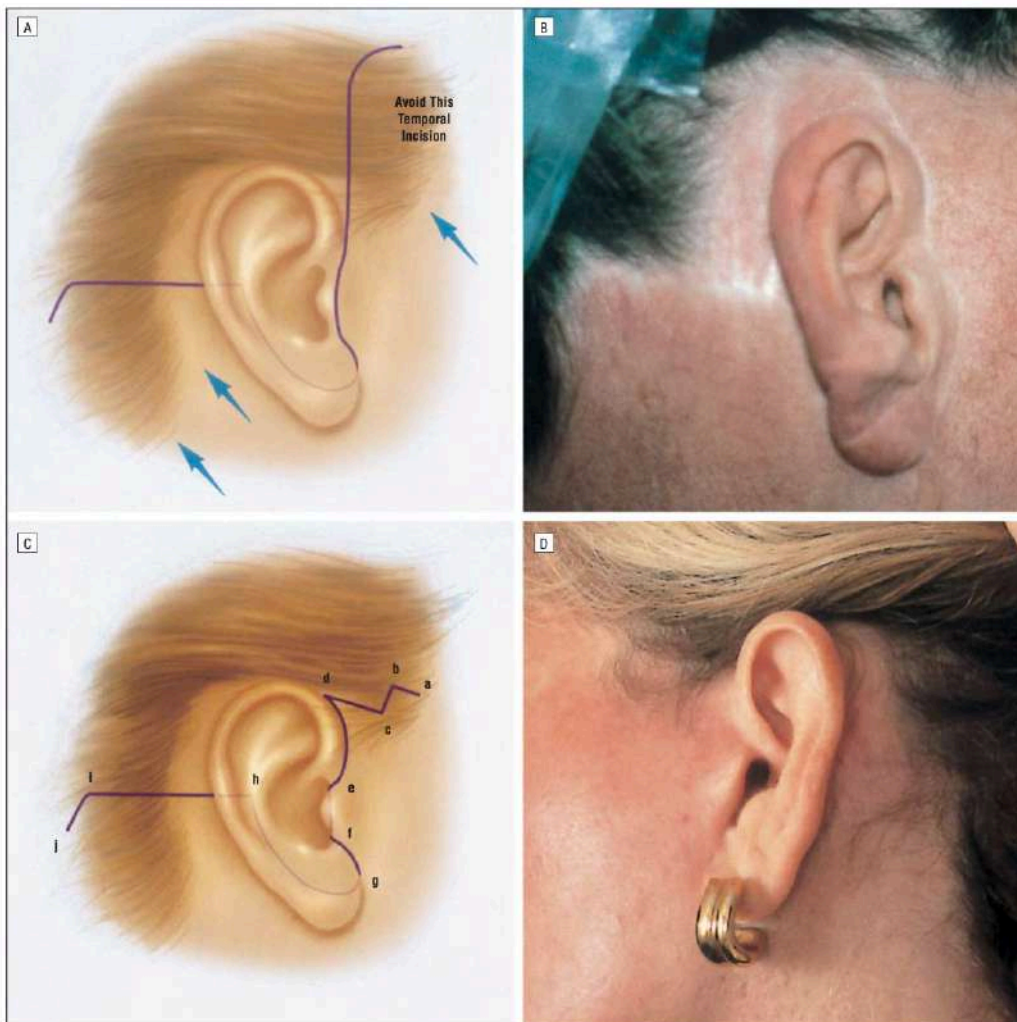


Figure 22 - A;B shows the preauricular incision extending into the temporal hair, which may lead to an elevated hairline as excess skin is excised. C;D show when a temporal hairline zig-zag incision is done to reduce skin tension and prevent elevation of hairline. Adapted from (20).

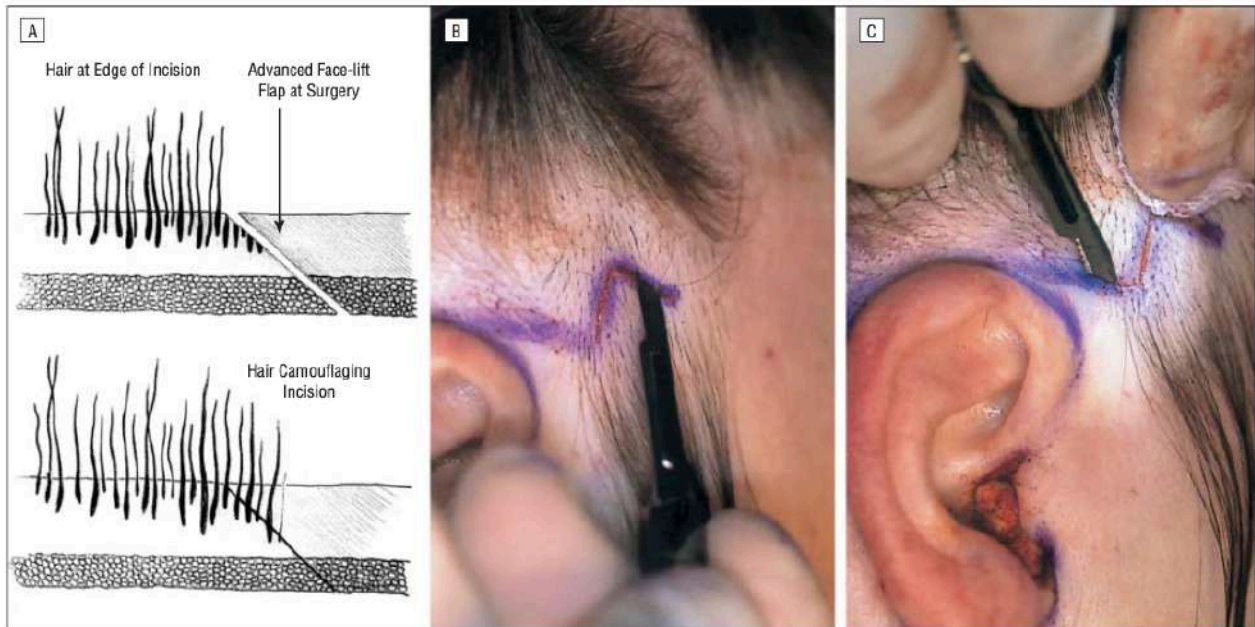


Figure 23 - A;C show when the incision at the hairline is done perpendicular to the hair, so that regrowth of hair occurs through sutured boundary. B shows when the incision is done parallel to the hair follicles, which minimises damage to hair however should be found on the sutured flap to better hide the incision. Adapted from (20).

SMAS plication/imbrication Facelift

The primary skin incision is also done at the preauricular sulcus, and may extend to the post-auricular sulcus (21). This technique involves the mobile SMAS in front of the anterior border of the parotid where the fixed tightly bound SMAS is found (22). Plication involves the infolding of SMAS tissue and suturing this together. Imbrication involves undermining and incision or excision of the excess SMAS tissue and then overlapping the ends of the flap and suturing it (Figure 24) (22).

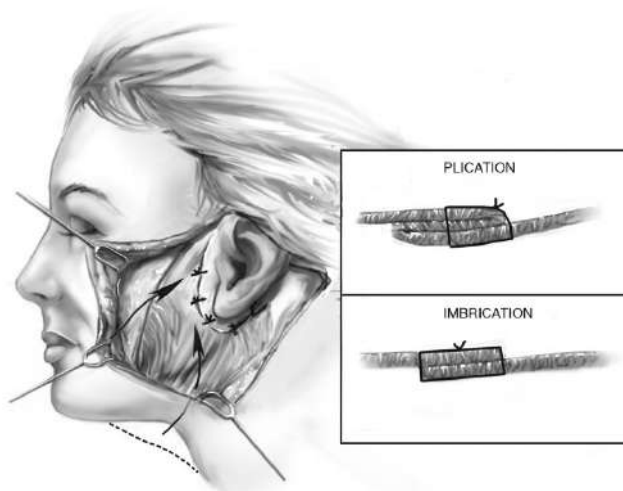


Figure 24 - shows the difference between plicated tissue and imbricated tissue and how it appears from the surgeons perspective on the lateral aspect of the face. Adapted from (23).

Excess skin is also marked post and preauricularly and excised. SMAS plication/imbrication is safer than deep plane facelifts as there is greater preservation of the facial nerve branches (22).

Continuing, it is also more effective than subcutaneous facelifts as it manipulates mobile denser tissues and also have a more expeditious recovery (22). However, the limitation of undermining SMAS in certain regions, such as its limited release from the anterior masseteric ligament, prevents adequate tightening of the nasolabial fold i.e. the anterior midcheek and face (2,3). It is adequate for tightening of jowls and labiomandibular folds (22).

Deep Plane, Extended SMAS and Composite Facelifts

Classic deep plane facelift, start with a preauricular incision and subcutaneous flap formation which is dissected along the surface of the SMAS up until the entry incision into layer 4 of the soft tissue. i.e. the deep plane (Figures 25 and 26) (24).

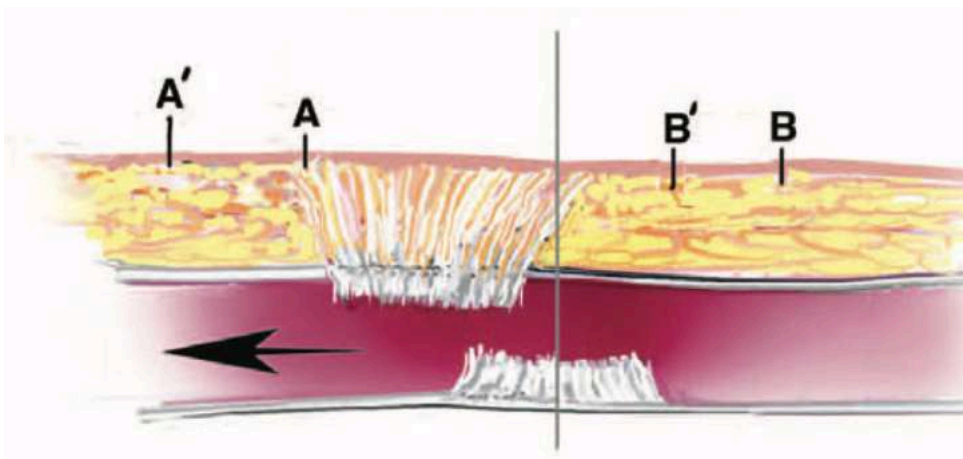


Figure 25 - shows the deep plane (layer 4 in red) where the retaining ligaments are cut to undermine the SMAS. The skin, subcutis and SMAS are advanced to the left (arrow) to their new positions (A';B') from their original positions (A;B). Adapted from (10).

The entry incision into deep plane is done from the angle of the mandible to the lateral canthus of the eye and for the necklift follows the posterior border of the platysma (Figure 26) (25).

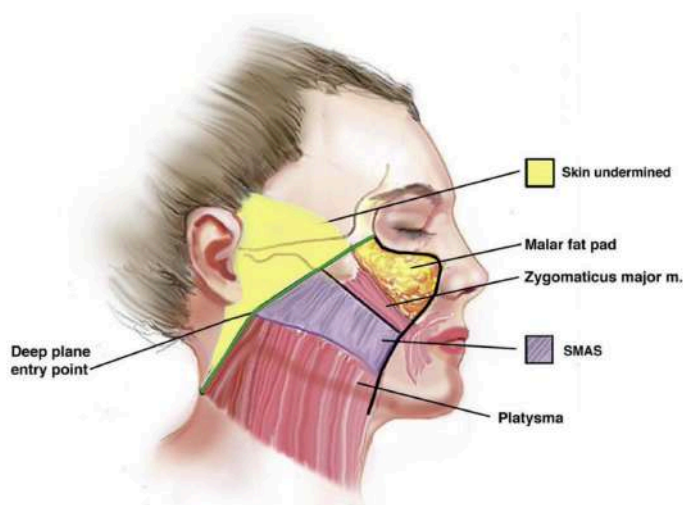


Figure 26 - shows the deep plane incision (green line), the extent to which the skin is dissected (yellow area), the muscles with the mobile SMAS (purple area), and the extent of undermining of the SMAS (black line). Adapted from (25).

Once the incision of the SMAS is done, undermining and thus release of the SMAS from ZCL, masseteric, maxillary and mandibular retaining ligaments is conducted toward the medial face up

until the border of the zygomaticus major muscle (25). This forms a composite flap (containing all 1-3 layers of soft tissue) providing good vascularity (2,3). This flap may then be fixated superolaterally, with the excess undermined subcutaneous flap removed, providing a new lift vector for correction of jowls and the nasolabial fold (25). However due to the limited effect on the medial face, on the correction of nasolabial fold and the inferior malar fat shift the modified extended and composite facelift we developed (26). The extended SMAS facelift is modified to further extend both the subcutaneous flap and SMAS flap (Figure 27) (26). The SMAS flap continues as a more superficial dissection passed the zygomaticus major muscle reaching the nasolabial fold, where the final release of the maxillary ligament occurs (27). Similarly, the subcutaneous flap also extends further medially to almost reach the nasolabial fold (26). This creates dual plane flaps as they can be fixated in different vectors (2,26). The SMAS flap is suspended, at a more vertical vector, to the parotid and deep temporal fascia, while excess skin on the subcutaneous flap is excised, and suspended in a similar vector but slightly more lateral to the SMAS flap, to allow for minimal/no tension at the closure site, for minimal scarring (26).

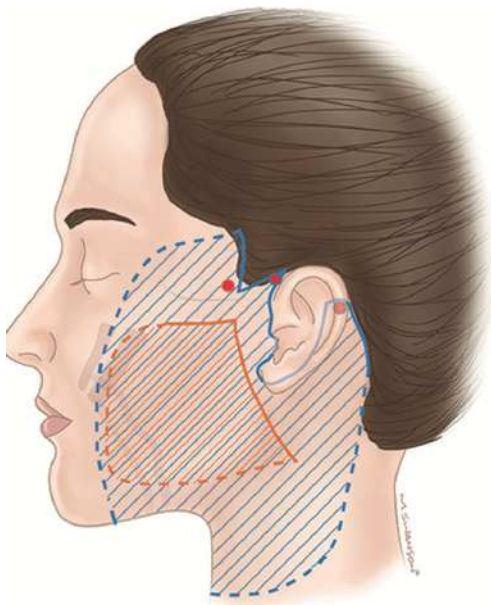


Figure 27 - shows the extent of skin dissection (blue shaded area) and the extent of mobile SMAS dissection in an extended SMAS facelift (orange shaded area). Adapted from (28).

This allows for better correction the nasolabial fold, but however some claim that is has a reduced effect on jowl correction due to the greater distance of dissection between the new suspension of the SMAS and the jowl (27,28). However, due to the superolateral vectors found in these aforementioned SMAS techniques, they may give the appearance of a lateral sweep (27). This is the due to a unidirectional correction vector that does not totally address tissue descent in the vertical vector, as occurs with ageing (27). Furthermore these techniques also do not address other parts of the aged face such as the orbit and forehead (24,27). In order to holistically rejuvenate multiple aspects of the face to give a more natural look, the composite facelift was undertaken by Harma (27).

Initially, the composite facelift, starts with an upper blepharoplasty and the anterior portion of the submental neck (2). The midcheek lift is performed in the same plane as the extended deep plane facelift starting from a preauricular and post-auricular skin dissection and making entry in the deep plane at the anterior border of the parotid where the mobile SMAS begins (28). Where SMAS undermining continues to the nasolabial fold, but more superficial at the zygomaticus major muscle (28). The neck is separately dissected starting laterally and preplatysmal to the inferior neck crease, and then a deep plane dissection is done subplatysmal (27,28). Then a separate forehead dissection is done at the temporal region through a hairline/coronal incision (28). This results in 3 mesenteries being formed: meso-temporalis, meso-zygomaticus and meso-mandibularis (Figure 28) (27). These mesenteries contain the branches of the facial nerve (27). Furthermore, during lower blepharoplasty orbicularis muscle suspension and septal reset (27,29, 30) is also performed. The deep plane midface lift is performed last in the composite surgery (28).

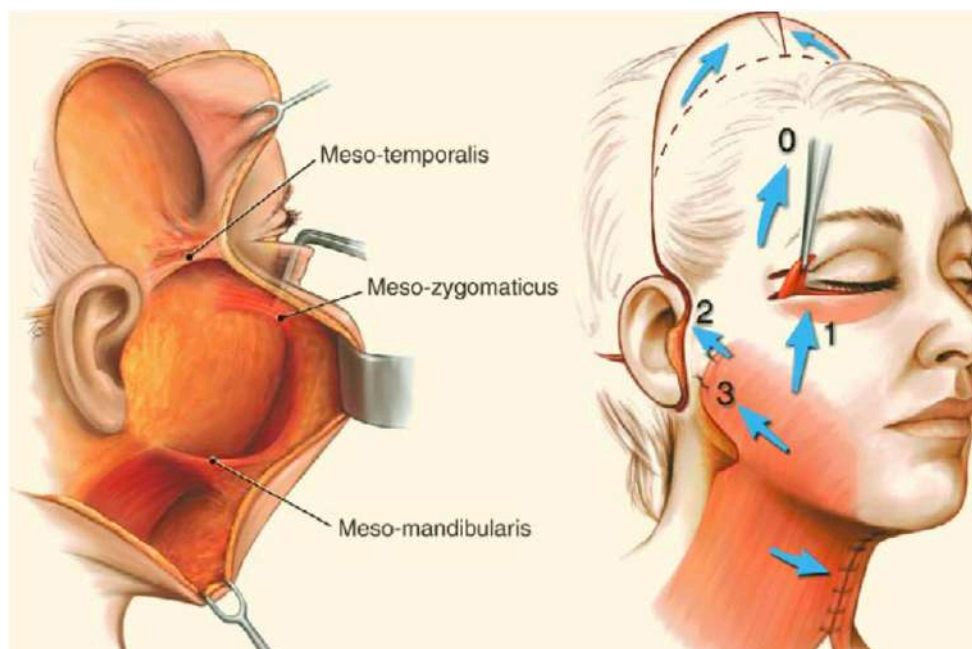


Figure 28 - left: shows the 3 mesenteries formed by undermining the SMAS in 3 different areas as well as subciliary entry for orbicularis muscle suspension and orbital septum reset. Right: shows the vertical suspension vectors stronger than lateral vectors in composite facelift. Adapted from (27).

The composite lift of the forehead, upper and lower blepharoplasty, address the other aspects of ageing and give a more natural look by thus applying a more superomedial vector (27). Together with the deep plane midface lift that lateralises the soft tissue provides a more natural lifted face as it does not give a lateral sweep appearance (27). However, some disadvantages of longer recovery period and a more complex surgical operation poses risk of successful outcome (27,28).

Lateral SMASectomy

Starting with a preauricular incision which may only slightly need to be extended post-auricularly based on the required amount of neck correction needed (28). This is referred to as the short scar technique (2,28). Subcutaneous dissection from the preauricular region continues to 2-3cm before the nasolabial folds and 5-6cm inferior to the mandible (28). The mobile SMAS is identified and weakened areas may be resected or plicated (2,28). The remaining SMAS flap may also be fixated in a more superolateral vector, i.e. in a perpendicular vector to the nasolabial folds (28,31). This flap may be anchored to the fixed parotid SMAS (2,28). A stacking of SMAS may also be done to add volume to the lateral cheek (28). Benefits include the simplicity of this technique, but it does not adequately address the midcheek (2).

High SMAS Facelift

The standard skin incision is performed with subcutaneous dissection done to 4-5cm within the preauricular region (25,28). The SMAS incision is done higher up to the border of the lateral orbicularis oculi muscle (OOM) (25). Undermining of the SMAS in the higher malar regions is done along the border of the OOM to identify the start of the zygomaticus major muscle (ZMM) (28). Dissection of the fixed parotid SMAS is done until reaching the mobile lateral SMAS which is then further undermined carefully to avoid damage to the facial nerve branches (Figure 29) (25). The SMAS is released from the ZCL, as with other deep plane facelifts dissection occurs superficial to the ZMM in the subcutaneous plane (28). This gives traction to the malar fat in the midcheek as the entire flap is then suspended higher to the deep temporal fascia, so that the cheek as well as the lower eyelid is advanced (Figure 29) (25,28). As a result this technique allows for the correction of the midcheek as well as jowls and neck (24,31). The composite (containing all tissue layers) flap allows for better vascularisation and ultimately less hematoma formation as less dissections are performed than with individual flaps (28). Although, dissection in the temporal area should be performed with caution as not to damage the temporal branches of the facial nerve (2).

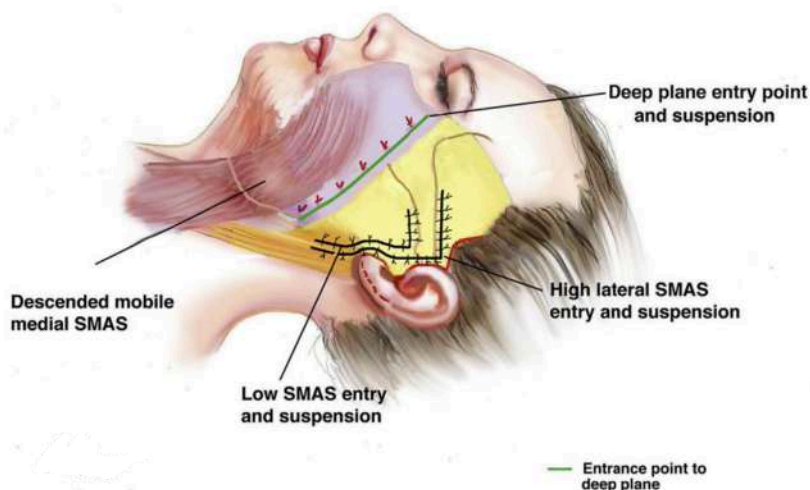


Figure 29 - shows the extent to which the skin is dissected (yellow area) from the preauricular incision (red line), then dissection of the fixed SMAS from the high lateral SMAS entry point (black line labeled), containing the mobile SMAS and undermining further. *Adapted from (25).*

Minimal Access Cranial Suspension (MACS) Facelift

MACS facelift is more recent technique that offers a shorter recovery time due to it being a less invasive procedure (28). Firstly, a zig-zag temporal prehairline incision is done starting at the height of the lateral canthus (28). A subcutaneous flap is made by subcutaneous dissection 5-6cm anterior and down to the posterior platysma border (2,28). Once the subcutaneous flap is dissected, a pair of loop sutures is placed through an anchoring point in the deep temporal fascia, 1 cm anterior to the root of the ear helix (2,28). The posterior suture travels to the superoposterior border of the platysma and is anchored by a “U” shaped pursed string suture, thus tightening the laxity over this region of the platysma (Figure 30) (2). The second suture is passed down at a 30° angle to the jowls, where the pursed string suture is threaded in an “O” shape through the mobile SMAS (Figure 30), allowing tension to be place drawing the mobile SMAS together, reducing the laxity of the roofs of the jowls and labiomandibular folds (2).

In the extended variations of the MACS procedure, the temporal hairline incision is slightly extended and a third suture is anchored at the most anterior part of the deep fascia and is extended to the malar fat compartment (Figure 30), advancing the malar region superolaterally (2,28). Excess skin is removed by a subciliary approach at the lower eye lid and vertically at the lateral cheek and temporal region (3).

The procedure allows for a superolateral lift that is quite lasting and does not require deep plane undermining of SMAS with the risk of damaging critical nerve and vascular structures (28).

Although, some argue that fibrotic tissue forms around the sutures along the SMAS (2).

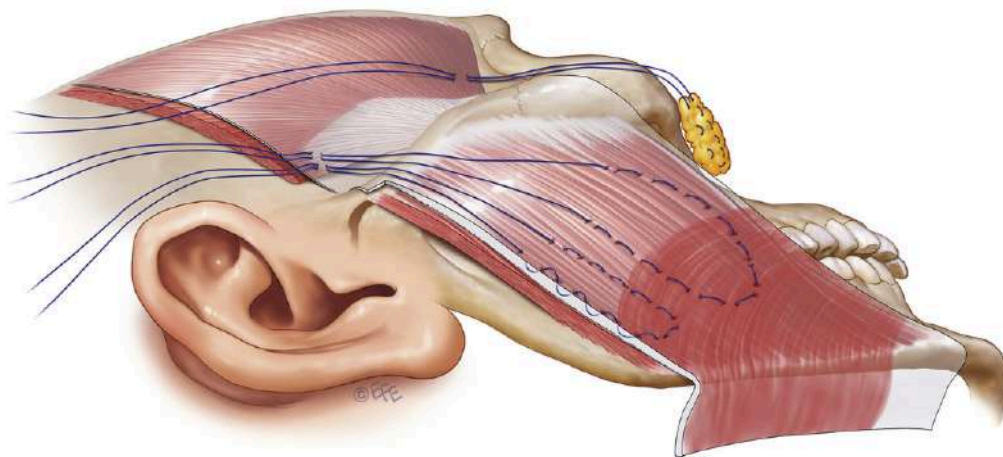


Figure 30 - shows the entry point of the sutures in the deep temporal fascia extending to the superior portion of the platysma and lateral and anterior aspects of the mobile SMAS. Another suture is passed from the more anterior temporal fascia to the malar fat pad. Sutures are anchored by using the pursed string technique. *Adapted from (25).*

Subperiosteal Facelift

This facelift utilises a temporal hairline incision and accesses the subperiosteal plane in which dissection is performed where the lateral and midface are separated from their attachments and resuspended more 2-3cm more superiorly (2,3). The superficial and deep muscles, i.e. zygomaticus major and minor, levator labii superioris, levator anguli oris and their related ligaments are released, as well as the masseteric fascia and all are reattached (2,3). If another glabellar dissection is performed toward the tip of the nose, and conserves the medial canthal ligament (2). This dissection allows for the entirety of facial soft tissues to be lifted (2,3).

An extended version of this facelift is carried out with a supra-zygomatic arch incision that provides access to the subperiosteal plane, away from the branches of the facial nerve (2,3). Similarly, this point of access allows for efficient release of masseteric fascia and allows for a smaller preauricular incision (2,3). However, these facelifts require lengthier recoveries, the high risk of trauma to the facial nerve branches during tissue suspension (20% risk of zygomatic and frontal palsies) and the new vectors, after reattachment of muscle and ligamentous insertions, could be awkward and strange (2,3).

Complications and Recovery

Several post and intraoperative complications can be identified that affect the outcome of the procedure as well as the length of the recovery.

Hematomas

Is the most common intra and immediate postoperative complication (32). As poor surgical dissection damaging the dermis and perforating vessels around the retaining ligaments creates large amount of bleeding and poor healing (33). This may further be complicated with tissue necrosis, edema and pigmentation of the surrounding structures (2). Subcutaneous dissection carries larger risk of hematoma formation than deep plane dissection as the vessels are easier to identify intraoperatively (2). Predisposing factors such a male gender, hypertension and non-steroidal anti-inflammatory drugs (NSAIDS) have to be cautioned at initial patient evaluations (2,34). Around 4.5% of hematomas are required to be removed, to mitigate further complications (2).

Nerve Damage

Sensory nerve damage occurs frequently as dissection and formation of a subcutaneous skin flap damages these nerve ending (32). This sensory loss last for 15-18 months after which most patients recover (33). Notice should be put on the path of the great auricular nerve, that superficially traverses tissues from McKinney's point, 6.5 cm below the external auditory canal (2). This is important when performing facelifts in conjunction with a neck lift requiring post-auricular dissection (2).

The motor component, i.e. the facial nerve branches, are also at risk of damage during any facelift procedure. Neuropraxia, as a result of tension or dissection, is most frequently found in the temporal branches resulting in temporalis muscle paralysis (2,33). The frontal and marginal mandibular rami are also affected and are clinically important as they are terminal branches, while the buccal branches have interconnecting segments (2,4). Most nerve damages tend to recover several months into the postoperative period, where total paralysis is infrequent and occurs up to 0.3% (2).

Skin Wasting

Facelifts use and dissect large areas of skin, that can be subject to ischemia and thus necrosis under tension (35). The post-auricular region is most vulnerable to this type of complications and recovery is managed by secondary wound healing (2,28). One study identified that 74% of patients with skin loss were smokers while another study found 19.5% were smokers, highlighting the large implication that smoking has on facelift recovery risks (2).

Scar formation

Skin tension always poses a risk to scar formation. They may be hyper or hypo-pigmented scars, that can hypertrophy or form keloids in the event of longer healing times and increased tension (28). Hair loss, scar widening and deformities at the earlobe or temple areas may result from errors in incision planning and design (2,28,32).

Infections

These complications are rare and occur in less than 1% of postoperative patients. Patients are given antibiotics in the preparatory phase of the undergoing facelift procedure (2,28).

Recovery and Duration of Results

Postoperative recovery time is usually between 3-6 weeks, for all the edema and wound healing to occur (28). However, deeper tissue healing occurs for several months after that and the final result can only be visualised after 6 months post surgery (28). The patients healing time may be attributed to several aspects. The quality of tissues the patient has such as the thickness and elasticity which are affected by age and external factors including photo-ageing and smoking (32). Furthermore, the architecture of the underlying bone structure and how it has atrophied is implicated in the result (28,32). All these factors delay healing. The surgical technique and the surgeons skill/agility to perform meticulous dissections, and precise closures not leaving any pockets in tissues contribute to more rapid healing (34). As a result the natural gliding plane (layer 4) should be preferred in facelifts for dissections and undermining over subcutaneous dissections (35). Minimising subcutaneous dissection and closing with fibrin glue and transcutaneous suturing which reduces edema formation (34). The type of post-surgical dressing should be put into question as they also seem to affect healing as some seem to give better results than others with reduced compression to the face (34). Postoperative antibiotic and pain management (NSAIDS) are of limited use as the complications of infection are rare, and do not seem to influence the

outcome of the surgery (2,34). The duration of a facelift similarly depends on the patients intrinsic qualities. Some patients age faster than others and may live an unhealthier life style, so this is hard to discern, however, different techniques also have their benefits (36). SMAS manipulation techniques are superior to the subcutaneous facelift as they manipulate dense tissue they take a longer time to weaken than that of the skin (37). SMAS, overall, is more resilient tissue for facelift longevity. The age at which the surgery was performed also influence the duration of results as a young patient that has undergone a facelift, for example at the age of 30, will be younger for longer versus a person that has undergone a facelift at the age of 50 (36,37). To reiterate this point where youthfulness can still be maintained for years after surgery: A study was conducted where a large group of 200 patients were questioned about their satisfaction 5, 10 and 20 years after undergoing a facelift. In all groups the majority either claimed that their results were either good or very good at 5 and 10 year time points, and satisfactory at 20 years (34). Other studies found that secondary facelifts and tertiary were performed 9 and 7.5 years after the preceding lift (37). So it may be said that overall longevity for facelift may be considered as several years and it varies for patient to patient, as all humans have different physiological qualities based on genetics and lifestyle, that affect how they age, and thus how the facelift ages (38).

Non-Surgical Facelift Techniques and Comparisons

The non-surgical facelift has recently developed several modalities and has become an effective alternative to the surgical facelift. The Aesthetic Plastic Surgery National Database in the United States of America, conducted a statistical report for 2020-2021 for various aesthetic procedures and compared surgical vs non-surgical interventions. They found that surgical facelifts were significantly less common than other aesthetic procedures such as liposuction, breast augmentation, abdominoplasties, mastopexies, etc (39). However, of the non-surgical interventions, non-surgical facelifts were the most common sought out procedure (40). The amount of procedures non-surgical facial procedures exceeded 9 times that of facelifts (39). These interventions are most commonly in the age group 36-50, while surgical facelifts are more common in people aged >45 years old (39,40). Globally, the amount of yearly facelifts within the period 2017-2020 has decreased by 11%, however in 2021 it has risen by 2.7% greater than that of 2017 (41). This might be attributed to the recent corona pandemic (41). While non-surgical procedures rose approximately 54% for facial rejuvenation (41). There is wide popularity for non-surgical procedures as the ease and recovery are superior to surgical facelifts, however the long terms costs, long term recovery and the perceived age reduction in less efficient than in a surgical facelift (Figure 31) (42). Patients tend to use non-surgical procedures prior to surgical facelifts, as well as to augment post surgical facelifts (42). A study showed that patients underwent 7 non-surgical treatments before requesting a surgical facelift. With a 3 day recovery, that makes a total of 21 days of recovery, while the study had the patients back to normal life behaviours between 10-14 days (42). Some of the patients claimed they would have undergone surgical treatment sooner if they were more aware with the effectiveness and increase longevity of the results (42). Nevertheless, non-surgical facial rejuvenation is a rapidly growing market and a

powerful tool, that is used for more subtle corrections and for those with less extravagant age related changes (41). Patients seek quicker short term recoveries and less risky outcomes (42). In continuation, the various non-surgical procedures are explained below.

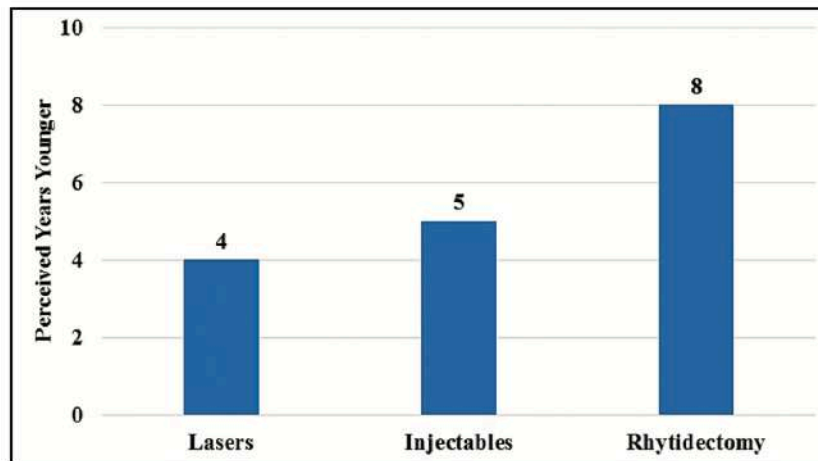


Figure 31 - shows the relative perceived years younger based on a specific anti-ageing procedure undertaken. Their relative differences can be deduced, showing the risk:reward features. Adapted from (42).

Botulinum Toxin Injection

Botulinum Toxin, more commonly known as Botox, is the most widely used non-surgical intervention for cosmetic rejuvenation (41). It functions by blocking acetylcholine transmission and the neuromuscular end plate, by preventing the release of acetylcholine from the presynaptic nerve terminals (2,43). This results in a paralytic effect of the muscle that those nerve ending innervate (44). The effects start 2-3 days after injection and climax around 1 week post injection (44). The durability of treatment is usually around 3 months, and thus repeat injections are required for maintenance (43). Botox is used to indirectly reduce movement of the skin in regions of the face where it most happens (44). This is achieved by paralysing the underlying muscles, to alter the balance between tensions of elevator and depressor muscles to achieve facial symmetry and skin deformations (wrinkles) (2,45). By reducing tension in the area, it aids in scar management and in other procedures such as in the brow lift, for postoperative control (2). It is administered in using a small gauge needle (32/33 G) and injected intramuscular in smaller aliquots (46). The solution of Botox has predefined concentrations in units per millilitre. The estimated amount of units required per region of the face can be seen in Figure 32. As low volumes should be injected sometimes higher concentrations, for example at 10 units/0.1ml, are needed (2). Molecular variations exist that confer different properties to the effects. Abobotulinumtoxin-A has a greater distribution and thus can cover a greater area per injection, which is beneficial for larger surfaces such as the midcheek (2). On the other hand onabotulinumtoxin-A is able to be injected at higher concentrations and thus may be used for more precise induction of muscle paralysis (2). Patients may be followed up a week to 2 weeks

following a treatment (2,47). It is important to note patients allergic to eggs or albumin; or have infections should not receive Botox (46).

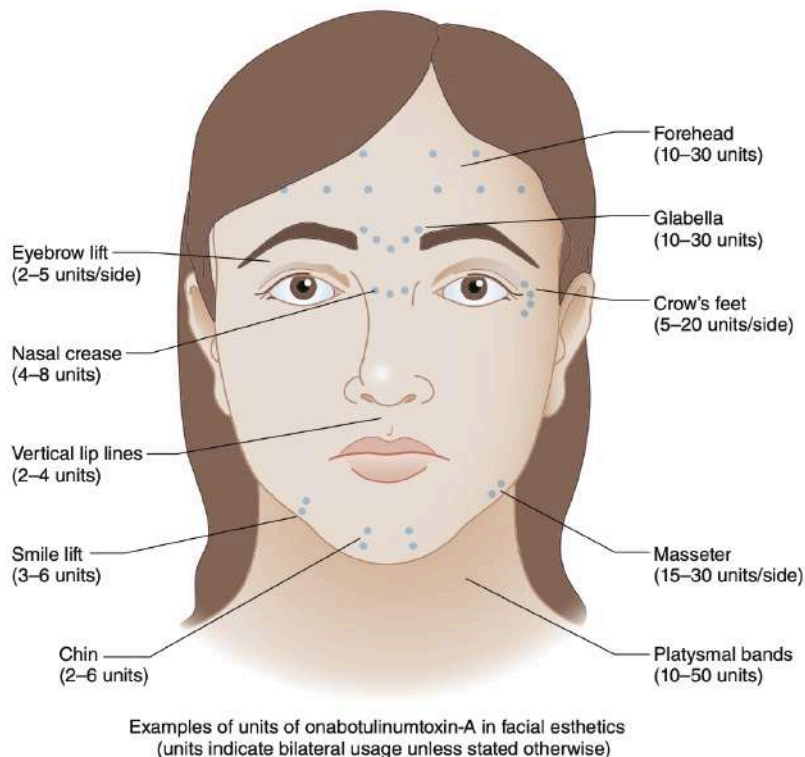


Figure 32 - shows the amount of units that should be used in each region of wrinkling. Higher concentrations with lower volume should be injected in smaller areas such as at the crow's feet. Adapted from (2).

Complications of botox are infrequent and may affect the eyes. Which may be dried, watery and/or cross eyed from muscle paralysis (44). Furthermore, adverse effects are reduced ability to swallow with weakness of the mouth and neck. Ptosis of regions in which Botox is injected occurs due to loss of underlying muscle tone (46). For example, loss of OOM tone, from injection of crow's feet leads to lower lid laxity and bagging (2,46).

Soft Tissue Fillers

Fillers are used both to augment a youthful image as well as to address ageing changes. Fat grafting is a cost effective and abundant tool for facial rejuvenation (46). However, the integration of the fat graft is unreliable, as retention of cells vary depending on the viability when they are grafted and their procedure used (46). Power assisted methods that induce trauma should not be used as they reduce cell concentration (47). When grafting is done should be done to reduce fat trauma and nodule formation (44). This is one of the most common complications together with poor contouring where new lines become visible (46). This can be seen in the periorbital region if fat is injected to superficially in or above the OOM, rather than deep to the OOM, i.e. preperiosteal (46). Vascular embolisms may also occur, as in synthetic fillers, which are difficult to treat (2,46). Lastly, many treatments might be needed to reach the desired outcome as retention of the graft is unreliable, due to the above mention reasons (46,47).

Synthetic fillers have various material properties that affect their behaviour to external forces, such as stretch and compression, distribution and viscosity (2). These influence the effects they give but may be unpredictable over time (44). Mostly, fillers are injected in the skin at various depths (Figures 33 and 34), mostly in the deep subcutaneous layer as has adequate spacing and does not result in a dermal reaction (granulomas) and using various techniques (Figure 35) (44,46). Non-biodegradable and Biodegradable fillers are manufactured.

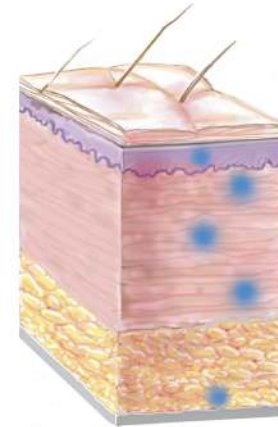
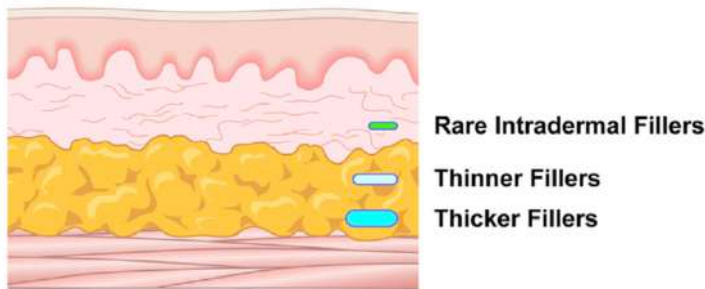

Figure 33 - shows the depth at which types of fillers should be placed. Thicker fillers that provide greater structural support as they do not disperse easily, should be placed deeper. Those with better dispersion characteristics may be placed more superficially, as to prevent nodule formation. Adapted from (44).

Figure 34 - shows the depth at which types of fillers/toxins should be placed in blue. Intramuscular placement of Botox is done to achieve muscle paralysis. Preperiosteal placement of filler is done in regions that naturally have greater laxity such as at the orbicularis oculi, preventing nodule formation. Adapted from (46).

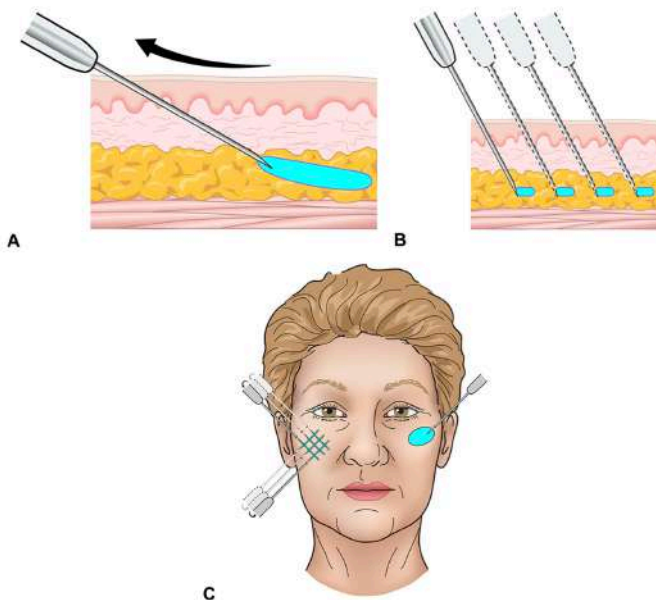


Figure 35 - A, shows the linear threading technique of filler infiltration, where filler is added continuously while drawing back, for large regions to be covered. B, serial puncture technique where small volumes are reinjected in adjacently spaced areas, allows for precision. C (left), cross hatching technique where linear threading is done in perpendicular vectors, covering larger areas more controlled. C (right), depot method for large volume deliver in tissue and is then massaged in adjacent tissue. Adapted from (44).

Silicone oil is a non-biodegradable filler, that functions to stimulate collagen formation as well as direct volume infiltration (2). It may be used to provide volume in areas of medium/small sized degenerated scars (2). However, as it is irreversible and non-biodegradable foreign-body granuloma formation may occur, together with embolisms and allergic reactions (2).

Another non-biodegradable filler is Polymethylmethacrylate (PMMA) microspheres, which induce collagen formation (2). It is administered with bovine collagen which is degraded, however, may induce allergic reactions, and the microspheres also may stimulate granulomatous reactions (2).

Calcium Hydroxyapatite microspheres mimic the bone molecular composition and stimulate the production of collagen (2,46). They have a longer durability of effects which last around 15 months, and due to its properties do not distort its initial shape with time (47). It is primarily used for contouring of the nasolabial folds (46). However, as it is irreversible, care has to be taken when being injected as it may cause pigmentation of the skin if it is injected superficially, such as in the eyes and lips (45,46).

Poly-L-Lactic acid (PLLA) is a synthetic molecule that over time is broken down to lactic acid. It is injected into the skin and results in increased collagen production (44,47). With PLLA 3 injections are required over a period of months and the patients should massage the area of injection 5 times a day, for 5 days post injection for 5 minutes (2). Care to avoid overfilling injection sites is promoted to reduce granuloma formation risk (2).

Hyaluronic acid (HA) is another biodegradable filler that is also naturally occurring as one of the major components of the extracellular matrix (43). It is the most common filler currently used (41). It is cross-linked by design to reduce the amount of degradation by hyaluronidase (2,46). It forms the foundation on which collagen is laid upon and also increases the osmolality which draws water to sites of injection (47). When hyaluronic acid is infiltrated into the skin it lasts between 4-12 months (2). The longevity depends on the patient's efficiency of hyaluronidase activity in particular regions of the face and the extent of cross-linking and other molecular properties defined by the producer (2,46). This filler is used mostly for the correction of wrinkles and nasolabial folds and other grooves (46,47).

Volume replacement may be used to provide support in regions of jowling, scarring (as in acne), tear through deformity, for example (Figure 36) (46). Different manufacturers generally produce this filler with either good distribution properties which can be injected more superficially and those with greater structural integrity (thus greater longevity) for greater support and are injected slightly deeper (2). Nasolabial folds and labiomandibular folds are optimally corrected using fillers that have some properties of both (Figure 36) (2,46). Folds should be injected in a vertical or at a slightly angled cannula to the fold to prevent exacerbating the fold (2). A particular complication is blue-grey dyschromia, specifically in the periorbital area due to high dermal infiltration that may occur even months after injection (2). Bruising also occurs thus care should be taken to avoid highly vascularised regions such as the interglabellar area (2). Injecting fillers into vessels has serious complications such as blindness and even stroke (46). Compression may be applied previous to and after injections to reduce bruising (44).

It is important to not create an appearance of a lifted face, by using minimal or no fillers filler at regional boundaries of the face (2). This filler may be removed at sites, and possibly reverse blindness (within 90 minutes of the symptom) by injection of hyaluronidase (2). Blindness and

stroke may also be treated with high-flow oxygen, anticoagulants and anti-glaucoma medications (46). Delayed onset nodules also may form with several weeks after injections and may be treated with antibiotics and hyaluronidase, suggesting an immune component of their pathophysiology (2).

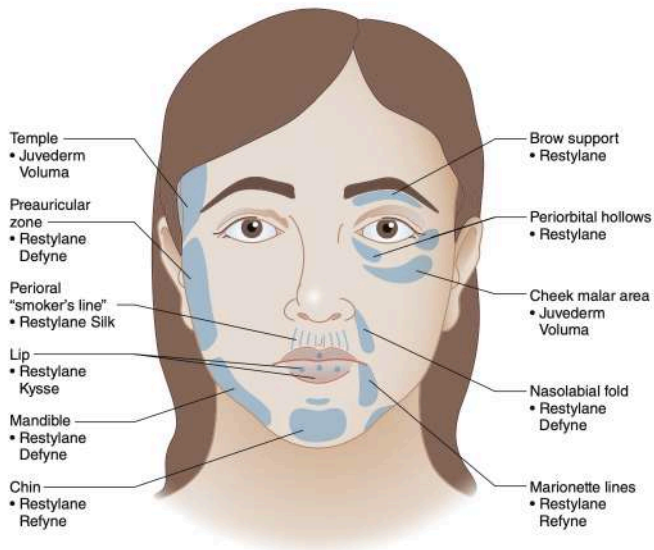


Figure 36 - shows sites and areas which can be corrected using HA. As different manufacturers produce HA with different properties, i.e more cross-linked HA for greater structural support or visa versa for better distribution (larger areas), thus certain products are better suited for certain areas, as shown. Adapted from (2).

Minimum Invasion Liposuction

Injectable lipolytics are used to reduce fat in regions of the chin or neck. Deoxycholic acid, under the trade name, Kybella, is a naturally found molecule that is administered subcutaneously (46). Patients usually need between 2 and 4 injections and are allowed up to 6 injections (46,47). Unfortunately, there are several complications, most frequently: bruising, redness, pain, loss of sensation and induration at site of injection (2). Dysphagia and facial nerve injury are rarer but more troublesome side effects. Kybella is costly especially when several treatments are needed and caution has to be taken when injecting, not to infiltrate it into the skin which causes necrosis and ulceration (46).

Cryolipolysis is another effective method for reducing fatty tissue in the submental region. The mechanism functions by freezing fat cells which leads to their destruction (2). Studies found that there was approximately a 20% decrease in submental adiposity that stabilised after 6 weeks (46). Patient evaluation is important as patients with submental laxity, will have even more laxity after such an intervention (2,47). However, it may take between 1 and 4 months for results to come to fruition and also has side effects of bruising, redness, edema, pain and site induration (46,47). Interestingly, some cases were reported of paradoxical fat hypertrophy and risk factors include: male sex, previous cryolipolysis and Hispanic ethnicity (46).

Skin Remodelling Techniques

Skin resurfacing methods are used to correct wrinkles, dyspigmentation and shallow scarring (2,46). Their primary goal is to rejuvenate the skin from early ageing and photo-damage. They all have relatively reduced side effects and recovery periods compared to other methods.

Microabrasion is a skin resurfacing technique involving the use of abrasive crystals and a vacuum to remove the top layer of the skin (stratum corneum) (46). After which, the skin is remodelled with a new stratum corneum layer. The results tend to be mediocre, but it allows improved absorption of other skincare products through the epidermis (46,47). The procedure is tolerated by all Fitzpatrick skin types and people sensitive to pigmentation and scarring (46). Initially the face needs to be cleaned and then the targeted area of skin undergoes abrasion 3 times in different directions (46). Once complete, sunscreen is applied to the targeted area (46). Patients may need to undergo this treatment several times and may experience irritation, redness, dyspigmentation, burning and petechia (2,46).

Chemical peels exfoliate the skin using acidic topical agents. The skin remodels and rejuvenates during the healing process during which all the exfoliated layers are regenerated (48). They are functionally classified by the depth to which they exfoliate the layers of the skin. Superficial peels such as low concentration trichloroacetic acid and salicylic acid remove the upper layers of the epidermis (2,46). Salicylic acid derivative (e.g. Beta-lipohydroxy acid) has antibacterial, anti-fungal and anti-inflammatory properties (48). These beneficial properties confer prophylaxis against invading infectious agents as the skin is damaged during the procedure losing its protective barrier (48). The outcome can usually be noticed 3-5 days following the treatment (46). Pain and burning may occur after treatment, and long sun exposure should be reduced with larger quantities of sunscreen applied (2).

Medium peels exfoliate the skin at the level of the basal layer of the epidermis and upper dermis. Some specialists favour the use of Obagi's medium range Blue Peel which uses trichloroacetic acid (2). The preparation allows for slower peeling of the skin providing control to the treatment. Redness and dyspigmentation (post inflammatory hyperpigmentation) are adverse effects that may occur more commonly in Fitzpatrick skin types 3 and 4 or higher (46). Antivirals (Acyclovir or Valacyclovir) are recommended to restrict resurgence of herpes (2,46,48). Sunscreen and bleaching products (hydroquinone) should be applied after the treatment in case of pigmentation (46).

Deep peels exfoliate deeper scars and skin deformities, i.e. the deeper dermis, by applying Baker-Gordon phenol, in the surgical theatre (2,46). The recovery period is up to 2 weeks and usually more painful as compared to other more superficial peels (46). Milia formation may occur that may be treated with topical tretinoin (46).

Platelet rich plasma (PRP), derived autologously, is used independently or as an adjuvant to fat grafting, microneedling and other techniques in facial rejuvenation of nasolabial folds and the

midcheek (49). Treatment is done once or 3 times every several weeks depending on differences in protocol (2,49). PRP is administered intradermally to improve volume, structural integrity, colour and wrinkling (46). Mixed results are found in terms of the quality of results and may seem to reduce fat retention when used in combination (46). Bruising, redness and edema may occur as side effects (49).

Microneedling of the epidermis leads to damage of the upper layers of the skin inducing elastin and collagen formation (2). This procedure can be done once a month and after 6 months studies indicate a 400% increase in elastin and collagen deposition (2). Modern microneedling devices may penetrate the skin up to 2 mm deep allowing for correction of deeper scars, not only superficial wrinkles (2). Speckled bleeding results from the needling, and the area may develop bruising, redness and irritations (46). Sunblock should be applied to the treated region (46). This procedure may be used in conjunction with PRP and radiofrequency, for increased efficiency and expanded use to people of darker skin types (2,46). Similarly, microinjections of fillers (e.g. Hyaluronic acid) are used with microneedling to deliver the fillers into the dermis and allow for other topical products to be more rapidly absorbed through the micropores formed in the skin (46). Similar complications occur as with standard microneedling, and although currently considered effective additional studies are required to confirm its practical usage (46).

Radiofrequency treatment generates thermal energy targeting the dermis while bypassing the epidermis (49). The mechanism stimulates angiogenesis with elastin and collagen formation in the dermis by way of single high energy or multiple low energy treatments (46). Different modalities may be used depending on the manufacturer. Mono-polar instruments use a single electrode with grounding to allow for ion flow in one direction; unipolar instruments use a single electrode without grounding allowing multidirectional flow; bipolar instruments use 2 electrodes, one subcutaneously and one percutaneously allowing ion flow between the 2 electrodes (46). Mono-polar modes affect deeper layers of tissue while bipolar modes affect superficial skin between the electrodes allowing more precise superficial effects (46,49). The epidermis is spared and thus complications of scarring and pigmentation are minimised (46). Treatments are indicated in wrinkles, brow lifting, nasolabial folds, jowls, labiomandibular folds, jawline contouring, and neck laxity (46,49). Patients with wound healing pathologies and internal medical devices such as pacemakers are contraindicated to such procedures (2,46). Full effectiveness is visible between 6-12 months and common side effects of bruising, edema and loss of sensation can be seen for the first 2 months (49). Older patients have reduced efficacy after undergoing treatment due to a weaker healing ability (46). As mentioned above, It may be used in conjunction with microneedling to bolster effects, but has an increased recovery time (2,46,49).

Microfocused Ultrasound (MFU) is uses ultrasound waves to induce heat energy within the subcutaneous tissue and reticular dermis (2). It acts at a depth of around 5 mm causing instances of coagulation with the reticular dermis and subcutis (2). This stimulates production of collagen and thus gives structural support to the tissues. MFU-V modes on certain devices allow high

quality visualisation to depths of 8 mm, which allows for personalised treatments and more guided ultrasound into specific regions (2,49). It is suitable for patients with minimal to moderate laxity and those with no wound healing pathologies (46). Fortunately, until now studies have shown that it does not affect the epidermis (46). Some cases were reported of hypo-pigmentation in Fitzpatrick skin types 5 and 6 (46). However, it may cause irritations, edema, bruising, transient nerve palsies and most commonly discomfort, which may be treated with NSAIDs (2,46).

Laser skin resurfacing uses monochromatic laser light to induce injury to the epidermis and dermis in order to flatten wrinkles, better skin colour and minimise dyspigmentation (50). People that have heavy scarring and Fitzpatrick skin type 5 or more, should not be recommended for laser treatment (46,50).

Initially patients may be given tretinoin and hydroquinone for better laser efficacy and prevention of pigmentation, respectively (50). Patients should also be given antiherpetic treatment with acyclovir or valacyclovir (2). Superficial laser treatment is done with topical anaesthetic while deeper laser treatment is performed under sedation. Functionally there are ablative and non-ablative lasers as well as fractionated and non-fractionated laser treatments (46).

Non-ablative lasers include intense pulsed light, neodymium:YAG, etc, and they cause heat injury to the dermis without affecting the epidermis, stimulating fibroblast collagen deposition in the dermis. Thus non-ablative lasers have reduced recovery periods and less complications (46). Ablative lasers are carbon dioxide (CO₂) and Erbium:YAG lasers which evaporate water in targeted tissue causing injury and thus stimulate collagen formation. The lasers have longer recovery periods up to 6 months, and have increased risk to cause hypo-pigmentation (more so in CO₂ lasers) (2,46).

Fractionated lasers apply separated smaller beams of light to the targeted area that may penetrate deeper, so there are small areas of unaffected skin in between each smaller beam (2,46). This improves recovery time as there is less surface area damaged however it may require several treatments every 2 - 4 weeks to achieve results (2,46). Non-fractionated lasers beam light to cover the entire targeted area, thus causing a greater surface of injury, resulting in a longer recovery (46). Non-ablative non-fractionated lasers such as the 1320nm neodymium:YAG laser and Ablative fractionated lasers such as 10 600nm CO₂ laser offer a good risk:reward tradeoff. As weaker lasers have poorer effects while more powerful treatments have long recovery periods (46). It is up to the patient to decide what they would be comfortable with in terms of total recovery length versus outcome quality.

Occlusive dressing should be used in recovery from ablative lasers and sunblock added when the epidermis begins to heal (50).

Redness and hypo-pigmentation or hyperpigmentation may occur depending on the Fitzpatrick skin type being higher or lower, respectively. They are not treated and usually self-limiting but hyperpigmentation may be treated with intense pulsed light (2,50). Possibility of infections should not be forgotten and treated accordingly.

Thread lifting is another minimally invasive technique that is used to lift all parts of the face. It is incorporated into the SMAS and deeper tissue layers of the lower face and midcheek (and other regions) (49). It is used to redirect tissues to a new desired vector, analogous to what a MACS facelift would be. It confers slightly less risk, side-effects and faster recovery relative to the surgical facelifts (51). Threads used in this lifting method may be classified as Resorbable and non-resorbable, method of fixation, barbed/non-barbed (52). Threads may be fixed by being anchored to deep temporal fascia or mastoid fascia (51). Also, they may be free floating as they are fixed into the tissues they give traction to (51). Threads may be unidirectionally or bidirectionally barbed, furthermore they may be barbed cogged threads that are also unidirectional, bidirectional or multidirectional (52). Non-barbed threads are have either Plain or Spiral formation (52). Most commonly used threads are made from resorbable mono-polydioxanone (PDO) (49). PDO threads may also be cogged. Plain PDO threads may be inserted into the dermis and subcutis when they stimulate collagen formation through mechanical infiltration of the surrounding tissue (53). While barbed PDO threads are inserted into deeper tissues such as the subcutis and SMAS and mechanically are pulled to give tension and lift to the tissues (53). Thus plain PDO threads can be used for skin tightening of the face and wrinkle effacement. While barbed and cogged PDO threads are used to lift lower displaced tissue in nasolabial folds, labiomandibular folds, cheeks and eyebrows, for example (52,53). Usually, both superficial and deep threading is done, when patients undergo this treatment (53). Threads are infiltrated at different planes and different directions during the procedure, explained in Figure 37. Patient evaluation for specific threading requirements may be seen in Figure 38 (next page), as suggested by those authors (53).

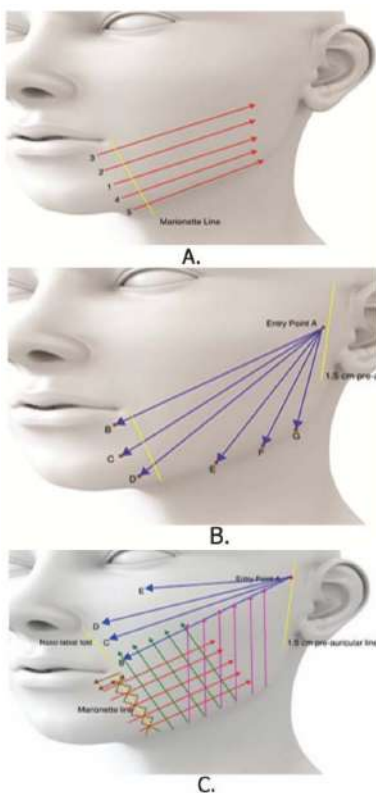


Figure 37 - A, shows placement of plain PDO threads into the dermis and subcutaneous tissue, for collagen stimulation.

B, shows placement of cogged PDO threads from the temporal region into the deeper SMAS tissue towards the labiomandibular folds and jowls, to provide traction and thus lifting.

C, shows placement of cogged PDO threads from the temporal region into the deeper SMAS tissue towards the nasolabial folds and malar tissues (blue), while additional plain PDO threads are placed superficially in the dermis and subcutis (green, pink). This in fact forms a topographical meshwork of threads.

Adapted from (53).

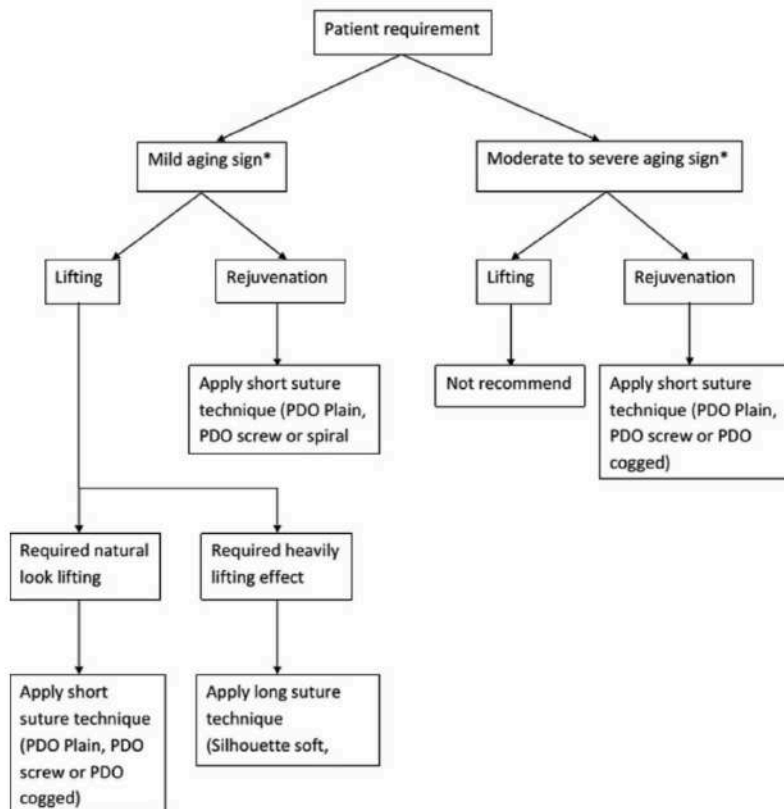


Figure 38 - shows the algorithm for patient evaluation when deciding to undergo a thread lift. When compared to surgical SMAS manipulation techniques, threading is slightly inferior in outcome and durability, therefore depending upon ageing characteristics of the patient, it may be decided whether it is an appropriate option or not.

Adapted from (53).

Several complications may arise using threading: bruising, pain, edema, infection, nerve trauma, asymmetry, thread breakage and palpability, skin wrinkling and granuloma formation (49). Antibiotics, NSAIDs and cold packs should be used in postoperative management (49). In terms of results patients gain an estimated 1 cm lift, that is continues to last after the thread is degraded 6 months post operation (49,51). Patient satisfaction scores vary however, according to some authors the effects may last for more than a year, some saying even up to 2.5 years, after which time their is lack of evidence of longer lasting effects (51). Other claim effects start subsiding from 6 months and are negligible by 2 years (52). Even so, threading has become a trending technique due to it being more simple with better recovery times while offering results lasting longer than injectables, comparable to certain surgical facelifts .

Advancements and Future Directions of Facelifts

Current trends in facial rejuvenation, as mentioned earlier, show a general increase in the amount of facelift procedures conducted. The International Survey on Aesthetic/Cosmetic Procedures has shown downtrends during the period of 2017-2020, however in the period 2017-2021 there has been an overall 2.7% increase in the amount of facelifts conducted (Figure 39) (41).

TOTAL SURGICAL PROCEDURES	2021	2020	2017	Percent Change 2021 vs. 2020	Percent Change 2021 vs. 2017
Eyelid Surgery	1,446,890	1,225,540	1,346,886	18.1%	7.4%
Rhinoplasty	995,149	852,554	877,254	16.7%	13.4%
Lip Enhancement/Perioral Procedure	717,596	N/A	N/A	N/A	N/A
Fat Grafting - Face	589,494	515,819	602,760	14.3%	-2.2%
Facelift	477,705	419,046	465,296	14.0%	2.7%
Neck Lift	290,844	251,308	263,219	15.7%	10.5%
Brow Lift	290,107	288,306	249,343	0.6%	16.3%
Ear Surgery	272,493	254,931	287,070	6.9%	-5.1%
Facial Bone Contouring	131,656	106,173	98,003	24.0%	34.3%

Figure 39 - shows volume of procedures done in recent years and their growth/decline over those periods. Red circle highlights percentage change in Facelift procedures performed from 2017 to 2021. Adapted from (41).

In the USA alone, the American Society for Aesthetic Surgery claims facelift procedures grew by 27.7% in the period of 1997-2014 (54). However, in light of the brand new implementations of non-invasive and minimally invasive techniques explained above, the proportion of demand for these procedures far outweighs that of surgical procedures (Figure 40) (41). The growth of filler and skin tightening is exponential compared to surgical facelift, and the number of procedures are a several multiples to that of invasive procedures (39,41).

Rank	NON-SURGICAL PROCEDURES	Total	Percent of Total Non-Surgical Procedures	Total Procedures in 2020	Total Procedures in 2017	Percent Change 2021 vs. 2020	Percent Change 2021 vs. 2017
1	Botulinum Toxin	7,312,616	41.6%	6,213,859	5,033,693	17.7%	45.3%
2	Hyaluronic Acid	5,279,344	30.0%	4,053,016	3,298,266	30.3%	60.1%
3	Hair Removal	1,836,111	10.4%	1,837,052	997,372	-0.1%	84.1%
4	Non-Surgical Skin Tightening	1,003,731	5.7%	N/A	N/A	N/A	N/A
5	Non-Surgical Fat Reduction	730,980	4.2%	560,464	478,739	30.4%	52.7%
6	Chemical Peel	534,831	3.0%	409,054	357,753	30.7%	49.5%
7	Cellulite Treatment	379,224	2.2%	N/A	N/A	N/A	N/A
8	Calcium Hydroxylapatite	290,095	1.6%	222,785	167,385	30.2%	73.3%

Figure 40 - shows trends and growth/decline of various non-surgical interventions of facelifting and the large volumes of procedures done compared to surgical facelifts, in the table above. Adapted from (41).

This can be attributed to patient associated and clinical factors. Factors including: safety, recovery, simplicity of procedure and durability are most important in governing demand for these various procedures (54). Furthermore, social media influence through Instagram, Google and other networks has risen and the global population is more exposed to cosmetic corrections (55). Impressively, even during the COVID-19 pandemic, there has been an increased interest for facial

rejuvenation procedures (56). According to the Google Trends survey, during the 2020 phase of the pandemic there were large increases in searches for injectable fillers (57). Younger generations, in the 31-50 age group mostly seek conservative non-surgical facial rejuvenation while the age averages for more radical surgical interventions is over 45 years of age (40,41). Factors implicated here may be reduced efficiency of conservative treatments as patients age, making it more sustainable and effective for older people to undergo more radical procedures (42).

Based on these several studies, it may be deduced that the most popular trends for now are conservative treatments such as injectables and resurfacing devices, that then translate into surgical procedures with age. As people have become more aware of self-image and age through social media, they also seek preventative treatments much younger to maintain their youth through these minimal interventions (55).

It seems that these trends are likely to continue where conservative treatment experiences higher growth compared to surgical facelifts. This current small growth in surgical facelift procedures may even diminish and become negative, as more and more potential and existing patients migrate from surgical procedures to non-invasive ones (38).

In the future, as technology develops, the prices of devices for minimally invasive procedures such as radiofrequency and microneedling, will start to decrease and size becomes smaller. This will allow potentially home-use of these more efficient appliances and will possibly boom in popularity (55,58).

In addition, novel era techniques are being researched and developed. Regenerative stem cells, nanotechnology and gene editing are the new up and coming innovations. Briefly, stem cell therapies adapt autologous mesenchymal stem cells and adipocyte derived stem cells, and other stem cell populations, which are prepared and seeded/grafted in required areas (59). These stem cells integrate into the surrounding tissues, and rejuvenate the tissue integrity. This is of particular interest in fat volume restoration and support to fat grafting (59).

Nanotechnology uses specific vehicles to enhance delivery of drugs and gene-editing enzymes. Liposomes and exosomes are some of the common vehicles employed in nanotechnology. Liposomes may be used to deliver retinoids transdermally as they are better absorbed, which ultimately results in skin rejuvenation (59). Fat may be enzymatically degraded to nanofat, which is being incorporated with microneedling, referred to as nanofat microneedling and in topical applications after fractionated laser treatments (59). Nanofat is has greater fat retention for volume restoration, increased collagen formation, increased angiogenesis and thus better facial rejuvenation (59).

With the advent of gene editing technologies such as CRISPR and discovery of new genes involved in skin regeneration, gene therapies for facial rejuvenation are a promising future (59). New gene segments may be integrated into cells using viral and other nano vectors, that contribute to collagen growth and angiogenesis (59).

Similarly, advanced Artificial Intelligence (AI) is being incorporated into cosmetic intervention. AI will be able to relate other interconnected areas such as the microbiota of the skin and gut to facial rejuvenation, and provide possible solutions (59). Together with imaging and diagnostic tools that AI will also allow a patient centred approach by being able to predict outcomes of specific interventions and match them with patient desires (59).

All these new technologies are being researched and will require some time before their full potential is reached and until they may be translated into clinical practice. However, with the power of their potential contributions we will be able to personalise aesthetic surgery (59).

Conclusion

There is progress through the timeline of facial rejuvenating treatments, from its start 100 years ago with subcutaneous facelifts, to more modern SMAS manipulation techniques. The wide range of SMAS facelift surgeries available, deep-plane facelift, composite facelift, MACS facelift, etc, gives a range of choices to both the patient and surgeon. Patients request facial correction consultations and under evaluation of the surgeon a compromise of risk:reward is reached between the 2 parties. The ageing face is ironically an old enemy to the cosmetic surgeon. Various presentations of ageing from jowling, nasolabial folds, marionette lines, eye bags, etc, pose considerable difficulty to treatment. The individual aspect of ageing and extrinsic factors at play, mean that people age differently and at different velocities. This makes facial rejuvenation a balance between art and science.

In contemporary days the dominating trend of non-surgical techniques such as Injectables (Botox and Hyaluronic acid), resurfacing devices and thread lifting are taking priority. Patients are more interested in taking least risk and recovery time for optimal and lasting results. Making non-surgical techniques a more attractive option generally and especially among the younger age groups. Many authors claim that thread lifting is the future of the facelift as it is minimally invasive, has results comparable to surgical facelifts and tends to last, although subjectively, for several months to a few years. This is a significantly shorter lasting outcome than surgical facelifting, however, does not have the risk of surgical manipulation of tissues. Thus the surgical facelift is undertaken for the more aged individual, where non-surgical techniques tend to fail to bring the desired outcome. The risk of complications is diverse across different modalities of facelifting. But are all usually self-limited, short lasting and reversible, including serious nerve palsies.

Though today several procedures are merged to optimise and achieve the desired facial appearance. Facelift surgeries are contoured with fat grafts and fillers to augment the results, and this makes the effects even more durable. Microneedling is similarly incorporating radiofrequency and filler treatments, providing greater efficiency. This synergy between procedures provides flexibility to the patient and surgeon, allowing for a smoother transition to a youthful appearance. What the definite future holds is unknown, however, the facial rejuvenation pipeline has new potential technologies in store. The long terms goal stands: to achieve maximum youthful regeneration with minimal intervention. Stem cell technologies provide personalised youthful tissues for volume restoration and reshaping. Nanotechnologies provide the vehicle to precisely deliver molecular elements such as growth factors and editing tools, that drive rejuvenation. Gene-editing enables modification and optimisation of inherent shortcomings that influence ageing and youthful restoration. As devices, AI and these aforementioned technologies develop and slowly transition into the facial surgery clinic, we will be closer to our goal of ultimately achieving personalised and precision based facial rejuvenation.

References

1. Niamtu J III. What is a facelift? History and semantics. In: *The Art and Science of Facelift Surgery*. Elsevier; 2019. p. 1–5.
2. Farhadieh, Bulstrode, Mehrara, Cugno S. *Plastic surgery - principles and practice*. Farhadieh R, Bulstrode N, Mehrara BJ, Cugno S, editors. Philadelphia, PA: Elsevier - Health Sciences Division; 2021.
3. Farhadieh RD, Bulstrode NW, Cugno S, editors. *Plastic and reconstructive surgery: Approaches and techniques*. Chichester, UK: John Wiley & Sons, Ltd; 2015.
4. Niamtu J III. Facelift Surgery (Cervicofacial Rhytidectomy). In: *The Art and Science of Facelift Surgery*. Elsevier; 2019. p. 62–143.
5. Warren RJ, Aston SJ, Mendelson BC. Face lift. *Plast Reconstr Surg* [Internet]. 2011;128(6):747e–64e. Available from: <http://dx.doi.org/10.1097/PRS.0b013e318230c939>
6. Chung. *Grabb and Smith's Plastic Surgery*. 8th ed. Chung KC, editor. Philadelphia, PA: Lippincott Williams and Wilkins; 2019.
7. Park DM. Total facelift: forehead lift, midface lift, and neck lift. *Arch Plast Surg* [Internet]. 2015;42(2):111–25. Available from: <http://dx.doi.org/10.5999/aps.2015.42.2.111>
8. Pourdanesh F, Esmaeelinejad M, Jafari SM, Nematollahi Z. Facelift: Current Concepts, Techniques, and Principles. In: *A Textbook of Advanced Oral and Maxillofacial Surgery Volume 3*. InTech; 2016.
9. Niamtu J III. The Aging Face. In: *The Art and Science of Facelift Surgery*. Elsevier; 2019. p. 6–20.
10. Alghoul M, Codner MA. Retaining ligaments of the face: review of anatomy and clinical applications. *Aesthet Surg J* [Internet]. 2013;33(6):769–82. Available from: <http://dx.doi.org/10.1177/1090820X13495405>
11. Hashem AM, Couto RA, Duraes EFR, Çakmakoğlu Ç, Swanson M, Surek C, et al. Facelift part I: History, anatomy, and clinical assessment. *Aesthet Surg J* [Internet]. 2020;40(1):1–18. Available from: <http://dx.doi.org/10.1093/asj/sjy326>
12. Lee J-H, Hong G. Definitions of groove and hollowness of the infraorbital region and clinical treatment using soft-tissue filler. *Arch Plast Surg* [Internet]. 2018;45(3):214–21. Available from: <http://dx.doi.org/10.5999/aps.2017.01193>
13. Peng H-LP, Peng J-H. Treating the tear trough-eye bag complex: Treatment targets, treatment selection, and injection algorithms with case studies. *J Cosmet Dermatol* [Internet]. 2020;19(9):2237–45. Available from: <http://dx.doi.org/10.1111/jocd.13622>

14. Niamtu J III. Evaluating the cosmetic facial surgery patient. In: *The Art and Science of Facelift Surgery*. Elsevier; 2019. p. 21–44.
15. Shamouelian D, Sand JP. Rhytidectomy Essentials. In: *Facial Plastic and Reconstructive Surgery*. Cham: Springer International Publishing; 2021. p. 395–415.
16. Stuzin JM, Rohrich RJ, Dayan E. The facial fat compartments revisited: Clinical relevance to subcutaneous dissection and facial deflation in face lifting. *Plast Reconstr Surg* [Internet]. 2019;144(5):1070–8. Available from: <http://dx.doi.org/10.1097/PRS.00000000000006181>
17. Coleman SR, Mazzola RF, Pu LLQ, editors. Chapter 49 ANATOMY AND HISTOLOGY OF THE FAT COMPARTMENTS OF THE FACE. In: *Fat Injection*. Stuttgart: Georg Thieme Verlag; 2018.
18. Minelli L, Yang H-M, van der Lei B, Mendelson B. The surgical anatomy of the jowl and the mandibular ligament reassessed. *Aesthetic Plast Surg* [Internet]. 2023;47(1):170–80. Available from: <http://dx.doi.org/10.1007/s00266-022-02996-3>
19. Beer GM, Spicher I, Seifert B, Emanuel B, Kompatscher P, Meyer VE. Oral premedication for operations on the face under local anesthesia: a placebo-controlled double-blind trial. *Plast Reconstr Surg*. 2001;108(3):637–643.
20. Kridel RWH, Liu ES. Techniques for creating inconspicuous face-lift scars: avoiding visible incisions and loss of temporal hair: Avoiding visible incisions and loss of temporal hair. *Arch Facial Plast Surg* [Internet]. 2003;5(4):325–33. Available from: <http://dx.doi.org/10.1001/archfaci.5.4.325>
21. Gradinger GP. The pretragal incision in rhytidectomy. *Aesthet Surg J* [Internet]. 2001;21(6):564–8. Available from: <http://dx.doi.org/10.1067/maj.2001.120367>
22. Joshi K, Hohman MH, Seiger E. SMAS Plication Facelift. [Updated 2023 Mar 1]. In: *StatPearls* [Internet]. Treasure Island (FL): StatPearls Publishing; 2023 Jan-. Available from: <https://www.ncbi.nlm.nih.gov/books/NBK531458/#>
23. Themes UFO. RHYTIDECTOMY [Internet]. *Pocket Dentistry*. 2016 [cited 2023 May 8]. Available from: <https://pocketdentistry.com/rhytidectomy/>
24. Raggio BS, Patel BC. Deep Plane Facelift. [Updated 2023 Mar 13]. In: *StatPearls* [Internet]. Treasure Island (FL): StatPearls Publishing; 2023 Jan-. Available from: <https://www.ncbi.nlm.nih.gov/books/NBK545277/>
25. Jacono A, Bryant LM. Extended deep plane facelift: Incorporating facial retaining ligament release and composite flap shifts to maximize midface, jawline and neck rejuvenation. *Clin Plast Surg* [Internet]. 2018;45(4):527–54. Available from: <http://dx.doi.org/10.1016/j.cps.2018.06.007>
26. del Toro E, Aldrich J. Extended SMAS Facelift. [Updated 2022 Aug 29]. In: *StatPearls* [Internet]. Treasure Island (FL): StatPearls Publishing; 2023 Jan-. Available from: <https://www.ncbi.nlm.nih.gov/books/NBK562296/>

27. Hamra ST, Choucair RJ. The Composite Facelift. *Semin Plast Surg* [Internet]. 2002;16(4):331–46. Available from: <http://dx.doi.org/10.1055/s-2002-37452>
28. Hashem AM, Couto RA, Surek C, Swanson M, Zins JE. Facelift part II: Surgical techniques and complications. *Aesthet Surg J* [Internet]. 2021;41(10):NP1276–94. Available from: <http://dx.doi.org/10.1093/asj/sjab081>
29. Stutman RL, Codner MA. Tear trough deformity: review of anatomy and treatment options. *Aesthet Surg J* [Internet]. 2012;32(4):426–40. Available from: <http://dx.doi.org/10.1177/1090820X12442372>
30. Zoumalan CI, Lattman J, Zoumalan RA, Rosenberg DB. Orbicularis suspension flap and its effect on lower eyelid position: A digital image analysis. *Arch Facial Plast Surg* [Internet]. 2010;12(1):24–9. Available from: <http://dx.doi.org/10.1001/archfaci.2009.105>
31. Mani M. Total composite flap facelift and the deep-plane transition zone: A critical consideration in SMAS-release midface lifting. *Aesthet Surg J* [Internet]. 2016;36(5):533–45. Available from: <http://dx.doi.org/10.1093/asj/sjv250>
32. Niamtu J III. Complications of face and neck lift: Recognition, treatment and prevention. In: *The Art and Science of Facelift Surgery*. Elsevier; 2019. p. 183–241.
33. Mottura AA. Face lift postoperative recovery. *Aesthetic Plast Surg* [Internet]. 2002;26(3):172–80. Available from: <http://dx.doi.org/10.1007/s00266-001-0029-3>
34. Botti C, Botti G, Pascali M. Facial aging surgery: Healing time, duration over the years, and the right time to perform a facelift. *Aesthet Surg J* [Internet]. 2021;41(11):NP1408–20. Available from: <http://dx.doi.org/10.1093/asj/sjab304>
35. Bertossi D, Botti G, Gualdi A, Fundarò P, Nocini R, Pirayesh A, et al. Effectiveness, longevity, and complications of facelift by barbed suture insertion. *Aesthet Surg J* [Internet]. 2019;39(3):241–7. Available from: <http://dx.doi.org/10.1093/asj/sjy042>
36. Wu WTL. Commentary on: Effectiveness, longevity, and complications of facelift by barbed suture insertion. *Aesthet Surg J* [Internet]. 2019;39(3):248–53. Available from: <http://dx.doi.org/10.1093/asj/sjy340>
37. Beale EW, Rasko Y, Rohrich RJ. A 20-year experience with secondary rhytidectomy: A review of technique, longevity, and outcomes. *Plast Reconstr Surg* [Internet]. 2013;131(3):625–34. Available from: <http://dx.doi.org/10.1097/prs.0b013e31827c70f1>
38. Swanson E. Objective assessment of change in apparent age after facial rejuvenation surgery. *J Plast Reconstr Aesthet Surg* [Internet]. 2011;64(9):1124–31. Available from: <http://dx.doi.org/10.1016/j.bjps.2011.04.004>
39. Aesthetic plastic surgery national databank statistics 2020-2021. *Aesthet Surg J* [Internet]. 2022;42(Suppl 1):1–18. Available from: <http://dx.doi.org/10.1093/asj/sjac116>

40. Inaugural ASPS insights and trends report: Cosmetic surgery 2022 [Internet]. [Plasticsurgery.org](https://www.plasticsurgery.org). [cited 2023 May 8]. Available from: <https://www.plasticsurgery.org/documents/News/Trends/2022/trends-report-cosmetic-surgery-2022.pdf>
41. ISAPS INTERNATIONAL SURVEY ON [Internet]. [Isaps.org](https://www.isaps.org). [cited 2023 May 8]. Available from: https://www.isaps.org/media/vdpdanke/isaps-global-survey_2021.pdf
42. Jacono AA, Malone MH, Lavin TJ. Nonsurgical facial rejuvenation procedures in patients under 50 prior to undergoing facelift: Habits, costs, and results. *Aesthet Surg J* [Internet]. 2016;sjw217. Available from: <http://dx.doi.org/10.1093/asj/sjw217>
43. Larrabee Y, Jowett N. Fillers, botulinum toxin, mid-facial implants, and tissue expansion. In: *Facial Plastic and Reconstructive Surgery*. Cham: Springer International Publishing; 2021. p. 299–320.
44. Alam M, Tung R. Injection technique in neurotoxins and fillers: Planning and basic technique. *J Am Acad Dermatol* [Internet]. 2018;79(3):407–19. Available from: <http://dx.doi.org/10.1016/j.jaad.2018.01.034>
45. Surek CC. Facial anatomy for filler injection: The superficial musculoaponeurotic system (SMAS) is not just for facelifting. *Clin Plast Surg* [Internet]. 2019;46(4):603–12. Available from: <http://dx.doi.org/10.1016/j.cps.2019.06.007>
46. Farber SE, Epps MT, Brown E, Krochonis J, McConville R, Codner MA. A review of nonsurgical facial rejuvenation. *Plast Aesthet Res* [Internet]. 2020;2020. Available from: <http://dx.doi.org/10.20517/2347-9264.2020.152>
47. Attenello NH, Maas CS. Injectable fillers: review of material and properties. *Facial Plast Surg* [Internet]. 2015;31(1):29–34. Available from: <http://dx.doi.org/10.1055/s-0035-1544924>
48. Lieberman DM, Roy S. Chemical Peels. In: *Facial Plastic and Reconstructive Surgery*. Cham: Springer International Publishing; 2021. p. 285–97.
49. Panda AK, Chowdhary A. Non-surgical modalities of facial rejuvenation and aesthetics. In: *Oral and Maxillofacial Surgery for the Clinician*. Singapore: Springer Singapore; 2021. p. 661–89.
50. Goodrich J. Lasers in Aesthetic Surgery. In: *Facial Plastic and Reconstructive Surgery*. Cham: Springer International Publishing; 2021. p. 351–9.
51. Tavares J de P, Oliveira CACP, Torres RP, Bahmad F Jr. Facial thread lifting with suture suspension. *Braz J Otorhinolaryngol* [Internet]. 2017;83(6):712–9. Available from: <http://dx.doi.org/10.1016/j.bjorl.2017.03.015>
52. Myung Y, Jung C. Mini-midface lift using polydioxanone cog threads. *Plast Reconstr Surg Glob Open* [Internet]. 2020;8(6):e2920. Available from: <http://dx.doi.org/10.1097/GOX.0000000000002920>

53. Yongtrakul P, Sirithanabadeekul P, Siriphan P. Thread lift: Classification, technique, and how to approach to the patient. 2016; Available from: <http://dx.doi.org/10.5281/zenodo.1127579>
54. Chuang J, Barnes C, Wong B.J.F. Overview of facial plastic surgery and current developments. *Surg J* [Internet]. 2016;2(1):e17–28. Available from: <http://dx.doi.org/10.1055/s-0036-1572360>
55. Thawanyarat K, Hinson C, Gomez DA, Rowley M, Navarro Y, Johnson C, et al. #PRS: A study of plastic surgery trends with the rise of Instagram. *Aesthet Surg J Open Forum* [Internet]. 2023;5:ojad004. Available from: <http://dx.doi.org/10.1093/asjof/ojad004>
56. Sharma GK, Asaria J. The impact of COVID-19 on patient interest in facial plastic surgery. *Plast Reconstr Surg Glob Open* [Internet]. 2021;9(10):e3890. Available from: <http://dx.doi.org/10.1097/GOX.0000000000003890>
57. Dhanda AK, Leverant E, Leshchuk K, Paskhover B. A Google Trends analysis of facial plastic surgery interest during the COVID-19 pandemic. *Aesthetic Plast Surg* [Internet]. 2020;44(4):1378–80. Available from: <http://dx.doi.org/10.1007/s00266-020-01903-y>
58. Rohrich RJ, Cason RW, Avashia YJ, Savetsky IL. Evidence-based innovations driving the future of plastic surgery. *Plast Reconstr Surg* [Internet]. 2021;147(1):258–61. Available from: <http://dx.doi.org/10.1097/PRS.0000000000007502>
59. Crowley JS, Liu A, Dobke M. Regenerative and stem cell-based techniques for facial rejuvenation. *Exp Biol Med (Maywood)* [Internet]. 2021;246(16):1829–37. Available from: <http://dx.doi.org/10.1177/15353702211020701>

Author's Biography

Matej Miljak was born on the 29 October 1994. He completed his primary and secondary education in Johannesburg, South Africa, achieving first place in combined Natural Sciences in the country. After which, he graduated with honours from the University of Edinburgh, Scotland. His degree in Edinburgh was BSc (Hons) Medical Science. During this period, he participated in summer internships, almost every year, at the Department of Head and Neck Surgery, KBC Sestre Milosrdnice, Zagreb, Croatia. He is an aspiring plastic surgeon, and is proud to have attended the University of Zagreb, Medical School, with the world-class standard and knowledge they provide.