

Heterotopic ossifications in patients post SARS-CoV infection: case report and literature review

Papič, Peter

Master's thesis / Diplomski rad

2023

Degree Grantor / Ustanova koja je dodijelila akademski / stručni stupanj: **University of Zagreb, School of Medicine / Sveučilište u Zagrebu, Medicinski fakultet**

Permanent link / Trajna poveznica: <https://um.nsk.hr/um:nbn:hr:105:237809>

Rights / Prava: [In copyright](#) / [Zaštićeno autorskim pravom.](#)

Download date / Datum preuzimanja: **2024-12-01**



Repository / Repozitorij:

[Dr Med - University of Zagreb School of Medicine Digital Repository](#)



**UNIVERSITY OF ZAGREB
SCHOOL OF MEDICINE**

Peter Papič

**Heterotopic ossifications in patients post
SARS-CoV-2 infections: Case report and
literature review**

GRADUATE THESIS



Zagreb, 2023

This graduate thesis was made at the Department of Orthopaedic Surgery, School of Medicine, University of Zagreb, under the supervision of prof. Tomislav Smoljanović, MD, PhD and was submitted for evaluation in the academic year 2022/2023.

LIST OF ABBREVIATIONS:

ACE – angiotensin-converting enzyme

ALP – alkaline phosphatase

BMP – bone morphogenic protein

CK – creatine kinase

COVID-19 – coronavirus disease 2019

CRP – c-reactive protein

CT – computed tomography

ESR – erythrocyte sedimentation rate

FOP – fibrodysplasia ossificans progressiva

GNAS – guanine nucleotide-binding protein, alpha-stimulating activity

HO – heterotopic ossification

ICU – intensive care unit

IL – interleukin

IQR – interquartile range

MCP – monocyte chemoattractant protein

MERS – middle east respiratory syndrome

MRI – magnetic resonance imaging

mTOR – mammalian target of rapamycin

NSAID – non-steroidal anti-inflammatory drugs

ROM – range of motion

SARS-CoV-2 – severe acute respiratory syndrome coronavirus 2

SCI – spinal cord injury

TBI – traumatic brain injury

TMPRSS2 – transmembrane protease serine 2

TNF – tumour necrosis factor

TABLE OF CONTENTS

1. SUMMARY.....
2. SAŽETAK
3. INTRODUCTION.....	1
4. HETEROTOPIC OSSIFICATION	2
4.1. ETIOLOGY.....	2
4.1.1. GENETIC FORM.....	4
4.1.2. ACQUIRED FORM.....	4
4.2. CLINICAL PICTURE.....	7
4.3. DIAGNOSIS AND DIFFERENTIAL DIAGNOSIS.....	8
4.4. TREATMENT AND PREVENTION	10
5. HO AND SARS-COV-2 INFECTION.....	12
5.1. REVIEW OF THE LITERATURE	13
6. CASE REPORT	19
7. DISCUSSION.....	23
8. CONCLUSION	27
9. ACKNOWLEDGEMENTS.....	28
10. LITERATURE:	29
11. BIOGRAPHY.....	36

1. SUMMARY

Heterotopic ossification (HO) is defined as the ectopic formation of lamellar bone in extraskeletal tissues. It can cause pain, redness, warmth, swelling, and limited range of motion at the affected site, significantly reducing patients' quality of life. HO most commonly occurs after mechanical trauma, burns, traumatic brain injury, and various orthopedic surgical procedures. Why HO occurs hasn't been proven, but it has been hypothesized to be connected with an increase in inflammatory markers causing the differentiation of mesenchymal stem cells into osteoprogenitor cells. Since the beginning of the global coronavirus disease 2019 (COVID-19) pandemic officially declared by the World Health Organization on May 11th, 2020, numerous authors have reported a possible correlation between severe acute respiratory syndrome coronavirus 2 (SARS-CoV-2) infection and increased risk of formation of HO. A report of a patient who developed HO in hip and knee regions following severe SARS-CoV-2 infection is provided together with a literature review related to the subject. This literature review included 42 patients who experienced HO after being admitted to the intensive care unit and receiving mechanical ventilation due to SARS-CoV-2 infection. Out of the 32 patients whose HO locations were identified, the hip joint was affected in 22 patients (68.8%), making it the most prevalent area affected. Surgical excision of the HO was reported for 13 patients. For the remaining patients, conservative, non-surgical treatments were utilized, which resulted in significant relief. A common denominator between these cases of ectopic bone growth after COVID-19 infection was analysed. It is considered that the occurrence of HO following SARS-CoV-2 infection is due to the increase in inflammatory markers connected to prolonged hospitalization in the intensive care unit, lack of mobility and mechanical ventilation, and associated metabolic disturbances, but confirmation requires additional research.

Keywords: heterotopic ossification, SARS-CoV-2, COVID-19 infection, mechanical ventilation, intensive care unit, inflammation

2. SAŽETAK

Heterotopična ossifikacija (HO) definirana je kao ektopična formacija laminarne kosti u ekstra-skeletnim tkivima. To može uzrokovati bol, crvenilo, toplinu, oticanje i ograničen raspon pokreta u zahvaćenom području, značajno smanjujući kvalitetu života bolesnika. Najčešće se HO javlja nakon mehaničke traume, opekline, traumatske ozljede mozga i raznih ortopedskih kirurških postupaka. Zašto se HO javlja nije dokazano, ali se hipotetiziralo da je povezano s povećanjem upalnih markera koji uzrokuju diferencijaciju mezenhimalnih matičnih stanica u osteoprogenitorske stanice. Od službenog proglašenja globalne koronavirus bolesti 2019 (eng. *coronavirus disease 2019* (COVID-19)) pandemije od strane Svjetske zdravstvene organizacije 11. svibnja 2020. godine, nekoliko autora izvijestilo je o mogućoj povezanosti između teškog akutnog respiratornog sindroma uzrokovanog koronavirusom 2 (eng. *severe acute respiratory syndrome coronavirus 2* (SARS-CoV-2)) infekcije i povećanog rizika formacije HO. Prikazan je slučaj bolesnika u kojega su se razvile HO u području kukova i koljena nakon preboljenja teškog oblika SARS-CoV-2 infekcije zajedno s pregledom literature iz te tematike. Ovaj pregled literature obuhvatio je 42 pacijenta koji su razvili HO nakon što su bili primljeni na intenzivnu njegu i primali mehaničku ventilaciju zbog infekcije SARS-CoV-2. Zglob kuka bio je najčešće pogođeno područje od strane HO, zahvaćajući 22 od ukupno 32 (68,8%) pacijenata čije su lokacije HO-a bile prikazane. Kirurško uklanjanje HO učinjeno je kod 13 pacijenta. Za preostale pacijente primjenjivane su konzervativne, nekirurške terapije koje su rezultirale značajnim olakšanjem. Analiziran je zajednički uzročnik nastanka HO nakon COVID-19 infekcije. Smatra se da je pojavnost HO nakon SARS-COV-2 infekcije povezana s povećanjem upalnih čimbenika tijekom produljene hospitalizacije u jedinici intenzivne njege, nedostane pokretljivosti i mehaničke ventilacije s povezanim metaboličkim poremećajima, ali potvrda tih sumnji zahtijeva dodatna istraživanja.

Ključne riječi: heterotopične ossifikacije, SARS-CoV-2, COVID-19 infekcija, mehanička ventilacija, jedinica intenzivne njege, upala

3. INTRODUCTION

Ever since the onset of the coronavirus disease 2019 (COVID-19) pandemic, it has been established that infection with the virus affects various organ systems. The musculoskeletal system, in particular, has been found to be susceptible to this virus, which possesses a positive-sense, single-stranded RNA structure. As a result, conditions such as sarcopenia, osteoporosis, and osteoarthritis have been identified as potential consequences (1). Additionally, there is a hypothesis suggesting a connection between COVID-19 infection and a clinical condition known as heterotopic ossification (HO). Several authors have presented cases where hospitalized patients infected with this virus have exhibited signs of HO. HO can have a significant impact on an individual's quality of life. Pain, discomfort, reduced range of motion (ROM), functional impairment as well as emotional and psychological effects have all been observed in patients suffering from this disease. Despite the declaration on May 5th, 2023, stating that COVID-19 is no longer considered a public health emergency of international concern, it remains highly prevalent. This has led to the decision to perform the latest update on cases of HO following COVID-19 infection. This will hopefully lead to a better insight into the relationship between HO and severe acute respiratory syndrome coronavirus 2 (SARS-CoV-2) infection. It will also contribute to the growing body of knowledge regarding the association between severe SARS-CoV-2 infection and HO highlighting the importance of early detection, monitoring, and targeted interventions for this potential complication.

4. HETEROTOPIC OSSIFICATION

HO is described as the formation of mature lamellar bone in extra-skeletal soft tissues (2). The phenomenon was first described around 1000 years ago in the context of healing fractures, complications of amputations, and as a consequence of injuries from military combat. Specifically, it was described in the literature about American Civil War as well as World War I.

HO has become a significant medical entity in the field of orthopedic surgery due to its detrimental effects on quality of life. The formation of heterotopic bone exhibits significant similarities in terms of molecular and histological characteristics when compared to the natural process of bone development (3). To form new bone (physiologically or pathologically) 3 requirements have to be met. The first requirement is the existence of inductive signalling pathways consisting of chemical mediators such as chemokines and cytokines. These include bone-morphogenic protein (BMP), platelet-derived growth factors, fibroblast growth factors, prostaglandins, and interleukins (IL), all of which induce osteogenesis. The second requirement is the presence of osteoprogenitor cells with the capacity of transforming into osteoblasts, such as the cells present in muscle or fascia, most likely primitive mesenchymal cells (4). Finally, an environment that is favorable for osteogenesis and provides a proper scaffold for the deposition of new bone must be present (2).

By now 2 forms of HO have been described: genetic and non-genetic (also described as acquired).

4.1. ETIOLOGY

The etiology and pathophysiology of HO still remain largely unknown (5). However, to gain better insight into the development of HO several animal models have been developed such as genetic models, traumatic models, BMP-induced models, and neurogenic and SCI models.

Genetic models typically reproduce conditions similar to fibrodysplasia ossificans progressiva (FOP). On the other hand, traumatic models, BMP-induced models, and neurogenic and SCI models study the mechanisms of acquired HO. These models gave us a general idea of potential cell precursors responsible for the generation of ectopic bone. Collective data suggests, that the main source of HO is from local stromal/fibroblastic cells of mesenchymal origin within the connective tissue of skeletal muscle, fascia, and subcutaneous tissue. Other cell types reported to contribute to HO genesis also include endoneurial cells (6), pericytes and other perivascular cells (7), and endothelial cells, which had undergone endothelial-to-mesenchymal transition (8, 9). It has been also proposed, that nonhematopoietic circulating mesenchymal cells participate in HO formation (5). Conversely, research conducted using genetically modified animals that have been engineered to express a specific reporter gene has indicated certain cell types that are unlikely to serve as direct cellular precursors for the formation of abnormal bone and cartilage in HO. These include cells such as degenerating skeletal muscle fibres, vascular smooth muscle, and chronic inflammatory cells. However, considering the various models of HO in mice, it is important to understand, that cell types which are the main drivers of this mechanism, are still not clearly defined.

In a simplified understanding, inflammation plays a key role as a fundamental factor in the emergence of HO (5). It is a shared characteristic among many conditions that increase the likelihood of HO formation, whether it is acquired such as after surgery, trauma, burn, or due to a genetic cause like FOP. Components of both innate and adaptive immunity have been proposed as mediators of inflammation and the formation of HO. Specifically, macrophages and mast cells of the innate immune system have been suggested through mouse models as playing a big role. The role of adaptive immunity is somewhat less understood, but lymphocytic inflammation has been identified as a frequent histological characteristic of HO, specifically the presence of perivascular lymphocytic inflammation, which consistently occurs in peri-articular, non-genetic instances of HO (10).

Several signalling pathways have been by now described to contribute to HO formation. BMP signalling, mammalian target of rapamycin (mTOR), hypoxia-inducible factors, retinoic acid receptor signalling as well as guanine nucleotide-binding protein, alpha-stimulating activity (GNAS) pathway have all been tested and somewhat proven

to play a significant part in HO development. However, the exact pathway responsible for HO is still not known.

4.1.1. GENETIC FORM

The genetic forms are very rare but debilitating, with HO as their main clinical feature, and include conditions such as FOP, progressive osseous heteroplasia, and other GNAS1-related conditions. The most common of these is FOP, an autosomal dominant inherited disorder with an approximated prevalence of 1-1.5 in 2 million caused by a gain of function mutation of the ACVR1/Alk2 gene (11). This leads to constitutive activation and hypersensitivity of type I receptors for BMP, promoting ectopic bone formation. It presents with a distinct congenital abnormality of the big toes (hallux valgus), which may be the first sign of disease. However other congenital abnormalities like malformed thumbs, fused cervical vertebrae, or reduced digit count, along with clinical signs such as tibial osteochondromas, can also occur with varying frequency and severity. HOs usually start in childhood and gradually worsen over time with alternating periods of flare-ups and quiescence, resulting in basically the formation of a »second skeleton«, significantly reducing patients' quality of life (3). Extensive knowledge of genetic causes of HOs is of utter importance, since it may lead us to an understanding of acquired causes of HOs and possible treatment in the patients.

4.1.2. ACQUIRED FORM

The acquired form of HO is much more common. The most common clinical risk factors leading to it are SCI and TBI, thermal injury (i.e. burns), physical trauma (i.e. fractures), and various surgical procedures (most common after hip arthroplasty). The prevalence varies depending on the type of injury, ranging from 0.2% to 4% after burn injury, 10 to 53% after central neurologic injury to as high as 90% after certain hip arthroplasty or acetabular fracture (12).

SCI and TBI fall into the group of neurogenic HO, whose pathophysiology is still mostly unknown. Factors that increase the likelihood of HO in patients with SCI include the degree of injury severity and the location of the injury. In particular, injuries to the cervical and thoracic spine were associated with more severe cases of HO. Most of the risk factors for SCI are shared with TBI. However, in contrast to SCI where most of the HOs develop inferior to the site of injury with peripheral joints usually being spared, following TBI, they may develop anywhere throughout the body.

In patients with thermal injuries, the extent of the burn injury is the primary risk factor associated with the development of HO alongside male sex and full-thickness burns near or at a joint. Specifically, burns that affect more than 20% of the body are strongly associated with an increased likelihood of HO.

The rates at which HOs develop following hip arthroplasty vary, with extensive peri-articular HOs occurring in approximately 2% to 7% (5). If we consider all levels of ossification severity, the occurrence of HO after arthroplasty has been reported to reach up to around 28% (13). In a study by Spinarelli et al. (13) 181 hips were reviewed post-arthroplasty using a standard lateral approach for the implant of a non-cemented femoral component and a non-cemented acetabular component. Out of those, HO developed in 52 hips (28.7%). Heterotopic bone in the hips was classified according to Brooker classification as class I in 32 (17.7%) cases, class II in 14 (7.73%) cases, class III in 6 (3.3%) cases, and there were no cases classified as class IV. The average preoperative Harris hip score for the entire group was 48 points, while at the latest follow-up, the average postoperative score in the group with heterotopic ossification (HO) was 89 points (with a maximum possible score of 100 points). In comparison, the mean Harris hip score for the group of patients who didn't develop HO was 91 points.

For hip arthroscopy, in a study by Bedi et al. (14) published in 2012 from 616 procedures performed development of HO was observed to occur in 4.7% of cases, 1.1% of which needed a further procedure for excision of HOs at a mean 11.6 months after the index case. Following the excision procedure, no recurrences were observed. However, the type of procedure of HO excision was not specified (open versus arthroscopic technique).

It is noteworthy that various surgical factors, such as extended ischemia time, and the use of cemented implants, may increase the risk of HO. The type of approach to total

hip arthroplasty as well has been proven to increase/decrease the incidence of HO with the direct lateral approach being associated with increased occurrence compared to the posterior approach (15).

The most extensive research on post-fracture development of HO has been done in the setting of acetabular and elbow fractures. The occurrence of up to 58% of HO has been observed in patients after operative fixation of an acetabular fracture (16, 17). In a study by Daum et al. (16) 18 out of 38 fractures (43%) developed HO of any class (Brooker classification) regardless of treatment. In 26 cases (out of 38) no appropriate prophylaxis was received for HO. This resulted in 16 (out of a total of 18) cases of HO. Out of those, 6 were either Brooker class 3 or 4. None of the patients receiving prophylaxis either with a full course of indomethacin or prophylactic radiation prior to 48 hours postoperatively, developed HO. Out of 2 fractures that received prophylactic radiation beyond 48 hours, both also developed HO Brooker class 2. The relationship between predisposing factors and the development of HO was examined in the 26 patients not receiving prophylaxis. It was found that the time interval from injury to surgery significantly impacted the development of HO. Furthermore, a delay in performing the surgery was associated with a higher severity of HO occurrence. The mean time between the injury and the surgery for HO classes III and IV according to Brooker classification was 10.5 days compared to the mean time of 3.9 days, 5.2 days, and 4.5 days for classes 0, I, and II, respectively.

In another study by Kaempffe et al. (17) 29 of 50 patients (58%) developed HO after open reduction and internal fixation of the acetabular fracture, none of which received HO prophylaxis. Out of those, 5 patients required a secondary procedure for resection of the HO followed by postoperative irradiation with 200 rads for 5 days, which resulted in no recurrences. Another 1 patient in addition to HO excision also required total hip arthroplasty and postoperative irradiation with 200 rads for 5 days for HO following open reduction internal fixation of a posterior hip dislocation with an associated posterior wall fracture of the acetabulum. This was performed 18 months after the original injury. No recurrence of HO was noted on radiographs taken 3 years later.

The surgical approach has been suggested to play a role in the development of HO in the surgical treatment of femoral fractures (18). In a systematic review including 176 patients a lower incidence of HO was observed following trochanteric flip compared to anterior and posterior approach (33.3% versus 42.1% and 36.9%, respectively). HO

was also observed to occur following an elbow fracture (19, 20) . Among 219 patients who had either a distal humeral fracture (89 patients) or a proximal ulnar or radial fracture (130 patients), approximately 39% experienced HO, with all cases detected within 3 months after fracture fixation. Within the distal humeral fracture group, 78% of the patients (29 out of 37) showed moderate to severe functional impairment, while within the proximal radial or ulnar fracture group, 54% of the patients (26 out of 48) displayed the same. Surgical excision of the HO was required in a total of 20 patients, with 7 following distal humerus fracture and 13 following proximal radial or ulnar fracture. The surgical excision of HO following the treatment of the proximal radial or ulnar fracture was performed at the mean of 33 ± 30 weeks (median, 20 weeks; range, 12 to 122 weeks) with the goal of improving ROM. In 1 out of these 13 patients, HO recurred. In the humeral fracture group, certain factors were found to be significant in increasing the risk of HO development. These factors included simultaneous head injury, delayed internal fixation, the specific method of fracture fixation (parallel plating was associated with a higher risk compared to using a single plate), as well as the use of bone graft or substitute. In cases of proximal ulnar or radial fracture, factors that increased the risk of HO development were concurrent elbow dislocation or subluxation, severe chest injury, and open injuries.

4.2. CLINICAL PICTURE

The clinical findings following the development of HO differ based on the severity and the stage of the disease (21). When HO is clinically significant, there is a gradual progression of pain and swelling, which can eventually result in ankylosis (joint immobility). In the early stages (0-4 weeks), symptoms include pain, swelling, and a subjective feeling of stiffness at the affected site. In the intermediate stages (5-8 weeks), both subjective and objective stiffness increase. In the late stages (9-12 weeks), there is a decrease in the ROM, and the possibility of joint immobility (ankylosis) arises. A classification was created by Brooker et al. (22) which divides HOs at the hip into 4 groups, depending on the severity (Table 1), and is still the most commonly used classification today.

Table 1. Brooker classification of heterotopic ossification (HO) at the hip joint. According to Brooker et al. (22)

Class	Definition
I	Islands of bone within soft tissues of the hip
II	Bone spurs in the pelvis or femur but with ≥ 1 cm between bone surfaces
III	Bone spurs within the pelvis or femur with ≤ 1 cm between bone surfaces
IV	Ankylosis of the hip

A study by Rudiger et al. (23) examined the severity of HO following total hip arthroplasty. The study found that the incidence of HO was 29.9%, with the majority of cases classified as Brooker grades 1 to 3. Patients with lower grades of HO were largely asymptomatic. However, Brooker grade 4, present in only 0.57% of patients, led to significantly worse patient-reported outcome measures. Another study by Zheng et al. (24) involving 327 patients who underwent hip arthroscopy identified 14 cases (4.28%) of radiographically confirmed HO. Among these cases, 12 patients were asymptomatic during the last follow-up. In most instances, HO was observed in the central area of the arthroscopic portals or capsulotomy. For 2 patients with Brooker grade 2 disease revision hip arthroscopy to remove symptomatic HO was required. Fortunately, both patients were able to resume their previous recreational activities and did not experience a recurrence at the 2-year follow-up.

4.3. DIAGNOSIS AND DIFFERENTIAL DIAGNOSIS

Multiple diagnostic modalities for the detection of HO have been described throughout the literature. Plain radiographs (X-ray) represent the first option, because of their simplicity and low cost, however, they can have limitations early in the disease process due to the inability to determine the anatomical extent of the disease (12). Computed tomography (CT) scans are superior in that regard but are usually saved for preoperative planning for three-dimensional visualization. Magnetic resonance

imaging (MRI) as well can be used, for more detailed visualization of local soft-tissue and/or neurovascular involvement. Three-phase bone scans have also been proven useful in the early diagnosis of HO. The bone scan is utilized for both diagnostic purposes and to evaluate the progression of HO. A three-phase bone scan is performed as an initial scan once symptoms of HO appear. Subsequent scans are conducted every few months to monitor a decreasing trend in blood flow and blood pool activity, indicating the maturation of the disease. Once a steady state is reached for 2 to 3 months, indicating disease maturity, surgical intervention can be considered to enhance joint mobility (25). This imaging however has a relatively high false positive rate due to the inability to differentiate HOs from inflammation or callus at the site of injury (26). Ultrasound, even though it is operator dependent can also be used for diagnosis. Novel imaging technology called Raman spectroscopy is a technique that identifies and analyses the molecular vibrations present in a sample, providing insights into the sample's molecular structures and chemical properties (27). It has also shown potential and superior advantages for early diagnosis of HO compared to the current diagnostic modalities mentioned above (12).

Some commonly conducted laboratory tests include measuring serum levels of calcium, phosphorus, and alkaline phosphatase (ALP). In the early stages of the HO, these test results are often high, but they typically return to normal within 9 to 12 weeks (21). None of these, however, has been proven to be a reliable screening tool for the early detection of HO (28). Other laboratory values that may be elevated during the acute stage of the disease are c-reactive protein (CRP), erythrocyte sedimentation rate (ESR), and serum creatine kinase (CK). CRP is a more specific indicator than ESR, and both markers tend to normalize as time passes. While elevated CRP and ESR levels can indicate an infection, the inclusion of calcium, phosphorus, and ALP together provides a more specific indication of HO. Serum CK has been demonstrated to serve as a reliable predictor of the occurrence and severity of HO (29). Finally, if there is a possibility of a tumour, a biopsy may be considered but comes with a risk of worsening the symptoms of HO.

Differential diagnoses of HO include dystrophic calcification, which is virtually indistinguishable on plain films, CT, or MRI early in the disease course (30). HO undergoes a process of organization and ossification that occurs gradually over several months, resulting in the formation of lamellar bone. On the other hand,

dystrophic calcifications will persist as amorphous, non-ossified calcifications. Chondrocalcinosis can also present similar to HO. However, the linear deposits along the articular surface in chondrocalcinosis contrast with circumferential calcific mass with minimal intra-articular involvement in HO. Tumoral calcinosis also exhibits similar symptoms to HO with joint pain, swelling, and immobility, however, this develops over the course of several years. In comparison to HO, tumoral calcinosis is characterized on plain radiographs, CT and MRI as a fluid-filled lobulated, cystic calcification, while HO appears neither fluid-filled nor cystic. An avulsion fracture is a type of fracture where a small piece of bone breaks away due to the forceful pulling or tearing of a tendon or ligament attached to it. On X-ray, it can present identically to HO. Clinical history as well as the timing of diagnostic imaging are required to differentiate between the 2 clinical entities. An avulsion fracture will be present immediately after trauma, while HO needs multiple weeks to develop and months to mature. Primary osteosarcoma, the most common primary bone tumour as well can clinically and radiographically mimic HO. The appearance on plain radiographs is commonly described as a »sunburst« appearance. On CT however, the amorphous osteoid formation of osteosarcoma can be differentiated from organized circumferential osteoid formation in HO. Calcific tendonitis, a condition defined by calcium deposition in tendons is yet another differential diagnosis of HO. It lacks however some of the HO characteristics such as its well-defined shape as well as the hyperintense core seen on T1 weighted images.

4.4. TREATMENT AND PREVENTION

Management of HO is divided into prophylaxis and treatment. Treatment options once the diagnosis is made are quite limited. No clear evidence exists proving that physical therapy improves ROM following injury (12). As for pharmacological treatment, the use of retinoid acid receptor gamma agonists such as Palovarotene has been suggested for the treatment of HO caused by FOP. Phase II and phase III clinical trials provided evidence of the safety and effectiveness of palovarotene as a potential disease-modifying treatment for individuals with FOP. Although post hoc analyses have

demonstrated significant efficacy, there have been reports of side effects and complications, such as premature growth plate closure in certain patients (31).

The only definitive treatment once the diagnosis is made is surgical excision. This is considered when no clinical improvement is observed despite non-surgical interventions or if there is progressive disability despite stable imaging results. It is recommended to delay surgery until 12 to 18 months after the formation of HO to allow for the maturation of the lesion and sufficient recovery time for the patient's tissues. This delay aims to reduce intraoperative complications and the likelihood of HO reoccurrence. While surgery can be effective, it inherently causes tissue trauma, which can trigger similar inflammatory conditions that lead to HO formation. As a result, surgery is often associated with high rates of HO reoccurrence (30). Malignant transformation of HO to osteosarcoma has been reported (32), however, it is extremely rare. Regular follow-up is recommended for early detection and management.

Prevention is the preferred method of management of HO. Nonsteroidal anti-inflammatory drugs (NSAIDs), bisphosphonates, and radiotherapy have all been used in the past for HO prophylaxis. Out of those, the use of bisphosphonates has been the most disputable, with some studies concluding that their use is either ineffective or even increases the risk of developing HO (33, 34). The use of either NSAIDs or radiotherapy has been proven equally effective. A study was done by Moore et al. (35) in the setting of HO following acetabular fracture, described no significant difference between the 2 treatment modalities concluding, that whether to use NSAIDs or radiotherapy depends mostly on the clinical context of the patient. To illustrate, as soft-tissue contracture complications can significantly harm burn patients, NSAID therapy may be a better option than radiation, assuming there are no gastrointestinal issues. However, patients undergoing hip arthroplasty may qualify for either preventive method. Other factors, such as long-term drug adherence and expenses, should also be taken into account.

5. HO AND SARS-COV-2 INFECTION

SARS-Cov-2 is an enveloped single-stranded positive-sense mRNA virus that falls in the category of coronaviruses together with SARS-CoV-1 and Middle East respiratory syndrome coronavirus (MERS-CoV). It enters the cells through the angiotensin-converting enzyme (ACE) 2 receptor using the serine protease TMPRSS2 (36). Even though the virus gains entry through the respiratory tract (more specifically type II pneumocytes) viremia can develop due to the compromised alveolar epithelium observed in certain individuals affected by COVID-19. This makes the rest of the organ systems expressing ACE 2 receptors including the musculoskeletal system susceptible to infection. After infection, 3 pathophysiologic mechanisms have been described to explain the effects of COVID-19 on the musculoskeletal system (37). These include the development of a prothrombotic state, autoimmunity, and the cytokine storm, characterized by systemic elevation of many cytokine levels, particularly on the IL-6/ tumour necrosis factor (TNF) alpha axis (38). Increased levels of IL-6 have been correlated with increased severity of the disease. A study by Coomes and Haghbayan (39) found levels of IL-6 to be 2.9 times higher in patients with complicated versus non-complicated COVID-19 disease. This pro-inflammatory response induced by SARS-CoV-2 infection is mediated through the host's innate and adaptive immune system and could be implicated in the development of HO in patients following a severe disease course. It has been previously demonstrated that altered levels of inflammatory cytokines correlate with HO occurrence. In a mouse study, when a cutaneous burn was combined with Achilles tenotomy, the researchers observed higher levels of TNF-alpha, IL-1 beta, IL-6, and monocyte chemoattractant protein-1 (MCP-1) in the bloodstream, which were linked to the formation of HO (40). Elevated levels of inflammatory markers have also been noticed in cases of human traumatic HO, both locally and systemically. For instance, individuals with penetrating, high-energy battle wounds in their extremities showed among other risk factors heightened levels of various cytokines and chemokines, each of which was linked to the development of HO. Specifically, increased levels of IL-6, IL-10, and MCP-1 in the blood serum, as well as interferon gamma-induced protein 10 and macrophage inflammatory protein 1-alpha in the wound effluent, were positively associated with the formation of HO (41). Another study conducted on combat-related high-energy trauma

revealed a connection between the occurrence of HO and higher levels of IL-3 in both the blood serum and wound effluent. Conversely, lower levels of serum IL-12p70 and wound fluid IL-13 in these patients were linked to a decreased likelihood of developing HO (5). Even though other factors in these studies played a role in the development of HO, the role of cytokines should still be considered to be relevant. Other factors found to possibly contribute to the development of HO in patients suffering from severe SARS-CoV-2 infection are prolonged intensive care unit (ICU) stay, chronic immobilization, and metabolic changes associated with mechanical ventilation. These were all previously described to affect the formation of HO, in the context of other critical illnesses (42).

5.1. REVIEW OF THE LITERATURE

A literature search of PubMed and Google Scholar by using keywords “COVID-19” and “heterotopic ossification” revealed 19 reports among which there was a letter to the editor and a correspondence. Unfortunately, 2 articles written in the German language by Peters et al. (43) and Dahmen et al. (44) were out of reach. In total, 42 patients were reported to suffer from HO after contracting COVID-19, 22 of which were reported as independent case reports (Table 2) (45-61). Additional 10 patients were presented in a letter to the editor by Stoira et al. (62). Another 10 cases were reported and described radiologically by Mezghani et al (63) but with no clinical context. The genetic form of HO as a part of diseases such as FOP, which presents similarly, was not included in the analysis.

Meyer et al. (45) were the first to describe the association between HO and COVID-19. In their case series, they described 4 male patients developing HO after severe COVID-19 pneumonia requiring a lengthy stay at the ICU and mechanical ventilation. Older patients aged 64, 73, and 74 years developed HO around the hip joint either monolaterally or bilaterally (the youngest among them). The last of the 4 patients, who was 39 years old developed HO in the shoulder joint bilaterally. After contracting COVID-19 all of the patients were admitted to the ICU, where they were intubated due to their severe respiratory distress. Older patients stayed on a mechanical ventilator

Table 2. Reported cases of heterotopic ossification (HO) post severe acute respiratory syndrome coronavirus 2 (SARS-CoV-2) infection.

1 st Author & Year	A/G	Site involved	DOH	DOMV	MCKL	MALPL
Meyer (2020) (45)	64/M	H	N/A	26 days	N/A	200 UI/L
	73/M	H	N/A	27 days	N/A	126 UI/L
	74/M	H	N/A	30 days	N/A	105 UI/L
	39/M	S	N/A	28 days	N/A	200 UI/L
Ploegmakers (2020) (46)	59/M	S	N/A	N/A (stated as nearly a month)	N/A	N/A (stated as elevated)
	53/M	H, S	N/A	10 weeks	N/A	397 U/L
Valero (2020) (47)	62/M	H	45 days	N/A	N/A	N/A
Aziz (2021) (48)	51/F	S	47 days	N/A	968 U/L	148 U/L
	43/F	S	33 days	N/A	2199 U/L	N/A (stated as within normal limits)
Brance (2022) (49)	55/M	H, S, E, K, A	67 days	N/A	75 U/L	111 UI/L (bone ALP – 69%)
Benkhaled (2022) (50)	52/M	H, S	N/A	N/A	N/A	N/A
Minjauw (2022) (51)	74/M	H	N/A	27 days	N/A	N/A
Liu (2022) (52)	23/F	K	81 days	N/A	N/A	N/A
Vardar (2022) (53)	45/M	H, S, E	60 days	55 days	N/A	291 IU/L
Micolich (2022) (54)	63/M	I, SS, TM	134 days	N/A	N/A	N/A
Chang (2022) (55)	55/M	S	N/A	N/A	N/A	Stated as “moderately elevated”
Ochten (2022) (56)	59/M	H	N/A (but 100+ days)	43 days	N/A	N/A
Milner (2022) (57)	20/M	H	90 days	69 days	N/A	N/A
da Nóbrega Danda (2022) (58)	52/F	H	76 days	37 days	N/A	N/A
Nieto Morales (2022) (59)	76/M	H	4 months (2 months in the ICU)	2 months	N/A (elevated)	N/A (elevated)
Castro (2022) (60)	60/M	H	N/A	2 months	N/A	N/A
Grosjean (2022) (61)	63/M	HS	N/A	22 days	N/A	N/A

A/G – age/gender, DOH – duration of hospitalisation, DOMV – duration on mechanical ventilation, MCKL – maximal creatine kinase levels, MALPL – maximal alkaline phosphatase levels, M – male, F – female, H – Hip, K – knee, S – shoulder, E – elbow, A – ankle, I – intercostal muscle, SS – subscapular muscle, TM – teres major muscle, N/A – not available, UI/L – units per litre, ICU – intensive care unit

for 26, 27, and 30 days respectively. After 39, 40 and 41 days respectively all 3 patients started to complain of acute pain with reduced ROM in hip joints, which limited gait and sitting. Lab findings revealed ALP levels at 200, 126, and 105 UI/L respectively. The youngest of the 4 patients required intubation for 28 days. At day 30 he complained of acute bilateral scapular pain with limited ROM. ALP levels were elevated at 200 UI/L. It is hypothesized by the author that multiple factors played a role in the development of HO in these patients. Altered acid-base homeostasis and tissue hypoxia induced by mechanical ventilation, inflammatory reaction induced by COVID-19 as well as prolonged immobilization could all result in the development of HO.

Following the publication of this case series by Meyer et al. (45), other authors started publishing their own cases where patients developed HO following COVID-19 infection. Of 22 patients presented as case reports out of a total of 42 cases, 18 of the patients were males and 4 females, which developed HOs after a serious COVID-19 all requiring admission to the ICU and mechanical ventilation. Unfortunately, no controls were present to which comparisons could be made. The median age of the 22 patients at the time of HO development was 57 years old, with the youngest patient being 20 years old and the oldest 76 years old. Single joint affection with HO had 16 patients (72.7% of all patients), while the remaining 6 patients had an affection of 2 or more regions with HO. The most common affected site was the hip joint affecting 15 patients (68.2%), 10 of which were bilateral and 5 monolateral. The soft tissues surrounding the shoulder joint were involved in 10 cases (45.5%; 7 bilateral, 3 monolateral), the elbow and knee in 2 cases each, and the ankle in 1 patient. In 1 patient HOs developed bilaterally in intercostal, subscapular, and teres minor muscles. For 9 patients, the studies provided comprehensive particulars about the duration of hospitalization. The patients stayed at the ICU from 33 days to up to 134 (median 71.5 days). Another study reported that the patient stayed for more than 100 days, but not specifically how long (56). For 12 patients the duration of mechanical ventilation was specified. It ranged from 22 days to as much as 70 days (stated as 10 weeks) with a median of 37 days. For 1 patient, the duration of mechanical ventilation was given as »nearly a month« (46). Only 3 patients were provided with maximal CK values, 2 of which had drastically increased values (968 and 2199 U/L), 1 with a value within the reference range (75 U/L). 1 study stated CK levels only as »elevated« (59). Another

characteristic noted to be associated with HOs was levels of ALP. It was measured in 12 patients. The results spanned from 105 to 397 U/L. There were 4 exceptions in which it was stated either as »elevated« or »moderately elevated« (3 cases) and another one where the value was »within the normal limits« (46, 48, 55, 59). In 1 case, ALP was within the reference range (111 UI/L), however, bone-specific ALP was increased (49) (69%, reference range 20-40).

Out of these 22 patients, 3 patients were surgically treated while additional 3 patients consulted orthopaedic surgeons for potential surgery. Whether the surgery was performed or not is not available. Another patient considered a surgical candidate was lost to follow-up making his treatment plan unavailable.

In the letter to the editor published by Stoira et al. (62), 52 patients suffering from SARS-CoV-2 infection requiring mechanical ventilation were included in the study, 10 of whom developed HO during their hospitalization. The diagnosis of HO was confirmed with CT imaging. The most common site involved was the musculature of the hip, posteriorly and medially located (gluteus minimus, gemellus superior and inferior, quadratus femoris, piriformis, and obturator internus muscles in 6 cases, 4 bilateral and 2 monolateral) and anteriorly located (ileopsoas muscle in 1 case, monolateral). The shoulder muscles were affected in 3 cases (subscapularis muscle in 2 cases, mono-lateral and rotator cuff, deltoid, biceps and triceps in 1 case, bilateral), and elbow in 1 case (medial head of triceps, monolateral). Characteristics such as laboratory results, duration of treatment, and demographics of the 2 groups were compared (diseased vs non-diseased). The study discovered that 3 factors showed a significant statistical correlation with the occurrence of HO (Table 3).

Patients who experienced HO demonstrated longer periods of mechanical ventilation (with a median of 36 days compared to 22 days), extended hospital stays (with a median of 53 days compared to 33 days), and higher levels of maximal measured CK (with a median of 820 U/L compared to 295 U/L). On the other hand, factors like age, gender, body-mass index, comorbidities, treatment with steroids, and other variables were not identified as being connected to the development of HOs.

Table 3. Findings by Stoira et al. (62) of patients hospitalized due to SARS-CoV-2 infection who developed heterotopic ossification (HO) vs. those who did not develop it. Prolonged duration of mechanical ventilation and hospitalization as well as increased maximal level of creatine kinase significantly increased the risk of developing HO. IQR – interquartile range

Characteristic	HO N=10	No HO N=42	P-value
Age median, (IQR)	71, (67-74)	69, (60-73)	0.530
Male gender	8	34	0.945
Duration of mechanical ventilation, days median, (IQR)	36, (25-45)	22, (7-36)	<0.001
Maximal creatine kinase, U/L median, (IQR)	820 (262-1114)	295, (154-507)	0.037
Duration of hospitalization, days median, (IQR)	53, (43-58)	33, (24-42)	0.002

A correspondence by Mezghani et al. (63) reported another 10 patients with a total of 19 HOs following severe COVID-19 infection requiring admission to the ICU and mechanical ventilation. No clinical context was provided in the study such as length of stay at the ICU, duration of mechanical ventilation, or laboratory values. However, a detailed radiological evaluation of the HOs was performed using biphasic CT. This was done as a part of the preoperative assessment prior to the HO excision. The most common site involved was again the hip joint representing 14 out of a total of 19 HOs (73.7%). The only other site involved was the knee joint with 5 total HOs. The location of HOs was most common posterior to the joints, observed in 7 out of 19 HOs. There were 3 instances of capsular disruption and another 3 cases of neural involvement of sciatic nerve. Another patient presented with concomitant venous thrombosis ipsilateral to the HO. Bilateral presentation of HO was recorded in 70% of the cases. The study found several imaging features specific to COVID-19-related HOs compared to another similar study by Law-Ye et al. (64) analysing pre-surgical

radiological features of neurogenic myositis ossificans using biphasic CT. These included less severe damage to vascular and neural structures, less severe bone demineralization, and less joint shrinkage which they attributed to the shorter time course of the pathology, compared to other causes of HO. Contrary to expectations, anterior muscle involvement did not prevail as anticipated. This was expected due to the prone positioning used as a part of treatment for patients hospitalized in the ICU for COVID-19 infection.

6. CASE REPORT

A male patient aged 50 years old with chronic arterial hypertension presented to the hospital on 14. 11. 2020 with a cough, generalized pain, and febrility of up to 38.4 °C. He was diagnosed with SARS-Cov-2 infection by polymerase chain reaction test on 17. 11. 2020 and hospitalized 2 days later. He was treated with remdesivir and dexamethasone and oxygenized through a high-flow nasal cannula. Intubation was performed on 22. 11. 2020 due to the development of acute respiratory distress syndrome (ARDS). He was extubated 8 days later (30. 11. 2020) and transferred to a clinic for infectious diseases. Prior to that *Klebsiella oxytoca* and *Acinetobacter baumannii* were isolated from bronchoalveolar lavage. He was again reintubated on 02. 12. 2020. At the same time, a dialysis catheter was placed for continuous venovenous hemofiltration due to renal failure. Hospitalization was complicated by brain hypoperfusion and hyperdense zone on a CT scan in the occipital horn of the right lateral ventricle which could represent a small zone of haemorrhage, from which he recovered days later. The patient remained on ventilatory support until 29. 12. 2020 during which a tracheostomy was performed (09. 12. 2020), for a total of 35 days on mechanical ventilation. The dialysis catheter was removed on the same day due to the improvement of his renal status. He was transferred to another hospital on 05. 01. 2021 due to a suspicion of a brain tumour. Following a CT scan, those lesions were characterised as secondary lesions due to the previous episode of brain haemorrhage mentioned above. A suspicion of melanoma on the choroid layer of the eye was also made during this hospital stay, which was later dismissed. He was hospitalized there until 18. 01. 2021 for a total duration of hospitalization of 61 days. During his hospitalization, the peak levels of CK and ALP recorded were 111 IU/L and 175 U/L, respectively.

The first evidence of HO was seen on positron emission tomography CT (PET-CT) obtained a month and a half following discharge from the hospital (Figure 1). The PET-CT was followed by plain radiographs of both hip and knee joints, which confirmed the diagnosis of HO (Figures 2 and 3).

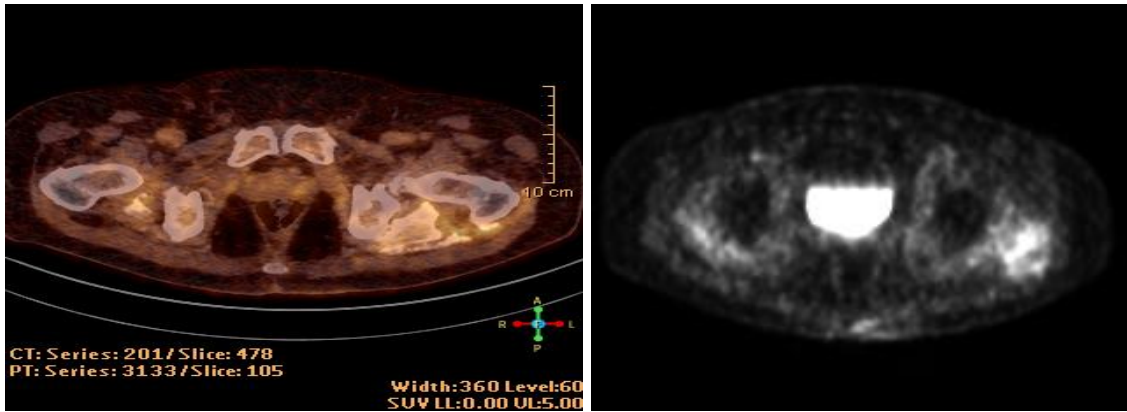


Figure 1. On the left is a tomographic transverse section of the pelvis fused with positron emission tomography (PET) and computed tomography (CT) images or PET-CT of the hip demonstrating increased accumulation of fluorodeoxyglucose in both hip joints with a maximum standardized uptake value of 4.6. On the right is a PET scan of both hips demonstrating early heterotopic ossifications in surrounding pelvic muscles. The imaging was obtained on 01. 03. 2021.

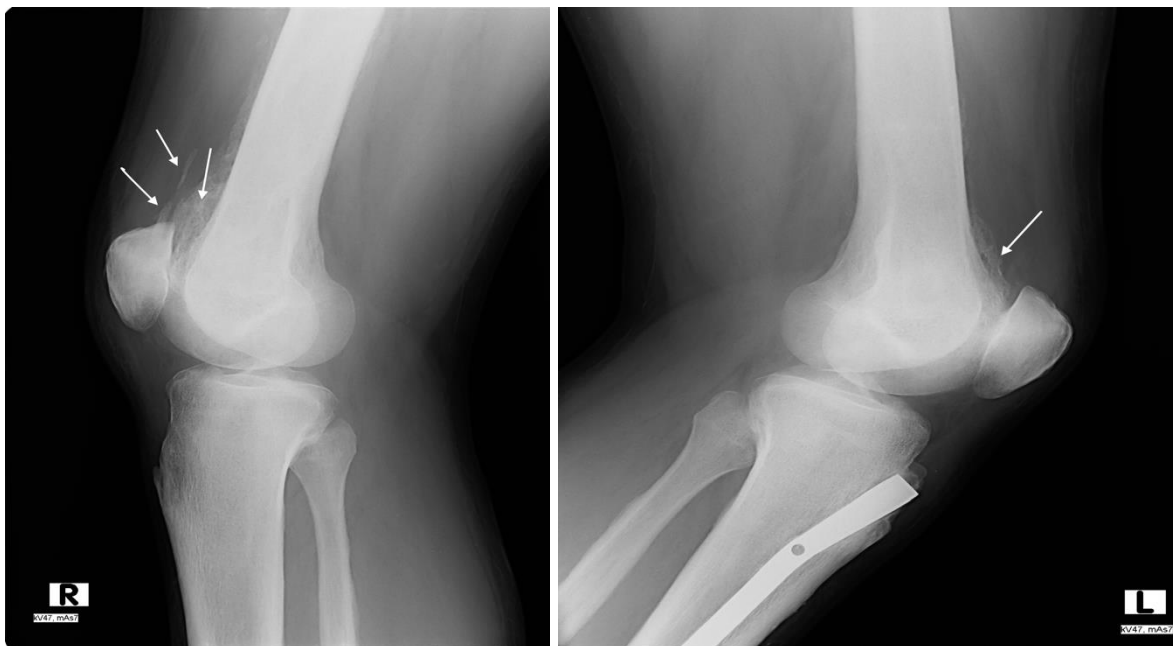


Figure 2. X-ray of the right knee (left) and left knee (right) from laterolateral projection obtained on 20. 10. 2021, i.e. approximately 11 months post admission. Heterotopic ossifications (HOs) are seen in the superior aspect of both knees as depicted by the

arrows. An intramedullary nail can be seen in the left knee, which was introduced in the year 2012 during osteosynthesis following a tibial fracture.

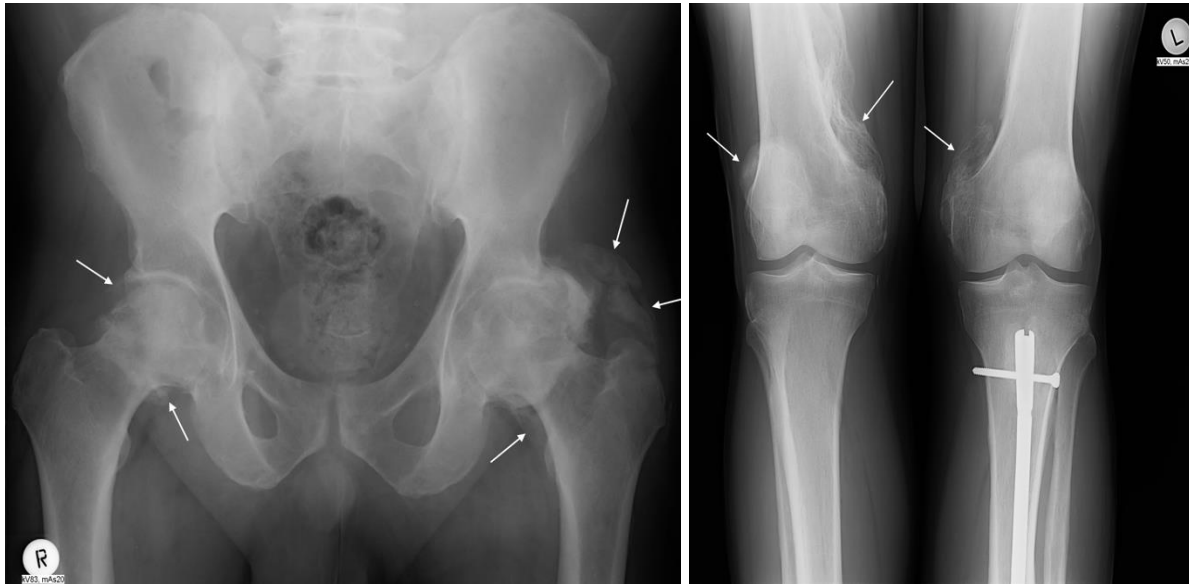


Figure 3. Anteroposterior projection X-rays of the hips (left) and knees (right) obtained on 20. 10. 2021, i.e. approximately 11 months post admission. Heterotopic ossifications (HOs) are seen bilaterally in both hip (left) and knee (right) joints as depicted by the arrows. On the left knee, an intramedullary nail can be seen following osteosynthesis performed in the year 2012 due to a tibial fracture.

The patient presented to orthopaedic surgeon on 02. 11. 2021. complaining of left hip pain that started after he recovered from COVID-19. A diagnosis of bilateral hip osteoarthritis, as well as bilateral hip and knee HO, was made. At the time, the surgery for either was contraindicated due to the HO still being in a developmental stage so follow-up was indicated. The patient returned to the clinic approximately 6 months later, on 05. 05. 2022, with subjective improvement, and further follow-up was arranged. The last follow-up examination of the patient was performed on 25. 05. 2023. The patient had minor discomfort within the left hip and right knee area. Limited active dorsiflexion of the left ankle and foot drop on the left side, as well as hypoesthesia on the left foot, was noted. The symptoms were present since the recovery from COVID-19. He could not walk on his heel on his right foot but could

normally walk on his toes. ROM in his hips and knees was limited, most profoundly on his left hip and right knee. Flexion of his knee was limited to 130 ° on the right side and 145° on the left side. Flexion in both hips was possible up to 110 ° on the left side and 115 ° on the right side. Internal rotation in flexion on the right side was around 10 ° and it was blocked on the left side. External rotation was terminally limited in both hips, possible on the right side up to 30° and on the left side up to 15°. Abduction on the left side was possible up to 20° and on the right side up to 35°. HOs in the knees were not painful on palpation. Due to the improvement of symptoms following physical rehabilitation and no radiological progression seen on the X-ray (Figure 4.), the decision not to perform surgery was made and the patient is being followed up on a regular basis. He was also instructed to continue performing home exercises as taught and to take prescribed NSAIDs as needed. The patient signed an informed consent agreeing to display his case in this graduate thesis.

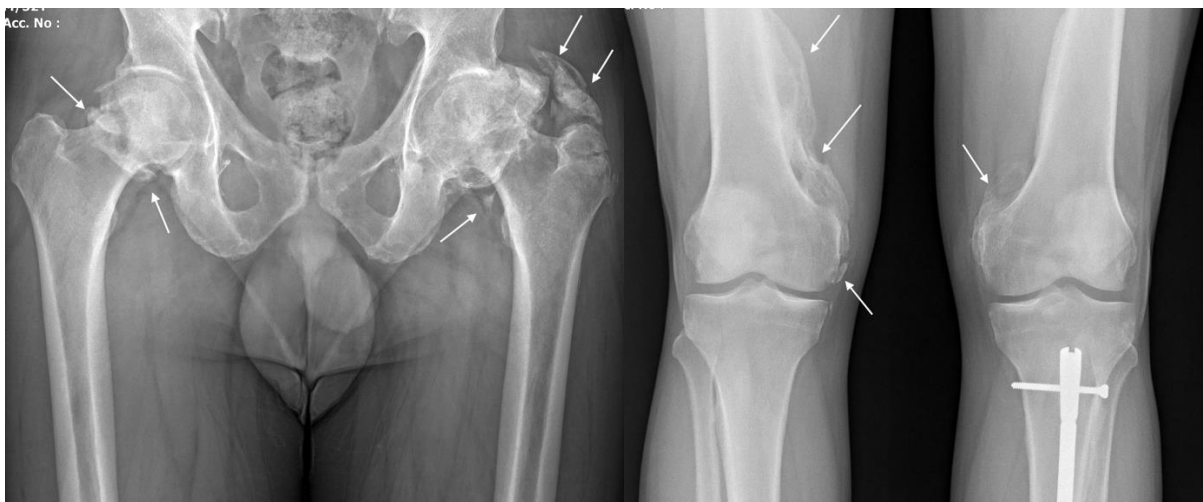

Figure 4. X-ray of the hips (left) and knees (right) from anteroposterior projection obtained on 25. 05. 2023, i.e. approximately 2.5 years post admission. Heterotopic ossifications (HOs) are seen bilaterally in both hip (left) and knee (right) joints as depicted by the arrows. No progression was noted from the previous X-rays. On the left knee, an intramedullary nail can be seen following osteosynthesis performed in the year 2012 due to a tibial fracture.

7. DISCUSSION

The evidence currently available does suggest a link between SARS-CoV-2 infection and an increased risk for HO. At least 43 cases of HO following severe COVID-19 infection have been by now confirmed in the literature, with the prevalence among patients with severe COVID-19 being reported as high as 19.2% (62). HO following COVID-19 infection presents as a clinically significant entity, causing major functional impairments such as pain and reduced ROM, with up to 37.2% of patients required to undergo surgical treatment due to symptomatic HO.

Every single one of the patients who developed HO followed a complicated course of COVID-19 infection requiring admission to the ICU and mechanical ventilation due to respiratory failure. A conclusion was made that a prolonged duration of hospitalization correlated with an increased incidence of HO. The mean duration of hospitalization was markedly increased in patients who went on to develop HO (71.5 days from the 9 case reports that provided details and 53 days from the study by Stoiria et al. (62)) compared to those who didn't (33 days from the same study by Stoiria et al. (62)). The same observation was made for the duration of mechanical ventilation. Patients who developed HO spent significantly longer periods on mechanical ventilation (a mean of 37 days from 12 case reports and 36 days from the study by Stoiria et al. (62)) compared to the individuals who did not develop HO (a mean of 22 days from the same study by Stoiria et al. (62)). The patient presented in the thesis stayed on a mechanical ventilator for 35 days and was hospitalized for 61 days in total. The time of mechanical ventilation in the patient was within the limits presented in the literature related to the topic.

The prolonged duration of artificial ventilation was associated with an increased incidence of neurogenic HO. In a study by Hendricks et al. (65), patients following TBI who developed HO were on mechanical ventilation for approximately 15 days longer than those who didn't. However, prolonged coma, the occurrence of autonomic dysregulation, diffuse axonal injury, spasticity, and systemic infection all were associated with HO development as well. The same observation was made in a study by van Kampen et al. (66) where longer duration of coma and mechanical ventilation

as well as autonomic dysregulation and surgically treated extremity fractures showed statistically significant association with the development of HO.

Several theories regarding the pathophysiology of HO development following mechanical ventilation have been proposed. In one the suggested explanation for the connection between artificial ventilation and the development of HO is that prolonged use of mechanical ventilation, which is frequently observed in patients with TBI and SCI, can disrupt the patient's homeostasis, particularly affecting electrolyte levels (such as calcium and phosphorus) and the acid-base balance (including changes in oxygen levels and pH) (67). Another hypothesis regarding the relationship between artificial ventilation and the development of HO proposes that the intentional hyperventilation performed during the acute phase of traumatic brain injury TBI patients, aimed at reducing intracranial pressure by lowering pCO₂ levels, can lead to systemic changes. This can cause a shift towards alkaline blood pH, increasing the risk of salt precipitation, particularly calcium precipitation. These alterations may potentially expedite callus formation and accelerate fracture healing processes (68). The mechanical ventilation settings however are adjusted for each individual patient specifically. In patients with TBI, mechanical ventilation may be used to control intracranial pressure while in patients with severe respiratory distress due to COVID-19 pneumonia, mechanical ventilation is primarily focused on providing adequate oxygenation and ventilation support. This is why the pathophysiological mechanism of developing HO after prolonged mechanical ventilation due to TBI might not apply to COVID-19 patients.

It seems that the prolonged hospital stay and mechanical ventilation could be indicators of overall disease (in our case COVID-19) severity which positively correlates to HO incidence. The severity of COVID-19 infection itself is likely a significant factor influencing the occurrence of HO. The systemic inflammatory response, immune dysregulation, and endothelial dysfunction associated with severe COVID-19 could potentially trigger abnormal bone formation. Prolonged ventilation times and ICU stay may just serve as a surrogate marker for the severity of the disease, as patients with more severe infections tend to require extended respiratory support.

The complication of brain hypoperfusion and haemorrhagic lesions in the patient described in the case report adds an intriguing dimension to the discussion. While

central nervous system injuries, such as TBI or SCI have been proven to increase the risk of HO, brain hypoperfusion is pathophysiologically distinct. However, it is plausible that the disruption of normal CNS function and associated metabolic imbalances might contribute to the development of HO.

The weakness in the left-side lower leg experienced by the presented patient adds further complexity to the case. While suspicion of asymmetric infectious neuropathy or critical illness neuropathy has arisen based on electromyography results, clinical presentation, and patient history, a definitive diagnosis is still pending. Exploring potential causes, it is worth considering the possibility of sciatic nerve compression at the hip level due to HO, or compression of the common peroneal nerve by HO at the knee level. Supporting this notion, Mezghani et al. (63) reported sciatic nerve involvement in 3 out of 10 patients with HO following severe COVID-19. Additionally, they documented 6 cases where HO caused nerve displacement, albeit without specifying the nerves affected. Notably, among the 22 patients described in case reports, only 1 required surgical release for sciatic nerve compression (60).

An observation was also made regarding 2 laboratory values (ALP and CK) that tended to increase in patients with HO compared to those without HO. Correlation has been proposed between CK levels and HO development in patients following SCI. Several authors (29), (69) provided valuable data suggesting CK having predictive value of severity of HO. Stoira et al. (62) displayed significantly elevated levels of CK in patients who developed HO post severe COVID-19 infection (a mean value of 820 U/L) compared to those who did not (a mean value of 295 U/L). The patient in presented case report had values within the reference range (55 to 170 U/L for males and 30 to 135 U/L for females (70)) with a peak value of 111 U/L. In the literature review 3 additional patients had elevated values of CK compared to 1 patient who did not. Even though there is some evidence suggesting CK has value in the diagnosis of HO in patients post severe COVID-19 infection, the sample size is still too small to firmly conclude it. Larger scale studies would be necessary to prove the same correlation between COVID-19 infection and HO development.

More consistently measured were serum ALP levels in the literature review. ALP levels were above the reference range (38-126 IU/L (45)) in 9 of 13 patients (69.2%) whose data was presented in the literature. The patient presented in the thesis is included among the 13 patients. Several studies were done previously on this topic with

different results. Citak et al. (28) analysed ALP levels at the time of diagnosis of HO following SCI. They concluded that ALP is not a reliable screening tool as only 49 out of 87 patients (49.4%) included in the study had elevated levels of ALP. Conversely, in a study by Orzel & Rudd (71), serum ALP levels were proposed as an excellent screening tool. The study included 43 patients with the diagnosis of HO following different types of injuries, with proper samples being collected from 35 patients. In every single one of those 35 patients, the serum ALP levels were elevated at the time of diagnosis. This literature provides a template for further research regarding serum ALP levels as a screening tool, since a relatively high percentage of tested patients showed elevated levels.

There are limitations to the current evidence. The available studies consist of small sample sizes and mostly lack control groups for comparison. This makes it challenging to establish a definitive causal relationship between SARS-CoV-2 infection and HO. Furthermore, factors such as comorbidities, medications, different treatment approaches, and individual variations may confound the observed associations. To obtain a more comprehensive understanding of the relationship between severe SARS-CoV-2 infection and HO, further research is necessary. Larger-scale studies with well-defined control groups and longitudinal follow-up are required to establish a more robust association. Long-term studies that track COVID-19 patients over an extended period, assessing their bone health and identifying cases of HO, would significantly contribute to our understanding of this potential link. Moreover, further molecular and cellular investigations exploring the mechanisms underlying the development of HO in COVID-19 patients would provide valuable insights. Understanding the specific pathways and immune responses involved in this process could potentially lead to the development of preventive strategies or targeted therapies.

8. CONCLUSION

Through a comprehensive analysis of 42 patients documented in the literature and a detailed case report of an additional patient, common patterns and factors emerged. Notably, prolonged hospitalization duration and mechanical ventilation were shared characteristics among these patients. Furthermore, elevated levels of ALP were consistently observed.

The findings underscore the potential link between severe SARS-CoV-2 infection and the development of HO. The extended periods of hospitalization, mechanical ventilation and associated with severe COVID-19 may contribute to the pathological bone formation observed in these patients. They may also serve as surrogate markers for the severity of the disease, which itself could be one of the risk factors. Monitoring ALP levels could serve as valuable indicators for assessing the risk of HO in individuals recovering from severe COVID-19.

Overall, this thesis contributes to the expanding knowledge base on the link between severe SARS-CoV-2 infection and HO, emphasizing the significance of early identification, continuous monitoring, and specific interventions for addressing this potential complication.

9. ACKNOWLEDGEMENTS

I would like to express my deepest gratitude and appreciation to my mentor prof. Tomislav Smoljanović, MD, PhD, for their invaluable guidance and support throughout my journey in completing this graduate thesis. Their expertise, encouragement, and commitment to my academic and professional growth have been essential in shaping the quality and direction of my research.

Additionally, I would like to extend my heartfelt thanks to my family for their constant love, encouragement, and belief in my abilities. Their unwavering support, understanding, and sacrifices have been the pillars of strength that have carried me throughout this challenging academic endeavour.

10. LITERATURE:

1. Veronesi F, Contartese D, Martini L, Visani A, Fini M. Speculation on the pathophysiology of musculoskeletal injury with COVID-19 infection. *Front Med (Lausanne)*. 2022;9:930789.
2. Edwards DS, Clasper JC. Heterotopic ossification: a systematic review. *J R Army Med Corps*. 2015;161(4):315-21.
3. Cappato S GR, Bocciardi R, Brunelli S. Genetic and acquired heterotopic ossification: A translational tale of mice and men. *Biomedicines*. 2020;8(12).
4. Chalmers J, Gray DH, Rush J. Observations on the induction of bone in soft tissues. *J Bone Joint Surg Br*. 1975;57(1):36-45.
5. Meyers C, Lisiecki J, Miller S, Levin A, Fayad L, Ding C, et al. Heterotopic ossification: A comprehensive review. *JBMR Plus*. 2019;3(4):e10172.
6. Olmsted-Davis EA, Salisbury EA, Hoang D, Davis EL, Lazard Z, Sonnet C, et al. Progenitors in peripheral nerves launch heterotopic ossification. *Stem Cells Transl Med*. 2017;6(4):1109-19.
7. Kan L, Peng CY, McGuire TL, Kessler JA. Glast-expressing progenitor cells contribute to heterotopic ossification. *Bone*. 2013;53(1):194-203.
8. Lounev VY, Ramachandran R, Wosczyzna MN, Yamamoto M, Maidment AD, Shore EM, et al. Identification of progenitor cells that contribute to heterotopic skeletogenesis. *J Bone Joint Surg Am*. 2009;91(3):652-63.
9. Medici D, Shore EM, Lounev VY, Kaplan FS, Kalluri R, Olsen BR. Conversion of vascular endothelial cells into multipotent stem-like cells. *Nat Med*. 2010;16(12):1400-6.
10. Foley KL, Hebel N, Keenan MA, Pignolo RJ. Histopathology of periarticular non-hereditary heterotopic ossification. *Bone*. 2018;109:65-70.
11. Ramirez-Gonzalez A, Castaneda-de-la-Fuente A, Castro-Cervantes V, Pineda C, Sandoval H, Hidalgo-Bravo A. Fibrodysplasia (myositis) ossificans progressiva (FOP). *Clin Rheumatol*. 2022;41(6):1929-30.
12. Ranganathan K LS, Agarwal S, Wong VW, Forsberg J, Davis TA, Wang S, James AW, Levi B. Heterotopic ossification: Basic-science principles and clinical correlates. *J Bone Joint Surg Am*. 2015;97(13):1101-11.

13. Spinarelli A, Patella V, Petrera M, Abate A, Pesce V, Patella S. Heterotopic ossification after total hip arthroplasty: our experience. *Musculoskelet Surg.* 2011;95(1):1-5.
14. Bedi A, Zbeda RM, Bueno VF, Downie B, Dolan M, Kelly BT. The incidence of heterotopic ossification after hip arthroscopy. *Am J Sports Med.* 2012;40(4):854-63.
15. van Erp JHJ, Massier JRA, Truijen S, Bekkers JEJ, Snijders TE, de Gast A. Heterotopic ossification in primary total hip arthroplasty using the posterolateral compared to the direct lateral approach. *Arch Orthop Trauma Surg.* 2021;141(7):1253-9.
16. Daum WJ, Scarborough MT, Gordon W, Jr., Uchida T. Heterotopic ossification and other perioperative complications of acetabular fractures. *J Orthop Trauma.* 1992;6(4):427-32.
17. Kaempffe FA, Bone LB, Border JR. Open reduction and internal fixation of acetabular fractures: heterotopic ossification and other complications of treatment. *J Orthop Trauma.* 1991;5(4):439-45.
18. Guo JJ, Tang N, Yang HL, Qin L, Leung KS. Impact of surgical approach on postoperative heterotopic ossification and avascular necrosis in femoral head fractures: a systematic review. *Int Orthop.* 2010;34(3):319-22.
19. Foruria AM, Augustin S, Morrey BF, Sanchez-Sotelo J. Heterotopic ossification after surgery for fractures and fracture-dislocations involving the proximal aspect of the radius or ulna. *J Bone Joint Surg Am.* 2013;95(10):e66.
20. Foruria AM, Lawrence TM, Augustin S, Morrey BF, Sanchez-Sotelo J. Heterotopic ossification after surgery for distal humeral fractures. *Bone Joint J.* 2014;96-B(12):1681-7.
21. Zhou L, Gee SM, Hansen JA, Posner MA. Heterotopic ossification after arthroscopic procedures: A scoping review of the literature. *Orthop J Sports Med.* 2022;10(1):23259671211060040.
22. Brooker AF, Bowerman JW, Robinson RA, Riley LH, Jr. Ectopic ossification following total hip replacement. Incidence and a method of classification. *J Bone Joint Surg Am.* 1973;55(8):1629-32.
23. Rudiger HA, Dittrich M, Robinson J, Mansour T, Schwab T, Stadelmann VA, et al. The impact of heterotopic ossification on self-reported outcomes after total hip arthroplasty using the direct anterior approach. *J Bone Joint Surg Am.* 2020;102(Suppl 2):91-8.

24. Zheng L, Hwang JM, Hwang DS, Kang C, Lee JK, Park YC. Incidence and location of heterotopic ossification following hip arthroscopy. *BMC Musculoskelet Disord.* 2020;21(1):132.
25. Kommana H, Magram M, Dilsizian V. The role of bone scan in the management of heterotopic ossification. *Soc Nuclear Med*; 2009.
26. Peterson JR, Okagbare PI, De La Rosa S, Cilwa KE, Perosky JE, Eboda ON, et al. Early detection of burn induced heterotopic ossification using transcutaneous Raman spectroscopy. *Bone.* 2013;54(1):28-34.
27. Dodo K, Fujita K, Sodeoka M. Raman spectroscopy for chemical biology research. *J Am Chem Soc.* 2022;144(43):19651-67.
28. Citak M, Grasmucke D, Suero EM, Cruciger O, Meindl R, Schildhauer TA, et al. The roles of serum alkaline and bone alkaline phosphatase levels in predicting heterotopic ossification following spinal cord injury. *Spinal Cord.* 2016;54(5):368-70.
29. Singh RS, Craig MC, Katholi CR, Jackson AB, Mountz JM. The predictive value of creatine phosphokinase and alkaline phosphatase in identification of heterotopic ossification in patients after spinal cord injury. *Arch Phys Med Rehabil.* 2003;84(11):1584-8.
30. Mujtaba B, Taher A, Fiala MJ, Nassar S, Madewell JE, Hanafy AK, et al. Heterotopic ossification: radiological and pathological review. *Radiol Oncol.* 2019;53(3):275-84.
31. Pignolo RJ, Pacifici M. Retinoid agonists in the targeting of heterotopic ossification. *Cells.* 2021;10(11).
32. Eckardt JJ, Ivins JC, Perry HO, Unni KK. Osteosarcoma arising in heterotopic ossification of dermatomyositis: case report and review of the literature. *Cancer.* 1981;48(5):1256-61.
33. Thomas BJ, Amstutz HC. Results of the administration of diphosphonate for the prevention of heterotopic ossification after total hip arthroplasty. *JBJS.* 1985;67(3):400-3.
34. Shafer DM, Bay C, Caruso DM, Foster KN. The use of eidronate disodium in the prevention of heterotopic ossification in burn patients. *Burns.* 2008;34(3):355-60.
35. Moore KD, Goss K, Anglen JO. Indomethacin versus radiation therapy for prophylaxis against heterotopic ossification in acetabular fractures: a randomised, prospective study. *J Bone Joint Surg Br.* 1998;80(2):259-63.

36. Disser NP DMA, Schonk MM, Konnaris MA, Piacentini AN, Edon DL, Toresdahl BG, Rodeo SA, Casey EK, Mendias CL. Musculoskeletal consequences of COVID-19. *J Bone Joint Surg Am.* 2020;102(14):1197-204.
37. Omar IM, Weaver JS, Samet JD, Serhal AM, Mar WA, Taljanovic MS. Musculoskeletal manifestations of COVID-19: Currently described clinical symptoms and multimodality imaging findings. *Radiographics.* 2022;42(5):1415-32.
38. Hussman JP. Cellular and molecular pathways of COVID-19 and potential points of therapeutic intervention. *Front Pharmacol.* 2020;11:1169.
39. Coomes EA, Haghbayan H. Interleukin-6 in COVID-19: A systematic review and meta-analysis. *Rev Med Virol.* 2020;30(6):1-9.
40. Sung Hsieh HH, Chung MT, Allen RM, Ranganathan K, Habbouche J, Cholok D, et al. Evaluation of salivary cytokines for diagnosis of both trauma-induced and genetic heterotopic ossification. *Front Endocrinol (Lausanne).* 2017;8:74.
41. Evans KN, Forsberg JA, Potter BK, Hawksworth JS, Brown TS, Andersen R, et al. Inflammatory cytokine and chemokine expression is associated with heterotopic ossification in high-energy penetrating war injuries. *J Orthop Trauma.* 2012;26(11):e204-13.
42. Christakou A, Alimatiri M, Kouvarakos A, Papadopoulos E, Patsaki I, Kotanidou A, et al. Heterotopic ossification in critical ill patients: a review. *Int J Physiother Res.* 2013;1(4):188-95.
43. Peters J, Köhler H-C, Oltmanns K, Besselmann M, Zwaan M, Gutcke A, et al. Heterotope Ossifikationen nach Langzeitbeatmung bei COVID-19 Erkrankung. *Die Rehabilitation.* 2021;60(04):231-4.
44. Dahmen A, Roukens R, Lindenberg S, Peters KM. Heterotope Ossifikationen nach Langzeitbeatmung bei COVID-19. *Osteologie.* 2021;30(02):182-6.
45. Meyer C, Haustrate MA, Nisolle JF, Deltombe T. Heterotopic ossification in COVID-19: A series of 4 cases. *Ann Phys Rehabil Med.* 2020;63(6):565-7.
46. Ploegmakers DJM, Zielman-Blokhuis AM, van Duijnhoven HJR, de Rooy JWJ, Geurts ACH, Nonnekes J. Heterotopic ossifications after COVID-19 pneumonia. *Ned Tijdschr Geneeskd.* 2020;164.
47. Valero JM, Picó JJ, Amaro A, Bueno RA, García AB, Medina C. Bilateral heterotopic ossification of the hip in a patient COVID19: A case report. *International Journal of Case Reports in Orthopaedics* 2021; 3(1): 09-11

48. Aziz A, Choudhari R, Alexander AJ, Allam E. Heterotopic ossification post COVID-19: Report of two cases. *Radiol Case Rep.* 2021;16(2):404-9.
49. Brance ML, Coccaro NM, Casalongue AN, Duran A, Brun LR. Extensive progressive heterotopic ossification post-COVID-19 in a man. *Bone.* 2022;155:116287.
50. Benkhaled S, Gomes da Silveira Cauduro C, Alexiou J, Jayankura M, Van Gestel D. Heterotopic ossification and severe COVID-19 infection. *QJM.* 2022;115(4):201-3.
51. Minjauw C, Wautier D, Mundama M. Mono-articular idiopathic heterotopic ossification in a coronavirus infected patient admitted in the intensive care unit. *Acta Orthop Belg.* 2022;88(1):206-10.
52. Liu J, Luther L, Dwivedi S, Evans AR. Long-term orthopedic manifestations of COVID-19: Heterotopic ossification and digital necrosis. *R I Med J* (2013). 2022;105(7):31-5.
53. Vardar S, Ozsoy Unubol T, Ata E, Yilmaz F. A case report of a patient with COVID-19 infection and widespread heterotopic ossification. *Turk J Phys Med Rehabil.* 2022;68(1):149-53.
54. Micolich Vergara A, Marsico S, Solano Lopez A, Zuccarino F. Bilateral intercostal, subscapular and teres major heterotopic ossifications in a 63-year-old male with COVID-19. *Oxf Med Case Reports.* 2022;2022(3):omac024.
55. Chang Y, Stathopoulou E. P053 Heterotopic ossification after COVID-19 infection-case report. *Rheumatology.* 2022 May;61(Supplement_1):keac133-052.
56. Van Ochten N, Shori A, Benert J, Puderbaugh M, Krishnamurthy M. Heterotopic ossification in post-COVID-19 patient on anticoagulation with limited treatment options. *Archives of Physical Medicine and Rehabilitation.* 2022 Mar 1;103(3):e34.
57. Milner JE, Schwartz EC, Geller JS, Constantinescu D, Allegra PR, Trapana JE, et al. Heterotopic ossification after a prolonged course of COVID-19: A case report and review of the literature. *Trauma Care.* 2022 Oct 18;2(4):550-5.
58. da Nóbrega Danda GJ. Ossificação heterotópica na COVID-19: Relato de caso e revisão da literatura. *The Brazilian Journal of Infectious Diseases.* 2022;26:102046.
59. Nieto Morales ML, Lara Martinez MF, Luna Gomez C, Bello Baez A, Allende Riera AJ. Heterotopic ossification in SARS-CoV-2: Scintigraphic and radiological images. *Rehabilitacion (Madr).* 2022;56(4):399-403.

60. Castro JM, De-la-hoz JJ, Valiente JM, Feliu E, Llamas A. Osificación heterotópica masiva en un paciente con infección por SARS-CoV-2. Reporte de caso. *Revista chilena de radiología*. 2022;28(3):109-12.
61. Grosjean D, Dekoster M, Beudart C, Kaux JF. Heterotopic ossifications after hospitalisation in intensive care for SARS-CoV-2 pneumopathy. *Rev Med Liege*. 2022;77(1):13-7.
62. Stoira E, Elzi L, Puligheddu C, Garibaldi R, Voinea C, Chiesa AF, et al. High prevalence of heterotopic ossification in critically ill patients with severe COVID-19. *Clin Microbiol Infect*. 2021;27(7):1049-50.
63. Mezghani S, Salga M, Tordjman M, Amar R, Carlier RY, Chiche L. Heterotopic ossification and COVID 19: Imaging analysis of ten consecutive cases. *Eur J Radiol*. 2022;152:110336.
64. Law-Ye B, Hangard C, Felter A, Safa D, Denormandie P, Genet F, et al. Pre-surgical CT-assessment of neurogenic myositis ossificans of the hip and risk factors of recurrence: a series of 101 consecutive patients. *BMC Musculoskelet Disord*. 2016;17(1):433.
65. Hendricks HT, Geurts AC, van Ginneken BC, Heeren AJ, Vos PE. Brain injury severity and autonomic dysregulation accurately predict heterotopic ossification in patients with traumatic brain injury. *Clin Rehabil*. 2007;21(6):545-53.
66. van Kampen PJ, Martina JD, Vos PE, Hoedemaekers CW, Hendricks HT. Potential risk factors for developing heterotopic ossification in patients with severe traumatic brain injury. *J Head Trauma Rehabil*. 2011;26(5):384-91.
67. Sakellariou VI, Grigoriou E, Mavrogenis AF, Soucacos PN, Papagelopoulos PJ. Heterotopic ossification following traumatic brain injury and spinal cord injury: insight into the etiology and pathophysiology. *J Musculoskelet Neuronal Interact*. 2012;12(4):230-40.
68. Newman RJ, Stone MH, Mukherjee SK. Accelerated fracture union in association with severe head injury. *Injury*. 1987;18(4):241-6.
69. Sherman AL, Williams J, Patrick L, Banovac K. The value of serum creatine kinase in early diagnosis of heterotopic ossification. *J Spinal Cord Med*. 2003;26(3):227-30.
70. Junpaparp P. Creatine Kinase. [Internet]: Medscape; 2023 [cited 2023 June 30]. Available from :<https://emedicine.medscape.com/article/2074023-overview#showall>

71. Orzel JA, Rudd TG. Heterotopic bone formation: clinical, laboratory, and imaging correlation. *J Nucl Med.* 1985;26(2):125-32.

11. BIOGRAPHY

I was born on 13th September 1998 in Ljubljana, Slovenia. Growing up, I developed a deep appreciation for the power of empathy and the value of human connections. These early experiences laid the foundation for my desire to pursue a career in medicine.

My educational journey began at primary school Kolezija in Ljubljana, followed by 4 years of high school in Bundesgymnasium und Bundesrealgymnasium für Slowenen in Klagenfurt, Austria, where I cultivated a love for learning and discovered my passion for the sciences. Throughout my academic years, I maintained a steadfast commitment to excellence, which propelled me toward my goal of attending medical school.

I enrolled in medical school in 2017 at Sarajevo School of Science and Technology and transferred to the medical university Zagreb after 1st year, where I finished the rest of my education.