

Retrospective analysis of patients with thrombotic thrombocytopenic purpura treated at the University Hospital Center Zagreb

Pour Modjib, Kiarash

Master's thesis / Diplomski rad

2023

Degree Grantor / Ustanova koja je dodijelila akademski / stručni stupanj: **University of Zagreb, School of Medicine / Sveučilište u Zagrebu, Medicinski fakultet**

Permanent link / Trajna poveznica: <https://um.nsk.hr/um:nbn:hr:105:777383>

Rights / Prava: [In copyright](#)/[Zaštićeno autorskim pravom.](#)

Download date / Datum preuzimanja: **2024-08-26**



Repository / Repozitorij:

[Dr Med - University of Zagreb School of Medicine Digital Repository](#)



**UNIVERSITY OF ZAGREB
SCHOOL OF MEDICINE**

Kiarash Pour Modjib

**Retrospective analysis of patients with
thrombotic thrombocytopenic purpura treated
at the University Hospital Center Zagreb**

Graduation Thesis



Zagreb, 2023

This graduate thesis was made at the Division of Hematology, Department of Internal Medicine, University Hospital Center Zagreb, and School of Medicine, University of Zagreb, Zagreb, Croatia, mentored by Associate Professor Dražen Pulanić, MD, PhD, and was submitted for evaluation in the academic year 2022/2023.

Abbreviations

ADAMTS13 – A disintegrin and metalloproteinase with thrombospondin motif 13

ATIII – Antithrombin III

aTTP – acquired thrombotic thrombocytopenic purpura

BGA – Blood gas analysis

CABG – Coronary artery bypass grafting

CBC – Complete blood count

CLL – Chronic lymphocytic leukemia

CNS – Central nervous system

cTTP – congenital thrombotic thrombocytopenic purpura

DIC – Disseminated intravascular coagulation

DMARDS – Disease modifying anti – rheumatic drugs

ELISA – Enzyme – linked immunosorbent assay

Hb - Hemoglobin

HRT – Hormonal Replacement Therapy

HSCT – Hematopoietic stem cell transplantation

hTTP – hereditary thrombotic thrombocytopenic purpura

HUS – Hemolytic uremic syndrome

INR – International Normalized Ratio

iTTP – immune thrombotic thrombocytopenic purpura

IVIG – Intravenous immunoglobulin

ICU – Intensive care unit

LDH – Lactate dehydrogenase

MAHA – Microangiopathic hemolytic anemia

MI – myocardial infarction

MOFS – multi organ failure syndrome

NSTEMI – non-ST elevation myocardial infarction

PCI – Percutaneous coronary interventions

PPI – Proton pump inhibitor

PT – Prothrombin time

PTSD – Post traumatic stress disorder

PTT – Partial thromboplastin time

rADAMTS13 – recombinant ADAMTS13

RRT – Renal replacement therapy

SLE – Systemic Lupus Erythematosus

STEMI – ST elevation myocardial infarction

TMA - Thrombotic microangiopathic anemia

TPE – Therapeutic plasma exchange

TTP – Thrombotic thrombocytopenic purpura

USS – Upshaw – Schulman syndrome

VWF – von Willebrand factor

Contents

Summary	6
Sažetak.....	7
Introduction	8
1. History of thrombotic thrombocytopenic purpura	8
2. Acquired TTP	8
2.1. Pathophysiology of acquired TTP	8
2.2. Epidemiology of acquired TTP	9
3. Congenital (hereditary) TTP	9
3.1. Pathophysiology of congenital (hereditary) TTP	9
4. Diagnosis	10
4.1. Signs and symptoms	10
4.2. Laboratory diagnosis for TTP	11
4.3. Other diagnostic tools and laboratory examinations	11
4.4. Predictive scores for TTP	11
4.5. Differential diagnosis of TTP and etiologies of acquired TTP.....	13
4.5.1. Drugs	13
4.5.2. Surgeries.....	13
4.5.3. Pregnancy.....	13
4.5.4. Malignancies	14
4.5.5. Autoimmune diseases	14
4.5.6. Infections	14
5. Treatment of TTP.....	15
5.1. Plasma therapy	15
5.2. Corticosteroids.....	15
5.3. Rituximab.....	15
5.4. Caplacizumab	16

5.5. Splenectomy	16
5.6. Recombinant ADAMTS13	16
5.7. Symptomatic treatment and supportive care	17
6. Prognosis of TTP	17
Hypothesis	19
Primary endpoint	20
Secondary endpoint	20
Material and methods	21
Statistical analysis	21
Results	22
1. Gender distribution and age at time of diagnosis of acquired TTP	22
1.1. Clinical presentations and laboratory values at an acute TTP episode in aTTP	23
1.2. Bleeding during an acute TTP episode in aTTP	25
1.3. Bleeding into different organs systems in acquired TTP patients with disease relapse	25
1.4. Thrombosis during an acute TTP episode of aTTP	25
1.5. Data about different etiological factors in acquired TTP patients	26
1.6. Therapy of acquired TTP patients	26
1.8. Treatment result and outcome in acquired TTP patients	26
2. Data analysis in patients with hereditary TTP	26
Discussion	27
Conclusion	30
Acknowledgments	31
References	32
Biography	41

Summary

Title: Retrospective analysis of patients with thrombotic thrombocytopenic purpura treated at the University Hospital Center Zagreb

Author: Kiarash Pour Modjib

Thrombotic thrombocytopenic purpura (TTP) is a microangiopathic hemolytic anemia with thrombocytopenia caused by low ADAMTS13. There is the acquired and the hereditary type. In the acquired type there is immune-mediated ADAMTS13 deficiency, caused by autoantibodies against ADAMTS13, and the hereditary TTP is caused by compound heterozygote or homozygote mutations in ADAMTS13 gene. The clinical picture of acute TTP presents with microangiopathic hemolytic anemia, thrombocytopenia, usually mild kidney impairment, neurological symptoms and sometimes fever. Since TTP is an emergency, which can end up in stroke, multiorgan failure and death, quick diagnosis and intervention is needed. In this work retrospective analysis of 10 patients with TTP who were followed up in the Hematology outpatient clinic of the University Hospital Center Zagreb from 2016-2022 was performed. Two patients had hereditary and 8 patients had acquired TTP.

This work confirmed already existing facts about the disease and presents results about age and gender distribution, clinical symptoms, laboratory parameters, etiological factors, treatment outcome and long – term sequelae in these patients.

Keywords: thrombotic thrombocytopenic purpura – microangiopathic hemolytic anemia – ADAMTS13 – thrombocytopenia

Sažetak

Naslov: Retrospektivna analiza bolesnika s trombotičnom trombocitopeničnom purpustom liječenim u KBC Zagreb

Autor: Kiarash Pour Modjib

Trombotična trombocitopenična purpura (TTP) je mikroangiopatska hemolitička anemija s trombocitopenijom uzrokovana niskim ADAMTS13. Postoji stečeni i nasljedni tip. U stečenom tipu postoji imunološki posredovani nedostatak ADAMTS13, uzrokovan autoantitijelima protiv ADAMTS13, a nasljedni TTP uzrokovan je složenim heterozigotnim ili homozigotnim mutacijama u genu ADAMTS13. Klinička slika akutne TTP manifestira se mikroangiopatskom hemolitičkom anemijom, trombocitopenijom, obično blagim oštećenjem bubrega, neurološkim simptomima i ponekad vrućicom. Budući da je TTP hitan slučaj, koji može završiti moždanim udarom, multiorganskim zatajenjem i smrću, potrebna je brza dijagnoza i intervencija.

U ovom radu provedena je retrospektivna analiza 10 bolesnika s TTP-om koji su praćeni u hematološkoj ambulanti KBC-a Zagreb od 2016.-2022. Dva bolesnika imala su nasljednu, a 8 bolesnika stečenu TTP.

Ovim radom potvrđene su već postojeće činjenice o bolesti te su prikazani rezultati o dobnoj i spolnoj distribuciji, kliničkim simptomima, laboratorijskim parametrima, etiološkim čimbenicima, ishodu liječenja i dugoročnim posljedicama u ovih bolesnika.

Ključne riječi: trombotična trombocitopenična purpura – mikroangiopatska hemolitička anemija – ADAMTS13 – trombocitopenija

Introduction

1. History of thrombotic thrombocytopenic purpura

Thrombotic thrombocytopenic purpura (TTP) was the first time described by Dr. Elli Moschkowitz, a Hungarian high school teacher and doctor working in the US, in 1925 in Beth Israel Hospital. First it was thought to be caused by a toxin. Moschkowitz's first patient was a 16 – year – old girl. She showed some bruises, had anemia, microscopic hematuria and disseminated thrombosis (1). In 1966 from 255 cases, 16 cases were reported to have a classical pentad of symptoms including thrombocytopenia, microangiopathic hemolytic anemia, neurologic symptoms, kidney failure and fever (2). Abnormal large multimers of von Willebrand Factor (VWF) were found in that disease in 1982 and in 1988 the deficient VWF-cleaving was discovered as the cause of TTP (3).

There are two types of TTP, the acquired (immune) TTP (aTTP) and the very rare congenital (hereditary) TTP (cTTP).

2. Acquired TTP

2.1. Pathophysiology of acquired TTP

ADAMTS13 is VWF-cleaving protease and stands for “a disintegrin and metalloproteinase with thrombospondin motif 13”. It consists of 1427 amino acids and a multidomain structure. Its gene is located on chromosome 9q34 near the ABO blood group locus. It is synthesized in the stellate cells of the liver, renal podocytes, platelets and endothelial cells (4). Plasma half-life of ADAMTS13 is 2 – 3 days (5). The main task of ADAMTS13 as a protease is to cleave ultra – large VWF multimers.

Since in aTTP the ADAMTS13 activity is reduced, due to antibodies against the protease, the formation of complexes of VWF multimers and platelets increases and leads to formation of microclots. The friction between erythrocytes and large VWF complexes creates shear stress on the erythrocytes and leads to hemolytic anemia and schistocyte formation. The spread of the microthrombi leads to occlusion of small vessels and organ ischemia, which usually occurs at an ADAMTS13 activity of less than 10%.

The immune reaction against ADAMTS13 is characterized by inhibitory and non – inhibitory antibodies. Bethesda – like assays can demonstrate the active inhibitors of ADAMTS13, but in

10 – 25% non – inhibitors are present, which hypothetically accelerate the clearance of ADAMTS13 (6 - 8).

The autoantibodies in immune acquired TTP are of IgG type, but there are also possibilities of IgM and IgA type (9, 10). In the group of IgG, the most common is the IgG₄ subclass followed by IgG₁, IgG₂ and IgG₃. High IgG₄ levels are associated with high risk of relapse. In a low percentage of cases the presence of IgG₁ and IgA in acute TTP is associated with a bad prognosis (11).

2.2. Epidemiology of acquired TTP

Acquired TTP is in general a rare disease. The incidence is 3 to 11 cases per million people and prevalence is 10 cases per million people. It is more common in women with a relation 2:1 to 3,5:1. Afro-American and Caribbean people are more affected (12).

In the United States and in Japan the main incidence age group is the fifties. In Europe the main age of incidence age group is the thirties (13).

3. Congenital (hereditary) TTP

The congenital (hereditary) type of TTP is even a rarer disease and mainly caused by compound heterozygote or homozygote mutations in ADAMTS13 gene (14). There are around 100 different mutation types. Missense mutations are the most common type, followed by nonsense, splice site mutations, insertions, point mutations and frameshift mutations on both alleles of ADAMTS13 gene on chromosome 9q34 and other ADAMTS13 domains decrease the amount or activity of the protease (15). Homozygous mutations are mainly found in families with consanguinity (16).

3.1. Pathophysiology of congenital (hereditary) TTP

In cTTP there is a complete lack of ADAMTS13, which leads to the formation of large VWF complexes in form of microthrombi and the shear stress leads to hemolytic anemia. In cTTP signs and symptoms may occur immediately after birth and some may remain asymptomatic until the second or third decade of life. This variability depends on the mutation of the

ADAMTS13. In newborns it presents itself with jaundice and thrombocytopenia, while in childhood it might be symptomless or have symptoms like infections. If cTTP should occur in adulthood the symptoms appear suddenly by a main trigger like pregnancy or an infection (17).

4. Diagnosis of TTP

4.1. Signs and symptoms of TTP

TTP has usually a sudden and acute onset of symptoms and can have a severe course. The mortality is high if untreated and even if treated there is significant mortality (18). In the past, it was postulated that there is a pentad of symptoms of TTP such as microangiopathic hemolytic anemia, thrombocytopenia, renal impairment, fever and neurological symptoms. But nowadays it is rare to have all 5 symptoms present at the beginning of disease. The most important signs and symptoms are microangiopathic hemolytic anemia with thrombocytopenia, usually mild renal impairment and neurological symptoms. Sometimes there is a prodrome of symptoms occurring before TTP onset, such as flu – like symptoms, fatigue, arthralgia, myalgia and abdominal or lumbar pain. Different neurological symptoms occur very often (19). Cardiac events like NSTEMI or STEMI, congestive heart failure, arrhythmias, cardiogenic shock and sudden cardiac arrest may also be part of the symptoms and disease manifestation. The elevated levels of troponin are accurate predictors of acute MI, death, recurrence of disease and treatment refractoriness (20). Digestive tract events include abdominal pain, nausea, vomiting and diarrhea.

4.2. Laboratory diagnosis of TTP

There is always a microangiopathic hemolytic anemia and thrombocytopenia present. Microangiopathic hemolytic anemia is characterized by low hemoglobin, high reticulocytes, high LDH, high unconjugated bilirubin and low haptoglobin (21). Peripheral blood smear shows typically schistocytes. Direct Coombs test is negative. Usually mild to moderate renal impairment is present as well. Standard coagulation tests are within normal range. Troponin is also used for estimation of heart involvement.

Clinical scores are rapid predictors for TTP, since ADAMTS13 activity measurement and immune assays take time to be available (22).

ADAMTS13 activity and autoantibodies provide the most accurate diagnosis. For the definite diagnosis of TTP the ADAMTS13 activity has to be below 10%, and aTTP should have also positive antibodies against ADAMTS13 (23).

4.3. Other diagnostic tools and laboratory examinations

If patient presents with signs and symptoms of stroke, a CT of head is immediately needed, eventually an angiography or MRI might be needed. Important is also for exclusion of differential diagnosis to measure complement factor C3, C4, CH50 and other complement factor activity. For exclusion of antiphospholipid syndrome anticardiolipin antibodies, lupus anticoagulans and anti – GPI β 2 has to be measured.

It is also important to exclude primary etiology, since the treatment of TTP includes treatment of the main disease if detected (24).

4.4. Predictive scores for TTP

Usually, it takes some time to analyze ADAMTS13 levels and to confirm definitely diagnosis of TTP, depending on laboratory availability. Acute TTP is a dangerous state, which needs prompt recognition and treatment. There are two main prediction scores used most common, namely the French and PLASMIC score (Table 1) (25, 26). The PLASMIC score includes conditions like cancer, transplant and DIC, while the French score excludes them. They both include platelet count below 30, and serum creatinine levels of < 2 ng/ml in the PLASMIC score and $< 2,25$ ng/ml in the French score. The PLASMIC score includes signs of hemolysis like indirect bilirubin levels higher than 2 mg/dl or reticulocyte $< 2,5$ % or no detectable haptoglobin. INR $> 1,5$ is included in PLASMIC score and not in French score. MCV more

than 90 fl is included in the PLASMIC score only (Table 1). So according to the French score 0 point has the probability of 2% having TTP, having 1 point has the probability of 70% and 2 points the probability of 94% with a TTP activity below 10%. In the Plasmic score 0 – 4 points have a probability of up to 4%, 5 points are 5 – 24% and 6 – 7 points are 62% and 82% (Table 1) (26 - 29).

Table 1: Different scores for TTP evaluation and prognostic outcome (According to: Chiasakul T et co. (2018)(29))

Components of the scores	PLASMIC score	French score
Platelet count	< 30 x 10 ⁹ /L: 1 point	< 30 x 10 ⁹ /L: 1 point
Creatinine levels	<2 ng/ml: 1 point	<2.26 ng/ml: 1 point
Parameters of hemolysis	Reticulocyte count >2.5% or Haptoglobin undetectable or Indirect bilirubin >2mg/dl: 1 point	----
Associated conditions	No active cancer: 1 point No history of solid – organ or hematopoietic stem cell transplant: 1 point	----
MCV	<90 fl: 1 point	----
INR	< 1,5: 1 point	----
ANA	----	Positive: 1 point
D – Dimer	----	----
Prognostic risk, severity score	PLASMIC score	French score
Mild	0– 4	0
Intermediate	5	1
Severe	6– 7	2– 3

4.5. Differential diagnosis of TTP and etiologies of acquired TTP

Sometimes symptoms and signs of TTP are similar to other diseases such as other microangiopathic hemolytic anemias (MAHA), typical and atypical HUS.

In typical HUS, Shiga – like toxin is produced by enterohemorrhagic bacteria like *E. coli* (30). The disease is initiated with a prodrome of diarrhea followed by MAHA, thrombocytopenia and severe renal insufficiency. The patients have usually normal or just slightly lower ADAMTS13 levels (31).

Atypical HUS is linked to abnormal activation of the alternative complement pathway. This might be caused by genetical mutations in several complement factors (32).

Further differential diagnosis are diseases or conditions like pregnancy associated MAHA, eclampsia, preeclampsia, DIC, cancers, infections, drug intake, Evans syndrome etc., which mimic TTP. DIC usually presents with low fibrinogen, high D-dimers, prolonged PT, prolonged PTT, and low ATIII (33). There might be an overlap between TTP and HUS, which needs multidisciplinary approach between hematologists and nephrologists (34).

4.5.1. Drugs

Drugs like mitomycin, cyclosporine A, cisplatin, bleomycin, quinines, ticlopidine, clopidogrel, pentostatin, oxymorphone, tacrolimus, sulfonamides, estrogen, imatinib and HRT might cause thrombotic MAHA and even aTTP (35). In ticlopidine, an antiplatelet drug from the thienopyridine family, after 2 – 4 weeks of use, autoantibodies against ADAMTS13 can be proven and lead to severe ADAMTS13 deficiency. But the newer generations of drugs like clopidogrel or prasugrel do not have high incidences of TTP (36).

4.5.2. Surgeries

Cardiac and orthopedic surgeries and invasive procedures such as PCI and hematopoietic stem cell transplantation may cause thrombotic MAHA and even aTTP (37 - 39).

4.5.3. Pregnancy

TTP occurs rarely in pregnancy and manifests usually in the last trimester. It rarely occurs in the first trimester (40). The association between pregnancy and TTP is due to hemostatic and immunological changes in pregnancy. MAHA with thrombocytopenia during pregnancy may be present in eclampsia, HELLP syndrome (Hemolysis, Elevated Liver enzymes and Low

platelets) or preeclampsia and may be confused with TTP. TMA like HUS would have another pathophysiological mechanism but has similarities in symptoms. TTP may be also a trigger for eclampsia, HELLP syndrome, or preeclampsia (41 - 43).

4.5.4. Malignancies

TMA in patients with malignancies is mostly associated with mucin producing adenocarcinomas and further with disseminating cancers and tumors invading the bone marrow. Most commonly, thus in 26,2 % of the cases, TMA is associated with gastric cancer followed by breast, prostate and lung cancer. It may also occur in further cancer types of the gastrointestinal, hepatobiliary and genitourinary tract. Endocrine and hematological malignancies can cause TMA. In cancer it is important to exclude differential diagnosis like TMA and DIC (44).

4.5.5. Autoimmune disorders

Autoimmune diseases are often observed in patients with immune (acquired) TTP (45). Autoimmune diseases like SLE can cause TTP. Patients with SLE and rheumatoid arthritis might show severe ADAMTS13 deficiency with non – inhibitory anti – ADAMTS13 antibodies (46). Autoantibodies targeted against ADAMTS decrease the activity of the cleaving proteases (47). An association between Graves` disease and TTP also exists and must be detected and treated immediately due to high fatality (48). Patients with other connective tissue disorders like systemic sclerosis and rheumatoid arthritis also can develop TTP (49).

4.5.6. Infections

HIV infection is still the most common reason for aTTP in Africa. In Europe with the introduction of antiretroviral therapy the incidence decreased (50). The outcome in patients who developed TTP secondary to infection is better than those who developed it unrelated to HIV infection. There are reports of E. coli and TTP, but infections with E. coli led more to HUS (51). There are also a few reports about patients with COVID – 19, who developed aTTP (52, 53).

5. Treatment of TTP

The treatment approach for congenital and acquired TTP is different.

5.1. Plasma therapy

Plasma treatment is used for both types of TTP, the congenital and acquired type. Therapeutic plasma exchange (PEX) with corticosteroids remains the current first line treatment option for aTTP. Therapeutic plasma exchange helps to replenish ADAMTS13 activity, remove autoantibodies against it, removing immune complexes and VWF multimers and to replace normal VWF. Therapeutic plasma exchange is continued until platelet count has normalized, hemolysis has ceased and no other organ dysfunction has occurred. Usually 10 – 20 ml/kg up to 60 – 80 ml/kg of fresh frozen plasma are used. Around 1,5-fold of the plasma is exchanged (54).

In cTTP periodical plasma infusions are usually sufficient to prevent acute episodes, but sometimes PEX is needed as well. For prevention of acute episodes in cTTP for the period of 2 -3 weeks a plasma infusion with 10 – 15 ml/kg up to 20 – 40 ml/kg is given. In refractory cases it can be used up to twice daily (55).

5.2. Corticosteroids

Since in the aTTP there is the built up of autoantibodies, the use of corticosteroids together with PEX is mandatory. Usually prednisone dose of 1 – 2 mg/kg/day (or equivalent steroid dose) is used (56).

5.3. Rituximab

Rituximab is an anti – CD20 humanized antibody. It was introduced in patients with aTTP with disease exacerbation and relapses, which means recurrence of thrombocytopenia during a period of therapeutic plasma exchange or in 30 days after stopping PEX. It may be also indicated for patients who have remission but still very low ADAMTS13 levels or in later relapses. The usual dose is 375 mg/m² weekly 4 weeks in a row, but low dose rituximab 100 mg weekly, for 4 weeks could be sufficient as well (57). There are also other different schemes of administrations of rituximab in aTTP. This therapy has the purpose to inhibit anti – ADAMTS13 antibody production (58). Many studies proved that the use of rituximab led to

decreased and delayed relapses (59). It is recommended in some studies that rituximab might be used as the first line of treatment together with PEX and steroids (60). One of the main side effects is secondary hypogammaglobulinemia, which can be corrected if needed by IVIG (61), and nowadays there are also concerns of possibility of worse COVID-19 outcome after administration of rituximab (62).

5.4. Caplacizumab

Caplacizumab is the first drug approved for treatment of aTTP together with PEX and immunosuppression in adults and children older than 12 years and weight at least 40 kg. It is a nanobody which targets the A1 domain on VWF and prevents the interaction between thrombocytes and VWF. In many studies caplacizumab proved to shorten the recovery time of platelets, with a mean time of 3 days and faster normalization of ischemia parameters (63). Exacerbations were also reduced according to studies. The drug also proved to decrease the microthrombi and ischemic incidences (64). The usual dose is 10mg/kg s.c. injection, which is received after first dose of 10 mg i.v. caplacizumab, that is administered before the start of plasma exchange (65). Since caplacizumab may cause bleeding, patients using anticoagulants should be aware about the risk of bleeding using both drugs concomitantly.

5.5. Splenectomy

For some refractory cases of aTTP splenectomy might be considered. Before splenectomy pneumococcal and meningococcal vaccinations are mandatory (66).

5.6. Recombinant ADAMTS13

Recombinant ADAMTS13 (rADAMTS13) is still in clinical trials but it might be a potential future treatment option (67). In cTTP the main missing component is ADAMTS13, so that a replacement option might be the recombinant form of ADAMTS13. The enzyme has a half-life of 53h. The usual activity dose used are 20 – 40 U/kg every 2 to 4 weeks (68). The recombinant protease in clinical trials proved not to have severe adverse effects and to be tolerated well by patients. The result of using rADAMTS13 is an increase in platelet count and decrease in VWF multimers (69). There is research going on about the use of rADAMTS13 in aTTP as well (70).

5.7. Symptomatic treatment and supportive care

Most patients in the acute setting of TTP are treated in the ICU department, and besides standard therapy also supportive therapy is important. Sometimes mechanical ventilation is needed (71). If hemoglobin should be below 70 g/L and in cardiac patients below 90 g/L RBC concentrates are used. Platelet transfusions should be restricted (72, 73). In severe kidney failure renal replacement therapy with hemodialysis and electrolyte replacement with infusions must be initiated. (74, 75).

6. Prognosis of TTP

Mortality is around 10 – 20% of acute TTP, in spite of treatment (76). Many patients complain about concentration difficulties and endurance problems after surviving acute TTP, caused probably by post-traumatic stress disorder (PTSD). Patients should be followed up for cardiovascular and cerebrovascular diseases, autoimmune disorders and PTSD (77).

TTP is a rare disease and real - world data about such complex and life – threatening condition are always important. In this work a retrospective analysis of TTP patients followed-up from 2016 to 2022 in the Hematology outpatient clinic of the University Hospital Center Zagreb was performed to assess their treatment outcome.

Hypothesis

Hypothesis of this retrospective analysis of TTP patients followed-up from 2016 to 2022 in the Hematology outpatient clinic of the University Hospital Center Zagreb is that their treatment outcome will not differ comparing to literature outcome.

Primary endpoint

The primary endpoint of this work is analysis of the long-term outcome of TTP patients who are followed up in the Hematology outpatient clinic of the University Hospital Center Zagreb.

Secondary endpoints

Secondary endpoints of this work are as follows:

- 1) analysis of laboratory parameters, signs and symptoms at the time of diagnosis of acute aTTP episode
- 2) analysis of treatment administration during acute aTTP episode
- 3) analysis of time to reach remission and time between remission and possible relapse
- 4) separate analysis of patients with cTTP.

Materials and Methods

Data of TTP patients (8 with aTTP and 2 with cTTP) followed up in the Hematology outpatient clinic of the University Hospital Center Zagreb from 2016 to 2022 were retrospectively analyzed. The data were obtained from patients' hospital records.

These data include sex, age at diagnosis of TTP, type of TTP, the presence of microangiopathic hemolytic anemia, thrombocytopenia, kidney failure, fever and neurological symptoms during episode of acute TTP. Laboratory parameters such as hemoglobin, platelets, creatinine, lactate dehydrogenase (LDH), ADAMTS13 activity and anti – ADAMTS13 antibodies were also collected. Further data consisted of presence of skin bleeding, genitourinary tract bleeding, CNS bleeding, GI bleeding, epistaxis and lung bleeding occurring the first time and in cases of relapse. Thrombosis in different organ systems were also analyzed, as well as comorbidities like autoimmune diseases, cancer, HIV, pregnancy and other diseases. Further therapy options were analyzed, such as plasmapheresis, fresh frozen plasma, corticosteroids, rituximab, and caplacizumab.

Further analysis was outcome of disease: remission or relapse, the time between remission and relapse and the time to reach remission. Long-term sequelae of TTP were also assessed.

Patients with hereditary TTP were analyzed separately.

Laboratory referral values were according to the laboratory in the University Hospital Center Zagreb as following:

Hemoglobin	119 – 157 g/L
Lactate dehydrogenase (LDH)	<241 IU/L
Thrombocytes.....	158 – 424 x10 ⁹ /L
Creatinine.....	49 – 90 μmol/L
ADAMTS13 activity.....	0,60 – 1,21 kIU/L

Statistical analysis

For descriptive analysis number (N) and percentage, minimal, maximal values and median values were used. Excel was used as the main tool for calculation.

Results

1. Gender distribution and age at time of diagnosis of acquired TTP

Among 8 patients with aTTP, 5 were female (62,5%) and 3 were male (37,5%). The median age at time of diagnosis was 39 years. The youngest patient at the onset of aTTP had 15 years and the oldest 56 years. As can be seen in Figure 1, most of the patients were in age group 30 – 40 years, and in the age group 40 – 50 years.

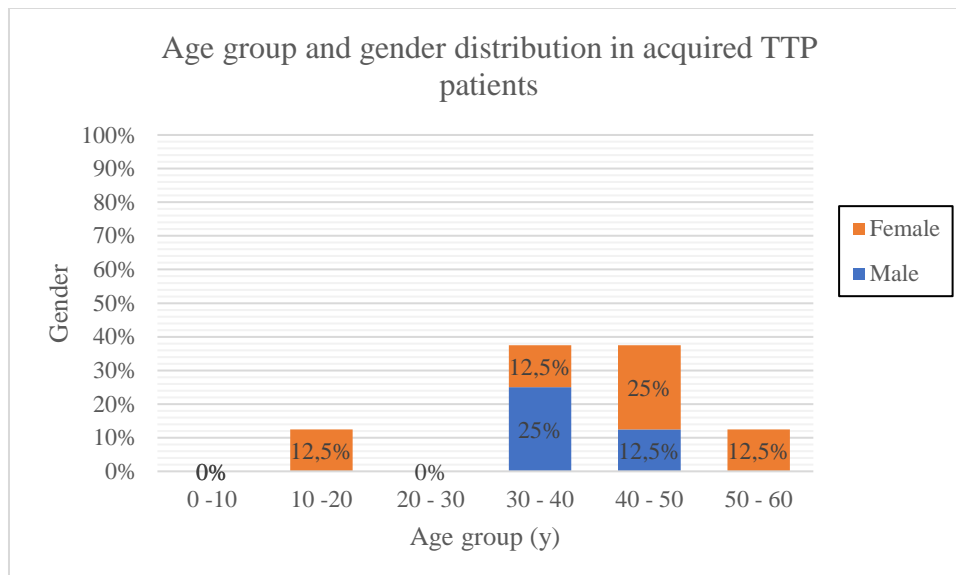


Figure 1: Age group and gender distribution in acquired TTP patients, TTP= thrombotic thrombocytopenic purpura

1.1. Clinical presentations and laboratory values at an acute TTP episode in aTTP

In the Figure 2, clinical presentations and laboratory values at an acute TTP episode were described.

Microangiopathic hemolytic anemia and thrombocytopenia were present in all aTTP patients (N = 8).

Kidney failure was present in 3 patients, and fever in 1 patient.

Neurological symptoms like headache and motoric dysphasia were present in 6 patients.

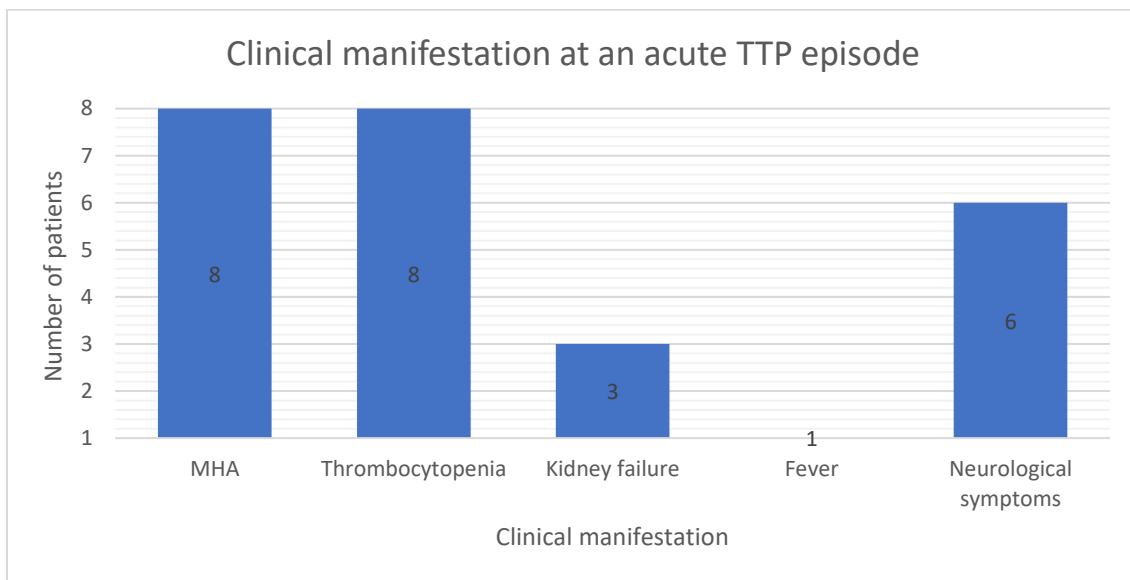


Figure 2: Clinical symptoms of aTTP patients at an acute TTP episode, MHA = microangiopathic hemolytic anemia

The table below (Table 2) shows laboratory values at the onset of acute aTTP. The median hemoglobin value was 89 (60-107) g/L. The median platelet count was 41 (12-101) $\times 10^9/L$. The median LDH levels were 587,5 (283-2557) IU/L. The median creatinine levels were 82,5 (51 – 123) $\mu\text{mol/L}$. The median ADAMTS13 levels at first manifestation of diseases were $< 0,1$ kIU/L.

Table 2: Laboratory values in aTTP patients at an acute TTP episode

Patient Number	Hb (g/L)	Platelets ($\times 10^9/L$)	LDH (IU/L)	Creatinine ($\mu\text{mol/L}$)	ADAMTS13 activity (kIU/L)
1	unknown	unknown	unknown	unknown	0,1
2	60	101	283	67	$< 0,1$
3	unknown	unknown	unknown	unknown	unknown
4	107	12	2557	51	0
5	86	101	423	71	$< 0,1$
6	75	22	1261	94	unknown
7	96	64	311	123	$< 0,1$
8	92	26	752	109	$< 0,1$

LDH = lactate dehydrogenase, Hb = hemoglobin

1.2. Bleeding during an acute TTP episode in aTTP

In Figure 3 bleeding to different organ sites in aTTP patients at an acute TTP episode is illustrated. Bleeding occurred in 6 patients. The most common bleeding site was the CNS, which occurred in 4 patients. In 2 patients CNS bleeding was severe and in other 2 patients CNS bleeding was minimal. 1 patient had genitourinary tract bleeding. One of the patients, who had CNS bleeding also had genitourinary bleeding. 1 patient had skin bleeding.

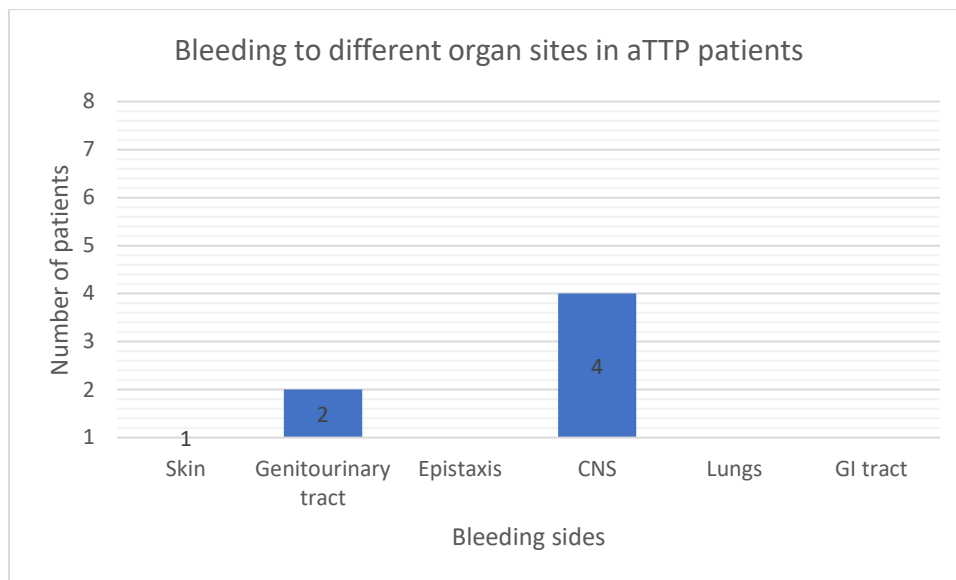


Figure 3: Bleeding to different organ sites in aTTP patients at an acute TTP episode, CNS = central nervous system, GI = gastrointestinal

1.3. Bleeding into different organs systems in acquired TTP patients with disease relapse

In general, 3 patients relapsed. The patient who developed epistaxis in disease relapse, had also CNS bleeding and GI bleeding.

1.4. Thrombosis during an acute TTP episode of aTTP

During the acute TTP episode 2 patients developed thrombosis. 1 patient with disease relapse developed deep vein thrombosis in the acute TTP episode, and another patient developed in the acute TTP episode thrombosis of cerebral arteries and consequently stroke. Later in remission the patient, who developed deep vein thrombosis in disease relapse, developed emboli of the cerebral arteries and consequently stroke.

1.5. Data about different etiological factors in acquired TTP patients

One patient had cervical cancer at diagnosis of aTTP. Another patient had a COVID – 19 infection at the time of an acute TTP episode. Other etiological factors were not confirmed.

1.6. Therapy of acquired TTP patients

All patients (N = 8) received PEX and corticosteroids as the first line therapy.

Rituximab was received by 6 patients. In 3 patients it was received as the first –line treatment and in 2 further patients it was received as the second – line treatment and one patient received it preemptively.

2 patients received caplacizumab together with PEX and corticosteroids as first – line treatment, one of them received it in another institution outside of Croatia, during the acute TTP episode. In disease relapse patients received PEX, corticosteroids and rituximab.

1.7. Treatment result and outcome in acquired TTP patients

The median time to reach remission after an acute aTTP episode was 17 days. The longest time needed to reach remission was 30 days and the shortest time was 5 days. 3 patients relapsed; 1 patient relapsed 5 times, 1 patient relapsed 3 times and 1 patient relapsed 1 time. The median time to relapse after remission was 1.5 (1-66) months. The median time to reach remission again after relapse was 8 (4-25) days. 7 patients are alive and come to follow – ups regularly, and one patient is lost to follow-up. All patients, who were followed up till the year 2022 are in remission. 6 patients have long term sequelae. 3 patients have kidney impairment and 3 patients have neurological symptoms such as psycho - organic syndrome, motoric dysphasia and mild cognitive impairment.

2. Data analysis in patients with hereditary TTP

One female and 1 male patient had hereditary TTP. Both were diagnosed in their infancy, receiving FFP prophylaxis. The female patient received PEX and corticosteroids during exacerbation of acute TTP and has mild renal impairment. She had 2 successful pregnancies.

Discussion

This real – world data retrospective analysis of TTP patients followed-up at the University Hospital Center Zagreb showed similar characteristics and outcome comparing to the literature. Female were more than 60% of all TTP patient in our work. The female to male ratio in our work was 1,5:1, which resembles the epidemiological ratio (78).

The peak incidences are in the age groups 30 – 40 years and 40 – 50 years. The median age at time of diagnosis is 39 years. According to other epidemiological data the median age is 40 years of age, which is almost similar to our data (79).

The most common clinical laboratory manifestations at diagnosis of acute TTP episode were microangiopathic hemolytic anemia and thrombocytopenia. Anemia presents usually with fatigue and dyspnea and thrombocytopenia may present depending on the level of thrombocytes with purpura (80, 81). All patients in our work had a low hemoglobin and thrombocytopenia at the onset of acute TTP.

Six patients (75%) presented with neurological symptoms, with an equal distribution among genders. According to the Oklahoma registry of diseases only 10% of patients present with fever and neurological symptoms are reported to be the most prevalent symptoms in aTTP patients (82), although abdominal symptoms also occur frequently (83).

Fever occurred in one TTP patient in this work. In 3 aTTP patients kidney failure occurred at an acute onset of TTP in our study. According to Stanley M. et co. the kidney is with the CNS the most affected organ in TTP (84). According to data from Bloombery P., Kivivali L. et co. 46% of patients report bleeding symptoms (85). In our case bleeding occurred in 75%. The LDH levels were elevated in all the patients as a sign of hemolysis and end – organ damage. Chiasakul T. and Cuker A. integrated in their studies TTP registries of different countries in different continents, like the French registry, United Kingdom TTP registry, Oklahoma registry, Harvard TMA registry, Australian TMA/TTP registry and Japanese registry, which contained and compared collected data about frequencies of clinical pictures, long – term outcomes and mean laboratory results (86). The median LDH levels in our data are 587,5 IU/L. The median LDH is in their data 1107 – 1750 IU/L much higher than in ours. The median platelet count in our study is $41 \times 10^9/L$ and in their study $10 – 17 \times 10^9/L$, which is much more in ours. The median creatinine value in our study was 82,5 $\mu\text{mol/L}$, while in their it is 96 – 142 $\mu\text{mol/L}$, which is higher than ours (86). The data deviation is probably due to the small number of patients in our data. In an article Crowley J. et. co. claimed that there is a correlation between disease outcome and hemoglobin as LDH levels (87). All the patients in our study had very

severe ADAMTS13 deficiency, i.e. ADAMTS13 activity < 1%. The clinical symptoms and the laboratory values correlated.

According to Figure 3, six patients in our work had bleeding at time of an acute TTP episode. The organ sites which were involved were the skin, genitourinary tract and the CNS. In CNS 4 patients bled. According to Oklahoma registry bleeding occurs in 54% of the cases (88).

According to our data thrombosis at an acute TTP episode occurred in the male patient, who had 5 relapses. He had a DVT and developed also hemorrhagic stroke with severe CNS bleeding. The female patient had cerebral artery thrombosis.

According to the etiology of the aTTP patients one patient had cervical cancer and the other a SARS - CoV2 infection.

There are associations between cancer and TTP in general and between cervical cancer and TTP (89). There are several reports about SARS - CoV2 infection and TTP (90).

According to our data about treatment options, all patients received plasmapheresis and corticosteroids.

75% of the patients received rituximab, as second – line and preemptive use. 3 patients received rituximab as first – line treatment and 2 received it for second – line treatment and 1 patient received it preemptively. Patients received rituximab (375mg/m²) once a week for 4 weeks, as a 1st and 2nd line treatment and just once as preemptive treatment. The study of Westwood et. co. proved primarily that the use of rituximab prevents relapse of disease and that low dose of 200mg rituximab has higher re – treatment rates than usual dose of 375mg/m² rituximab (91). None of our patients received lower dose than standard dose of 375 mg/m². The number of relapses and needs for re-treatment with rituximab was in general low.

Caplacizumab was used as the first line treatment together with PEX and steroids in two patients, to reduce exacerbation and shorten acute phase (92). One patient received caplacizumab in University Hospital Center Zagreb and another patient received it outside of Croatia.

From all aTTP patients (N =8), 3 patients (37,5%) relapsed. According to Abou – Ismail MY et. co. around 30 – 50% of patients relapse after reaching initial remission (93), which means that the number of our patients is in that range. Also, the prospective cohort study by Vesely SK et. co. proved that relapse occurs in 30 – 50% of patients (94). According to our data the median time to relapse after remission is 1,5 months, in the prospective study the median is 3,7 months, which means more than the double of our study (94).

6 of our patients developed long – term sequelae from TTP. In 3 of our patients long – term sequelae are kidney impairment and in other 3 patients long – term consequences are

neurological symptoms such as psycho - organic syndrome, motoric dysphasia and minor cognitive impairment. In the article of George JN, who also took into count the Oklahoma registry, in which the major long – term consequence is depression, followed by cognitive impairment and autoimmune diseases like SLE (95). According to his article the most common long – term disease after recovery of an acute TTP episode are depressions, which occur in 44% of their patients and only 8% of those tested for cognitive impairment had mild cognitive impairment, which is much more than in our patients. Most of their patients had neurological and psychiatric issues. Kidney failure occurred only in 21% of their patients, which is less than in our patients (95).

The usual mortality rate after an acute TTP episodes is 10 – 20% (96).

This study had some limitations since it was a retrospective analysis, some data were missing and the number of patients was low.

Despite all those limitations our real – world data study from tertial hospital center showed comparable results to other literature (97 - 99).

Conclusion

Thrombotic thrombocytopenic purpura is a rare disease, but when it develops it is an acute situation and needs fast intervention. There are two types of TTP, the acquired and hereditary type. In the acquired type autoantibodies against a protease named ADAMTS13 reduce its activity and in the hereditary type there is a complete absence of ADAMTS13. The clinical manifestations are microangiopathic hemolytic anemia, thrombocytopenia, kidney failure, neurological symptoms and fever. Further complications are bleeding and thrombosis in different organ sites. The etiology for the acquired type is mostly unknown, but infections, malignancies, pregnancy, autoimmune diseases etc. are known to be causative factors. Treatment options for aTTP are plasmapheresis, glucocorticoids, rituximab and caplacizumab. In patients with hereditary TTP usually plasma infusion is used as main treatment. The retrospective analysis of our work showed comparable results and outcomes of TTP patients treated at the University Hospital Center comparing to the literature data.

Acknowledgments

I would like to thank Prof. Pulanić for mentoring me during the time of my medical studies and motivated me to keep my interest in hematology and accepted to be my mentor for the thesis and for his comments and feedback on my performance.

My especial appreciation is for my beloved mother Mahnaz, who supported me financially and mentally and always stood beside me in hard times of my life. I would like to thank my beloved family also for the mental support as my friends, who always stood beside me.

Prof. Mirijana Kalauz, Prof. Tomislav Jukic, Prof. Ernest Bilic, Dr. Zrinko Salek and Dr. Ivan Durlen I would also like to thank for mentoring me during my scientific publications.

I would like to thank Dr. med. univ. Reza Malayeri, hematologist and oncologist in Iran and my dear friend and colleague Mr. Mohsen Ebadollahi Novin, future dentist, for rereading my thesis and correcting my grammatical and spelling mistakes, since English is not my mother tongue.

Further I would like to thank my mentor Dr. med. Thamer Sliwa for mentoring me during my clinical rotations in the department of hematology and oncology in Hanusch hospital.

I would also like to thank the Medical School University of Zagreb for the chance to fulfill my goal to become a medical doctor.

References

- (1) Moschcowitz E. An acute febrile pleiochromic anemia with hyaline thrombosis of the terminal arterioles and capillaries; an undescribed disease. *Am J Med.* 1952;13(5):567-569.
- (2) Amorosi EL, Ultmann JE. Thrombotic thrombocytopenic purpura. *Medicine.* 1966;45(2):139-160.
- (3) Rock GA, Shumak KH, Buskard NA, et al. Comparison of plasma exchange with plasma infusion in the treatment of thrombotic thrombocytopenic purpura. Canadian Apheresis Study Group. *N Engl J Med.* 1991;325(6):393-397.
- (4) Zhou W, Inada M, Lee TP, et al. ADAMTS13 is expressed in hepatic stellate cells. *Lab Invest.* 2005;85(6):780-788.
- (5) Furlan M, Robles R, Morselli B, Sandoz P, Lämmle B. Recovery and half-life of von Willebrand factor-cleaving protease after plasma therapy in patients with thrombotic thrombocytopenic purpura. *Thromb Haemost.* 1999;81(1):8-13.
- (6) Thomas MR, de Groot R, Scully MA, Crawley JT. Pathogenicity of Anti-ADAMTS13 Autoantibodies in Acquired Thrombotic Thrombocytopenic Purpura. *EBioMedicine.* 2015;2(8):942-952.
- (7) Feys HB, Liu F, Dong N, et al. ADAMTS-13 plasma level determination uncovers antigen absence in acquired thrombotic thrombocytopenic purpura and ethnic differences. *J Thromb Haemost.* 2006;4(5):955-962.
- (8) Liu L, Choi H, Bernardo A, et al. Platelet-derived VWF-cleaving metalloprotease ADAMTS-13. *J Thromb Haemost.* 2005;3(11):2536-2544.
- (9) Ferrari S, Mudde GC, Rieger M, Veyradier A, Kremer Hovinga JA, Scheiflinger F. IgG subclass distribution of anti-ADAMTS13 antibodies in patients with acquired thrombotic thrombocytopenic purpura. *J Thromb Haemost.* 2009;7(10):1703-1710.
- (10) Pos W, Sorvillo N, Fijnheer R, et al. Residues Arg568 and Phe592 contribute to an antigenic surface for anti-ADAMTS13 antibodies in the spacer domain. *Haematologica.* 2011;96(11):1670-1677.
- (11) Ferrari S, Scheiflinger F, Rieger M, et al. Prognostic value of anti-ADAMTS 13 antibody features (Ig isotype, titer, and inhibitory effect) in a cohort of 35 adult French patients

undergoing a first episode of thrombotic microangiopathy with undetectable ADAMTS 13 activity. *Blood*. 2007;109(7):2815-2822.

(12) Martino S, Jamme M, Deligny C, et al. Thrombotic Thrombocytopenic Purpura in Black People: Impact of Ethnicity on Survival and Genetic Risk Factors. *PLoS One*. 2016;11(7):e0156679.

(13) Yagi H, Matsumoto M, Fujimura Y. Paradigm shift of childhood thrombotic thrombocytopenic purpura with severe ADAMTS13 deficiency. *Presse Med*. 2012;41(3 Pt 2):e137-e155.

(14) Lotta LA, Wu HM, Mackie IJ, et al. Residual plasmatic activity of ADAMTS13 is correlated with phenotype severity in congenital thrombotic thrombocytopenic purpura. *Blood*. 2012;120(2):440-448.

(15) Levy GG, Nichols WC, Lian EC, et al. Mutations in a member of the ADAMTS gene family cause thrombotic thrombocytopenic purpura. *Nature*. 2001;413(6855):488-494.

(16) Schneppenheim R, Budde U, Oyen F, et al. von Willebrand factor cleaving protease and ADAMTS13 mutations in childhood TTP. *Blood*. 2003;101(5):1845-1850.

(17) Scully M, Knöbl P, Kentouche K, et al. Recombinant ADAMTS-13: first-in-human pharmacokinetics and safety in congenital thrombotic thrombocytopenic purpura. *Blood*. 2017;130(19):2055-2063.

(18) Veyradier A, Meyer D. Thrombotic thrombocytopenic purpura and its diagnosis. *J Thromb Haemost*. 2005;3(11):2420-2427.

(19) Shatzel JJ, Taylor JA. Syndromes of Thrombotic Microangiopathy. *Med Clin North Am*. 2017;101(2):395-415.

(20) Benhamou Y, Boelle PY, Baudin B, et al. Cardiac troponin-I on diagnosis predicts early death and refractoriness in acquired thrombotic thrombocytopenic purpura. Experience of the French Thrombotic Microangiopathies Reference Center. *J Thromb Haemost*. 2015;13(2):293-302.

(21) Sukumar S, Lämmle B, Cataland SR. Thrombotic Thrombocytopenic Purpura: Pathophysiology, Diagnosis, and Management. *J Clin Med*. 2021;10(3):536.

- (22) Alwan F, Vendramin C, Vanhoorelbeke K, et al. Presenting ADAMTS13 antibody and antigen levels predict prognosis in immune-mediated thrombotic thrombocytopenic purpura. *Blood*. 2017;130(4):466-471.
- (23) Jamwal M, Sharma P, Das R. Laboratory Approach to Hemolytic Anemia. *Indian J Pediatr*. 2020;87(1):66-74.
- (24) Chapman K, Seldon M, Richards R. Thrombotic microangiopathies, thrombotic thrombocytopenic purpura, and ADAMTS-13. *Semin Thromb Hemost*. 2012;38(1):47-54.
- (25) Coppo P, Schwarzinger M, Buffet M, et al. Predictive features of severe acquired ADAMTS13 deficiency in idiopathic thrombotic microangiopathies: the French TMA reference center experience. *PLoS One*. 2010;5(4):e10208.
- (26) Bendapudi PK, Hurwitz S, Fry A, et al. Derivation and external validation of the PLASMIC score for rapid assessment of adults with thrombotic microangiopathies: a cohort study. *Lancet Haematol*. 2017;4(4):e157-e164.
- (27) Benhamou Y, Assié C, Boelle PY, et al. Development and validation of a predictive model for death in acquired severe ADAMTS13 deficiency-associated idiopathic thrombotic thrombocytopenic purpura: the French TMA Reference Center experience. *Haematologica*. 2012;97(8):1181-1186.
- (28) Dutt T, Scully M. A proposal: the need for thrombotic thrombocytopenic purpura Specialist Centres--providing better outcomes. *Br J Haematol*. 2015;170(5):737-742.
- (29) Chiasakul T, Cuker A. Clinical and laboratory diagnosis of TTP: an integrated approach. *Hematology Am Soc Hematol Educ Program*. 2018;2018(1):530-538.
- (30) Tsai HM, Chandler WL, Sarode R, et al. von Willebrand factor and von Willebrand factor-cleaving metalloprotease activity in Escherichia coli O157:H7-associated hemolytic uremic syndrome. *Pediatr Res*. 2001;49(5):653-659.
- (31) Dundas S, Todd WT, Stewart AI, Murdoch PS, Chaudhuri AK, Hutchinson SJ. The central Scotland Escherichia coli O157:H7 outbreak: risk factors for the hemolytic uremic syndrome and death among hospitalized patients. *Clin Infect Dis*. 2001;33(7):923-931.
- (32) Noris M, Remuzzi G. Atypical hemolytic-uremic syndrome. *N Engl J Med*. 2009;361(17):1676-1687.

- (33) Papageorgiou C, Jourdi G, Adjambri E, et al. Disseminated Intravascular Coagulation: An Update on Pathogenesis, Diagnosis, and Therapeutic Strategies. *Clin Appl Thromb Hemost*. 2018;24(9_suppl):8S-28S.
- (34) Conlon PJ, Howell DN, Macik G, Kovalik EC, Smith SR. The renal manifestations and outcome of thrombotic thrombocytopenic purpura/hemolytic uremic syndrome in adults. *Nephrol Dial Transplant*. 1995;10(7):1189-1193.
- (35) Medina PJ, Sipols JM, George JN. Drug-associated thrombotic thrombocytopenic purpura-hemolytic uremic syndrome. *Curr Opin Hematol*. 2001;8(5):286-293.
- (36) Jacob S, Dunn BL, Qureshi ZP, et al. Ticlopidine-, clopidogrel-, and prasugrel-associated thrombotic thrombocytopenic purpura: a 20-year review from the Southern Network on Adverse Reactions (SONAR). *Semin Thromb Hemost*. 2012;38(8):845-853.
- (37) Iosifidis MI, Ntavlis M, Giannoulis I, Malioufas L, Ioannou A, Giantsis G. Acute thrombotic thrombocytopenic purpura following orthopedic surgery: a case report. *Arch Orthop Trauma Surg*. 2006;126(5):335-338.
- (38) Tordon B, Warkentin TE, Moore JC, Arnold DM. Post-cardiac surgery thrombotic thrombocytopenic purpura: presence of anti-ADAMTS13 autoantibodies at preoperative baseline. *Platelets*. 2022;33(3):479-483.
- (39) Lee JM, Hur SH, Nam CW, et al. Thrombotic thrombocytopenic purpura after percutaneous coronary intervention. *Korean J Intern Med*. 2006;21(2):120-122.
- (40) Sikka P, Chopra S, Aggarwal N, Suri V, Chandrasekaran A. Thrombotic thrombocytopenic purpura in the first trimester of pregnancy. *Asian J Transfus Sci*. 2013;7(1):79-80.
- (41) Ferrari B, Peyvandi F. How I treat thrombotic thrombocytopenic purpura in pregnancy. *Blood* 2020; 136 (19): 2125–2132.
- (42) Moatti-Cohen M, Garrec C, Wolf M, et al. Unexpected frequency of Upshaw-Schulman syndrome in pregnancy-onset thrombotic thrombocytopenic purpura. *Blood*. 2012;119(24):5888-5897.
- (43) Ramadan MK, Badr DA, Hubeish M, Itani S, Hijazi H, Mogharbil A. HELLP Syndrome, Thrombotic Thrombocytopenic Purpura or Both: Appraising the Complex Association and Proposing a Stepwise Practical Plan for Differential Diagnosis. *J Hematol*. 2018;7(1):32-37.

- (44) Govind Babu K, Bhat GR. Cancer-associated thrombotic microangiopathy. *Ecancermedalscience*. 2016;10:649.
- (45) Kremer Hovinga JA, Vesely SK, Terrell DR, Lämmle B, George JN. Survival and relapse in patients with thrombotic thrombocytopenic purpura. *Blood*. 2010;115(8):1500-1662.
- (46) Rieger M, Mannucci PM, Kremer Hovinga JA, et al. ADAMTS13 autoantibodies in patients with thrombotic microangiopathies and other immunomediated diseases. *Blood*. 2005;106(4):1262-1267.
- (47) Yamada R, Nozawa K, Yoshimine T, et al. A Case of Thrombotic Thrombocytopenia Purpura Associated with Systemic Lupus Erythematosus: Diagnostic Utility of ADAMTS-13 Activity. *Autoimmune Dis*. 2011;2011:483642.
- (48) Chitnis SD, Mene-Afejuku TO, Aujla A, et al. Thrombotic thrombocytopenic purpura possibly triggered by Graves' disease. *Oxf Med Case Reports*. 2017;2017(10):omx057.
- (49) Matsuyama T, Kuwana M, Matsumoto M, Isonishi A, Inokuma S, Fujimura Y. Heterogeneous pathogenic processes of thrombotic microangiopathies in patients with connective tissue diseases. *Thromb Haemost*. 2009;102(2):371-378.
- (50) Benjamin M, Terrell DR, Vesely SK, et al. Frequency and significance of HIV infection among patients diagnosed with thrombotic thrombocytopenic purpura. *Clin Infect Dis*. 2009;48(8):1129-1137.
- (51) Roberts JR. HUS and TTP Associated with Escherichia Coli 0157: H7. *Emergency Medicine News*. 2004;26(2):24-27. [cited 2022 Jul 30]. Available on: https://journals.lww.com/emnews/fulltext/2004/02000/hus_and_ttp_associated_with_escherichia_coli_0157_.17.aspx
- (52) Alhomoud M, Alhobayb T, Armitage K. COVID-19 infection triggering Thrombotic Thrombocytopenic Purpura. *IDCases*. 2021;26:e01256.
- (53) Saluja P, Gautam N, Yadala S, Venkata AN. Thrombotic thrombocytopenic purpura (TTP) after COVID-19 vaccination: A systematic review of reported cases. *Thromb Res*. 2022;214:115-121.
- (54) Scully M, Hunt BJ, Benjamin S, et al. Guidelines on the diagnosis and management of thrombotic thrombocytopenic purpura and other thrombotic microangiopathies. *Br J Haematol*. 2012;158(3):323-335.

- (55) Sayani FA, Abrams CS. How I treat refractory thrombotic thrombocytopenic purpura [published correction appears in *Blood*. 2017 Oct 5;130(14):1684]. *Blood*. 2015;125(25):3860-3867.
- (56) Ozsoylu S. Corticosteroids in the treatment of thrombotic thrombocytopenic purpura. *Acta Paediatr*. 2003;92(10):1229.
- (57) Reddy MS, Hofmann S, Shen YM, et al. Comparison of low fixed dose versus standard-dose rituximab to treat thrombotic thrombocytopenic purpura in the acute phase and preemptively during remission. *Transfus Apher Sci*. 2020;59(6):102885.
- (58) Scully M, Cohen H, Cavenagh J, et al. Remission in acute refractory and relapsing thrombotic thrombocytopenic purpura following rituximab is associated with a reduction in IgG antibodies to ADAMTS-13. *Br J Haematol*. 2007;136(3):451-461.
- (59) Page EE, Kremer Hovinga JA, Terrell DR, Vesely SK, George JN. Rituximab reduces risk for relapse in patients with thrombotic thrombocytopenic purpura. *Blood*. 2016;127(24):3092-3094.
- (60) Chen H, Fu A, Wang J, et al. Rituximab as first-line treatment for acquired thrombotic thrombocytopenic purpura. *J Int Med Res*. 2017;45(3):1253-1260.
- (61) Cuker A. Adjuvant rituximab to prevent TTP relapse. *Blood*. 2016;127(24):2952-2953.
- (62) Yarahmadi P, Alirezaei M, Forouzannia SM, Naser Moghadasi A. The Outcome of COVID-19 in Patients with a History of Taking Rituximab: A Narrative Review. *Iran J Med Sci*. 2021;46(6):411-419.
- (63) Scully M, Cataland SR, Peyvandi F, et al. Caplacizumab Treatment for Acquired Thrombotic Thrombocytopenic Purpura. *N Engl J Med*. 2019;380(4):335-346.
- (64) Peyvandi F, Scully M, Kremer Hovinga JA, et al. Caplacizumab for Acquired Thrombotic Thrombocytopenic Purpura. *N Engl J Med*. 2016;374(6):511-522. doi:10.1056/NEJMoa1505533.
- (65) Cablivi: EPAR - Medicine overview. September 10, 2018 [cited 2023 Feb 18] Available on: <https://www.ema.europa.eu/en/medicines/human/EPAR/cablivi>
- (66) Kappers-Klunne MC, Wijermans P, Fijnheer R, et al. Splenectomy for the treatment of thrombotic thrombocytopenic purpura. *Br J Haematol*. 2005;130(5):768-776.

- (67) Scully M, Knöbl P, Kentouche K, et al. Recombinant ADAMTS-13: first-in-human pharmacokinetics and safety in congenital thrombotic thrombocytopenic purpura. *Blood*. 2017;130(19):2055-2063.
- (68) Knöbl P. Thrombotic thrombocytopenic purpura. *Memo*. 2018;11(3):220-226.
- (69) Plaimauer B, Kremer Hovinga JA, Juno C, et al. Recombinant ADAMTS13 normalizes von Willebrand factor-cleaving activity in plasma of acquired TTP patients by overriding inhibitory antibodies. *J Thromb Haemost*. 2011;9(5):936-944.
- (70) Jian C, Xiao J, Gong L, et al. Gain-of-function ADAMTS13 variants that are resistant to autoantibodies against ADAMTS13 in patients with acquired thrombotic thrombocytopenic purpura. *Blood*. 2012;119(16):3836-3843.
- (71) Page EE, Kremer Hovinga JA, Terrell DR, Vesely SK, George JN. Thrombotic thrombocytopenic purpura: diagnostic criteria, clinical features, and long-term outcomes from 1995 through 2015. *Blood Adv*. 2017;1(10):590-600.
- (72) Kremer Hovinga, J. A. & Lämmle, B. Role of ADAMTS13 in the pathogenesis, diagnosis, and treatment of thrombotic thrombocytopenic purpura. *Hematology Am. Soc. Hematol. Educ. Program* 2012, 610–616 (2012).
- (73) Nokes T, George JN, Vesely SK, Awab A. Pulmonary involvement in patients with thrombotic thrombocytopenic purpura. *Eur J Haematol*. 2014;92(2):156-163.
- (74) Fontana S, Kremer Hovinga JA, Lämmle B, Mansouri Taleghani B. Treatment of thrombotic thrombocytopenic purpura. *Vox Sang*. 2006;90(4):245-254.
- (75) Carson JL, Stanworth SJ, Dennis JA, et al. Transfusion thresholds for guiding red blood cell transfusion. *Cochrane Database Syst Rev*. 2021;12(12):CD002042.
- (76) Chaturvedi S, Oluwole O, Cataland S, McCrae KR. Post-traumatic stress disorder and depression in survivors of thrombotic thrombocytopenic purpura. *Thromb Res*. 2017;151:51-56.
- (77) Deford CC, Reese JA, Schwartz LH, et al. Multiple major morbidities and increased mortality during long-term follow-up after recovery from thrombotic thrombocytopenic purpura. *Blood*. 2013;122(12):2023-2142.
- (78) Swart L, Schapkaitz E, Mahlangu JN. Thrombotic thrombocytopenic purpura: A 5-year tertiary care centre experience. *J Clin Apher*. 2019;34(1):44-50.

- (79) Reese JA, Muthurajah DS, Kremer Hovinga JA, Vesely SK, Terrell DR, George JN. Children and adults with thrombotic thrombocytopenic purpura associated with severe, acquired Adamts13 deficiency: comparison of incidence, demographic and clinical features. *Pediatr Blood Cancer*. 2013;60(10):1676-1682.
- (80) von Krogh AS, Quist-Paulsen P, Waage A, et al. High prevalence of hereditary thrombotic thrombocytopenic purpura in central Norway: from clinical observation to evidence. *J Thromb Haemost*. 2016;14(1):73-82.
- (81) Griffin D, Al-Nouri ZL, Muthurajah D, et al. First symptoms in patients with thrombotic thrombocytopenic purpura: what are they and when do they occur?. *Transfusion*. 2013;53(1):235-237.
- (82) Chang JC. The understanding of thrombotic thrombocytopenic purpura: Dyadic, triadic, pentadic, and other manifestations. *J Clin Apher*. 2004;19(1):2-4.
- (83) Ruggenti P, Remuzzi G. Pathophysiology and management of thrombotic microangiopathies. *J Nephrol*. 1998;11(6):300-310.
- (84) Stanley M, Killeen RB, Michalski JM. Thrombotic Thrombocytopenic Purpura. In: *StatPearls*. Treasure Island (FL): StatPearls Publishing; August 21, 2022. [cited 2023 Feb 2]. Available on: <https://www.ncbi.nlm.nih.gov/books/NBK430721/>
- (85) Blombery P, Kivivali L, Pepperell D, et al. Diagnosis and management of thrombotic thrombocytopenic purpura (TTP) in Australia: findings from the first 5 years of the Australian TTP/thrombotic microangiopathy registry. *Intern Med J*. 2016;46(1):71-79.
- (86) Chiasakul T, Cuker A. Clinical and laboratory diagnosis of TTP: an integrated approach. *Hematology Am Soc Hematol Educ Program*. 2018;2018(1):530-538.
- (87) Crowley JP, Metzger JB, L'Europa RA. The blood counts and lactate dehydrogenase levels in thrombotic thrombocytopenic purpura (TTP). *Am J Clin Pathol*. 1983;80(5):700-702.
- (88) Beckford R, Shah G. Thrombotic Thrombocytopenic Purpura: A Review of the Disease Entity, its Clinical and Laboratory Features, and Management Strategies. *The Medicine Forum*. 2010;12(1).
- (89) Kadikoylu G, Barutca S, Tataroglu C, et al. Thrombotic thrombocytopenic purpura as the first manifestation of metastatic adenocarcinoma in a young woman. *Transfus Apher Sci*. 2010;42(1):39-42.

- (90) Darnahal M, Azhdari Tehrani H, Vaezi M, Haghghi S. Covid-19 and Thrombotic Thrombocytopenic Purpura: A Case Report. *Int J Hematol Oncol Stem Cell Res.* 2021;15(1):72-74.
- (91) Westwood JP, Thomas M, Alwan F, et al. Rituximab prophylaxis to prevent thrombotic thrombocytopenic purpura relapse: outcome and evaluation of dosing regimens. *Blood Adv.* 2017;1(15):1159-1166.
- (92) Chen B, Li X, Xiao D, Raimundo RD, Zhou R, Lei Y. Comparison of the efficacy and safety of caplacizumab versus placebo in thrombotic thrombocytopenic purpura: a meta-analysis and systematic review based on randomized controlled trials. *Ann Transl Med.* 2022;10(12):657.
- (93) Abou-Ismaïl MY, Arafah Y, Fu P, Cao S, Schmaier AH, Nayak L. Outcomes of Immune Thrombotic Thrombocytopenic Purpura (iTTP) With Upfront Cyclophosphamide vs. Rituximab. *Front Med (Lausanne).* 2020;7:588526.
- (94) Vesely SK, George JN, Lämmle B, et al. ADAMTS13 activity in thrombotic thrombocytopenic purpura-hemolytic uremic syndrome: relation to presenting features and clinical outcomes in a prospective cohort of 142 patients. *Blood.* 2003;102(1):60-68.
- (95) George JN. TTP: long-term outcomes following recovery. *Hematology Am Soc Hematol Educ Program.* 2018;2018(1):548-552.
- (96) Nuñez Zuno JA, Khaddour K. Thrombotic Thrombocytopenic Purpura Evaluation and Management. [Updated 2022 Jul 25]. In: StatPearls [Internet]. Treasure Island (FL): StatPearls Publishing; 2022 Jan-. [cited 2022 Feb 8]. Available from: <https://www.ncbi.nlm.nih.gov/books/NBK470585/>
- (97) Çeneli Ö, Yılmaz S, Karaselek MA, Çamlı K. Outcome of Thrombotic Thrombocytopenic Purpura Patients: A Single-Center Experience. *Turk J Haematol.* 2019;36(3):214-215.
- (98) Huang F, Li XP, Xu Y, et al. Clinical characteristics and outcomes of adult patients with acquired thrombotic thrombocytopenic purpura: a single center retrospective study. *Ann Palliat Med.* 2021;10(5):5351-5358.
- (99) Iqbal S, Zaidi SZ, Motabi IH, Alshehry NF, AlGhamdi MS, Tailor IK. Thrombotic thrombocytopenic purpura - analysis of clinical features, laboratory characteristics and therapeutic outcome of 24 patients treated at a Tertiary Care Center in Saudi Arabia. *Pak J Med Sci.* 2016;32(6):1494-1499.

Biography

The author was born on 5th of June 1997 in Vienna, Austria as a child of two Iranian immigrants. He finished elementary and grammar school in Austria and after a period of 9 months finishing obligatory civilian service, he started to study medicine in Zagreb, Croatia. During his studies he did voluntary internships in hospitals in Austria like Klinik Donaustadt (internal medicine hematology and oncology, orthopedics and traumatology and pediatrics), in university hospital Krems (hematology and oncology), Klinik Floridsdorf (gastroenterology), in many GP offices. He did his clinical rotations in Klinik Donaustadt in the ENT department and 2 months in Hanusch – Krankenhaus on hematology and oncology. He also published many papers and attended scientific student conferences.

In the period between April – June 2023 he will work in the university hospital Basel in Switzerland as a student in the department of internal medicine.

After receiving his diploma, the author plans to go back to Austria to start his career as a medical doctor and finally to specialize in the field of internal medicine, especially hematology and oncology.