

Facial reconstruction after gunshot wound injuries in the Department for Maxillofacial Surgery

Stein, Sebastian Leander

Master's thesis / Diplomski rad

2023

Degree Grantor / Ustanova koja je dodijelila akademski / stručni stupanj: **University of Zagreb, School of Medicine / Sveučilište u Zagrebu, Medicinski fakultet**

Permanent link / Trajna poveznica: <https://um.nsk.hr/um:nbn:hr:105:186422>

Rights / Prava: [In copyright](#)/[Zaštićeno autorskim pravom.](#)

Download date / Datum preuzimanja: **2024-07-14**



Repository / Repozitorij:

[Dr Med - University of Zagreb School of Medicine Digital Repository](#)



UNIVERSITY OF ZAGREB
SCHOOL OF MEDICINE

Leander Stein

**Facial reconstruction after gunshot wound
injuries in the Department for Maxillofacial
Surgery**

Graduation Thesis



Zagreb, 2023

This graduate thesis was made at the Department of Maxillofacial Surgery, Dubrava University Hospital, and School of Medicine, Zagreb, Croatia, mentored by Assistant Professor Emil Dediol, MD, PhD, and was submitted for evaluation in the academic year 2022/2023.

Abbreviations

ALT – Anterolateral thigh

AO – Arbeitsgemeinschaft für Osteosynthesefragen

DCIA – Deep circumflex iliac artery

GSW – Gunshot wound

FHF – Forehead flap

FFF – Fibula free flap

FOSC – Fibula osteoseptocutaneous

PMF – Pectoralis major flap

NOE – Naso-orbito-ethmoidal

RFFF – Radial free forearm flap

SOFF – Scapula osseous free flap

SIGSW – Self-inflicted gunshot wound

VML – Volumetric muscle loss

ZMC – Zygomatico-maxillary complex

Contents

ABSTRACT	5
SAŽETAK	6
INTRODUCTION	7
1. History of facial reconstruction	7
2. Importance of collaboration	7
3. Psychological and social implications of facial disfigurement	8
4. Anatomy of the face	8
5. Gun ballistics	9
6. Surgical techniques and technologies in facial reconstruction	10
7. Flap techniques	11
8. Challenges of facial reconstruction	12
MATERIAL AND METHODS	13
Statistical analysis	13
RESULTS	14
1. Gender distribution and age at time of injury	14
2. Hospitalization history	15
3. Circumstances involved in accidents	16
3.1. GSW vs. SIGSW	16
3.2. Type of firearm	16
4. Distribution of maxillofacial impairments among trauma patients	17
4.1. Patterns of maxillofacial fractures	17
4.1.1. Patterns of mandibular fractures	18
4.1.2. Patterns of maxillary fractures	19
4.2. Soft tissue injury distribution in the maxillofacial region	20
5. Procedures	21

5.1. Primary wound care	21
5.2. Tracheotomy	21
5.3. Mandible reconstruction.....	22
5.4. Maxillary and palatine reconstruction	23
5.5. Zygomatic bone and orbital floor reconstruction	23
5.6. Nasal bone reconstruction	24
5.7. Soft tissue reconstruction.....	24
DISCUSSION	25
1. Demographic characteristics and clinical features	25
2. Hospitalization history	26
3. Importance of mental health support and suicide prevention	26
4. Surgical approaches and reconstruction techniques	27
4.1. Mandible reconstruction.....	27
4.2. Maxillary and palatine reconstruction.....	28
4.3. Zygomatic bone and orbital floor reconstruction	28
4.4. Nose reconstruction.....	28
4.5. Additional surgical procedures	29
5. Limitations and future directions	29
CONCLUSION.....	30
ACKNOWLEDGMENT	31
REFERENCES.....	32
BIOGRAPHY	35

ABSTRACT

Title: Facial reconstruction after gunshot wound injuries in the Department for Maxillofacial Surgery

Author: Leander Stein

Objective: This study investigated demographic characteristics, clinical features, and surgical approaches in facial reconstruction for patients with gunshot wound (GSW) injuries.

Methods: A retrospective analysis was conducted on selected cases of GSW injuries at University Hospital Dubrava in the Department of Maxillofacial Surgery, from January 2010 to August 2022.

Results: 17 male patients (mean age 41.8 years) underwent facial reconstruction for GSW injuries, predominantly caused by rifles (76.5%) and associated with suicide attempts (70.1%). Mandible fractures (41.2%) were most common, followed by maxillary and zygomatic-orbital fractures (20.6% each). Soft tissue injuries frequently occurred in the lips (41.2%). Surgical approaches varied, involving repositioning, osteosynthesis, bone grafting, and tissue flaps (e.g., RFFF and FFF). Bone grafting was required for vestibuloplasty, primarily in mandibular and maxillary reconstruction. Osteocutaneous flaps were commonly used for mandibular reconstruction, less so for maxillary and palate reconstruction. Zygomatic and orbital fractures were managed with osteosynthesis and titanium mesh. Lip reconstruction had the most versatile approaches. Enucleation of the eyeball was performed in three cases.

Conclusion: This study provides valuable insights into demographic trends, clinical features, and surgical considerations in facial reconstruction following GSW injuries. The predominance of suicide attempts underscores the need for comprehensive mental health support. The distribution of fractures, with mandible fractures being most common, has implications for surgical management. These findings align with existing knowledge and can inform the development of optimized approaches for managing facial gunshot injuries.

Keywords: facial reconstruction – gunshot wound injuries – self-inflicted gunshot wound injuries – mandible reconstruction

SAŽETAK

Naslov: Rekonstrukcija lica nakon prostrijelnih ozljeda na Klinici za kirurgiju lica, čeljusti i usta

Autor: Leander Stein

Cilj: Ova studija je istraživala demografske karakteristike, kliničke značajke i kirurške pristupe u rekonstrukciji lica kod pacijenata s ozljedama iz vatrenog oružja (VO).

Metode: Provedena je retrospektivna analiza odabranih slučajeva ozljeda iz VO u Kliničkoj bolnici Dubrava na Klinici za kirurgiju lica, čeljusti i usta od siječnja 2010. do kolovoza 2022. godine.

Rezultati: 17 muških pacijenata (prosječna dob 41,8 godina) podvrgnuto je rekonstrukciji lica zbog ozljeda iz VO, uglavnom uzrokovanih puškama (76,5%) i povezanih sa samoubojstvima (70,1%). Najčešći su bili prijelomi donje čeljusti (41,2%), slijedili su prijelomi gornje čeljusti i zigomatično-orbitalni prijelomi (20,6% svaki). Često su se javljale ozljede mekog tkiva usana (41,2%). Kirurški pristupi su varirali i uključivali su repoziciju-osteosintezu, transplantaciju kosti i slobodne reznjeve (npr. podlaktični režanj i fibularni slobodni režanj). Transplantacija kosti bila je potrebna za vestibuloplastiku, uglavnom kod rekonstrukcije donje čeljusti i gornje čeljusti. Osteokutani reznjevi su često korišteni za rekonstrukciju donje čeljusti, manje za rekonstrukciju gornje čeljusti i nepca. Prijelomi zigomatične kosti i orbite su se liječili osteosintezom i titanskom mrežicom. Rekonstrukcija usana je imala najraznovrsnije pristupe. Enukleacija bulbusa je izvršena u tri slučaja.

Zaključak: Ovo istraživanje pruža vrijedne uvide u demografske trendove, kliničke značajke i kirurške smjernice u rekonstrukciji lica nakon ozljeda iz VO. Prevladavajući pokušaji samoubojstava naglašavaju potrebu za sveobuhvatnom podrškom mentalnom zdravlju. Distribucija prijeloma, s najčešćim prijelomima donje čeljusti, ima implikacije na kirurško liječenje. Ovi rezultati se podudaraju s postojećim saznanjima i mogu pridonijeti razvoju optimiziranih pristupa u liječenju ozljeda lica izazvanih vatrenim oružjem.

Ključne riječi: rekonstrukcija lica – ozljede iz vatrenog oružja – samoozlijeđivanje iz vatrenog oružja – rekonstrukcija donje čeljusti

Introduction

1. History of facial reconstruction

Facial reconstruction is a specialized area of maxillofacial and plastic surgery that aims to restore facial form and function after traumatic injuries or congenital abnormalities. The history of facial reconstruction dates back to ancient civilizations, such as the Egyptian Old Kingdom in 3000 BC, where primitive methods were used to reconstruct facial defects (1). However, significant advancements were made in the 20th century, particularly after World War I and II, thanks to the contributions of notable surgeons like Archibald McIndoe and Harold Gilles (2).

After the Second World War, the discovery of acrylic resins and silicone elastomers revolutionized the field of facial prosthesis. Osseointegrated implant devices also came into widespread use in the 1980s to support and retain dental and maxillofacial prostheses for jaw, nose, ear, and eye replacement (3).

Despite significant progress, facial injuries caused by gunshot wounds (GSW) during conflicts in the region of former Yugoslavia in the 1990s continue to pose significant challenges to surgeons (4). However, advances in surgical techniques and technology, such as 3D printing and virtual surgical planning (VSP), have improved outcomes for patients. Research into regenerative medicine and tissue engineering also holds promise for the future of facial reconstruction (5,6).

The ongoing conflict between Russia and Ukraine serves as a reminder of the continued risk of war and the prevalence of facial injuries caused by gunshot wounds, which often require extensive facial reconstruction. This highlights the critical need for ongoing innovation and progress in the field of facial injury treatment to address the challenges faced by those affected by conflict and trauma (7).

2. Importance of collaboration

GSW injuries are one of the most common causes of facial trauma and can result in significant deformities and functional impairments. Such injuries require a multidisciplinary approach, involving maxillofacial surgeons, plastic surgeons, otolaryngologists, neurosurgeons, ophthalmologists, prosthetics and dentists (8,9).

3. Psychological and social implications of facial disfigurement

Facial disfigurement resulting from self-inflicted gunshot wound (SIGSW) injuries or assault can have profound psychological and social implications for the patient. These may include depression, anxiety, post-traumatic stress disorder (PTSD), body image issues, low self-esteem, and reduced self-confidence (6,10). In severe cases, patients may avoid social situations or public places and may face discrimination in various aspects of life. Such challenges can negatively impact the patient's quality of life and have long-term effects on their social and professional development. Patients who have performed a SIGSW are also at an increased risk of further suicide attempts, and having a facial disfigurement may compound their struggles (11). Therefore, addressing the psychological and social implications of facial disfigurement is critical in the patient's overall treatment and rehabilitation plan. The importance of facial reconstruction, therefore, extends beyond physical restoration to include promoting positive self-image and social reintegration.

4. Anatomy of the face

An in-depth comprehension of facial anatomy is crucial in managing GSW injuries to the face. The facial region consists of multiple bony structures, such as the mandible, maxilla, zygomatic, and nasal bones (12), all of which are prone to fracture when subjected to the impact of a bullet.

The Le Fort I-III classification system categorizes facial fractures based on their involvement in the facial bones, with Le Fort I fractures involving the maxilla above the roots of the teeth, Le Fort II fractures extending beyond the maxilla to affect the nasal bone and orbital floor, and Le Fort III fractures being the most severe, involving the nasoethmoidal complex, frontozygomatic suture, and orbital rim (13). Additionally, there are other fracture classifications, including e.g. the zygomatico-maxillary complex I-V (ZMC) and naso-orbito-ethmoidal I-III (NOE) classifications (14).

Facial gunshot wounds can cause significant damage to soft tissues such as muscles, blood vessels, nerves, and skin, in addition to bone fractures. Reconstruction should aim not only to repair physical damage but also to restore natural facial appearance and function while addressing any associated functional deficits, such as speech, chewing, and vision problems.

5. Gun ballistics

Gun ballistics is a crucial factor to consider in facial reconstruction when dealing with GSW. The velocity of the bullet is a critical aspect that determines the severity of the damage caused by the bullet.

Low-velocity bullets (below 600 m/s or 2,000 ft/sec), are commonly utilized in handguns and shotguns. While these bullets can be lethal, they are less likely to cause significant damage to the target. High-velocity bullets (higher than 600 m/s or 2,000 ft/sec), on the other hand, typically used in rifles for long-range shooting, hunting, and military applications, have a higher potential to cause severe damage. They have more recoil and are more accurate over longer ranges. These bullets can cause extensive damage to the target, including tissue necrosis and permanent or temporary cavities in the soft tissues. This damage is more severe than that caused by low-velocity bullets due to their higher kinetic energy (15–17).

Following ballistic trauma, the most common primary consequences include soft-tissue damage, volumetric muscle loss (VML), hemorrhage, bone fractures, and pain. The major site of firearm wounds are of musculoskeletal origin in the extremities in both military (18) and civilian populations (16). Indeed, injuries promoted by firearm incidents that impact skeletal muscle induce severe disability, extended hospitalizations, and overall a poor quality of life. The damage caused by a bullet is influenced by various factors, such as the type of firearm, ammunition, bullet size and shape, angle of entry, and wound location (19).

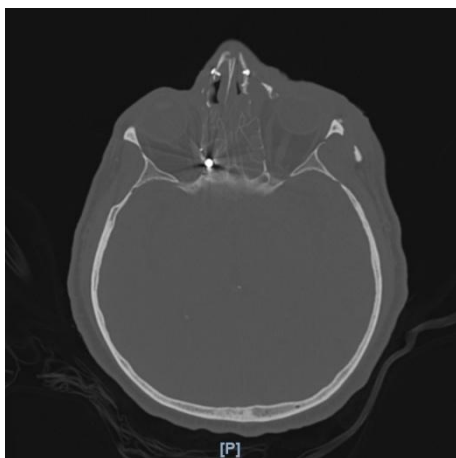


Figure 1. Axial computed tomography (CT) scan of the skull. A shotgun bullet is observed stuck in the region of the posterior ethmoids, located in close proximity to the medial wall of the orbit and optic nerve.

6. Surgical techniques and technologies in facial reconstruction

Primary wound care is an integral part of managing facial trauma. Soft tissue injuries should be thoroughly cleaned using irrigation techniques. For small wounds with minimal contamination, irrigation with a large volume of normal saline is recommended. However, for larger wounds with gross contamination, it is advised to use a dilute soap solution (20). When a soft tissue injury cannot be closed primarily, it is often allowed to heal by secondary intention (21). However, in such cases, bony reconstruction is typically addressed at a later stage. This delayed approach often leads to significant scar contracture and less than optimal cosmetic and functional outcomes (22). Hemostasis must be achieved through the application of direct pressure or addition of epinephrine. Nonviable tissue should be conservatively debrided. Following this, appropriate dressing should be applied to facilitate proper wound healing. Throughout the recovery process, patients must be closely monitored for potential infections and other complications. Due to bleeding and swelling the airways may be compromised. In order to ensure adequate ventilation, tracheotomy may be necessary (20). Repositioning and osteosynthesis techniques, such as plates, screws, and wires, may be used to fix displaced bones in place. Bone grafting with autograft or allograft bone may be required to reconstruct missing bone tissue. Flaps may be used to repair soft tissue defects and provide coverage for bone grafts (17). Additional reconstructive procedures, such as vestibuloplasty (23), enucleation for severe eye injuries (24) or reconstruction of the nose (25), may be necessary.

7. Flap techniques

Flap techniques are fundamental in the realm of facial reconstruction surgery, enabling the transfer of tissue from one anatomical site to another for the purpose of addressing soft tissue or bony defects. These flaps can be categorized based on their constituent components (cutaneous, fasciocutaneous, musculocutaneous, osteocutaneous), their relation to the defect (local, regional, distant, free), the nature of their blood supply (random or axial), and the required movement for optimal placement (advancement, rotation, transposition, interposition) (21).

Local flaps rely on adjacent tissue to reconstruct the affected area. Advancement, rotational, and transposition flaps are considered random pattern local flaps, whereas axial pattern local flaps derive their arterial blood supply from a cutaneous artery incorporated into the flap. Advancement flaps involve the movement of tissue from another facial region towards the defect and are suitable for small to medium-sized defects. Rotation flaps entail the rotation of neighboring tissue to cover irregularly shaped or areas with limited adjacent tissue (21).

Regional flaps utilize tissue from nearby anatomical regions to address medium to large-sized defects. Examples of regional flaps encompass the nasolabial flap, paramedial forehead flap (FHF), and pectoralis major flap (PMF) (26,27).

Free flaps, alternatively known as axial flaps, constitute a class of reconstructive surgical techniques utilized for extensive defects that cannot be adequately addressed with local or regional flaps. These procedures rely on specific arteries, forming the vascular pedicle, to ensure the continuous blood supply to the flap. Employing microsurgical methods, the vascular pedicle is meticulously detached from the donor site and anastomosed to recipient site blood vessels, thereby restoring blood circulation, promoting flap viability, and facilitating successful integration (21,26).

Examples of free flaps include the anterolateral thigh flap (ALT) involving the harvesting of skin, soft tissue, and underlying fascia from the anterior and lateral aspect of the thigh, the fibula free flap (FFF) commonly employed for reconstructing bony defects by harvesting a segment of the fibula along with its vascular supply, the radial forearm flap (RFFF) available in fasciocutaneous or osteocutaneous variations by harvesting skin, soft tissue, and either the radial artery or a segment of the radius bone, and the scapula osseous free flap (SOFF) which encompasses the harvest of scapula bone, muscle, skin, and soft tissue for reconstructing complex defects in various anatomical regions (27).

The choice of flap technique depends upon factors such as the size, location, and extent of tissue loss in the defect, the availability of suitable donor tissue, and the patient's overall health status. Each technique possesses its own set of advantages and limitations, necessitating a tailored approach to optimize outcomes in individual cases (21).

8. Challenges of facial reconstruction

Facial reconstruction is a complex and challenging field that requires a multidisciplinary approach (8,9). Successful outcomes are dependent on numerous factors, including the extent of the injury, timing of surgery, patient factors, and the selection of appropriate reconstruction techniques.

One of the primary challenges in facial reconstruction is the extent of the injury, which can involve significant tissue loss, bone fractures, and damage to vital structures such as nerves and blood vessels. Accurate assessment of the extent of the damage is essential in determining the most appropriate approach for reconstruction.

The timing of facial reconstruction after a gunshot wound remains a topic of debate (28). Traditional approaches have favored delayed reconstruction, but recent studies have demonstrated success with more immediate definitive reconstruction within 24 to 48 hours. Delayed reconstruction was thought to reduce infection rates and allow for a better assessment of the extent of injury. However, studies have shown that immediate reconstruction can actually reduce wound contracture, scarring rate, and local dead space. It also improves immunoreactivity, provides more robust biologic coverage, and enhances the delivery of hematogenous nutrients essential for wound healing. In addition, immediate reconstruction leads to fewer and less complex revisionary procedures (22,29–31). Overall, the choice of timing for facial reconstruction should be tailored to the individual case, considering factors such as the extent of tissue loss and the patient's overall health. Patient factors, such as age, overall health, and pre-existing medical conditions, can also impact the success of facial reconstruction. Surgeons must carefully consider these factors when developing a personalized treatment plan.

The selection of the appropriate reconstruction technique is crucial in achieving successful outcomes in facial reconstruction. Surgical planning must consider the patient's unique needs and the extent of the injury (17). In addition, flap rejection due to coagulation and malperfusion is a common complication that requires revision surgery (32).

Materials and Methods

A retrospective analysis was conducted at the Maxillofacial Surgery department of the Clinical Hospital Dubrava, involving 17 patients who survived firearm injuries to the face. The study spanned from January 2010 to August 2022, utilizing data obtained from hospital records.

Epidemiological information, including age, gender, date of first hospitalization, and hospitalization history, was collected and analyzed. The cause of injury (GSW or SIGSW), type of firearm used, and the specific locations of the injuries were documented. The injuries were classified into bony fractures and soft tissue injuries. Bony fractures were further categorized into mandibular, maxillary, zygomatic-orbital, nasal, frontal, and skull regions. It should be noted that the frontal bone and skull are part of the neurocranium, not the viscerocranium. Soft tissue injuries were classified based on the affected areas, such as the jaw, chin, cheeks, nose, floor of the mouth, upper lip, and lower lip.

The study also recorded the surgical procedures performed, which included primary wound management, osteosynthesis and repositioning of fractured bones, bone grafting, flap treatment, and other reconstructive procedures.

The objective of this comprehensive analysis was to provide insights into the characteristics and management of firearm-related facial injuries.

Statistical analysis

For descriptive analysis number (n) and percentage, minimal, maximal values and medium were used. Excel was used as the main tool for calculation.

Results

1. Gender distribution and age at Injury

In this analysis, it was found that all patients with GSW to the face were male, with an average age of 41.8 years. The youngest patient was 12 years old, while the oldest was 71 years old. As depicted in Figure 2, the majority of patients were in the age range of 30-40 years and 50-60 years.

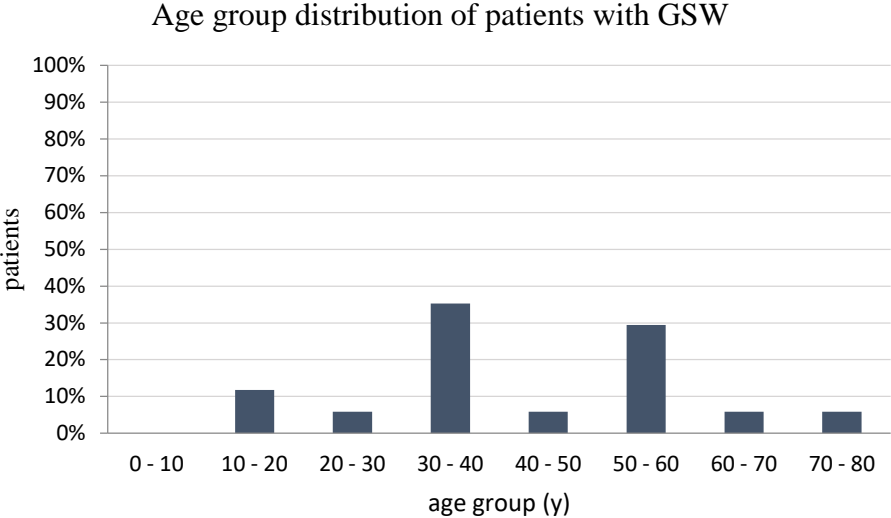


Figure 2. Age group distribution of patients with GSW, GSW = Gunshot wounds

2. Hospitalization history

Based on the data, it appears that the first (n=6) and third quarter (n=7) of the year saw the greatest incidence of surgeries of this nature. Additionally, it's worth noting that the years 2010, 2011, and 2018 had the highest frequency of surgeries for patients who had suffered from GSWs to the face, with three such cases reported during each of these years (Figure 3).

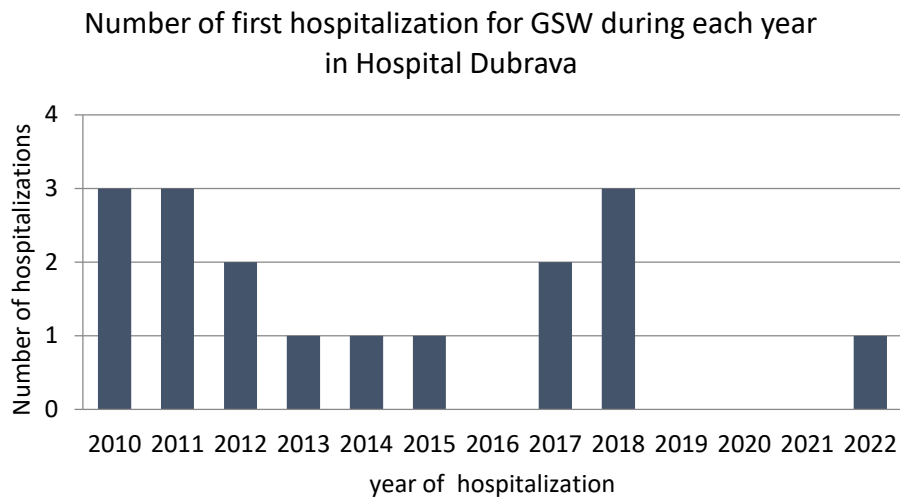


Figure 3. Number of first hospitalization for GSW during each year in Hospital Dubrava, GSW= Gunshot wound

Thirteen individuals were transferred from other medical facilities to the current hospital for further treatment. Among them, seven patients underwent various medical procedures. These included primary wound care for three individuals, tracheotomy for one patient, fracture reposition for two patients, and orbit enucleation for one patient.

The hospitalization history of the patients varied, with seven patients being admitted only once, while one patient was admitted up to a maximum of fourteen times. On average, the patients were hospitalized 4.2 times during the course of their treatment.

The duration of first hospitalization also varied among the patients, with an average length of stay of 29.6 days. The minimum hospitalization period was four days, while the maximum duration was 105 days.

When analyzing the length of the first hospitalization, it was found that 13 patients were transferred and spent an average of 34.7 days in the ward. On the other hand, 4 patients were admitted directly to the current hospital and spent an average of 13.25 days during their first hospitalization.

3. Circumstances involved in accidents

3.1. GSW vs. SIGSW

In the examination of GSW injuries, a significant subset of patients (70.1%, n=12) were discovered to have engaged in suicidal behavior by utilizing firearms, resulting in self-inflicted gunshot wounds (SIGSW). The term SIGSW was adopted to represent these occurrences succinctly and effectively. These results indicate a noteworthy prevalence of SIGSW in patients suffering from GSW injuries.

3.2. Type of firearm

Based on the information provided, there were a total of 17 incidents where firearms or pyrotechnics were used resulting in injuries to patients. Among these incidents, rifles were the most commonly used type of firearm, being involved in 13 (76.5%) of the incidents. It is noteworthy that of these 13 rifle-related incidents, one involved a hunting rifle and another involved a semi-automatic rifle. Shotguns were used in two incidents, while pistols were involved in only one incident. Additionally, one incident involved the use of pyrotechnics, resulting in injuries to a patient (Figure 4).

The data suggests that the use of rifles is a significant factor in incidents resulting in patient injuries, with shotguns and pistols playing a smaller role. The infrequent use of pyrotechnics in this context underscores the potential harm such devices can cause.

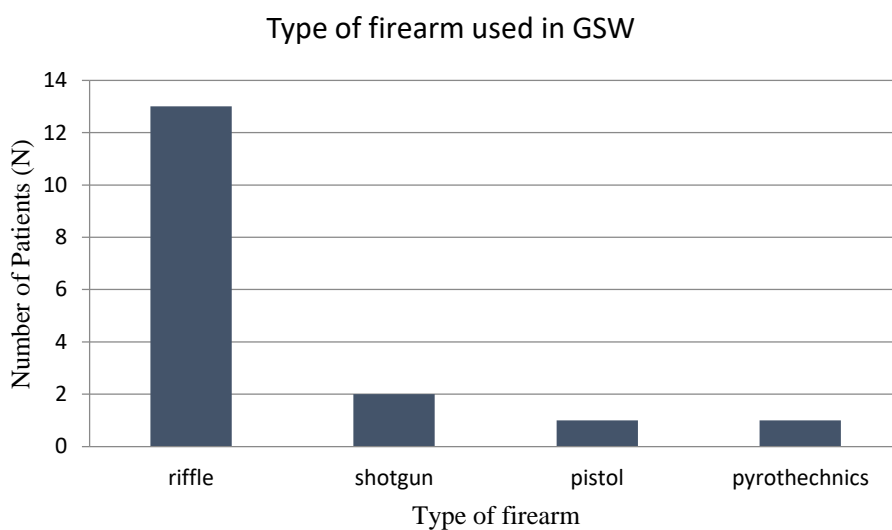


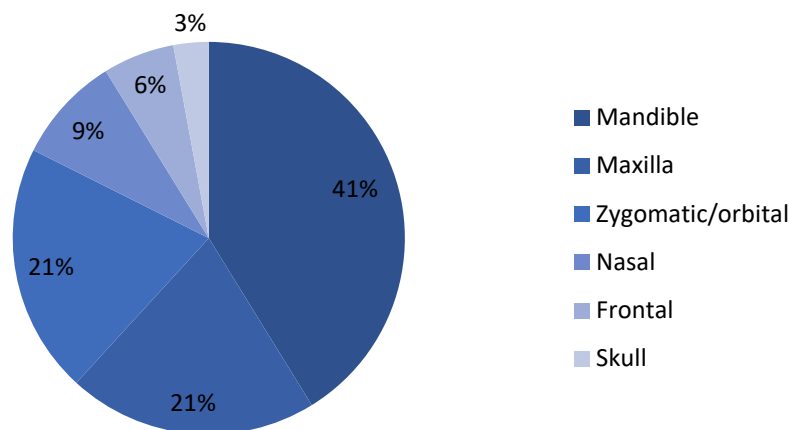
Figure 4. Relationship between the type of firearm used and the number of patients with injuries, GSW = Gunshot wound

4. Distribution of maxillofacial impairments among trauma patients

4.1. Patterns of maxillofacial fractures

Figure 5 illustrates that all but one of the patients in the study sustained facial fractures, resulting in a total of 34 affected facial regions. Among these fractures, the mandible was the most commonly involved region, accounting for 41.2% of the fractures. Out of the seven maxillary fractures, three were classified as Le Fort fractures. However, for one patient, it was challenging to differentiate between a Le Fort I and Le Fort II fracture. The remaining two maxillary fractures were identified as Le Fort II and III, respectively. Additionally, almost all patients (82.4%) sustained mandibular fractures, while a significant proportion also had maxillary and zygomatic/orbital fractures (41.2%). Furthermore, there were two cases of frontal fractures and one case of a skull fracture.

Maxillofacial fracture distribution after GSW



Oral and maxillofacial region	Number of fractures/ region (n = 34)	% of fractures/ region (n = 34)	% of Patients with fracture (n =17)
Mandible	14	41.2	82.4
Maxilla	7	20.6	41.2
Zygomatic/orbital	7	20.6	41.2
Nasal	3	8.8	17.6
Frontal	2	5.9	11.8
Skull	1	2.9	5.9

Figure 5. Distribution of maxillofacial fractures due to shot wounds (January 2010 to August 2022, n = 17), GSW = Gunshot wound. Note: Of the 17 patients, 16 had facial fractures in 34 facial regions.

4.1.1. Patterns of mandibular fractures

The analysis conducted on mandibular fracture patterns demonstrated that the regions that were most commonly affected were the proximal regions of the mandible, specifically the body and symphysis & parasymphysis (central unit). Among the cases studied, bilateral body fractures were observed in three cases. On the other hand, fractures in the angle and ramus regions were less frequent. Notably, there were no reported cases of condylar fractures.

The fractures were classified as either simple or complex, with some cases demonstrating complete loss of bone. Table 1 presents a detailed account of the various fracture types identified in each region of the mandible, including the number of simple fractures, comminuted fractures, and instances of bone loss. The body region (n = 8) and central unit (n = 7) had the highest number of fractures with a mixed presentation of simple, comminuted, and bone loss fractures. The angle and ramus regions demonstrated three fractures, respectively. In total, the analysis characterized 21 fracture regions.

Table 1. *Characterization of mandibular fracture patterns*

Bony part of mandible	Simple fracture	Complex fracture	Loss of bone	Total
Central unit	3	2	3	7 (33%)
Body	4	3	2	8 (38%)
Angle	2	-	1	3 (14%)
Ramus	2	1	-	3 (14%)
Condyle	-	-	-	0

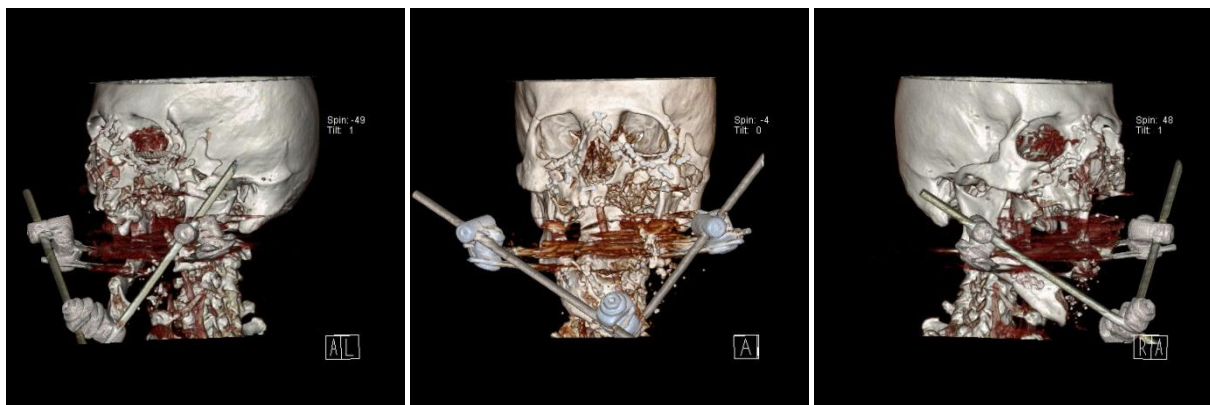


Figure 6. *Three-dimensional computed tomography (CT) reconstruction of the skull and viscerocranium (preoperative). Left-anterior (left), anterior-posterior (middle), and right-anterior (right) views. An elderly male (71 years), attempted suicide with a shotgun and was transferred after initial wound care for further reconstruction. The mandible exhibits bone loss in the symphysis/parasymphysis (central unit), bilateral body, and left ramus/angle. Temporary repositioning of mandible fragments was achieved using external fixation in another institution. The maxilla shows defects in the alveolar ridge and hard palate together with multifragmented zygomatic bone on the left.*

Furthermore, Table 2 provides a detailed distribution of mandibular fractures in different regions. For clarification reasons the AO-classification (Arbeitsgemeinschaft für Osteosynthesefragen) for mandibular fractures was used (33). The mandible was subdivided into following locations symphysis and parasymphysis (S), body (B), angle and ramus (A). The morphology was reduced to simple (s) and complex (c).

Table 2. Distribution of mandibular fractures in different regions. S = symphysis/ parasymphysis (central uni), B = body, A = angle/ ramus, 2 =bilateral.

Patient	Defect location	Defect morphology
1	S	Complex
2	S	Simple
4	B	Complex
5	B	Simple
6	S+2B	Complex
7	B+A	Complex
8	2B	Complex
9	2B	Simple
10	A	Simple
11	S	Simple
12	S+A	Simple
15	B+A	Simple
16	S	Complex
17	S+B+A	Complex

4.1.2. Patterns of maxillary fractures

Seven patients suffered maxillary fractures due to GSW, with three each having Le Fort, alveolar ridge, and hard palate defects. The type of fracture for the remaining patients is unknown (Table 3).

Table 3. Distribution of maxillary fractures.

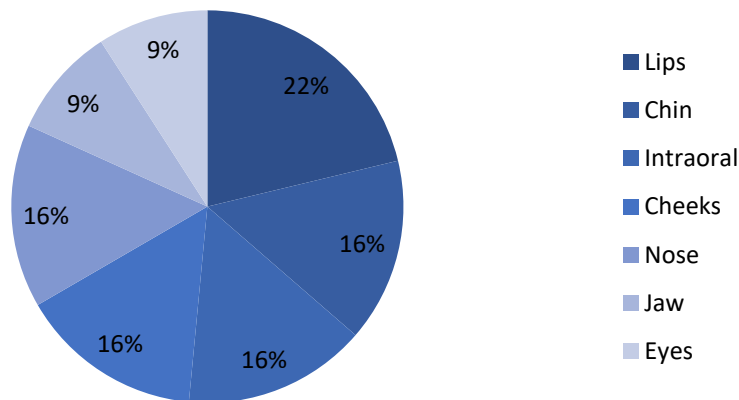
Patient	Le Fort	Maxillary defect	Palatine defect
6	-	Alveolar ridge	-
8	-	Alveolar ridge	Hard palate
9	I/II	-	Hard palate
10	-	Maxillary	Hard palate
11	II	Alveolar ridge	-
15	III	-	-
16	-	Bilateral maxillary	-

4.2. Soft tissue injury distribution in the maxillofacial region

All 17 patients with GSW had soft tissue injuries. However, the soft tissue injuries of two patients were not further characterized or specified.

The highest percentage of soft tissue injuries per patient was observed in the lips (41.2%), followed by the nasal, intraoral and cheek region (each 29.4%). Three cases of bulbus ruptures of the eye were reported (Figure 7).

Maxillofacial soft tissue injury distribution after GSW



Oral and maxillofacial region (general)	Number of soft tissue injuries/ region (n = 32)	% of soft tissue injuries/ region (n = 32)	% of patients with impaired region (n = 17)
Jaw	3	9.4	17,7
Chin	5	15.6	29,4
Intraoral	5	15.6	29,4
Lips	7	21.9	41,2
Cheeks	5	15.6	29,4
Eyes	3	9.4	17.7
Nose	5	15.6	29.4

Figure 7. General distribution of maxillofacial soft tissue injuries due to shot wounds (January 2010 to August 2022, n = 17). Note: Of the 17 patients, 15 had characterized soft tissue injuries in 31 facial regions, GSW =Gunshot wound

Additionally, Table 4 indicates that the patients had a slightly higher incidence of lower lip injuries (35.3%) compared to upper lip injuries (23.5%).

Table 4. Detailed distribution of oral and lip soft tissue injuries due to shot wounds (January 2010 to August 2022, n = 17).

Oral and maxillofacial region (detailed)	Relationship of soft tissue injuries/ region	% of patients with impaired region (n =17)
Sublingual/ lingual	4/ 4	23.5/ 23.5
Lower lip/ upper lip	6/ 4	35.3/ 23.5

5. Procedures

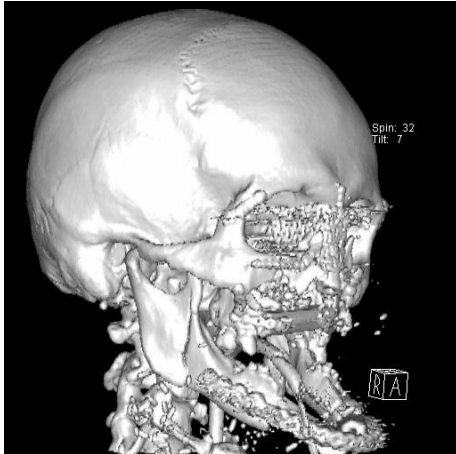


Figure 8. 3D CT reconstruction of the skull and viscerocranium (post-surgery), right-anterior view. A 38-year-old patient attempted suicide with a rifle, resulting in defect of anterior mandibular arch, hard palate, anterior maxilla, and nose. Reconstruction involved a fibula free flap (FFF) for the mandible and floor of the mouth, a radial free forearm flap (RFFF) for upper lip and the maxilla, and in another surgery scapula osseous free flap (SOFF) for the hard palate. Additional reconstructions included local flaps for the lower lip and neck defect, a reverse Karapandzic flap for the upper lip, and a rib graft and frontal forehead flap (FHF) for the nose.

5.1. Primary wound care

This study evaluated the management of soft tissue injuries in 17 patients who had sustained gunshot wounds. Three patients had received treatment for their soft tissue injuries before being transferred to Dubrava Hospital, and one of these cases required revision. Details of primary wound management were reported for twelve patients, while no information was provided for the remaining cases, which either were not described or received flaps for soft tissue healing.

5.2. Tracheotomy

Four patients who had sustained gunshot wounds underwent tracheotomy. Half of these patients had received the procedure before transfer to Dubrava Hospital. No further information was provided regarding the timing or indications for tracheotomy in these cases.

5.3. Mandible reconstruction

Twelve out of 14 patients with mandibular fractures underwent repositioning and osteosynthesis. Plate fixation was used in 8 cases, while one received external fixation, and three had unknown procedures.

In selected cases (Patients 1, 6, 11, and 17), lower vestibular reconstruction was required for mandibular alveolar bone reconstruction due to extensive bone loss or damage. An autogenous bone graft, was used to address this issue.

Six patients with mandibular fractures caused by gunshot wounds were treated with flaps. The radial forearm free flap (RFFF), fibula free flap (FFF), pectoralis major flap (PMF) were utilized. With the RFFF being used three times for all types of fractures and FFF twice for simple fractures (Table 5). PMF was used for skin of the chin reconstruction.

Table 5. Overview of mandibular reconstructive procedures. *S = Symphysis/ Parasymphysis (central unit), B = Body, A = Angle/ Ramus, 2 =bilateral, FFF = Fibula free flap, PMF = Pectoralis major flap, RFFF = Radial free forearm flap*

Patient	Defect location	Defect morphology	Osteosynthesis	Bone graft	Flaps
1	S	Complex	Plate	1	RFFF, FFF
2	S	Simple	Plate	-	-
4	B	Complex	Plate	-	-
5	B	Simple	Plate	-	-
6	S+2B	Complex	Plate	1	PMF
7	B+A	Complex	Plate	-	-
8	2B	Simple	1	-	FFF
9	2B	Simple	1	-	-
10	A	Simple	Plate	-	-
11	S	Simple	-	1	FFF
12	S+A	Simple	-	-	RFFF
15	B+A	Simple	1	-	-
16	S	Complex	Plate	-	-
17	S+B+A	Complex	External fixation	1	RFFF, PMF

5.4. Maxillary and palatine reconstruction

Maxillary and palatine reconstruction can involve reposition and osteosynthesis, which was reported in four cases without the need for grafting. Flap techniques were also used in four cases: the FFF and RFFF for alveolar ridge defects, and the scapula osseous free flap (SOFF) and local mucosal flap for hard and soft palate repairs (Table 6).

Table 6. Overview of maxillary reconstructive procedures. FFF = Fibula free flap, SOFF = Scapula osseous free flap, RFFF = Radial free forearm flap

Patient	Le Fort	Maxillary defect	Osteosynthesis	Flaps	Palatine defect	Flaps
6	-	Alveolar ridge	-	FFF	-	
8	-	Alveolar ridge	1	RFFF	Hard palate	SOFF
9	I/II	-	-	-	Hard palate	
10	-	Maxillary	1	-	Hard palate	Local mucosal flap
11	II	Alveolar ridge	-	-	-	
15	III	-	1	-	-	
16	-	Bilateral maxillary	1	-	-	

5.5. Zygomatic bone and orbital floor reconstruction

Zygomatic osteosynthesis was conducted on seven patients with zygomatic fractures. Orbital floor reconstruction was performed using a titanium mesh in one patient, while the method used in the other four patients is unknown. No flaps were utilized in the procedures (Table 7).

Table 7. Overview of zygomatic and orbital reconstructive procedures.

Patient	Defect location	Osteosynthesis	Orbit reconstruction
4	Zygomatic	1	-
6	Orbital	-	Titan Mesh
8	Zygomatic + orbital	1	1
13	Zygomatic + orbital	1	1
15	Zygomatic + orbital	1	1
16	Orbital	-	1
17	Zygomatic	1	-

5.6. Nasal bone reconstruction

The study documented three cases of nasal bone injury, including two patients with complete bone loss. Treatment involved rib cartilage bone grafts and paramedial forehead flaps (FHF) to address the associated soft tissue injury. However, the treatment approach for patient 7, who presented with a nasal bone fracture, remains unknown (Table 8).

Table 8. Overview of nasal bone reconstructive procedures, FHF = Forehead flap

Patient	Nasal bone defect	Bone Graft	Flaps
6	Complete loss	Rib cartilage	FHF
7	Fracture	-	-
8	Complete loss	Rib cartilage	FHF

5.7. Soft tissue reconstruction

Table 9 demonstrates the use of various flaps for covering different maxillofacial soft tissue regions. Some flaps were versatile and employed for multiple regions. The osteocutaneous flaps (FFF, RFFF) were commonly used for jaw, chin, cheek, lower lip, and floor of mouth reconstruction. FHF was frequently utilized for nose and upper lip reconstruction. Various flaps were employed for lower lip and upper lip reconstruction. Nasolabial flap was used for nostril reconstruction in one case. Additional procedures were performed for soft tissue injuries in the mouth (rima oris plasty, mouth angle suspension, commissurotomy), chin (mentolabial sulcus plasty), and eye (medial canthopexy, orbit enucleation).

Table 9. Soft tissue reconstruction of Maxillofacial and oral regions, ALT = Anterolateral thigh flap, FHF = Forehead flap, FFF = Fibula free flap, PMF = Pectoralis major flap, RFFF = Radial free forearm flap

Maxillofacial region	Flaps
Chin	ALT, FFF (2x), PMF, RFFF, rotational flap
Jaw	FFF, PMF, RFFF
Cheeks	cervicofacial flap, PMF, RFFF,
Nose	FHF (2x), nasolabial flap
Floor of mouth	FFF (3x), PMF, RFFF
Upper Lip	Abbe flap, FHF, reverse karapandzic flap (2x)
Lower Lip	ALT(2x), FFF (3x), PMF (2x), RFFF (3x), nasolabial flap, advancement flap (V-Y), rotational flap, transposition flap

Discussion

Our retrospective analysis at Department of Maxillofacial Surgery, University Hospital Dubrava provides valuable insights into the demographic characteristics, clinical features, and surgical approaches for facial reconstruction in gunshot wound (GSW) injuries. The findings from our study are largely consistent with previous literature on facial reconstruction following GSWs, reinforcing the existing knowledge in this field. In this discussion, we will further delve into the implications of our findings and highlight the importance of a comprehensive and multidisciplinary approach to managing these injuries.

1. Demographic characteristics and clinical features:

Our study found that 70.1% of patients with gunshot injuries had self-inflicted gunshot wounds (SIGSW) motivated by suicide. All patients in our study were male, consistent with previous research showing that men are more likely to use firearms for suicide attempts compared to women, who tend to choose less violent methods (34–36).

The average age of patients in our study, which falls in their early forties, aligns with previous research (11,18,34,35) indicating that individuals in this age group are more prone to facial GSW injuries. Understanding the demographic characteristics of patients can help inform targeted interventions and prevention strategies.

Regarding the firearms used, rifles were the most frequently utilized, followed by shotguns, among individuals with SIGSW. This finding is consistent with a previous study by Nordenram and Freiberg in 1972, where rifles were used by ten individuals and shotguns by five individuals in a sample of 15 SIGSW patients (35). Handguns were not employed by any of the patients in that study.

In a more recent study conducted by Quenzer in the United States in, which reviewed a larger sample size of 7,828 SIGSW injuries, 82% of the cases involved handguns, while the remaining 18% involved other specified firearms such as rifles or shotguns. This study also revealed a higher mortality rate for SIGSW injuries caused by handguns compared to injuries caused by all other types of firearms combined (11).

The discrepancy in mortality rates may be due to the increased difficulty in successfully performing a suicide attempt using a rifle or shotgun, possibly because of factors such as the length of the firearm barrel and the recoil associated with these types of weapons. As a result, individuals who utilize rifles or shotguns for self-harm may more frequently require maxillofacial surgery for reconstructive interventions.

2. Hospitalization history:

Examining the hospitalization history, we observed that the first and third quarters of the year had the highest incidence of surgeries for GSWs to the face. Additionally, the years 2010, 2011, and 2018 had the highest frequency of surgeries, with three cases reported each year. These variations in hospitalizations may reflect underlying factors such as seasonal patterns or fluctuations in societal circumstances. Among the patients, the hospitalization duration for the first stay ranged from four days to 105 days, with an average length of 29.6 days.

3. Importance of mental health support and suicide prevention:

Nordenram and Freiberg observed that 26.7% of patients (4 out of 15) who underwent facial reconstruction after SIGSW later died by suicide (35). These findings underscore the critical need for comprehensive mental health support, suicide prevention measures, and effective psychiatric care for individuals affected by self-inflicted gunshot wounds, given the high prevalence of re-attempts associated with SIGSW (34).

Moreover, Vranković et al. noted a significant increase in self-inflicted gunshot brain injuries during and after the Croatian war (1991-1996), with nearly six times more cases compared to the preceding peace time period (1985-1990), highlighting the influence of external factors such as war conditions and firearm availability on the incidence of SIGSW (34).

Additionally, a study conducted by Mai et al. (2019) investigated the effects of gunshot wounds on 77 patients and identified several common complications and long-term consequences. These included bone segment loss, paresthesia (abnormal sensations like tingling or numbness), infection, facial nerve paralysis, limitations in masticatory function (chewing ability), malocclusion (misalignment of teeth), and recurrent sinusitis. The study emphasized the importance of a multidisciplinary approach to care, involving professionals from fields such as psychology and psychiatry, due to the significant psychological impact these injuries can have on individuals. From a financial perspective, gunshot wounds result in varying lengths of medical leave, with an average duration of 11.7 months (18).

4. Surgical approaches and reconstruction techniques:

4.1. Mandible reconstruction

Our study identified the following as the most commonly observed facial fractures: mandible fractures, maxillary fractures, and zygomatic-orbital fractures. These findings are consistent with previous research (18,35,37).

However, in a separate study by Hollier et al. (2001), zygomatic and orbital fractures (34.5% and 26.2% respectively), were slightly more prevalent than mandibular fractures (29.8%), but mandibular fractures had a higher percentage of injuries requiring surgery (76.0%) compared to other fractures (34.5% for zygomatic, 31.8% for orbital, 38.9% for skull, and 50% for nasoethmoid (37).

The higher incidence of mandible fractures requiring surgical intervention suggests the need for specialized approaches and techniques in mandibular reconstruction. The analysis of mandible fractures revealed that the central unit (symphysis/parasymphysis) accounted for 33% of fractures, while the mandible body was involved in 38% of cases. These findings align with a pictorial review by Nardi et al., which found higher fracture rates in the medial mandible and lower rates in the distal parts in traumatic injuries (38).

Reconstruction of mandibular fractures often involves repositioning and osteosynthesis, with reconstructive plate fixation being the most commonly used method. In cases with bone loss or damage, bone grafting may be necessary for mandibular alveolar bone reconstruction. An autogenous bone graft was observed in four patients.

A 2018 review by Vaca et al. proposed different treatment approaches for mandibular defects based on their size and complexity. For very small defects (less than 5 cm) without mucosal tissue loss, bone grafting was recommended. However, larger and more complex defects require the use of osteocutaneous free tissue flaps (39).

According to Schulz et al.'s 2015 algorithm, osteocutaneous free tissue flaps can be used for reconstruction. For smaller defects, the deep circumflex iliac artery (DCIA) flap with or without a vein graft is recommended. On the other hand, larger defects and those involving the mandibular condyle are better suited for the fibula osteoseptocutaneous (FOSEC) flap, also known as the fibula free flap (FFF) (40).

In mandibular reconstruction, the FFF and radial forearm free flap (RFFF) are commonly used, according to Vaca. The FFF offers advantages such as enabling the placement of osseointegrative dental implants and improving the success rates of dental rehabilitation (39).

In our study, the flap choices included the RFFF three times, fibula, FFF two times, pectoralis major flap (PMF) with reconstruction plate two times. Although no clear pattern linking fracture location and morphology to flap selection was evident, the preference for RFFF and FFF aligns with existing literature.

4.2. Maxillary and palatine reconstruction

Maxillary and palatine defects resulting from GSWs were primarily addressed through repositioning and osteosynthesis without the need for grafting in most cases. However, alveolar ridge defects required the use of the FFF and RFFF. For repairing hard and soft palate defects, the scapula osseous free flap (SOFF) and local mucosal flap were employed. Schulz et al. proposed an algorithm in 2015 for maxillary defects, taking into consideration variables such as the type of fracture, size of the bone support deficiency, pedicle length, and the need for skin or mucosal lining. This algorithm can guide in choosing between the deep circumflex iliac artery (DCIA) flap and FFF for future maxillary reconstruction (40).

4.3. Zygomatic bone and orbital floor reconstruction

Reconstruction of zygomatic bone and orbital floor fractures typically involves direct repositioning and fixation. In addition, the use of a titanium mesh is common for orbital floor reconstruction. These approaches highlight the significance of achieving anatomical precision and stability to restore the integrity of the zygomatic and orbital regions (37).

4.4. Nose reconstruction

For nasal bone reconstruction and repair of soft tissue injuries, rib cartilage bone grafts and paramedial forehead flaps (FHF) were commonly used. These techniques have been documented in previous literature and have shown to be effective in addressing nasal bone and soft tissue defects (39,41). Additionally, nasolabial flaps were employed specifically for nostril reconstruction.

4.5. Additional surgical procedures

In addition to the aforementioned procedures, several other surgical interventions were performed to address soft tissue injuries in the mouth. These included rima oris plasty, commisurotomy, and mouth angle suspension. These procedures are crucial for restoring both functional and cosmetic aspects of the lips, especially in cases involving facial nerve paralysis and sagging of the lips at the corner of the mouth (42).

Managing periorbital injuries requires a meticulous assessment of the level of injury and individual repair of the anterior and posterior lamella. Sutures placed at the gray line and lash line in an everted fashion are crucial for restoring the contour of the eyelid margin. Repairing conjunctival injuries may involve the use of fine resorbable sutures, while cannalicular injuries may require repair using a silastic lacrimal stent. These techniques ensure optimal outcomes and functional restoration (20).

5. Limitations and future directions:

It is important to acknowledge that our study was conducted at a single hospital and had limitations inherent to its retrospective design. Therefore, further research with larger sample sizes and multiple healthcare institutions is necessary to expand upon our findings.

In addition, future research should aim to investigate long-term outcomes, including functional and aesthetic results, quality of life, and psychological well-being of individuals undergoing facial reconstruction after GSW injuries. Prospective studies that incorporate standardized assessment tools and long-term follow-up will provide a more comprehensive understanding of the effectiveness of different surgical approaches and interventions in this context.

Conclusion

In conclusion, our study highlights the demographic characteristics, clinical features, and surgical approaches for facial reconstruction in GSW injuries. The predominance of male patients and the high prevalence of self-inflicted gunshot wounds underscore the urgent need for comprehensive mental health support and suicide prevention measures in this population. The findings from our study emphasize the importance of a comprehensive and multidisciplinary approach, as well as further research, to optimize outcomes and provide effective treatment for individuals with facial GSW injuries.

Acknowledgments

First, I would like to express deep and sincere gratitude to my mentor Prof. Dr. Emil Dediol. He not only provided valuable guidance and feedback on this research, but also inspired me with his passion for the topic. I am grateful for his unwavering support and willingness to answer my questions throughout the project.

Furthermore, I would like to acknowledge the contributions of the committee members, Prof. Dr. Ivica Lukšić (Head of the Committee) and Doc. Dr. Željko Orihovac (second member of the Committee). Their insightful feedback and critical evaluation have been instrumental in improving the quality of this work.

I would also like to thank Zagreb University, School of Medicine, for providing me with the opportunity to pursue my medical studies and for continuously imparting valuable knowledge and skills.

Finally, I owe a debt of gratitude to my family that has been the foundation of my success and unwavering support system throughout my academic journey.

References

1. Whitaker IS, Karoo RO, Spyrou G, Fenton OM. The Birth of Plastic Surgery: The Story of Nasal Reconstruction from the Edwin Smith Papyrus to the Twenty-First Century: *Plast Reconstr Surg*. 2007 Jul;120(1):327–36.
2. Thomas R, Fries A, Hodgkinson D. Plastic Surgery Pioneers of the Central Powers in the Great War. *Craniomaxillofacial Trauma Reconstr*. 2019 Mar;12(1):1–7.
3. Wolfaardt J, Sugar A, Wilkes G. Advanced technology and the future of facial prosthetics in head and neck reconstruction. *Int J Oral Maxillofac Surg*. 2003 Apr;32(2):121–3.
4. Janković S, Buca A, Busić Z, Zuljan I, Primorac D. Orbitocranial war injuries: report of 14 cases. *Mil Med*. 1998 Jul;163(7):490–3.
5. Akadiri OA. Evolution and Trends in Reconstructive Facial Surgery: An Update. *J Maxillofac Oral Surg*. 2012 Dec;11(4):466–72.
6. Kim JY, Xin X, Moioli EK, Chung J, Lee CH, Chen M, et al. Regeneration of Dental-Pulp-like Tissue by Chemotaxis-Induced Cell Homing. *Tissue Eng Part A*. 2010 Oct;16(10):3023–31.
7. Unukovych D. Surgical services during the war in Ukraine: challenges and call for help. *Br J Surg*. 2022 Aug 16;109(9):785–6.
8. Jones NF, Johnson JT, Shestak KC, Myers EN, Swartz WM. Microsurgical Reconstruction of the Head and Neck: Interdisciplinary Collaboration Between Head and Neck Surgeons and Plastic Surgeons in 305 Cases: *Ann Plast Surg*. 1996 Jan;36(1):37–43.
9. Kruse-Lösler B, Presser D, Meyer U, Schul C, Luger T, Joos U. Reconstruction of large defects on the scalp and forehead as an interdisciplinary challenge: Experience in the management of 39 cases. *Eur J Surg Oncol EJSO*. 2006 Nov;32(9):1006–14.
10. Pushpakumar SB, Barker JH, Soni CV, Joseph H, Van Aalst VC, Banis JC, et al. Clinical considerations in face transplantation. *Burns*. 2010 Nov;36(7):951–8.
11. Quenzer F, Givner A, Dirks R, Coyne CJ, Ercoli F, Townsend R. Self-Inflicted Gun Shot Wounds: A Retrospective, Observational Study of U.S. Trauma Centers. *West J Emerg Med*. 2021 May 19;22(3):518–24.
12. Marur T, Tuna Y, Demirci S. Facial anatomy. *Clin Dermatol*. 2014 Jan;32(1):14–23.
13. Oliveira-Campos GH, Lauriti L, Yamamoto MK, Júnior RC, Luz JGC. Trends in Le Fort Fractures at a South American Trauma Care Center: Characteristics and Management. *J Maxillofac Oral Surg*. 2016 Mar;15(1):32–7.
14. Fraioli RE, Branstetter BF, Deleyiannis FWB. Facial Fractures: Beyond Le Fort. *Otolaryngol Clin North Am*. 2008 Feb;41(1):51–76.
15. Moriscot A, Miyabara EH, Langeani B, Belli A, Egginton S, Bowen TS. Firearms-related skeletal muscle trauma: pathophysiology and novel approaches for regeneration. *Npj Regen Med*. 2021 Mar 26;6(1):17.

16. Lichte P, Oberbeck R, Binnebösel M, Wildenauer R, Pape HC, Kobbe P. A civilian perspective on ballistic trauma and gunshot injuries. *Scand J Trauma Resusc Emerg Med.* 2010;18(1):35.
17. Kaufman Y, Cole P, Hollier LH. Facial Gunshot Wounds: Trends in Management. *Craniofacial Trauma Reconstr.* 2009 May;2(2):85–90.
18. Maia ABP, Assis SG, Ribeiro FML, Pinto LW. The marks of gunshot wounds to the face. *Braz J Otorhinolaryngol.* 2021 Mar;87(2):145–51.
19. Bartlett CS, Helfet DL, Hausman MR, Strauss E. Ballistics and Gunshot Wounds: Effects on Musculoskeletal Tissues: *J Am Acad Orthop Surg.* 2000 Jan;8(1):21–36.
20. Cho DY, Willborg BE, Lu GN. Management of Traumatic Soft Tissue Injuries of the Face. *Semin Plast Surg.* 2021 Nov;35(04):229–37.
21. Michele M, Giuseppe G. *Textbook of Plastic and Reconstructive Surgery Basic Principles and New Perspectives.* Springer International Publishing; 2022: 250, 348-50.
22. Vatsyayan A, Adhyapak AK, Debnath SC, Malik K. Reconstruction and rehabilitation of short-range gunshot injury to lower part of face: A systematic approach of three cases. *Chin J Traumatol.* 2016 Aug;19(4):239–43.
23. Comprehensive Reconstruction of Mandibular Defects with Free Fibula Flaps and Endosseous Implants. *J Diagn Treat Oral Maxillofac Pathol.* 2017 Feb 18;1(1):6–10.
24. Grant WF, Swan KG. Gunshot Wounds of the Orbit: *J Trauma Inj Infect Crit Care.* 1980 Sep;20(9):809–11.
25. Long V, Lo LJ, Chen YR. Facial reconstruction after a complicated gunshot injury. *Chang Gung Med J.* 2002 Aug;25(8):557–62.
26. Saber AY, Hohman MH, Dreyer MA. Basic Flap Design. [Updated 2022 Aug 29]. In: StatPearls [Internet]. Treasure Island (FL): StatPearls Publishing; 2023 [cited 2023 May 2]. Available from: <https://www.ncbi.nlm.nih.gov/books/NBK563252/>.
27. Fagan JJ. Open access atlas of otolaryngology, head and neck operative surgery. Volume 1, Head and neck. Chapter 5 Reconstructive Surgery [Internet]. Cape Town: libretexts; 2017 [cited 2023 Jun 2]. Available from: https://med.libretexts.org/Bookshelves/Anatomy_and_Physiology/Atlas_of_Otolaryngology_Head_and_Neck_Operative_Surgery.
28. Williams CN, Cohen M, Schultz RC. Immediate and Long-Term Management of Gunshot Wounds to the Lower Face: *Plast Reconstr Surg.* 1988 Sep;82(3):433–9.
29. Vayvada H, Menderes A, Yilmaz M, Mola F, Kzlkaya A, Atabey A. Management of Close-Range, High-Energy Shotgun and Rifle Wounds to the Face: *J Craniofac Surg.* 2005 Sep;16(5):794–804.
30. Váscónez HC, Shockley ME, Luce EA. High-energy Gunshot Wounds to the Face: *Ann Plast Surg.* 1996 Jan;36(1):18–25.

31. Gruss JS, Antonyshyn O, Phillips JH. Early Definitive Bone and Soft-Tissue Reconstruction of Major Gunshot Wounds of the Face: *Plast Reconstr Surg*. 1991 Mar;87(3):436–50.
32. Stewart M, Swendseid B, Hammond P, Khatiwala I, Sarwary J, Zhan T, et al. Anastomotic Revision in Head and Neck Free Flaps. *The Laryngoscope*. 2021 May;131(5):1035–41.
33. Ellis III E, Schubert W. Terminology; Mandibular Fractures [Internet]. [cited 2023 May 2]; Available from: <https://surgeryreference.aofoundation.org/cmft/trauma/mandible/further-reading/terminology>.
34. Vranković Dj, Splavski B, Hećimović I, Glavina K, Muršić B, Blagus G, et al. Self-inflicted gunshot wounds to the head during the war and post-war period. *Injury*. 1998 Jun;29(5):369–73.
35. Nordenram Å, Freiberg N. Suicidal gunshot wounds resulting in severe maxillofacial injury. *Int J Oral Surg*. 1974 Jan;3(1):29–33.
36. World Health Organization. Suicide Prevention [Internet]. 1968 [cited 2023 Jun 3]. Available from: <https://apps.who.int/iris/handle/10665/37821>
37. Hollier L, Grantcharova EP, Kattash M. Facial gunshot wounds: A 4-year experience. *J Oral Maxillofac Surg*. 2001 Mar;59(3):277–82.
38. Nardi C, Vignoli C, Pietragalla M, Tonelli P, Calistri L, Franchi L, et al. Imaging of mandibular fractures: a pictorial review. *Insights Imaging*. 2020 Dec;11(1):30.
39. Vaca EE, Bellamy JL, Sinno S, Rodriguez ED. Management of High-energy Avulsive Ballistic Facial Injury: A Review of the Literature and Algorithmic Approach. *Plast Reconstr Surg - Glob Open*. 2018 Mar;6(3):1693.
40. Schultz BD, Sosin M, Nam A, Mohan R, Zhang P, Khalifian S, et al. Classification of Mandible Defects and Algorithm for Microvascular Reconstruction: *Plast Reconstr Surg*. 2015 Apr;135(4):743–54.
41. Chaiyasate K, Gupta R, Boudiab EM, Vega D, Hart J, Nossoni F, et al. Comprehensive Treatment and Reconstructive Algorithm for Functional Restoration after Ballistic Facial Injury. *Plast Reconstr Surg - Glob Open*. 2022 Jul 27;10(7):4453.
42. Momeni Roochi M, Razmara F. Maxillofacial gunshot injures and their therapeutic challenges: Case series. *Clin Case Rep*. 2020 Jun;8(6):1094–100.

Biography

Leander Stein was born on the 24th of June 1994 in Gräfelfing, Germany, to Dieter (born in 1955) and Beate Stein (born in 1967). His father is an artist in Munich, and his mother works as a business administration specialist. He is the eldest child in the family and has a younger sister named Pamina Stein (born in 1996).

Leander developed an early interest in medicine, and in October 2017, he graduated from the Technical University of Munich (TUM) with a Bachelor's degree in sport science. Later that year, he was accepted into the medical faculty at the University of Zagreb, where he pursued his medical studies while concurrently writing his Bachelor's thesis, "A biomechanical study of forearm muscle activity during the golf swing in relation to handicap."

During his holidays, Leander worked as a research assistant in the department for bone tumors and soft tissue sarcomas at the Ludwig-Maximilian University (LMU) hospital, clinic Großhadern, in Munich. His main interest lies in surgeries, particularly in the field of plastic and reconstructive surgery. He is currently completing his rotations in the plastic, reconstructive, hand, and burn surgery department at Klinikum Bogenhausen under the guidance of Prof. Dr. med. Milomir Ninkovic.

In addition to his medical pursuits, Leander enjoys a variety of hobbies, including golf, gymnastics, Olympic weightlifting, crossfit, swimming, volleyball, skiing, and spending time with his family and friends. He is fluent in German and English and has a working knowledge of Croatian.