

# Osteochondral transplantation in the knee

---

**Tsadić, Coral**

**Master's thesis / Diplomski rad**

**2023**

*Degree Grantor / Ustanova koja je dodijelila akademski / stručni stupanj:* **University of Zagreb, School of Medicine / Sveučilište u Zagrebu, Medicinski fakultet**

*Permanent link / Trajna poveznica:* <https://um.nsk.hr/um:nbn:hr:105:585909>

*Rights / Prava:* [In copyright](#)/[Zaštićeno autorskim pravom.](#)

*Download date / Datum preuzimanja:* **2025-03-14**



*Repository / Repozitorij:*

[Dr Med - University of Zagreb School of Medicine Digital Repository](#)



**UNIVERSITY OF ZAGREB**

**SCHOOL OF MEDICINE**

**Coral Tsadik**

**Osteochondral Transplantation**

**In The Knee**



Graduate thesis

Zagreb, 2023

This graduation paper was realized at the Department of Orthopedic Surgery, School of Medicine, University of Zagreb, and Clinical Hospital Center Zagreb, under the supervision of Prof. dr. sc. Mislav Jelić and it was submitted for evaluation in the academic year of 2022/2023.

Mentor of the graduate thesis; Prof. dr. sc. Mislav Jelić

## ABBREVIATIONS

- ACL: Anterior Cruciate Ligament
- PCL: Posterior Cruciate Ligament
- MCL: Medial Collateral Ligament
- LCL: Lateral Collateral Ligament
- ROM: Range Of Motion
- OAT: Osteochondral Autograft Transfer
- OATS: Osteochondral Autograft Transfer System
- OCA: Osteochondral Allograft Transplant
- OCD: Osteochondral Defect
- ST: Sulcus Terminalis
- MRI: Magnetic resonance imaging
- BMI: Body Mass Index
- LVP: Lateral Viewing Portal
- IP: Inferior Pole
- LBP: Lateral Border of the Patella
- RS: Recipient Site
- MFC: Medial Femoral Condyle
- DG: Donor Graft

## Table of Contents

<b>1. ABSTRACT</b>	<b>1</b>
<b>2. SAŽETAK</b>	<b>2</b>
<b>3. Introduction</b>	<b>4</b>
<b>4. Anatomy of the knee</b>	<b>6</b>
<b>5. Knee biomechanics and stability</b>	<b>9</b>
<b>6. History, Exam, Imaging</b>	<b>11</b>
<b>7. Indications</b>	<b>14</b>
7.1. Osteochondral Autograft Transplantation (OAT)	15
7.2. Osteochondral Allograft Transplantation (OCA)	17
<b>8. Contraindications</b>	<b>19</b>
8.1. Osteochondral Autograft Transplantation (OAT)	19
8.2. Osteochondral Allograft Transplantation (OCA)	20
<b>9. Techniques</b>	<b>21</b>
9.1. Osteochondral Autograft Transplantation (OAT)	21
9.2. Osteochondral Allograft Transplantation (OCA)	29
<b>10. Failure and Complications</b>	<b>33</b>
10.1. Osteochondral Autograft Transplantation (OAT)	33
10.2. Osteochondral Allograft Transplantation (OCA)	33
<b>11. Conclusion</b>	<b>35</b>
<b>12. Acknowledgment</b>	<b>36</b>
<b>13. References</b>	<b>37</b>
<b>14. Biography</b>	<b>41</b>

## 1. ABSTRACT

**Keywords: knee joint damage, cartilage restoration, Autografts and allografts, Patient selection**

**Author: Coral Tsadik**

Osteochondral transplantation is a promising surgical technique for the treatment of chondral defects in the knee joint, particularly in young, active individuals. The procedure involves the transfer of healthy osteochondral tissue from a donor site to the damaged area, facilitating the restoration of joint function and pain relief.

Chondral defects, often a result of trauma or degenerative joint diseases, are prevalent in the 15-55 age group, with epidemiological data indicating a higher incidence among athletes and physically active individuals (1). In cases where conservative management and other surgical interventions have proven ineffective, osteochondral transplantation offers a viable alternative.

The current gold standard for osteochondral transplantation is the osteochondral autograft transfer system (OATS), which utilizes autologous grafts harvested from a low-weight-bearing area of the patient's own knee. This technique boasts several advantages, including reduced immunogenicity and optimal graft integration.

However, it is limited by the availability of donor tissue and potential donor site morbidity. Despite these limitations, osteochondral transplantation has demonstrated success in terms of pain relief, functional improvement, and overall patient satisfaction. Further research is needed to optimize patient selection criteria, refine surgical techniques, and explore the potential of allografts and tissue-engineered constructs to overcome current challenges in the field.

## 2. SAŽETAK

**Ključne riječi: oštećenje zgloba koljena, obnova hrskavice, autotransplantati i alografti, odabir pacijenata**

**Autor: Coral Tsadik**

Osteohondralna transplantacija je obećavajuća kirurška tehnika za liječenje hondralnih defekata u zglobu koljena, osobito kod mladih i aktivnih osoba. Postupak uključuje prijenos zdravog osteohondralnog tkiva s donorskog mjesta na oštećeno područje, čime se olakšava ponovna uspostava funkcije zgloba i ublažavanje boli. Hondralni defekti, koji se često pojavljuju kao posljedica traume ili degenerativnih bolesti zglobova, prevladavaju u dobnoj skupini od 15 do 55 godina, a epidemiološki podaci ukazuju na veću učestalost među sportašima i tjelesno aktivnim osobama (1). U slučajevima u kojima su se konzervativno liječenje i druge kirurške intervencije pokazale neučinkovitim, osteohondralna transplantacija nudi održivu alternativu.

Trenutačni zlatni standard za osteohondralnu transplantaciju je sustav za prijenos osteohondralnog autotransplantata (OATS), koji koristi autologe transplantate prikupljene iz nenosivog dijela pacijentovog vlastitog koljena. Ova tehnika ima nekoliko prednosti, uključujući smanjenu imunogenost i optimalnu integraciju presatka. Međutim, ograničen je dostupnošću donorskog tkiva i mogućim morbiditetom na mjestu presađivanja. Unatoč ovim ograničenjima, osteohondralna transplantacija je pokazala uspjeh u smislu ublažavanja boli, funkcionalnog poboljšanja i ukupnog zadovoljstva pacijenata. Potrebna su daljnja istraživanja kako bi se optimizirali kriteriji odabira pacijenata, usavršile kirurške tehnike i istražio

potencial alografta i konstrukta napravljenih tkivnim inženjeringom za prevladavanje trenutnih izazova na terenu.



### 3. Introduction

Osteochondral transplantation in the knee has emerged as an increasingly popular and effective treatment option for chondral defects, providing pain relief and functional improvement in patients with joint injuries or degenerative conditions.

There are several main types of osteochondral transplantation procedures, including mosaicplasty, osteochondral autograft transfer system (OATS), and osteochondral allograft transplantation. Each technique involves the transfer of osteochondral tissue to the affected area, aiming to restore the joint surface and promote integration with the surrounding cartilage.

A critical distinction exists between osteochondral autograft transplantation (OAT) and osteochondral allograft transplantation (OCA). OAT involves harvesting healthy osteochondral tissue from a non-weight-bearing region of the patient's own knee, whereas allograft transplantation utilizes donor tissue from a cadaveric source. Both methods have demonstrated clinical success, but they differ in terms of graft availability, immune response, and integration potential. (2)

In this thesis paper, we will delve deeper into the procedural intricacies of osteochondral transplantation, focusing on the indications and contraindications of the technique. We will also address potential complications associated with the procedure, ranging from graft failure to infection, and key conclusions drawn from the existing literature.

<b>Advantages</b>	<b>Disadvantages</b>
Mature hyaline cartilage	Limited quantity
No chance of immune response	Donor site morbidity
Immediate fill of lesion	Possibly > 1 surgical site
No graft availability concerns	Limited lesion size
Addresses subchondral and chondral layer	

Table 1: Summary of the Advantages and Disadvantages of OATS (2).

<b>Advantages</b>	<b>Disadvantages</b>
Mature hyaline cartilage	Immunogenicity concerns
No limit to size of donor graft	Banked tissue therefore less cell viability
Immediate fill of lesion	Difficult to procure and store
Addresses subchondral and chondral layer	Additional expense
No donor site morbidity	Possible graft size mismatching

Table 2: Summary of the Advantages and Disadvantages of OCA (2).

#### 4. Anatomy of the knee

In the human body, the knee has the biggest and most superficial synovial joint. It is primarily categorized as a pivotal-hinge joint with a unique variety of movements that permit flexion and extension. Yet, this kind of joint also combines rolling, gliding, and rotating about a vertical axis. Running, walking, and jumping all require the use of the knee to support the body's weight in both horizontal and vertical directions.

Many loading scenarios are handled by the knee while maintaining stability and control. It is made up of two bony articulations: the femur and tibia articulation supports the majority of the body's weight, while the patella and femur articulation transmits forces generated by the quadriceps femoris muscle contraction frictionlessly over the knee. The femorotibial joint and the patellofemoral joint are the knee's two primary joints and allow for three separate planes of motion (sagittal, transverse, and frontal). This provides a range of motion with multiple degrees of freedom, including flexion, extension (sagittal planes), internal and external rotation (transverse plane), and varus and valgus stress (frontal plane). The knee is vulnerable to injuries because of its location between the body's two longest lever arms, the femur and tibia, and because it bears weight. (3,4)

Various structures exist within the knee joint, including ligaments, menisci, and connecting bursae. These components provide stability and support to the knee joint due to the misalignment of the articular surfaces. The two primary ligaments in the knee are the anterior cruciate ligament (ACL) and the posterior cruciate ligament (PCL). The ACL, which is the most commonly injured knee ligament, along with the PCL, plays a crucial role in maintaining knee stability. Additionally, the lateral

collateral ligament (LCL) and medial collateral ligament (MCL) contribute to the overall integrity of the knee joint. (5,6)

The anterior cruciate ligament (ACL) is one of the two cruciate ligaments responsible for stabilizing the knee joint. It is a robust structure composed of connective tissue and collagenous fibers, extending from the anteromedial aspect of the intercondylar region of the tibial plateau posteromedially to the lateral femoral condyle. The ACL is divided into two bundles: the anteromedial bundle and the posterolateral bundle.

Together with the posterior cruciate ligament (PCL), the ACL forms an "X" within the knee, functioning to limit excessive forward or backward movement of the tibia relative to the femur during flexion and extension. Furthermore, the ACL plays a critical role in stabilizing the knee during rotation under varus or valgus stress. (7)

The medial and lateral meniscus, which are situated between the femur and tibia, are two cartilage structures found in the knee. The menisci are crescentic plates that make up the articular surface and are made of fibrocartilage. They contribute to shock absorption, enabling the articulation between the flat tibial plateau and rounded femoral condyles to be more effective. (5,6)

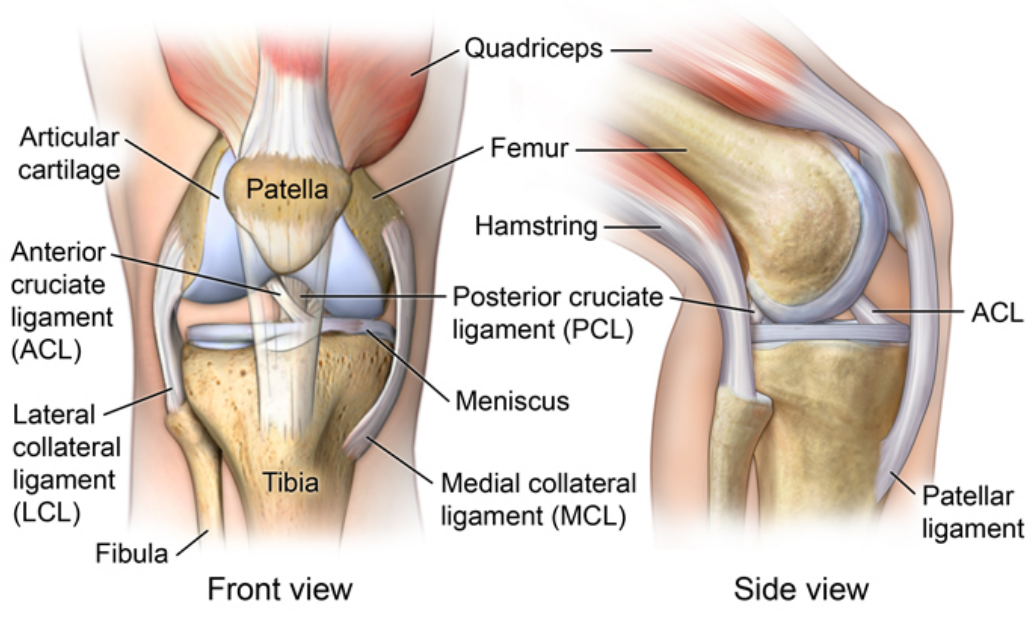


Figure 1: Anatomy of the Knee (8)

## 5. Knee biomechanics and stability

The knee joint is a complex synovial joint with tibiofemoral and patellofemoral articulations. Since it must have a large ROM and be able to sustain strong forces, it is put under a lot of strain. It also connects the two longest bones in the body. Thus, these independent levers can place a lot of strain on the ligaments that provide stability.

The tibia and femur surfaces are not as closely aligned as those of other joints, such as the hip, yet the knee is nevertheless said to have a range of motion with multiple degrees of freedom. This indicates that the knee joint may move in three dimensions, including abduction, adduction, flexion, extension, internal rotation, anterior/posterior draw, medial/lateral shift, and compression/distraction. These degrees of freedom can be assessed as supplementary motions. Hence, even though the knee may flex, extend, and also provide some rotation, it requires these 6 degrees of freedom to do so. (9)

Stability of the joint is governed by a combination of static ligaments, dynamic muscular forces, meniscocapsular aponeurosis, bony topography, and joint load. (5)

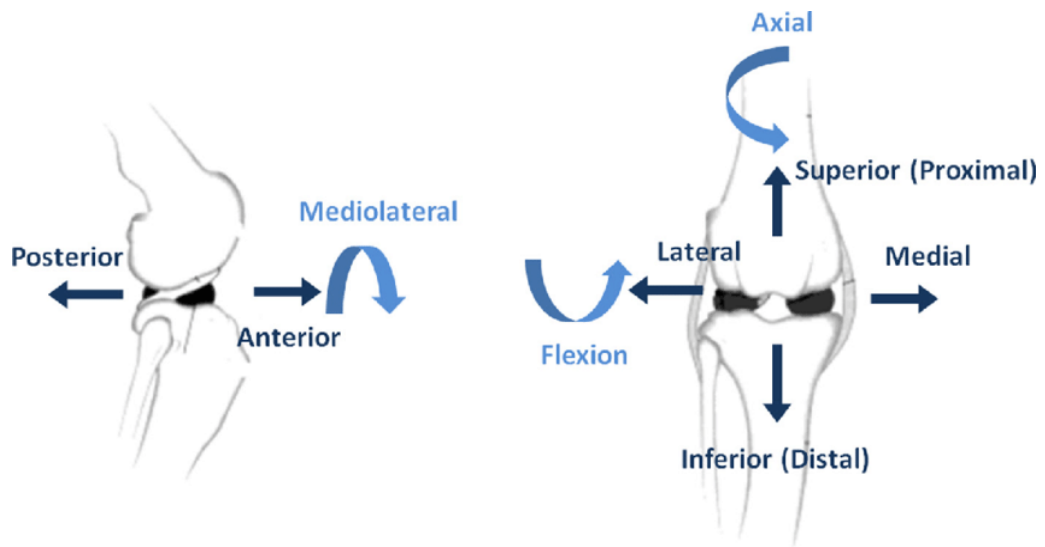


Figure 2: Multidimensional Range of Motion: Visualizing the Complex Movements of the Knee Joint(10)

## 6. History, Exam, Imaging

Individuals with cartilage abnormalities frequently have a history of previous knee surgery or damage. Localized knee pain and joint swelling are typical symptoms that are frequently made worse by exercise. Patients could experience "catching," "locking," and "giving way" as mechanical symptoms.

Patients often retain an intact range of motion during a physical examination, and effusion is frequently seen. The afflicted compartment is frequently sensitive to palpation, and there might be catching or pinching there. Due to the chronic nature of the illness, quadriceps atrophy is frequently observed. It is usual to have loose bodies from chondral fragments, and they may be accompanied by locking or a restricted range of motion.

Weight-bearing radiographs are a current imaging technique. A weight-bearing lateral, skiers' or notch, anteroposterior, and view of the knee is acquired (Fig. 3). A sunrise view is obtained to evaluate the patellofemoral joint. To assess the mechanical axis for any varus or valgus deformity that may predispose the patient to chondral injury, bilateral long-leg alignment radiographs are taken (Fig. 3).

For preoperative planning, recent knee magnetic resonance imaging is essential. The best way to determine the size of the defect and check for cysts or edema in the subchondral bone before surgery, which may necessitate bone grafting, is with T2 weighted magnetic resonance imaging (Fig. 4).



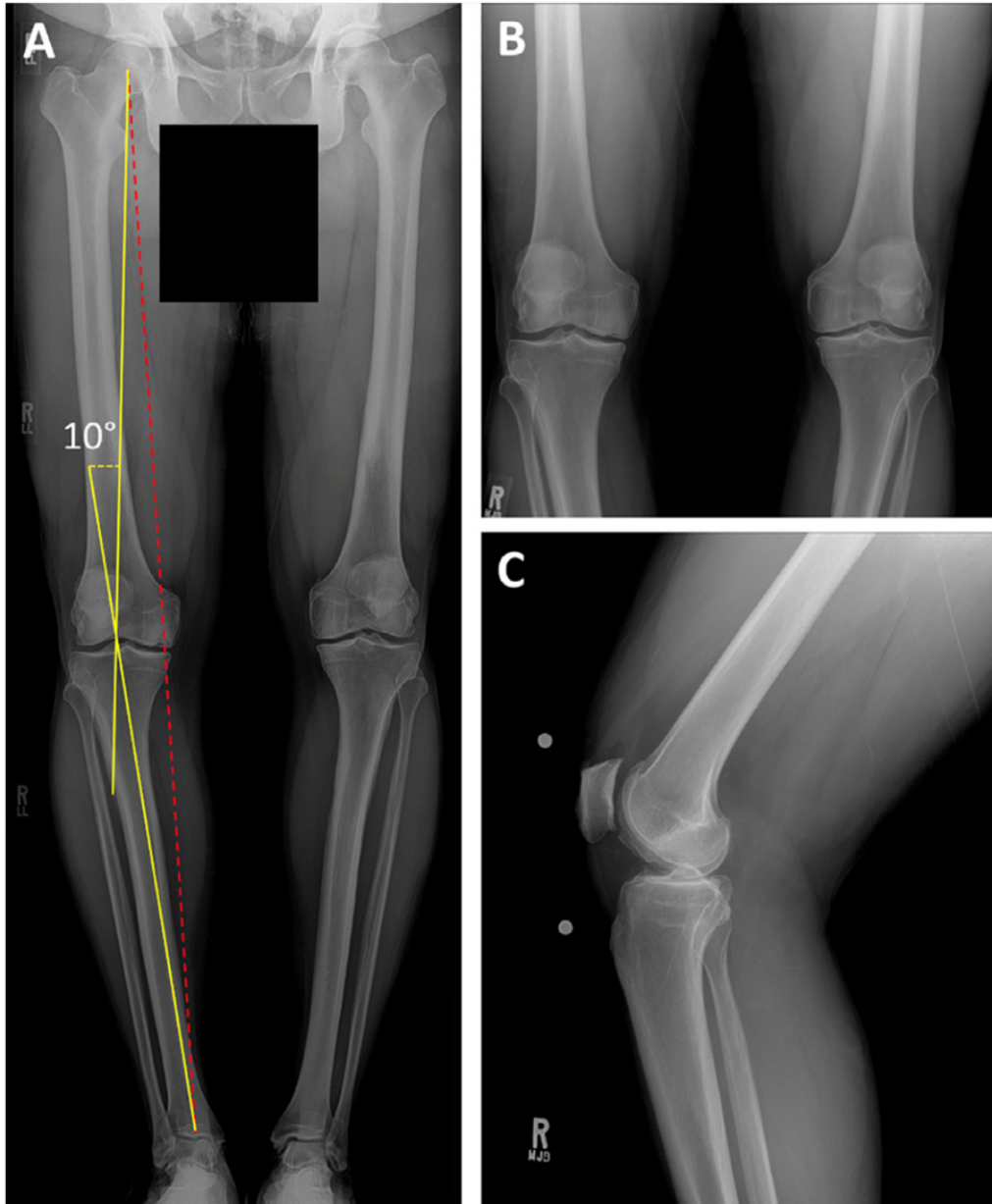


Figure 3: Preoperative radiographs (A) A representative standing weight-bearing radiograph showing a varus deformity that predisposes the patient to medial compartment osteochondral disease to assess sagittal alignment. (B) An example of a standing anteroposterior radiograph of both knees, perhaps demonstrating an osteochondral lesion of the right medial femoral condyle. Right knee lateral radiograph (C) (11)

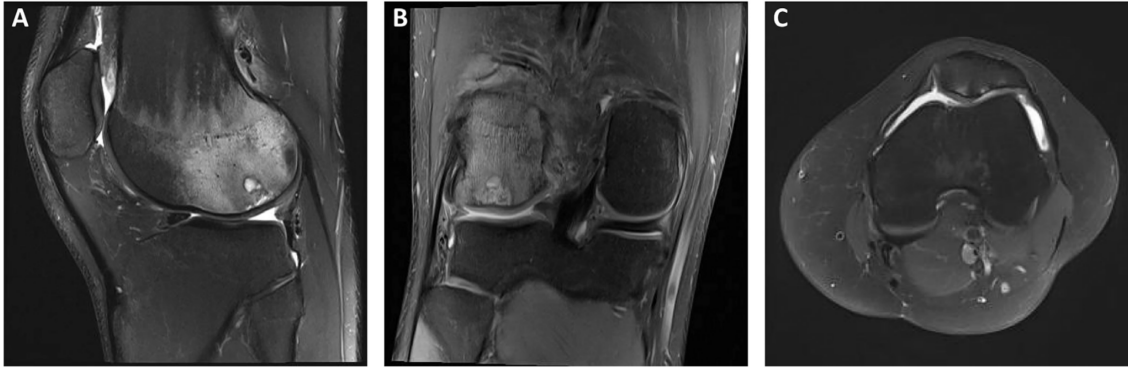

Figure 4: Right knee preoperative magnetic resonance imaging. T2 weighted sagittal (A) and coronal (B) MRI pictures showing subchondral edema and a localized chondral defect in the posterior lateral femoral condyle. (C) A focal chondral defect of the medial patellar facet may be seen in the T2 weighted axial MRI picture (11)

## 7. Indications

Young, energetic patients are frequently affected by cartilage abnormalities, which can result in incapacitating injuries and cause intense pain and edema (11). Since hyaline cartilage is avascular, chondral injuries have a low chance of healing and require complicated medical care (12–14). Making treatment selections requires taking into account a variety of variables, including the location of the lesion, the size and depth of the defect, and the unique patient features of age and level of activity (15,16,16,17).

The current method of decision-making advances linearly from non-operative to surgical treatment, including palliative, reparative, or restorative surgery, based on the geometry of the defect and the features of the patient (12,18).

In general, non-operative treatment is used for small (0.5-1 cm<sup>2</sup>) and/or superficial (grade I or II) lesions as well as for diffuse degenerative articular disease. Activity moderation, maintaining a healthy weight, over-the-counter non-steroidal anti-inflammatory drugs, physical therapy, and occasionally intra-articular corticosteroid or viscosupplementation injections make up non-operative care (12,15,19).

## **7.1. Osteochondral Autograft Transplantation (OAT)**

The following are some examples of the procedure's indications: (15,20–27)

1. Younger than 50 years of age
2. Lower than 35 for body mass index
3. Previously failed medical or conservative measures
4. Magnetic resonance imaging (MRI) is used to diagnose femoral condyle osteochondral lesions of grade III to IV (Fig 5) or arthroscopy
5. Standard or proper alignment
6. Ligamentary stability that is normal or modifiable
7. Meniscal integrity that is normal or repairable
8. Availability to follow the rehabilitation protocol
9. Realistic expectations for the recovery period.

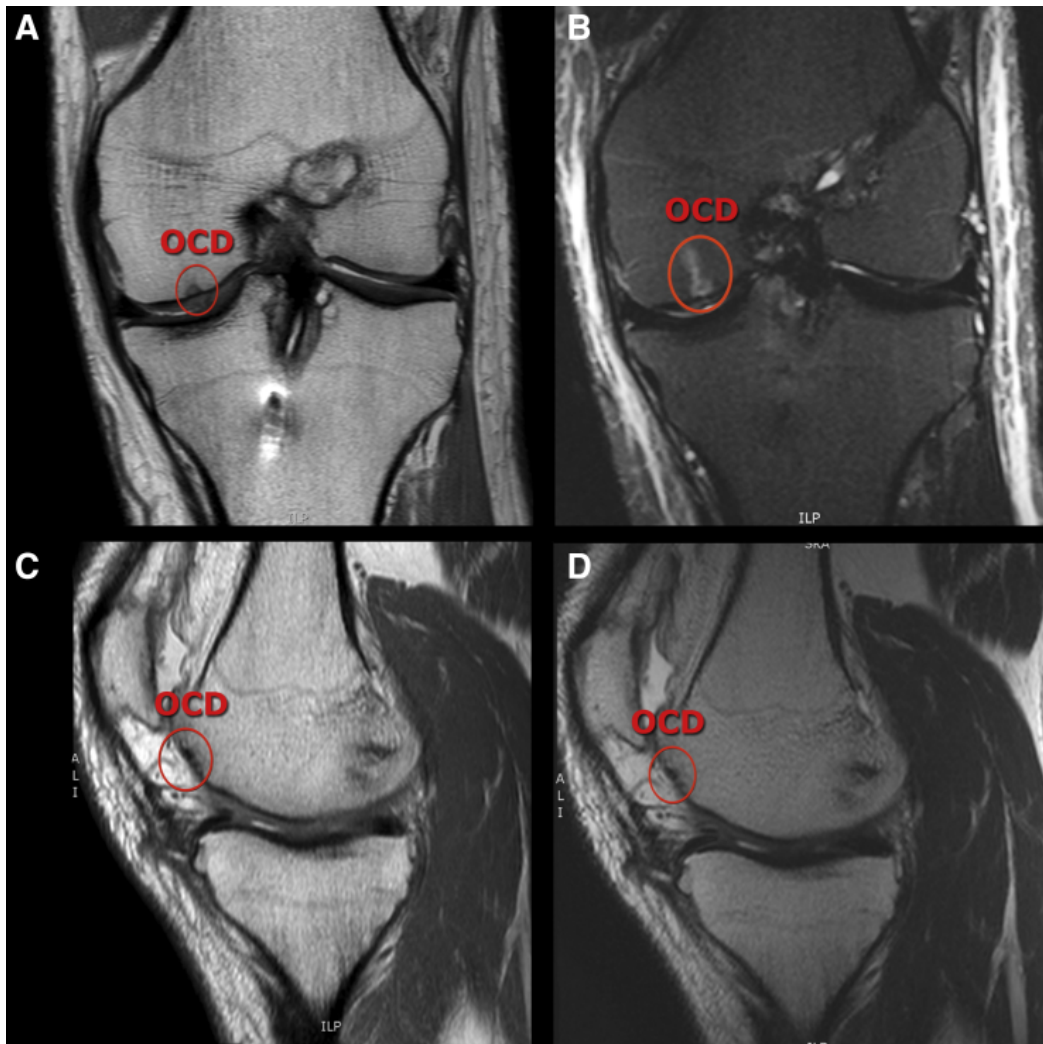


Figure 5: Left knee magnetic resonance imaging (A) An osteochondral defect (OCD) can be seen on a T1-weighted picture in the coronal plane running down the left medial femoral condyle. The same OCD can be seen running along the left medial femoral condyle in T2-weighted images in the coronal plane (B), T1-weighted images in the sagittal plane (C), and T2-weighted images in the sagittal plane (D). (27)

## **7.2. Osteochondral Allograft Transplantation (OCA)**

OCA transplantation is recommended for the first-line surgical management of large (>2-3 cm<sup>2</sup>), full thickness (grade 3 or 4) chondral or osteochondral lesions of the femoral condyles, as well as the second-line surgical management of patellofemoral and tibial defects in symptomatic patients who have failed to respond to nonsurgical treatment (12,15–17,28–32).

OCA transplantation may be used to treat idiopathic and posttraumatic lesions, as well as deficiencies linked to osteochondritis dissecans, osteonecrosis, and unsuccessful previous cartilage restoration (12,16,17,32).

Prior to or at the time of osteochondral allograft (OCA) transplantation, it is important to correct any articular or peri-articular pathology to prevent overloading of the diseased compartment. This may involve addressing modifiable comorbidities and concomitant pathologies, such as limb malalignment, ligament deficiency, and meniscal deficiency. It is also worth noting that the need for multiple osteochondral allografts for the multifocal chondral disease is not necessarily a contraindication. Ideally, patients undergoing OCA transplantation should have a body mass index (BMI) of less than 30 kg/m<sup>2</sup> (11,12,15,16,32,33).

<b>Indications</b>	<b>Contraindications (Relative)</b>	<b>Contraindications (Absolute)</b>
Active patients not suitable for joint replacement	BMI >35 kg/m <sup>2</sup>	Advanced osteoarthritis
Defects due to trauma, OCD, AVN, osteonecrosis, or intra-articular plateau fractures	Uncorrected lower limb malalignment	Inflammatory arthritis
Symptomatic large (≥2 cm <sup>2</sup> ) osteochondral defects	Smoking or alcohol abuse	Uncorrected ligamentous instability
Previous failed cartilage procedures	Prolonged corticosteroid use	Poor surgical candidate

**Abbreviations:** AVN, avascular necrosis; BMI, body mass index; OCD, osteochondritis dissecans.

Table 3: Indications and Contraindications for Osteochondral Allograft Transplantation (34)

## 8. Contraindications

### 8.1. Osteochondral Autograft Transplantation (OAT)

There are several contraindications to osteochondral autograft transfer, including:

- Global arthrosis
- Opposing "kissing" lesions
- Inflammatory arthropathies
- Infection (septic arthritis)
- Biomechanically altered joint line
- Diffuse degenerative changes

Global arthrosis is an absolute contraindication, but focal lesions in two or more areas of the knee may still be amenable to this technique. However, if there are secondary changes present, such as osteophytes or joint space narrowing, the efficacy of the procedure may be reduced. (35)

Obesity, generalized osteoarthritis, osteonecrosis, an active infection or bone malignancy, and a lack of accompanying symptoms are among the more contentious contraindications (20,21,23,24,27,36).



## **8.2. Osteochondral Allograft Transplantation (OCA)**

The following conditions are contraindicated:

1. Current use of tobacco
2. A body mass index (BMI) of 35 kg/m or higher (37)
3. Inflammation
4. Diffuse degenerative articular changes
5. Untreated knee pathologies, such as abnormal patellar tracking, meniscal deficiency, ligamentous insufficiency, or knee malalignment (12,16,32).

## 9. Techniques

### 9.1. Osteochondral Autograft Transplantation (OAT)

On a typical operating table, the patient is lying face up with a lateral post 1 handbreadth above the top of the kneecap. An upper thigh tourniquet is applied, but it is left deflated and is only used in extremely rare instances of bleeding. A conventional vertical incision is created on the knee following the administration of general anesthesia, where a line connecting the lateral side of the patella with the bottom of the kneecap (Fig 6) (35,38)

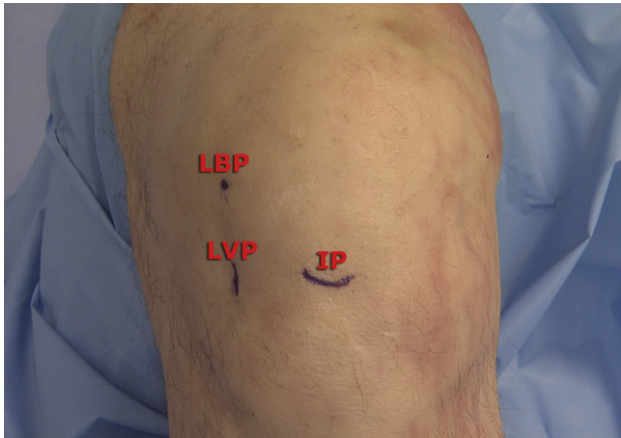


Figure 6: The lateral viewing portal (LVP), which is made at the intersection of the inferior pole (IP) of the patella and the lateral border of the patella, is visible in this photo of a left knee that is flexed at 90 degrees (LBP) (27).

A superolateral outflow portal is made using a common arthroscopic procedure. A diagnostic arthroscopy is carried out, if additional problems are corrected, and a 4-mm arthroscope is implanted. To make the cartilage lesion and graft harvest site more visible, a portion of the fat pad is removed using a non-aggressive shaver and a

thermal device (27). For the repair site and the graft harvesting location, this is done at the lateral side of the medial femoral condyle (Fig 7).

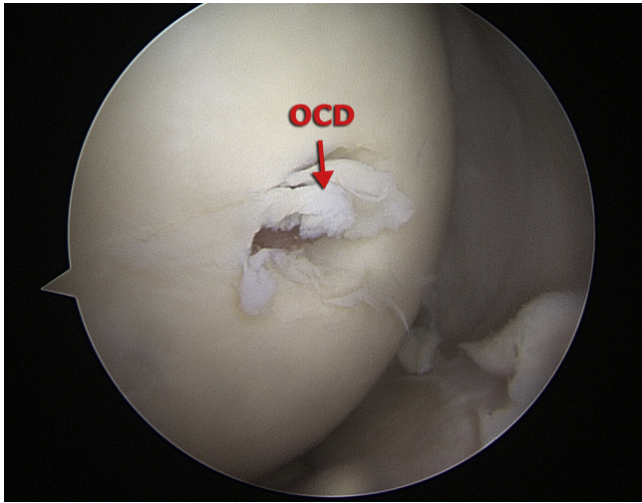


Figure 7: An osteochondral defect is visible in the arthroscopic picture of the left medial femoral condyle taken through the lateral viewing portal (OCD) (27).

The ideal option for transferring articular cartilage is the Arthrex single-use OATS set. During the preoperative MRI, the cartilage defect is evaluated, and measures of the defect's size and depth help with surgical planning. Once the lesion has been properly identified, a calibrated probe verifies its size and assesses the stability of the cartilage around it. After that, the auxiliary anteromedial portal is incised longitudinally while maintaining the greatest feasible perpendicularity to the osteochondral lesion. There are three different graft harvest options: 6, 8, and 10. These sizes allow for several osteochondral plugs in larger lesions (27,35).

Knee flexion is altered to position the cannulated guide perpendicular to the recipient site after it has been put on the cartilage surface at the lesion site. Before withdrawing the cannulated guide, the OATS guide pin is advanced to a depth of roughly 10 to 12 mm (27,39). Lastly, a cannulated reamer of the appropriate size is positioned over the

pin and advanced to the cystic change's depth on the MRI, which is commonly 8 to 10 mm (Fig 8).

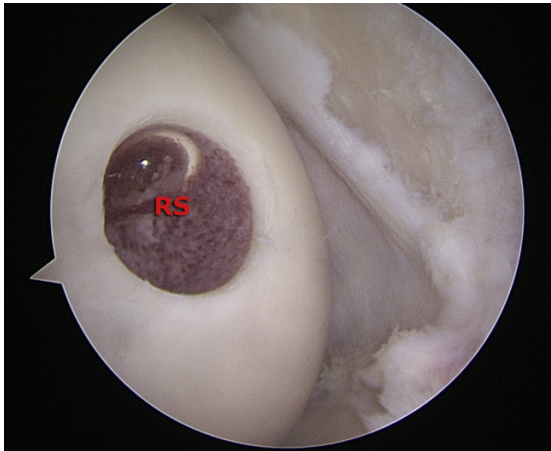


Figure 8: A cannulated reamer is utilized to remove the osteochondral defect from the left medial femoral condyle in an arthroscopic picture taken through the lateral viewing portal in order to prepare the recipient site (RS) (27).

An arthroscopic shaver is reinserted after the central pin has been withdrawn to remove any remaining bone fragments and free edge cartilage. The depths at the 12, 3, 6, and 9 o'clock positions are then measured using a cannulated dilator from the OATS kit (Arthrex) (Fig 9).

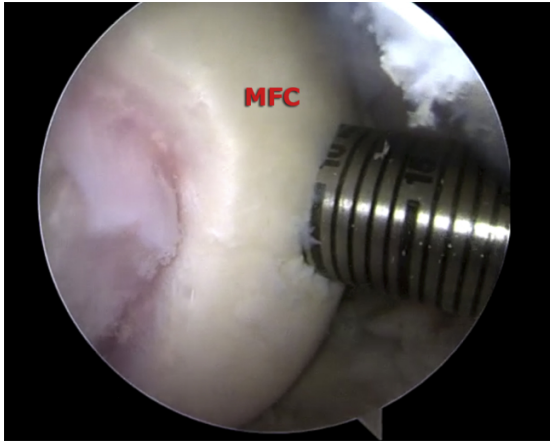


Figure 9: The depth of the recipient site is being measured at the three, six, nine, and twelve o'clock locations of the left medial femoral condyle in this arthroscopic picture taken through the lateral viewing portal (MFC) (27).

The donor-site harvest should match this angulation difference if it is found that the location is not exactly perpendicular to the cartilage surface (for example, one side measures 9 mm while another side measures 10 mm) (27,35).

The process of getting the graft comes next. At the intersection of the lateral trochlea and lateral femoral condyle, right in front of the sulcus terminalis, is where grafts are typically harvested (in the non-weight-bearing zone). Yet, a different position for harvesting is possible; it is above and to the side of the intercondylar notch (Fig 10).

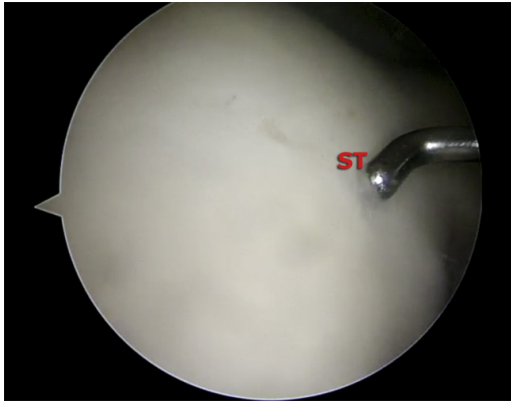


Figure 10: An arthroscopic picture taken through the lateral viewing portal reveals an arthroscopic probe locating the left knee's sulcus terminalis (ST) in preparation for donor-site harvest (27).

The anterolateral portal incision is extended to about 2 cm after identifying the sulcus terminalis in order to get ready to harvest the graft. At the intended harvest site, an appropriately sized harvester (Donor Harvester; Arthrex) is placed, as necessary, either perpendicular to the donor surface or modified to fit any modest angulation of the recipient site (Fig 11).

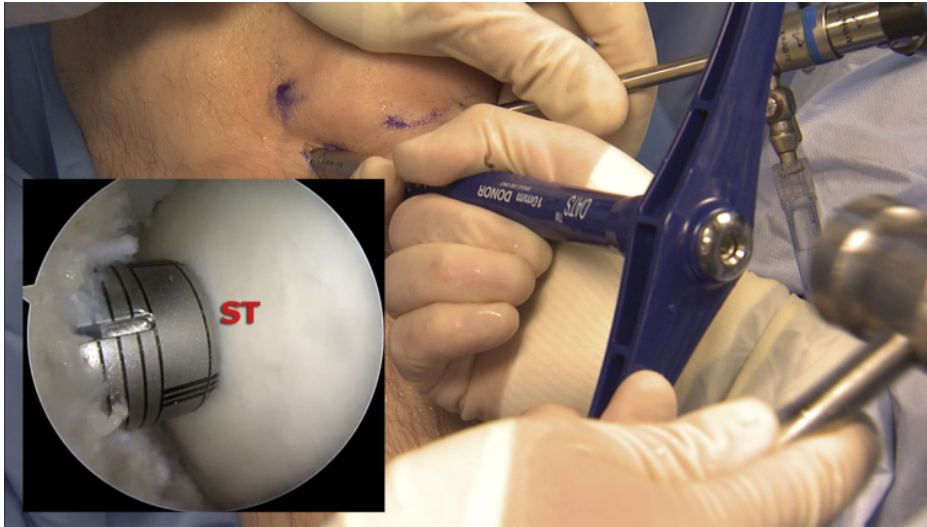


Figure 11: The Osteochondral Autograft Transfer System graft harvester (Arthrex) is visible in an arthroscopic image taken through the lateral viewing portal of the left knee at the anterior border of the sulcus terminalis (ST), and a photograph shows the graft harvester being struck with a mallet to a depth of about 10 mm. When taking a graft from the donor site, care is taken to keep the donor site perpendicular to the articular surface (27).

The harvester is positioned and impacted to a depth of roughly 10 mm with a collared pin protecting the chondral surface. An axial load helps in graft removal as the T-handle is turned to split the donor graft from the deep bone. The sulcus terminalis can be used to harvest up to three grafts if necessary (27,35,40).

The graft is examined, sculpted with a rongeur, and has its bone edges chamfered for simpler insertion after harvesting. To ensure a smooth surface, the graft is cut by 1 mm and, if necessary, orientated during implantation to match the angulation of the recipient site (Fig 12).

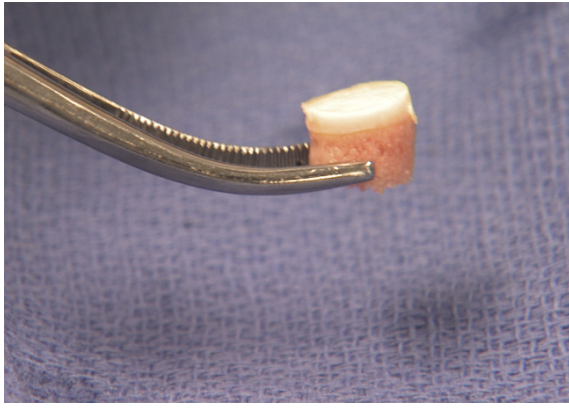


Figure 12: Donor plug from the left sulcus terminalis for the Osteochondral Autograft Transfer System. The donor plug's contoured look after being rongeured to a depth 1 mm shorter than the recipient site's preparedness should be noted to ensure a flush finish (27).

In a plastic tube that is aligned with the recipient's location, the cartilage portion of the transplant is placed before being reinserted into the joint. The graft is placed using a bone tamp, which ensures that it is precisely oriented and flush with the surrounding cartilage (Figs 13 and 14).

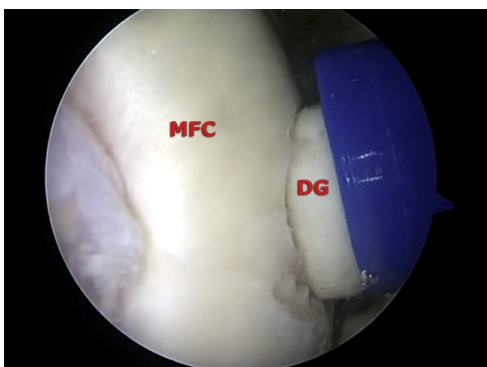


Figure 13: The donor graft (DG) is being advanced into the recipient site on the left medial femoral condyle in this arthroscopy picture taken through the lateral viewing portal (MFC). It should be noted that overlap happens between the impactor and the recipient site to stop the donor graft from being countersunk (27).



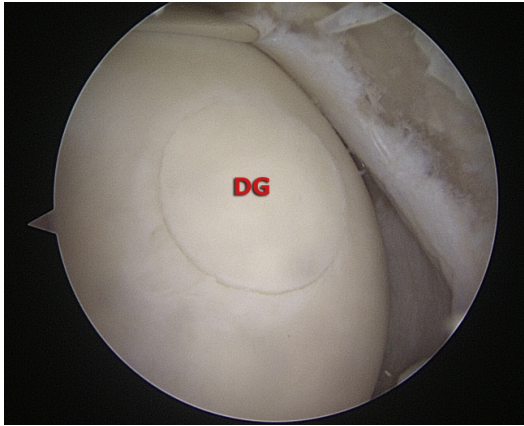

Figure 14: An arthroscopic picture taken through a lateral viewing portal demonstrates the ultimate outcome following the impaction of the donor graft (DG) into the ipsilateral recipient site on the left medial femoral condyle. It's important to pay attention to how the articular surface is well-contoured and seems flush (27).

The graft harvest site is then either filled with a backfill plug that is 1 mm larger than the harvested diameter or left empty. The incision sites are closed once the last arthroscopic pictures are taken. Following the application of a local anesthetic, the knee is covered with a soft dressing and placed on ice (27).

## **9.2. Osteochondral Allograft Transplantation (OCA)**

The patient is positioned supine on a standard operating table and has a tourniquet placed around their proximal thigh. The foot of the bed can be lowered to enable access to the posterior condyles for treating femoral condyle lesions. The leg is exsanguinated, and the tourniquet is inflated to increase visibility. We prefer to first have a diagnostic arthroscopy to address any extra or recurrent pathology before the allograft transplant. A medial or lateral parapatellar arthrotomy incision is made to reveal the deficit on the appropriate femoral condyle (Fig. 15A).

Retractors inserted in the medial or lateral gutter and the femoral notch can improve the exposure. An medial parapatellar arthrotomy is used for patellofemoral lesions. The patella can be retracted to reveal the femoral trochlea or everted to reveal the articular surface. Defect size is determined using a cannulated sizing cylinder (Arthrex Inc., Naples, FL) (Fig. 15B). A guiding pin is drilled perpendicular to the lesion while the cylinder is positioned in the middle of the cartilage defect (Fig. 15B).

After removing the size cylinder, the guiding pin is crossed by a cannulated reamer, which is then reamed to a depth of 6–8 mm (Fig. 15C, D). If the reamer is not adequately shielded during drilling, it could harm soft tissue or the patellar cartilage. The 12 o'clock position is marked on the recipient site after reaming. The recipient site is sharply debrided to clean edges as necessary using a no. 15 scalpel. To precisely prepare the donor osteochondral plug, a ruler is used to measure the depth of the recipient site at the 12-, 3-, 6-, and 9-o'clock locations (Fig. 15E).

Vascular channels can be made in the recipient site's base using a Kirshner wire or a tiny drill. To remove any osseous or chondral pieces, the recipient site is then extensively irrigated with saline that has been infused with antibiotics. A femoral hemicondyle allograft is used to create the osteochondral allograft plug. A powersaw is used to trim the hemicondyle as necessary to fit it into the allograft workstation safely. The radius of curvature of the graft is determined to match the donor site's.

Above the intended harvest spot, a diameter-specific bushing is placed in the middle and firmly fixed in position (Fig. 16A). To protect the graft harvest, the guide must be locked in place. The cylindrical allograft dowel is then reamed with cold irrigation using a circular reamer to prevent thermal necrosis (Fig. 16B).

Following graft removal, the 12-o'clock position is verified, and an ACL saw is used to trim the graft's base to the recipient depth measurements (Fig. 16C). Pulsatile lavage is used to rinse the transplant before to implantation in order to remove any leftover marrow components (Fig. 16D). The recipient site is dilated with a calibrated dilator to a diameter of about 0.5 mm larger just before the graft is implanted. The graft is press-fit into the recipient site once the 12 o'clock positions have been lined up. To fully seat the graft, a large tamp is employed with extremely gentle impaction (Fig. 15F). If necessary, large grafts that might not be completely secured can be fastened with compression or headless bioabsorbable screws.

After that, an interrupted #1 or #2 suture is used to seal the arthrotomy. The conventional method of closing the subcutaneous tissue is then used. The knee is secured in an extension with a hinged brace. (11)

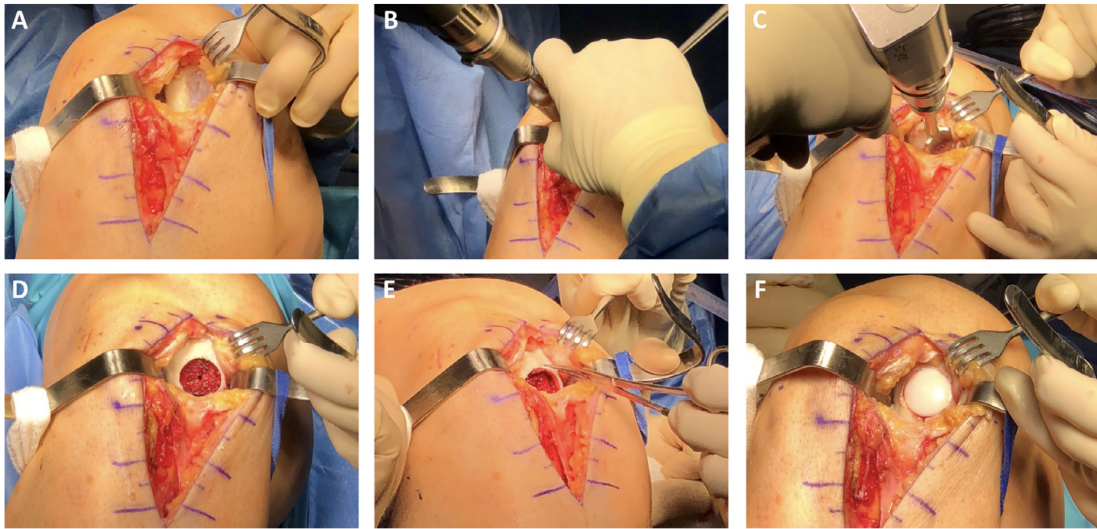


Figure 15: Femoral condyle osteochondral allograft transplanting procedure. (A) The patient is positioned supine on the operating table, with the right knee prepared and sterilely draped. In order to disclose the chondral defect of the afflicted condyle, a parapatellar arthrotomy is carried out. (B) The chondral defect is measured using a cylindrical sizing guide, and a guide pin is correctly inserted into the defect's center. (C) The chondral defect is reamed to an acceptable depth of 6 to 8 mm by placing a cannulated bone reamer over the guide pin. (D) After irrigation, the recipient location is ready by being cleaned of any loose debris. (E) To properly prepare the donor allograft, the depth of the recipient site is assessed at the hours of 12, 3, and 6. (F) To restore the articular surface, the allograft plug is press-fit into the recipient site. (11)

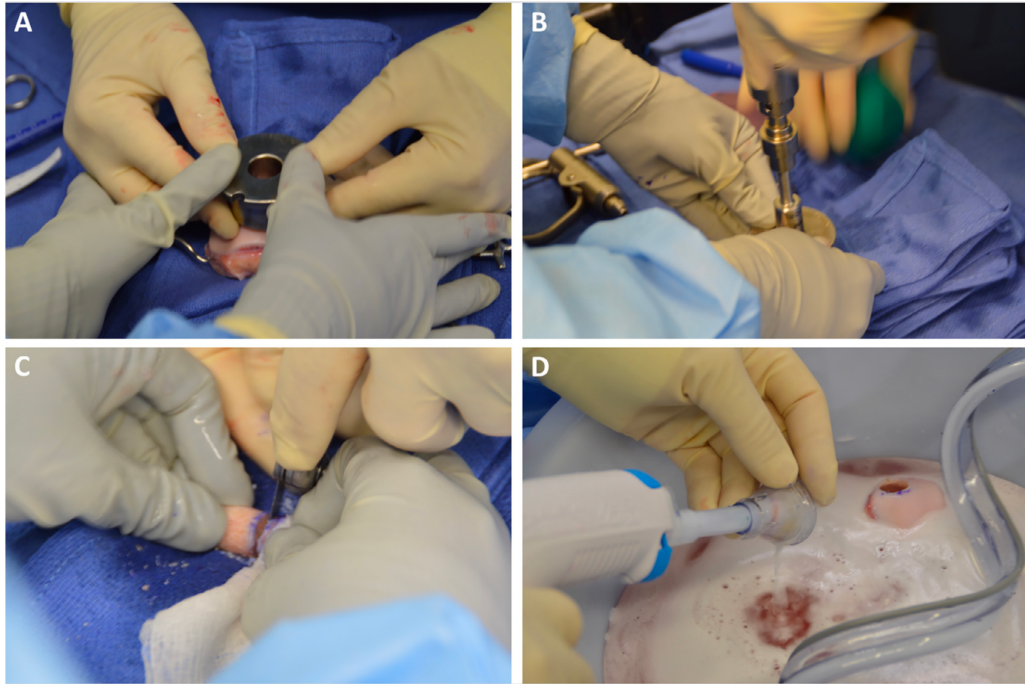


Figure 16: Preparation of an Osteochondral Allograft (A) The sterile back table is installed with the allograft still intact. The chosen allograft donor site is covered with a brush, which is then (B) employed as a guide to cut an allograft dowel using a circular donor harvester. (C) The allograft dowel is marked with the necessary depth, as measured from the recipient site, and an ACL saw is then used to cut at the proper level. (D) Before implantation, the allograft plug is rinsed with antibiotic-infused saline using pulse lavage. This removes any leftover DNA fragments from the allograft (11).

## **10. Failure and Complications**

### **10.1. Osteochondral Autograft Transplantation (OAT)**

Osteochondral autografting has been associated with a number of problems (35).

1. During insertion, the donor cartilage may sustain an injury, which could cause degeneration and graft failure.
2. The graft may not fit seamlessly with the recipient joint's surface, causing excessive pressure on the graft's edges and increasing the risk of infection and graft instability.
3. With osteochondral transplantation, donor site morbidity—which includes significant postoperative bleeding and donor site pain—remains a problem.

### **10.2. Osteochondral Allograft Transplantation (OCA)**

Age at the time of the main allograft, the number of prior operations, the magnitude of the defects, and bicondylar involvement have all been associated with failure of the osteochondral allografts. Graft failure occurs 3.5 times more frequently in patients who were 30 years of age or older at the time of surgery (41,42). Similar to this, allograft failure was 2.8 times more common in patients with two or more prior surgeries on the operative knee (41,42). Failure of osteochondral allografting does not exclude the use of additional reconstructive techniques, such as arthroplasty or a second graft surgery (41,43).

Lack of integration is one of the most frequent reasons for transplant failure.

Sclerosis, a narrowing or obliteration of the joint space, and the development of osteophytes are possible indicators of unsuccessful integration (41,44). Subchondral

cyst development is another indication of graft failure, although it is not a sign of insufficient graft integration.

Complications with immunogenic origins are regarded as uncommon. There hasn't been any overt indication of transplant rejection in the histopathologic examination of unsuccessful osteoarticular allografts (41,45). Supposedly, the hyaline cartilage's thick matrix polysaccharides shield the graft chondrocytes from the host's tissue and fluids (41). Allografts are thoroughly lavaged to eliminate any remaining bone marrow components in order to further reduce potential immunogenicity (41,42). It is believed that subchondral bone and articular cartilage have immunological privileges and don't need anti-immunogenic medications (41,46). Using radiographs, donors and receivers are matched based on physical measurements rather than ABO blood type (41,42).

Osteochondral allograft complications could still include the spread of disease. The probability of catastrophic disease transmission has been reduced thanks to modern screening procedures, which include a minimum 14-day waiting period to allow for serologic and microbiological testing.

## 11. Conclusion

Osteochondral autografting is a highly successful technique for repairing articular cartilage. It has benefits over micro-fracture surgery, including a lowered risk of arthritis development and decreased fibrocartilage proliferation. When done with the right patient selection, assessment, and graft selection, osteochondral autograft transplantation (OAT) and osteochondral allograft transplantation (OCA) both produce great clinical results.

Additionally, the treatment of focal and widespread chondral abnormalities with osteochondral allograft transplantation generally yields positive results and has high patient satisfaction rates. Results are typically better for patients with osteochondritis dissecans, traumatic and idiopathic etiologies, a younger age, unipolar lesions, and shorter symptom duration.

To simplify data pooling across studies and further our understanding of these procedures and their long-term effects, future research should use validated outcome instruments and comparable control groups.



## 12. Acknowledgment

I would like to express my deepest gratitude to my mentor, Prof. Dr. Sc. Mislav Jelić, for his unwavering guidance and support throughout the process of writing my thesis paper. His invaluable insights, constructive feedback, and dedication to my academic growth have been instrumental in the completion of this work.

I would also like to extend my sincere appreciation to Prof. Dr. Sc. Domagoj Delimar and Izv. Prof. Dr. Sc. Tomislav Đapić for their time and effort in reading and examining my thesis. Their expertise and thoughtful critiques have significantly contributed to the refinement of my research.

To all of you, I am truly grateful for the knowledge and wisdom you have imparted to me, and I am honored to have had the opportunity to learn from such esteemed professionals in the field.

## 13. References

1. Parry D, Meads C, Burls A. Autologous chondrocyte transplantation for cartilage defects in the knee joint. 2000 Jan 1;
2. Jacob G, Shimomura K, Nakamura N. Osteochondral Injury, Management and Tissue Engineering Approaches. *Front Cell Dev Biol.* 2020 Nov 4;8:580868.
3. Abulhasan JF, Grey MJ. Anatomy and Physiology of Knee Stability. *J Funct Morphol Kinesiol.* 2017 Dec;2(4):34.
4. Whitesides TE. Orthopaedic Basic Science. Biology and Biomechanics of the Musculoskeletal System. 2nd ed.: *J Bone Jt Surg-Am Vol.* 2001 Mar;83(3):482.
5. F F, G H. Normal anatomy and biomechanics of the knee. *Sports Med Arthrosc Rev* [Internet]. 2011 Jun [cited 2023 Apr 4];19(2). Available from: <https://pubmed-ncbi-nlm-nih-gov.sheba.idm.oclc.org/21540705/>
6. Evans J, Nielson J I. Anterior Cruciate Ligament Knee Injuries. In: *StatPearls* [Internet]. Treasure Island (FL): StatPearls Publishing; 2023 [cited 2023 Apr 4]. Available from: <http://www.ncbi.nlm.nih.gov/books/NBK499848/>
7. J E, J I N. Anterior Cruciate Ligament Knee Injuries [Internet]. PubMed. 2023 [cited 2023 Apr 4]. Available from: <https://pubmed.ncbi.nlm.nih.gov/29763023/>
8. Ortho C. Anatomy of the Knee [Internet]. *Comprehensive Orthopaedics.* 2016 [cited 2023 Apr 5]. Available from: <https://comportho.com/anatomy/anatomy-of-the-knee/>
9. The knee joint biomechanics [Internet]. *MSKphysio.* 2014. Available from: <http://mskphysio.blogspot.com/2014/08/the-knee-joint-biomechanics-knee-joint.html>
10. Jun S, Zhou X, Ramsey DK, Krovi VN. Smart Knee Brace Design With Parallel Coupled Compliant Plate Mechanism and Pennate Elastic Band Spring. *J Mech Robot.* 2015 Nov 1;7(4):041024.
11. Stone AV, Christian DR, Redondo ML, Yanke AB, Southworth TM, Tauro TM, et al. Osteochondral Allograft Transplantation and Osteochondral Autograft Transfer. *Oper Tech Sports Med.* 2018 Sep;26(3):183–8.
12. Haber DB, Logan CA, Murphy CP, Sanchez A, LaPrade RF, Provencher MT. OSTEOCHONDRAL ALLOGRAFT TRANSPLANTATION for the KNEE: POST-OPERATIVE REHABILITATION. *Int J Sports Phys Ther.* 2019 Jun;14(3):487–99.
13. Mankin HJ. The response of articular cartilage to mechanical injury. *J Bone Joint Surg Am.* 1982 Mar;64(3):460–6.
14. Alford JW, Cole BJ. Cartilage restoration, part 1: basic science, historical perspective, patient evaluation, and treatment options. *Am J Sports Med.* 2005 Feb;33(2):295–306.

15. Camp CL, Stuart MJ, Krych AJ. Current concepts of articular cartilage restoration techniques in the knee. *Sports Health*. 2014 May;6(3):265–73.
16. Cole BJ, Pascual-Garrido C, Grumet RC. Surgical management of articular cartilage defects in the knee. *J Bone Joint Surg Am*. 2009 Jul;91(7):1778–90.
17. Sherman SL, Garrity J, Bauer K, Cook J, Stannard J, Bugbee W. Fresh osteochondral allograft transplantation for the knee: current concepts. *J Am Acad Orthop Surg*. 2014 Feb;22(2):121–33.
18. McNickle AG, Provencher MT, Cole BJ. Overview of existing cartilage repair technology. *Sports Med Arthrosc Rev*. 2008 Dec;16(4):196–201.
19. Poddar SK, Widstrom L. Nonoperative Options for Management of Articular Cartilage Disease. *Clin Sports Med*. 2017 Jul;36(3):447–56.
20. Zak L, Krusche-Mandl I, Aldrian S, Trattig S, Marlovits S. Clinical and MRI evaluation of medium- to long-term results after autologous osteochondral transplantation (OCT) in the knee joint. *Knee Surg Sports Traumatol Arthrosc Off J ESSKA*. 2014 Jun;22(6):1288–97.
21. Wang D, Eliasberg CD, Wang T, Fader RR, Coxe FR, Pais MD, et al. Similar Outcomes After Osteochondral Allograft Transplantation in Anterior Cruciate Ligament-Intact and -Reconstructed Knees: A Comparative Matched-Group Analysis With Minimum 2-Year Follow-Up. *Arthrosc J Arthrosc Relat Surg Off Publ Arthrosc Assoc N Am Int Arthrosc Assoc*. 2017 Dec;33(12):2198–207.
22. Gudas R, Kalesinskas RJ, Kimtys V, Stankevicius E, Toliulis V, Bernotavicius G, et al. A prospective randomized clinical study of mosaic osteochondral autologous transplantation versus microfracture for the treatment of osteochondral defects in the knee joint in young athletes. *Arthrosc J Arthrosc Relat Surg Off Publ Arthrosc Assoc N Am Int Arthrosc Assoc*. 2005 Sep;21(9):1066–75.
23. Baltzer AWA, Ostapczuk MS, Terheiden HP, Merk HR. Good short- to medium-term results after osteochondral autograft transplantation (OAT) in middle-aged patients with focal, non-traumatic osteochondral lesions of the knee. *Orthop Traumatol Surg Res OTSR*. 2016 Nov;102(7):879–84.
24. Krych AJ, Harnly HW, Rodeo SA, Williams RJ. Activity levels are higher after osteochondral autograft transfer mosaicplasty than after microfracture for articular cartilage defects of the knee: a retrospective comparative study. *J Bone Joint Surg Am*. 2012 Jun 6;94(11):971–8.
25. Gracitelli GC, Meric G, Briggs DT, Pulido PA, McCauley JC, Belloti JC, et al. Fresh osteochondral allografts in the knee: comparison of primary transplantation versus transplantation after failure of previous subchondral marrow stimulation. *Am J Sports Med*. 2015 Apr;43(4):885–91.
26. Emre TY, Ege T, Kose O, Tekdos Demircioglu D, Seyhan B, Uzun M. Factors affecting the outcome of osteochondral autografting (mosaicplasty) in articular cartilage defects of the knee joint: retrospective analysis of 152 cases. *Arch Orthop Trauma Surg*. 2013 Apr;133(4):531–6.

27. Rowland R, Colello M, Wyland DJ. Osteochondral Autograft Transfer Procedure: Arthroscopic Technique and Technical Pearls. *Arthrosc Tech*. 2019 Jun 11;8(7):e713–9.
28. Dean CS, Chahla J, Serra Cruz R, LaPrade RF. Fresh Osteochondral Allograft Transplantation for Treatment of Articular Cartilage Defects of the Knee. *Arthrosc Tech*. 2016 Feb;5(1):e157-161.
29. Ferrari MB, Sanchez G, Chang A, Sanchez A, Ellera Gomes JL, Provencher MT. Osteochondral Allograft Transplantation for Treatment of Focal Patellar Osteochondral Lesion. *Arthrosc Tech*. 2017 Aug;6(4):e907–12.
30. Harris JD, Siston RA, Pan X, Flanigan DC. Autologous chondrocyte implantation: a systematic review. *J Bone Joint Surg Am*. 2010 Sep 15;92(12):2220–33.
31. Görtz S, Bugbee WD. Fresh osteochondral allografts: graft processing and clinical applications. *J Knee Surg*. 2006 Jul;19(3):231–40.
32. Gomoll AH, Farr J, Gillogly SD, Kercher J, Minas T. Surgical management of articular cartilage defects of the knee. *J Bone Joint Surg Am*. 2010 Oct 20;92(14):2470–90.
33. Cotter EJ, Waterman BR, Kelly MP, Wang KC, Frank RM, Cole BJ. Multiple Osteochondral Allograft Transplantation with Concomitant Tibial Tubercle Osteotomy for Multifocal Chondral Disease of the Knee. *Arthrosc Tech*. 2017 Aug;6(4):e1393–8.
34. Lai W, Bohlen H, Fackler N, Wang D. Osteochondral Allografts in Knee Surgery: Narrative Review of Evidence to Date. *Orthop Res Rev*. 2022 Aug 1;Volume 14:263–74.
35. Branam GM, Saber AY. Osteochondral Autograft Transplantation. In: *StatPearls* [Internet]. Treasure Island (FL): StatPearls Publishing; 2023 [cited 2023 Apr 7]. Available from: <http://www.ncbi.nlm.nih.gov/books/NBK560655/>
36. Cognault J, Seurat O, Chaussard C, Ionescu S, Saragaglia D. Return to sports after autogenous osteochondral mosaicplasty of the femoral condyles: 25 cases at a mean follow-up of 9 years. *Orthop Traumatol Surg Res OTSR*. 2015 May;101(3):313–7.
37. Arøen A, Løken S, Heir S, Alvik E, Ekeland A, Granlund OG, et al. Articular cartilage lesions in 993 consecutive knee arthroscopies. *Am J Sports Med*. 2004;32(1):211–5.
38. Rowland R, Colello M, Wyland DJ. Osteochondral Autograft Transfer Procedure: Arthroscopic Technique and Technical Pearls. *Arthrosc Tech*. 2019 Jun 11;8(7):e713–9.
39. Koh JL, Wirsing K, Lautenschlager E, Zhang LO. The effect of graft height mismatch on contact pressure following osteochondral grafting: a biomechanical study. *Am J Sports Med*. 2004 Mar;32(2):317–20.
40. Diduch DR, Chhabra A, Blessey P, Miller MD. Osteochondral autograft plug

- transfer: achieving perpendicularity. *J Knee Surg.* 2003 Jan;16(1):17–20.
41. Torrie AM, Kesler WW, Elkin J, Gallo RA. Osteochondral allograft. *Curr Rev Musculoskelet Med.* 2015 Oct 17;8(4):413–22.
  42. Levy YD, Görtz S, Pulido PA, McCauley JC, Bugbee WD. Do fresh osteochondral allografts successfully treat femoral condyle lesions? *Clin Orthop.* 2013 Jan;471(1):231–7.
  43. Getgood A, Gelber J, Gortz S, De Young A, Bugbee W. Combined osteochondral allograft and meniscal allograft transplantation: a survivorship analysis. *Knee Surg Sports Traumatol Arthrosc Off J ESSKA.* 2015 Apr;23(4):946–53.
  44. Bakay A, Csönge L, Papp G, Fekete L. Osteochondral resurfacing of the knee joint with allograft. *Clinical analysis of 33 cases. Int Orthop.* 1998;22(5):277–81.
  45. Chahal J, Gross AE, Gross C, Mall N, Dwyer T, Chahal A, et al. Outcomes of osteochondral allograft transplantation in the knee. *Arthrosc J Arthrosc Relat Surg Off Publ Arthrosc Assoc N Am Int Arthrosc Assoc.* 2013 Mar;29(3):575–88.
  46. Taylor DW, C Bohm K, Taylor JE, Gross AE. Use of fresh osteochondral allograft in repair of distal femur after trauma. *McGill J Med MJM Int Forum Adv Med Sci Stud.* 2011 Jun;13(1):22.

## 14. Biography

Coral Tsadik was born on December 16, 1995, in Ramat Gan, Israel. She attended "Atid" high school in Lod City, Israel, from 2010 to 2014, where she achieved full matriculation with honors (Cum Laude). Coral's studies focused on Biology, Computer Science, Mathematics, and English.

At age 18, Coral enlisted in the Israel Defense Forces, serving in a classified unit within the Air Intelligence Group as an Air Purpose Investigator from 2014 to 2016. In this role, she analyzed and interpreted aerial photographs, made intelligence-related decisions, and worked closely with advanced computer systems to organize data for various intelligence needs.

In 2016, Coral studied at the Medical Doctor International Academy for Medical Studies Abroad in Tel Aviv, Israel, for four months. After passing the entrance exam for the University of Zagreb in Croatia, she began her medical studies in September 2017.

Coral enjoys a variety of hobbies, including traveling, singing, and participating in numerous sports. She is also heavily involved in volunteering and social activities. Coral has volunteered at a geriatric nursing center, exposing her to a unique population. As an avid debater, she participated in the Atid High School Debate Team for two years and later competed on the Tel Aviv University Debate Team for an additional two years. Coral took part in a student exchange delegation between Shoham, Israel, and Hamburg, Germany. She is a former member of the Israeli Scout Movement and volunteered as the Head of the Community Team for three years.

Additionally, Coral worked as a summer camp instructor and senior instructor for four summers.

Between 2011 and 2016, Coral found success as a tutor, teaching a variety of academic subjects to a total of one hundred and twenty students. Her dedication to student satisfaction and their rapid improvement contributed to her well-earned reputation as an effective and compassionate tutor.