

# **Urothelial carcinoma in a urinary bladder diverticulum: A case report and review of the literature**

---

**Matković, Andro; Ferenc, Thomas; Jurjević, Nikolina; Brkić, Filip; Kavur, Lovro; Jurenec, Franjo; Mužinić, Darija; Vidjak, Vinko**

*Source / Izvornik:* **Radiology Case Reports, 2023, 18, 1169 - 1174**

**Journal article, Published version**

**Rad u časopisu, Objavljena verzija rada (izdavačev PDF)**

<https://doi.org/10.1016/j.radcr.2022.12.020>

*Permanent link / Trajna poveznica:* <https://um.nsk.hr/um:nbn:hr:105:039694>

*Rights / Prava:* [Attribution-NonCommercial-NoDerivatives 4.0 International/Imenovanje-Nekomercijalno-Bez prerada 4.0 međunarodna](#)

*Download date / Datum preuzimanja:* **2024-07-13**



*Repository / Repozitorij:*

[Dr Med - University of Zagreb School of Medicine Digital Repository](#)



Available online at [www.sciencedirect.com](http://www.sciencedirect.com)

journal homepage: [www.elsevier.com/locate/radcr](http://www.elsevier.com/locate/radcr)

## Case Report

# Urothelial carcinoma in a urinary bladder diverticulum: A case report and review of the literature ☆☆☆

Andro Matković, MD<sup>a,1</sup>, Thomas Ferenc, MD<sup>a,1,\*</sup>, Nikolina Jurjević, MD<sup>a</sup>, Filip Brkić, MD<sup>a</sup>, Louro Kavur, MD<sup>a</sup>, Franjo Jurenc, MD, PhD<sup>b,c</sup>, Darija Mužinić, MD<sup>d</sup>, Vinko Vidjak, MD, PhD<sup>a,e</sup>

<sup>a</sup> Clinical Department of Diagnostic and Interventional Radiology, Merkur University Hospital, Zajčeva 19, Zagreb, Croatia

<sup>b</sup> Department of Urology, Merkur University Hospital, Zagreb, Croatia

<sup>c</sup> Faculty of Medicine, Josip Juraj Strossmayer University of Osijek, Osijek, Croatia

<sup>d</sup> Institute of Clinical Pathology and Cytology, Merkur University Hospital, Zagreb, Croatia

<sup>e</sup> School of Medicine, University of Zagreb, Zagreb, Croatia

### ARTICLE INFO

#### Article history:

Received 29 November 2022

Accepted 9 December 2022

#### Keywords:

Urinary bladder diverticulum

Urothelial carcinoma

Partial cystectomy

### ABSTRACT

Bladder diverticula are defined as an outpouching of the mucosa into the muscle layer of the bladder wall. There is a well-known link between urinary bladder diverticula and tumors arising within the diverticula. They are rare with an incidence rate of 0.8%–10%. We report an intradiverticular urothelial carcinoma in a 72-year-old man with a known history of multiple episodes of acute urinary retention and urinary tract infections, followed by transurethral resection of the benign prostatic hyperplasia.

© 2022 The Authors. Published by Elsevier Inc. on behalf of University of Washington.

This is an open access article under the CC BY-NC-ND license

(<http://creativecommons.org/licenses/by-nc-nd/4.0/>)

## Introduction

Bladder diverticula are defined as herniation of the mucosa into the muscle layer of the bladder wall, often ending with a narrow neck that communicates with the bladder lumen [1,2]. They may be congenital (mainly in boys, containing all layers) or acquired (often in older men, lacking mus-

cle layer) [2]. Most bladder diverticula are small and clinically insignificant; however, some may complicate with infection, calculus, or even neoplasm [2,3]. Primary intradiverticular bladder tumors (IDBT) are rare with an incidence rate of 0.8%–10% [4]. The most common histologic type is urothelial carcinoma, followed by a rare occurrence of squamous cell carcinoma, small cell carcinoma, adenocarcinoma, and sarcoma [2,5–7].

☆ Funding: No funding received.

☆☆ Competing Interests: The authors declare that they have no known competing financial interests or personal relationships that could have appeared to influence the work reported in this paper.

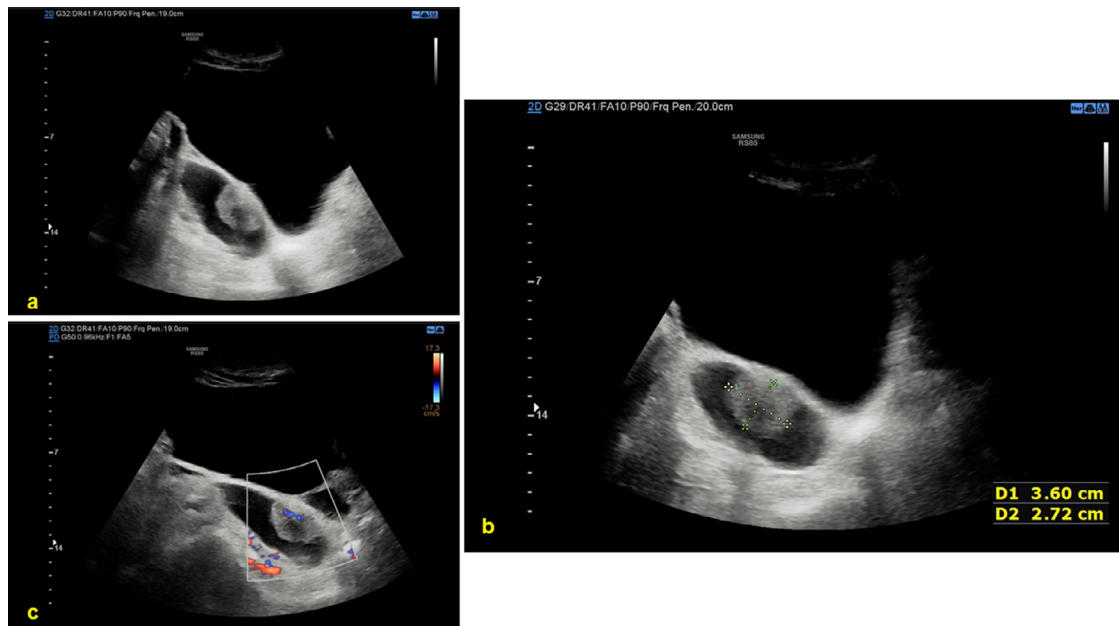\* Corresponding author.

E-mail address: [thomas.ferenc95@gmail.com](mailto:thomas.ferenc95@gmail.com) (T. Ferenc).

<sup>1</sup> Matković A and Ferenc T contributed equally to this manuscript and should be considered as co-first authors.

<https://doi.org/10.1016/j.radcr.2022.12.020>

1930-0433/© 2022 The Authors. Published by Elsevier Inc. on behalf of University of Washington. This is an open access article under the CC BY-NC-ND license (<http://creativecommons.org/licenses/by-nc-nd/4.0/>)



**Fig. 1 – Transabdominal US and color Doppler examination of intradiverticular urothelial carcinoma.**

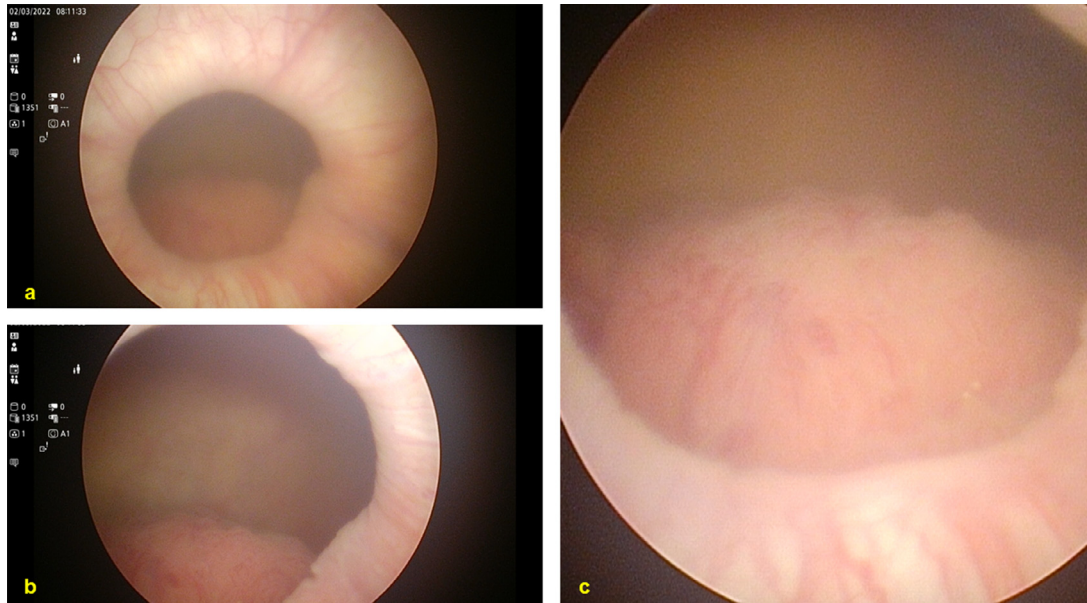
## Case report

A 72-year-old male patient presented with painless macrohematuria. After the detection of malignant urothelial cells in the urine sample at another institution, he was referred to our Urology Outpatient Clinic for further evaluation. His past medical history was significant for multiple episodes of acute urinary retention and urinary tract infections, followed by transurethral resection of the benign prostatic hyperplasia. A large solitary diverticulum of the bladder was sonographically discovered in 2014. As part of the initial assessment during the recent visit, transabdominal ultrasound (US) revealed a large diverticulum of the right posterolateral wall of the bladder with intraluminal, heterogeneous hypoechoic mass measuring  $3.6 \times 2.7$  cm. Internal blood flow was also detected (Fig. 1). An urgent cystoscopy was performed, and the US findings were confirmed (Fig. 2). Contrast-enhanced computed tomography urography (CTU) demonstrated a large diverticulum on the right posterolateral side of the bladder measuring  $8.1 \times 3.3 \times 5.7$  cm. The diverticulum was in communication with the bladder lumen via a narrow neck, 0.6 cm in diameter. Polypoid filling defect  $3.8 \times 3.3 \times 3.5$  cm in size was visualized within the diverticulum (Fig. 3). The described neoplasm showed avid enhancement and signs of diverticular wall invasion. There were no signs of lymphadenopathy or distant metastases. Magnetic resonance imaging (MRI) of the pelvis was performed as part of the local tumor staging; however, without gadolinium administration due to an increase in urea and creatinine levels (14.4 mmol/L (reference levels 2.8–8.3),  $171 \mu\text{mol/L}$  (64–104), respectively). The tumor displayed a hypointense signal on T2-weighted images and restricted diffusion on diffusion-weighted images (DWI) and apparent diffusion coefficient (ADC) maps (Fig. 4). There

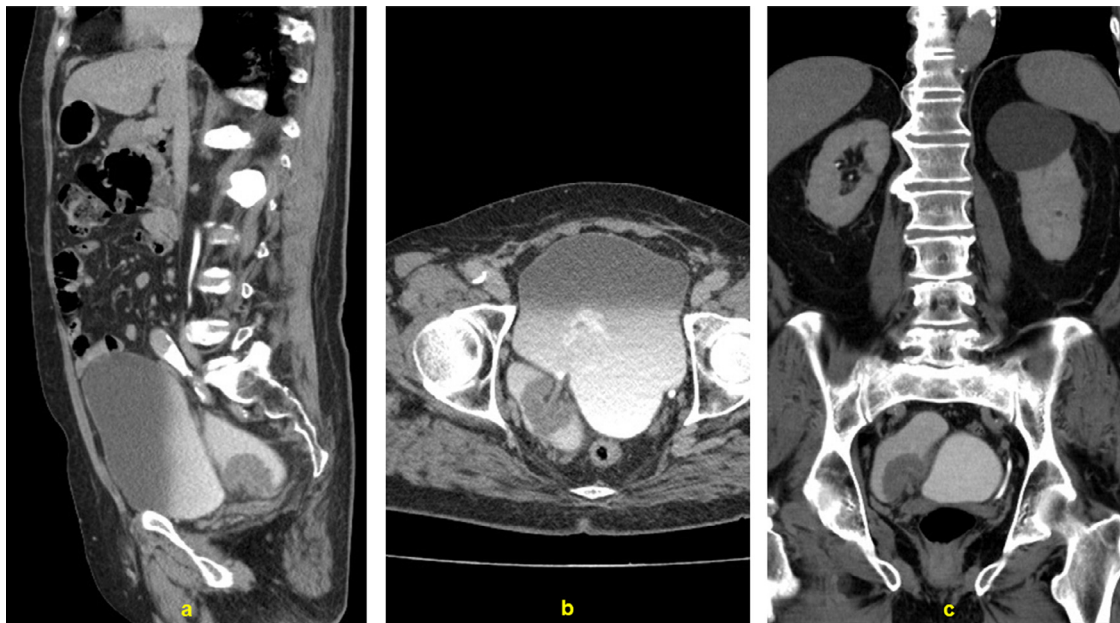
were no signs of extension beyond the diverticular wall or regional lymphadenopathy while both urethral walls were intact. Additionally, 2 more laterally formed diverticula of the bladder were detected. The prostate was moderately enlarged. Partial cystectomy with diverticulectomy was performed, and the intraoperative specimen was sent to pathology. On gross examination, an exophytic tumor measuring  $4.5 \times 4$  cm with a papillary surface was found within the resected diverticulum. Microscopically, the tumor was mainly composed of papillary formations of fibrovascular stroma lined with thickened urothelial epithelium showing disrupted stratification, prominent mitotic activity, and cellular atypia (Figs. 5a–c, e). A smaller part of the tumor was composed of solid nests of tumor cells (Fig. 5f). The tumor invaded the full thickness of the diverticular wall with the initial involvement of peridiverticular adipose tissue (Fig. 5d). Lymphovascular or perineural invasion was not detected. Urothelial carcinoma in situ (CIS) was found adjacent to the tumor (Fig. 5c). Surgical margins were tumor-free. The described findings were in correlation with high-grade, invasive intradiverticular urothelial carcinoma (pTNM: pT3a, pNx, pMx). The postoperative period was unremarkable, and the patient was discharged from the hospital in good condition. On the first follow-up, the patient was well with scheduled oncology consultations for the next visit.

## Discussion

There is a well-known link between urinary bladder diverticula and tumors arising within the diverticula. The first case of IDBT was documented in 1883, and the first surgical sample of such tissue was reported in 1896 [8]. Chronic inflammation



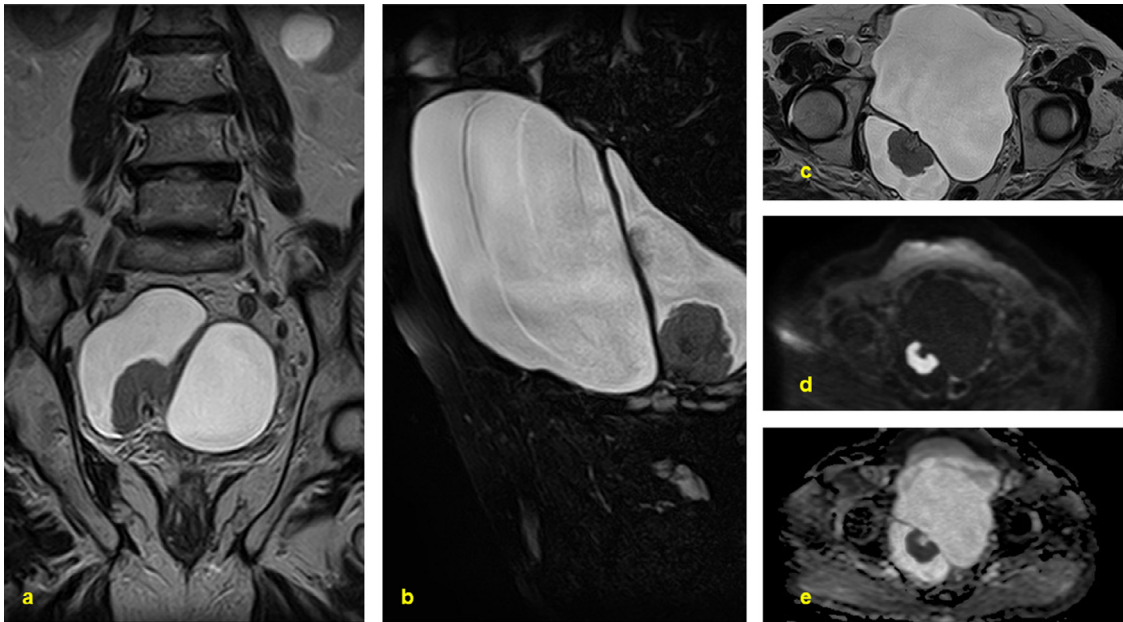
**Fig. 2 – Cystoscopy findings of bladder diverticulum with a tumorous mass.**



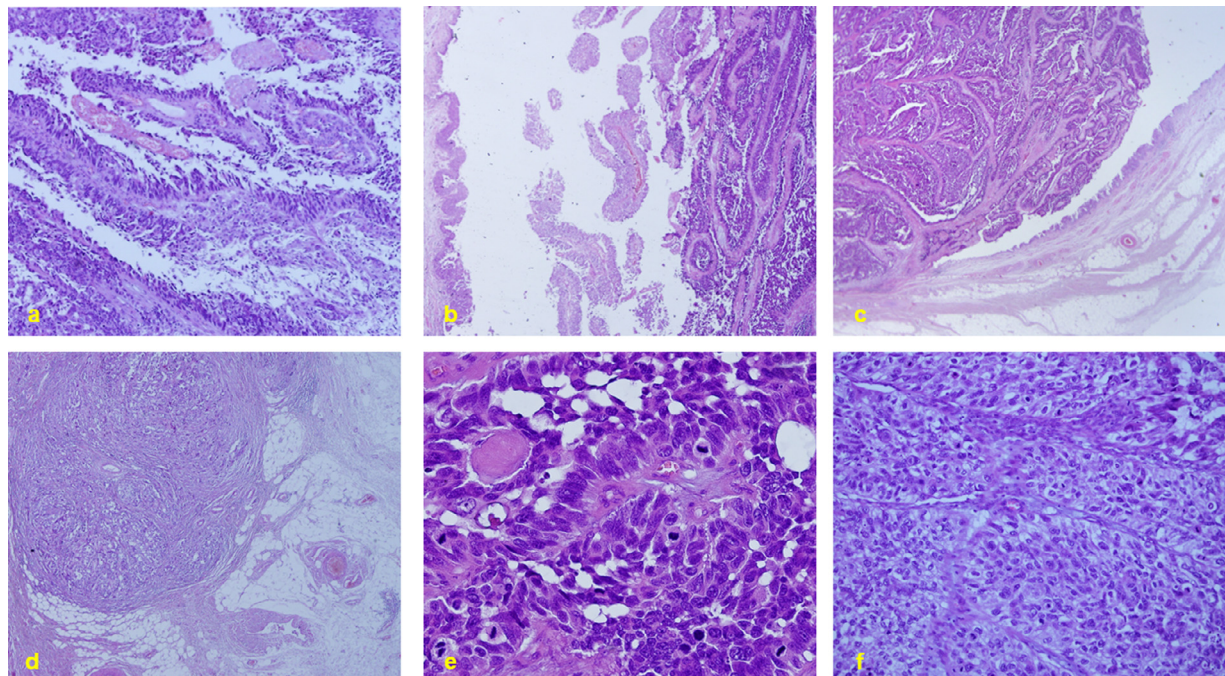
**Fig. 3 – CTU post-contrast images of intradiverticular urothelial carcinoma (a, sagittal plane; b, axial plane; c, coronal plane).**

secondary to urinary stasis, persistent exposure to carcinogens, and human papillomavirus (HPV) infection have been proposed to stimulate neoplastic changes in a bladder diverticulum [5,9,10]. The reported prevalence of IDBT is 0.8%-10%, occurring 11-12 times more often in men than in women, usually after the age of 60 years [2]. Painless hematuria is the most common presenting symptom in 57%-90% of patients [4,8,11]. One study found that IDBTs were mainly localized on the lateral side of the bladder walls (15/20, 75%), equally on both sides; however, they have rarely risen from the posterior bladder wall (1/20, 5%) [3].

The US is often the modality of choice for the initial imaging of patients with a suspected malignancy within a bladder diverticulum. Larger tumors are easily diagnosed; however, the US possesses poor sensitivity for IDBT less than 1 cm in diameter [2]. The mainstay for tumor evaluation and staging of patients with IDBT is contrast-enhanced CTU, especially in those unable to endure cystoscopy inspection. The study by Di Paolo et al. [12] involved 34 patients with IDBT where 2 radiologists with 6 and 2 years of experience interpreted their CT images. Patients predominantly presented with urothelial carcinoma (26/34, 76%), and the tumor morphology was poly-



**Fig. 4** – MRI images of intradiverticular urothelial carcinoma (a, coronal plane, T2-weighted image; b, sagittal plane, fat-saturated T2-weighted image; c, axial plane, T2-weighted image; d, axial plane, DWI; e, axial plane, ADC map).



**Fig. 5** – Pathohistological analysis of intradiverticular urothelial carcinoma (a, H&E, 100 x magnification: papillary formations of fibrovascular stroma lined with thickened urothelial epithelium; b, H&E, 40 x: papillary formations lined with atypical urothelial cells; c, H&E, 25 x: papillary formations lined with atypical urothelial cells. Adjacent urothelium displaying carcinoma in situ (CIS); d, H&E, 25 x: peridiverticular adipose tissue involvement; e, H&E, 400 x: atypical urothelial cells with high mitotic activity; f, H&E, 200 x: solid nests of atypical urothelial cells).

roid in 60.7% and 46.1%, respectively, whereas flat in 39.2% and 53.8%, respectively. According to reader one, the median tumor length was 23.5 mm and width was 14 mm, whereas reader 2 measured the median length of 18.5 mm and width of 9 mm. Out of the 7 patients with pathologically confirmed extension beyond the diverticular wall, both readers correctly detected 6 and 5 cases of extradiverticular invasion, respectively. MRI is mostly used as a problem-solving method and/or for local staging purposes. An earlier study by Dondalski et al. [13] (1993) has found that IDBT possesses higher T1 signal intensity than urine, slightly higher or equal T1 signal intensity in contrast to the bladder wall, and is hypointense compared to perivesical adipose tissue. The tumor also possesses a moderately increased T2 signal in comparison to the intermediate signal intensity of the bladder wall and is hypointense compared to hyperintense urine.

Based on the review by Walker et al. [2], most tumors have been urothelial carcinoma (72%), followed by small cell carcinoma (8.3%), urothelial carcinoma with squamous differentiation (5.6%), pure squamous cell carcinoma (5.6%), sarcoma (5.6%) and adenocarcinoma (2.8%). Another study also reported urothelial carcinoma as the predominant histological variant (78%), followed by squamous cell carcinoma (17%), a combination of urothelial and squamous carcinoma (2%) and adenocarcinoma (2%) [13]. In one study 22 out of 34 patients with IDBT (65%) had invasive and 31 (91%) of them had high-grade tumor features in bioptic material [12]. Neoplasms within the diverticulum are usually of stage T3 or greater [14]. In their study from 1997, Baniel and Vishna [15] suggested that a stage T1 IDBT should be analogous to stage T2/T3 malignancy in a normal bladder.

Transurethral resection (TUR) is advised for low-grade and stage T1 IDBT with regular follow-ups, including cystoscopy, urine cytology, and cross-sectional imaging; however, TUR is often challenging to perform in patients with IDBT due to narrow diverticular neck and thin diverticular walls which represents the risk of perforation and tumor dissemination [2,9]. Diverticulectomy is the preferred option for large, low-grade tumors when complete TUR is not feasible [2]. If a tumor within the diverticulum partially expands towards the bladder, the procedure can be broadened into partial cystectomy [2]. Partial cystectomy in combination with pelvic lymphadenectomy, followed by adjuvant treatment, is recommended in patients with high-grade tumors and without associated carcinoma in situ [2,9]. Radical cystectomy is a selected procedure for patients with high-grade, locally advanced IDBT with multifocal exophytic neoplasms within the bladder, associated carcinoma in situ, or multifocal disease in combination with unsatisfactory bladder function [9].

Overall 5-year survival rates for patients with IDBT are between 63% and 72% and for patients with stage T3 tumors 45% [2,16]. Poor prognosis related to IDBT may be contributed to the lack of a muscle layer in the diverticulum which enables early tumor invasion [15]. Features associated with worse overall outcomes were extradiverticular tumor extension (stage  $\geq$  T2), positive surgical margins, and larger tumor length and width measured on pre-treatment CT [12,16]. However, there were no statistically significant differences in overall survival between the patients that underwent radical in comparison to partial cystectomy [16,17].

## Conclusion

IDBT is rare with an incidence of 0.8%-10%. They are more common in elderly men with painless hematuria as the predominant presenting symptom. The diagnostic algorithm usually includes urine cytology, cystoscopy, US, and CT, while MRI is being preserved for local staging and inconclusive cases. The most common histologic type is urothelial carcinoma. Surgical options for IDBT are TUR, diverticulectomy, and partial or radical cystectomy, mainly depending on the tumor volume, stage, and grade. Overall, 5-year survival rates for patients with IDBT range from 63% to 72%.

## Patient consent

Written informed consent was obtained from the patient for the publication of this case report and accompanying images. The anonymity of all clinical and graphical data used is ensured.

## REFERENCES

- Wang CK, Chueh SC. Laparoscopic partial cystectomy with endo-GIA stapling device in bladder diverticular carcinoma. *J Endourol* 2007;21:772–5. doi:10.1089/end.2006.0348.
- Walker NF, Gan C, Olsburgh J, Khan MS. Diagnosis and management of intradiverticular bladder tumours. *Nat Rev Urol* 2014;11:383–90. doi:10.1038/nrurol.2014.131.
- Zhong H, George S, Kauffman E, Guru K, Azabdaftari G, Xu B. Clinicopathologic characterization of intradiverticular carcinoma of urinary bladder—a study of 22 cases from a single cancer center. *Diagn Pathol* 2014;9:222. doi:10.1186/s13000-014-0222-8.
- Pejčić T, Dzamić Z, Dimitrijević V, Aćimović M, Hadzi-Djokić J. The case of the diverticular bladder tumor treated with diverticulectomy. *Acta Chir Jugosl* 2013;60:91–3. doi:10.2298/aci1301091p.
- Štimac G, Knežević M, Grubišić I, Soipi S, Tomas D, Krušlin B. A rare case of squamous cell carcinoma in urinary bladder diverticulum successfully treated by bladder-sparing surgery. *Acta Clin Croat* 2015;54:363–6.
- Grubišić I, Leniček T, Tomas D, Džombeta T, Trnski D, Tomašković I, et al. Primary osteosarcoma of bladder diverticulum mimicking intradiverticular calculus: a case report. *Diagn Pathol* 2011;6:37. doi:10.1186/1746-1596-6-37.
- Dong WX, Ping YX, Liang WC, Jian LZ, Lin ZJ. Small cell carcinoma of the urinary bladder diverticulum: a case report and review of the literature. *J Cancer Res Ther* 2013;9:151–3. doi:10.4103/0973-1482.110372.
- Yu CC, Huang JK, Lee YH, Chen KK, Chen MT, Chang LS. Intradiverticular tumors of the bladder: surgical implications—an eleven-year review. *Eur Urol* 1993;24:190–6. doi:10.1159/000474292.
- Sah AK, Maharjan B, Adhikari MB, Rana R, Basnet S, Panta R, et al. Radical cystectomy for intradiverticular bladder carcinoma: a case report. *JNMA J Nepal Med Assoc* 2021;59:1069–71. doi:10.31729/jnma.6228.

- [10] Wang JS, Hsieh SP, Jiaan BP, Tseng HH. Human papillomavirus in cyclophosphamide and diverticulum-associated squamous cell carcinoma of urinary bladder: a case report. *Zhonghua Yi Xue Za Zhi (Taipei)* 1996;57:305–9.
- [11] Miñana López B, Fernández Aparicio T, Carrero López V, Caballero Alcántara J, García Luzón A, Pamplona Casamayor M, et al. Intradiverticular bladder tumors. *Actas Urol Esp* 1993;17:523–8 Spanish.
- [12] Di Paolo PL, Vargas HA, Karlo CA, Lakhman Y, Zheng J, Moskowitz CS, et al. Intradiverticular bladder cancer: CT imaging features and their association with clinical outcomes. *Clin Imaging* 2015;39:94–8. doi:10.1016/j.clinimag.2014.10.004.
- [13] Dondalski M, White EM, Ghahremani GG, Patel SK. Carcinoma arising in urinary bladder diverticula: imaging findings in six patients. *AJR Am J Roentgenol* 1993;161:817–20. doi:10.2214/ajr.161.4.8372767.
- [14] Neuzillet Y, Comperat E, Rouprêt M, Larre S, Roy C, Quintens H, et al. Intradiverticular bladder tumours: review of the Cancer Committee of the French Association of Urology. *Prog Urol* 2012;22:495–502 French. doi:10.1016/j.purol.2012.03.008.
- [15] Baniel J, Vishna T. Primary transitional cell carcinoma in vesical diverticula. *Urology* 1997;50:697–9. doi:10.1016/S0090-4295(97)00319-1.
- [16] Voskuilen CS, Seiler R, Rink M, Poyet C, Noon AP, Roghmann F, et al. Urothelial carcinoma in bladder diverticula: a multicenter analysis of characteristics and clinical outcomes. *Eur Urol Focus* 2020;6:1226–32. doi:10.1016/j.euf.2018.12.002.
- [17] Hu B, Satkunasivam R, Schuckman A, Miranda G, Cai J, Daneshmand S. Urothelial carcinoma in bladder diverticula: outcomes after radical cystectomy. *World J Urol* 2015;33:1397–402. doi:10.1007/s00345-014-1472-5.