

Clinical and immunopathological characteristics of autoimmune blistering skin diseases

Gunarić, Anita; Šimić, Dubravka; Marinović, Branka

Source / Izvornik: **Acta Dermatovenerologica Alpina Pannonica et Adriatica, 2023, 32, 141 - 149**

Journal article, Published version

Rad u časopisu, Objavljena verzija rada (izdavačev PDF)

<https://doi.org/10.15570/actaapa.2023.27>

Permanent link / Trajna poveznica: <https://urn.nsk.hr/urn:nbn:hr:105:788179>

Rights / Prava: [In copyright](#)/[Zaštićeno autorskim pravom.](#)

Download date / Datum preuzimanja: **2024-11-09**



Repository / Repozitorij:

[Dr Med - University of Zagreb School of Medicine
Digital Repository](#)



Clinical and immunopathological characteristics of autoimmune blistering skin diseases

Anita Gunarić^{1,2}, Dubravka Šimić², Branka Marinović^{3,4} ✉

¹Department of Dermatology and Venereology, Mostar University Clinical Hospital, Mostar, Bosnia and Herzegovina. ²School of Medicine, University of Mostar, Mostar, Bosnia and Herzegovina. ³Department of Dermatology, Zagreb University Hospital Center, Zagreb, Croatia. ⁴School of Medicine, University of Zagreb, Zagreb, Croatia.

Abstract

Autoimmune blistering skin diseases (AIBDs) encompass several heterogeneous conditions clinically characterized by blisters and erosions on the skin and mucous membranes and are immunopathologically characterized by autoantibodies against structural proteins of the skin. Those proteins are responsible for the intercellular contact between epidermal keratinocytes and adhesion of the basal keratinocytes to the dermis. Therefore, AIBDs are divided into two main groups: intraepidermal (the pemphigus group) and subepidermal (the pemphigoid) groups. The diagnostic methods for AIBDs have made tremendous progress in the last 2 decades due to the availability of standardized serological assays that allow precise diagnosis in most patients. If left untreated, these diseases are potentially life-threatening due to superinfections and loss of body fluids, and in some severe cases due to restricted food intake. Based on the available literature, this paper provides an overview of the clinical and immunopathological characteristics of the most common AIBDs.

Keywords: autoimmunity, skin diseases, vesiculobullous, pemphigus, bullous pemphigoid

Received: 10 October 2023 | Returned for modification: 11 October 2023 | Accepted: 3 November 2023

Introduction

Autoimmune bullous diseases (AIBDs) encompass a variety of organ-specific autoimmune diseases that manifest with cutaneous and/or mucosal blisters and erosions. They are characterized by autoantibodies targeting structural proteins of the skin, which are responsible for the intercellular connection between epidermal keratinocytes and for adhesion of the basal keratinocytes to the dermis. If the autoantibodies are directed against desmosomal structural proteins or intercellular junctions, intraepidermal separation occurs, and damaged hemidesmosomes at the epidermal–dermal junction cause subepidermal cleavage (1–4). Depending on the zone affected, AIBDs are divided into the intraepidermal or pemphigus group and the subepidermal or pemphigoid group (1, 4). The first group of AIBDs contains three major subtypes, including pemphigus vulgaris (PV), pemphigus foliaceus (PF), and pemphigus paraneoplasticus (PNP). The second group comprises bullous pemphigoid (BP), pemphigoid gestationis (PG), epidermolysis bullosa acquisita (EBA), linear IgA bullous dermatosis (LABD), mucous membrane pemphigoid (MMP), and anti-laminin γ -1 pemphigoid (1–5). The incidence of AIBDs differs in different countries and among ethnic groups, with the global average incidence of PV ranging from 0.76 to 16.1 cases per million per year and of BP from 2.5 to 42.8 cases per million per year, making these two the most common AIBDs in the general population (1, 6, 7). Sporadic PF appears in less than one person per million per year in Europe and the United States, whereas the endemic form affects from six to 20 persons per million per year in Brazil and Tunisia (1, 8, 9). The other blistering diseases of the pemphigoid group are also uncommon, with EBA affecting less than 0.5 persons and LABD from 0.5 to 2.3 persons per million per year (1, 10).

Autoimmune blistering diseases are multifactorial diseases

whose pathogenesis is conditioned by the influence of genetic, environmental, and immunologic factors (11–15).

Clinical manifestations of pemphigus diseases

In pemphigus diseases, the autoantibodies primarily target the cadherin-type transmembrane adhesion molecules desmoglein (Dsg) 1 and 3. Dsg and desmocollins provide cohesion between epidermal keratinocytes and are linked intracellularly to the intermediate filament network via different types of plakins. In response to autoantibody binding, cell metabolism, intracellular signaling, and desmosome structure are subject to alterations that cause the loss of cell-to-cell adhesion (acantholysis) and intra-epidermal split formation, resulting in flaccid blisters and erosions in the skin and/or mucous membranes (16).

Pemphigus vulgaris and pemphigus foliaceus

PV is the most frequent representative of the group of pemphigus diseases. The disease manifests particularly during middle age, with an age peak between the fourth and sixth decade of life, but it may even occur in the elderly or in children (17). In more than 70% of patients, the disease starts with lesions on the oral mucosa, which can be explained by the fact that in most of the patients Dsg3 is the first autoantibody detected, and Dsg3 is predominantly expressed in mucosal tissues. The erosions are multiple and present in various sizes and irregular shapes. The blisters are fragile and break easily (2, 6). Other mucous membranes can also be involved, including the conjunctiva, nasal mucosa, pharynx, larynx, esophagus, vagina, penis, and anus. Oral involvement may persist for months before progressing to involvement of the skin or other mucous membranes, but it can also be the only manifestation of the disease (6).

✉ Corresponding author: branka.marinovic@kbc-zagreb.hr

Patients with PV can also have autoantibodies against Dsg1, which is connected with the development of lesions on the skin (18). Based on the extent of affected skin and/or mucous membranes, three types of PV can be distinguished: the mucosal-dominant type with limited cutaneous involvement (Dsg3 autoantibodies are predominant), the mucocutaneous type with both mucosal and cutaneous involvement (Dsg3 and Dsg1 autoantibodies are equally present), and the cutaneous type with predominant anti-Dsg1 and pathogenically weak anti-Dsg3 autoantibodies (18). Cutaneous involvement can be localized or generalized. Most patients develop flaccid blisters with clear content on normal or erythematous skin. The blisters break easily, resulting in painful erosions (2, 6) (Fig. 1). Skin lesions can be observed in any location, but there is a predilection for the trunk, groin, armpits, scalp, and face. The palms and soles are usually spared. These erosions become covered by crusts with no tendency to heal spontaneously. Healing is usually without a scar, but pigmentary changes may be observed (6). Due to the abundance of desmogleins in the hair follicle, the scalp is commonly affected in PV. Erosions, crusts, and scaly plaques can be observed (19). During the active phase of PV, both Nikolsky signs can be elicited. The direct Nikolsky sign describes the phenomenon that, on clinically unchanged perilesional skin, tangential pressure results in shearing away of the epidermis. An additional less specific clinical sign is the indirect Nikolsky sign, whereby an intact blister can be shifted laterally and enlarged by digital pressure (17).

Pemphigus vegetans is a rare clinical variant of PV presenting with vegetating plaques composed of excessive granulation tissue and crusting. The intertriginous areas, scalp, and face are the most common sites for these lesions. Two clinical subtypes have been described. In pemphigus vegetans of Neumann, vegetating plaques evolve from typical pemphigus vulgaris lesions. Pemphigus vegetans of Hallopeau is a milder form of pemphigus vegetans in which bullae and lesions do not precede the vegetating plaques and lesions are usually found in intertriginous areas (2, 20).

Pemphigus herpetiformis is a term that describes PV or PF that manifests with urticarial plaques and cutaneous vesicles arranged in a herpetiform or annular pattern. Pruritus is frequently present. Mucosal involvement is uncommon (21).

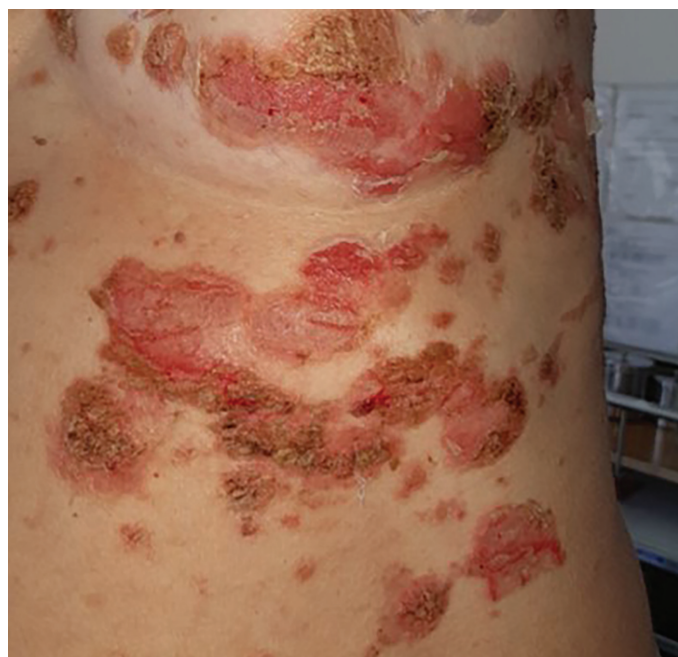

Figure 1 | Multiple erosions on the trunk of a patient with pemphigus vulgaris.

Unlike PV, PF affects only the skin; mucosal lesions do not occur because Dsg1 is mainly expressed in the skin. The skin lesions typically manifest as flaccid, superficial erosions preferentially in seborrheic areas. The erosions are usually covered by scaling, which is due to the detachment of the superficial layers of the epidermis. Skin blisters are rarely seen because of the fragility of the very thin blister roof (Fig. 2). In nearly all PF patients, anti-Dsg1 serum levels closely correlate with disease activity (4).

Endemic PF (Portuguese *fogo selvagem*), a clinical variant of PF, presents with clinical features similar to the idiopathic form of the disease. The disease predominantly affects young women in endemic regions, such as Limão Verde in Brazil and in Tunisia. An environmental trigger is believed to account for this variant of the disease (9).

Another clinical variant of PF is pemphigus erythematosus (Senear–Usher syndrome). Clinical features resemble cutaneous lupus erythematosus with superficial erosions, erythema, and hyperkeratosis. In about 80% of cases, antinuclear antibodies in the medium titer range can be detected, usually in a homogeneous pattern without anti-ds-DNA antibodies (9).

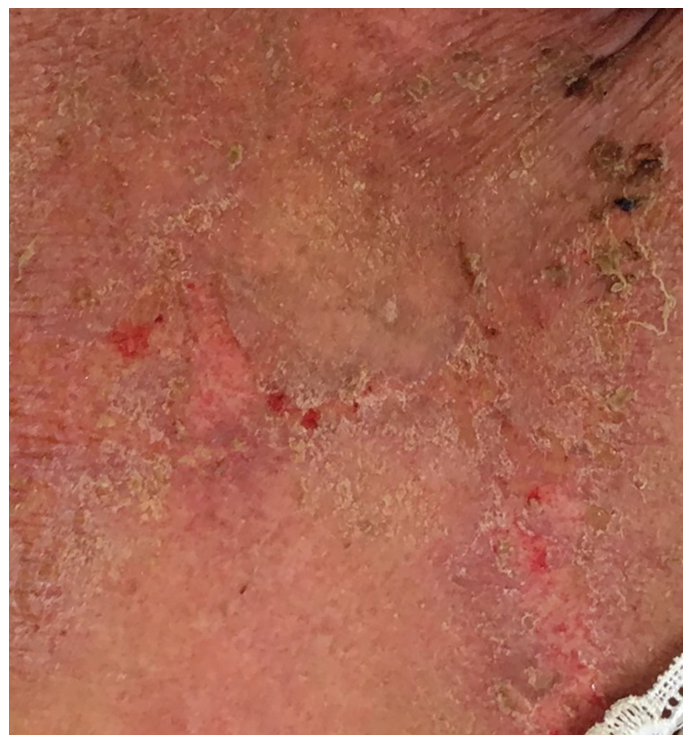

Figure 2 | Pemphigus foliaceus is characterized by erythema, scaling, and crusting, preferentially in seborrheic areas.

Paraneoplastic pemphigus

PNP is an AIBD associated with malignant (or rarely benign) neoplasm. It presents as hemorrhagic stomatitis with extensive mucous membrane erosions, intense pain, and resistance to therapy (Fig. 3). Polymorphic lesions may arise on any part of the skin and may include pemphigus-like lesions with flaccid blisters, erosions, erythema, and crusts; BP-like lesions such as urticarial lesions and tense blisters; erythema multiforme-like lesions; and lichen planus-like lesions presenting as flat scaly papules and intense mucous membrane involvement (22). Nail and periungual lesions (erosion and scaling) are frequently seen. Notably, bronchiolitis obliterans (an inflammation and fibrotic change obstructing the bronchioles), which shows pulmonary T-cell infiltration, occurs as a fatal complication of PNP but not in PV or PF. The prognosis

for PNP is poor, with a 5-year survival rate of 38%, because of infections and evolution of neoplasia (4).

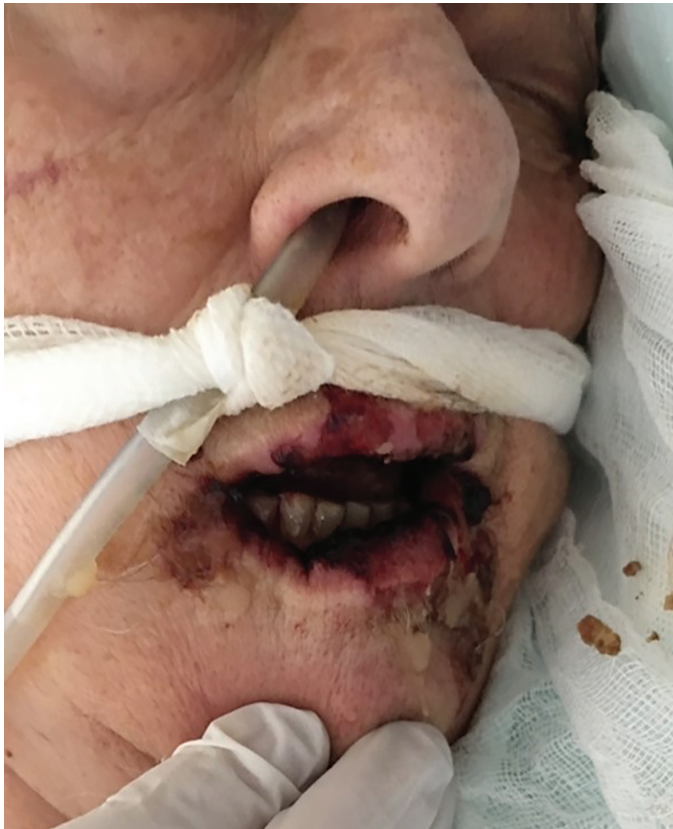

Figure 3 | Erosive mucositis in a patient with paraneoplastic pemphigus associated with bladder cancer.

IgA pemphigus

IgA pemphigus is a rare AIBD characterized by intercellular IgA deposits. IgA pemphigus is considered a distinct clinical entity that includes two subtypes with different histologic features and different IgA deposition patterns in the epidermis: the subcorneal pustular dermatosis and intraepidermal neutrophilic IgA dermatosis types. Both types of IgA pemphigus are characterized by the subacute development of vesicles that evolve into pustules (23). Erythematous plaques usually accompany the vesicles and pustules. A herpetiform, annular, or circinate pattern may be present. The trunk and proximal extremities are common sites for involvement. The scalp, postauricular skin, and intertriginous areas are less common sites for lesion development. Pruritus may be present. The mucous membranes are usually spared (23).

Clinical manifestations of pemphigoid diseases

The heterogenous group of pemphigoid diseases is characterized by subepidermal blister formation, which can occur in the skin and mucous membranes. Circulating autoantibodies target components of the dermal–epidermal junction (DEJ) (24). Because the targeted hemidesmosomal proteins and structural filaments provide contact between the epidermal cells and the basement membrane, the autoimmune reactions cause the epidermis to peel away from the underlying dermis (16). Because pemphigoid diseases cause subepidermal splitting, the blisters are more tense than those of pemphigus diseases. The main disorders include BP, PG, MMP, EBA, LABD, and anti-laminin γ -1 pemphigoid (25).

Bullous pemphigoid

BP is the most common disease in the entire group of AIBDs (16). There is currently no standardized classification of BP. However, it is possible to recognize distinct disease variants according to the age of onset, clinical presentation, and triggering factors (7). Classic BP affects elderly individuals, usually over 70, and presents with itchy, tense blisters over normal skin or an erythematous and edematous background on the trunk and extremities. These lesions mainly affect the axillary folds, lower abdomen, inguinal areas, and inner parts of the thighs (Fig. 4). They may be localized or widespread. Mucosal involvement is not often detected and is reported in 10% to 30% of the cases in which oral, esophageal, and genital lesions develop (7). One of the clinical variants of BP is lichen planus pemphigoid (3). Patients with this condition may present with pruritic violaceous plaques and papules resembling lichen planus lesions, usually on the extremities. Later, blisters and vesicles appear over lichenoid lesions and normal skin. The buccal mucosa may present whitish, lace-like, reticulated lesions (3, 7, 26). Reports of about 20% of patients with BP that never develop blisters have raised the question of whether nonbullous BP should be considered a variant of the disease instead of a prodromic phase. According to a systematic review published in 2017, only 9.8% of patients with nonbullous BP at the onset of the disease develop blisters during their follow-up, and they rarely display mucosal lesions. The most frequent clinical findings include pruritus with erythematous urticarial lesions, excoriations, papules, and nodules (27) (Fig. 5). Another rare manifestation of BP may be exfoliative erythroderma presenting with generalized erythema and desquamation without blisters. In some patients, lesions are localized to areas with burns, venous stasis, radiation exposure, and paralysis (28). Dyshidrosiform pemphigoid shows pompholyx-like vesicles in palmoplantar areas (4).

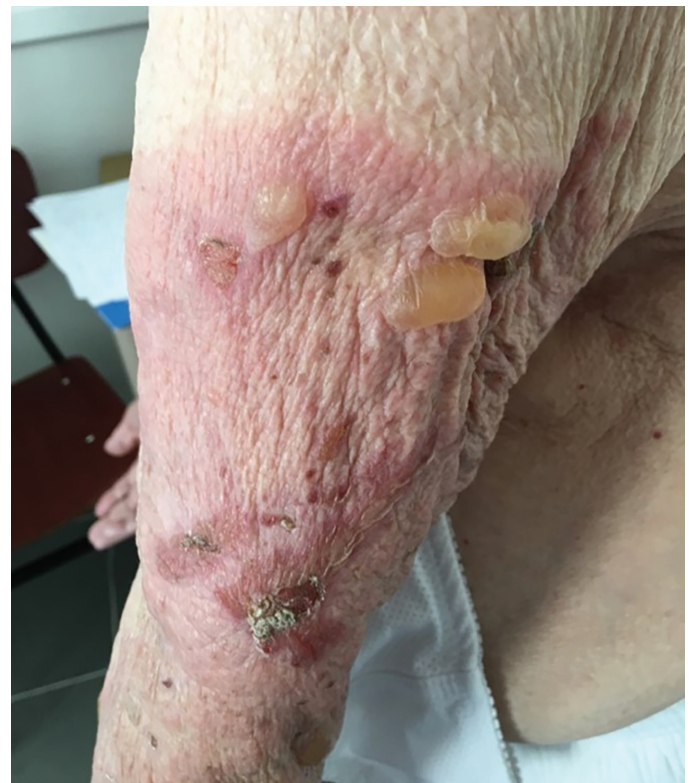

Figure 4 | Arm skin with tense bullae arising on urticarial plaques in a patient with bullous pemphigoid.

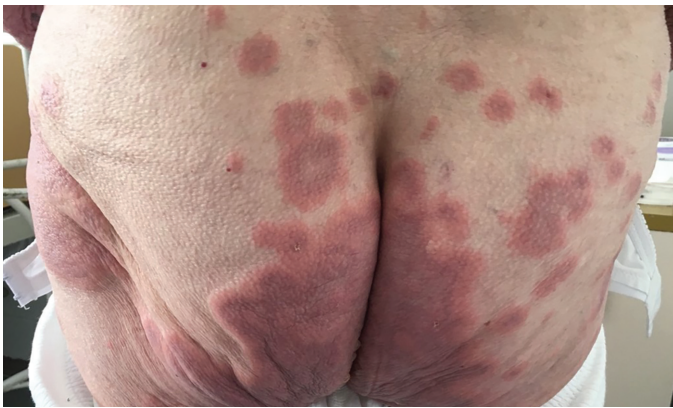

Figure 5 | Erythematous, urticarial plaques on the posterior trunk and gluteal region in a patient with a nonbullous form of bullous pemphigoid.

Pemphigoid gestationis

PG is an AIBD unique to childbearing women, and it primarily arises in the second or third trimester of pregnancy (29). This dermatosis initiates with a prodromal phase characterized by intense pruritus followed by the appearance of urticarial papules and plaques, often of a targetoid or polycyclic shape. In the second stage, grouped vesicles and bullae emerge in the previously affected sites, because of which the disease was formerly known as herpes gestationis (30). The lesions typically occur in the umbilical and periumbilical areas and then spread to the rest of the trunk and extremities, including the palms and soles. Mucous membranes are affected in up to 20% of cases (31). PG tends to recur in subsequent pregnancies, appearing earlier and with a more severe course. It usually takes a self-limited course with spontaneous healing within several weeks after delivery (1).

Mucous membrane pemphigoid

In MMP, lesions predominantly occur in the mucous membranes, whereas skin lesions are typically absent or mild. The most commonly affected site is the oral cavity (the gingiva and buccal mucosa), followed by the nasopharyngeal, laryngeal, esophageal, and genital mucosa. Clinical severity ranges from mild oral lesions to painful mucosal involvement. The prognosis is better if the disease is limited to the oral mucosa. In contrast, the involvement of other mucosae, such as of the eyes, larynx, esophagus, nasopharynx, and genitals, is predictive of a poorer prognosis. Ocular symptoms include chronic conjunctivitis, symblepharon, erosions, and scarring, eventually resulting in blindness. Laryngeal lesions may progress to dyspnea, and esophageal lesions may induce dysphagia (3, 4). Brunsting–Perry pemphigoid is a variant of MMP that affects the skin and especially occurs in elderly men. Usually, there is solitary involvement of the head, forehead, and nape of the neck with blisters and subsequent atrophy and scarring (17).

Linear IgA bullous dermatosis

Although both children and adults develop LABD, differences in the clinical characteristics of the disease are observed among these populations. It represents the most common AIBD of childhood, with age peak of 4 to 5 years. LABD of childhood, in the past also known as a chronic bullous disease of childhood, most

often presents with the acute development of vesicles or bullae on sites of inflamed or noninflamed skin. New blisters often form at the periphery of resolving lesions, resulting in an arciform or annular appearance. Such lesions are frequently described as resembling strings of pearls, crowns of jewels, or rosettes (32). The distribution of skin lesions is usually widespread, involving the trunk, face (particularly the perioral area), genitalia, hands, and feet, but also other sites. The most intensely involved areas are the perineum, lower abdomen, and inner thighs. Affected children may be asymptomatic, but pruritus is common and may be severe. In some patients, intense pruritus heralds recurrences of the disease (32). In adults, LABD primarily affects the perioral area, trunk, gluteal region, and extensor parts of extremities with itchy, tense vesicles and blisters, often in an annular or polycyclic arrangement, on normal-appearing or erythematous skin, and it often looks like BP (1). Mucosal disease occurs in up to 80% of adult patients. Any mucosal surface may be affected, but the oral and ocular mucosa are the most commonly affected mucosal sites (33).

Anti-laminin γ -1 pemphigoid

This is a rare disease that predominantly occurs in middle-aged patients. Anti-laminin γ -1 pemphigoid features erythematous plaques and tense blisters on the trunk as well as the palms and soles. Clinically there can be a resemblance to dermatitis herpetiformis. Scars and milia appear during disease evolution more frequently than in BP. The mucous membranes are involved in about 20% of the patients (34). Association with psoriasis is observed in 40% of cases (17).

Epidermolysis bullosa acquisita

The presence of tense blisters, erosions, and skin fragility characterizes EBA. The disease has two main clinical forms: inflammatory and mechanobullous (classical or non-inflammatory), with the inflammatory form being the most frequent one. In the mechanobullous form of EBA, skin fragility and vesiculobullous lesions occur in areas that are more subject to pressure and trauma, especially the extensor surfaces of the acral regions (hands, feet, elbows, knees, and pretibial region). The lesions usually appear across normal skin without edema or erythema (Fig. 6). They appear soon after trauma to the skin, which can be minimal. Mucous lesions are frequent (Fig. 7). Another clinical characteristic of this form is that, during disease evolution, milia, atrophic scars, hyper- or hypopigmentation, nail dystrophy and loss, cicatricial alopecia, digital contractures, and esophageal stenosis may develop (35).

In the inflammatory form, lesions occur throughout the skin, not only in areas most often subject to trauma, and skin fragility is not so important. It may therefore resemble other subepidermal AIBDs, such as BP, MMP, LABD, and Brunsting–Perry pemphigoid (36). The appearance of scars and milia during disease evolution is less frequent than in the mechanobullous form (35, 36).

Diagnostic procedures

The diagnosis of AIBDs is based on the evaluation of clinical presentation and tissue and serology tests according to the new S2K guidelines of the European Academy of Dermatology and Venereology (1, 4, 16, 37, 38) (Table 1).

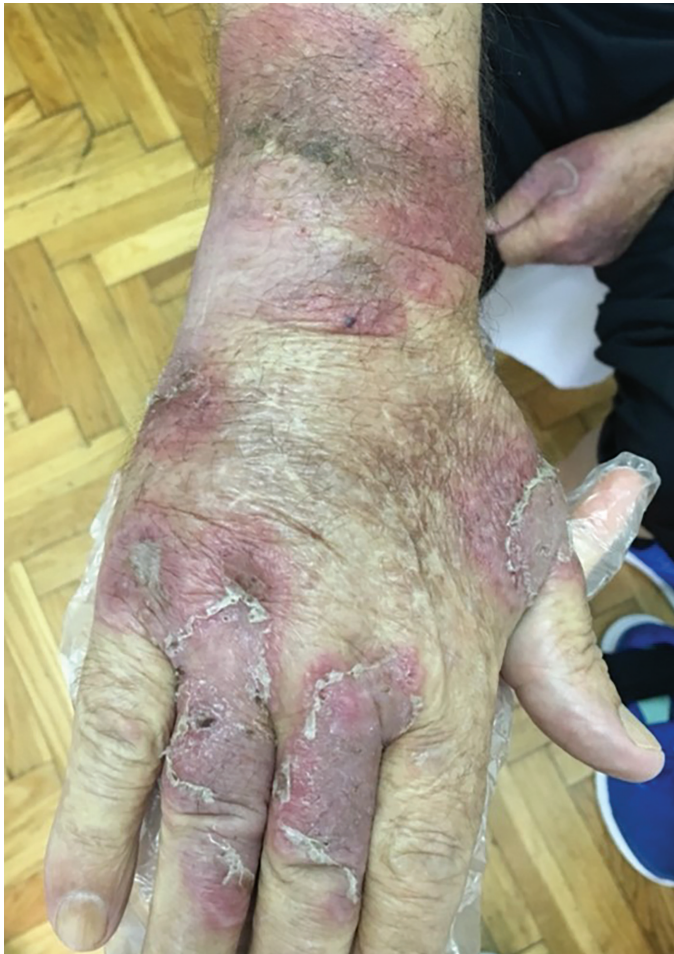

Figure 6 | Skin fragility, blisters, crusts, and erosions in areas that are more subject to pressure and trauma, such as extensor surfaces of the extremities in this patient with a mechanobullous form of epidermolysis bullosa acquisita.

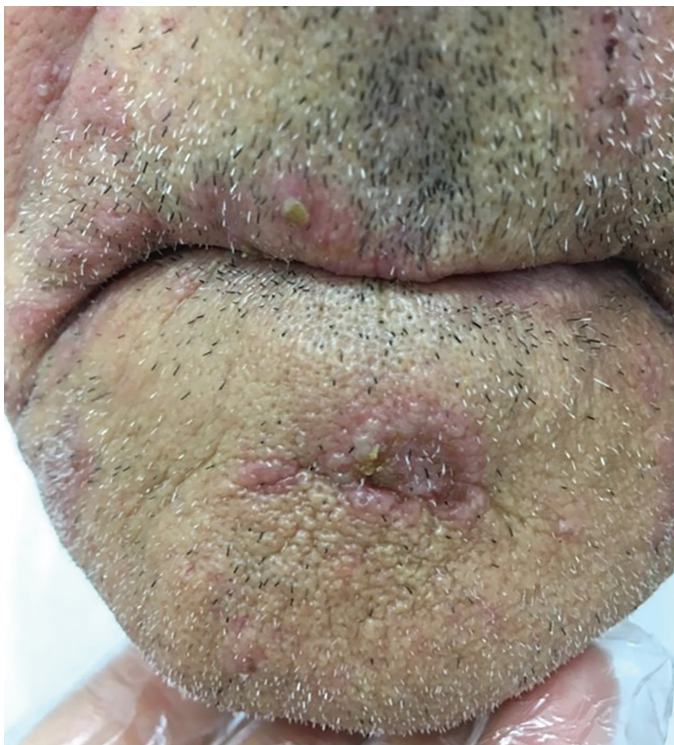

Figure 7 | Tense bullae, erosions, and crusts on the face of a patient with epidermolysis bullosa acquisita.

Histopathology

Tissue investigations comprise histopathology and direct immunofluorescence (DIF) (1). A biopsy of a recent vesicle, or one-third of the peripheral portion of a blister and two-thirds perilesional skin, placed in 4% formaldehyde solution, should be taken for routine histopathological analysis of AIBDs (37). The lesions of pemphigus patients, due to loss of intercellular connections, show acantholysis or blister formation in the suprabasal part of the epidermis in the case of PV, or in its subcorneal part in the case of PF (1).

BP and PG share similar histopathology findings, which depend on the stage of the disease and its clinical symptoms. The non-bullous or urticarial phase of these diseases shows eosinophilic spongiosis and dermal edema with mixed perivascular inflammatory cell infiltrate, whereas in the bullous phase subepidermal fibrin and eosinophil-filled blisters and mixed perivascular inflammatory infiltrate in the dermis are visible (3, 7, 38). The biopsies of EBA and LABD also show subepidermal blisters accompanied by a mixed cellular inflammatory infiltrate in EBA, and neutrophilic infiltrate with microabscess formation in the upper epidermis in LABD (1).

Direct immunofluorescence microscopy

Tissue-bound autoantibodies can be detected with DIF microscopy, the diagnostic gold standard for AIBDs. For DIF microscopy, cryosections of perilesional biopsies (about 1 cm from the blister/erosion) are required and need to be snap frozen and stored at -20°C or conserved in isotonic NaCl or modified Michel's medium until processed (39). The specimen is frozen, sectioned, and incubated with a primary antibody, such as anti-IgG, anti-IgA, anti-IgM, or anti-C3. The primary antibodies are labeled with a fluorophore, most frequently fluorescein isothiocyanate (FITC). The FITC-labeled antibodies are used to detect in vivo (tissue)-bound IgG and other immunodeposits in the patient's skin, and they are visualized using a microscope. The epithelial cell surface staining for in vivo IgG deposition is usually granular or linear, as observed by DIF examination (40). DIF of PV and PF patients shows IgG and/or C3 intercellular epidermal deposits in a honeycomb-like pattern (2, 4, 37) (Fig. 8), whereas linear deposits of C3 and/or IgG along the basement membrane zone (BMZ) are found in BP and PG (1, 3, 38).

Linear staining at the DEJ can further be differentiated into so-called "n-serrated" and "u-serrated" patterns. In an "n-serrated" pattern, the arches are closed at the top, and in a "u-serrated" staining pattern the arches are closed at the bottom, appearing like "growing grass" (39). The pathognomonic DIF finding of EBA is the "u-serrated" pattern because deposits of IgG autoantibodies to type VII collagen in the BMZ are not linear but undulated, whereas IgA and C3 can also be positive (10). Whereas "u-serration" is found in EBA, "n-serration" can be found in all other pemphigoid diseases (39). In LABD, DIF reveals linear IgA deposits along the BMZ and less frequently of IgG, IgM, and C3 (1).

Epithelial cell surface deposits can sometimes be associated with linear deposits of IgG or C3 along the DEJ, suggestive of PNP, pemphigus erythematosus, or the coexistence of pemphigus and pemphigoid. In specialized laboratories, plucked hairs can be utilized for DIF to diagnose pemphigus (37).

Table 1 | Clinical and immunopathological characteristics of autoimmune blistering skin diseases (AIBDs).

	Clinical features	Histopathology	DIF	IIF / preferred substrate	ELISA
PV	Fragile, flaccid bullae on normal or erythematous skin that break to reveal denuded skin with or without overlying crusts. Mucous membranes are often affected; lesions commonly begin in the oral cavity and subsequently spread to the skin.	Suprabasilar acantholysis	Intercellular deposition of IgG C3 in epidermis in a honeycomb-like pattern	Monkey esophagus: intercellular IgG deposits	Anti-Dsg3 Anti-Dsg1
PF	Crusted plaques, puff pastry- or cornflake-like scaling; erosions; superficial, flaccid vesiculobullae in a seborrheic distribution; mucous membranes are spared	Subcorneal acantholysis	Intercellular deposits of IgG C3 in epidermis in a honeycomb-like pattern	Human skin or guinea pig esophagus: intercellular IgG deposits	Anti-Dsg1
PNP	Severe hemorrhagic stomatitis with or without accompanying polymorphous cutaneous lesions in the setting of an underlying malignancy	Suprabasal (intraepidermal) acantholysis, interface dermatitis, and keratinocyte necrosis	Intercellular deposits of IgG C3 in epidermis in a honeycomb-like pattern often with linear, granular BMZ deposition	Rat bladder: intercellular IgG deposits	Anti-plectin Anti-desmoplakins I and II Anti-envoplakin Anti-periplakin Anti-A2ML1 Anti-BP230 Anti-Dsg1 Anti-Dsg3
IgA pemphigus	Vesicles and pustules overlying well-demarcated areas of erythematous skin	SPD subtype: subcorneal pustules IEN subtype: pustules throughout the entire epidermis	Intercellular deposits of IgA in epidermis in a honeycomb-like pattern	Monkey esophagus: intercellular IgA deposits	Anti-desmocolin 1 IgA autoantibodies
BP	Early phase: eczematous or urticarial lesions; Later stages: tense bullae on erythematous base, marked pruritus, erosions, crusts; mucous membranes are rarely affected	Prebullous phase: spongiosis and superficial papillary dermal infiltrate of eosinophils without vesiculation; Bullous phase: eosinophil-rich subepidermal split	Linear deposits of C3 and IgG along the BMZ	Human salt-split skin: anti-BMZ IgG antibodies; epidermal or epidermal and dermal binding	Anti-BP180 Anti-BP230
LPP	Lichenoid lesions consist of pink or violaceous, flat-topped, pruritic polygonal papules and plaques; BP lesions consist of tense bullae and vesicles that are superimposed on the lichenoid lesions, but may also be present on normal skin	Lichenoid lymphocytic interface inflammation, saw-toothing of rete ridges, hypergranulosis, and subepidermal separation with eosinophils	Linear deposits of IgG and or C3 along the BMZ; Lichenoid tissue reaction (scattered and clumped cytoid bodies with multiple conjugates and shaggy BMZ fibrinogen deposits)	Human salt-split skin: anti-BMZ IgG antibodies, epidermal binding	Anti-BP180 (MCW-4 epitope of the NC16A domain)
PG	Prodromal phase: intense pruritus, urticarial papules and plaques; Second phase: grouped vesicles and bullae on umbilical and periumbilical areas, trunk, extremities, palms and soles; mucous membranes are rarely affected	Urticarial phase: eosinophilic spongiosis, spongiotic vesicles, dermal edema with mixed perivascular inflammatory cell infiltrate; Bullous phase: eosinophil-rich subepidermal blisters with mixed cellular infiltrate; eosinophils almost always present	Linear deposits of C3 (100%) and IgG (25%–50%) along the BMZ	Human salt-split skin: anti-BMZ IgG antibodies; epidermal binding	Anti-BP180 (NC16A)

Table 1 | Continued.

	Clinical features	Histopathology	DIF	IIF / preferred substrate	ELISA
MMP	Typically presents as bright red, eroded gingiva with scattered areas of necrosis and shallow ulcerations covered with a pseudomembrane of necrotic epithelium/fibrin	Subepithelial separation with a variable presence of lymphocytes, eosinophils, and neutrophils	Linear deposition of IgG and/or IgA, IgM, and C3 along the BMZ	Human salt-split skin: anti-BMZ IgG and/or IgA antibodies; epidermal binding	Anti-BP230 Anti-BP180 Anti-laminin-332 Anti-laminin gamma1 Anti-integrin alpha6- and/or Anti-integrin beta4-subunit
LABD	Adult type: pruritic, tense vesicles and blisters in annular or polycyclic arrangement, on normal or erythematous skin of the perioral area, trunk, gluteal region, extensor parts of extremities	Subepidermal blisters with neutrophilic infiltrate with or without eosinophils and microabscesses in the upper epidermis	Strong linear deposition of IgA along the BMZ	Human salt-split skin: linear BMZ antibody staining at the blister roof or floor	Anti-BP180 (NC16a/ LAD-1/ LABD-97), anti-BP230
Anti-laminin γ -1 pemphigoid	Tense vesicles and blisters, urticarial plaques, scars, and/or milia on the extremities, trunk with or without palmoplantar and cephalic involvement; mucous membranes can be affected	Subepidermal blister with mild to dense inflammatory infiltrates in the upper dermis composed of neutrophils, eosinophils	Linear deposition of IgG and C3 along the BMZ	Human salt-split skin: linear BMZ antibody staining at the blister floor or at the blister roof and floor	Anti-laminin γ -1 (recombinant monomeric C-terminal fragment)
EBA	Mechanobullous form: erosions and tense vesicles or bullae, dystrophic changes, milia formation and scarring, localized on noninflamed, trauma-prone sites, including extensor surfaces; Inflammatory form: widespread tense bullae or vesicles on a background of inflamed skin and urticarial plaques, clinically may be indistinguishable from BP	Neutrophil-rich or paucinflamatory subepidermal blister	“U-serrated” pattern of IgG deposits in the BMZ, and sometimes of IgM, IgA, IgE, C3 and/or fibrin	Monkey esophagus: linear BMZ antibody staining; human salt-split skin: artificial split floor fluorescence	Anti-type VII collagen (NC1/NC2 domain)

BMZ = basement membrane zone, BP = bullous pemphigoid, C3 = complement 3, DIF = direct immunofluorescence, Dsg = desmoglein, EBA = epidermolysis bullosa acquisita, ELISA = enzyme-linked immunosorbent assay, IEN = intraepidermal neutrophilic, Ig = immunoglobulin, IIF = indirect immunofluorescence, LABD = linear IgA bullous dermatosis, LPP = lichen planus pemphigoides, MMP = mucous membrane pemphigoid, PF = pemphigus foliaceus, PG = pemphigoid gestationis, PNP = paraneoplastic pemphigus, PV = pemphigus vulgaris, SPD = subcorneal pustular dermatosis.

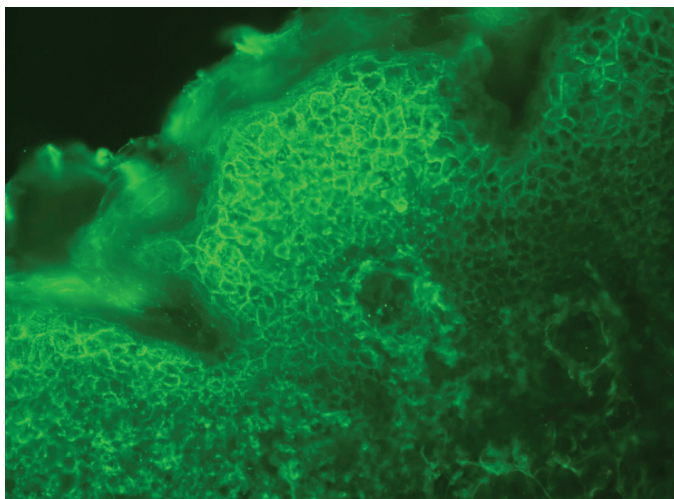


Figure 8 | Direct immunofluorescence microscopy of perilesional skin from a patient with pemphigus vulgaris reveals a characteristic intercellular pattern of IgG antibody binding.

Immune serological tests

Serological tests detect circulating antibodies from the patient's serum to target antigens, including indirect immunofluorescence (IIF) and enzyme-linked immunosorbent assay (ELISA) (1). Conventionally, the serological diagnosis of AIBD follows a multistep approach that is based on initial IIF screening using one or two tissue substrates, followed by individual antigen-specific assays (ELISA, immunoblot) that correspond to the clinical suspicion and the IIF screening results (16). Meanwhile, alternative approaches for highly efficient and expeditious testing are available utilizing multiparametric analysis tools (41).

Indirect immunofluorescence using tissue substrates

IIF tests are performed using a particular substrate containing the target antigen that is incubated with serial dilutions of serum containing the primary antibodies. Various substrates are used,

including monkey, rabbit, guinea pig, and human esophagus, normal human skin, monkey and rat bladder epithelium, amnion epithelium, and salt-split skin, depending on the suspected clinical diagnosis. FITC-labeled secondary antibodies are added to bind the primary antibodies and allow their visualization using a fluorescent microscope (16, 40). The most frequently used substrates are monkey esophagus and human split skin (39). IgG antibodies from the PV patient's serum can be better detected on monkey esophagus because it has a greater density of Dsg3. In comparison, normal human skin is preferably used in PF patients for greater density of Dsg1 (4, 37). On monkey esophagus, autoantibodies in pemphigus reveal intercellular labeling of the epithelium and linear staining of the DEJ in pemphigoid diseases (39). The tissue substrate with the highest sensitivity for autoantibodies in pemphigoid diseases is 1M NaCl split human skin (salt-split skin). Here, antibodies bind to either the epidermal ("roof") or dermal ("floor") side of the artificial blister. "Floor"-binding antibodies can be detected in EBA, anti-laminin γ 1 pemphigoid, and anti-laminin 332 MMP. "Roof"-binding antibodies target BP180 and BP230, and are observed in BP, LABD, PG, and anti-BP180-type MMP. The most sensitive substrates for detecting anti-plakin reactivity are monkey and rat bladder epithelium. In PG, the complement fixation test detects complement-fixing IgG on human salt-split skin (39).

Recombinant monospecific substrates in indirect immunofluorescence

Recombinant IIF assays are based on BIOCHIP technology (Euroimmun, Lübeck, Germany), in which the substrates are coated onto millimeter-sized BIOCHIPS and arranged on the reaction fields of microscope slides. The slides are incubated using the Titerplane technique, which provides parallel incubation of multiple samples under standardized, identical conditions (16). Two types of recombinant IIF substrates can be distinguished. In the first case, the target antigen is expressed in the human cell line HEK293, which provides authentic conformational folding and post-translational modification. Because transfected and mock-transfected control cells are coated onto the BIOCHIPS side by side, it is straightforward to distinguish true-positive sera containing antigen-specific antibodies (smooth to fine granular cytosolic fluorescence only in the subset of transfected cells) from sera reacting against other cell components (nuclear or cytoplasmic staining of all cells). Available recombinant cell-based substrates for AIBD serology include Dsg1, Dsg3, BP230, and type VII collagen (16). In the second case, purified recombinant antigens (e.g., BP180-NC16A-4X and GAF-3X) are coated directly onto the BIOCHIPS. If a positive serum sample is applied, the antigenic areas will fluoresce in a particular pattern (e.g., diamonds or circles) against a dark background (16).

Multiparametric BIOCHIP mosaics in indirect immunofluorescence

IIF-based assays employing recombinant forms of the target antigens are available as multivariant assays and thus offer a single-step method for diagnosing AIBDs. These assays are based on the BIOCHIP mosaic technology using normal-sized laboratory slides with five to 10 incubation fields. The serum sample is loaded onto an incubation field consisting of several miniature biochips coated with various substrates (e.g., monkey esophagus, salt-split

skin, recombinant BP180 NC16A, or HEK293 cells recombinantly expressing Dsg1, Dsg3, or BP230) (39). It has been shown that the sensitivity and specificity of BIOCHIP mosaic analysis is comparable to that of ELISA systems regarding AIBD (42).

Enzyme-linked immunosorbent assay

ELISA systems allow the identification and quantification of autoantibodies against specific autoantigens. They are applied for both diagnosis groups and monitoring of disease activity during the disease process (39). Commercial ELISA systems (MBL, Euroimmun) are available to detect autoantibodies against Dsg1 and Dsg3 in pemphigus and against envoplakin in PNP (16). In pemphigoid diseases, commercial ELISA (MBL, Euroimmun) includes BP180, BP230, and type VII collagen. Notably, the highest detection rate among BP patients is achieved by combining the ELISA results for anti-BP180 and anti-BP230 (87%–100%), reflecting a diagnostic added value compared to mere anti-BP180 testing (16). Therefore, in cases with clinically suspected BP, in which anti-BP180 testing is negative, it is recommended to analyze serum reactivity against BP230 (38). In addition, less standardized in-house ELISA systems are applied in specialized laboratories, including rare parameters, such as anti-laminin γ 1, anti-desmocolin, anti-laminin 332, and anti-BP180 (various forms) (16).

In addition, two multivariant ELISA systems compiled of the individual assays, including recombinant Dsg1 and Dsg3, BP180 NC16A, BP230, type VII collagen, and (only in one system) envoplakin, are widely available (39).

Immunoblotting and immunoprecipitation

Immunoblotting and immunoprecipitation are performed using recombinant proteins or extracts of the dermis, epidermis, bovine gingiva, amnion membrane, or cultured keratinocytes (43). These systems are part of the diagnostic algorithm for AIBD in some laboratories. They can be used for detecting anti-p200 autoantibodies, anti-laminin γ 1 autoantibodies, antibodies against C-terminal stretches of BP180, and the soluble ectodomain of BP180 (LAD-1), as well as autoantibodies against cell-derived forms of envoplakin, periplakin, desmoplakin, BP180, BP230, α 4 β 6-integrin, laminin 332, and type VII collagen. The latter test systems are, however, only available in specialized laboratories (39).

Management

Early diagnosis and differentiation of AIBD is crucial for initiating appropriate treatment (16). The primary objective is control and healing of the bullous skin and/or mucous lesions while minimizing serious side-effects of treatment as much as possible (45). In most AIBD entities (e.g., BP, LABD, and anti-laminin γ 1 pemphigoid), systemic corticosteroids in combination with further immunosuppressants/immunomodulants are sufficient to induce clinical remission. In contrast, treatment of pemphigus remains challenging, as reflected by a mortality of 8% to 42% in mucocutaneous PV (44). However, the prognosis has improved due to the development of new therapy options, including immunoadsorption, intravenous immunoglobulins, and anti-CD20 monoclonal antibodies (16). In PNP and anti-laminin 332 mucous membrane pemphigoid, the disease prognosis may be unfavorable due to associated neoplasia (12, 13, 16).

Conclusions

AIBDs constitute a diverse group of immune-mediated, rare, and severe disorders that are clinically recognizable by vesiculobullous cutaneous and/or mucosal lesions. The blistering diseases arise as a consequence of the patient's autoantibodies directed

against cell adhesion molecules. The diagnosis of AIBDs has made tremendous progress in the last decade due to the availability of standardized serological assays that, with knowledge of the clinical picture, allow the diagnosis in most patients. This review demonstrates the heterogeneous clinical spectrum and immunopathological characteristics of AIBDs.

References

- Vičić M, Marinović B. Autoimmune bullous diseases in pregnancy: an overview of pathogenesis, clinical presentations, diagnostics and available therapies. *Ital J Dermatol Venereol.* 2023;158:99–109.
- Montagnon CM, Tolkachjov SN, Murrell DF, Camilleri MJ, Lehman JS. Intraepithelial autoimmune blistering dermatoses: clinical features and diagnosis. *J Am Acad Dermatol.* 2021;84:1507–19.
- Montagnon CM, Tolkachjov SN, Murrell DF, Camilleri MJ, Lehman JS. Subepithelial autoimmune blistering dermatoses: clinical features and diagnosis. *J Am Acad Dermatol.* 2021;85:1–14.
- Egami S, Yamagami J, Amagai M. Autoimmune bullous skin diseases, pemphigus and pemphigoid. *J Allergy Clin Immunol.* 2020;145:1031–47.
- Kridin K. Subepidermal autoimmune bullous diseases: overview, epidemiology, and associations. *Immunol Res.* 2018;66:6–17.
- Porro AM, Seque CA, Ferreira MC, Enokihara MM. Pemphigus vulgaris. *An Bras Dermatol.* 2019;94:264–78.
- Miyamoto D, Santi CG, Aoki V, Maruta CW. Bullous pemphigoid. *An Bras Dermatol.* 2019;94:133–46.
- Kridin K. Pemphigus group: overview, epidemiology, mortality, and comorbidities. *Immunol Res.* 2018;66:255–70.
- Hans-Filho G, Aoki V, Bittner NR, Bittner GC. Fogo selvagem: endemic pemphigus foliaceus. *An Bras Dermatol.* 2018;93:638–50.
- Amber KT, Murrell DF, Schmidt E, Joly P, Borradori L. Autoimmune subepidermal bullous diseases of the skin and mucosae: clinical features, diagnosis, and management. *Clin Rev Allergy Immunol.* 2018;54:26–51.
- Yang M, Wu H, Zhao M, Chang C, Lu Q. The pathogenesis of bullous skin diseases. *J Transl Autoimmun.* 2019;2:100014.
- Montagnon CM, Lehman JS, Murrell DF, Camilleri MJ, Tolkachjov SN. Intraepithelial autoimmune blistering dermatoses disease activity assessment and therapy. *J Am Acad Dermatol.* 2021;84:1523–37.
- Montagnon CM, Lehman JS, Murrell DF, Camilleri MJ, Tolkachjov SN. Subepithelial autoimmune blistering dermatoses disease activity assessment and therapy. *J Am Acad Dermatol.* 2021;85:18–27.
- Ludwig RJ, Müller S, Marques A, Recke A, Schmidt E, Zillikens D, et al. Identification of quantitative trait loci in experimental epidermolysis bullosa acquisita. *J Invest Dermatol.* 2012;132:1409–15.
- Fortuna G, Marinkovich MP. Linear immunoglobulin A bullous dermatosis. *Clin Dermatol.* 2012;30:38–50.
- Saschenbrecker S, Karl I, Komorowski L, Probst C, Dährnich C, Fechner K, et al. Serological diagnosis of autoimmune bullous skin diseases. *Front Immunol.* 2019;10:1974.
- Kneisel A, Hertl M. Autoimmune bullous skin diseases. Part 1: clinical manifestations. *J Dtsch Dermatol.* 2011;9:844–56.
- Kasperkiewicz M, Ellebrecht CT, Takahashi H, Yamagami J, Zillikens D, Payne AS, et al. Pemphigus. *Nat Rev Dis Primer.* 2017;3:17026.
- Sar-Pomian M, Rudnicka L, Olszewska M. The significance of scalp involvement in pemphigus: a literature review. *Biomed Res Int.* 2018;2018:6154397.
- Ruocco V, Ruocco E, Caccavale S, Gambardella A, Lo Schiavo A. Pemphigus vegetans of the folds (intertriginous areas). *Clin Dermatol.* 2015;33:471–6.
- Kasperkiewicz M, Kowalewski C, Jabłońska S. Pemphigus herpetiformis: from first description until now. *J Am Acad Dermatol.* 2014;70:780.
- Czernik A, Wiczorek M. Paraneoplastic pemphigus: a short review. *Clin Cosmet Investig Dermatol.* 2016;9:291–5.
- Hashimoto T, Teye K, Ishii N. Clinical and immunological studies of 49 cases of various types of intercellular IgA dermatosis and 13 cases of classical subcorneal pustular dermatosis examined at Kurume University. *Br J Dermatol.* 2017;176:168.
- Goletz S, Zillikens D, Schmidt E. Structural proteins of the dermal-epidermal junction targeted by autoantibodies in pemphigoid diseases. *Exp Dermatol.* 2017;26:1154–62.
- Di Lernia V, Casanova DM, Goldust M, Ricci C. Pemphigus vulgaris and bullous pemphigoid: update on diagnosis and treatment. *Dermatol Pract Concept.* 2020;10:e2020050.
- Washio K, Nakamura A, Fukuda S, Hashimoto T, Horikawa T. A case of lichen planus pemphigoides successfully treated with a combination of cyclosporine A and prednisolone. *Case Rep Dermatol.* 2013;5:84–7.
- Lamberts A, Meijer JM, Jonkman MF. Nonbullous pemphigoid: a systematic review. *J Am Acad Dermatol.* 2018;78:989–95.
- Miyamoto D, Batista DI, Santi CG, Maruta CW, Delgado L, Aoki V. Exfoliative erythroderma as a clinical manifestation of autoimmune bullous diseases. *Int J Dermatol.* 2016;55:112–14.
- Ceryn J, Siekierko A, Skibińska M, Doss N, Narbutt J, Lesiak A. Pemphigoid gestationis—case report and review of literature. *Clin Cosmet Investig Dermatol.* 2021;14:665–70.
- Sävervall C, Sand FL, Thomsen SF. Pemphigoid gestationis: current perspectives. *Clin Cosmet Investig Dermatol.* 2017;10:441–9.
- Lipozenčić J, Ljubojević S, Bukvić-Mokos Z. Pemphigoid gestationis. *Clin Dermatol.* 2012;30:51–5.
- Venning VA. Linear IgA disease: clinical presentation, diagnosis, and pathogenesis. *Dermatol Clin.* 2011;29:453.
- Vico-Alonso C, Palencia-Pérez S. Linear IgA bullous dermatosis. *N Engl J Med.* 2020;382:2248.
- Goletz S, Hashimoto T, Zillikens D, Schmidt E. Anti-p200 pemphigoid. *J Am Acad Dermatol.* 2014;71:185–91.
- Miyamoto D, Gordilho JO, Santi CG, Porro AM. Epidermolysis bullosa acquisita. *An Bras Dermatol.* 2022;97:409–23.
- Prost-Squarcioni C, Caux F, Schmidt E, Jonkman MF, Vassileva S, Kim SC, et al. International bullous diseases group: consensus on diagnostic criteria for epidermolysis bullosa acquisita. *Br J Dermatol.* 2018;179:30–41.
- Joly P, Horvath B, Patsatsi A, Uzun S, Bech R, Beissert S, et al. Updated S2K guidelines on the management of pemphigus vulgaris and foliaceus initiated by the European Academy of Dermatology and Venereology (EADV). *J Eur Acad Dermatol Venereol.* 2020;34:1900–13.
- Borradori L, Van Beek N, Feliciani C, Tedbirt B, Antiga E, Bergman R, et al. Updated S2 K guidelines for the management of bullous pemphigoid initiated by the European Academy of Dermatology and Venereology (EADV). *J Eur Acad Dermatol Venereol.* 2022;36:1689–704.
- Witte M, Zillikens D, Schmidt E. Diagnosis of autoimmune blistering diseases. *Front Med (Lausanne).* 2018;5:296.
- Harrell J, Rubio XB, Nielson C, Hsu S, Motaparthy K. Advances in the diagnosis of autoimmune bullous dermatoses. *Clin Dermatol.* 2019;37:692–712.
- van Beek N, Dahnrich C, Johannsen N, Lemcke S, Goletz S, Hubner F, et al. Prospective studies on the routine use of a novel multivariant enzyme-linked immunosorbent assay for the diagnosis of autoimmune bullous diseases. *J Am Acad Dermatol.* 2017;76:889–94.
- van Beek N, Rentzsch K, Probst C, Komorowski L, Kasperkiewicz M, Fechner K, et al. Serological diagnosis of autoimmune bullous skin diseases: prospective comparison of the BIOCHIP mosaic-based indirect immunofluorescence technique with the conventional multi-step single test strategy. *Orphanet J Rare Dis.* 2012;7:49.
- Xuan RR, Yang A, Murrell DF. New biochip immunofluorescence test for the serological diagnosis of pemphigus vulgaris and foliaceus: a review of the literature. *Int J Womens Dermatol.* 2018;4:102–8.
- Harman KE, Brown D, Exton LS, Groves RW, Hampton PJ, Mohd Mustapa MF, et al. British Association of Dermatologists guidelines for the management of pemphigus vulgaris 2017. *Br J Dermatol.* 2017;177:1170–201.
- Chu KY, Yu HS, Yu S. Current and innovated managements for autoimmune bullous skin disorders: an overview. *J Clin Med.* 2022;11:3528.