

# Two sisters with one disease: Giant cell arteritis within one family

---

Barešić, Marko; Šimunić, Lucija; Šukara, Goran; Mayer, Miroslav; Anić, Branimir

Source / Izvornik: **Archives of Rheumatology, 2023, 38, 662 - 664**

Journal article, Published version

Rad u časopisu, Objavljena verzija rada (izdavačev PDF)

<https://doi.org/10.46497/ArchRheumatol.2023.10192>

Permanent link / Trajna poveznica: <https://urn.nsk.hr/urn:nbn:hr:105:820752>

Rights / Prava: [Attribution 4.0 International](#)/[Imenovanje 4.0 međunarodna](#)

Download date / Datum preuzimanja: **2024-07-13**



Repository / Repozitorij:

[Dr Med - University of Zagreb School of Medicine  
Digital Repository](#)



## Two sisters with one disease: Giant cell arteritis within one family

Marko Barešić , Lucija Šimunić , Goran Šukara , Miroslav Mayer , Branimir Anić 

*Division of Clinical Immunology and Rheumatology, Department of Internal Medicine, School of Medicine, University Hospital Center, Zagreb, Zagreb, Croatia*

**Correspondence:** Marko Barešić, MD.

**E-mail:** mbaresic@kbc-zagreb.hr

**Received:** February 26, 2023

**Accepted:** March 30, 2023

**Published online:** June 14, 2023

**Citation:** Barešić M, Šimunić L, Šukara G, Mayer M, Anić B. Two sisters with one disease: Giant cell arteritis within one family. Arch Rheumatol 2023;38(4):662-664. doi: 10.46497/ArchRheumatol.2023.10192.

*This is an open access article under the terms of the Creative Commons Attribution-NonCommercial License, which permits use, distribution and reproduction in any medium, provided the original work is properly cited and is not used for commercial purposes (<http://creativecommons.org/licenses/by-nc/4.0/>).*

Giant cell arteritis (GCA) is the most common of the vasculitides, with the incidence varying from 21.57 in Scandinavia to 7.26 per 100,000 in the rest of Europe. GCA follows a polygenic inheritance pattern and rare familiar clustering.<sup>1-6</sup> Thomsen et al.<sup>7</sup> reported a study in which only 1% of observed individuals diagnosed with GCA had a first-degree relative with GCA. Moreover, calculated familiar concordant risk for GCA was 2.14, and it was only significant for individuals having a female relative affected. A similar study showed the concordant familiar risk for ankylosing spondylitis, systemic lupus erythematosus, Sjögren syndrome, systemic sclerosis, polymyositis/dermatomyositis, and rheumatoid arthritis to be 18.42, 14.04, 8.63, 4.50, 4.03, and 3.03, respectively.<sup>9</sup> Difference in familiar risk for concordant disease, presented as SIR (standardized incidence ratio), is shown in Table 1 using parents and siblings as probands, using both if applicable.<sup>9</sup> Herein, we report on the cases of two sisters, who had GCA

diagnosed within less than a year, and their brother.

**Case 1-** A 67-year-old female with an unremarkable medical history and positive family history of pancreatic cancer was admitted to our department following one month of fever without any infection signs. The patient complained about unilateral blurry vision, malaise, and weight-loss. Laboratory results showed elevated C-reactive protein (CRP) and erythrocyte sedimentation rate (ESR) without leukocytosis and normocytic anemia. The patient continued to spike fever despite being administered wide-spectrum antibiotics. Detailed work-up and computed tomography were performed and showed inflammatory changes in subclavian and axillary arteries. An inflammatory signal was later confirmed using color Doppler ultrasonography in both subclavian arteries and the right axillary artery, while temporal arteries showed no signs of inflammation.

**Case 2-** A 63-year-old female with a positive family history of pancreatic cancer was hospitalized after several months of low-grade fever, fatigue, weight loss, and intermittent upper abdominal pain spreading to the back. The patient complained of left temporal headache. Initial laboratory workup also revealed elevated CRP and ESR without leukocytosis, discrete normocytic anemia, and no other pathological results. Color Doppler ultrasonography was done, and it showed signs of inflammation in both temporal arteries (halo sign).

**Case 3-** A 58-year-old male with an unremarkable medical history, recently reported blurred vision, and progressive poor eyesight in the right eye presented to our clinic. The patient

**Table 1.** Familiar risk of concordant autoimmune disease

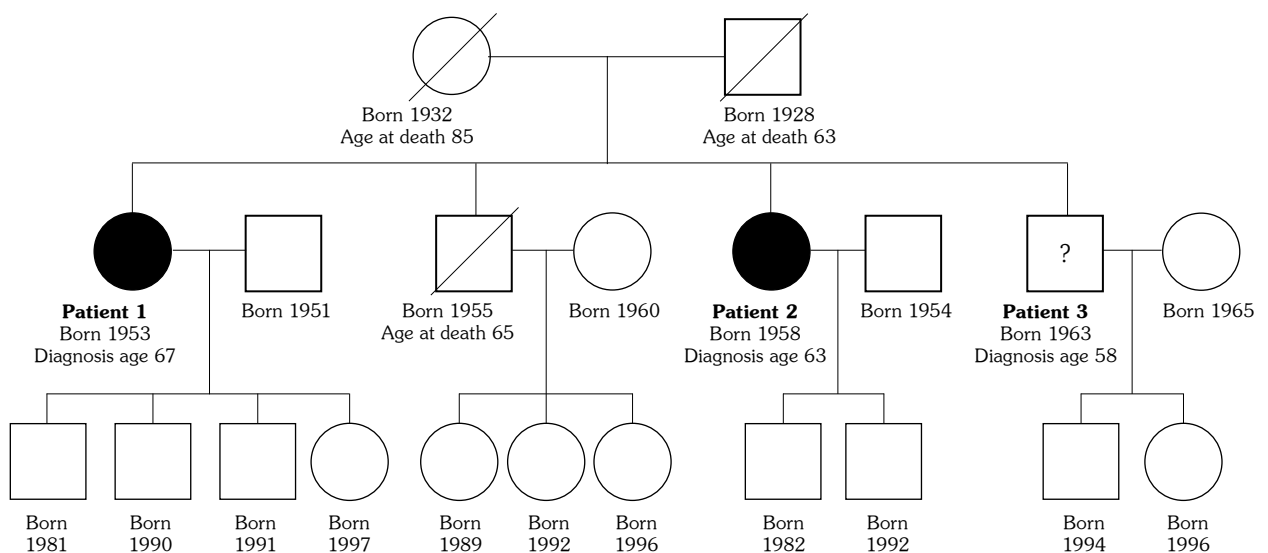
| Autoimmune disease                   | SIR (standardized incidence ratio) |               |                           |
|--------------------------------------|------------------------------------|---------------|---------------------------|
|                                      | Parents only                       | Siblings only | Both parents and siblings |
| Giant cell arteritis (GCA)           | 2.04                               | 1.94          | N/A                       |
| Rheumatoid arthritis (RA)            | 2.64                               | 2.86          | 7.17                      |
| Ankylosing spondylitis (AS)          | 16.12                              | 16.57         | 80.28                     |
| Polymyositis/dermatomyositis (PM/DM) | N/S                                | 7.39          | N/A                       |
| Sjögren syndrome (SS)                | 8.01                               | 9.41          | 24.69                     |
| Systemic sclerosis (SSc)             | 4.28                               | 3.92          | N/A                       |
| Systemic lupus erythematosus (SLE)   | 13.30                              | 13.55         | 19.53                     |

For PM/DM only sibling risk was significant so parent risk is not shown (N/S); Familiar risk for GCA, PM/DM and SSc for individuals with both parents and siblings affected is not available (N/A) since no such cases were observed.<sup>7,9</sup>

is currently under ophthalmologic workup, and the differential diagnosis includes ischemic optic neuropathy.

Patient 1 is the older sister of Patient 2, and Patient 3 is their brother (Figure 1). Patients 1 and 2 were diagnosed with GCA, started on glucocorticoids, and are currently in remission on low-dose oral methylprednisolone. Patient 3 is still under examination, and his clinical symptoms might include elements of GCA.

In conclusion, the majority of the studies about familiar risk of GCA are done in the North-European area, in which population the incidence of GCA is higher in general. Further studies of familiar risk are required in populations with lower background incidence of disease. GCA should be considered in elderly patients presenting with unexplained inflammatory condition, particularly if a first-degree relative with concordant disease is present.



**Figure 1.** Family tree. Patients 1 and 2 (black circles) diagnosed with GCA and Patient 3 (cuboid with the question mark) with probable GCA. Other deceased and living members of the family shown as circles (females) and cuboids (males). GCA: Giant cell arteritis.

**Patient Consent for Publication:** A written informed consent was obtained from each patient.

**Data Sharing Statement:** The data that support the findings of this study are available from the corresponding author upon reasonable request.

**Author Contributions:** Idea/concept: M.B., B.A.; Design: M.B., G.Š.; Control/supervision: M.B., G.Š., M.M.; Data collection and/or processing: L.Š., M.M.; Analysis and/or interpretation, literature review: L.Š.; Writing the article: M.B., L.Š., G.Š.; Critical review: M.B., B.A.; References and fundings: M.M., B.A., L.Š.; Materials: M.B., L.Š.

**Conflict of Interest:** The authors declared no conflicts of interest with respect to the authorship and/or publication of this article.

**Funding:** The authors received no financial support for the research and/or authorship of this article.

## REFERENCES

1. Lacy A, Nelson R, Koyfman A, Long B. High risk and low prevalence diseases: Giant cell arteritis. *Am J Emerg Med* 2022;58:135-40. doi: 10.1016/j.ajem.2022.05.042.
2. Greigert H, Genet C, Ramon A, Bonnotte B, Samson M. New insights into the pathogenesis of giant cell arteritis: Mechanisms involved in maintaining vascular inflammation. *J Clin Med* 2022;11:2905. doi: 10.3390/jcm11102905.
3. West SG, Koltenbach J. *Rheumatology secrets*. 4th ed. Philadelphia: Elsevier; 2019.
4. Bond M, Tomelleri A, Buttgerit F, Matteson EL, Dejaco C. Looking ahead: Giant-cell arteritis in 10 years time. *Ther Adv Musculoskelet Dis* 2022;14:1759720X221096366. doi: 10.1177/1759720X221096366.
5. Robinette ML, Rao DA, Monach PA. The immunopathology of giant cell arteritis across disease spectra. *Front Immunol* 2021;12:623716. doi: 10.3389/fimmu.2021.623716.
6. Ponte C, Grayson PC, Robson JC, Suppiah R, Gribbons KB, Judge A, et al. 2022 American College of Rheumatology/EULAR classification criteria for giant cell arteritis. *Ann Rheum Dis* 2022;81:1647-53. doi: 10.1136/ard-2022-223480.
7. Thomsen H, Li X, Sundquist K, Sundquist J, Försti A, Hemminki K. Familial risks between giant cell arteritis and Takayasu arteritis and other autoimmune diseases in the population of Sweden. *Sci Rep* 2020;10:20887. doi: 10.1038/s41598-020-77857-7.
8. Hussain S. A new conceptual framework for investigating complex genetic disease. *Front Genet* 2015;6:327. doi: 10.3389/fgene.2015.00327.
9. Thomsen H, Li X, Sundquist K, Sundquist J, Försti A, Hemminki K. Familial associations for rheumatoid autoimmune diseases. *Rheumatol Adv Pract* 2020;4:rkaa048. doi: 10.1093/rap/rkaa048.